A 24-year-old healthy college student enrolls into a research study investigating the factors affecting blood oxygen content. The study is performed at sea level, on room air with no additional oxygen. A technique is devised to measure the accurate partial pressure of oxygen in the blood as it flows through the circulation. Blood samples are obtained from the vena cavae, alveolar capillaries, and the aorta. All data are plotted, and the curve obtained is shown in the graph below.

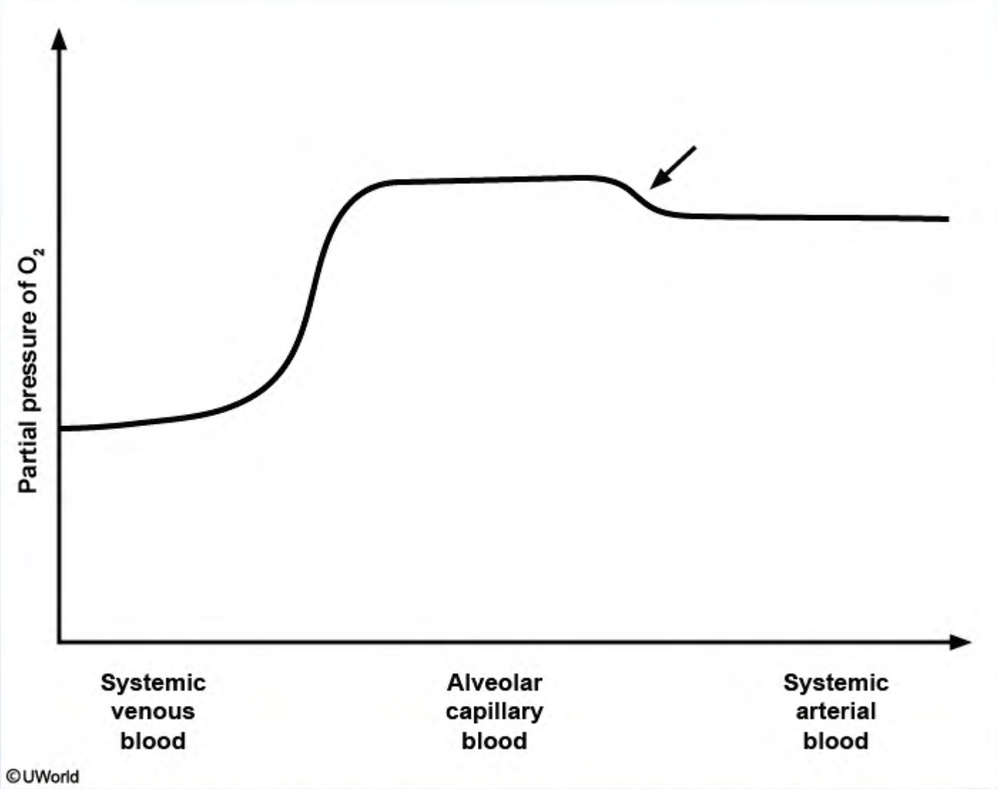

Which of the following factors most likely explains the change in partial pressure indicated by the arrow?

- A. Diffusion-limited oxygenation
- B. Increased dead space ventilation

https://t.me/USMLEWorldStep1

A 24-year-old healthy college student enrolls into a research study investigating the factors affecting blood oxygen
conter
measu
obtain
shown

Exhibit Display

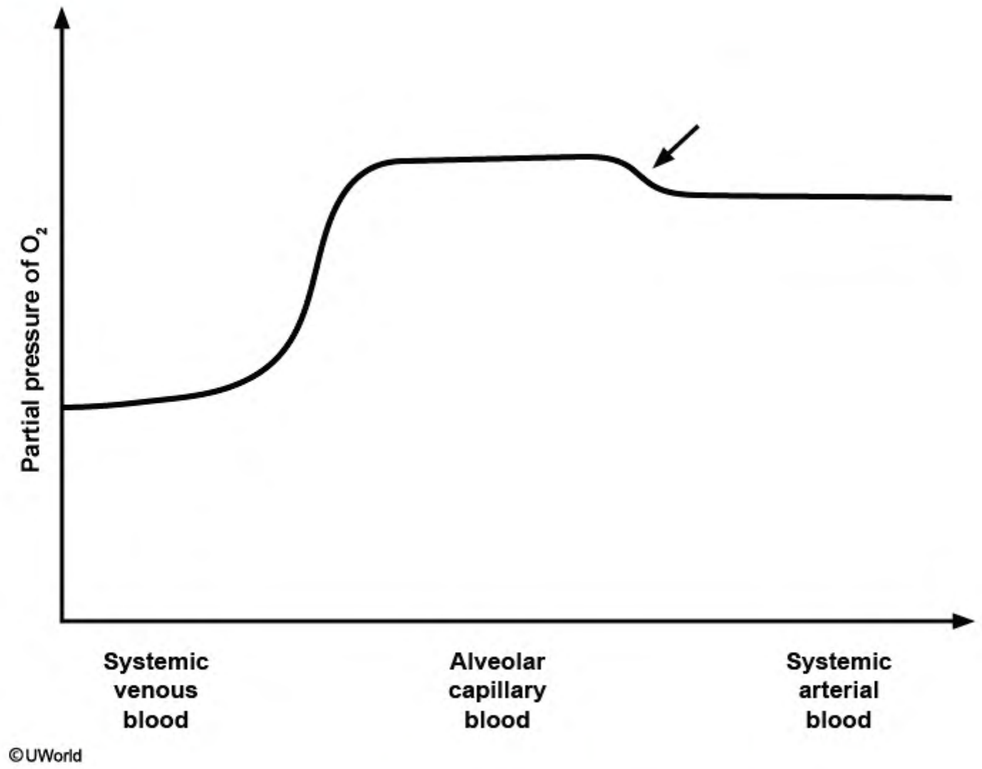

Zoom In | Zoom Out | Reset | New | Existing | My Notebook

Which

A. Diffusion-limited oxygenation

B. Increased dead space ventilation

https://t.me/USMLEWorldStep1

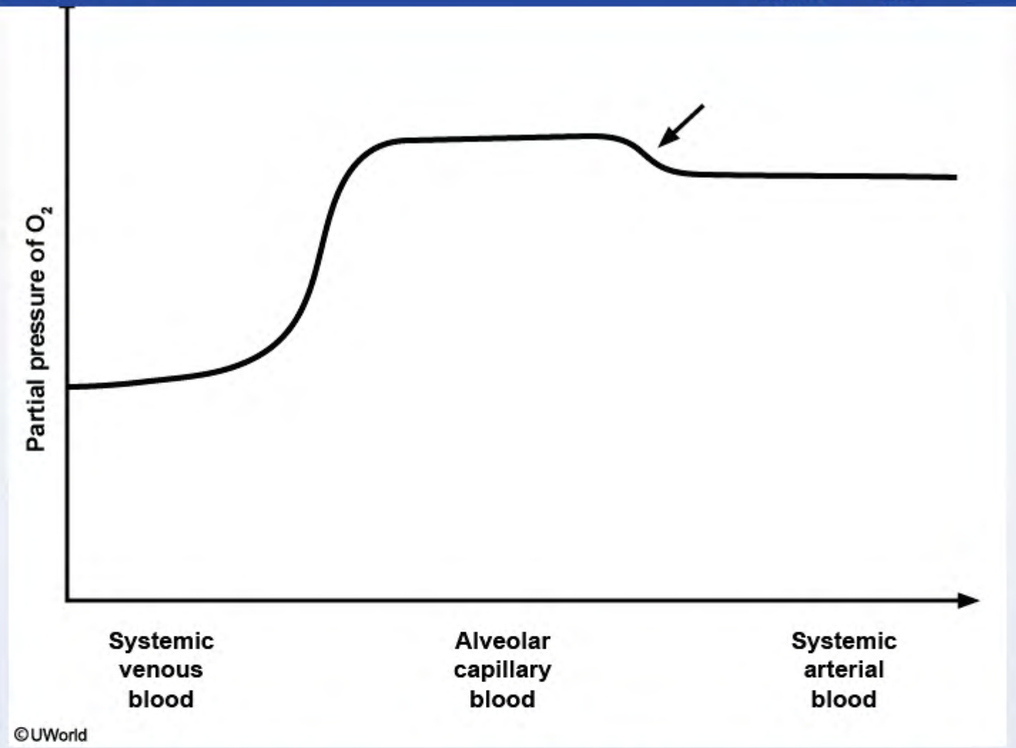

Which of the following factors most likely explains the change in partial pressure indicated by the arrow?

- A. Diffusion-limited oxygenation
- B. Increased dead space ventilation
- C. Mixture with deoxygenated blood
- D. Perfusion-limited oxygenation
- E. Shift in the hemoglobin dissociation curve

Submit

https://t.me/USMLEWorldStep1

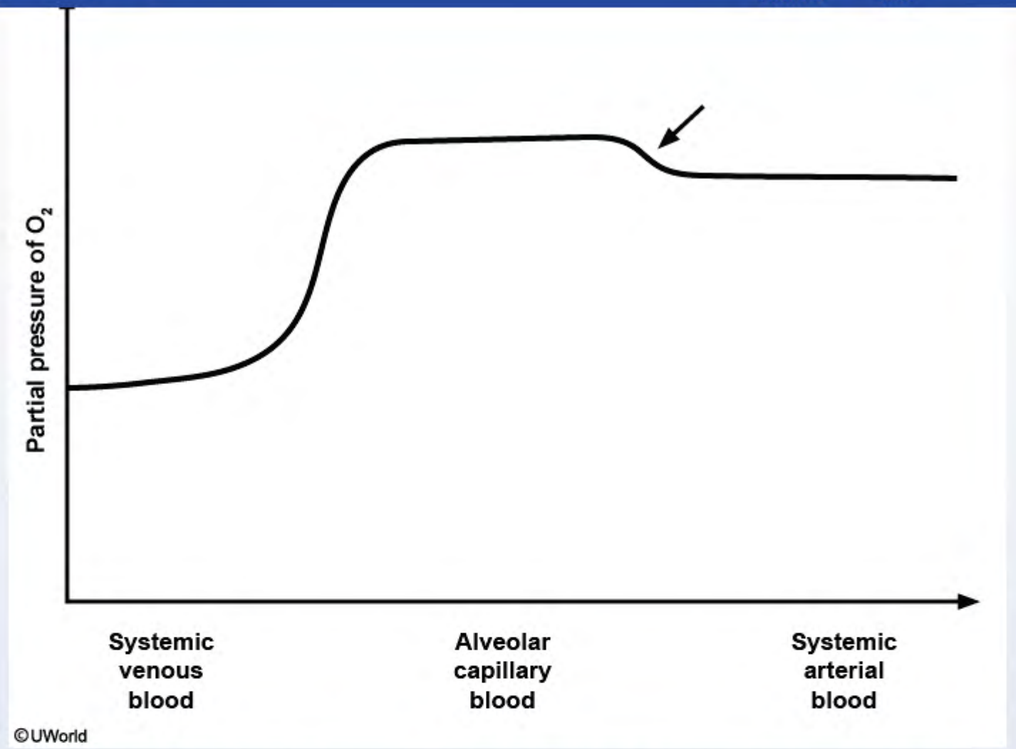

Which of the following factors most likely explains the change in partial pressure indicated by the arrow?

- A. Diffusion-limited oxygenation (10%)
- ✗ B. Increased dead space ventilation (2%)
- ✓ C. Mixture with deoxygenated blood (62%)
- D. Perfusion-limited oxygenation (14%)
- E. Shift in the hemoglobin dissociation curve (9%)

Incorrect
Correct answer
C

62%
Answered correctly

01 min, 19 secs
Time Spent

2023
Version

https://t.me/USMLEWorldStep1

D. Perfusion-limited oxygenation (14%)

Exhibit Display

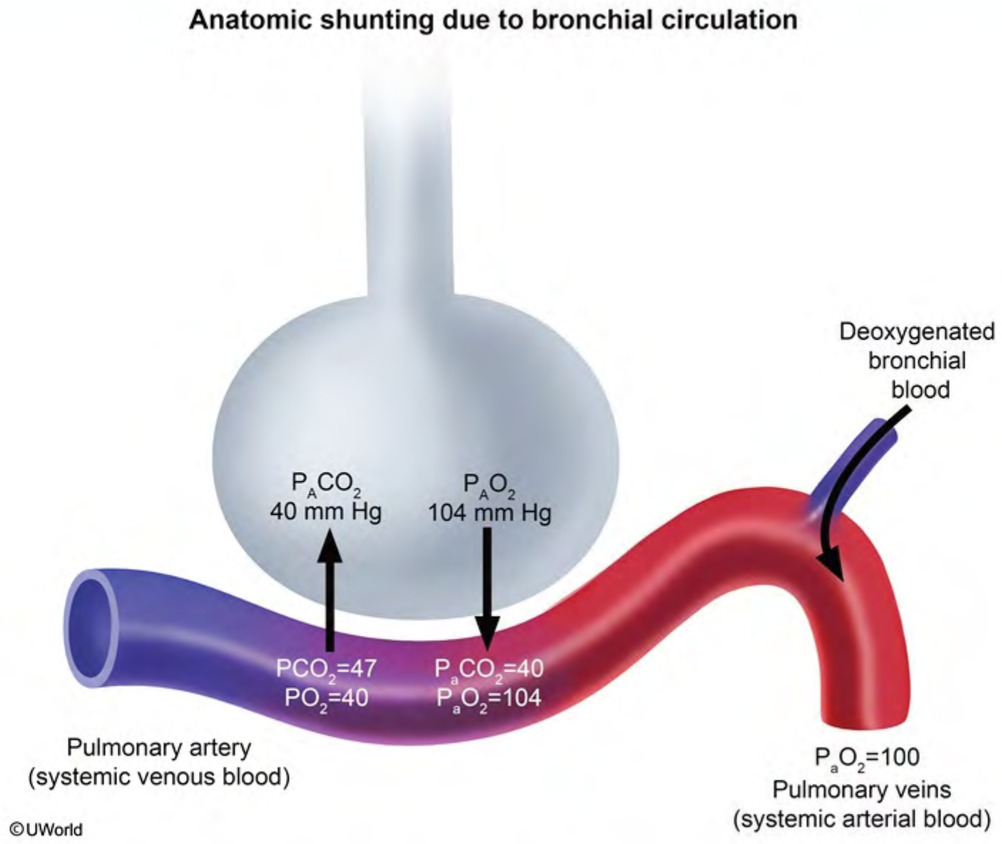

Zoom In | Zoom Out | Reset | New | Existing | My Notebook

Pulmonary veins
(systemic arterial blood)
©UWorld

https://t.me/USMLEWorldStep1

©UWorld

The graph illustrates the pO_2 of blood as it moves through the lungs and into the systemic circulation. Blood in the pulmonary arteries comes from the systemic venous system and is normally deoxygenated. As blood moves through the pulmonary capillaries, it becomes progressively more oxygenated until it equilibrates with the alveolar pO_2 (~104 mm Hg when breathing room air). This is represented by the curve's first upward deflection and subsequent plateau. However, blood in the left atrium and ventricle has a slightly lower pO_2 (~100 mm Hg) than blood in the pulmonary capillaries. This is due to the **mixing of deoxygenated blood** with oxygenated blood from the pulmonary veins and is represented by the downward deflection identified by the arrow. This deoxygenated blood comes from the following sources:

1. The **bronchial arteries** carry blood to the bronchi and bronchioles and, together with the pulmonary artery, form the dual blood supply to the lungs. The **bronchial veins** return only a portion of this blood to the right heart via the azygos and hemi-azygos veins; most of the blood supplied by the bronchial arteries returns to the left heart via the **pulmonary veins**.
2. Small cardiac (**thebesian**) veins that drain into the left atrium and ventricle also contribute to normal anatomic shunting.

(Choice A) Hypoxia due to a diffusion limitation frequently results from pulmonary fibrosis, acute respiratory distress syndrome, emphysema, or hyaline membrane disease of the infant. In diffusion-limited gas exchange, the blood pO_2 does not equilibrate with the alveolar pO_2 by the end of its traversal through the alveolar capillaries.

(Choice B) Dead space ventilation (wasted ventilation) refers to the volume of inspired air that does not participate in gas exchange. Anatomic dead space refers to the volume of air that remains in the conducting parts of the airways, such as the bronchi and bronchioles. Alveolar dead space refers to the volume of air in the alveoli that cannot participate in gas exchange due to poor perfusion.

(Choice D) Perfusion-limited gas exchange occurs in the normal physiologic resting state, as equilibration of the blood with the alveolar gas is complete by the time the blood traverses one-third of the total pulmonary capillary length.

https://t.me/USMLEWorldStep1

subsequent plateau. However, blood in the left atrium and ventricle has a slightly lower pO_2 (~100 mm Hg) than blood in the pulmonary capillaries. This is due to the **mixing of deoxygenated blood** with oxygenated blood from the pulmonary veins and is represented by the downward deflection identified by the arrow. This deoxygenated blood comes from the following sources:

1. The **bronchial arteries** carry blood to the bronchi and bronchioles and, together with the pulmonary artery, form the dual blood supply to the lungs. The **bronchial veins** return only a portion of this blood to the right heart via the azygos and hemi-azygos veins; most of the blood supplied by the bronchial arteries returns to the left heart via the **pulmonary veins**.
2. Small cardiac (**thebesian**) veins that drain into the left atrium and ventricle also contribute to normal anatomic shunting.

(Choice A) Hypoxia due to a diffusion limitation frequently results from pulmonary fibrosis, acute respiratory distress syndrome, emphysema, or hyaline membrane disease of the infant. In diffusion-limited gas exchange, the blood pO_2 does not equilibrate with the alveolar pO_2 by the end of its traversal through the alveolar capillaries.

(Choice B) Dead space ventilation (wasted ventilation) refers to the volume of inspired air that does not participate in gas exchange. Anatomic dead space refers to the volume of air that remains in the conducting parts of the airways, such as the bronchi and bronchioles. Alveolar dead space refers to the volume of air in the alveoli that cannot participate in gas exchange due to poor perfusion.

(Choice D) Perfusion-limited gas exchange occurs in the normal physiologic resting state, as equilibration of the blood with the alveolar gas is complete by the time the blood traverses one-third of the total pulmonary capillary length.

(Choice E) The hemoglobin dissociation curve shifts to the right in the systemic capillaries to increase oxygen delivery to the body tissues. Increases in pCO_2, temperature, and 2,3-diphosphoglycerate concentration cause right-shifting of the curve; the opposite conditions cause a left shift and favor oxygen loading in the lungs.

Educational objective:
The pO_2 in the left atrium and ventricle is lower than that in the pulmonary capillaries due to mixing of oxygenated blood from the pulmonary veins with deoxygenated blood from the bronchial circulation and thebesian veins.

https://t.me/USMLEWorldStep1

subsequent plateau. However, blood in the left atrium and ventricle has a slightly lower pO_2 (~100 mm Hg) than blood in the pulmonary capillaries. This is due to the **mixing of deoxygenated blood** with oxygenated blood from the pu
blood

1. T
   fo
   h
   th
2. S
   sl

(Choi
distres
blood

(Choi
particip
of the
that ca

(Choi
blood
length

(Choi
deliver
right-s

Educa
The p

blood from the pulmonary veins with deoxygenated blood from the bronchial circulation and thebesian veins.

Exhibit Display

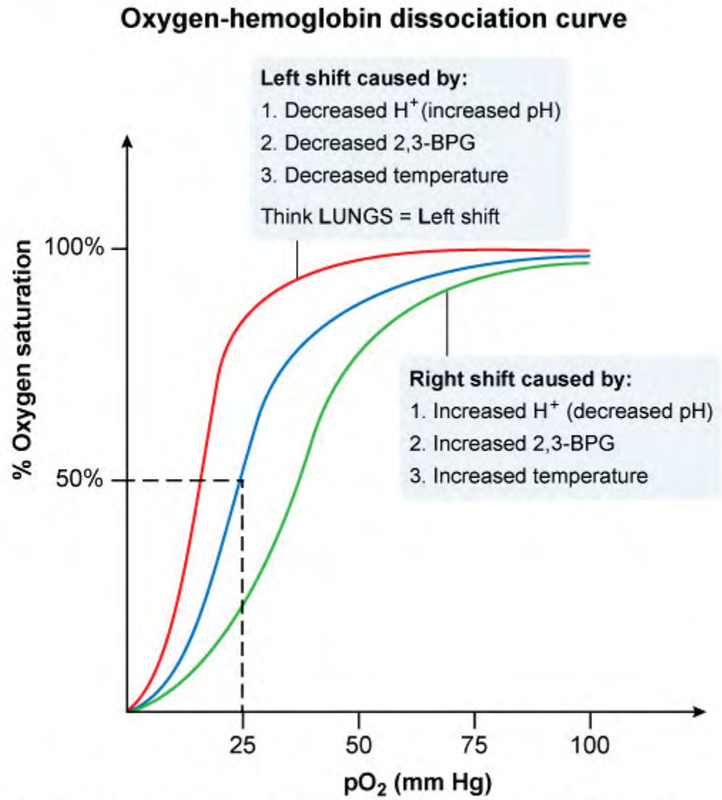

2,3-BPG = 2,3-bisphosphoglycerate; **pO_2** = partial pressure of oxygen in the blood.

©UWorld

Zoom In | Zoom Out | Reset | New | Existing | My Notebook

https://t.me/USMLEWorldStep1

A 43-year-old man comes to the office due to occasional dyspnea that awakens him at night. This symptom started approximately a year ago after a severe upper respiratory tract infection, and since then he has also had an episodic cough. The patient has no other medical problems and takes no medications. He has no drug allergies and does not use tobacco, alcohol, or illicit drugs. His older brother has atopic dermatitis. Vital signs are normal. Lung auscultation reveals bilateral normal breath sounds with no wheezing or crackles. Heart sounds are normal, and there is no extremity edema. Pulmonary function tests are as follows:

FEV1	88% of predicted
FEV1/FVC	84%
Diffusion capacity for carbon monoxide	95% of predicted

Administration of which of the following medications would be most useful during further diagnostic evaluation of this patient?

- A. Epinephrine
- B. Gadolinium
- C. Ipratropium bromide
- D. Levalbuterol
- E. Methacholine
- F. Regadenoson
- G. Theophylline

Submit

https://t.me/USMLEWorldStep1

A 43-year-old man comes to the office due to occasional dyspnea that awakens him at night. This symptom started approximately a year ago after a severe upper respiratory tract infection, and since then he has also had an episodic cough. The patient has no other medical problems and takes no medications. He has no drug allergies and does not use tobacco, alcohol, or illicit drugs. His older brother has atopic dermatitis. Vital signs are normal. Lung auscultation reveals bilateral normal breath sounds with no wheezing or crackles. Heart sounds are normal, and there is no extremity edema. Pulmonary function tests are as follows:

FEV1	88% of predicted
FEV1/FVC	84%
Diffusion capacity for carbon monoxide	95% of predicted

Administration of which of the following medications would be most useful during further diagnostic evaluation of this patient?

- ✗ A. Epinephrine (0%)
- B. Gadolinium (1%)
- C. Ipratropium bromide (3%)
- D. Levalbuterol (3%)
- ✓ E. Methacholine (89%)
- F. Regadenoson (0%)
- G. Theophylline (1%)

Incorrect
Correct answer
E

89%
Answered correctly

24 secs
Time Spent

2023
Version

Explanation

https://t.me/USMLEWorldStep1

This patient's intermittent nocturnal dyspnea and episodic cough that began after a respiratory infection suggest a diagnosis of **asthma**, a disease characterized by airway inflammation and bronchial hyperreactivity to various stimuli, including physical, chemical, and allergenic irritants. Patients often have a family history of other diseases in the "allergic triad" (ie, allergic rhinitis, atopic dermatitis, asthma). Asthma is an obstructive airway disease (FEV1/FVC ≤70%); however, **airflow obstruction is variable**, and lung function studies may be normal between exacerbations.

Bronchoprovocation testing can be useful in diagnosis when a patient presents with a history concerning for asthma but has normal spirometry values. Methacholine is an inhaled muscarinic cholinergic agonist that induces bronchoconstriction; patients are given increasing doses followed by serial spirometry. Patients with asthma demonstrate **hyperresponsivity** to bronchoprovocation with a reduction in FEV1 at lower doses than in those without asthma.

Conversely, bronchodilator administration can help diagnose patients who have obstructive values on spirometry at baseline. Spirometry is performed before and after administration of a bronchodilator (eg, levalbuterol); reversal of the airflow obstruction after therapy suggests the diagnosis of asthma, while irreversible obstruction suggests an alternative diagnosis (eg, bronchiolitis, COPD). However, in a patient who is currently asymptomatic with normal lung function studies, this is unlikely to aid in diagnosis **(Choice D)**.

(Choice A) Epinephrine, an adrenergic agonist, is used for treatment of anaphylaxis. Patients can develop respiratory compromise due to swelling of the airways; however, this is typically accompanied by hypotension and skin involvement (eg, hives, lip swelling). Epinephrine is not indicated in the workup of asthma.

(Choices B and F) Gadolinium is a contrast material used for MRI. Regadenoson is a coronary vasodilator used in cardiac stress testing to evaluate for coronary artery disease. Neither is indicated in the workup of asthma.

(Choices C and G) Ipratropium bromide is a muscarinic cholinergic antagonist used for asthma and chronic obstructive pulmonary disease, and theophylline is a phosphodiesterase-3 inhibitor sometimes used for refractory asthma. These medications can treat asthma but are not used for diagnostic purposes.

Educational objective:
Asthma is characterized by reversible airway obstruction, and lung function tests may be normal between

https://t.me/USMLEWorldStep1

in the "allergic triad" (ie, allergic rhinitis, atopic dermatitis, asthma). Asthma is an obstructive airway disease (FEV1/FVC ≤70%); however, **airflow obstruction is variable**, and lung function studies may be normal between exacerbations.

Bronchoprovocation testing can be useful in diagnosis when a patient presents with a history concerning for asthma but has normal spirometry values. Methacholine is an inhaled muscarinic cholinergic agonist that induces bronchoconstriction; patients are given increasing doses followed by serial spirometry. Patients with asthma demonstrate **hyperresponsivity** to bronchoprovocation with a reduction in FEV1 at lower doses than in those without asthma.

Conversely, bronchodilator administration can help diagnose patients who have obstructive values on spirometry at baseline. Spirometry is performed before and after administration of a bronchodilator (eg, levalbuterol); reversal of the airflow obstruction after therapy suggests the diagnosis of asthma, while irreversible obstruction suggests an alternative diagnosis (eg, bronchiolitis, COPD). However, in a patient who is currently asymptomatic with normal lung function studies, this is unlikely to aid in diagnosis **(Choice D)**.

(Choice A) Epinephrine, an adrenergic agonist, is used for treatment of anaphylaxis. Patients can develop respiratory compromise due to swelling of the airways; however, this is typically accompanied by hypotension and skin involvement (eg, hives, lip swelling). Epinephrine is not indicated in the workup of asthma.

(Choices B and F) Gadolinium is a contrast material used for MRI. Regadenoson is a coronary vasodilator used in cardiac stress testing to evaluate for coronary artery disease. Neither is indicated in the workup of asthma.

(Choices C and G) Ipratropium bromide is a muscarinic cholinergic antagonist used for asthma and chronic obstructive pulmonary disease, and theophylline is a phosphodiesterase-3 inhibitor sometimes used for refractory asthma. These medications can treat asthma but are not used for diagnostic purposes.

Educational objective:
Asthma is characterized by reversible airway obstruction, and lung function tests may be normal between exacerbations. Bronchoprovocation can be used to aid diagnosis in patients with normal spirometry; methacholine is administered and followed by serial spirometry. Patients with asthma demonstrate hyperresponsivity to the stimulus, leading to FEV1 reductions at lower doses than in those without asthma.

https://t.me/USMLEWorldStep1

E

Exp

Exhibit Display

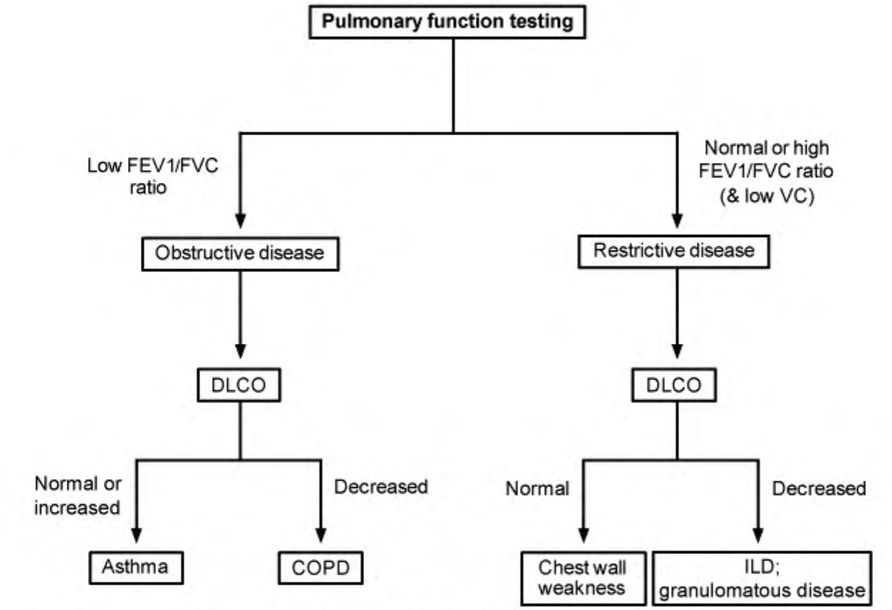

COPD = chronic obstructive pulmonary disease; **DLCO** = diffusion capacity of the lung for carbon monoxide; **FEV1** = forced expiratory volume in 1 second; **FVC** = forced vital capacity; **ILD** = interstitial lung disease; **VC** = vital capacity.
©UWorld

Zoom In Zoom Out Reset New | Existing My Notebook

This p
diagnc
stimuli
in the
(FEV1
exacer

Bronc
asthm
bronch
demor
withou

Conve
baseli
the air
alterna
lung fu

(Choi
respira
skin in

(Choi
in carc

(Choices B and C) Ipratropium bromide is a muscarinic cholinergic antagonist used for asthma and chronic obstructive pulmonary disease, and theophylline is a phosphodiesterase-3 inhibitor sometimes used for refractory

https://t.me/USMLEWorldStep1

E

Expl

Exhibit Display

Normal lung function study values	
FEV1/FVC	~80%
FEV1	≥80% of predicted value
DLCO	≥80%-120% of predicted value
DLCO = diffusion capacity for carbon monoxide.	

New | Existing | My Notebook

This p
diagnc
stimuli
in the
(FEV1
exacer

Bronc
asthm
bronch
demor
withou

Conve
baseli
the air
alterna
lung fu

(Choi
respira
skin in

(Choi
in carc

(Choices B and C) Ipratropium bromide is a muscarinic cholinergic antagonist used for asthma and chronic obstructive pulmonary disease, and theophylline is a phosphodiesterase-3 inhibitor sometimes used for refractory

https://t.me/USMLEWorldStep1

The pancreas of a 22-year-old man with recurrent pulmonary infections and finger clubbing shows extensive exocrine gland atrophy and fibrosis. The pancreatic ducts are lined with squamous epithelium with areas of keratinization. The finding of squamous metaplasia in the pancreatic ducts is most likely related to a deficiency of:

- A. Riboflavin
- B. Vitamin A
- C. Vitamin D
- D. Vitamin E
- E. Vitamin K
- F. Vitamin C

Submit

https://t.me/USMLEWorldStep1

The pancreas of a 22-year-old man with recurrent pulmonary infections and finger clubbing shows extensive exocrine gland atrophy and fibrosis. The pancreatic ducts are lined with squamous epithelium with areas of keratinization. The finding of squamous metaplasia in the pancreatic ducts is most likely related to a deficiency of:

- A. Riboflavin (8%)
- ✓ B. Vitamin A (56%)
- C. Vitamin D (5%)
- D. Vitamin E (18%)
- E. Vitamin K (4%)
- F. Vitamin C (7%)

Correct

56%
Answered correctly

04 mins, 23 secs
Time Spent

2023
Version

Explanation

Recurrent sinopulmonary infections and exocrine gland fibrotic atrophy in a young patient are suggestive of cystic fibrosis (CF). In the pancreas, severe CF may cause total obstruction followed by complete fibrotic atrophy of the exocrine glands. The resulting pancreatic insufficiency can cause a deficiency of fat soluble vitamins. Avitaminosis A in particular may contribute to squamous metaplasia of the epithelial lining of pancreatic exocrine ducts, which are already injured and predisposed to squamous metaplasia by inspissated mucus. Normal levels of vitamin A and its metabolite, retinoic acid, are required to maintain orderly differentiation of specialized epithelia, including mucus-secreting columnar epithelium. When a deficiency state exists, the epithelium undergoes squamous metaplasia to a keratinizing epithelium.

(Choices A and F) Riboflavin (vitamin B_2) and vitamin C are water soluble vitamins whose intestinal absorption is not affected by fat malabsorption.

https://t.me/USMLEWorldStep1

Explanation

Recurrent sinopulmonary infections and exocrine gland fibrotic atrophy in a young patient are suggestive of cystic fibrosis (CF). In the pancreas, severe CF may cause total obstruction followed by complete fibrotic atrophy of the exocrine glands. The resulting pancreatic insufficiency can cause a deficiency of fat soluble vitamins. Avitaminosis A in particular may contribute to squamous metaplasia of the epithelial lining of pancreatic exocrine ducts, which are already injured and predisposed to squamous metaplasia by inspissated mucus. Normal levels of vitamin A and its metabolite, retinoic acid, are required to maintain orderly differentiation of specialized epithelia, including mucus-secreting columnar epithelium. When a deficiency state exists, the epithelium undergoes squamous metaplasia to a keratinizing epithelium.

(Choices A and F) Riboflavin (vitamin B_2) and vitamin C are water soluble vitamins whose intestinal absorption is not affected by fat malabsorption.

(Choice C) Vitamin D is a fat soluble vitamin. However, vitamin D deficiency would not cause epithelial squamous metaplasia. Instead, it could produce rickets in children and osteomalacia in adults.

(Choice D) Vitamin E is a fat soluble vitamin. Deficiency of this vitamin could cause infertility and decreases in some serum phospholipids.

(Choice E) Vitamin K is a fat soluble vitamin. A vitamin K deficiency could cause a coagulopathy (bleeding diathesis) secondary to inadequate vitamin K dependent clotting factors.

Educational Objective:
Recurrent sinopulmonary infections and exocrine gland fibrotic atrophy in a young patient are suggestive of cystic fibrosis (CF). CF can lead to pancreatic insufficiency, fat malabsorption, and a deficiency of vitamins A, D, E and K. Vitamin A maintains orderly differentiation of specialized epithelia, including the mucus-secreting columnar epithelia of the ocular conjunctiva, respiratory and urinary tracts, and pancreatic and other exocrine ducts. Avitaminosis A can cause squamous metaplasia of such epithelia to a keratinizing epithelium.

Pathology	Pulmonary & Critical Care	Cystic fibrosis
Subject	System	Topic

https://t.me/USMLEWorldStep1

A 42-year-old woman is evaluated due to frequent episodes of shortness of breath, chest tightness, and cough. The patient has been hospitalized on several occasions because of these symptoms and recently required mechanical ventilation due to respiratory failure. She takes multiple inhaled and systemic medications. The patient does not use tobacco, alcohol, or illicit drugs. Physical examination reveals scattered expiratory wheezes in both lungs. Peak expiratory flow rate is decreased from baseline. The treatment regimen is expanded to include a monoclonal antibody that binds circulating IgE, with the resulting complexes being subsequently cleared by reticuloendothelial cells. This medication is most likely to help this patient through which of the following mechanisms?

- A. Decreasing airway collagen deposition
- B. Decreasing airway inflammation
- C. Decreasing alveolar destruction
- D. Increasing cyclic AMP–mediated smooth muscle relaxation
- E. Increasing pulmonary vasodilation

Submit

https://t.me/USMLEWorldStep1

A 42-year-old woman is evaluated due to frequent episodes of shortness of breath, chest tightness, and cough. The patient has been hospitalized on several occasions because of these symptoms and recently required mechanical ventilation due to respiratory failure. She takes multiple inhaled and systemic medications. The patient does not use tobacco, alcohol, or illicit drugs. Physical examination reveals scattered expiratory wheezes in both lungs. Peak expiratory flow rate is decreased from baseline. The treatment regimen is expanded to include a monoclonal antibody that binds circulating IgE, with the resulting complexes being subsequently cleared by reticuloendothelial cells. This medication is most likely to help this patient through which of the following mechanisms?

- A. Decreasing airway collagen deposition (1%)
- ✓ B. Decreasing airway inflammation (82%)
- C. Decreasing alveolar destruction (5%)
- D. Increasing cyclic AMP–mediated smooth muscle relaxation (6%)
- E. Increasing pulmonary vasodilation (4%)

Correct

82% Answered correctly

04 secs Time Spent

2023 Version

Explanation

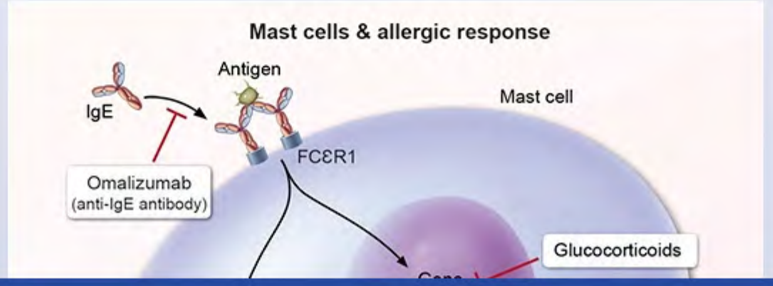

https://t.me/USMLEWorldStep1

B. Decreasing airway inflammation (82%)

Exhibit Display

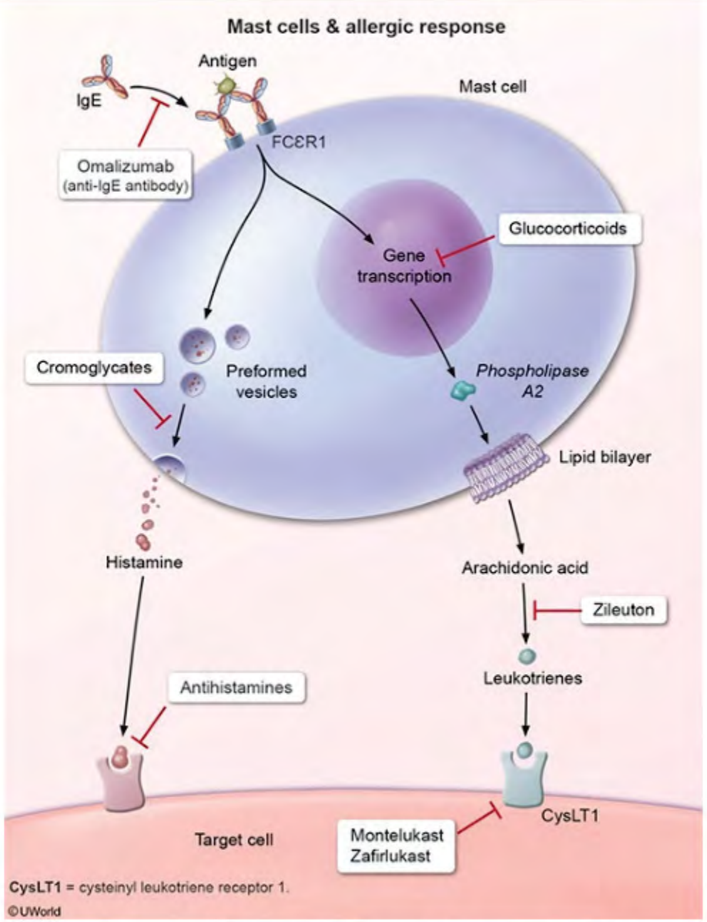

Zoom In | Zoom Out | Reset | New | Existing | My Notebook

Zileuton

https://t.me/USMLEWorldStep1

©UWorld

This patient's frequent episodes of shortness of breath, chest tightness, and cough complicated by respiratory failure requiring hospitalization is consistent with **asthma**. The mainstays of medication therapy for asthma include an as-needed short-acting beta agonist (eg, albuterol), an inhaled corticosteroid (eg, mometasone), and a long-acting beta agonist (eg, salmeterol). For patients whose symptoms remain uncontrolled after such therapy is optimized, the addition of an **IgE-binding monoclonal antibody** (eg, omalizumab) may be beneficial.

Many patients with asthma have high levels of circulating IgE antibodies generated against environmental antigens (eg, dust mites, animal dander). Omalizumab binds to the IgE antibody heavy chain and blocks the binding of IgE to the IgE receptors on mast cells. By preventing this binding, omalizumab **inhibits proinflammatory substance release** (including histamine and leukotrienes) by mast cells, markedly **reducing airway inflammation**.

(Choice A) Decreasing airway collagen deposition may help slow the progression of idiopathic pulmonary fibrosis (IPF). Certain tyrosine kinase inhibitors (eg, nintedanib) decrease fibroblast proliferation and have shown benefit in treating IPF.

(Choice C) Decreasing alveolar destruction would be helpful in treating chronic obstructive pulmonary disease (COPD). Smoking cessation is the most effective way to prevent and/or slow the rate of progression of COPD.

(Choice D) Beta-2 agonists (eg, albuterol, salmeterol) cause bronchodilation via cyclic AMP–mediated smooth muscle relaxation and are effective symptomatic treatments for asthma. These drugs do not significantly reduce airway inflammation.

(Choice E) Increasing pulmonary vasodilation helps improve pulmonary arterial hypertension and can be achieved with several classes of drugs, including endothelin receptor antagonists (eg, bosentan), phosphodiesterase inhibitors (eg, sildenafil), and prostacyclin analogs.

Educational objective:
IgE-binding monoclonal antibodies (eg, omalizumab) are effective in treating asthma that remains uncontrolled despite optimal therapy with bronchodilators and inhaled corticosteroids. IgE-binding monoclonal antibodies reduce airway inflammation by blocking the binding of IgE to the IgE receptors on mast cells and preventing the release of proinflammatory substances, including histamine and leukotrienes.

References

https://t.me/USMLEWorldStep1

A 49-year-old man comes to the office due to 4 months of cough and weight loss. His medical history is otherwise unremarkable and he takes no medications. The patient is a farmer who lives in Mississippi. He does not use tobacco, alcohol, or illicit drugs. His temperature is 37.9 C (100.2 F). Examination shows right lobe crackles. Chest x-ray reveals a pulmonary infiltrate in the right upper lobe. Bronchoscopy with transbronchial biopsy shows granulomatous inflammation. HIV testing is negative. Which of the following is most likely causing this patient's symptoms?

- A. *Blastomyces dermatitidis*
- B. *Candida albicans*
- C. *Mucor* species
- D. *Penicillium marneffei*
- E. *Pneumocystis jiroveci*

Submit

https://t.me/USMLEWorldStep1

A 49-year-old man comes to the office due to 4 months of cough and weight loss. His medical history is otherwise unremarkable and he takes no medications. The patient is a farmer who lives in Mississippi. He does not use tobacco, alcohol, or illicit drugs. His temperature is 37.9 C (100.2 F). Examination shows right lobe crackles. Chest x-ray reveals a pulmonary infiltrate in the right upper lobe. Bronchoscopy with transbronchial biopsy shows granulomatous inflammation. HIV testing is negative. Which of the following is most likely causing this patient's symptoms?

- ✓ A. *Blastomyces dermatitidis* (87%)
- ✗ B. *Candida albicans* (1%)
- C. *Mucor* species (5%)
- D. *Penicillium marneffei* (2%)
- E. *Pneumocystis jiroveci* (3%)

Incorrect
Correct answer
A

87%
Answered correctly

04 secs
Time Spent

2023
Version

Explanation

Blastomyces dermatitidis is a dimorphic fungus that can cause pulmonary infections in **immunocompetent** people and should be considered in individuals from an endemic area (states adjacent to and east of the Mississippi and Ohio river valleys; some overlap with *Histoplasmosis*). The fungus exists in the environment in mold form and is found in soil, organic matter, and many animals (eg, dogs, horses). It is transmitted by the respiratory route, entering the lungs and transforming into yeast form (thermal dimorphism).

B dermatitidis infection can be asymptomatic or it can mimic community-acquired pneumonia (resolves spontaneously) or chronic pneumonia (may be indistinguishable from tuberculosis, other fungal infections, or cancer). **Pulmonary** blastomycosis is characterized by **granuloma** formation. **Extrapulmonary** disease (skin,

https://t.me/USMLEWorldStep1

Blastomyces dermatitidis is a dimorphic fungus that can cause pulmonary infections in **immunocompetent** people and should be considered in individuals from an endemic area (states adjacent to and east of the Mississippi and Ohio river valleys; some overlap with *Histoplasmosis*). The fungus exists in the environment in mold form and is found in soil, organic matter, and many animals (eg, dogs, horses). It is transmitted by the respiratory route, entering the lungs and transforming into yeast form (thermal dimorphism).

B dermatitidis infection can be asymptomatic or it can mimic community-acquired pneumonia (resolves spontaneously) or chronic pneumonia (may be indistinguishable from tuberculosis, other fungal infections, or cancer). **Pulmonary** blastomycosis is characterized by **granuloma** formation. **Extrapulmonary** disease (skin, bone, and genitourinary system) occurs in **immunocompromised** patients. Examination of tissues or respiratory fluids shows round yeast with thick walls and **broad-based budding**. Itraconazole is the preferred treatment for blastomycosis.

(Choice B) *Candida albicans* is an opportunistic pathogen. It may cause superficial infections (eg, vulvovaginitis) in an immunocompetent host. Systemic disease, however, occurs only in the immunosuppressed (especially neutropenic patients).

(Choice C) *Mucor* species infect the paranasal sinuses in patients with neutropenia, burns, or diabetes mellitus. Mucormycosis is strongly associated with diabetic ketoacidosis.

(Choice D) *Penicillium marneffei* is an opportunistic infection in immunocompromised patients, primarily those with AIDS, in Southeast Asia. It is rare in immunocompetent individuals.

(Choice E) *Pneumocystis jiroveci* causes pulmonary disease in immunocompromised patients, particularly those with HIV. *P jiroveci* does not cause symptoms in immunocompetent hosts.

Educational objective:
Blastomyces dermatitides can cause pulmonary disease in the immunocompetent host. Dissemination (most commonly to skin and bones) occurs in immunocompromised individuals.

Subject	System	Topic
Microbiology	Pulmonary & Critical Care	Blastomycosis

https://t.me/USMLEWorldStep1

Explanation

Blasto
people
Missis
mold f
respira

B derm
sponta
cancer
bone,
fluids
blasto

(Choi
in an i
neutro

(Choi
Mucor

(Choi
AIDS,

(Choi
with H

Educa
Blasto
comm

Exhibit Display

Geographic distribution of blastomycosis

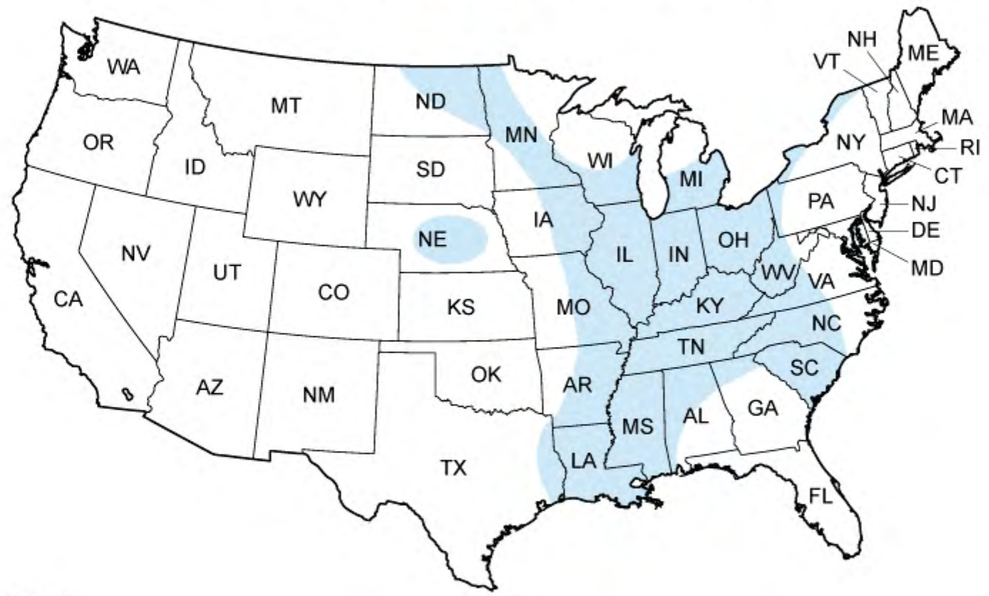

©UWorld

Zoom In | Zoom Out | Reset | New | Existing | My Notebook

Microbiology (Subject) | Pulmonary & Critical Care (System) | Blastomycosis (Topic)

https://t.me/USMLEWorldStep1

Explanation

Blasto
people
Missis
mold f
respira

B derm
sponta
cancer
bone,
fluids
blasto

(Choi
in an i
neutro

(Choi
Mucor

(Choi
AIDS,

(Choi
with H

Educa
Blasto
comm

Exhibit Display

Geographic distribution of histoplasmosis

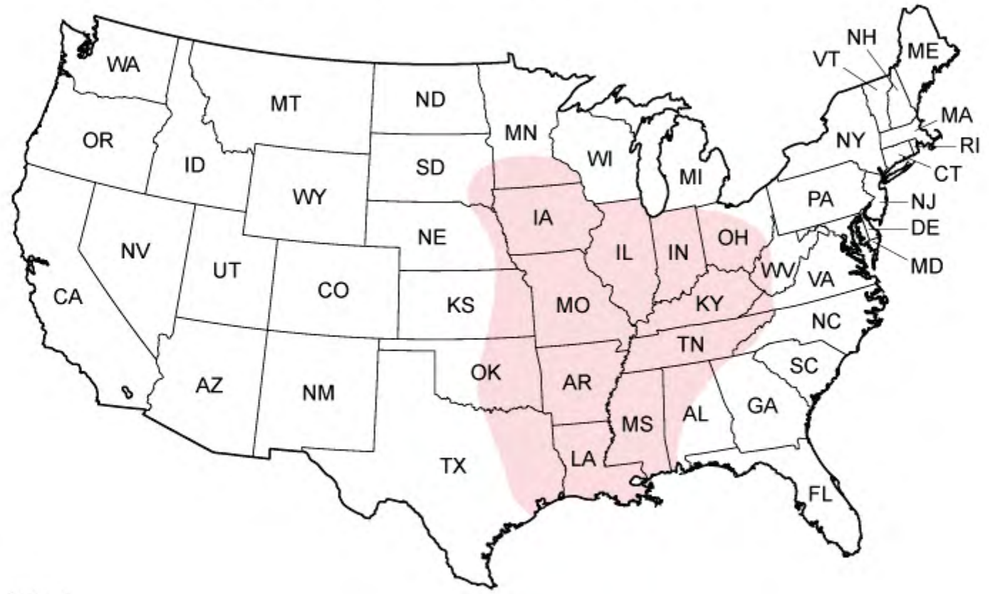

Zoom In | Zoom Out | Reset | New | Existing | My Notebook

Microbiology
Subject
Pulmonary & Critical Care
System
Blastomycosis
Topic

https://t.me/USMLEWorldStep1

A 57-year-old man comes to the office due to unrefreshing sleep. He feels tired during the day and occasionally has to nap during his lunch hours. According to his wife, the patient snores loudly during sleep and frequently gasps for breath. He also has severe claustrophobia. Past medical history is significant for hypertension. The patient takes no sedative medications and is a lifetime nonsmoker. Blood pressure is 156/94 mm Hg and BMI is 30 kg/m^2. Physical examination is significant for a bulky tongue and crowded, narrow oropharynx. Electrical stimulation of which of the following nerves may improve the pathophysiologic cause of this patient's symptoms?

- A. Hypoglossal
- B. Lingual
- C. Maxillary
- D. Phrenic
- E. Recurrent laryngeal

Submit

https://t.me/USMLEWorldStep1

A 57-year-old man comes to the office due to unrefreshing sleep. He feels tired during the day and occasionally has to nap during his lunch hours. According to his wife, the patient snores loudly during sleep and frequently gasps for breath. He also has severe claustrophobia. Past medical history is significant for hypertension. The patient takes no sedative medications and is a lifetime nonsmoker. Blood pressure is 156/94 mm Hg and BMI is 30 kg/m^2. Physical examination is significant for a bulky tongue and crowded, narrow oropharynx. Electrical stimulation of which of the following nerves may improve the pathophysiologic cause of this patient's symptoms?

- ✓ A. Hypoglossal (57%)
- B. Lingual (4%)
- C. Maxillary (2%)
- D. Phrenic (16%)
- E. Recurrent laryngeal (18%)

Correct

57%
Answered correctly

04 secs
Time Spent

2023
Version

Explanation

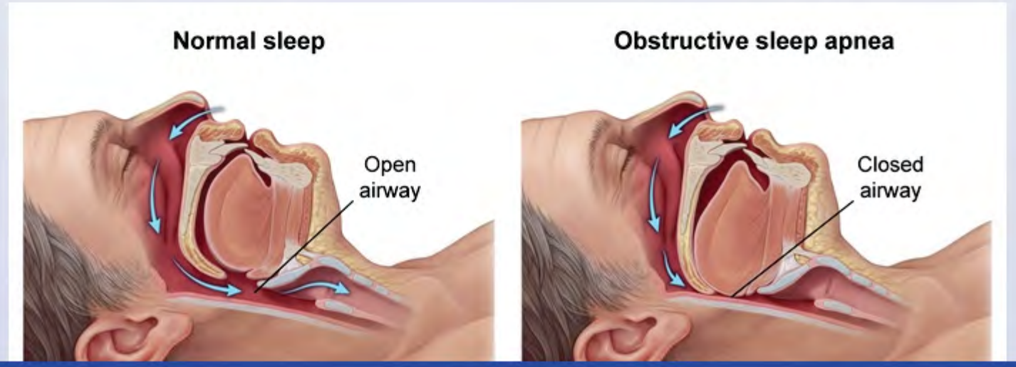

https://t.me/USMLEWorldStep1

A 57-year-old man comes to the office due to unrefreshing sleep. He feels tired during the day and occasionally has to
gasps
patien
kg/m².
stimul

Cor

Expl

Exhibit Display

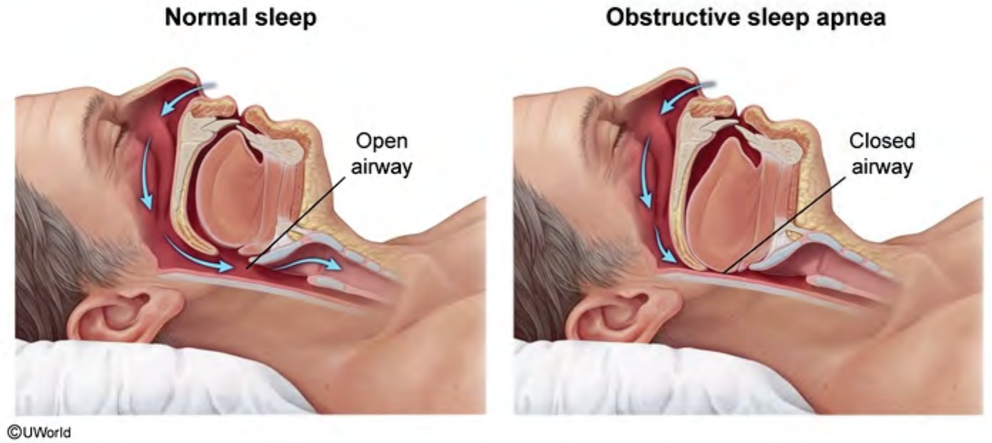

Zoom In | Zoom Out | Reset | New | Existing | My Notebook

https://t.me/USMLEWorldStep1

©UWorld

Obstructive sleep apnea (OSA) is characterized by recurrent episodes of **upper airway collapse** during sleep. Anatomical and neuromuscular mechanisms have been implicated in OSA. **Neuromuscular weakness** as a pathogenic mechanism in OSA is supported by the fact that apneas occur only during sleep, a time of muscle relaxation. The upper airway dilator muscles weaken during the transition from wake to sleep, leading to airway narrowing and ultimately collapse in individuals with OSA.

Stimulation of the **hypoglossal nerve** using an implantable nerve stimulator causes the tongue to move forward slightly, increasing the anteroposterior diameter of the airway. Studies with these devices have shown a reduction in the number of obstructive events during sleep.

(Choices B and C) The lingual nerve arises from the mandibular division of the trigeminal nerve and supplies sensory innervation to the tongue. The maxillary division of the trigeminal nerve provides sensation to the mid-face area. Neither of these nerves provides motor innervation to the oropharyngeal muscles involved in OSA.

(Choice D) The phrenic nerve supplies the diaphragm. Although diaphragmatic paralysis can cause sleep apnea, OSA with loud snoring and gasping respirations is due to oropharyngeal rather than diaphragmatic dysfunction.

(Choice E) The vocal cords are innervated by the recurrent laryngeal nerve, but sleep apnea is primarily a problem of the pharynx, not larynx.

Educational objective:
Neuromuscular weakness of the oropharynx is involved in the pathophysiology of obstructive sleep apnea. Electrical stimulation of the hypoglossal nerve increases the diameter of the oropharyngeal airway and decreases the frequency of apneic events.

References

- Hypoglossal nerve stimulation for obstructive sleep apnea.

Anatomy	Pulmonary & Critical Care	Obstructive sleep apnea
Subject	System	Topic

Copyright © UWorld. All rights reserved.

https://t.me/USMLEWorldStep1

Molecular biologists studying the properties of hemoglobin are investigating the structural changes associated with oxygen loading and unloading. During the transition from point 1 to point 2 on the graph shown below, hemoglobin molecules are most likely to release which of the following?

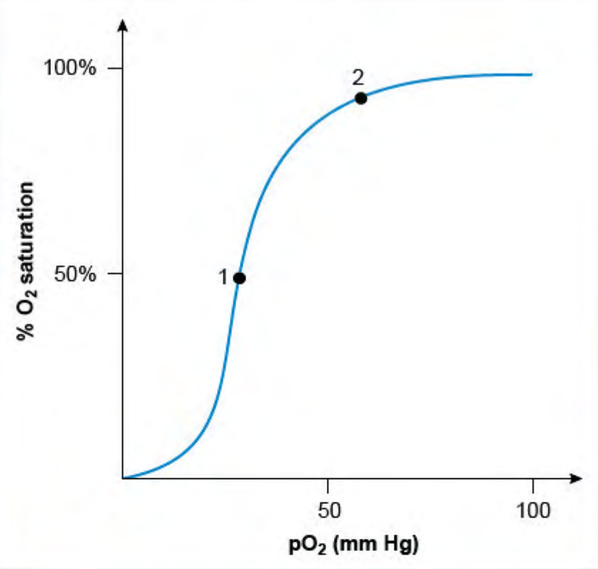

- A. Chloride
- B. Heme
- C. Oxygen
- D. Phosphate
- E. Protons

Submit

https://t.me/USMLEWorldStep1

Molecular biologists studying the properties of hemoglobin are investigating the structural changes associated with oxyge
molec

Exhibit Display

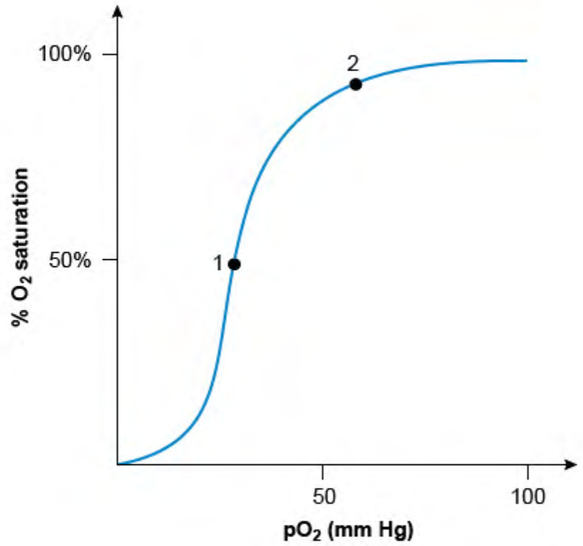

Zoom In | Zoom Out | Reset | New | Existing | My Notebook

Sub

https://t.me/USMLEWorldStep1

Molecular biologists studying the properties of hemoglobin are investigating the structural changes associated with oxygen loading and unloading. During the transition from point 1 to point 2 on the graph shown below, hemoglobin molecules are most likely to release which of the following?

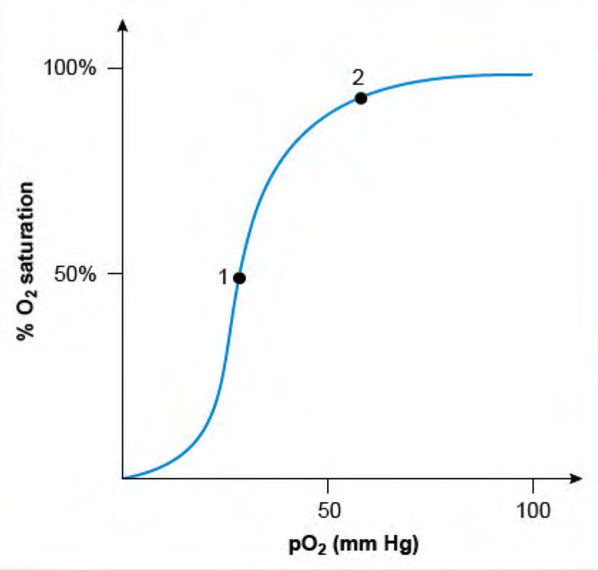

- A. Chloride (13%)
- ✗ B. Heme (1%)
- C. Oxygen (19%)
- D. Phosphate (6%)
- ✓ E. Protons (57%)

Incorrect
Correct answer
E

57%
Answered correctly

07 secs
Time Spent

2023
Version

https://t.me/USMLEWorldStep1

E

Answered correctly
Time Spent
Version

Exhibit Display

The Haldane & Bohr effects

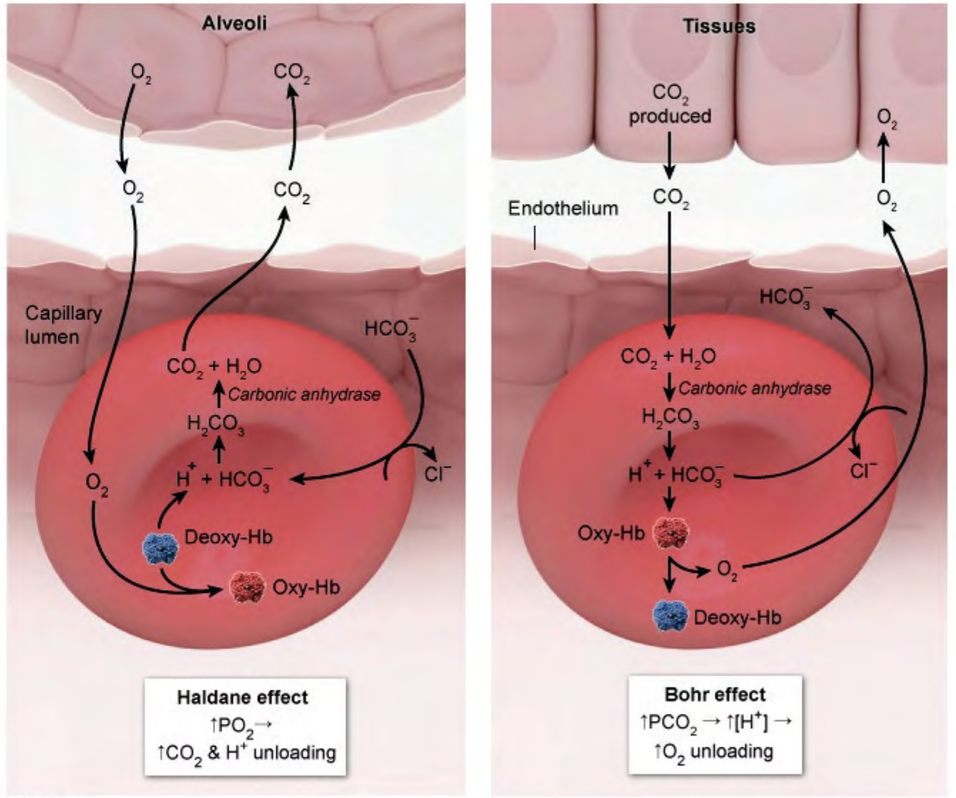

©UWorld

Zoom In | Zoom Out | Reset | New | Existing | My Notebook

The tra
as occ
of O_2 molecules is relatively difficult (as indicated by the early flatness of the curve). As the partial pressure of O_2

https://t.me/USMLEWorldStep1

©UWorld

The transition from point 1 to 2 on the graph represents the loading of O_2 onto partially deoxygenated hemoglobin as occurs in the **lungs**. At very low partial pressure of O_2 (pO_2), hemoglobin is mostly deoxygenated, and binding of O_2 molecules is relatively difficult (as indicated by the early flatness of the curve). As the partial pressure of O_2 increases, O_2 binds to 1 of the 4 binding sites on hemoglobin and **increases the O_2-binding affinity** of the other available binding sites (steepening of the curve), a phenomenon known as **cooperative binding**. Subsequently, additional O_2 molecules bind more easily as the pO_2 increases until hemoglobin becomes nearly fully saturated.

The binding of O_2 molecules to hemoglobin in the lungs has two consequences, known as the **Haldane effect**:

- The affinity of hemoglobin for CO_2 is decreased, resulting in unloading of CO_2 from hemoglobin (this accounts for a small percentage of overall CO_2 in the blood and is not pictured above).
- The acidity of the hemoglobin molecule is increased; in response, **protons (H^+ ions) are released** from the hemoglobin binding sites.

The H^+ ions combine with bicarbonate ions (the primary form of CO_2 in the blood) in the lungs to facilitate the production of water (H_2O) and CO_2. The CO_2 is then transferred to the alveoli and expired while oxygen is taken up by hemoglobin.

In the peripheral tissues, high levels of CO_2 create an increase in ambient acidity that shifts the hemoglobin dissociation curve to the right and facilitates the unloading of O_2 (**Bohr effect**). The CO_2 (and water) are converted into H^+ and HCO_3^-. The H^+ ions are carried by hemoglobin while the HCO_3^- is transferred to the plasma for transport back to the lungs.

(Choice A) In the lungs, chloride ions shift out of red blood cells and into the plasma in exchange for HCO_3^-. These chloride ions are not bound to or released by hemoglobin.

(Choice B) Heme is not released from hemoglobin during O_2 loading or unloading. However, it is released during the normal destruction of aged red blood cells in the spleen.

(Choice C) O_2 molecules bind to hemoglobin to increase hemoglobin saturation.

(Choice D) 2,3-diphosphoglycerate contains 2 phosphate groups and binds to hemoglobin to facilitate unloading

https://t.me/USMLEWorldStep1

The binding of O_2 molecules to hemoglobin in the lungs has two consequences, known as the **Haldane effect**:

- The affinity of hemoglobin for CO_2 is decreased, resulting in unloading of CO_2 from hemoglobin (this accounts for a small percentage of overall CO_2 in the blood and is not pictured above).
- The acidity of the hemoglobin molecule is increased; in response, **protons (H^+ ions) are released** from the hemoglobin binding sites.

The H^+ ions combine with bicarbonate ions (the primary form of CO_2 in the blood) in the lungs to facilitate the production of water (H_2O) and CO_2. The CO_2 is then transferred to the alveoli and expired while oxygen is taken up by hemoglobin.

In the peripheral tissues, high levels of CO_2 create an increase in ambient acidity that shifts the hemoglobin dissociation curve to the right and facilitates the unloading of O_2 (**Bohr effect**). The CO_2 (and water) are converted into H^+ and HCO_3^-. The H^+ ions are carried by hemoglobin while the HCO_3^- is transferred to the plasma for transport back to the lungs.

(Choice A) In the lungs, chloride ions shift out of red blood cells and into the plasma in exchange for HCO_3^-. These chloride ions are not bound to or released by hemoglobin.

(Choice B) Heme is not released from hemoglobin during O_2 loading or unloading. However, it is released during the normal destruction of aged red blood cells in the spleen.

(Choice C) O_2 molecules bind to hemoglobin to increase hemoglobin saturation.

(Choice D) 2,3-diphosphoglycerate contains 2 phosphate groups and binds to hemoglobin to facilitate unloading of O_2 in the tissues. However, phosphate molecules are not directly bound or released by hemoglobin.

Educational objective:
The binding of O_2 to hemoglobin increases the affinity for binding of subsequent O_2 molecules (cooperative binding). In the lungs, the binding of O_2 to hemoglobin drives the release of H^+ and CO_2 from hemoglobin (Haldane effect). In the peripheral tissues, high concentrations of CO_2 and H^+ facilitate O_2 unloading from hemoglobin (Bohr effect).

https://t.me/USMLEWorldStep1

The binding of O_2 molecules to hemoglobin in the lungs has two consequences, known as the **Haldane effect**:

- T
  fo
- T
  h

The H
produc
by her

In the
dissoc
into H
transp

(Choi
These

(Choi
the no

(Choi

(Choi
of O_2 i

Educa
The bi
bindin
effect).
effect).

Exhibit Display

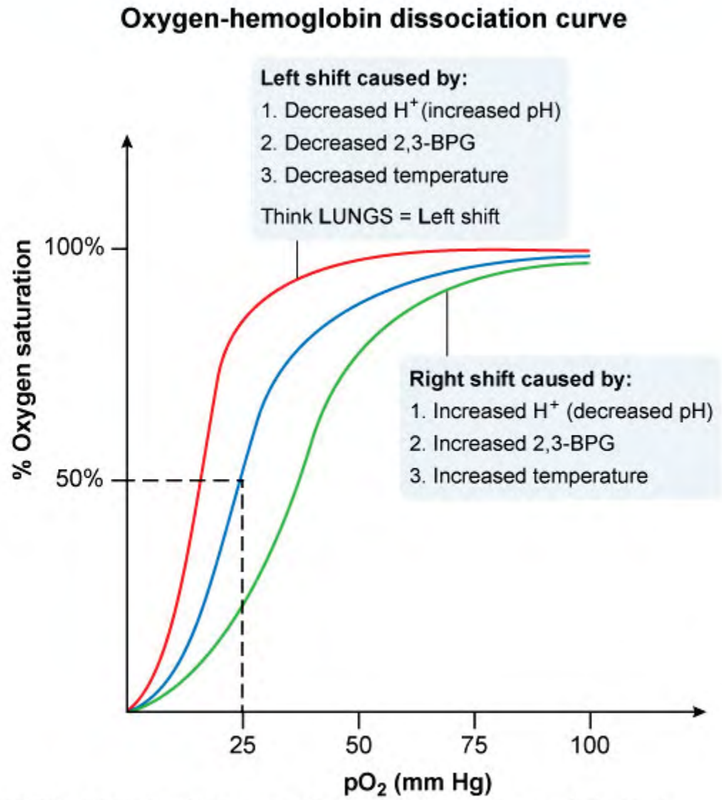

2,3-BPG = 2,3-bisphosphoglycerate; **pO_2** = partial pressure of oxygen in the blood.

©UWorld

Zoom In | Zoom Out | Reset | New | Existing | My Notebook

https://t.me/USMLEWorldStep1

A 64-year-old man is evaluated for worsening dyspnea on exertion. He has a 40-pack-year smoking history. The lungs are hyperresonant on percussion and there is diffuse wheezing on auscultation. Chest x-ray reveals a flattened diaphragm with a narrow mediastinum, and there are decreased bronchovascular markings in the peripheral lung region. Which of the following lung volume patterns is most likely to be present in this patient? (Each bar represents total lung capacity with different volumes as marked.)

- A. A
- B. B
- C. C
- D. D

Submit

https://t.me/USMLEWorldStep1

A 64-year-old man is evaluated for worsening dyspnea on exertion. He has a 40-pack-year smoking history. The
lungs
flatten
periph
(Each

Exhibit Display

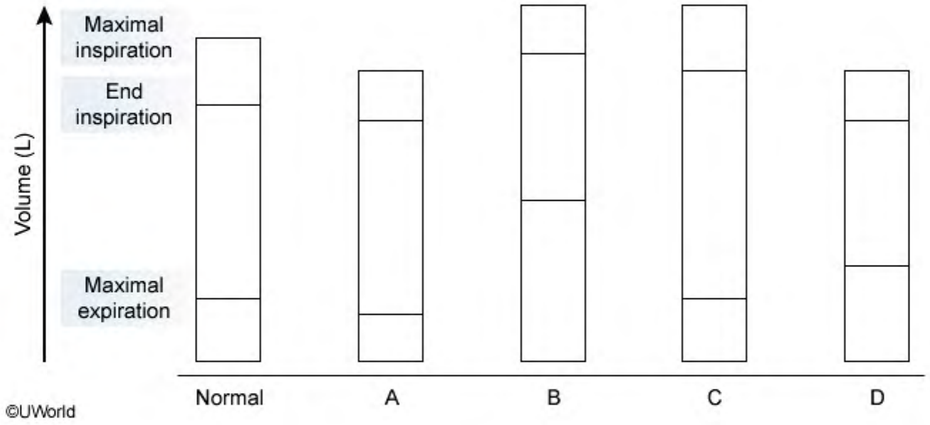

Zoom In Zoom Out Reset New | Existing My Notebook

Sub

https://t.me/USMLEWorldStep1

A 64-year-old man is evaluated for worsening dyspnea on exertion. He has a 40-pack-year smoking history. The lungs are hyperresonant on percussion and there is diffuse wheezing on auscultation. Chest x-ray reveals a flattened diaphragm with a narrow mediastinum, and there are decreased bronchovascular markings in the peripheral lung region. Which of the following lung volume patterns is most likely to be present in this patient? (Each bar represents total lung capacity with different volumes as marked.)

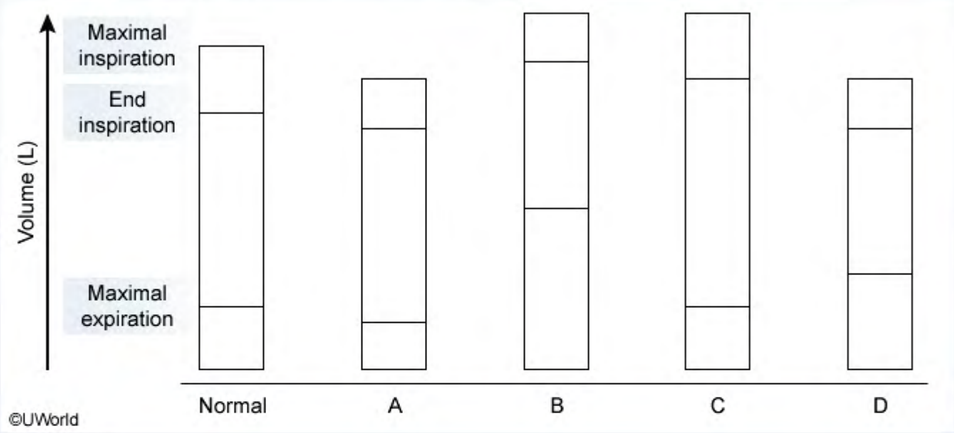

- A. A (7%)
- ✓ B. B (70%)
- C. C (17%)
- D. D (4%)

Correct

70% Answered correctly

08 secs Time Spent

2023 Version

Explanation

https://t.me/USMLEWorldStep1

Correct
70% Answered correctly
08 secs Time Spent
2023 Version

Exhibit Display

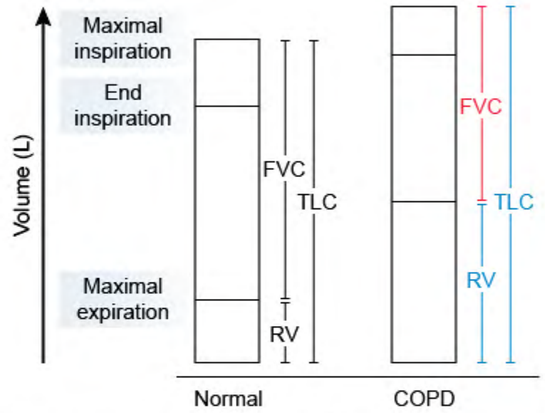

COPD = chronic obstructive pulmonary disease; **FVC** = forced vital capacity; **RV** = residual volume; **TLC** = total lung capacity.

©UWorld

Zoom In | Zoom Out | Reset | New | Existing | My Notebook

Expl

In **chr**
increa
increa
decre
(FEV1

In the
tidal v
in RV

(Choi
normal or increased.

(Choice C) This graph shows an increased TLC and FVC with a normal RV. Such an increase in FVC may be

https://t.me/USMLEWorldStep1

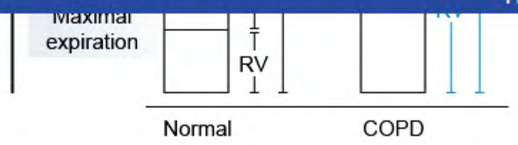

COPD = chronic obstructive pulmonary disease; **FVC** = forced vital capacity; **RV** = residual volume; **TLC** = total lung capacity.

©UWorld

In **chronic obstructive pulmonary disease** (COPD), air flow obstruction and hyperinflation (air trapping) cause **increased residual volume** (RV) and a consequent **increase in total lung capacity** (TLC). Because the increase in RV is greater than the increase in TLC, the RV/TLC ratio is increased. Airway obstruction also causes **decreased forced vital capacity** (FVC) and a more profound decrease in forced expiratory volume in one second (FEV1), resulting in a decreased FEV1/FVC ratio.

In the above graphs, the top section represents the inspiratory reserve volume, the middle section represents the tidal volume plus the expiratory reserve volume, and the bottom section represents the RV. In COPD, an increase in RV and TLC is expected, as is a decrease in FVC.

(Choice A) In restrictive lung disease, the TLC, RV, FVC, and FEV1 are all reduced, but the FEV1/FVC ratio is normal or increased.

(Choice C) This graph shows an increased TLC and FVC with a normal RV. Such an increase in FVC may be seen in elite athletes.

(Choice D) This graph shows a decrease in TLC and an increase in RV. As changes in these parameters are not typically discordant, this would be a rare clinical finding.

Educational objective:
In chronic obstructive pulmonary disease, air-trapping leads to an increase in residual volume (RV) and total lung capacity (TLC), as well as an increase in the RV/TLC ratio. Airway obstruction causes a decrease in forced vital capacity (FVC), forced expiratory volume in 1 second (FEV1), and the FEV1/FVC ratio.

Physiology	Pulmonary & Critical Care	COPD
Subject	System	Topic

Copyright © UWorld. All rights reserved.

https://t.me/USMLEWorldStep1

Maximal expiration

RV

Exhibit Display

In chr
increa
increa
decre
(FEV1

In the
tidal v
in RV

(Choi
norma

(Choi
seen i

(Choi
typical

Educa
In chr
capaci
capaci

Physiol
Subject

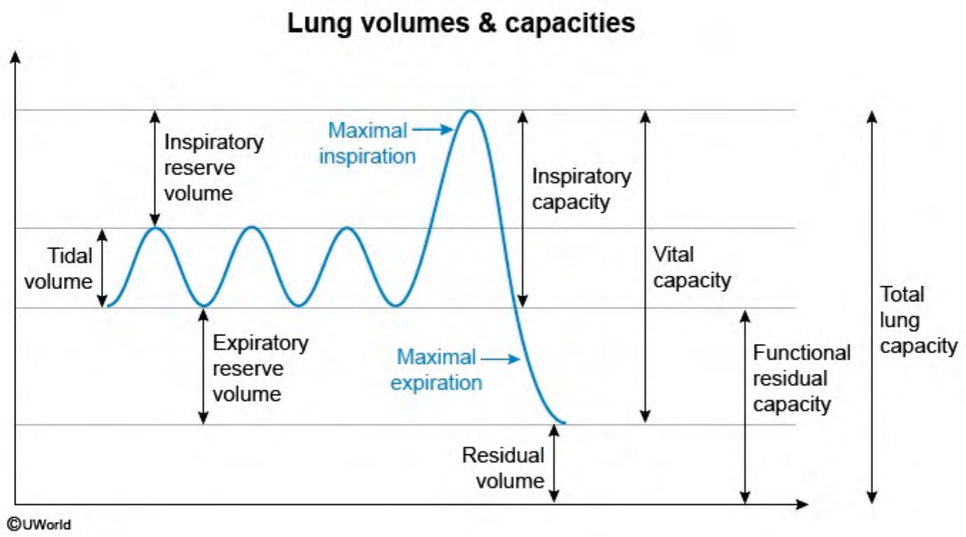

Zoom In | Zoom Out | Reset | New | Existing | My Notebook

Copyright © UWorld. All rights reserved.

https://t.me/USMLEWorldStep1

Physicians involved in regenerative medicine research conduct a series of animal experiments to determine pulmonary tissue regeneration capacity. During one of the experiments, lung alveoli are exposed to NO_2 and massive necrosis of the epithelial lining ensues. Histologic examination of the injured tissues a month later shows partial recovery of the alveolar epithelial lining. This regenerated tissue is most likely derived from which of the following cell types?

- A. Alveolar macrophages
- B. Ciliated epithelium
- C. Club cells
- D. Goblet cells
- E. Type I pneumocytes
- F. Type II pneumocytes

Submit

https://t.me/USMLEWorldStep1

Physicians involved in regenerative medicine research conduct a series of animal experiments to determine pulmonary tissue regeneration capacity. During one of the experiments, lung alveoli are exposed to NO_2 and massive necrosis of the epithelial lining ensues. Histologic examination of the injured tissues a month later shows partial recovery of the alveolar epithelial lining. This regenerated tissue is most likely derived from which of the following cell types?

- A. Alveolar macrophages (1%)
- ✗ B. Ciliated epithelium (1%)
- C. Club cells (3%)
- D. Goblet cells (0%)
- E. Type I pneumocytes (18%)
- ✓ F. Type II pneumocytes (74%)

Incorrect
Correct answer
F

74%
Answered correctly

04 secs
Time Spent

2023
Version

Explanation

Alveoli

https://t.me/USMLEWorldStep1

Physicians involved in regenerative medicine research conduct a series of animal experiments to determine
pulmo
massi
partial
followi

Exhibit Display

Alveoli

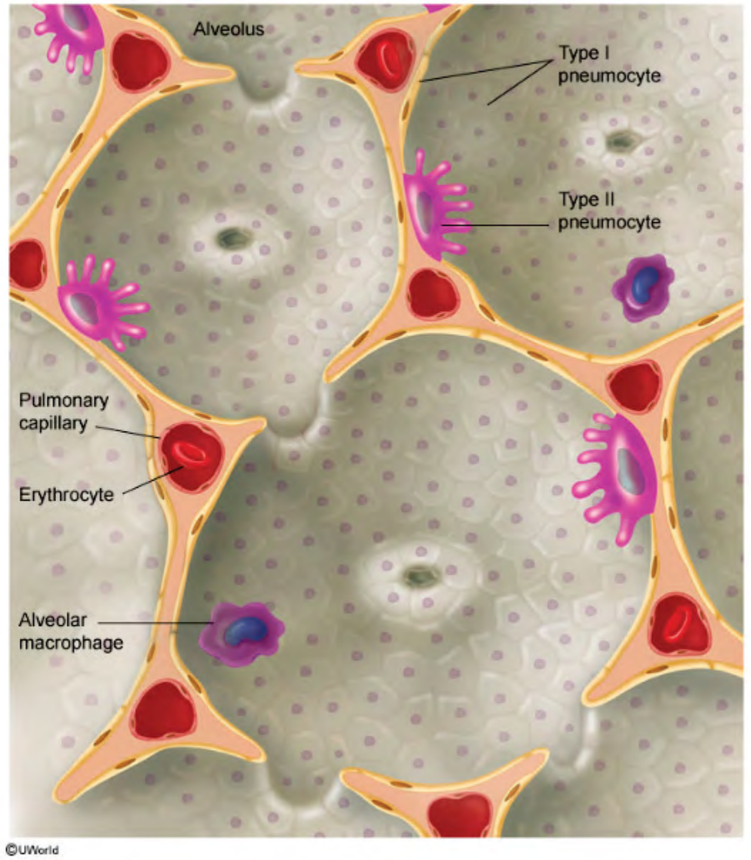

Zoom In | Zoom Out | Reset | New | Existing | My Notebook

Type II pneumocyte

https://t.me/USMLEWorldStep1

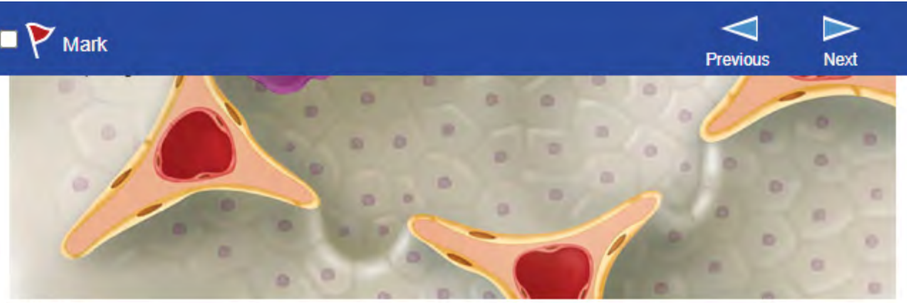

Ninety-five percent of the alveolar surface is covered by flat type I pneumocytes. The remaining 5% is covered by interspersed cuboidal **type II pneumocytes** that make up more than half of the total number of alveolar cells. Type II pneumocytes are the source of **pulmonary surfactant** and have the ability to **proliferate** in response to injury. They also act as progenitor cells for type I pneumocytes, which cannot regenerate on their own **(Choice E)**.

(Choice A) Alveolar macrophages are a self-maintaining population derived from fetal monocytes during lung development. They are the principal cells involved in clearing inhaled foreign particles from the terminal respiratory units.

(Choice B) The pseudostratified, ciliated, columnar epithelium of the tracheobronchial tree gradually tapers to become a simple ciliated cuboidal epithelium at the level of the terminal bronchioles. Ciliated cells are absent from the lining of alveolar ducts and alveolar sacs.

(Choice C) Club cells are nonciliated, secretory cells found predominantly in the terminal portions of the bronchioles. These cells can act as a regenerative source of ciliated cells in the bronchioles.

(Choice D) Goblet cells are found in the respiratory epithelium of the bronchi and larger bronchioles; they are absent from the alveolar mucosa. Goblet cells are considered terminally-differentiated, mucin-producing cells.

Educational objective:
Type II pneumocytes have 2 important functions: regeneration of the alveolar lining following injury and surfactant production.

Histology	Pulmonary & Critical Care	Respiratory mucosa
Subject	System	Topic

Copyright © UWorld. All rights reserved.

https://t.me/USMLEWorldStep1

A 58-year-old man comes to the office due to exertional dyspnea and cough. His symptoms started 6 months ago and have progressively worsened. Other medical conditions include recurrent pyelonephritis, peptic ulcer disease, and rheumatoid arthritis. The patient had taken a medication for rheumatoid arthritis for many years but stopped a year ago, as the drug failed to improve his worsening hand arthritis. He does not use tobacco, alcohol, or illicit drugs. Physical examination shows joint disease consistent with rheumatoid arthritis. Chest x-ray is shown in the image below.

Which of the following is the most likely explanation for this patient's pulmonary symptoms?

- A. Bilateral atelectasis
- B. Left ventricular failure
- C. Obstructive lung disease
- D. Pulmonary fibrosis
- E. Pulmonary hypertension

Submit

https://t.me/USMLEWorldStep1

A 58-year-old man comes to the office due to exertional dyspnea and cough. His symptoms started 6 months ago
and ha
and rh
year a
drugs.
image

Which

C. Obstructive lung disease

Exhibit Display

Zoom In Zoom Out Reset New | Existing My Notebook

https://t.me/USMLEWorldStep1

image below.

Which of the following is the most likely explanation for this patient's pulmonary symptoms?

- A. Bilateral atelectasis
- B. Left ventricular failure
- C. Obstructive lung disease
- D. Pulmonary fibrosis
- E. Pulmonary hypertension

Submit

https://t.me/USMLEWorldStep1

image below.

Which of the following is the most likely explanation for this patient's pulmonary symptoms?

- A. Bilateral atelectasis (3%)
- B. Left ventricular failure (1%)
- C. Obstructive lung disease (5%)
- ✓ D. Pulmonary fibrosis (84%)
- E. Pulmonary hypertension (4%)

Correct

84% Answered correctly

11 secs Time Spent

2023 Version

https://t.me/USMLEWorldStep1

Correct

84%
Answered correctly

11 secs
Time Spent

2023
Version

Exhibit Display

Pulmonary fibrosis

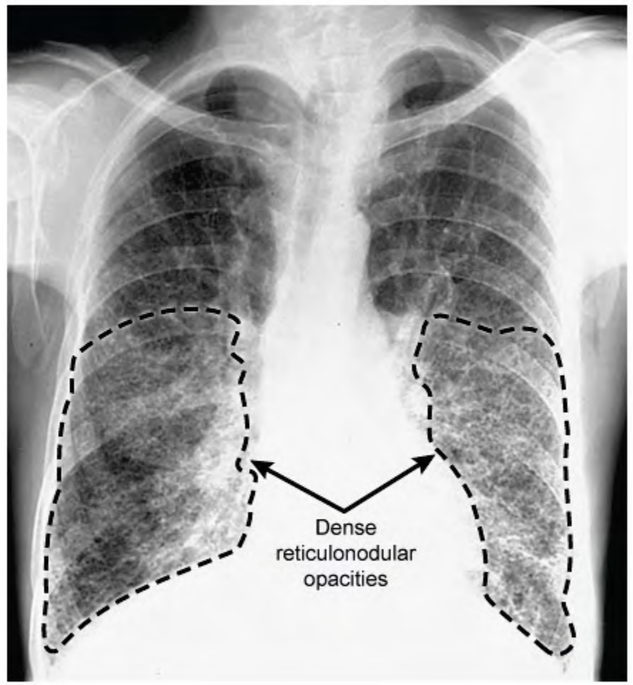

©UWorld

Zoom In | Zoom Out | Reset | New | Existing | My Notebook

As cor
(**reticu**
pulmo
fatigue, and eventual weight loss and failure to thrive.

https://t.me/USMLEWorldStep1

©UWorld

As compared to normal imaging, this patient's chest x-ray shows a bilateral and diffuse pattern of small, irregular (**reticulonodular**) opacities that are most pronounced in the lower lobes. These findings are most consistent with **pulmonary fibrosis**, which typically manifests with **gradual-onset progressive dyspnea**, nonproductive cough, fatigue, and eventual weight loss and failure to thrive.

Auscultation may reveal **end-inspiratory crackles** at the lung bases. Pulmonary function tests show a **restrictive pattern** with decreased lung volumes, decreased FEV1 and FVC levels, a normal or increased FEV1/FVC ratio, and decreased diffusion capacity of carbon monoxide. Microscopically, progressive fibrosis can lead to cystically dilated bronchioles that later coalesce to form the honeycomb appearance found in advanced disease.

Rheumatoid arthritis (RA) can cause a variety of pulmonary manifestations; the most common is a form of interstitial lung disease similar to idiopathic interstitial pneumonia. In addition, multiple agents used to treat RA (eg, methotrexate, cyclophosphamide, sulfasalazine) can cause fibrotic lung disease.

(Choice A) Atelectasis refers to diminished air volume in part of the lung and most commonly occurs due to obstruction of the corresponding bronchus or bronchiole. Chest x-ray shows opacification (collapse) of the corresponding lobe/lobule.

(Choice B) Chest x-ray in decompensated left ventricular failure shows cardiomegaly (heart >1 hemithorax in size), pulmonary edema, pleural effusions, and enlarged pulmonary vessels.

(Choice C) Obstructive pulmonary diseases (eg, asthma, chronic obstructive pulmonary disease) are associated with lung hyperinflation on chest x-ray. This patient has mild hyperinflation (likely due to a deep inspiration during imaging) however the diaphragms are not markedly flattened. In addition, reticulonodular opacities are not seen in these conditions.

(Choice E) Chest x-ray in pulmonary hypertension shows enlargement of the pulmonary arteries and the right ventricle.

Educational objective:
Pulmonary fibrosis presents with gradual-onset progressive dyspnea, nonproductive cough, fatigue, eventual weight loss, and bilateral reticulonodular opacities on chest x-ray. Pulmonary function tests reveal a restrictive pattern. Patients with rheumatoid arthritis can develop interstitial lung diseases, both from the pulmonary

https://t.me/USMLEWorldStep1

pulmonary fibrosis, which typically manifests with **gradual-onset progressive dyspnea**, nonproductive cough, fatigue, and eventual weight loss and failure to thrive.

Auscultation may reveal **end-inspiratory crackles** at the lung bases. Pulmonary function tests show a **restrictive pattern** with decreased lung volumes, decreased FEV1 and FVC levels, a normal or increased FEV1/FVC ratio, and decreased diffusion capacity of carbon monoxide. Microscopically, progressive fibrosis can lead to cystically dilated bronchioles that later coalesce to form the honeycomb appearance found in advanced disease.

Rheumatoid arthritis (RA) can cause a variety of pulmonary manifestations; the most common is a form of interstitial lung disease similar to idiopathic interstitial pneumonia. In addition, multiple agents used to treat RA (eg, methotrexate, cyclophosphamide, sulfasalazine) can cause fibrotic lung disease.

(Choice A) Atelectasis refers to diminished air volume in part of the lung and most commonly occurs due to obstruction of the corresponding bronchus or bronchiole. Chest x-ray shows opacification (collapse) of the corresponding lobe/lobule.

(Choice B) Chest x-ray in decompensated left ventricular failure shows cardiomegaly (heart >1 hemithorax in size), pulmonary edema, pleural effusions, and enlarged pulmonary vessels.

(Choice C) Obstructive pulmonary diseases (eg, asthma, chronic obstructive pulmonary disease) are associated with lung hyperinflation on chest x-ray. This patient has mild hyperinflation (likely due to a deep inspiration during imaging) however the diaphragms are not markedly flattened. In addition, reticulonodular opacities are not seen in these conditions.

(Choice E) Chest x-ray in pulmonary hypertension shows enlargement of the pulmonary arteries and the right ventricle.

Educational objective:
Pulmonary fibrosis presents with gradual-onset progressive dyspnea, nonproductive cough, fatigue, eventual weight loss, and bilateral reticulonodular opacities on chest x-ray. Pulmonary function tests reveal a restrictive pattern. Patients with rheumatoid arthritis can develop interstitial lung diseases, both from the pulmonary manifestations of the disease itself and from certain therapies (eg, methotrexate, cyclophosphamide, sulfasalazine).

https://t.me/USMLEWorldStep1

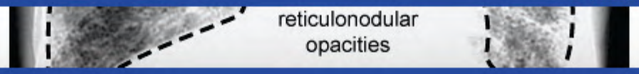

Exhibit Display

Normal chest x-ray

Zoom In | Zoom Out | Reset | New | Existing | My Notebook

As cor
(**reticu**
pulmo
fatigue

Auscu
patter
and de
dilatec

Rheur
interst
metho

(Choi
obstru
corres

(Choi
size),

(Choi
with lu
imagir
these

(Choi
ventricle.

https://t.me/USMLEWorldStep1

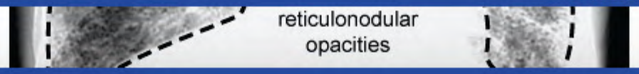

Exhibit Display

As cor
(**reticu**
pulmo
fatigue

Auscu
patter
and de
dilatec

Rheur
interst
metho

(Choi
obstru
corres

(Choi
size),

(Choi
with lu
imagir
these

(Choi
ventricle.

Pulmonary fibrosis

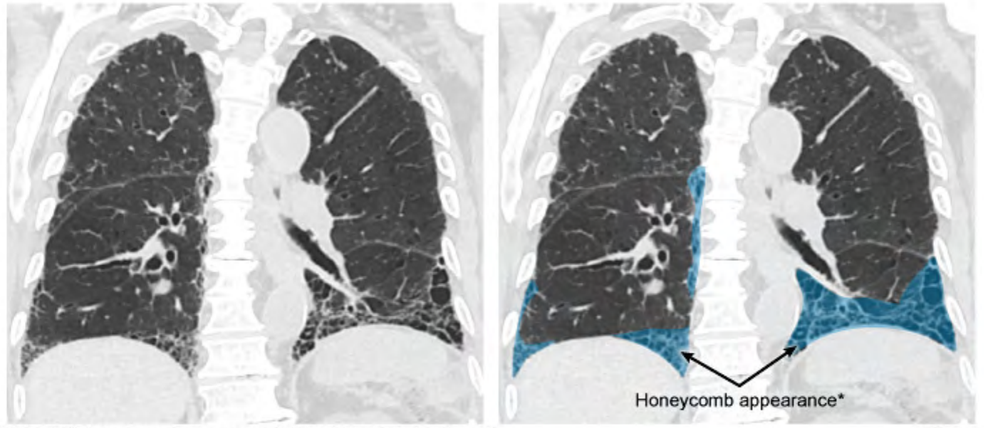

*Cystic dilation of airspaces surrounded by thickened, fibrotic walls.

©UWorld

Zoom In | Zoom Out | Reset | New | Existing | My Notebook

https://t.me/USMLEWorldStep1

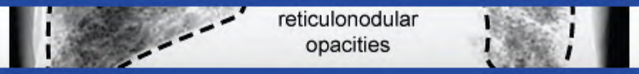

As cor
(**reticu**
pulmo
fatigue

Auscu
patter
and de
dilatec

Rheur
interst
metho

(Choi
obstru
corres

(Choi
size),

(Choi
with lu
imagir
these

(Choi
ventricle.

Exhibit Display

Atelectasis

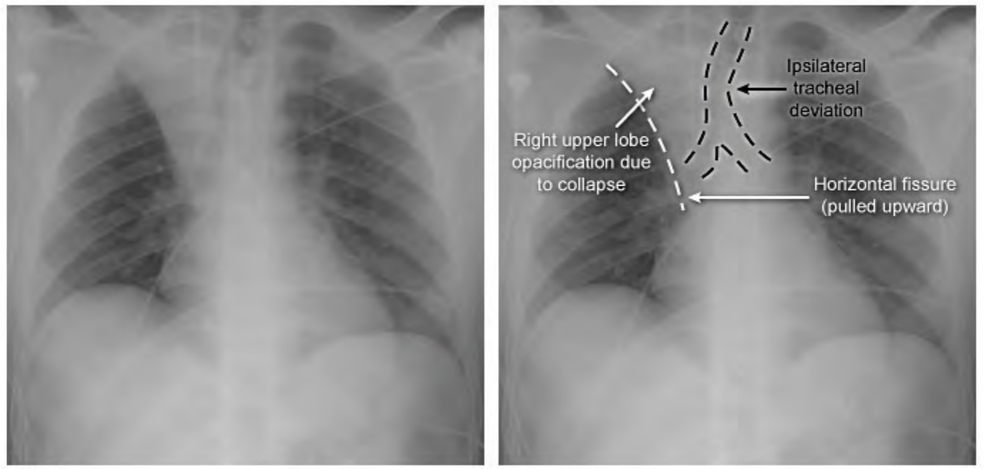

©UWorld

Zoom In | Zoom Out | Reset | New | Existing | My Notebook

https://t.me/USMLEWorldStep1

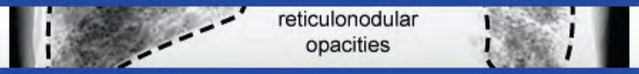

Exhibit Display

Decompensated heart failure

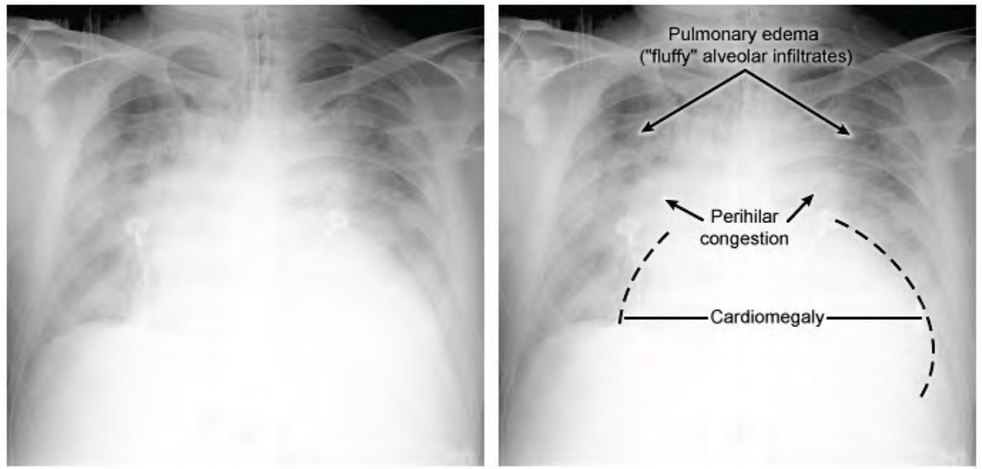

©UWorld

Zoom In | Zoom Out | Reset | New | Existing | My Notebook

As cor
(**reticu**
pulmo
fatigue

Auscu
patter
and de
dilatec

Rheur
interst
metho

(Choi
obstru
corres

(Choi
size), |

(Choi
with lu
imagir
these

(Choi
ventricle.

https://t.me/USMLEWorldStep1

reticulonodular opacities

Exhibit Display

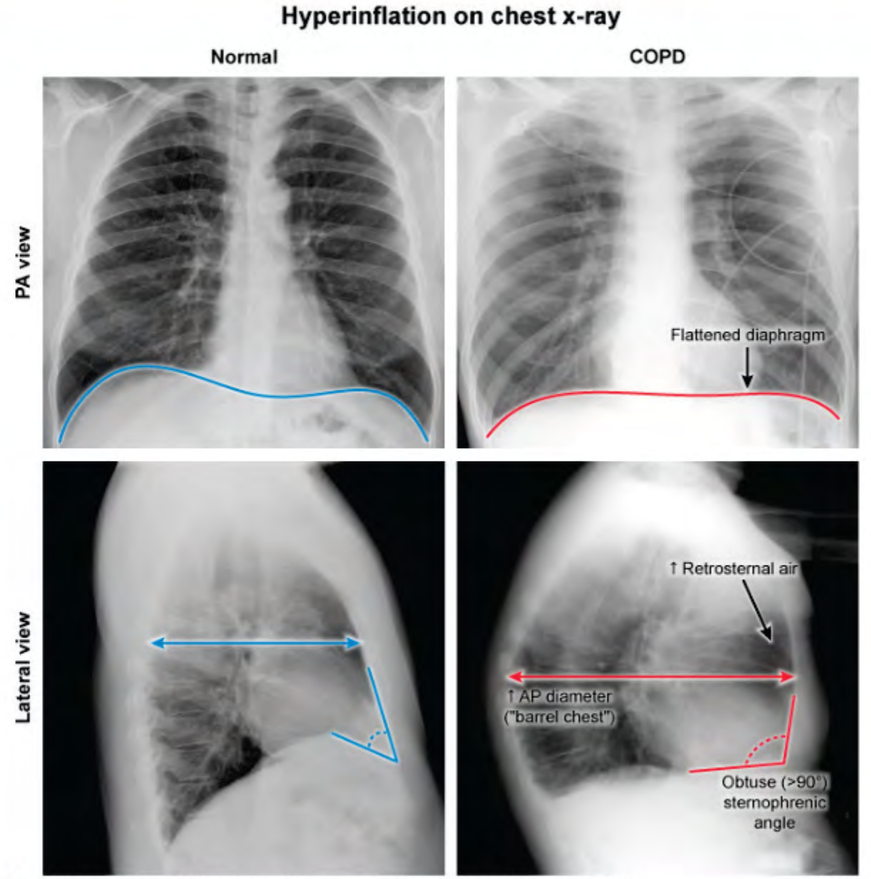

Zoom In | Zoom Out | Reset | New | Existing | My Notebook

As cor
(**reticu**
pulmo
fatigue

Auscu
patter
and de
dilatec

Rheur
interst
metho

(Choi
obstru
corres

(Choi
size), |

(Choi
with lu
imagir
these

(Choi
ventricle.

https://t.me/USMLEWorldStep1

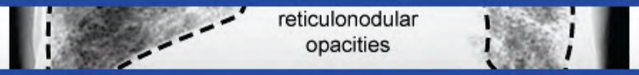

Exhibit Display

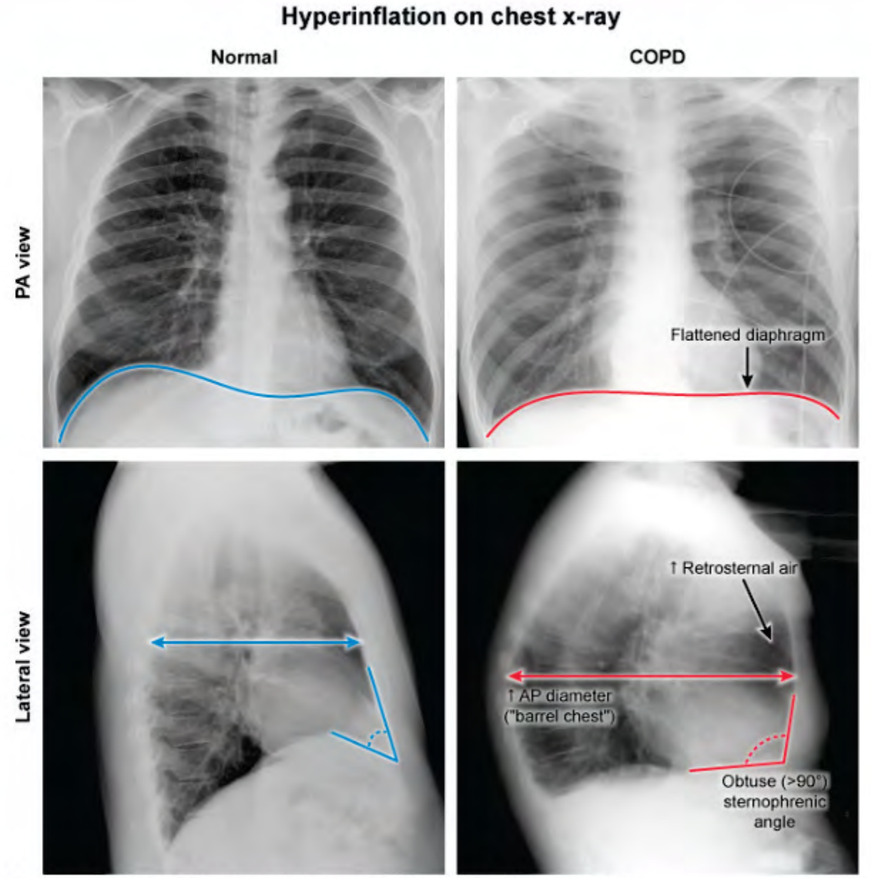

Zoom In | Zoom Out | Reset | New | Existing | My Notebook

As cor
(**reticu**
pulmo
fatigue

Auscu
patter
and de
dilatec

Rheur
interst
metho

(Choi
obstru
corres

(Choi
size), |

(Choi
with lu
imagir
these

(Choi
ventricle.

https://t.me/USMLEWorldStep1

©UWorld

As compared to normal imaging, this patient's chest x-ray shows a bilateral and diffuse pattern of small, irregular
(reticu
pulmo
fatigue

Auscu
patter
and de
dilatec

Rheun
interst
metho

(Choi
obstru
corres

(Choi
size),

(Choi
with lu
imagin
these

(Choi
ventric

Educa
Pulmo
weight loss, and bilateral reticulonodular opacities on chest x-ray. Pulmonary function tests reveal a restrictive

Exhibit Display

Pulmonary arterial hypertension

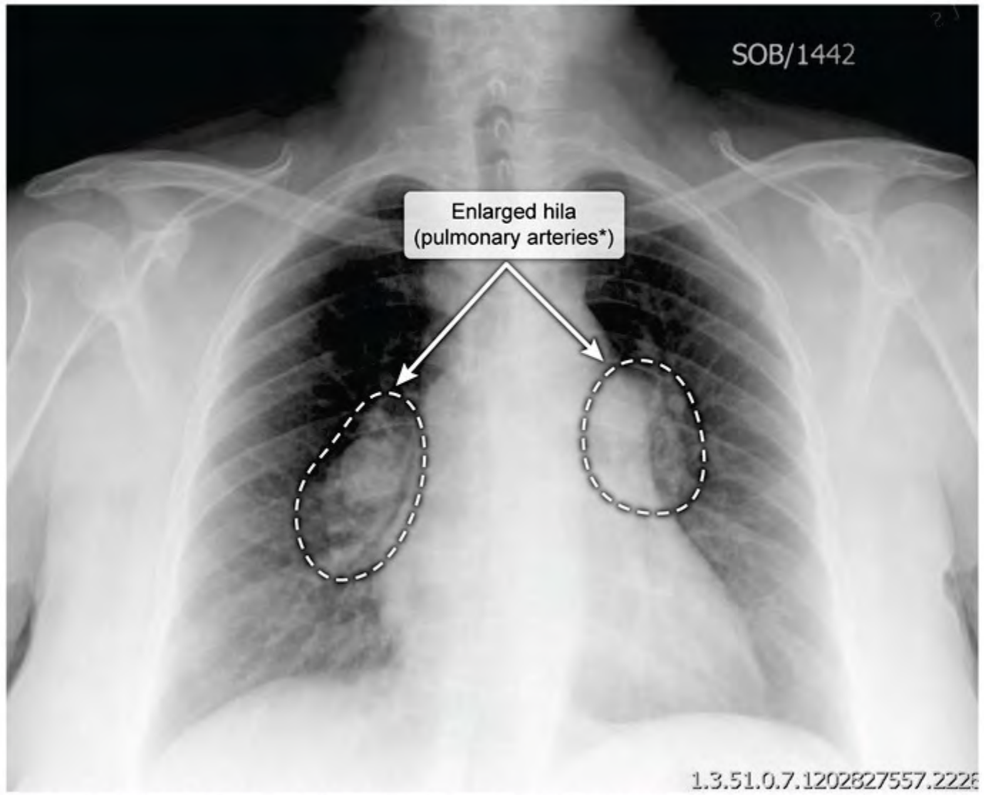

* Muscular hypertrophy in pulmonary arteries/arterioles elevates right-sided heart pressures

©UWorld

Zoom In | Zoom Out | Reset | New | Existing | My Notebook

https://t.me/USMLEWorldStep1

A 42-year-old woman comes to the office with a nonproductive cough and worsening shortness of breath with exertion. The patient has a history of primary pulmonary hypertension and underwent lung transplantation 8 months ago. She states that she has not missed any doses of her transplant medications. A chest x-ray reveals surgical evidence of her transplant but clear lung fields. Pulmonary function testing demonstrates a forced expiratory volume in 1 second (FEV_1), 67% of her best posttransplant FEV_1. Her forced vital capacity remains largely unchanged. A lung biopsy shows areas of total fibrotic obstruction in the terminal bronchioles. This patient's condition is most likely caused by which of the following?

- A. Acute transplant rejection
- B. Chronic obstructive pulmonary disease
- C. Chronic transplant rejection
- D. Ischemia-reperfusion injury
- E. Opportunistic infection
- F. Recurrence of pulmonary hypertension

Submit

https://t.me/USMLEWorldStep1

A 42-year-old woman comes to the office with a nonproductive cough and worsening shortness of breath with exertion. The patient has a history of primary pulmonary hypertension and underwent lung transplantation 8 months ago. She states that she has not missed any doses of her transplant medications. A chest x-ray reveals surgical evidence of her transplant but clear lung fields. Pulmonary function testing demonstrates a forced expiratory volume in 1 second (FEV_1), 67% of her best posttransplant FEV_1. Her forced vital capacity remains largely unchanged. A lung biopsy shows areas of total fibrotic obstruction in the terminal bronchioles. This patient's condition is most likely caused by which of the following?

- ✗ A. Acute transplant rejection (4%)
- B. Chronic obstructive pulmonary disease (6%)
- ✓ C. Chronic transplant rejection (77%)
- D. Ischemia-reperfusion injury (2%)
- E. Opportunistic infection (2%)
- F. Recurrence of pulmonary hypertension (6%)

Incorrect
Correct answer
C

77%
Answered correctly

03 secs
Time Spent

2023
Version

Explanation

This patient with cough, dyspnea, obstructive findings on spirometry, and fibrotic destruction of the small airways likely has **chronic transplant rejection**. Lung transplantation may be complicated by both acute and chronic rejection. Chronic rejection is a major cause of morbidity and mortality and occurs in almost half of all patients within 5 years of transplantation. These patients commonly present with dyspnea and a dry cough. Spirometry shows an **airflow limitation** with a drop in both the forced expiratory volume in 1 second (FEV_1) and the **FEV_1** to forced vital capacity (FVC) ratio.

https://t.me/USMLEWorldStep1

Explanation

This patient with cough, dyspnea, obstructive findings on spirometry, and fibrotic destruction of the small airways likely has **chronic transplant rejection**. Lung transplantation may be complicated by both acute and chronic rejection. Chronic rejection is a major cause of morbidity and mortality and occurs in almost half of all patients within 5 years of transplantation. These patients commonly present with dyspnea and a dry cough. Spirometry shows an **airflow limitation** with a drop in both the forced expiratory volume in 1 second (FEV_1) and the **FEV_1** to forced vital capacity (FVC) ratio.

Chronic rejection affects the small bronchioli producing the obstructive lung disease known as **bronchiolitis obliterans**. Initially, histopathology shows lymphocytic inflammation and destruction of the epithelium of the small airways. Subsequently, fibrinopurulent exudate and granulation tissue are found in the lumen of the bronchioli, which ultimately results in fibrosis, scarring, and the progressive obliteration of small airways.

(Choice A) Acute rejection usually occurs within the first 6 months. It is frequently asymptomatic and commonly discovered on surveillance biopsies. Histopathology demonstrates perivascular and interstitial mononuclear cell infiltrates.

(Choices B and F) Underlying lung disease, such as pulmonary hypertension or chronic obstructive pulmonary disease (COPD), may recur in the lung allograft. However, the obstructive pattern on spirometry and the histopathology findings are better explained by chronic rejection than by pulmonary hypertension or COPD, the latter of which would also show increased goblet cells and mucus gland hyperplasia.

(Choice D) Ischemia-reperfusion injury is a form of noncardiogenic pulmonary edema that occurs in the allograft due to surgical trauma or organ ischemia. It is seen during the first few days following transplantation.

(Choice E) Infection is a leading cause of death in lung transplant recipients. *Cytomegalovirus* causes the most significant opportunistic infection in transplant recipients. Infected cells have a characteristic intranuclear inclusion surrounded by a clear halo (owl's eye inclusion).

Educational objective:
Chronic rejection is a major problem in lung transplant recipients; it affects small airways, causing bronchiolitis

https://t.me/USMLEWorldStep1

likely has **chronic transplant rejection**. Lung transplantation may be complicated by both acute and chronic rejection. Chronic rejection is a major cause of morbidity and mortality and occurs in almost half of all patients within 5 years of transplantation. These patients commonly present with dyspnea and a dry cough. Spirometry shows an **airflow limitation** with a drop in both the forced expiratory volume in 1 second (FEV_1) and the **FEV_1** to forced vital capacity (FVC) ratio.

Chronic rejection affects the small bronchioli producing the obstructive lung disease known as **bronchiolitis obliterans**. Initially, histopathology shows lymphocytic inflammation and destruction of the epithelium of the small airways. Subsequently, fibrinopurulent exudate and granulation tissue are found in the lumen of the bronchioli, which ultimately results in fibrosis, scarring, and the progressive obliteration of small airways.

(Choice A) Acute rejection usually occurs within the first 6 months. It is frequently asymptomatic and commonly discovered on surveillance biopsies. Histopathology demonstrates perivascular and interstitial mononuclear cell infiltrates.

(Choices B and F) Underlying lung disease, such as pulmonary hypertension or chronic obstructive pulmonary disease (COPD), may recur in the lung allograft. However, the obstructive pattern on spirometry and the histopathology findings are better explained by chronic rejection than by pulmonary hypertension or COPD, the latter of which would also show increased goblet cells and mucus gland hyperplasia.

(Choice D) Ischemia-reperfusion injury is a form of noncardiogenic pulmonary edema that occurs in the allograft due to surgical trauma or organ ischemia. It is seen during the first few days following transplantation.

(Choice E) Infection is a leading cause of death in lung transplant recipients. *Cytomegalovirus* causes the most significant opportunistic infection in transplant recipients. Infected cells have a characteristic intranuclear inclusion surrounded by a clear halo (owl's eye inclusion).

Educational objective:
Chronic rejection is a major problem in lung transplant recipients; it affects small airways, causing bronchiolitis obliterans. It is characterized by lymphocytic inflammation, fibrosis, and, ultimately, destruction of the bronchioles.

References

- A review of bronchiolitis obliterans syndrome and therapeutic strategies.

https://t.me/USMLEWorldStep1

A 32-year-old woman comes to the office due to exertional dyspnea that has progressed over the last year. She can hardly walk a block without stopping to rest. The patient's mother died of "heart failure" at age 40. During auscultation, the pulmonary component of S2 is louder than the aortic component in the right and left second intercostal space. An accentuated impulse can also be palpated along the left upper sternal border. Chest x-ray shows clear lungs. Which of the following is the most likely cause of this patient's findings?

- A. Hypertensive heart disease
- B. Hypertrophic cardiomyopathy
- C. Left bundle branch block
- D. Pulmonary hypertension
- E. Pulmonic valve stenosis

Submit

https://t.me/USMLEWorldStep1

A 32-year-old woman comes to the office due to exertional dyspnea that has progressed over the last year. She can hardly walk a block without stopping to rest. The patient's mother died of "heart failure" at age 40. During auscultation, the pulmonary component of S2 is louder than the aortic component in the right and left second intercostal space. An accentuated impulse can also be palpated along the left upper sternal border. Chest x-ray shows clear lungs. Which of the following is the most likely cause of this patient's findings?

- A. Hypertensive heart disease (0%)
- ✕ B. Hypertrophic cardiomyopathy (4%)
- C. Left bundle branch block (2%)
- ✓ D. Pulmonary hypertension (72%)
- E. Pulmonic valve stenosis (19%)

Incorrect
Correct answer
D

72%
Answered correctly

03 secs
Time Spent

2023
Version

Explanation

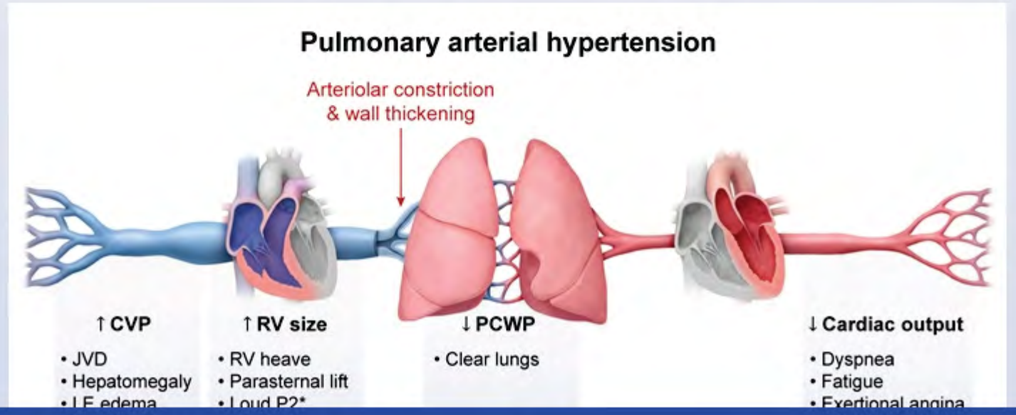

https://t.me/USMLEWorldStep1

Incorrect
Correct answer
D

72%
03 secs
2023

Exhibit Display

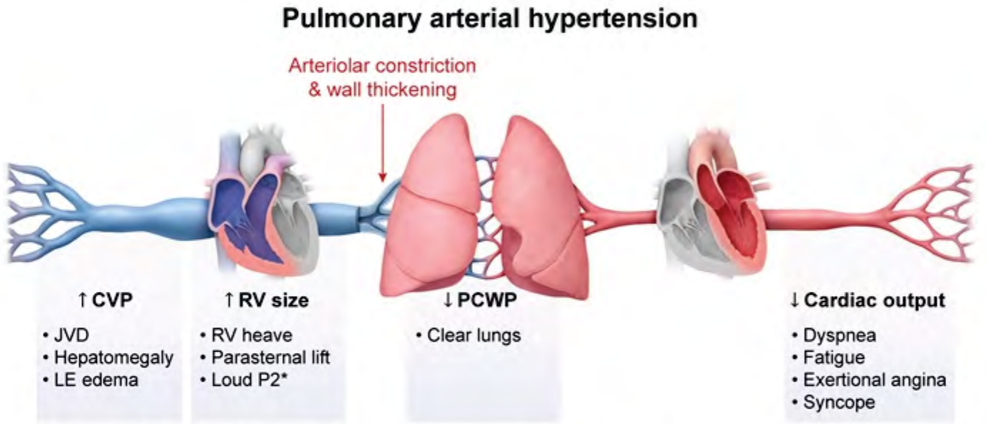

Zoom In | Zoom Out | Reset | New | Existing | My Notebook

This p
preser
exami
setting
pressu
the lef

Pulmo
small p
dyspnea are common and result from decreased cardiac output due to the inability of the right ventricle to pump blood through the lungs. Right-sided heart failure eventually develops, but because left ventricular function

https://t.me/USMLEWorldStep1

*Due to elevated pulmonary arterial pressure.
CVP = central venous pressure; **JVD** = jugular venous distension; **LE** = lower extremity; **PCWP** = pulmonary capillary wedge pressure; **RV** = right ventricle/ventricular.

©UWorld

This patient's clinical presentation is consistent with **pulmonary hypertension**. The disease most commonly presents with progressive dyspnea, and patients may also experience exertional angina or syncope. Physical examination reveals a **loud pulmonic component (P2) of S2**, caused by forceful pulmonic valve closure in the setting of high pulmonary arterial pressure. In addition, the right ventricle becomes enlarged due to increased pressure load (ie, concentric right ventricular hypertrophy), which can create an accentuated impulse palpated at the left sternal border (**left parasternal lift** due to **right ventricular heave**).

Pulmonary arterial hypertension describes pulmonary hypertension directly caused by vascular remodeling of the small pulmonary arteries/arterioles; relatively young women are most commonly affected. Fatigue and exertional dyspnea are common and result from decreased cardiac output due to the inability of the right ventricle to pump blood through the lungs. Right-sided heart failure eventually develops, but because left ventricular function remains intact, there is an **absence of pulmonary edema** in pulmonary arterial hypertension.

(Choice A) Hypertensive heart disease occurs as the result of prolonged systemic hypertension. It involves concentric left ventricular hypertrophy, leading to impaired ventricular compliance and diastolic heart failure. Pulmonary edema is expected with diastolic heart failure that is severe enough to cause dyspnea.

(Choice B) Hypertrophic cardiomyopathy typically demonstrates a crescendo-decrescendo systolic murmur best heard at the left sternal border. The murmur intensifies with maneuvers that decrease left ventricular blood volume (eg, abrupt standing, Valsalva strain phase).

(Choice C) Left bundle branch block can delay closure of the aortic valve, leading to later occurrence of the aortic component (A2) of S2 and narrowed or paradoxical splitting. However, left bundle branch block is unlikely to significantly affect the relative audible intensity of A2 and P2.

(Choice E) Pulmonic valve stenosis can delay the occurrence of P2 (later valve closure) but typically leads to a softer intensity of P2.

Educational objective:
Pulmonary hypertension can be recognized on physical examination by a loud pulmonic component of S2 and an accentuated, palpable impulse at the left sternal border (left parasternal lift due to right ventricular heave).

https://t.me/USMLEWorldStep1

presents with progressive dyspnea, and patients may also experience exertional angina or syncope. Physical examination reveals a **loud pulmonic component (P2) of S2**, caused by forceful pulmonic valve closure in the setting of high pulmonary arterial pressure. In addition, the right ventricle becomes enlarged due to increased pressure load (ie, concentric right ventricular hypertrophy), which can create an accentuated impulse palpated at the left sternal border (**left parasternal lift** due to **right ventricular heave**).

Pulmonary arterial hypertension describes pulmonary hypertension directly caused by vascular remodeling of the small pulmonary arteries/arterioles; relatively young women are most commonly affected. Fatigue and exertional dyspnea are common and result from decreased cardiac output due to the inability of the right ventricle to pump blood through the lungs. Right-sided heart failure eventually develops, but because left ventricular function remains intact, there is an **absence of pulmonary edema** in pulmonary arterial hypertension.

(Choice A) Hypertensive heart disease occurs as the result of prolonged systemic hypertension. It involves concentric left ventricular hypertrophy, leading to impaired ventricular compliance and diastolic heart failure. Pulmonary edema is expected with diastolic heart failure that is severe enough to cause dyspnea.

(Choice B) Hypertrophic cardiomyopathy typically demonstrates a crescendo-decrescendo systolic murmur best heard at the left sternal border. The murmur intensifies with maneuvers that decrease left ventricular blood volume (eg, abrupt standing, Valsalva strain phase).

(Choice C) Left bundle branch block can delay closure of the aortic valve, leading to later occurrence of the aortic component (A2) of S2 and narrowed or paradoxical splitting. However, left bundle branch block is unlikely to significantly affect the relative audible intensity of A2 and P2.

(Choice E) Pulmonic valve stenosis can delay the occurrence of P2 (later valve closure) but typically leads to a softer intensity of P2.

Educational objective:
Pulmonary hypertension can be recognized on physical examination by a loud pulmonic component of S2 and an accentuated, palpable impulse at the left sternal border (left parasternal lift due to right ventricular heave).

Pathophysiology	Pulmonary & Critical Care	Pulmonary Arterial Hypertension
Subject	System	Topic

https://t.me/USMLEWorldStep1

• JVD
• Hepatomegaly
• RV heave
• Parasternal lift
• Clear lungs
• Dyspnea
• Fatigue

Exhibit Display

Classification of pulmonary hypertension	
Pulmonary arterial hypertension (group 1)	• Primary change in pulmonary arteries ◦ Hereditary (eg, *BMPR2* mutation) ◦ Connective tissue disease (eg, RA, SS) ◦ HIV infection • Treatment targeted at endothelial dysfunction
Pulmonary hypertension (groups 2-5)	• Secondary to another disease process ◦ Left-sided heart failure (group 2) ◦ Chronic lung disease/hypoxia (group 3) ◦ Chronic pulmonary thromboembolism (group 4) ◦ Other (eg, sarcoidosis) (group 5) • Treatment aimed at underlying disease
RA = rheumatoid arthritis; **SS** = systemic sclerosis.	

New | Existing | My Notebook

This p
preser
exami
setting
pressu
the lef

Pulmo
small
dyspn
blood
remain

(Choi
concer
Pulmo

(Choi
heard
(eg, ab

(Choi
compo
signifi

(Choice E) Pulmonic valve stenosis can delay the occurrence of P2 (later valve closure) but typically leads to a softer intensity of P2.

https://t.me/USMLEWorldStep1

• JVD
• RV heave
• Clear lungs
• Dyspnea

Exhibit Display

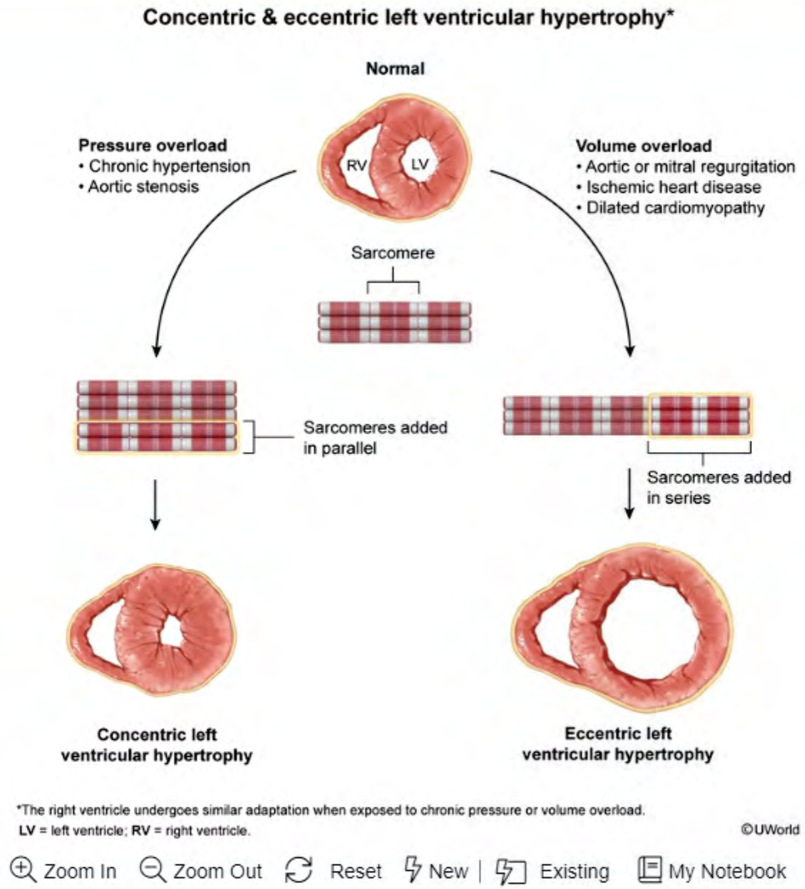

This p
preser
exami
setting
pressu
the lef

Pulmo
small p
dyspn
blood
remain

(Choi
concer
Pulmo

(Choi
heard
(eg, ab

(Choi
compo
significantly affect the relative audible intensity of A2 and P2.

(Choice E) Pulmonic valve stenosis can delay the occurrence of P2 (later valve closure) but typically leads to a softer intensity of P2.

https://t.me/USMLEWorldStep1

*Due to elevated pulmonary arterial pressure.
CVP = central venous pressure; **JVD** = jugular venous distension; **LE** = lower extremity; **PCWP** = pulmonary capillary wedge pressure; **RV** = right ventricle/ventricular.

©UWorld

This p
preser
exami
setting
pressu
the lef

Pulmo
small p
dyspn
blood
remain

(Choi
concer
Pulmo

(Choi
heard
(eg, ab

(Choi
compo
signifi

(Choi
softer

Educa

Pulmonary hypertension can be recognized on physical examination by a loud pulmonic component of S2 and an accentuated, palpable impulse at the left sternal border (left parasternal lift due to right ventricular heave).

Exhibit Display

Splitting of S2

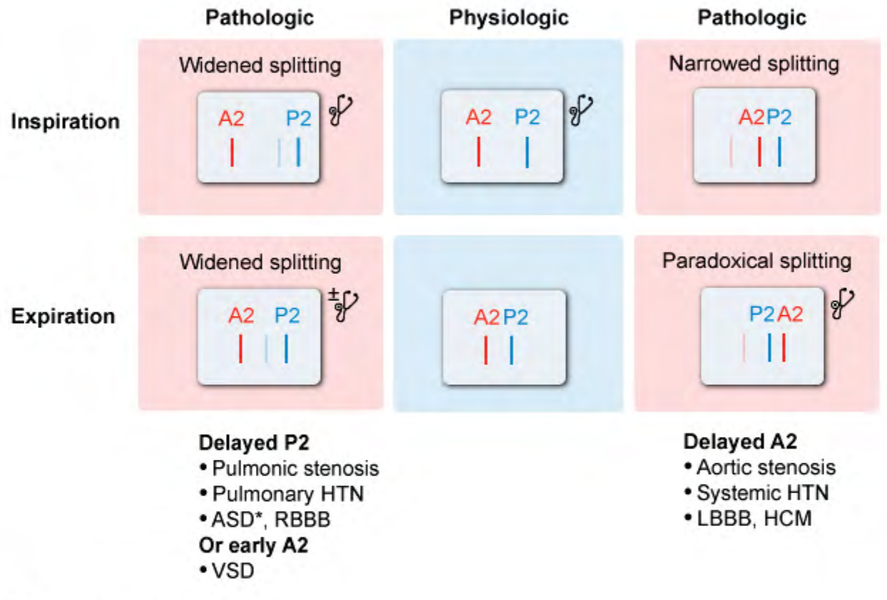

Delayed P2
- Pulmonic stenosis
- Pulmonary HTN
- ASD*, RBBB

Or early A2
- VSD

Delayed A2
- Aortic stenosis
- Systemic HTN
- LBBB, HCM

= Split is audibly discernible.
*Widened splitting is fixed throughout respiratory cycle.
ASD = atrial septal defect; **HCM** = hypertrophic cardiomyopathy; **HTN** = hypertension; **LBBB** = left bundle-branch block; **RBBB** = right bundle-branch block; **VSD** = ventricular septal defect.

©UWorld

Zoom In | Zoom Out | Reset | New | Existing | My Notebook

https://t.me/USMLEWorldStep1

A 66-year-old man is brought to the office by his daughter for medical evaluation. The patient reports no chronic medical conditions but has not seen a physician for many years. He takes no medications. The patient is a retired veteran and recently relocated to live closer to his daughter. He is an ex-smoker and does not use alcohol or recreational drugs. Oxygen saturation on room air is 98%. On physical examination, normal breath sounds are heard throughout both lungs. Hand examination findings are shown in the exhibit. The patient's hand findings are most suggestive of which of the following underlying conditions?

- A. Chronic bronchitis
- B. Chronic kidney disease
- C. Iron deficiency anemia
- D. Lung cancer
- E. Plaque psoriasis

Submit

https://t.me/USMLEWorldStep1

A 66-year-old man is brought to the office by his daughter for medical evaluation. The patient reports no chronic
medic
vetera
recrea
heard
most s

Sub

Exhibit Display

Zoom In | Zoom Out | Reset | New | Existing | My Notebook

https://t.me/USMLEWorldStep1

A 66-year-old man is brought to the office by his daughter for medical evaluation. The patient reports no chronic medical conditions but has not seen a physician for many years. He takes no medications. The patient is a retired veteran and recently relocated to live closer to his daughter. He is an ex-smoker and does not use alcohol or recreational drugs. Oxygen saturation on room air is 98%. On physical examination, normal breath sounds are heard throughout both lungs. Hand examination findings are shown in the exhibit. The patient's hand findings are most suggestive of which of the following underlying conditions?

- ✗ A. Chronic bronchitis (36%)
- B. Chronic kidney disease (5%)
- C. Iron deficiency anemia (15%)
- ✓ D. Lung cancer (41%)
- E. Plaque psoriasis (1%)

Incorrect
Correct answer
D

41%
Answered correctly

16 secs
Time Spent

2023
Version

Explanation

Conditions associated with digital clubbing	
Pulmonary neoplasms	• Bronchogenic carcinoma (adenocarcinoma most common)
Cardiopulmonary disease with hypoxemia	• Cyanotic congenital heart disease • Pulmonary arteriovenous malformations • Interstitial lung disease
	• Chronic lung abscess

https://t.me/USMLEWorldStep1

Conditions associated with digital clubbing	
Pulmonary neoplasms	• Bronchogenic carcinoma (adenocarcinoma most common)
Cardiopulmonary disease with hypoxemia	• Cyanotic congenital heart disease • Pulmonary arteriovenous malformations • Interstitial lung disease
Chronic cardiopulmonary infections	• Chronic lung abscess • Chronic empyema • Bronchiectasis (eg, cystic fibrosis) • Subacute/chronic bacterial endocarditis • Cavitary infections (eg, fungal, mycobacterial)

The patient is a former smoker and presents with **digital clubbing**, a thickening and widening of the nail bed and distal phalanges that give the fingers a bulbous drumstick appearance. Normally, when two opposing fingers are held nail to nail, a diamond-shaped space is formed between proximal nail folds; obliteration of this space is consistent with clubbing.

Clubbing is observed in cardiopulmonary disease states where **hypoxic-inflammatory pathways** are activated, releasing platelet and fibroblast-derived **growth factors** (especially vascular endothelial growth factor [VEGF]) that promote platelet clumping/embedment in the distal capillary beds (fingers, toes), which then leads to **local fibrovascular proliferation**.

Lung adenocarcinoma (ie, tumor-secreted VEGF) is the most common cause of clubbing in adults. Other common causes of clubbing include chronic chest infections (eg, bronchiectasis) and cardiopulmonary diseases with hypoxemia (eg, cyanotic heart defects). Occasionally, clubbing is associated with a painful periosteal reaction and synovitis, known as **hypertrophic pulmonary osteoarthropathy**, a paraneoplastic syndrome strongly linked to lung adenocarcinoma.

Examination for clubbing is clinically valuable because it may be the **only visible physical sign** of lung cancer

https://t.me/USMLEWorldStep1

neoplasms	most common)
Cardiopulmonary disease with hypoxemia	• Cyanotic congenital heart disease • Pulmonary arteriovenous malformations • Interstitial lung disease
Chronic cardiopulmonary infections	• Chronic lung abscess • Chronic empyema • Bronchiectasis (eg, cystic fibrosis) • Subacute/chronic bacterial endocarditis • Cavitary infections (eg, fungal, mycobacterial)

The patient is a former smoker and presents with **digital clubbing**, a thickening and widening of the nail bed and distal phalanges that give the fingers a bulbous drumstick appearance. Normally, when two opposing fingers are held nail to nail, a diamond-shaped space is formed between proximal nail folds; obliteration of this space is consistent with clubbing.

Clubbing is observed in cardiopulmonary disease states where **hypoxic-inflammatory pathways** are activated, releasing platelet and fibroblast-derived **growth factors** (especially vascular endothelial growth factor [VEGF]) that promote platelet clumping/embedment in the distal capillary beds (fingers, toes), which then leads to **local fibrovascular proliferation**.

Lung adenocarcinoma (ie, tumor-secreted VEGF) is the most common cause of clubbing in adults. Other common causes of clubbing include chronic chest infections (eg, bronchiectasis) and cardiopulmonary diseases with hypoxemia (eg, cyanotic heart defects). Occasionally, clubbing is associated with a painful periosteal reaction and synovitis, known as **hypertrophic pulmonary osteoarthropathy**, a paraneoplastic syndrome strongly linked to lung adenocarcinoma.

Examination for clubbing is clinically valuable because it may be the **only visible physical sign** of lung cancer, including small and surgically resectable (curable) tumors that would be otherwise asymptomatic. Therefore, the presence of clubbing should prompt further imaging of the chest for malignancy.

(Choice A) Uncomplicated chronic obstructive pulmonary disease (COPD without hypoxemia) alone is **not**

https://t.me/USMLEWorldStep1

releasing platelet and fibroblast-derived **growth factors** (especially vascular endothelial growth factor [VEGF]) that promote platelet clumping/embedment in the distal capillary beds (fingers, toes), which then leads to **local fibrovascular proliferation**.

Lung adenocarcinoma (ie, tumor-secreted VEGF) is the most common cause of clubbing in adults. Other common causes of clubbing include chronic chest infections (eg, bronchiectasis) and cardiopulmonary diseases with hypoxemia (eg, cyanotic heart defects). Occasionally, clubbing is associated with a painful periosteal reaction and synovitis, known as **hypertrophic pulmonary osteoarthropathy**, a paraneoplastic syndrome strongly linked to lung adenocarcinoma.

Examination for clubbing is clinically valuable because it may be the **only visible physical sign** of lung cancer, including small and surgically resectable (curable) tumors that would be otherwise asymptomatic. Therefore, the presence of clubbing should prompt further imaging of the chest for malignancy.

(Choice A) Uncomplicated chronic obstructive pulmonary disease (COPD without hypoxemia) alone is *not* associated with clubbing; clubbing in a patient with COPD should trigger further investigation for underlying complications (eg, malignancy, bronchiectasis, pulmonary hypertension). In addition, this patient has normal breath sounds, making COPD (eg, emphysema, chronic bronchitis) unlikely.

(Choice B) Chronic renal failure is associated with "half-and-half" nails (Lindsay nails), a sharply demarcated transverse leukonychia. The mechanism remains unknown but is unlikely to be related to azotemia because the transition line disappears after renal transplantation but not with hemodialysis.

(Choice C) Iron deficiency anemia is associated with koilonychia, or scooped concavity of the nail bed ("spoon nails"), possibly due to chronic nutrient deficiency leading to regression of the nail matrix.

(Choice E) Psoriatic nail dystrophy is due to primary involvement of the nail by psoriasis itself. It manifests as nail pitting, thickening, brittleness, and onycholysis (separation from the underlying nail bed).

Educational objective:
The most common cause of digital clubbing in adults is pulmonary malignancy (especially lung adenocarcinoma). More generally, clubbing is a sign of chronic cardiopulmonary disease associated with activation of hypoxic-inflammatory signaling (eg, chronic chest infections, right-to-left shunting).

References

https://t.me/USMLEWorldStep1

cardiopulmonary	• Bronchiectasis (eg, cystic fibrosis) • Subacute/chronic bacterial endocarditis

Exhibit Display

Digital clubbing | Clubbing

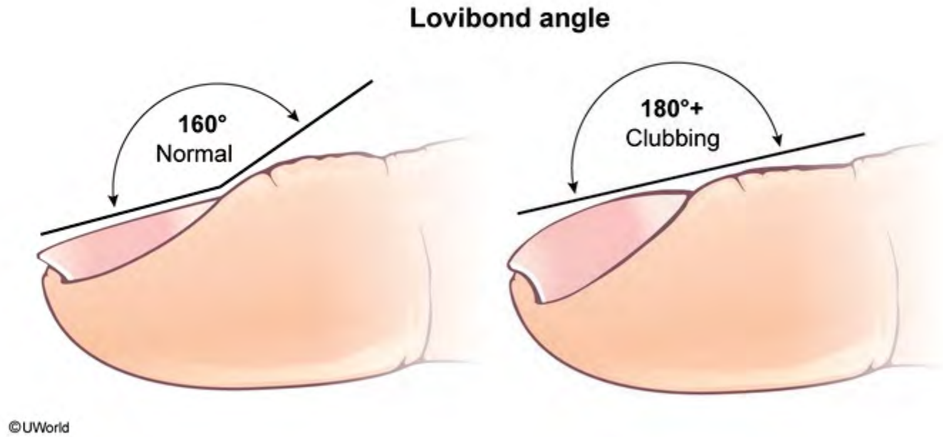

Zoom In | Zoom Out | Reset | New | Existing | My Notebook

The pa
distal
held n
consis

Clubbi
releas
promo
fibrov

Lung
comm
with hy
and sy
to lung

Exami
includi
preser

(Choi
associ
compli
breath

(Choi
transverse leukonychia. The mechanism remains unknown but is unlikely to be related to azotemia because the transition line disappears after renal transplantation but not with hemodialysis.

https://t.me/USMLEWorldStep1

cardiopulmonary	• Bronchiectasis (eg, cystic fibrosis) • Subacute/chronic bacterial endocarditis

Exhibit Display

Digital clubbing | Clubbing

Digital clubbing

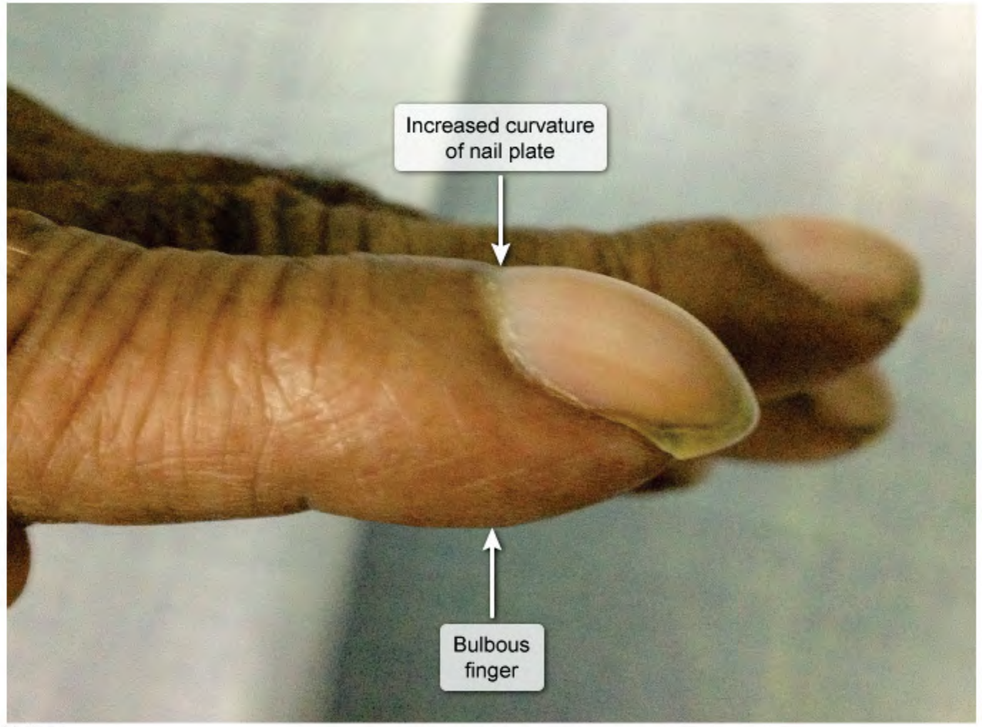

©UWorld

Zoom In | Zoom Out | Reset | New | Existing | My Notebook

The pa
distal p
held n
consis

Clubbi
releas
promo
fibrov

Lung
comm
with hy
and sy
to lung

Exami
includi
preser

(Choi
associ
compli
breath

(Choi
transverse leukonychia. The mechanism remains unknown but is unlikely to be related to azotemia because the transition line disappears after renal transplantation but not with hemodialysis.

https://t.me/USMLEWorldStep1

The patient is a former smoker and presents with **digital clubbing**, a thickening and widening of the nail bed and distal p
held n
consis

Clubbi
releas
promo
fibrov

Lung
comm
with hy
and sy
to lung

Exami
includi
preser

(Choi
associ
compli
breath

(Choi
transv
transit

(Choi
nails"), possibly due to chronic nutrient deficiency leading to regression of the nail matrix.

(Choice E) Psoriatic nail dystrophy is due to primary involvement of the nail by psoriasis itself. It manifests as nail

Exhibit Display

Half-and-half nails

*Associated with chronic renal failure.

©UWorld

Zoom In | Zoom Out | Reset | New | Existing | My Notebook

https://t.me/USMLEWorldStep1

The patient is a former smoker and presents with **digital clubbing**, a thickening and widening of the nail bed and
distal p
held n
consis

Clubbi
releas
promo
fibrov

Lung
comm
with hy
and sy
to lung

Exami
includi
preser

(Choi
associ
compli
breath

(Choi
transv
transit

(Choi
nails"), possibly due to chronic nutrient deficiency leading to regression of the nail matrix.

(Choice E) Psoriatic nail dystrophy is due to primary involvement of the nail by psoriasis itself. It manifests as nail

Exhibit Display

Koilonychia

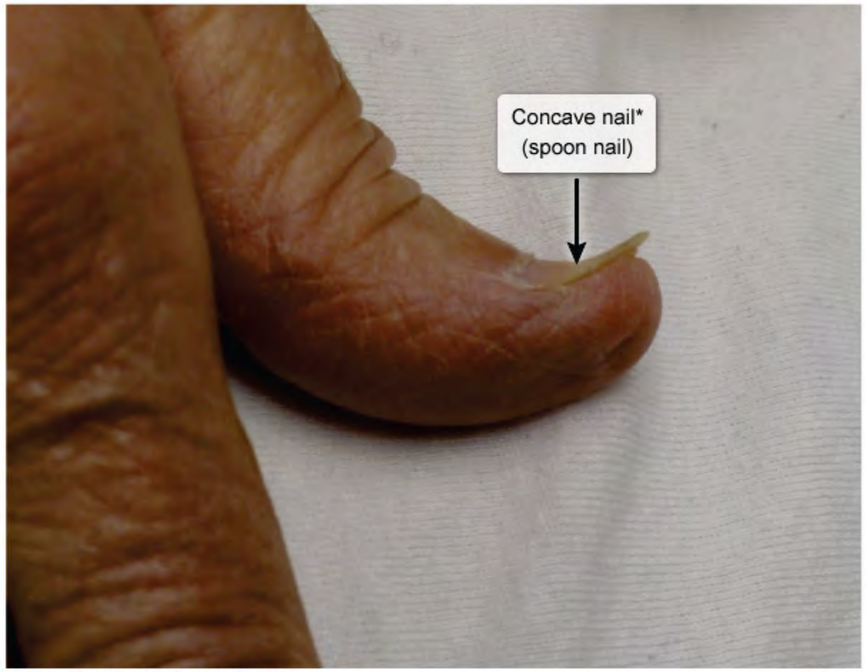

*Associated with iron deficiency anemia.

©UWorld

Zoom In | Zoom Out | Reset | New | Existing | My Notebook

https://t.me/USMLEWorldStep1

held nail to nail, a diamond-shaped space is formed between proximal nail folds; obliteration of this space is consistent with clubbing.

Clubbi
releas
promo
fibrov

Lung
comm
with hy
and sy
to lung

Exami
includi
preser

(Choi
associ
compli
breath

(Choi
transv
transit

(Choi
nails")

(Choi
pitting

Exhibit Display

Psoriasis

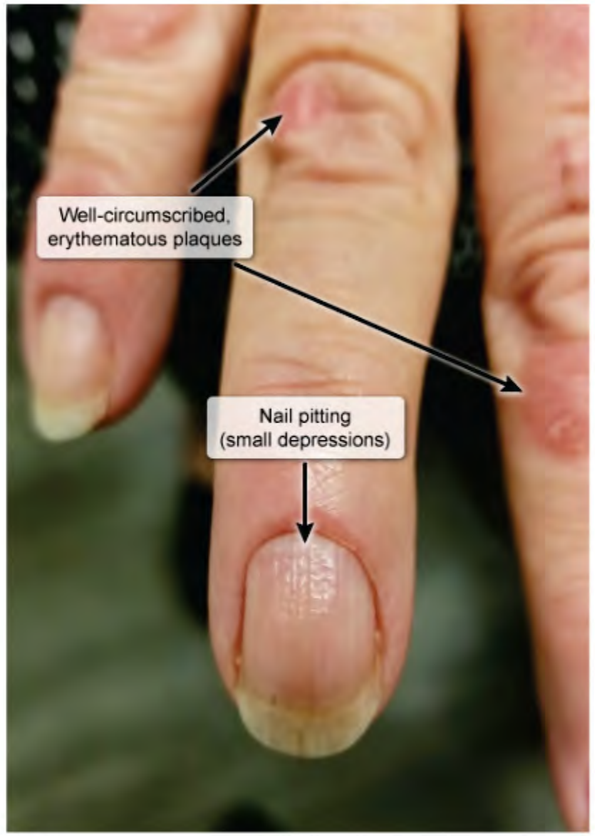

Zoom In | Zoom Out | Reset | New | Existing | My Notebook

Educational objective:

The most common cause of digital clubbing in adults is pulmonary malignancy (especially lung adenocarcinoma).

https://t.me/USMLEWorldStep1

A 54-year-old man comes to the emergency department due to worsening fever, cough, and shortness of breath. The patient initially presented a week ago with a fever, headache, myalgia, nasal discharge, and a sore throat. He tested positive for influenza A and was discharged home with symptomatic treatment. The patient's symptoms gradually improved, but over the past 2 days he has had high fevers, cough productive of yellowish sputum, sharp right-sided chest pain, and shortness of breath. The patient has no other medical problems and does not use tobacco, alcohol, or illicit drugs. Temperature is 38.9 C (102 F), blood pressure is 118/66 mm Hg, and pulse is 110/min. Physical examination reveals right-sided lung crackles. Chest x-ray reveals infiltrates in the right lung. Which of the following pathogens is most likely to be isolated from this patient's sputum?

- A. Cytomegalovirus
- B. *Klebsiella pneumoniae*
- C. *Listeria monocytogenes*
- D. Nontuberculous mycobacteria
- E. *Staphylococcus aureus*

Submit

https://t.me/USMLEWorldStep1

A 54-year-old man comes to the emergency department due to worsening fever, cough, and shortness of breath. The patient initially presented a week ago with a fever, headache, myalgia, nasal discharge, and a sore throat. He tested positive for influenza A and was discharged home with symptomatic treatment. The patient's symptoms gradually improved, but over the past 2 days he has had high fevers, cough productive of yellowish sputum, sharp right-sided chest pain, and shortness of breath. The patient has no other medical problems and does not use tobacco, alcohol, or illicit drugs. Temperature is 38.9 C (102 F), blood pressure is 118/66 mm Hg, and pulse is 110/min. Physical examination reveals right-sided lung crackles. Chest x-ray reveals infiltrates in the right lung. Which of the following pathogens is most likely to be isolated from this patient's sputum?

- A. Cytomegalovirus (1%)
- ✗ B. *Klebsiella pneumoniae* (14%)
- C. *Listeria monocytogenes* (2%)
- D. Nontuberculous mycobacteria (4%)
- ✓ E. *Staphylococcus aureus* (77%)

Incorrect
Correct answer
E

77%
Answered correctly

03 secs
Time Spent

2023
Version

Explanation

Influenza virus attacks the tracheobronchial epithelium and results in decreased cell size and a **loss of cilia**, which promotes bacterial colonization. The influenza surface protein neuraminidase also cleaves sialic acid off host glycoproteins, leading to an increased amount of free sugar in the respiratory tract, which fosters bacterial growth. These changes put patients recovering from influenza at increased risk for **secondary bacterial infections** in the respiratory tree.

Secondary bacterial pneumonia should be suspected when a patient with influenza has improved symptoms and

https://t.me/USMLEWorldStep1

Explanation

Influenza virus attacks the tracheobronchial epithelium and results in decreased cell size and a **loss of cilia**, which promotes bacterial colonization. The influenza surface protein neuraminidase also cleaves sialic acid off host glycoproteins, leading to an increased amount of free sugar in the respiratory tract, which fosters bacterial growth. These changes put patients recovering from influenza at increased risk for **secondary bacterial infections** in the respiratory tree.

Secondary bacterial pneumonia should be suspected when a patient with influenza has improved symptoms and then develops **worsening** fever and lower respiratory tract manifestations such as productive cough, pleuritic chest pain, and shortness of breath. Physical examination and chest x-ray findings typically demonstrate pulmonary consolidation. Most cases are caused by *Streptococcus pneumoniae*, ***Staphylococcus aureus***, and *Haemophilus influenzae*. Although the elderly are affected most commonly, post-influenza pneumonia due to *S aureus* frequently develops in young, previously healthy patients.

(Choice A) Cytomegalovirus may cause pneumonia in patients who are immunocompromised (eg, AIDS, post-transplantation). It is not associated with post-influenza infections and usually causes bilateral interstitial infiltrates on chest x-ray.

(Choice B) *Klebsiella pneumoniae* most commonly causes nosocomial pneumonia or aspiration pneumonia in patients who abuse alcohol or use intravenous drugs. It is classically associated with thick, blood-tinged "currant jelly" sputum due to significant inflammation and necrosis. This pathogen does not typically cause post-influenza pneumonia.

(Choice C) Older patients and those who are immunocompromised are at increased risk for *Listeria monocytogenes* sepsis and meningitis; pneumonia would be atypical.

(Choice D) *Mycobacterium avium-intracellulare* causes disseminated disease in AIDS, *M kansasii* may cause pulmonary tuberculosis-like symptoms, *M leprae* is responsible for cutaneous leprosy, and *M scrofulaceum* causes cervical lymphadenitis in children.

Educational objective:

Influenza infection alters the respiratory epithelium and can increase the risk of secondary bacterial pneumonia.

https://t.me/USMLEWorldStep1

which promotes bacterial colonization. The influenza surface protein neuraminidase also cleaves sialic acid off host glycoproteins, leading to an increased amount of free sugar in the respiratory tract, which fosters bacterial growth. These changes put patients recovering from influenza at increased risk for **secondary bacterial infections** in the respiratory tree.

Secondary bacterial pneumonia should be suspected when a patient with influenza has improved symptoms and then develops **worsening** fever and lower respiratory tract manifestations such as productive cough, pleuritic chest pain, and shortness of breath. Physical examination and chest x-ray findings typically demonstrate pulmonary consolidation. Most cases are caused by *Streptococcus pneumoniae*, ***Staphylococcus aureus***, and *Haemophilus influenzae*. Although the elderly are affected most commonly, post-influenza pneumonia due to *S aureus* frequently develops in young, previously healthy patients.

(Choice A) Cytomegalovirus may cause pneumonia in patients who are immunocompromised (eg, AIDS, post-transplantation). It is not associated with post-influenza infections and usually causes bilateral interstitial infiltrates on chest x-ray.

(Choice B) *Klebsiella pneumoniae* most commonly causes nosocomial pneumonia or aspiration pneumonia in patients who abuse alcohol or use intravenous drugs. It is classically associated with thick, blood-tinged "currant jelly" sputum due to significant inflammation and necrosis. This pathogen does not typically cause post-influenza pneumonia.

(Choice C) Older patients and those who are immunocompromised are at increased risk for *Listeria monocytogenes* sepsis and meningitis; pneumonia would be atypical.

(Choice D) *Mycobacterium avium-intracellulare* causes disseminated disease in AIDS, *M kansasii* may cause pulmonary tuberculosis-like symptoms, *M leprae* is responsible for cutaneous leprosy, and *M scrofulaceum* causes cervical lymphadenitis in children.

Educational objective:
Influenza infection alters the respiratory epithelium and can increase the risk of secondary bacterial pneumonia. The leading pathogens are *Streptococcus pneumoniae*, *Staphylococcus aureus*, and *Haemophilus influenzae*. The elderly are affected most commonly, but *S aureus* can cause secondary pneumonia in young, previously healthy patients.

https://t.me/USMLEWorldStep1

A 4-year-old boy is brought to the office due to a progressively worsening cough for the past 2 days that is productive of yellow sputum. A year ago, he was found to have bilateral lower-lobe pulmonary infiltrates on chest x-ray and was diagnosed with pneumonia. The patient has since had 2 additional episodes of pneumonia, each requiring antibiotics for improvement of symptoms. His current chest x-ray again reveals bilateral lower lobe infiltrates. Further testing shows a high chloride content in his sweat. Which of the following abnormalities is most likely to be seen in this patient?

- A. Abnormal post-translational processing of a transmembrane protein
- B. Decreased transcription of a transmembrane protein
- C. Increased conductivity of a transmembrane chloride channel
- D. Presence of a truncated transmembrane protein on the cell surface
- E. Transmembrane protein with increased regulatory response to cAMP and ATP

Submit

https://t.me/USMLEWorldStep1

A 4-year-old boy is brought to the office due to a progressively worsening cough for the past 2 days that is productive of yellow sputum. A year ago, he was found to have bilateral lower-lobe pulmonary infiltrates on chest x-ray and was diagnosed with pneumonia. The patient has since had 2 additional episodes of pneumonia, each requiring antibiotics for improvement of symptoms. His current chest x-ray again reveals bilateral lower lobe infiltrates. Further testing shows a high chloride content in his sweat. Which of the following abnormalities is most likely to be seen in this patient?

✓ A. Abnormal post-translational processing of a transmembrane protein (61%)
✗ B. Decreased transcription of a transmembrane protein (9%)
C. Increased conductivity of a transmembrane chloride channel (9%)
D. Presence of a truncated transmembrane protein on the cell surface (18%)
E. Transmembrane protein with increased regulatory response to cAMP and ATP (1%)

Incorrect
Correct answer
A

61%
Answered correctly

03 secs
Time Spent

2023
Version

Explanation

ΔF508 mutations & CFTR post-translational processing

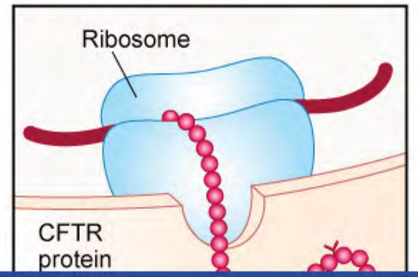

https://t.me/USMLEWorldStep1

A 4-year-old boy is brought to the office due to a progressively worsening cough for the past 2 days that is
produ
x-ray a
requiri
infiltrat
likely t

Inco
Corre
A

Expl

Exhibit Display

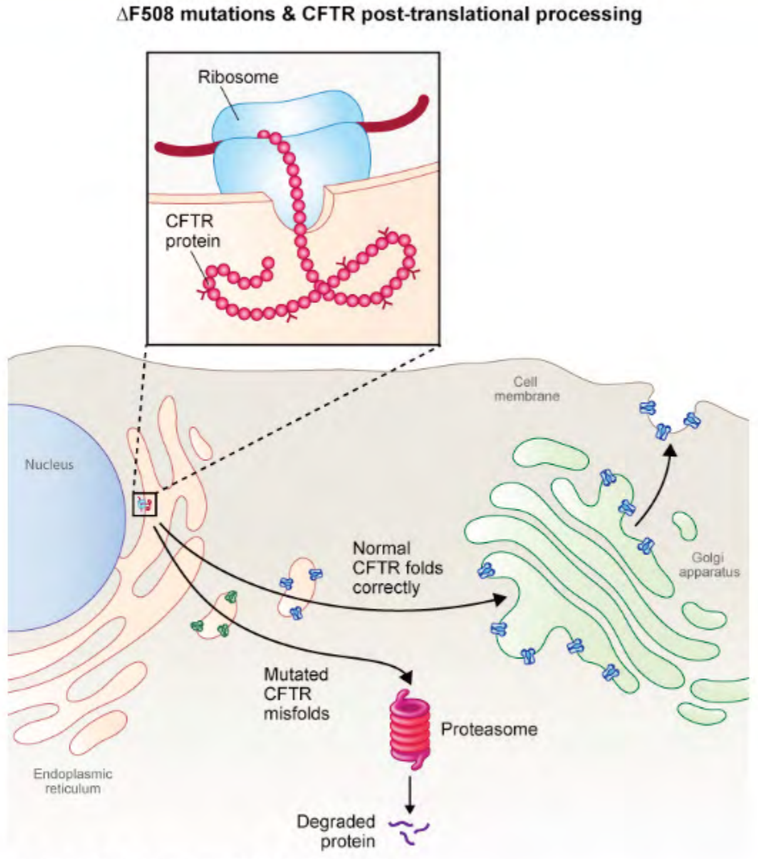

Zoom In | Zoom Out | Reset | New | Existing | My Notebook

https://t.me/USMLEWorldStep1

©UWorld

This patient most likely has cystic fibrosis (CF), an autosomal recessive disease characterized by recurrent **sinopulmonary infections**, pancreatic insufficiency, and malabsorption. It is caused by several different mutations that affect the CF transmembrane conductance regulator **(CFTR)** gene.

The **most common CFTR gene mutation** (found in approximately 70% of cases) is a 3-base pair deletion of phenylalanine at amino acid position 508 (**ΔF508**). This mutation causes **impaired post-translational processing** (eg, improper folding and glycosylation) of CFTR, which is detected by the endoplasmic reticulum. As a result, the abnormal protein is targeted for proteasomal degradation, preventing it from reaching the cell surface. Certain drugs (eg, lumacaftor) can partially correct this folding defect, leading to expression of functional CFTR.

(Choice B) Decreased production of functionally normal CFTR (eg, reduced messenger RNA or protein stability) often causes a milder form of the disease with normal sweat chloride levels that may not be diagnosed until adulthood.

(Choice C) Mutations affecting regulation of chloride ion conduction through a CFTR protein also result in CF. However, they result in decreased chloride conductivity and are less common than the ΔF508 mutation.

(Choice D) Mutations causing premature termination of the transmembrane protein (eg, nonsense, frameshift) also lead to a complete absence of membrane-bound CFTR as the truncated protein is typically recognized and degraded. These mutations are more common in the Ashkenazi Jewish population.

(Choice E) CFTR is an ATP-gated chloride channel activated by cAMP-mediated phosphorylation. Mutations that reduce the ability of the channel to open can also cause CF. The ΔF508 mutation, in addition to preventing proper trafficking to the cell surface, also reduces the regulatory effects of ATP and cAMP on channel opening.

Educational objective:
Cystic fibrosis (CF) is most commonly due to a 3-base pair deletion in the CF transmembrane conductance regulator (CFTR) gene at amino acid position 508 (ΔF508). This mutation impairs post-translational processing of CFTR, resulting in shunting of CFTR toward the proteasome, with complete absence of the protein on the cell surface. Elevated sweat chloride concentrations are found in most patients with CF.

References

https://t.me/USMLEWorldStep1

©UWorld

This patient most likely has cystic fibrosis (CF), an autosomal recessive disease characterized by recurrent
sinop
mutati

The **m**
pheny
proce
a resu
Certai

(Choi
often c
adulth

(Choi
Howev

(Choi
also le
degrac

(Choi
reduce
traffick

Educa
Cystic
regula
CFTR
surfac

References

Exhibit Display

Features of cystic fibrosis	

Pathogenesis	• Autosomal recessive mutation (**ΔF508**) impairs CFTR function
	• Decreased water content causes **thick, viscous mucus**:
	  ◦ Chronic airway obstruction
	  ◦ Gastrointestinal malabsorption

Clinical manifestations	• Chronic, productive cough • Recurrent **sinopulmonary infections** (eg, *Staphylococcus aureus*, *Pseudomonas aeruginosa*, & *Burkholderia cepacia* complex) • **Pancreatic insufficiency** • Male infertility (bilateral absence of vas deferens)
Diagnosis	• Elevated sweat chloride levels • Nasal potential difference measurements • Genetic testing for *CFTR* mutations
CFTR = cystic fibrosis transmembrane conductance regulator.	

New | Existing | My Notebook

https://t.me/USMLEWorldStep1

A 64-year-old man comes to the office due to worsening dyspnea on exertion for the past 3 months. The patient has had a nonproductive cough but no chest pain, fever, or chills. He was diagnosed with hypertension several years ago but takes no medications. Blood pressure is 160/96 mm Hg, pulse is 92/min, and respirations are 18/min. Physical examination shows bilateral inspiratory crackles as well as dullness to percussion and decreased breath sounds at the right lung base. Chest x-ray reveals a right-sided pleural effusion. Which of the following pleuropulmonary changes are most likely present in this patient?

	Vascular permeability	Vascular hydrostatic pressure	Vascular oncotic pressure	Lymphatic flow
○ A.	Increased	Normal	Normal	Decreased
○ B.	Increased	Increased	Decreased	Decreased
○ C.	Normal	Normal	Decreased	Increased
○ D.	Normal	Increased	Normal	Increased
○ E.	Decreased	Decreased	Increased	Increased

Submit

https://t.me/USMLEWorldStep1

A 64-year-old man comes to the office due to worsening dyspnea on exertion for the past 3 months. The patient has had a nonproductive cough but no chest pain, fever, or chills. He was diagnosed with hypertension several years ago but takes no medications. Blood pressure is 160/96 mm Hg, pulse is 92/min, and respirations are 18/min. Physical examination shows bilateral inspiratory crackles as well as dullness to percussion and decreased breath sounds at the right lung base. Chest x-ray reveals a right-sided pleural effusion. Which of the following pleuropulmonary changes are most likely present in this patient?

		Vascular permeability	Vascular hydrostatic pressure	Vascular oncotic pressure	Lymphatic flow	
✗	A.	Increased	Normal	Normal	Decreased	(6%)
	B.	Increased	Increased	Decreased	Decreased	(32%)
	C.	Normal	Normal	Decreased	Increased	(2%)
✓	D.	Normal	Increased	Normal	Increased	(56%)
	E.	Decreased	Decreased	Increased	Increased	(1%)

Incorrect
Correct answer
D

56%
Answered correctly

03 secs
Time Spent

2023
Version

Explanation

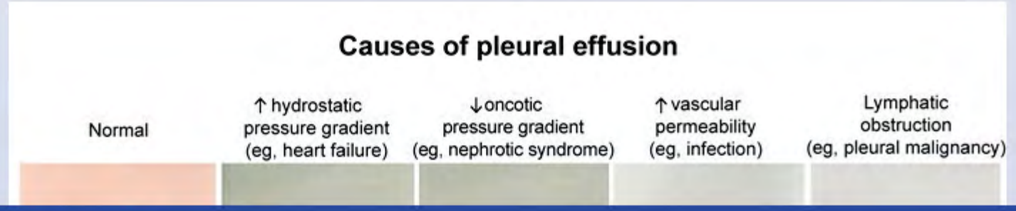

https://t.me/USMLEWorldStep1

A 64-year-old man comes to the office due to worsening dyspnea on exertion for the past 3 months. The patient has ha
years
18/mir
breath
pleuro

Exhibit Display

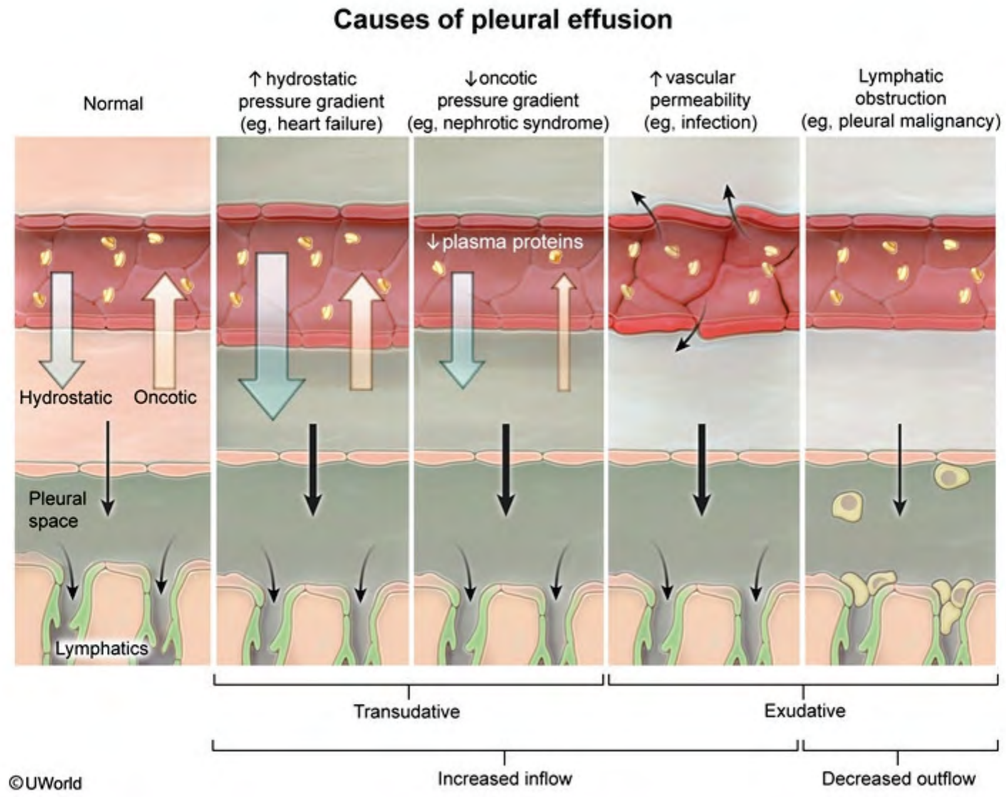

Zoom In | Zoom Out | Reset | New | Existing | My Notebook

Inco
Corre
D

Expl

(eg, heart failure) (eg, nephrotic syndrome) (eg, infection) (eg, pleural malignancy)

https://t.me/USMLEWorldStep1

In the normal state, the pleural space contains a small amount of fluid (eg, 5-10 mL) that undergoes constant turnover, with the rate of inflow equivalent to the rate of outflow. The **rate of inflow** is determined by vascular **hydrostatic pressure**, vascular **oncotic pressure**, and vascular **membrane permeability** (ie, the Starling equation), whereas the **rate of outflow** is determined by the drainage capacity of the **parietal pleural lymphatics**. A **pleural effusion** results from an increased rate of pleural fluid inflow, a decreased rate of pleural fluid outflow, or a combination of the two.

This patient with progressive dyspnea on exertion, nonproductive cough, bilateral crackles on lung auscultation, and a right-sided pleural effusion most likely has **decompensated heart failure** (chronic, poorly controlled hypertension is a common cause). Pleural effusion in decompensated heart failure is primarily driven by backward transmission of pressure from the failing left ventricle to the pulmonary circulation, resulting in **increased pulmonary capillary hydrostatic pressure** and an increased rate of fluid inflow to the pleural space. Vascular permeability remains normal, as does vascular oncotic pressure (which is mostly determined by serum albumin concentration). Outflow through the parietal pleural lymphatics increases in response to the increased fluid inflow, but it is unable to keep up, resulting in development of pleural effusion.

(Choice A) Lung malignancy can cause pleural effusion via both an increased rate of inflow due to an inflammatory increase in vascular membrane permeability and a decreased rate of outflow due to obstruction of parietal pleural lymphatics.

(Choice B) All 4 of these changes encourage the development of pleural effusion and multiple disturbances would be required for such changes to take place (eg, lung malignancy [increased vascular permeability and decreased lymphatic flow] in the setting of both hypoalbuminemia [decreased oncotic pressure] and heart failure [increased hydrostatic pressure]).

(Choice C) Hypoalbuminemia (eg, due to nephrotic syndrome or malnutrition) causes pleural effusion due to an increased rate of pleural fluid inflow from reduced vascular oncotic pressure. As with decompensated heart failure, lymphatic flow increases but is unable to keep up with the increased inflow.

(Choice E) All 4 of these changes would discourage the development of pleural effusion.

Educational objective:
Pleural effusion results from an increased rate of fluid inflow from the nearby vasculature or a decreased rate of

https://t.me/USMLEWorldStep1

equation), whereas the **rate of outflow** is determined by the drainage capacity of the **parietal pleural lymphatics**. A **pleural effusion** results from an increased rate of pleural fluid inflow, a decreased rate of pleural fluid outflow, or a combination of the two.

This patient with progressive dyspnea on exertion, nonproductive cough, bilateral crackles on lung auscultation, and a right-sided pleural effusion most likely has **decompensated heart failure** (chronic, poorly controlled hypertension is a common cause). Pleural effusion in decompensated heart failure is primarily driven by backward transmission of pressure from the failing left ventricle to the pulmonary circulation, resulting in **increased pulmonary capillary hydrostatic pressure** and an increased rate of fluid inflow to the pleural space. Vascular permeability remains normal, as does vascular oncotic pressure (which is mostly determined by serum albumin concentration). Outflow through the parietal pleural lymphatics increases in response to the increased fluid inflow, but it is unable to keep up, resulting in development of pleural effusion.

(Choice A) Lung malignancy can cause pleural effusion via both an increased rate of inflow due to an inflammatory increase in vascular membrane permeability and a decreased rate of outflow due to obstruction of parietal pleural lymphatics.

(Choice B) All 4 of these changes encourage the development of pleural effusion and multiple disturbances would be required for such changes to take place (eg, lung malignancy [increased vascular permeability and decreased lymphatic flow] in the setting of both hypoalbuminemia [decreased oncotic pressure] and heart failure [increased hydrostatic pressure]).

(Choice C) Hypoalbuminemia (eg, due to nephrotic syndrome or malnutrition) causes pleural effusion due to an increased rate of pleural fluid inflow from reduced vascular oncotic pressure. As with decompensated heart failure, lymphatic flow increases but is unable to keep up with the increased inflow.

(Choice E) All 4 of these changes would discourage the development of pleural effusion.

Educational objective:
Pleural effusion results from an increased rate of fluid inflow from the nearby vasculature or a decreased rate of fluid outflow through the parietal pleural lymphatics. Decompensated heart failure causes pleural effusion primarily due to increased fluid inflow from increased pulmonary capillary hydrostatic pressure; lymphatic outflow increases but is unable to keep up with the increased inflow.

https://t.me/USMLEWorldStep1

Exhibit Display

Starling equation & capillary fluid exchange

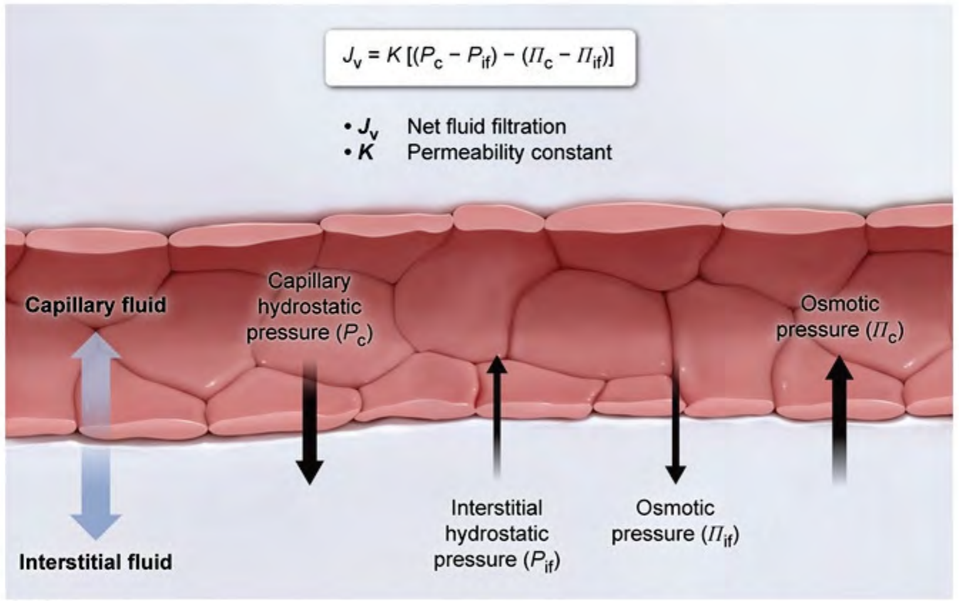

©UWorld

Zoom In | Zoom Out | Reset | New | Existing | My Notebook

In the
turnov
hydro
equati
lymph
fluid o

This p
and a
hypert
transm
pulmo
perme
concer
but it i

(Choi
inflam
parieta

(Choi
be req
lymphatic flow] in the setting of both hypoalbuminemia [decreased oncotic pressure] and heart failure [increased hydrostatic pressure]).

https://t.me/USMLEWorldStep1

An 18-year-old woman comes to the clinic due to intermittent dry cough, wheezing, and shortness of breath. She recently began practicing twice a day for her college track team and has been experiencing these symptoms with running. Her symptoms have been limiting her ability to complete practice but usually resolve after several minutes of rest. Medical history includes childhood asthma that has not required treatment for the past 5 years. The patient is prescribed a medication that reduces bronchoconstriction by inhibiting the interaction of inflammatory mediators with cell surface receptors. Which of the following drugs was most likely used in this patient?

- A. Albuterol
- B. Dextromethorphan
- C. Fluticasone
- D. Ipratropium
- E. Montelukast
- F. Zileuton

Submit

https://t.me/USMLEWorldStep1

An 18-year-old woman comes to the clinic due to intermittent dry cough, wheezing, and shortness of breath. She recently began practicing twice a day for her college track team and has been experiencing these symptoms with running. Her symptoms have been limiting her ability to complete practice but usually resolve after several minutes of rest. Medical history includes childhood asthma that has not required treatment for the past 5 years. The patient is prescribed a medication that reduces bronchoconstriction by inhibiting the interaction of inflammatory mediators with cell surface receptors. Which of the following drugs was most likely used in this patient?

- ✗ A. Albuterol (3%)
- B. Dextromethorphan (0%)
- C. Fluticasone (9%)
- D. Ipratropium (2%)
- ✓ E. Montelukast (75%)
- F. Zileuton (9%)

Incorrect
Correct answer
E

75%
Answered correctly

03 secs
Time Spent

2023
Version

Explanation

Arachidonic acid metabolic pathways in asthma

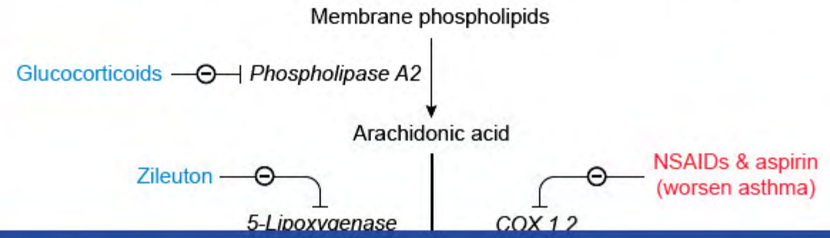

https://t.me/USMLEWorldStep1

An 18-year-old woman comes to the clinic due to intermittent dry cough, wheezing, and shortness of breath. She recent
runnin
of rest
patien
media

Exhibit Display

Arachidonic acid metabolic pathways in asthma

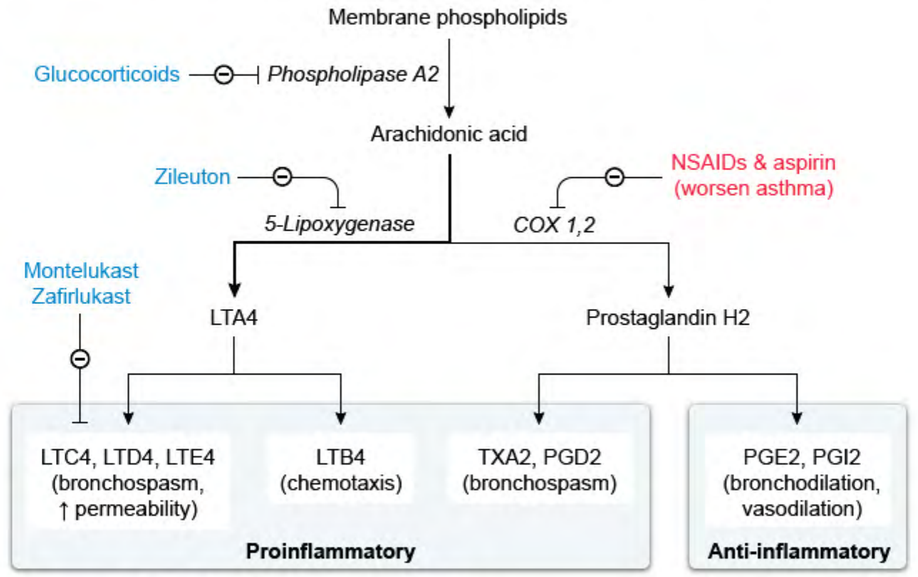

LT = leukotriene; **NSAIDs** = nonsteroidal anti-inflammatory drugs;
PG = prostaglandin; **TX** = thromboxane.

©UWorld

Zoom In | Zoom Out | Reset | New | Existing | My Notebook

https://t.me/USMLEWorldStep1

Exercise-induced bronchoconstriction is common in patients with underlying **asthma**. Asthma occurs due to a complex inflammatory response to the environment that involves Th2 lymphocytes, eosinophils, and mast cells. Eosinophils and mast cells synthesize and release **leukotrienes**, which are inflammatory mediators that induce bronchial smooth muscle contraction **(bronchoconstriction)**, bronchial **mucus secretion**, and bronchial **edema**. The leukotrienes mainly responsible for these responses are the cysteinyl-containing leukotrienes such as leukotriene C4, D4, and E4.

Leukotriene receptor antagonists (eg, montelukast, zafirlukast) effectively treat asthma by binding to leukotriene receptors on bronchial smooth muscle cells and blocking the effects of cysteinyl-containing leukotrienes.

(Choice A) Albuterol causes short-acting bronchodilation via selective stimulation of beta 2 receptors. It is typically used as an as-needed rescue inhaler in patients with asthma.

(Choice B) Dextromethorphan suppresses cough via stimulation of sigma opioid receptors in the CNS (it does not stimulate mu or delta opioid receptors and therefore does not cause other typical opioid effects). It is commonly used in cold medication but is not effective for treatment of asthma.

(Choice C) Inhaled corticosteroids (eg, fluticasone, budesonide) help treat asthma by inhibiting nuclear transcription of inflammatory genes leading to widespread anti-inflammatory effects. One effect is reduced activity of the enzyme phospholipase A2 to decrease the production of leukotrienes. Corticosteroids do not block cell surface receptors.

(Choice D) Ipratropium stimulates bronchodilation via blockade of the binding of acetylcholine (a neurotransmitter) to muscarinic receptors. Inhaled ipratropium is sometimes used in the treatment of asthma but is more commonly used for chronic obstructive pulmonary disease.

(Choice F) Zileuton is a 5-lipoxygenase enzyme inhibitor that reduces the production of leukotrienes (it does not block leukotriene cell surface receptors). It can be used for treatment of asthma, but it is often avoided due to concerns about toxicity.

Educational objective:
The cysteinyl-containing leukotrienes (ie, leukotriene C4, D4, and E4) are inflammatory mediators that stimulate bronchoconstriction, bronchial mucus secretion, and bronchial edema to contribute to the pathogenesis of asthma.

https://t.me/USMLEWorldStep1

bronchial smooth muscle contraction **(bronchoconstriction)**, bronchial **mucus secretion**, and bronchial **edema**. The leukotrienes mainly responsible for these responses are the cysteinyl-containing leukotrienes such as leukotriene C4, D4, and E4.

Leukotriene receptor antagonists (eg, montelukast, zafirlukast) effectively treat asthma by binding to leukotriene receptors on bronchial smooth muscle cells and blocking the effects of cysteinyl-containing leukotrienes.

(Choice A) Albuterol causes short-acting bronchodilation via selective stimulation of beta 2 receptors. It is typically used as an as-needed rescue inhaler in patients with asthma.

(Choice B) Dextromethorphan suppresses cough via stimulation of sigma opioid receptors in the CNS (it does not stimulate mu or delta opioid receptors and therefore does not cause other typical opioid effects). It is commonly used in cold medication but is not effective for treatment of asthma.

(Choice C) Inhaled corticosteroids (eg, fluticasone, budesonide) help treat asthma by inhibiting nuclear transcription of inflammatory genes leading to widespread anti-inflammatory effects. One effect is reduced activity of the enzyme phospholipase A2 to decrease the production of leukotrienes. Corticosteroids do not block cell surface receptors.

(Choice D) Ipratropium stimulates bronchodilation via blockade of the binding of acetylcholine (a neurotransmitter) to muscarinic receptors. Inhaled ipratropium is sometimes used in the treatment of asthma but is more commonly used for chronic obstructive pulmonary disease.

(Choice F) Zileuton is a 5-lipoxygenase enzyme inhibitor that reduces the production of leukotrienes (it does not block leukotriene cell surface receptors). It can be used for treatment of asthma, but it is often avoided due to concerns about toxicity.

Educational objective:
The cysteinyl-containing leukotrienes (ie, leukotriene C4, D4, and E4) are inflammatory mediators that stimulate bronchoconstriction, bronchial mucus secretion, and bronchial edema to contribute to the pathogenesis of asthma. Leukotriene receptor antagonists (eg, montelukast, zafirlukast) treat asthma by binding to leukotriene receptors on bronchial smooth muscle cells and blocking these effects.

https://t.me/USMLEWorldStep1

A 65-year-old woman with chronic obstructive pulmonary disease comes to the office for a follow-up appointment. The patient reports increasing shortness of breath that is not relieved by her inhalers. Her other medical conditions include osteoarthritis. She is a former smoker with a 45-pack-year history. Blood pressure is 120/70 mm Hg, pulse is 75/min, and respirations are 22/min. Oxygen saturation on room air is 91% at rest. On physical examination, jugular venous pressure is elevated. There is increased intensity of the pulmonic component of S2. Breath sounds are decreased bilaterally with scattered wheezes but no crackles. There is 2+ lower extremity edema. Which of the following hemodynamic parameters is most likely to be increased in this patient?

- A. Left ventricular preload
- B. Left ventricular stroke volume
- C. Pulmonary arterial compliance
- D. Pulmonary capillary wedge pressure
- E. Right ventricular afterload

Submit

https://t.me/USMLEWorldStep1

A 65-year-old woman with chronic obstructive pulmonary disease comes to the office for a follow-up appointment. The patient reports increasing shortness of breath that is not relieved by her inhalers. Her other medical conditions include osteoarthritis. She is a former smoker with a 45-pack-year history. Blood pressure is 120/70 mm Hg, pulse is 75/min, and respirations are 22/min. Oxygen saturation on room air is 91% at rest. On physical examination, jugular venous pressure is elevated. There is increased intensity of the pulmonic component of S2. Breath sounds are decreased bilaterally with scattered wheezes but no crackles. There is 2+ lower extremity edema. Which of the following hemodynamic parameters is most likely to be increased in this patient?

- A. Left ventricular preload (2%)
- ✗ B. Left ventricular stroke volume (0%)
- C. Pulmonary arterial compliance (3%)
- D. Pulmonary capillary wedge pressure (15%)
- ✓ E. Right ventricular afterload (76%)

Incorrect
Correct answer
E

76%
Answered correctly

04 secs
Time Spent

2023
Version

Explanation

This patient with chronic obstructive pulmonary disease (COPD) has evidence of **pulmonary hypertension** complicated by **right-sided heart failure**. Hypoxic vasoconstriction is a physiologic mechanism unique to lung tissue that helps minimize ventilation-perfusion mismatch and increase overall gas exchange efficiency. However, sustained pulmonary vasoconstriction in advanced **hypoxic lung disease** (eg, COPD, interstitial lung disease, obesity hypoventilation syndrome) can promote pulmonary hypertension (ie, **increased right ventricular afterload**).

Pulmonary hypertension typically presents with dyspnea and/or fatigue, and some patients may develop exertional

https://t.me/USMLEWorldStep1

Explanation

This patient with chronic obstructive pulmonary disease (COPD) has evidence of **pulmonary hypertension** complicated by **right-sided heart failure**. Hypoxic vasoconstriction is a physiologic mechanism unique to lung tissue that helps minimize ventilation-perfusion mismatch and increase overall gas exchange efficiency. However, sustained pulmonary vasoconstriction in advanced **hypoxic lung disease** (eg, COPD, interstitial lung disease, obesity hypoventilation syndrome) can promote pulmonary hypertension (ie, **increased right ventricular afterload**).

Pulmonary hypertension typically presents with dyspnea and/or fatigue, and some patients may develop exertional angina or syncope due to reduced cardiac output. Physical examination can reveal **left parasternal lift** (due to right ventricular hypertrophy) and a **loud pulmonic component of S2** due to high pulmonary artery pressure. Over time, the right ventricle may be unable to pump against the increased afterload and right-sided heart failure can develop, evidenced by **jugular venous distension** and prominent **lower extremity edema**.

(Choices A, B, and D) The hemodynamic parameters in pulmonary hypertension secondary to hypoxic lung disease are similar to those in pulmonary arterial hypertension. Left ventricular preload and stroke volume (cardiac output) are decreased due to impaired pumping of blood through the lungs to the left atrium. Pulmonary capillary wedge pressure, an estimate of left atrial pressure and a representation of left-sided preload, is also decreased.

(Choice C) Pulmonary arterial compliance decreases with pulmonary hypertension due to vascular remodeling and stiffening of the pulmonary arterial wall.

Educational objective:
Advanced hypoxic lung disease (eg, chronic obstructive pulmonary disease, interstitial lung disease, obesity hypoventilation syndrome) is a common cause of pulmonary hypertension (ie, increased right ventricular afterload). The increase in pulmonary arterial pressure mainly results from chronic and diffuse hypoxic vasoconstriction, with a lesser degree of vascular remodeling than in (primary) pulmonary arterial hypertension.

Pathophysiology	Pulmonary & Critical Care	Pulmonary Arterial Hypertension
Subject	System	Topic

Copyright © UWorld. All rights reserved.

https://t.me/USMLEWorldStep1

Explanation

This p
compli
tissue
sustai
obesit
afterl

Pulmo
angina
right v
Over t
can de

(Choi
diseas
output
wedge

(Choi
and st

Educa
Advan
hypov
afterlo
vasoc

Pathoph
Subject

Exhibit Display

Classification of pulmonary hypertension	
Pulmonary arterial hypertension (group 1)	• Primary change in pulmonary arteries ◦ Hereditary (eg, *BMPR2* mutation) ◦ Connective tissue disease (eg, RA, SS) ◦ HIV infection • Treatment targeted at endothelial dysfunction
Pulmonary hypertension (groups 2-5)	• Secondary to another disease process ◦ Left-sided heart failure (group 2) ◦ Chronic lung disease/hypoxia (group 3) ◦ Chronic pulmonary thromboembolism (group 4) ◦ Other (eg, sarcoidosis) (group 5) • Treatment aimed at underlying disease
RA = rheumatoid arthritis; **SS** = systemic sclerosis.	

New | Existing | My Notebook

Copyright © UWorld. All rights reserved.

https://t.me/USMLEWorldStep1

Explanation

This p
compli
tissue
sustai
obesit
afterl

Pulmo
angina
right v
Over t
can de

(Choi
diseas
output
wedge

(Choi
and st

Educa
Advan
hypov
afterlo
vasoc

Pathoph
Subject

Exhibit Display

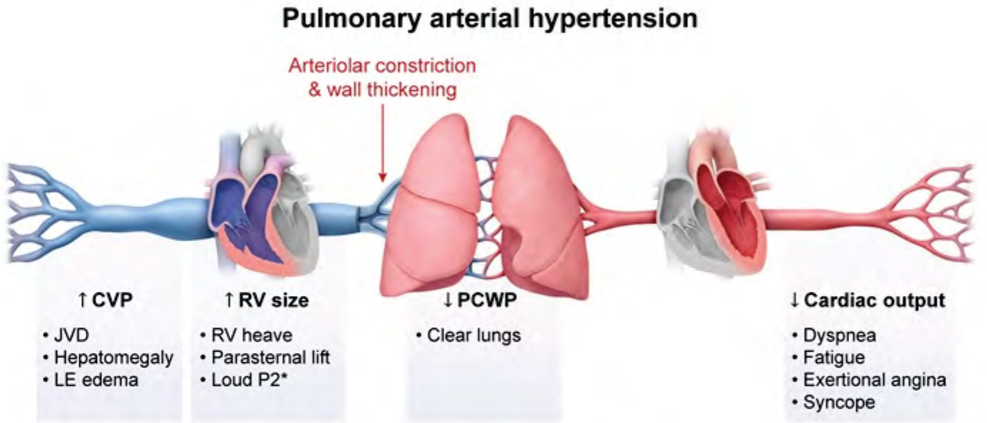

Zoom In | Zoom Out | Reset | New | Existing | My Notebook

Copyright © UWorld. All rights reserved.

https://t.me/USMLEWorldStep1

A 34-year-old woman comes to the office for tuberculosis evaluation. The patient was advised to have tuberculosis testing after her father, who is visiting her family from Haiti, was found to have active pulmonary tuberculosis. She has no history of tuberculosis or any other chronic medical conditions and takes no medications. Tuberculin skin testing is performed and results 48 hours later are negative. Eight weeks later, the patient returns for follow-up and says she feels healthy and has had no fever, cough, shortness of breath, or weight loss. Physical examination shows no abnormalities. Repeat tuberculin skin testing reveals significant skin induration around the injection site at 48 hours. Chest radiograph shows no parenchymal opacities, pleural effusion, or enlarged lymph nodes. Which of the following effector cells are primarily responsible for immunologic control of this patient's infection?

- A. B lymphocytes and macrophages
- B. CD4 T lymphocytes and macrophages
- C. CD4 T lymphocytes and neutrophils
- D. CD8 T lymphocytes and B lymphocytes
- E. CD8 T lymphocytes and NK cells

Submit

https://t.me/USMLEWorldStep1

A 34-year-old woman comes to the office for tuberculosis evaluation. The patient was advised to have tuberculosis testing after her father, who is visiting her family from Haiti, was found to have active pulmonary tuberculosis. She has no history of tuberculosis or any other chronic medical conditions and takes no medications. Tuberculin skin testing is performed and results 48 hours later are negative. Eight weeks later, the patient returns for follow-up and says she feels healthy and has had no fever, cough, shortness of breath, or weight loss. Physical examination shows no abnormalities. Repeat tuberculin skin testing reveals significant skin induration around the injection site at 48 hours. Chest radiograph shows no parenchymal opacities, pleural effusion, or enlarged lymph nodes. Which of the following effector cells are primarily responsible for immunologic control of this patient's infection?

- A. B lymphocytes and macrophages (4%)
- ✓ B. CD4 T lymphocytes and macrophages (72%)
- C. CD4 T lymphocytes and neutrophils (5%)
- D. CD8 T lymphocytes and B lymphocytes (7%)
- E. CD8 T lymphocytes and NK cells (10%)

Correct

72% Answered correctly

03 secs Time Spent

2023 Version

Explanation

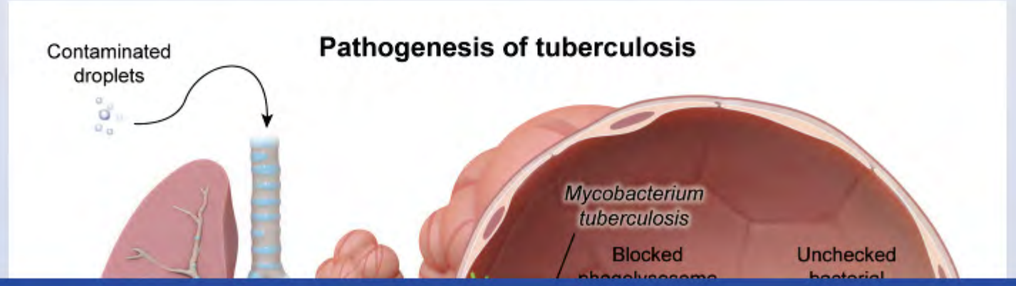

https://t.me/USMLEWorldStep1

Correct

72%
Answered correctly

03 secs
Time Spent

2023
Version

Exhibit Display

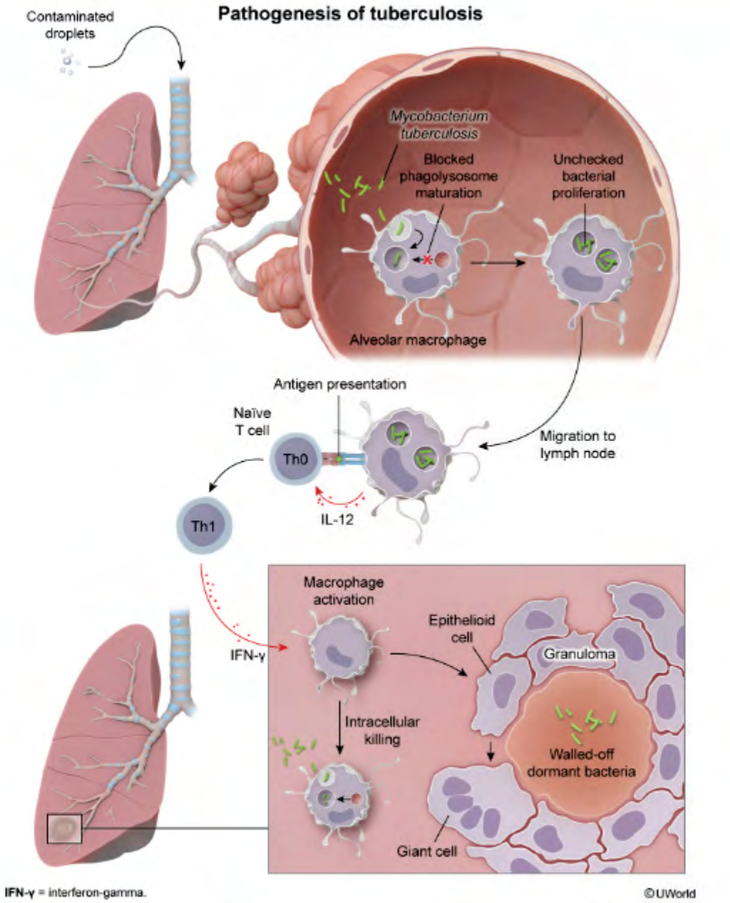

Zoom In | Zoom Out | Reset | New | Existing | My Notebook

https://t.me/USMLEWorldStep1

Mycobacterium tuberculosis is transmitted by aerosolized droplets from a patient with active pulmonary tuberculosis. Initially, the pathogen replicates in an unchecked fashion due to virulence factors (eg, cord factor) that allow the bacteria to escape destruction within the phagolysosomes of alveolar macrophages. After a few weeks, antigen-presenting cells in the draining lymphatic system display mycobacterial antigens on major histocompatibility complex class II molecules and release **interleukin-12**, which differentiates **naïve CD4 cells** into T-helper subtype-1 (**Th1**) cells.

Th1 cells migrate to the sites of infection and secrete **interferon-gamma**, resulting in the **activation of macrophages**. Activated macrophages are able to form fully mature phagolysosomes to destroy intracellular mycobacteria. They also differentiate into cells (eg, epithelioid, Langhans giant cells) that surround extracellular mycobacteria and form granulomas. Granulomas have an acidic, hypoxic central environment that limits the proliferation of mycobacteria but does not usually eliminate the infection.

Because the cell-mediated response to *M tuberculosis* takes several weeks to form, recently exposed patients frequently have a negative initial tuberculin skin test (as in this patient). Although most patients with primary tuberculosis have no symptoms and no chest x-ray findings, after several months, a Ranke complex (calcified lower lobe nodule and ipsilateral hilar lymph node) can often be seen on x-ray.

(Choice A) Facultative, intracellular organisms such as *M tuberculosis* are protected from antibodies and complement when within cells. As a result, elimination of these pathogens does not primarily rely on the humoral immune system (eg, B lymphocytes).

(Choice C) Neutrophils are a crucial immune component for control of most extracellular bacterial infections (eg, *Streptococcus pneumoniae*). However, macrophages are the more important effector cells for control of *M tuberculosis* and many other intracellular bacterial infections.

(Choice D) Intracellular organisms that replicate in the cytosol, such as viruses or certain intracellular bacteria (eg, *Listeria*), are processed by the proteasome and displayed on major histocompatibility complex (MHC) class I molecules. This leads to the activation of CD8 T lymphocytes. *M tuberculosis* primarily replicates within the phagosome (not the cytosol), leading to display of mycobacterial antigens on MHC class II molecules and the subsequent activation of CD4, rather than CD8, cells.

https://t.me/USMLEWorldStep1

Th1 cells migrate to the sites of infection and secrete **interferon-gamma**, resulting in the **activation of macrophages**. Activated macrophages are able to form fully mature phagolysosomes to destroy intracellular mycobacteria. They also differentiate into cells (eg, epithelioid, Langhans giant cells) that surround extracellular mycobacteria and form granulomas. Granulomas have an acidic, hypoxic central environment that limits the proliferation of mycobacteria but does not usually eliminate the infection.

Because the cell-mediated response to *M tuberculosis* takes several weeks to form, recently exposed patients frequently have a negative initial tuberculin skin test (as in this patient). Although most patients with primary tuberculosis have no symptoms and no chest x-ray findings, after several months, a Ranke complex (calcified lower lobe nodule and ipsilateral hilar lymph node) can often be seen on x-ray.

(Choice A) Facultative, intracellular organisms such as *M tuberculosis* are protected from antibodies and complement when within cells. As a result, elimination of these pathogens does not primarily rely on the humoral immune system (eg, B lymphocytes).

(Choice C) Neutrophils are a crucial immune component for control of most extracellular bacterial infections (eg, *Streptococcus pneumoniae*). However, macrophages are the more important effector cells for control of *M tuberculosis* and many other intracellular bacterial infections.

(Choice D) Intracellular organisms that replicate in the cytosol, such as viruses or certain intracellular bacteria (eg, *Listeria*), are processed by the proteasome and displayed on major histocompatibility complex (MHC) class I molecules. This leads to the activation of CD8 T lymphocytes. *M tuberculosis* primarily replicates within the phagosome (not the cytosol), leading to display of mycobacterial antigens on MHC class II molecules and the subsequent activation of CD4, rather than CD8, cells.

(Choice E) Natural killer cells are cytotoxic lymphocytes that can recognize damaged or infected cells without requiring MHC activation. They are important for clearing viral infections and for tumor immunosurveillance, but are not the primary effector cell in tuberculosis infection.

Educational objective:
Mycobacterium tuberculosis primarily replicates within the phagosome, leading to display of mycobacterial antigens on major histocompatibility complex class II molecules. This results in the activation of CD4 cells and subsequent control of the infection with macrophages.

https://t.me/USMLEWorldStep1

Th1 cells migrate to the sites of infection and secrete **interferon-gamma**, resulting in the **activation of macrophages**. Activated macrophages are able to form fully mature phagolysosomes to destroy intracellular mycob
mycob
prolife

Becau
freque
tuberc
lower

(Choi
compl
immun

(Choi
Strept
tuberc

(Choi
Listeri
molec
phago
subse

(Choi
requiri
are no

Educa
Mycob
antige
subsequent control of the infection with macrophages.

Exhibit Display

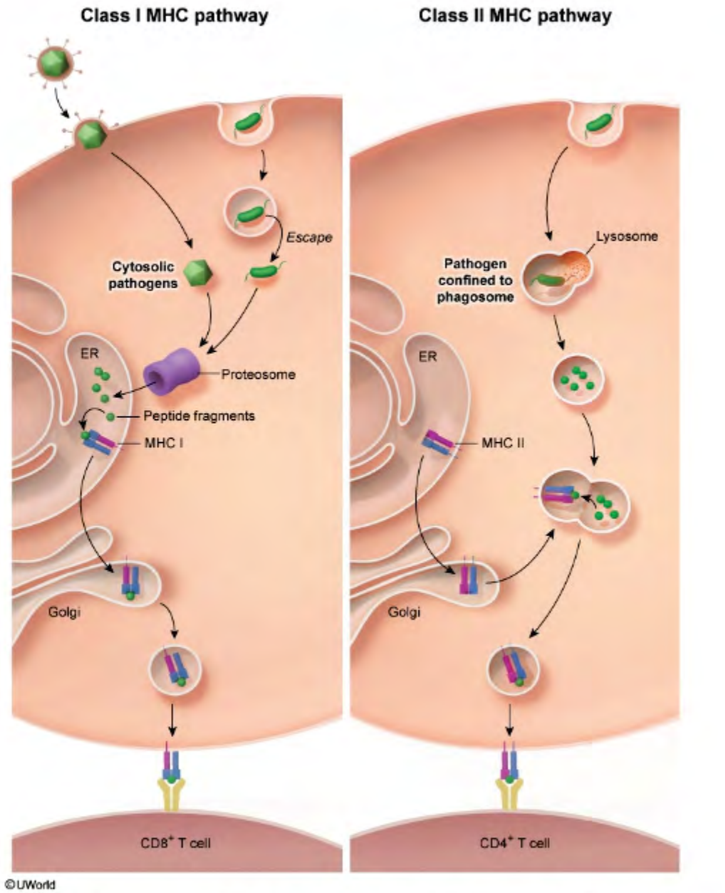

Zoom In | Zoom Out | Reset | New | Existing | My Notebook

https://t.me/USMLEWorldStep1

A 56-year-old woman with a history of hypertension is brought to the emergency department due to 3 days of dysuria and back pain. Temperature is 39.2 C (102.6 F), blood pressure is 70/40 mm Hg, pulse is 130/min, and respirations are 28/min. The patient is confused and has suprapubic and costovertebral angle tenderness. The skin is diffusely warm but there are no rashes or edema. Complete blood count demonstrates leukocytosis with increased neutrophils but is otherwise normal. Coagulation studies are normal. Urinalysis is positive for leukocyte esterase and nitrites, and microscopy shows numerous bacteria. Several hours later, the patient becomes increasingly hypoxic and requires mechanical ventilation. This patient's respiratory symptoms are most likely due to which of the following pathologic conditions?

- A. Fluid accumulation in the alveolar spaces
- B. Necrotizing inflammation with pulmonary hemorrhage
- C. Scattered noncaseating granulomas
- D. Thick mucus plugs in the bronchi and bronchioles
- E. Wedge-shaped areas of hemorrhagic necrosis

Submit

https://t.me/USMLEWorldStep1

A 56-year-old woman with a history of hypertension is brought to the emergency department due to 3 days of dysuria and back pain. Temperature is 39.2 C (102.6 F), blood pressure is 70/40 mm Hg, pulse is 130/min, and respirations are 28/min. The patient is confused and has suprapubic and costovertebral angle tenderness. The skin is diffusely warm but there are no rashes or edema. Complete blood count demonstrates leukocytosis with increased neutrophils but is otherwise normal. Coagulation studies are normal. Urinalysis is positive for leukocyte esterase and nitrites, and microscopy shows numerous bacteria. Several hours later, the patient becomes increasingly hypoxic and requires mechanical ventilation. This patient's respiratory symptoms are most likely due to which of the following pathologic conditions?

- ✓ A. Fluid accumulation in the alveolar spaces (77%)
- ✗ B. Necrotizing inflammation with pulmonary hemorrhage (11%)
- C. Scattered noncaseating granulomas (1%)
- D. Thick mucus plugs in the bronchi and bronchioles (1%)
- E. Wedge-shaped areas of hemorrhagic necrosis (8%)

Incorrect
Correct answer
A

77%
Answered correctly

04 secs
Time Spent

2023
Version

Explanation

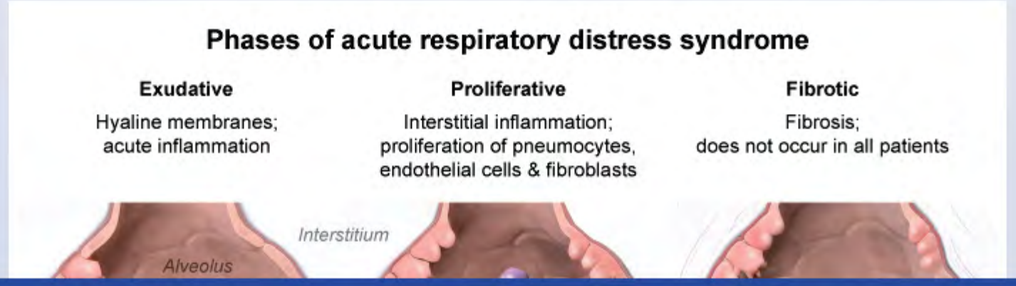

https://t.me/USMLEWorldStep1

Incorrect
Correct answer
A

77%
04 secs
2023

Exhibit Display

Expl

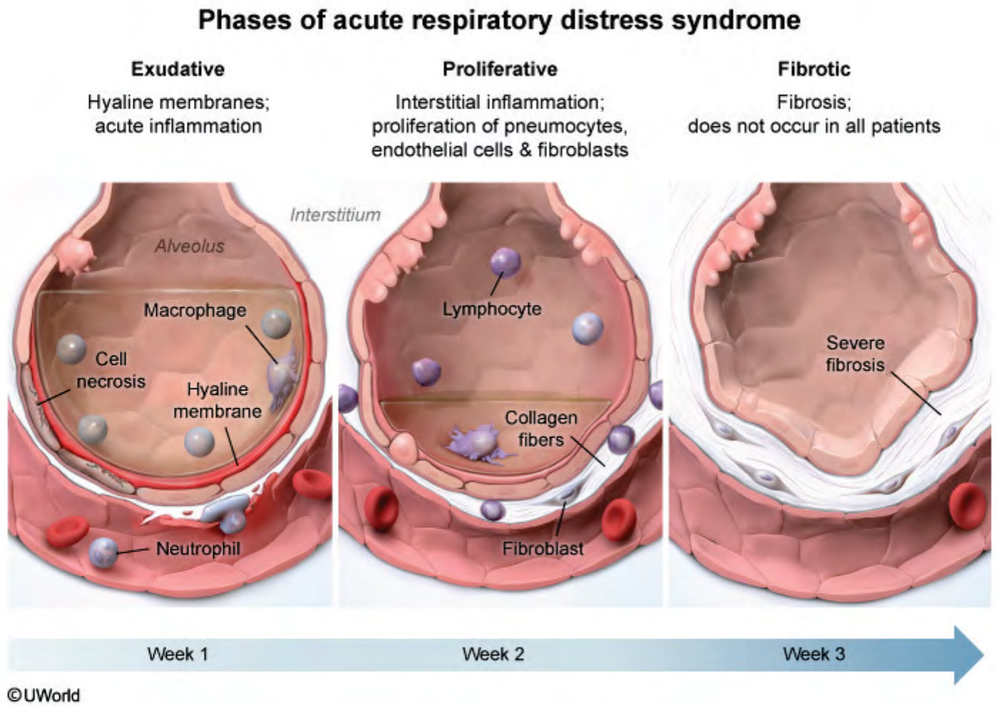

Zoom In Zoom Out Reset New | Existing My Notebook

This p
Her ra
charac
direct
burns, pancreatitis) that result in pulmonary epithelial and/or endothelial injury.

The 2 phases of ARDS follow the disease's progression:

https://t.me/USMLEWorldStep1

This patient has a urinary tract infection complicated by fever and hemodynamic instability consistent with **sepsis**. Her rapid-onset respiratory failure is suggestive of **acute respiratory distress syndrome** (ARDS). ARDS is characterized by bilateral pulmonary infiltrates and hypoxemia in the absence of heart failure. It can occur due to direct pulmonary trauma (eg, pulmonary contusions, inhaled irritants) or indirect nonpulmonary insults (eg, sepsis, burns, pancreatitis) that result in pulmonary epithelial and/or endothelial injury.

The 3 phases of ARDS follow the disease's progression:

- **Exudative phase:** Inflammatory cytokines (eg, tumor necrosis factor, IL-1, IL-6) activate the pulmonary endothelium and recruit neutrophils to the lung tissue. Resultant endothelial damage leads to increased capillary permeability and **leakage of protein-rich fluid into the alveolar space**. Organization of the edema and cellular debris leads to the formation of hyaline membranes.
- **Proliferative phase:** One to two weeks later, endothelial cells, pneumocytes, and fibroblasts proliferate in attempts to repair the damaged lung; collagen is deposited and scarring may occur. Edema is reabsorbed.
- **Fibrotic phase:** In a minority of patients, excessive collagen deposition leads to irreversible pulmonary fibrosis and pulmonary hypertension.

(Choice B) Necrotizing inflammation and pulmonary hemorrhage are commonly associated with granulomatosis with polyangiitis, which involves both the lungs and the kidneys. However, this condition normally presents subacutely with cough, hemoptysis, and nephritic syndrome; this patient's acute respiratory decline in the setting of sepsis is more consistent with ARDS.

(Choice C) Noncaseating granulomas are found in sarcoidosis, which typically presents more chronically with cough, skin findings, or uveitis. Hemodynamic instability and acute respiratory failure would be unexpected.

(Choice D) Mucus plugging typically occurs in patients with underlying lung disease (eg, cystic fibrosis, chronic obstructive pulmonary disease). Mucus plugs can cause hypoxemia but would not be expected to cause hypotension and fevers, and acute respiratory deterioration in the setting of sepsis is more likely due to ARDS.

https://t.me/USMLEWorldStep1

- **Exudative phase:** Inflammatory cytokines (eg, tumor necrosis factor, IL-1, IL-6) activate the pulmonary endothelium and recruit neutrophils to the lung tissue. Resultant endothelial damage leads to increased capillary permeability and **leakage of protein-rich fluid into the alveolar space**. Organization of the edema and cellular debris leads to the formation of hyaline membranes.
- **Proliferative phase:** One to two weeks later, endothelial cells, pneumocytes, and fibroblasts proliferate in attempts to repair the damaged lung; collagen is deposited and scarring may occur. Edema is reabsorbed.
- **Fibrotic phase:** In a minority of patients, excessive collagen deposition leads to irreversible pulmonary fibrosis and pulmonary hypertension.

(Choice B) Necrotizing inflammation and pulmonary hemorrhage are commonly associated with granulomatosis with polyangiitis, which involves both the lungs and the kidneys. However, this condition normally presents subacutely with cough, hemoptysis, and nephritic syndrome; this patient's acute respiratory decline in the setting of sepsis is more consistent with ARDS.

(Choice C) Noncaseating granulomas are found in sarcoidosis, which typically presents more chronically with cough, skin findings, or uveitis. Hemodynamic instability and acute respiratory failure would be unexpected.

(Choice D) Mucus plugging typically occurs in patients with underlying lung disease (eg, cystic fibrosis, chronic obstructive pulmonary disease). Mucus plugs can cause hypoxemia but would not be expected to cause hypotension and fevers, and acute respiratory deterioration in the setting of sepsis is more likely due to ARDS.

(Choice E) Wedge-shaped areas of hemorrhagic necrosis can be seen with pulmonary embolism, which can cause acute respiratory failure, hypotension, and tachycardia. However, patients often have chest pain, and in general, decompensation occurs suddenly (not progressively over a course of hours). In addition, urinary symptoms, confusion, and high fevers are unexpected in this condition.

Educational objective:
Acute respiratory distress syndrome is caused by injury of the pulmonary epithelium and/or endothelium, and occurs most often due to sepsis or pneumonia. Cytokines recruit neutrophils to the lung tissue, which cause capillary damage and leakage of protein-rich fluid into the alveoli. Later, cellular proliferation and collagen deposition occurs, and in some patients, this leads to irreversible pulmonary fibrosis.

https://t.me/USMLEWorldStep1

Exhibit Display

Acute respiratory distress syndrome

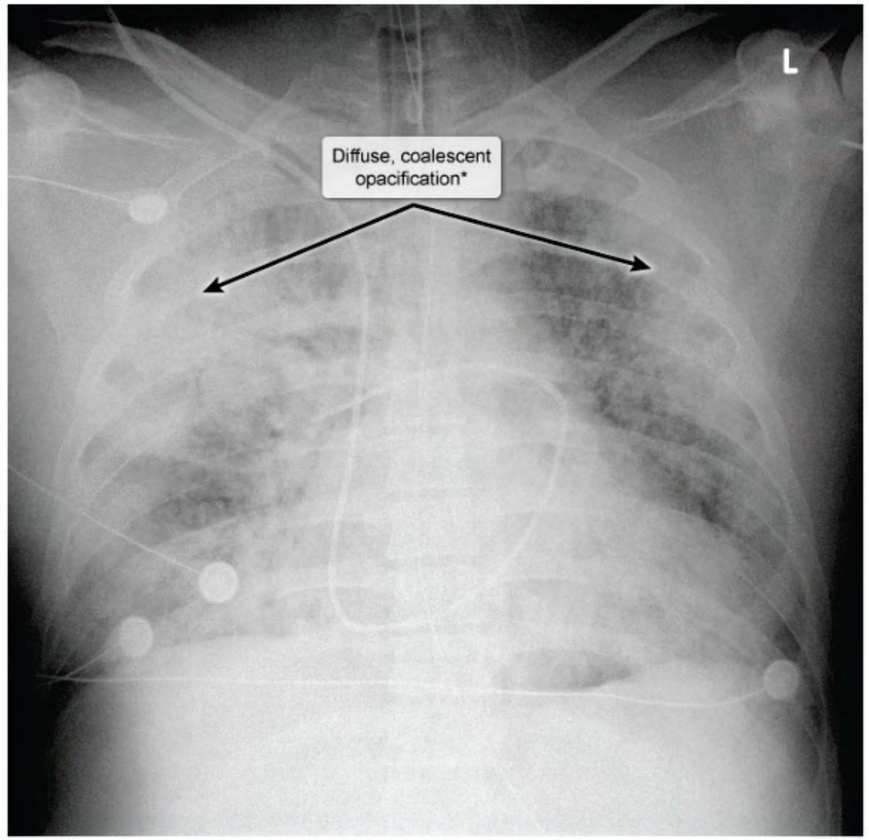

*Exudate due to diffuse alveolar endothelial damage (eg, sepsis, pneumonia, trauma)

©UWorld

Zoom In | Zoom Out | Reset | New | Existing | My Notebook

This p
Her ra
charac
direct
burns,

The 3

- **E**
- **P**
- **F**

(Choi
with p
subac
sepsis

(Choi
cough, skin findings, or uveitis. Hemodynamic instability and acute respiratory failure would be unexpected.

https://t.me/USMLEWorldStep1

Exhibit Display

Diffuse alveolar damage

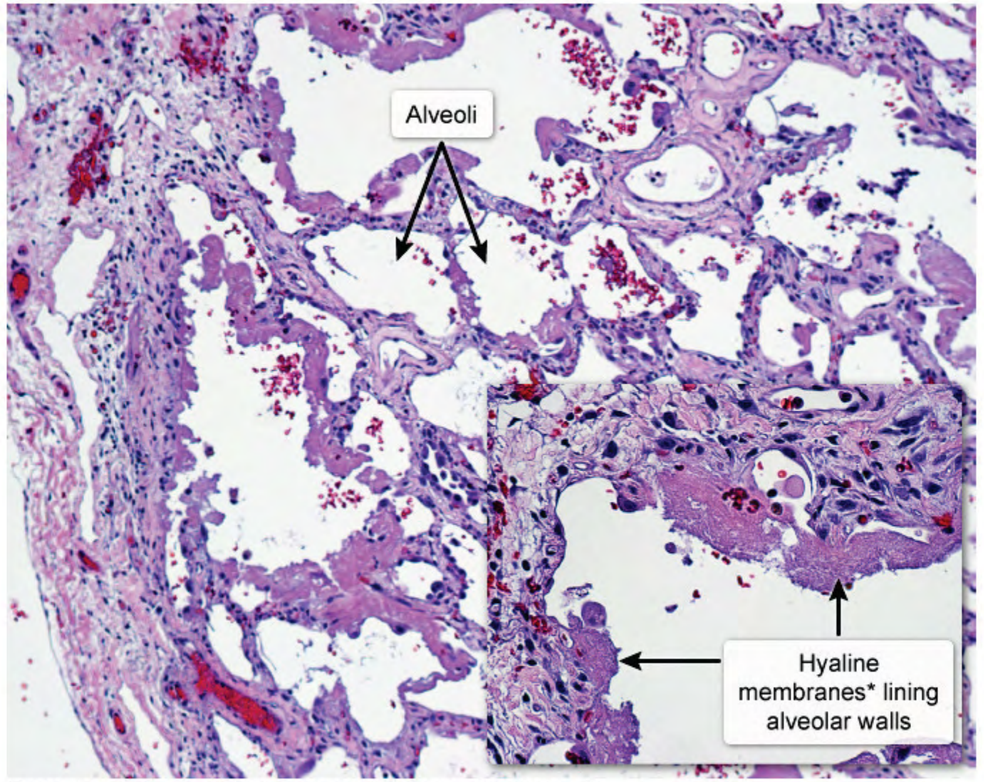

*Dense pink material composed of plasma proteins and necrotic epithelial cells

©UWorld

Zoom In | Zoom Out | Reset | New | Existing | My Notebook

This p
Her ra
charac
direct
burns,

The 3

- **E**
- **P**
- **F**

(Choi
with p
subac
sepsis

(Choi
cough, skin findings, or uveitis. Hemodynamic instability and acute respiratory failure would be unexpected.

https://t.me/USMLEWorldStep1

A 32-year-old woman comes to the emergency department due to 4 weeks of worsening cough, shortness of breath, and low-grade fevers. She also has had an unintentional weight loss of 4.5 kg (10 lb) over the past 3 months. Temperature is 37.1 C (98.8 F), blood pressure is 120/70 mm Hg, pulse is 102/min, and respirations are 22/min. Pulse oximetry shows 86% on ambient air. Lung auscultation reveals bilateral crackles. There are no heart murmurs, and jugular venous pressure is normal. Chest x-ray reveals diffuse interstitial infiltrates. The patient undergoes bronchoscopy; methenamine silver staining of the bronchoalveolar lavage specimen is shown in the image.

Which of the following is the most appropriate pharmacotherapy for this patient's current condition?

- A. Caspofungin
- B. Ceftriaxone and azithromycin
- C. Doxycycline
- D. Ganciclovir
- E. Trimethoprim-sulfamethoxazole
- F. Vancomycin

Submit

https://t.me/USMLEWorldStep1

A 32-year-old woman comes to the emergency department due to 4 weeks of worsening cough, shortness of breath
month
22/mir
heart r
patien
the im

Exhibit Display

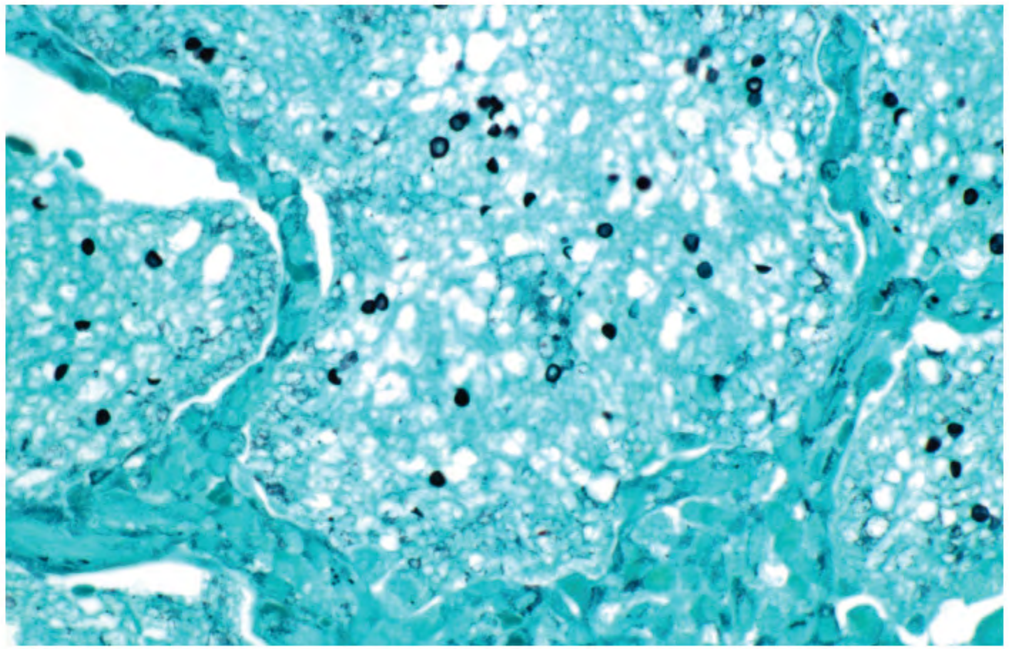

Zoom In | Zoom Out | Reset | New | Existing | My Notebook

Which

C. Doxycycline

https://t.me/USMLEWorldStep1

the image.

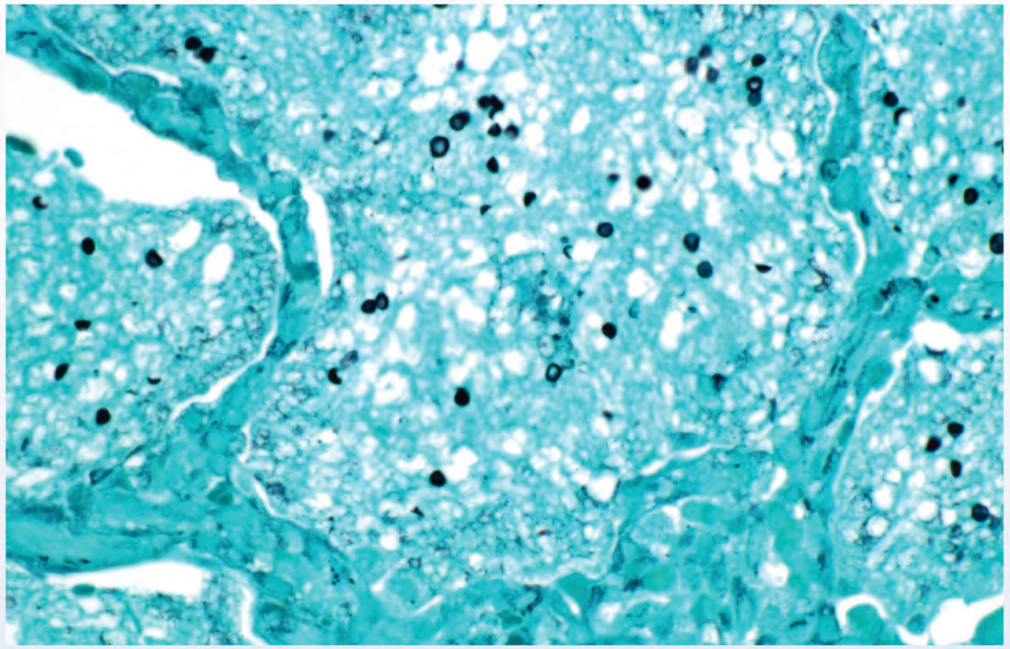

Which of the following is the most appropriate pharmacotherapy for this patient's current condition?

- A. Caspofungin
- B. Ceftriaxone and azithromycin
- C. Doxycycline
- D. Ganciclovir
- E. Trimethoprim-sulfamethoxazole
- F. Vancomycin

Submit

https://t.me/USMLEWorldStep1

the image.

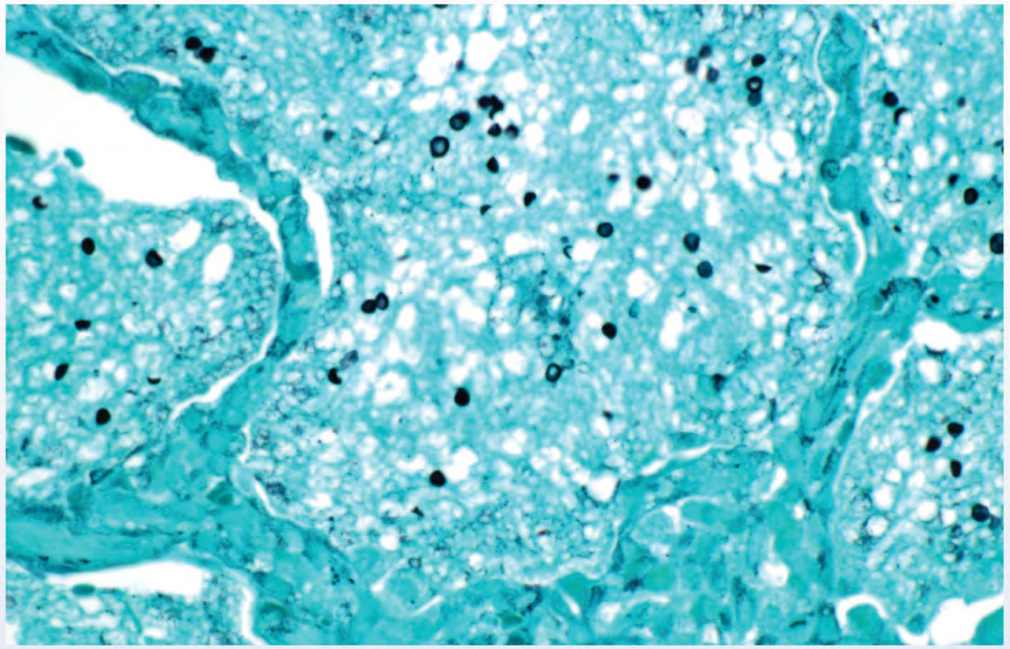

Which of the following is the most appropriate pharmacotherapy for this patient's current condition?

- A. Caspofungin (16%)
- B. Ceftriaxone and azithromycin (10%)
- C. Doxycycline (5%)
- ✗ D. Ganciclovir (1%)
- ✓ E. Trimethoprim-sulfamethoxazole (65%)
- F. Vancomycin (0%)

Incorrect
Correct answer
E

65%
Answered correctly

11 secs
Time Spent

2023
Version

https://t.me/USMLEWorldStep1

Incorrect
Correct answer
E

65%
Answered correctly

11 secs
Time Spent

2023
Version

Exhibit Display

Pneumocystis jirovecii

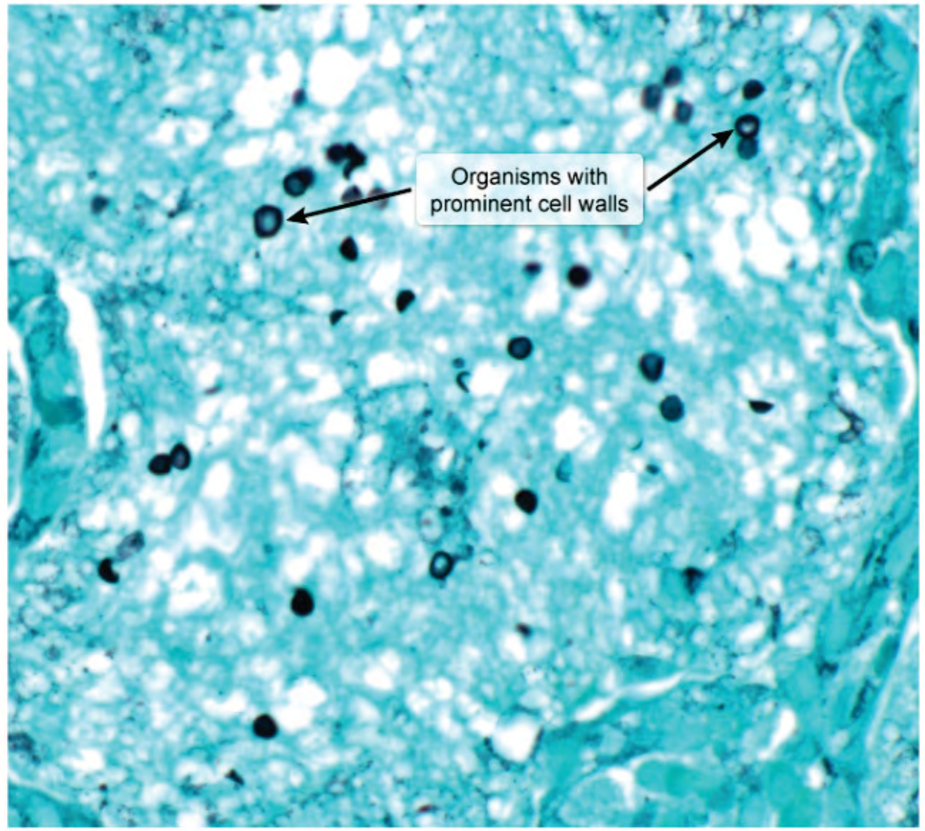

©UWorld

Zoom In | Zoom Out | Reset | New | Existing | My Notebook



©UWorld

https://t.me/USMLEWorldStep1

©UWorld

Pneumocystis* pneumonia** is an AIDS-defining illness that is often seen in patients who were previously unaware of HIV infection. The underlying pathogen is an atypical fungus called ***Pneumocystis jirovecii. Healthy patients rapidly clear the inhaled organisms, but those with impaired cell-mediated immunity are at risk for a noninvasive infection that fills the alveoli and leads to slowly worsening pulmonary symptoms (eg, dry cough, shortness of breath), hypoxia, and a diffuse, bilateral interstitial infiltrate. Fever and weight loss are also usually present.

P jirovecii cannot be cultured; therefore, definitive diagnosis requires identification of the organism in respiratory secretions. **Methenamine silver stain** is frequently used to identify the cell wall of the pathogen, which often appears as a crescent, a crushed ping-pong ball, or a circular ring around a clear center. First-line treatment with **trimethoprim-sulfamethoxazole** is usually curative.

(Choice A) Invasive pulmonary aspergillosis may be treated with caspofungin and is most common in patients with severe immunosuppression (eg, AIDS, neutropenia). It usually presents with fever, cough, chest pain, dyspnea, and hemoptysis. Silver stain can be used to diagnose aspergillosis, but numerous hyphae (not cystic organisms) will be seen.

(Choice B) Ceftriaxone and azithromycin are often used to treat community-acquired bacterial pneumonia, which usually presents acutely with productive cough, fever, and shortness of breath. Chest x-ray typically reveals a lobar infiltrate rather than a diffuse interstitial infiltrate.

(Choice C) Doxycycline can be used to treat *Mycoplasma* pneumonia, which often presents with several weeks of incessant cough and chest x-ray showing interstitial infiltrates. However, significant hypoxia is uncommon, and *M pneumoniae* is not identified on silver stain.

(Choice D) Patients with advanced AIDS are at risk for cytomegalovirus (CMV) pneumonia, which is treated with ganciclovir and can cause fever, cough, dyspnea, and diffuse pulmonary infiltrates. The presence of "owl's eye" inclusion bodies on histopathology strongly supports a CMV infection.

(Choice F) Vancomycin inhibits cell wall synthesis and is primarily used for severe or drug-resistant, Gram-positive bacterial infections such as methicillin-resistant *Staphylococcus aureus*.

Educational objective:

https://t.me/USMLEWorldStep1

P jirovecii cannot be cultured; therefore, definitive diagnosis requires identification of the organism in respiratory secretions. **Methenamine silver stain** is frequently used to identify the cell wall of the pathogen, which often appears as a crescent, a crushed ping-pong ball, or a circular ring around a clear center. First-line treatment with **trimethoprim-sulfamethoxazole** is usually curative.

(Choice A) Invasive pulmonary aspergillosis may be treated with caspofungin and is most common in patients with severe immunosuppression (eg, AIDS, neutropenia). It usually presents with fever, cough, chest pain, dyspnea, and hemoptysis. Silver stain can be used to diagnose aspergillosis, but numerous hyphae (not cystic organisms) will be seen.

(Choice B) Ceftriaxone and azithromycin are often used to treat community-acquired bacterial pneumonia, which usually presents acutely with productive cough, fever, and shortness of breath. Chest x-ray typically reveals a lobar infiltrate rather than a diffuse interstitial infiltrate.

(Choice C) Doxycycline can be used to treat *Mycoplasma* pneumonia, which often presents with several weeks of incessant cough and chest x-ray showing interstitial infiltrates. However, significant hypoxia is uncommon, and *M pneumoniae* is not identified on silver stain.

(Choice D) Patients with advanced AIDS are at risk for cytomegalovirus (CMV) pneumonia, which is treated with ganciclovir and can cause fever, cough, dyspnea, and diffuse pulmonary infiltrates. The presence of "owl's eye" inclusion bodies on histopathology strongly supports a CMV infection.

(Choice F) Vancomycin inhibits cell wall synthesis and is primarily used for severe or drug-resistant, Gram-positive bacterial infections such as methicillin-resistant *Staphylococcus aureus*.

Educational objective:
Pneumocystis pneumonia is common in patients with advanced HIV and usually presents with slowly worsening cough and dyspnea, hypoxia, and bilateral interstitial infiltrates. Diagnosis requires visualizing the organism in respiratory secretions using special stains (eg, methenamine silver stain). First-line treatment is trimethoprim-sulfamethoxazole.

Microbiology Pulmonary & Critical Care Pneumocystis pneumonia

https://t.me/USMLEWorldStep1

Exhibit Display

***Pneumocystis jiroveci* pneumonia**

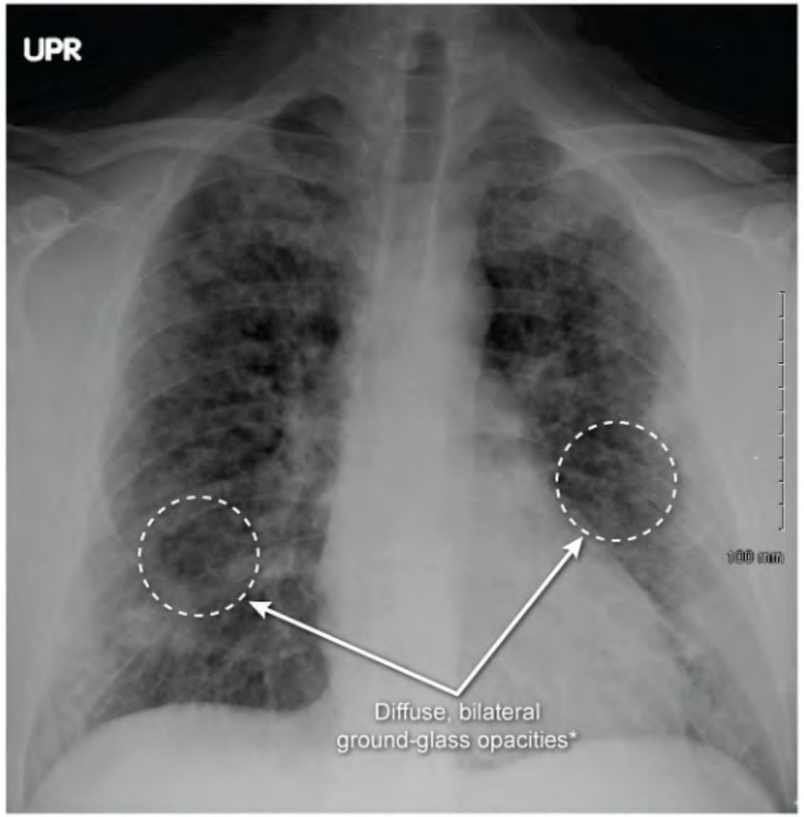

*Widespread inflammatory response causing diffuse alveolar damage with interstitial infiltrates

©UWorld

Zoom In | Zoom Out | Reset | New | Existing | My Notebook

Pneu
of HIV
rapidly
infecti
breath

P jirov
secret
appea
trimet

(Choi
with se
dyspn
organi

(Choi
usuall
lobar i

(Choi
incessant cough and chest x-ray showing interstitial infiltrates. However, significant hypoxia is uncommon, and *M pneumoniae* is not identified on silver stain.

https://t.me/USMLEWorldStep1

Exhibit Display

Aspergillus

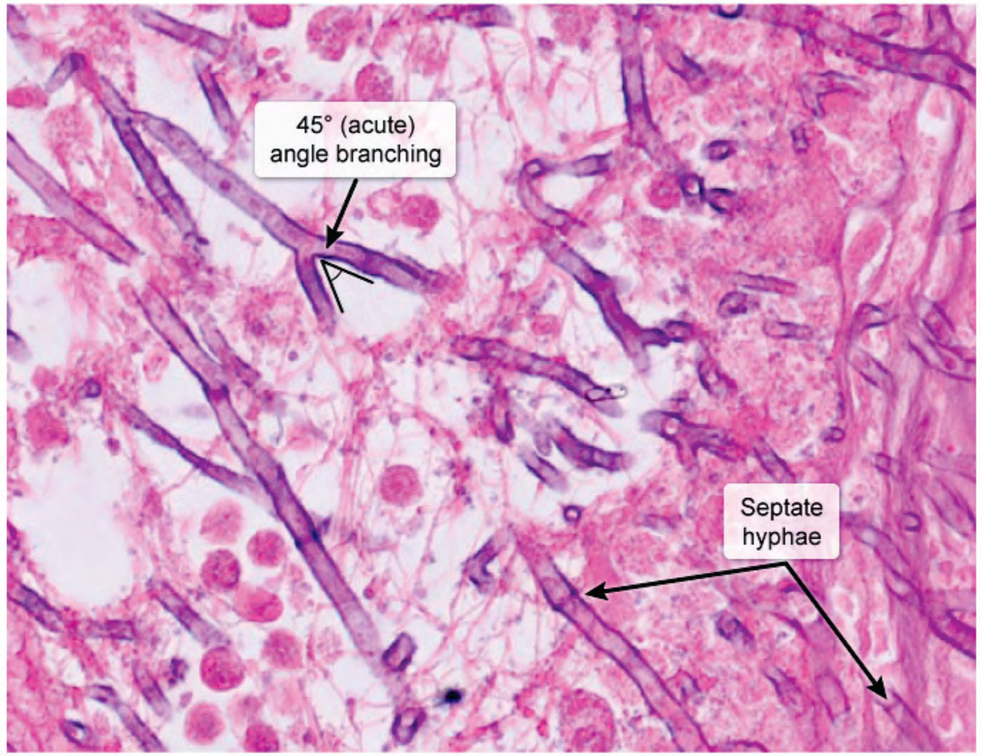

©UWorld

Zoom In | Zoom Out | Reset | New | Existing | My Notebook

Pneu
of HIV
rapidly
infecti
breath

P jirov
secret
appea
trimet

(Choi
with se
dyspn
organi

(Choi
usuall
lobar i

(Choi
incess
pneum

(Choi
ganciclovir and can cause fever, cough, dyspnea, and diffuse pulmonary infiltrates. The presence of "owl's eye" inclusion bodies on histopathology strongly supports a CMV infection.

https://t.me/USMLEWorldStep1

Exhibit Display

Right lower lobe pneumonia

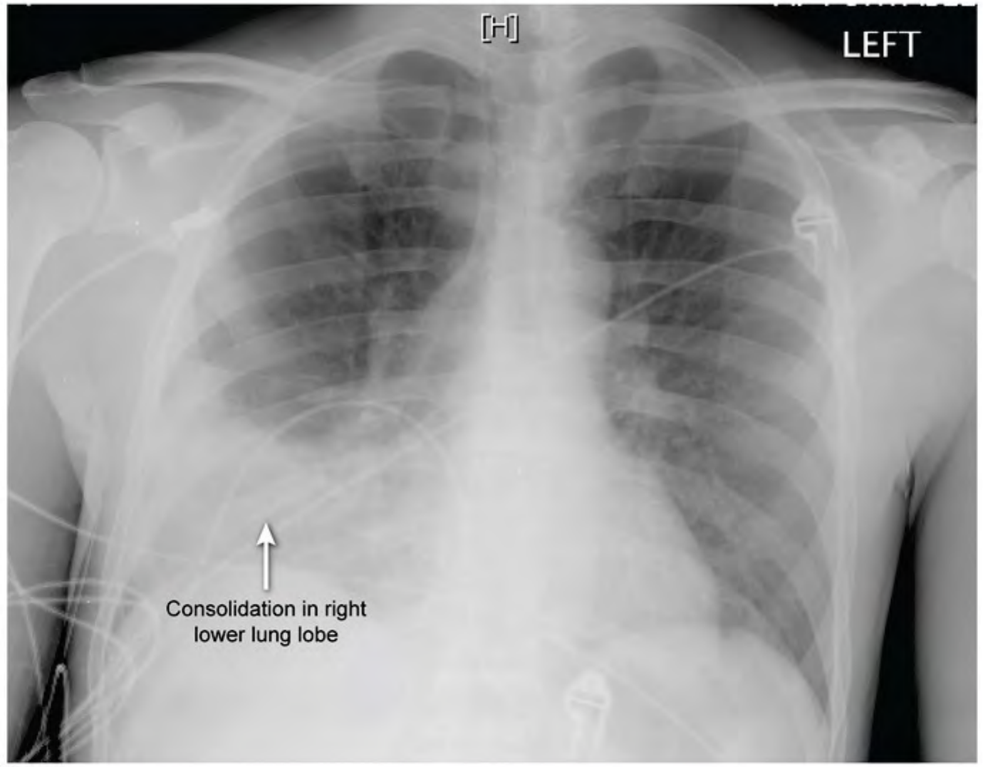

©UWorld

Zoom In | Zoom Out | Reset | New | Existing | My Notebook

Pneu
of HIV
rapidly
infecti
breath

P jirov
secret
appea
trimet

(Choi
with se
dyspn
organi

(Choi
usuall
lobar i

(Choi
incess
pneum

(Choi
ganciclovir and can cause fever, cough, dyspnea, and diffuse pulmonary infiltrates. The presence of "owl's eye" inclusion bodies on histopathology strongly supports a CMV infection.

https://t.me/USMLEWorldStep1

©UWorld

Exhibit Display

Cytomegalovirus

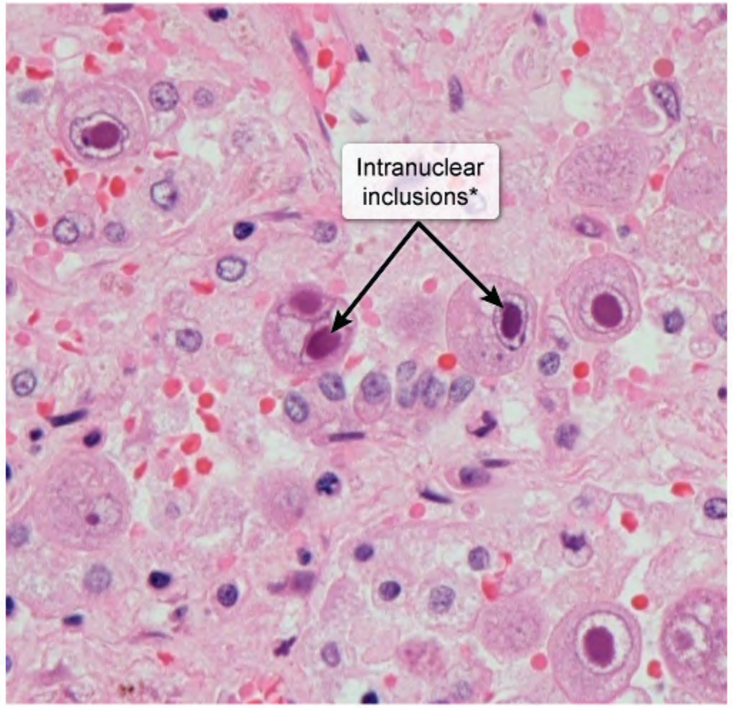

*"Owl's eye" appearance

©UWorld

Zoom In | Zoom Out | Reset | New | Existing | My Notebook

Pneu
of HIV
rapidly
infecti
breath

P jirov
secret
appea
trimet

(Choi
with se
dyspn
organi

(Choi
usuall
lobar i

(Choi
incess
pneum

(Choi
gancic
inclusi

(Choi
positive bacterial infections such as methicillin-resistant *Staphylococcus aureus*.

Educational objective:

https://t.me/USMLEWorldStep1

A 55-year-old man comes to the emergency department due to several weeks of productive cough with occasional hemoptysis, weight loss, and low-grade fever. He has lost 7 kg (15.4 lb) over the past 3 months. Medical history is significant for type 2 diabetes mellitus and chronic kidney disease, and the patient works as a prison guard. Temperature is 37.8 C (100 F), blood pressure is 110/70 mm Hg, pulse is 78/min, and respirations are 18/min. Chest x-ray reveals a right apical lung infiltrate and cavitary lesion. He is placed in respiratory isolation, and appropriate empiric therapy is started. The cavitary lesions seen in this patient most likely formed through which of the following pathogenic mechanisms?

- A. Aggregation of activated leukocytes
- B. Bacterial toxin–induced cell necrosis
- C. Exudation and alveolar hepatization
- D. Intraalveolar bacterial overgrowth
- E. Obliterative lower airway inflammation

Submit

https://t.me/USMLEWorldStep1

A 55-year-old man comes to the emergency department due to several weeks of productive cough with occasional hemoptysis, weight loss, and low-grade fever. He has lost 7 kg (15.4 lb) over the past 3 months. Medical history is significant for type 2 diabetes mellitus and chronic kidney disease, and the patient works as a prison guard. Temperature is 37.8 C (100 F), blood pressure is 110/70 mm Hg, pulse is 78/min, and respirations are 18/min. Chest x-ray reveals a right apical lung infiltrate and cavitary lesion. He is placed in respiratory isolation, and appropriate empiric therapy is started. The cavitary lesions seen in this patient most likely formed through which of the following pathogenic mechanisms?

- ✓ A. Aggregation of activated leukocytes (70%)
- B. Bacterial toxin–induced cell necrosis (12%)
- C. Exudation and alveolar hepatization (3%)
- D. Intraalveolar bacterial overgrowth (10%)
- E. Obliterative lower airway inflammation (2%)

Correct

70%
Answered correctly

03 secs
Time Spent

2023
Version

Explanation

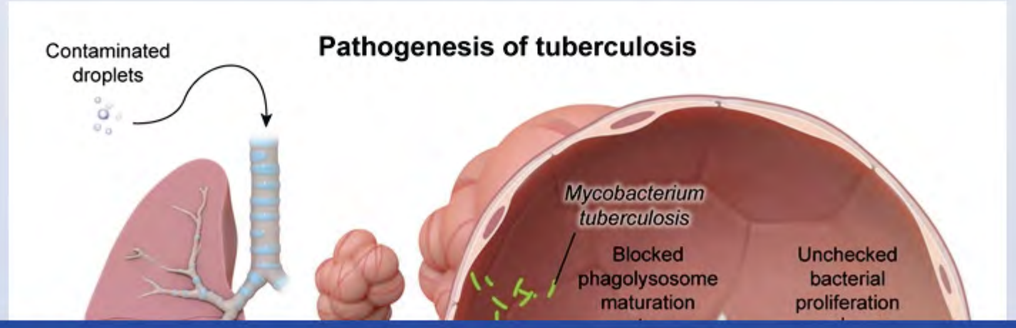

https://t.me/USMLEWorldStep1

A 55-year-old man comes to the emergency department due to several weeks of productive cough with occasional hemop
signifi
Tempe
Chest
approp
the fol

Cor

Expl

Exhibit Display

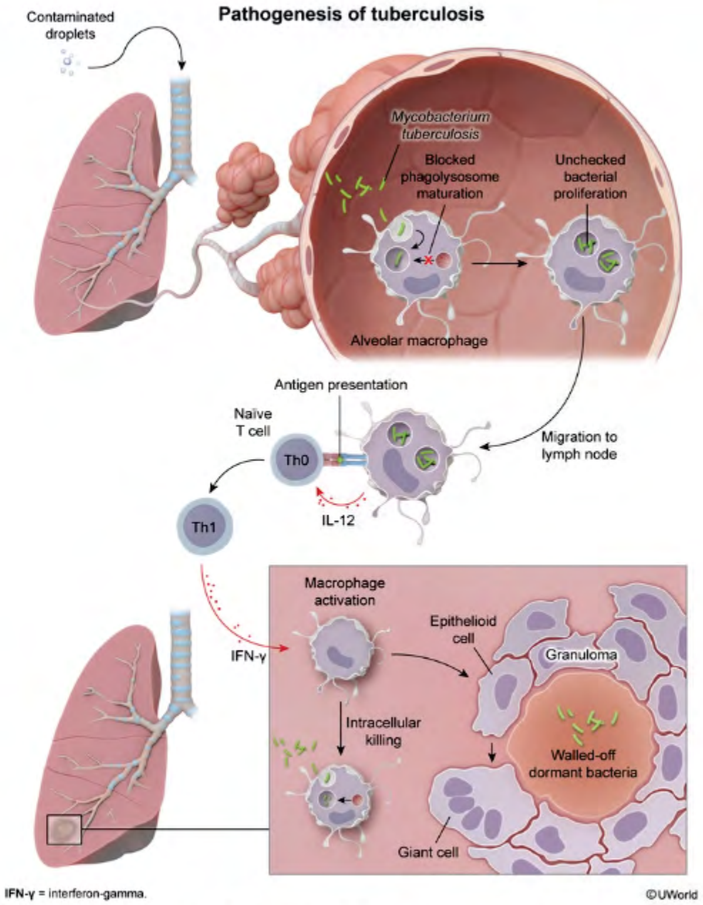

Zoom In | Zoom Out | Reset | New | Existing | My Notebook

https://t.me/USMLEWorldStep1

This patient has a productive cough, hemoptysis, fever, and weight loss with an apical cavitary lung lesion, findings characteristic of **active tuberculosis**. *Mycobacterium tuberculosis* is an acid-fast bacillus that replicates within the alveoli. The bacteria are phagocytized by alveolar macrophages, which are initially unable to destroy the pathogen due to microbial adaptations that inhibit the formation of an effective phagolysosome. However, in the weeks after the initial infection, antigen presenting cells (eg, macrophages, dendritic cells) display mycobacterial antigens to naïve $CD4^+$ T lymphocytes in regional lymph nodes, which subsequently differentiate into **T helper type 1** (Th1) cells that **secrete interferon-gamma**.

Interferon-gamma **activates macrophages**, leading to the formation of fully acidified phagolysosomes capable of destroying intracellular mycobacteria. Activated macrophages also aggregate and differentiate into epithelioid histiocytes and multinucleated giant cells, which surround extracellular mycobacteria within granulomas. The release of **proteases, nitric oxide, and reactive oxygen species** by these cells helps contain the infection. However, these compounds also cause extensive **collateral tissue damage** and can result in the formation of cavitary lung lesions.

(Choice B) *M tuberculosis* produces trehalose dimycolate (cord factor), which inhibits phagolysosome maturation and may contribute to the formation of caseating granulomas. However, cord factor does not directly cause the tissue necrosis associated with cavitary lesions; the release of digestive enzymes by activated macrophages lining the granuloma drives caseation and cavitation.

(Choice C) Lobar pneumonia is characterized by the initial accumulation of an abundant proteinaceous exudate within the alveoli, followed by hepatization of the affected lobe. Lobar pneumonia is typically caused by pathogens such as *Streptococcus pneumoniae*. However, lobar pneumonia presents acutely, not slowly, over several weeks.

(Choice D) Intraalveolar mycobacteria do not directly cause cavitary lesions. Activated macrophages that surround the extracellular mycobacteria are primarily responsible for the tissue damage that leads to cavitation.

(Choice E) Obliterative lower airway inflammation can occur as a feature of cryptogenic organizing pneumonia. In this condition, inflammation causes the proliferation of granulation tissue, which obstructs small bronchioles and leads to alveolar consolidation. However, apical cavitary lesions and hemoptysis are uncommon.

Educational objective:

https://t.me/USMLEWorldStep1

the initial infection, antigen presenting cells (eg, macrophages, dendritic cells) display mycobacterial antigens to naïve $CD4^+$ T lymphocytes in regional lymph nodes, which subsequently differentiate into **T helper type 1** (Th1) cells that **secrete interferon-gamma**.

Interferon-gamma **activates macrophages**, leading to the formation of fully acidified phagolysosomes capable of destroying intracellular mycobacteria. Activated macrophages also aggregate and differentiate into epithelioid histiocytes and multinucleated giant cells, which surround extracellular mycobacteria within granulomas. The release of **proteases, nitric oxide, and reactive oxygen species** by these cells helps contain the infection. However, these compounds also cause extensive **collateral tissue damage** and can result in the formation of cavitary lung lesions.

(Choice B) *M tuberculosis* produces trehalose dimycolate (cord factor), which inhibits phagolysosome maturation and may contribute to the formation of caseating granulomas. However, cord factor does not directly cause the tissue necrosis associated with cavitary lesions; the release of digestive enzymes by activated macrophages lining the granuloma drives caseation and cavitation.

(Choice C) Lobar pneumonia is characterized by the initial accumulation of an abundant proteinaceous exudate within the alveoli, followed by hepatization of the affected lobe. Lobar pneumonia is typically caused by pathogens such as *Streptococcus pneumoniae*. However, lobar pneumonia presents acutely, not slowly, over several weeks.

(Choice D) Intraalveolar mycobacteria do not directly cause cavitary lesions. Activated macrophages that surround the extracellular mycobacteria are primarily responsible for the tissue damage that leads to cavitation.

(Choice E) Obliterative lower airway inflammation can occur as a feature of cryptogenic organizing pneumonia. In this condition, inflammation causes the proliferation of granulation tissue, which obstructs small bronchioles and leads to alveolar consolidation. However, apical cavitary lesions and hemoptysis are uncommon.

Educational objective:
Control of *Mycobacterium tuberculosis* infection is mediated primarily by activated macrophages, which surround extracellular mycobacteria and wall them off within granulomas. The release of digestive enzymes by these cells not only helps control the infection, but also leads to damage of the surrounding tissue and the formation of cavitary lung lesions.

https://t.me/USMLEWorldStep1

Exhibit Display

Pulmonary tuberculosis

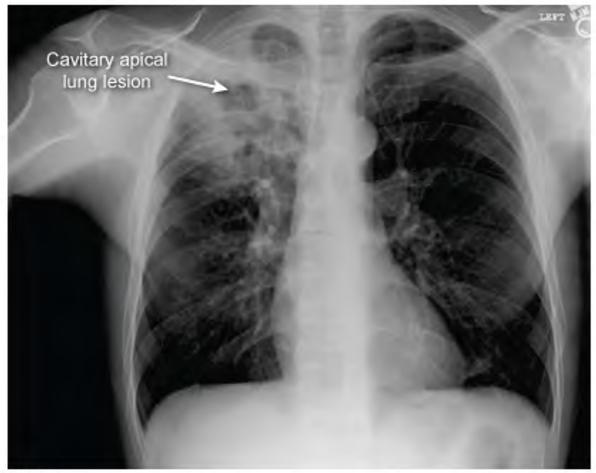

©UWorld

Zoom In | Zoom Out | Reset | New | Existing | My Notebook

This p
charac
alveoli
due to
the ini
naïve
cells th

Interfe
destro
histioc
releas
Howev
cavitar

(Choic
and m
tissue
the gra

(Choice C) Lobar pneumonia is characterized by the initial accumulation of an abundant proteinaceous exudate

https://t.me/USMLEWorldStep1

This patient has a productive cough, hemoptysis, fever, and weight loss with an apical cavitary lung lesion, findings characteristic of **active tuberculosis**. *Mycobacterium tuberculosis* is an acid-fast bacillus that replicates within the alveoli due to the init naïve cells th

Interfe destro histioc releas Howev cavitar

(Choi and m tissue the gra

(Choi within such a

(Choi surrou

(Choi this co leads t

Educational objective:

Control of *Mycobacterium tuberculosis* infection is mediated primarily by activated macrophages, which surround

Exhibit Display

***Mycobacterium tuberculosis* lymphadenitis**

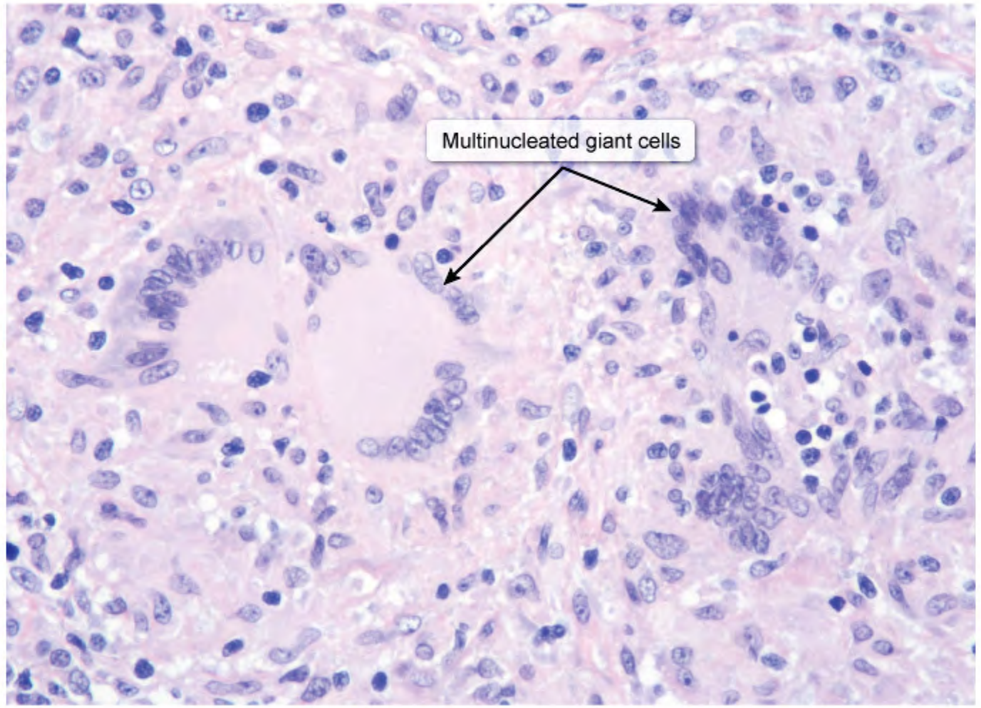

©UWorld

Zoom In | Zoom Out | Reset | New | Existing | My Notebook

https://t.me/USMLEWorldStep1

This patient has a productive cough, hemoptysis, fever, and weight loss with an apical cavitary lung lesion, findings characteristic of **active tuberculosis**. *Mycobacterium tuberculosis* is an acid-fast bacillus that replicates within the alveoli
due to
the ini
naïve
cells th

Interfe
destro
histioc
releas
Howev
cavitar

(Choi
and m
tissue
the gra

(Choi
within
such a

(Choi
surrou

(Choi
this co
leads t

Educational objective:
Control of *Mycobacterium tuberculosis* infection is mediated primarily by activated macrophages, which surround

Exhibit Display

Right lower lobe pneumonia

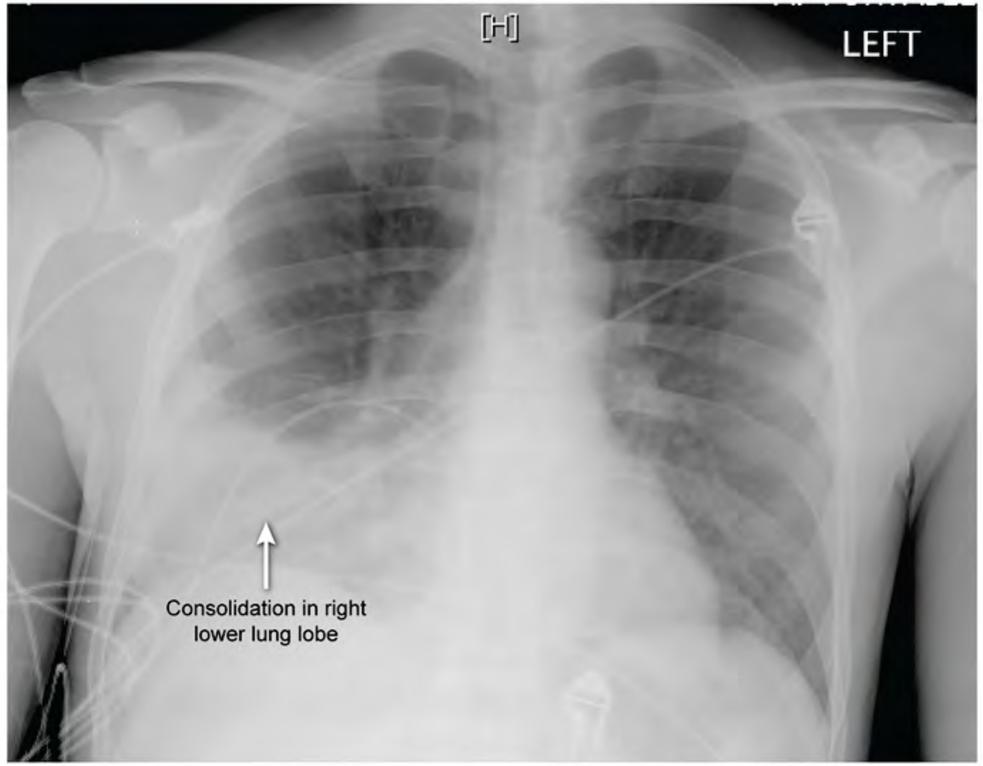

©UWorld

Zoom In | Zoom Out | Reset | New | Existing | My Notebook

https://t.me/USMLEWorldStep1

A 23-year-old woman, gravida 2 para 1, with poorly controlled type 1 diabetes and hypothyroidism comes to the hospital with preterm, premature rupture of membrane at 30 weeks' gestation. Her medications include prenatal vitamins and insulin. Vital signs are normal and examination shows clear vaginal discharge. The patient's cervix is closed and she has no uterine contractions. Laboratory results are as follows:

Hemoglobin	11.8 g/dL
Glucose	200 mg/dL
Hemoglobin A1c	7.2%

Which of the following medications has the greatest positive impact on fetal survival?

- A. Dexamethasone
- B. Insulin
- C. Magnesium
- D. Nifedipine
- E. Terbutaline

Submit

https://t.me/USMLEWorldStep1

A 23-year-old woman, gravida 2 para 1, with poorly controlled type 1 diabetes and hypothyroidism comes to the hospital with preterm, premature rupture of membrane at 30 weeks' gestation. Her medications include prenatal vitamins and insulin. Vital signs are normal and examination shows clear vaginal discharge. The patient's cervix is closed and she has no uterine contractions. Laboratory results are as follows:

Hemoglobin	11.8 g/dL
Glucose	200 mg/dL
Hemoglobin A1c	7.2%

Which of the following medications has the greatest positive impact on fetal survival?

- ✓ A. Dexamethasone (61%)
- ✗ B. Insulin (20%)
- C. Magnesium (5%)
- D. Nifedipine (4%)
- E. Terbutaline (8%)

Incorrect
Correct answer
A

61%
Answered correctly

03 secs
Time Spent

2023
Version

Explanation

In the terminal saccular stage of lung development, the type II pneumocytes produce pulmonary surfactant, a lipoprotein complex rich in phospholipids, most notably **dipalmitoylphosphatidylcholine** (DPPC, a type of lecithin). This surfactant **decreases** alveolar **surface tension** by creating a lipid-rich monolayer that separates alveolar gas from the underlying aqueous fluid. The phenomenon prevents atelectasis and end-expiratory collapse and increases pulmonary compliance.

https://t.me/USMLEWorldStep1

In the terminal saccular stage of lung development, the type II pneumocytes produce pulmonary surfactant, a lipoprotein complex rich in phospholipids, most notably **dipalmitoylphosphatidylcholine** (DPPC, a type of lecithin). This surfactant **decreases** alveolar **surface tension** by creating a lipid-rich monolayer that separates alveolar gas from the underlying aqueous fluid. The phenomenon prevents atelectasis and end-expiratory collapse and increases pulmonary compliance.

In a fetus, efflux of lung fluid into amniotic fluid enables testing of markers of lung maturity. Until 33 weeks gestation, the lecithin and sphingomyelin levels are about equal. After 33 weeks, the lecithin levels rise dramatically compared to sphingomyelin. A lecithin-to-sphingomyelin ratio >1.9 is indicative of mature fetal lungs.

Premature infants born at <32 weeks gestation are at significant risk of surfactant deficiency. Corticosteroids (eg, **betamethasone, dexamethasone**) have the greatest effect on increasing surfactant production by accelerating **maturation of type II pneumocytes**. They are administered to patients at risk for preterm labor (eg, preterm premature rupture of membranes) to decrease the risk of respiratory distress syndrome and mortality.

(Choice B) Uncontrolled maternal hyperglycemia causes fetal hyperinsulinemia and inhibits the maturational effects of cortisol and the production of surfactant proteins. Infants of these mothers can develop respiratory distress syndrome. Although corticosteroids cause temporary hyperglycemia, the beneficial effects of maternal steroid administration on surfactant production and eventual reduction of mortality far outweigh this side effect.

(Choice C) In pregnancies at risk for preterm delivery, antenatal administration of magnesium sulfate has been shown to decrease the risk for cerebral palsy. While cerebral palsy can result in permanent neurologic disability, impaired lung function is a more common cause of death in premature infants.

(Choices D and E) Nifedipine and terbutaline are medications used for inhibition of preterm labor (tocolysis). Nifedipine is a calcium channel blocker and results in myometrial relaxation by inhibition of myosin light-chain kinase-mediated phosphorylation. Terbutaline is a β-sympathomimetic that increases intracellular cAMP formation in myometrial cells. This inhibits myosin light-chain kinase and relaxes the smooth muscle. Neither drug directly affects fetal lung maturity.

Educational objective:
Both maternal and fetal cortisol help to accelerate fetal lung maturation by stimulating surfactant production.

https://t.me/USMLEWorldStep1

alveolar gas from the underlying aqueous fluid. The phenomenon prevents atelectasis and end-expiratory collapse and increases pulmonary compliance.

In a fetus, efflux of lung fluid into amniotic fluid enables testing of markers of lung maturity. Until 33 weeks gestation, the lecithin and sphingomyelin levels are about equal. After 33 weeks, the lecithin levels rise dramatically compared to sphingomyelin. A lecithin-to-sphingomyelin ratio >1.9 is indicative of mature fetal lungs.

Premature infants born at <32 weeks gestation are at significant risk of surfactant deficiency. Corticosteroids (eg, **betamethasone, dexamethasone**) have the greatest effect on increasing surfactant production by accelerating **maturation of type II pneumocytes**. They are administered to patients at risk for preterm labor (eg, preterm premature rupture of membranes) to decrease the risk of respiratory distress syndrome and mortality.

(Choice B) Uncontrolled maternal hyperglycemia causes fetal hyperinsulinemia and inhibits the maturational effects of cortisol and the production of surfactant proteins. Infants of these mothers can develop respiratory distress syndrome. Although corticosteroids cause temporary hyperglycemia, the beneficial effects of maternal steroid administration on surfactant production and eventual reduction of mortality far outweigh this side effect.

(Choice C) In pregnancies at risk for preterm delivery, antenatal administration of magnesium sulfate has been shown to decrease the risk for cerebral palsy. While cerebral palsy can result in permanent neurologic disability, impaired lung function is a more common cause of death in premature infants.

(Choices D and E) Nifedipine and terbutaline are medications used for inhibition of preterm labor (tocolysis). Nifedipine is a calcium channel blocker and results in myometrial relaxation by inhibition of myosin light-chain kinase-mediated phosphorylation. Terbutaline is a β-sympathomimetic that increases intracellular cAMP formation in myometrial cells. This inhibits myosin light-chain kinase and relaxes the smooth muscle. Neither drug directly affects fetal lung maturity.

Educational objective:
Both maternal and fetal cortisol help to accelerate fetal lung maturation by stimulating surfactant production. Betamethasone or dexamethasone is administered to pregnant women at risk of premature delivery to prevent neonatal respiratory distress syndrome.

References

https://t.me/USMLEWorldStep1

A 65-year-old man comes to the office due to shortness of breath, weakness, and cough for 1 week. He underwent bilateral lung transplantation for idiopathic pulmonary fibrosis 3 months ago. Temperature is 38.3 C (101 F), blood pressure is 130/80 mm Hg, pulse is 90/min, and respirations are 18/min. Chest x-ray shows perihilar opacities and interstitial edema. Transbronchial biopsies reveal moderate perivascular and peribronchiolar mononuclear infiltrate predominantly composed of lymphocytes. No viral inclusions are present. Which of the following is the most likely diagnosis?

- A. Left ventricular dysfunction
- B. Pneumococcal pneumonia
- C. Polyarteritis nodosa
- D. Recurrence of primary lung disease
- E. Transplant rejection

Submit

https://t.me/USMLEWorldStep1

A 65-year-old man comes to the office due to shortness of breath, weakness, and cough for 1 week. He underwent bilateral lung transplantation for idiopathic pulmonary fibrosis 3 months ago. Temperature is 38.3 C (101 F), blood pressure is 130/80 mm Hg, pulse is 90/min, and respirations are 18/min. Chest x-ray shows perihilar opacities and interstitial edema. Transbronchial biopsies reveal moderate perivascular and peribronchiolar mononuclear infiltrate predominantly composed of lymphocytes. No viral inclusions are present. Which of the following is the most likely diagnosis?

- ✗ A. Left ventricular dysfunction (0%)
- B. Pneumococcal pneumonia (8%)
- C. Polyarteritis nodosa (2%)
- D. Recurrence of primary lung disease (4%)
- ✓ E. Transplant rejection (83%)

Incorrect
Correct answer
E

83%
Answered correctly

03 secs
Time Spent

2023
Version

Explanation

Lung transplant rejection			
Type	**Onset**	**Etiology**	**Pathophysiology**
Hyperacute	Minutes to hours	**Preformed host antibodies** to donor ABO or HLA	Neutrophilic infiltration with fibrinoid necrosis and thrombosis
Acute	≤6 months	Cell-mediated response to mismatched donor HLA	Perivascular (small lung vessels) & submucosal (bronchiole) lymphocytic infiltrates

https://t.me/USMLEWorldStep1

Lung transplant rejection			
Type	**Onset**	**Etiology**	**Pathophysiology**
Hyperacute	Minutes to hours	**Preformed host antibodies** to donor ABO or HLA	Neutrophilic infiltration with fibrinoid necrosis and thrombosis
Acute	≤6 months	Cell-mediated response to mismatched donor HLA	Perivascular (small lung vessels) & submucosal (bronchiole) lymphocytic infiltrates
Chronic	Months or years	Chronic, low-grade, mixed cell-mediated and antibody response to HLA antigens	Submucosal inflammation → granulation, scarring & **bronchiolitis obliterans**
HLA = human leukocyte antigen.			

This patient with dyspnea, cough, fever, and lung biopsy revealing lymphocytic infiltration several months after lung transplant likely has **acute lung transplant rejection**. Acute transplant rejection (ATR) is a **cell-mediated response** involving T-lymphocyte activation against donor antigens (eg, mismatched HLA types) and most commonly occurs **within 6 months** of transplant.

Patients with ATR may be asymptomatic (with rejection detected by surveillance biopsy) or can present with **low-grade fever**, dyspnea, **cough**, and/or fatigue. Chest x-ray may reveal hilar lymphatic enlargement and edematous interstitial thickening. Lung biopsy reveals **perivascular and peribronchiolar mononuclear infiltrate** primarily composed of **lymphocytes**. The **absence of viral inclusions** in epithelial cells helps rule out cytomegalovirus, a common infection in lung transplant recipients that can present similarly to acute rejection.

The risk of ATR markedly increases with poor adherence to immunosuppression medications (eg, tacrolimus, mycophenolate), but it can affect all transplant recipients, regardless of medication adherence. Episodes of ATR are usually reversible with increased immunosuppression (eg, high-dose steroids); however, patients with frequent episodes of ATR are at greater risk of developing chronic transplant rejection, which is typically irreversible.

https://t.me/USMLEWorldStep1

This patient with dyspnea, cough, fever, and lung biopsy revealing lymphocytic infiltration several months after lung transplant likely has **acute lung transplant rejection**. Acute transplant rejection (ATR) is a **cell-mediated response** involving T-lymphocyte activation against donor antigens (eg, mismatched HLA types) and most commonly occurs **within 6 months** of transplant.

Patients with ATR may be asymptomatic (with rejection detected by surveillance biopsy) or can present with **low-grade fever**, dyspnea, **cough**, and/or fatigue. Chest x-ray may reveal hilar lymphatic enlargement and edematous interstitial thickening. Lung biopsy reveals **perivascular and peribronchiolar mononuclear infiltrate** primarily composed of **lymphocytes**. The **absence of viral inclusions** in epithelial cells helps rule out cytomegalovirus, a common infection in lung transplant recipients that can present similarly to acute rejection.

The risk of ATR markedly increases with poor adherence to immunosuppression medications (eg, tacrolimus, mycophenolate), but it can affect all transplant recipients, regardless of medication adherence. Episodes of ATR are usually reversible with increased immunosuppression (eg, high-dose steroids); however, patients with frequent episodes of ATR are at greater risk of developing chronic transplant rejection, which is typically irreversible.

(Choice A) Left ventricular dysfunction can cause pulmonary edema with similar appearance to ATR on chest x-ray. However, fever is not expected, and lung biopsy typically reveals hemosiderin-laden macrophages with no evidence of inflammatory lymphocytic infiltrate.

(Choice B) Lung transplant recipients are at increased risk of bacterial (eg, Pneumococcal) pneumonia; however, chest x-ray is more likely to reveal focal alveolar consolidation, and neutrophil predominance is expected on lung biopsy.

(Choice C) Polyarteritis nodosa is a medium vessel vasculitis that typically demonstrates lymphocytic infiltrate with vascular wall necrosis on biopsy. It can affect multiple organs, including the liver, kidneys, intestines, and skin; however, it characteristically spares the lungs.

(Choice D) Eventual recurrence of primary lung disease following lung transplantation is possible for many diseases (eg, interstitial lung disease, bronchiectasis) but is unlikely within only several months.

Educational objective:
Acute lung transplant rejection is a cell-mediated response involving T-lymphocyte activation against donor

https://t.me/USMLEWorldStep1

commonly occurs **within 6 months** of transplant.

Patients with ATR may be asymptomatic (with rejection detected by surveillance biopsy) or can present with **low-grade fever**, dyspnea, **cough**, and/or fatigue. Chest x-ray may reveal hilar lymphatic enlargement and edematous interstitial thickening. Lung biopsy reveals **perivascular and peribronchiolar mononuclear infiltrate** primarily composed of **lymphocytes**. The **absence of viral inclusions** in epithelial cells helps rule out cytomegalovirus, a common infection in lung transplant recipients that can present similarly to acute rejection.

The risk of ATR markedly increases with poor adherence to immunosuppression medications (eg, tacrolimus, mycophenolate), but it can affect all transplant recipients, regardless of medication adherence. Episodes of ATR are usually reversible with increased immunosuppression (eg, high-dose steroids); however, patients with frequent episodes of ATR are at greater risk of developing chronic transplant rejection, which is typically irreversible.

(Choice A) Left ventricular dysfunction can cause pulmonary edema with similar appearance to ATR on chest x-ray. However, fever is not expected, and lung biopsy typically reveals hemosiderin-laden macrophages with no evidence of inflammatory lymphocytic infiltrate.

(Choice B) Lung transplant recipients are at increased risk of bacterial (eg, Pneumococcal) pneumonia; however, chest x-ray is more likely to reveal focal alveolar consolidation, and neutrophil predominance is expected on lung biopsy.

(Choice C) Polyarteritis nodosa is a medium vessel vasculitis that typically demonstrates lymphocytic infiltrate with vascular wall necrosis on biopsy. It can affect multiple organs, including the liver, kidneys, intestines, and skin; however, it characteristically spares the lungs.

(Choice D) Eventual recurrence of primary lung disease following lung transplantation is possible for many diseases (eg, interstitial lung disease, bronchiectasis) but is unlikely within only several months.

Educational objective:
Acute lung transplant rejection is a cell-mediated response involving T-lymphocyte activation against donor antigens and typically occurs within 6 months of transplant. Affected patients can have shortness of breath, cough, and low-grade fever. Lung biopsy reveals perivascular and peribronchiolar lymphocytic infiltrate and absence of epithelial cell viral inclusions (ruling out cytomegalovirus).

https://t.me/USMLEWorldStep1

A 32-year-old woman is brought to the emergency department due to severe shortness of breath. She has no chest pain. The patient does not use tobacco. Temperature is 36.7 C (98 F), blood pressure is 132/81 mm Hg, pulse is 102/min, and respirations are 30/min. During physical examination, her condition deteriorates and she is emergently intubated due to acute respiratory failure. Shortly after intubation, she goes into cardiac arrest and dies despite resuscitation efforts. Review of the patient's medical records shows that she had been prescribed multiple medications but had a history of noncompliance. Autopsy shows hyperinflated lungs, airway mucus plugging, and cellular infiltration of the bronchial wall. Long-term use of which of the following drugs would have best prevented the cellular reaction in this patient's airways?

- A. Albuterol
- B. Fluticasone
- C. Ipratropium
- D. Magnesium sulfate
- E. Montelukast
- F. Theophylline

Submit

https://t.me/USMLEWorldStep1

A 32-year-old woman is brought to the emergency department due to severe shortness of breath. She has no chest pain. The patient does not use tobacco. Temperature is 36.7 C (98 F), blood pressure is 132/81 mm Hg, pulse is 102/min, and respirations are 30/min. During physical examination, her condition deteriorates and she is emergently intubated due to acute respiratory failure. Shortly after intubation, she goes into cardiac arrest and dies despite resuscitation efforts. Review of the patient's medical records shows that she had been prescribed multiple medications but had a history of noncompliance. Autopsy shows hyperinflated lungs, airway mucus plugging, and cellular infiltration of the bronchial wall. Long-term use of which of the following drugs would have best prevented the cellular reaction in this patient's airways?

- A. Albuterol (7%)
- ✓ B. Fluticasone (57%)
- C. Ipratropium (11%)
- D. Magnesium sulfate (0%)
- E. Montelukast (18%)
- F. Theophylline (3%)

Correct

57% Answered correctly

03 secs Time Spent

2023 Version

Explanation

This patient's autopsy findings of lung hyperinflation and bronchial inflammation are suggestive of **uncontrolled asthma**, a disease characterized by chronic airway inflammation, airway hyperresponsiveness, and intermittent bronchoconstriction. **Chronic inflammation**, composed mainly of **eosinophils**, helper T cells, and mast cells, causes airway remodeling (ie, bronchial wall thickening, **increased smooth muscle**), which further worsens airway obstruction and asthma symptoms.

https://t.me/USMLEWorldStep1

This patient's autopsy findings of lung hyperinflation and bronchial inflammation are suggestive of **uncontrolled asthma**, a disease characterized by chronic airway inflammation, airway hyperresponsiveness, and intermittent bronchoconstriction. **Chronic inflammation**, composed mainly of **eosinophils**, helper T cells, and mast cells, causes airway remodeling (ie, bronchial wall thickening, **increased smooth muscle**), which further worsens airway obstruction and asthma symptoms.

Corticosteroids inhibit the production of inflammatory mediators (eg, cytokines, prostaglandins, leukotrienes), reduce leukocyte extravasation into the respiratory epithelium, and induce apoptosis of inflammatory cells. In addition, corticosteroids decrease smooth muscle proliferation and mucus production by goblet cells.

Systemic corticosteroids (eg, oral prednisone) are used in short courses to treat acute asthma exacerbations, whereas inhaled corticosteroids (eg, **fluticasone**) reduce the frequency and severity of exacerbations and are used for long-term asthma control in patients with persistent symptoms. Suppression of airway inflammation is evident within hours of administration but reaches maximal effect after several months of inhaled therapy. Nonadherence to long-term therapy can increase the risk of life-threatening asthma exacerbation.

(Choices A and C) Albuterol is a selective beta-2 adrenergic agonist that induces bronchodilation. Acetylcholine released through vagal stimulation mediates bronchoconstriction via muscarinic receptors on bronchial smooth muscle cells; ipratropium is a muscarinic antagonist that promotes bronchodilation and reduced mucus production. Neither of these agents has anti-inflammatory properties, and although short-acting beta agonists are widely used to provide rapid relief of symptoms during an exacerbation, they do not prevent inflammation-induced airway remodeling or alter the chronic disease course.

(Choice D) Magnesium sulfate inhibits calcium influx into airway smooth muscle and promotes bronchodilation when given intravenously during an acute asthma flare-up. Magnesium also reduces inflammation by stabilizing T cells and inhibiting mast cell degranulation; however, it is less effective than corticosteroids.

(Choice E) Leukotrienes are potent inducers of airway bronchoconstriction and inflammation. Leukotriene inhibitors (eg, montelukast) are useful for long-term control in some patients with asthma. However, they possess less efficacy and have fewer anti-inflammatory properties than inhaled glucocorticoids.

(Choice F) Theophylline, a phosphodiesterase inhibitor, results in increased intracellular cyclic AMP, which

https://t.me/USMLEWorldStep1

Corticosteroids inhibit the production of inflammatory mediators (eg, cytokines, prostaglandins, leukotrienes), reduce leukocyte extravasation into the respiratory epithelium, and induce apoptosis of inflammatory cells. In addition, corticosteroids decrease smooth muscle proliferation and mucus production by goblet cells.

Systemic corticosteroids (eg, oral prednisone) are used in short courses to treat acute asthma exacerbations, whereas inhaled corticosteroids (eg, **fluticasone**) reduce the frequency and severity of exacerbations and are used for long-term asthma control in patients with persistent symptoms. Suppression of airway inflammation is evident within hours of administration but reaches maximal effect after several months of inhaled therapy. Nonadherence to long-term therapy can increase the risk of life-threatening asthma exacerbation.

(Choices A and C) Albuterol is a selective beta-2 adrenergic agonist that induces bronchodilation. Acetylcholine released through vagal stimulation mediates bronchoconstriction via muscarinic receptors on bronchial smooth muscle cells; ipratropium is a muscarinic antagonist that promotes bronchodilation and reduced mucus production. Neither of these agents has anti-inflammatory properties, and although short-acting beta agonists are widely used to provide rapid relief of symptoms during an exacerbation, they do not prevent inflammation-induced airway remodeling or alter the chronic disease course.

(Choice D) Magnesium sulfate inhibits calcium influx into airway smooth muscle and promotes bronchodilation when given intravenously during an acute asthma flare-up. Magnesium also reduces inflammation by stabilizing T cells and inhibiting mast cell degranulation; however, it is less effective than corticosteroids.

(Choice E) Leukotrienes are potent inducers of airway bronchoconstriction and inflammation. Leukotriene inhibitors (eg, montelukast) are useful for long-term control in some patients with asthma. However, they possess less efficacy and have fewer anti-inflammatory properties than inhaled glucocorticoids.

(Choice F) Theophylline, a phosphodiesterase inhibitor, results in increased intracellular cyclic AMP, which contributes to its role as a bronchodilator. Theophylline also has anti-inflammatory effects, although they are far less potent than glucocorticoids.

Educational objective:
Asthma is characterized by chronic airway inflammation, which leads to airway remodeling, airway hyperresponsiveness, and bronchoconstriction. Corticosteroids reduce airway inflammation and are used for both chronic asthma management (inhaled administration) and acute exacerbations (systemic administration).

https://t.me/USMLEWorldStep1

A previously healthy 43-year-old man comes to the office during the early fall due to a 4-week history of cough. He initially had a "bad cold" that lasted about 10 days. The sneezing, runny nose, and muscle aches that accompanied the cold have improved, but the cough has persisted and worsened. The patient has "bursts of coughing" for several minutes as he feels unable to clear the mucus. On at least 5 occasions, these attacks were so severe that he vomited afterward. The patient is a children's karate teacher. He received all of his childhood vaccinations but has not seen a physician in many years. There is no history of recent travel. Vital signs and physical examination are normal. Chest x-ray is unrevealing. Which of the following is the most likely cause of this patient's symptoms?

- A. Acid-fast bacillus
- B. Gram-negative coccobacillus
- C. Gram-positive diplococcus
- D. *Mycoplasma*
- E. RNA virus

Submit

https://t.me/USMLEWorldStep1

A previously healthy 43-year-old man comes to the office during the early fall due to a 4-week history of cough. He initially had a "bad cold" that lasted about 10 days. The sneezing, runny nose, and muscle aches that accompanied the cold have improved, but the cough has persisted and worsened. The patient has "bursts of coughing" for several minutes as he feels unable to clear the mucus. On at least 5 occasions, these attacks were so severe that he vomited afterward. The patient is a children's karate teacher. He received all of his childhood vaccinations but has not seen a physician in many years. There is no history of recent travel. Vital signs and physical examination are normal. Chest x-ray is unrevealing. Which of the following is the most likely cause of this patient's symptoms?

- ✗ A. Acid-fast bacillus (3%)
- ✓ B. Gram-negative coccobacillus (40%)
- C. Gram-positive diplococcus (17%)
- D. *Mycoplasma* (14%)
- E. RNA virus (23%)

Incorrect
Correct answer
B

40%
Answered correctly

04 secs
Time Spent

2023
Version

Explanation

Pertussis (whooping cough) is a highly contagious infection transmitted via respiratory droplets. It was predominantly a childhood disease before vaccination became the norm; however, many cases now occur in adolescents/adults whose immunity has waned. The diagnosis should be considered in any **adult** with acute tracheobronchitis who has **not had vaccination boosters**. This patient may have contracted the disease during karate sessions with his students. Chest x-ray is unremarkable in most cases as there is no pulmonary consolidation. The phases of pertussis include:

https://t.me/USMLEWorldStep1

Pertussis (whooping cough) is a highly contagious infection transmitted via respiratory droplets. It was predominantly a childhood disease before vaccination became the norm; however, many cases now occur in adolescents/adults whose immunity has waned. The diagnosis should be considered in any **adult** with acute tracheobronchitis who has **not had vaccination boosters**. This patient may have contracted the disease during karate sessions with his students. Chest x-ray is unremarkable in most cases as there is no pulmonary consolidation. The phases of pertussis include:

1. Catarrhal phase - similar to many routine upper respiratory infections (eg, malaise, mild fever, rhinorrhea)
2. Paroxysmal phase - marked by **severe coughing spells** with the classic inspiratory whoop or **post-tussive emesis/syncope**
3. Convalescent phase - during which the cough improves

Pertussis is caused by the **gram-negative coccobacillus** *Bordetella pertussis*, which produces virulence factors that include adhesins and toxins. Pertactin, which forms the basis of the acellular pertussis vaccine, promotes *B pertussis* adherence to the ciliated upper respiratory epithelium. Tracheal cytotoxin subsequently promotes local tissue destruction, resulting in cough. **Pertussis toxin** causes excessive **adenylate cyclase activity**, which prevents effective phagocytosis and allows the organism to persist in alveolar macrophages and ciliated epithelial cells, leading to a prolonged disease course. **Lymphocytosis**, induced by pertussis toxin, is also common.

(Choice A) This patient lacks the constitutional symptoms (eg, night sweats, weight loss, fever) and chest x-ray findings (eg, upper lobe infiltrates with cavitation) expected in pulmonary tuberculosis, which is caused by the acid-fast bacillus *Mycobacterium tuberculosis*.

(Choice C) *Streptococcus pneumoniae*, a gram-positive diplococcus, is the most common cause of pneumonia and typically presents with lobar consolidation on chest x-ray. This patient's negative chest x-ray and lack of fever make pneumococcal pneumonia unlikely.

(Choice D) *Mycoplasma pneumoniae* typically causes atypical pneumonia characterized by a persistent nonproductive cough, pharyngitis, ear pain, and constitutional symptoms (eg, fever, headache, malaise). Chest x-ray classically reveals a diffuse interstitial infiltrate.

(Choice E) Examples of RNA viruses causing respiratory infections include respiratory syncytial virus, influenza,

https://t.me/USMLEWorldStep1

3. Convalescent phase - during which the cough improves

Pertussis is caused by the **gram-negative coccobacillus** *Bordetella pertussis*, which produces virulence factors that include adhesins and toxins. Pertactin, which forms the basis of the acellular pertussis vaccine, promotes *B pertussis* adherence to the ciliated upper respiratory epithelium. Tracheal cytotoxin subsequently promotes local tissue destruction, resulting in cough. **Pertussis toxin** causes excessive **adenylate cyclase activity**, which prevents effective phagocytosis and allows the organism to persist in alveolar macrophages and ciliated epithelial cells, leading to a prolonged disease course. **Lymphocytosis**, induced by pertussis toxin, is also common.

(Choice A) This patient lacks the constitutional symptoms (eg, night sweats, weight loss, fever) and chest x-ray findings (eg, upper lobe infiltrates with cavitation) expected in pulmonary tuberculosis, which is caused by the acid-fast bacillus *Mycobacterium tuberculosis*.

(Choice C) *Streptococcus pneumoniae*, a gram-positive diplococcus, is the most common cause of pneumonia and typically presents with lobar consolidation on chest x-ray. This patient's negative chest x-ray and lack of fever make pneumococcal pneumonia unlikely.

(Choice D) *Mycoplasma pneumoniae* typically causes atypical pneumonia characterized by a persistent nonproductive cough, pharyngitis, ear pain, and constitutional symptoms (eg, fever, headache, malaise). Chest x-ray classically reveals a diffuse interstitial infiltrate.

(Choice E) Examples of RNA viruses causing respiratory infections include respiratory syncytial virus, influenza, parainfluenza, rhinovirus, and corona virus. Although viral infections can cause a postinfectious cough for up to 8 weeks, severe paroxysmal coughing spells associated with post-tussive emesis in an adult without booster vaccinations are more concerning for pertussis.

Educational objective:
Pertussis should be considered in any adult who has not had updated vaccination boosters. The clinical presentation is a paroxysmal cough lasting >2 weeks that is associated with post-tussive emesis or inspiratory whoop after a severe coughing episode.

References

- Pertussis: a reemerging infection.

https://t.me/USMLEWorldStep1

A 72-year-old man comes to the office after several days of mild headache and lethargy. He has also had weakness, chronic cough, and decreased appetite. He drinks 2 or 3 beers each weekend and has a 40-pack-year smoking history. Temperature is 37 C (98.6 F), blood pressure is 120/84 mm Hg, pulse is 78/min, and respirations are 24/min. Lung examination shows mildly prolonged expiration with end-expiratory wheezes. Laboratory results are as follows:

Hemoglobin	11.2 g/dL
Platelets	194,000/mm^3
Leukocytes	7,600/mm^3
Sodium	122 mEq/L
Potassium	3.9 mEq/L
Bicarbonate	24 mEq/L
Blood urea nitrogen	16 mg/dL
Creatinine	0.6 mg/dL
Glucose	95 mg/dL
Osmolality, plasma	250 mOsm/kg H_2O
Osmolality, urine	310 mOsm/kg H_2O

Chest x-ray reveals overinflated lungs and a 2.5-cm left hilar mass. Biopsy of the mass would most likely show which of the following?

- A. Carcinoid tumor
- B. Lung adenocarcinoma
- C. Lymphoma

https://t.me/USMLEWorldStep1

Hemoglobin	11.2 g/dL
Platelets	194,000/mm^3
Leukocytes	7,600/mm^3
Sodium	122 mEq/L
Potassium	3.9 mEq/L
Bicarbonate	24 mEq/L
Blood urea nitrogen	16 mg/dL
Creatinine	0.6 mg/dL
Glucose	95 mg/dL
Osmolality, plasma	250 mOsm/kg H_2O
Osmolality, urine	310 mOsm/kg H_2O

Chest x-ray reveals overinflated lungs and a 2.5-cm left hilar mass. Biopsy of the mass would most likely show which of the following?

- A. Carcinoid tumor
- B. Lung adenocarcinoma
- C. Lymphoma
- D. Mesothelioma
- E. Small cell lung cancer
- F. Squamous cell lung carcinoma

Submit

https://t.me/USMLEWorldStep1

Hemoglobin	11.2 g/dL
Platelets	194,000/mm^3
Leukocytes	7,600/mm^3
Sodium	122 mEq/L
Potassium	3.9 mEq/L
Bicarbonate	24 mEq/L
Blood urea nitrogen	16 mg/dL
Creatinine	0.6 mg/dL
Glucose	95 mg/dL
Osmolality, plasma	250 mOsm/kg H_2O
Osmolality, urine	310 mOsm/kg H_2O

Chest x-ray reveals overinflated lungs and a 2.5-cm left hilar mass. Biopsy of the mass would most likely show which of the following?

- A. Carcinoid tumor (3%)
- B. Lung adenocarcinoma (4%)
- ✗ C. Lymphoma (1%)
- D. Mesothelioma (0%)
- ✓ E. Small cell lung cancer (72%)
- F. Squamous cell lung carcinoma (16%)

Incorrect
Correct answer
E

72%
Answered correctly

06 secs
Time Spent

2023
Version

https://t.me/USMLEWorldStep1

Explanation

Lung malignancies & associated paraneoplastic syndromes	
Small cell	• SIADH (ectopic ADH) • Cushing syndrome (ectopic ACTH) • Lambert-Eaton myasthenic syndrome • Cerebellar ataxia
Squamous cell	• Hypercalcemia (secretion of PTHrP)
Adenocarcinoma	• Hypertrophic osteoarthropathy • Dermatomyositis or polymyositis • Migratory thrombophlebitis (Trousseau syndrome)
ACTH = adrenocorticotropic hormone; **ADH** = antidiuretic hormone; **PTHrP** = parathyroid hormone-related peptide; **SIADH** = syndrome of inappropriate antidiuretic hormone.	

This patient's **hyponatremia** is most likely due to syndrome of inappropriate antidiuretic hormone (**SIADH**), which is one of several paraneoplastic syndromes that may occur in patients with **small cell lung cancer** (SCLC).

Presenting symptoms of SIADH are often vague (eg, lethargy), but untreated SIADH can lead to significant

https://t.me/USMLEWorldStep1

This patient's **hyponatremia** is most likely due to syndrome of inappropriate antidiuretic hormone (**SIADH**), which is one of several paraneoplastic syndromes that may occur in patients with **small cell lung cancer** (SCLC).

Presenting symptoms of SIADH are often vague (eg, lethargy), but untreated SIADH can lead to significant hyponatremia causing seizures or coma. Physical examination shows **euvolemia**, and laboratory results demonstrate **decreased serum osmolality** consistent with true (hypotonic) hyponatremia. An essential characteristic of SIADH is **urine osmolality >100** mOsm/kg H_2O, which reflects inability of the kidneys to produce adequately dilute urine to remove excess free water from the body (due to inappropriately high levels of ADH).

SIADH may be caused by excessive release of ADH from the posterior pituitary (eg, central nervous system disorder, medication adverse effect) or **ectopic secretion of ADH**. SCLC, a neuroendocrine tumor that typically presents as a hilar mass in patients with a significant **smoking history**, is the most common cause of ectopic secretion of ADH.

(Choice A) Carcinoids are rare neuroendocrine tumors that typically occur in the digestive tract or lungs. They may lead to carcinoid syndrome (eg, flushing, diarrhea, bronchoconstriction), which is a paraneoplastic syndrome caused by secretion of serotonin, histamine, and kinins. Carcinoids may rarely cause SIADH, but SCLC is more likely in this patient with a hilar mass and significant smoking history.

(Choices B, D, and F) Lung adenocarcinoma may cause paraneoplastic hypertrophic osteoarthropathy, and squamous cell carcinoma can lead to paraneoplastic hypercalcemia (eg, secretion of parathyroid hormone-related protein). Mesothelioma is a rare malignancy derived from the mesothelial lining of the thoracic cavity and has been associated with a variety of paraneoplastic syndromes (eg, peripheral neuropathy, migratory thrombophlebitis). SIADH due to any of these malignancies would be unusual.

(Choice C) Paraneoplastic syndromes associated with lymphoma include hypercalcemia due to overproduction of 1,25-dihydroxyvitamin D and cerebellar degeneration. SIADH would be atypical.

Educational objective:
Small cell lung cancer is a neuroendocrine malignancy associated with several paraneoplastic syndromes. It is the most common cause of syndrome of inappropriate antidiuretic hormone (SIADH) due to ectopic secretion of antidiuretic hormone. SIADH is characterized by hyponatremia, decreased serum osmolality, and urine osmolality

https://t.me/USMLEWorldStep1

This patient's **hyponatremia** is most likely due to syndrome of inappropriate antidiuretic hormone (**SIADH**), which is one of several paraneoplastic syndromes that may occur in patients with **small cell lung cancer** (SCLC).

Presenting symptoms of SIADH are often vague (eg, lethargy), but untreated SIADH can lead to significant hyponatremia causing seizures or coma. Physical examination shows **euvolemia**, and laboratory results demonstrate **decreased serum osmolality** consistent with true (hypotonic) hyponatremia. An essential characteristic of SIADH is **urine osmolality >100** mOsm/kg H_2O, which reflects inability of the kidneys to produce adequately dilute urine to remove excess free water from the body (due to inappropriately high levels of ADH).

SIADH may be caused by excessive release of ADH from the posterior pituitary (eg, central nervous system disorder, medication adverse effect) or **ectopic secretion of ADH**. SCLC, a neuroendocrine tumor that typically presents as a hilar mass in patients with a significant **smoking history**, is the most common cause of ectopic secretion of ADH.

(Choice A) Carcinoids are rare neuroendocrine tumors that typically occur in the digestive tract or lungs. They may lead to carcinoid syndrome (eg, flushing, diarrhea, bronchoconstriction), which is a paraneoplastic syndrome caused by secretion of serotonin, histamine, and kinins. Carcinoids may rarely cause SIADH, but SCLC is more likely in this patient with a hilar mass and significant smoking history.

(Choices B, D, and F) Lung adenocarcinoma may cause paraneoplastic hypertrophic osteoarthropathy, and squamous cell carcinoma can lead to paraneoplastic hypercalcemia (eg, secretion of parathyroid hormone-related protein). Mesothelioma is a rare malignancy derived from the mesothelial lining of the thoracic cavity and has been associated with a variety of paraneoplastic syndromes (eg, peripheral neuropathy, migratory thrombophlebitis). SIADH due to any of these malignancies would be unusual.

(Choice C) Paraneoplastic syndromes associated with lymphoma include hypercalcemia due to overproduction of 1,25-dihydroxyvitamin D and cerebellar degeneration. SIADH would be atypical.

Educational objective:
Small cell lung cancer is a neuroendocrine malignancy associated with several paraneoplastic syndromes. It is the most common cause of syndrome of inappropriate antidiuretic hormone (SIADH) due to ectopic secretion of antidiuretic hormone. SIADH is characterized by hyponatremia, decreased serum osmolality, and urine osmolality >100 mOsm/kg H_2O.

https://t.me/USMLEWorldStep1

ADH = antidiuretic hormone; **PTHrP** = parathyroid hormone-related peptide; **SIADH** = syndrome of

Exhibit Display

This p
is one

Prese
hypon
demor
charac
adequ

SIADH
disord
preser
secret

(Choi
may le
cause
likely i

(Choi
squam
protein
associ
SIADH

(Choi
1,25-d

Educational objective:

Posterior pituitary (neurohypophysis)

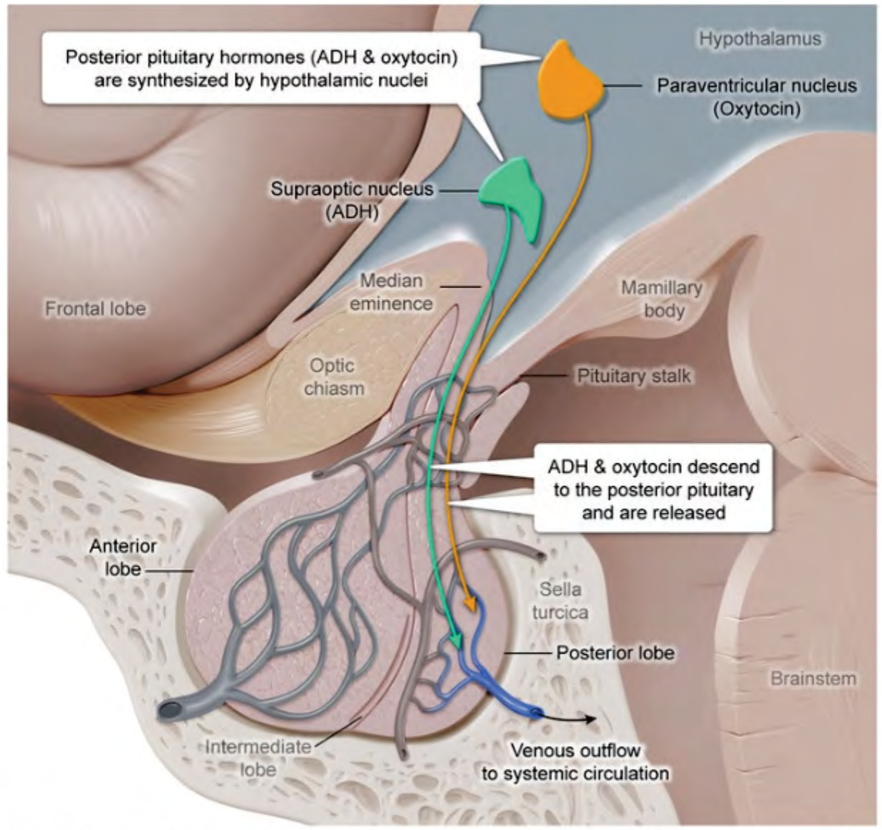

ADH = Antidiuretic hormone (ie, vasopressin).

©UWorld

Zoom In | Zoom Out | Reset | New | Existing | My Notebook

https://t.me/USMLEWorldStep1

A 44-year-old man comes to the emergency department with a 3-day history of fever, chills, malaise, dyspnea, and a cough productive of "greenish" sputum. The patient has no prior medical problems and has never been hospitalized. He has a 25-pack-year smoking history and drinks 4-5 beers a week. His temperature is 39.4 C (103 F), blood pressure is 130/80 mm Hg, pulse is 98/min, and respirations are 20/min. On examination, dullness to percussion, crackles, and egophony are present at the right lung base. The remainder of the examination is normal. Chest x-ray shows a dense infiltrate occupying the entire right lower lobe. Which of the following most likely accounts for the color of this patient's sputum?

- A. Epithelial necrosis
- B. Hemolysis
- C. High bacterial load
- D. Mucopolysaccharides
- E. Myeloperoxidase

Submit

https://t.me/USMLEWorldStep1

A 44-year-old man comes to the emergency department with a 3-day history of fever, chills, malaise, dyspnea, and a cough productive of "greenish" sputum. The patient has no prior medical problems and has never been hospitalized. He has a 25-pack-year smoking history and drinks 4-5 beers a week. His temperature is 39.4 C (103 F), blood pressure is 130/80 mm Hg, pulse is 98/min, and respirations are 20/min. On examination, dullness to percussion, crackles, and egophony are present at the right lung base. The remainder of the examination is normal. Chest x-ray shows a dense infiltrate occupying the entire right lower lobe. Which of the following most likely accounts for the color of this patient's sputum?

- ✗ A. Epithelial necrosis (5%)
- B. Hemolysis (6%)
- C. High bacterial load (17%)
- D. Mucopolysaccharides (20%)
- ✓ E. Myeloperoxidase (50%)

Incorrect
Correct answer
E

50%
Answered correctly

04 secs
Time Spent

2023
Version

Explanation

This middle-aged man presenting with new-onset fevers, productive cough, and a dense lobar infiltrate likely has community-acquired **pneumonia** (CAP). CAP in otherwise healthy individuals is most commonly caused by *Streptococcus pneumoniae*, the most common bacterial etiology worldwide. Tobacco use further increases its risk. In nonelderly patients, pneumococcal pneumonia presents with abrupt-onset fevers, rigors, tachypnea, and productive cough with consolidation in one lobe of the lungs.

Neutrophil **myeloperoxidase** is responsible for the **green** color of pus and sputum in bacterial infections. It is a blue-green heme-based pigmented molecule contained within the azurophilic granules of neutrophils and catalyzes

https://t.me/USMLEWorldStep1

Explanation

This middle-aged man presenting with new-onset fevers, productive cough, and a dense lobar infiltrate likely has community-acquired **pneumonia** (CAP). CAP in otherwise healthy individuals is most commonly caused by *Streptococcus pneumoniae*, the most common bacterial etiology worldwide. Tobacco use further increases its risk. In nonelderly patients, pneumococcal pneumonia presents with abrupt-onset fevers, rigors, tachypnea, and productive cough with consolidation in one lobe of the lungs.

Neutrophil **myeloperoxidase** is responsible for the **green** color of pus and sputum in bacterial infections. It is a blue-green heme-based pigmented molecule contained within the azurophilic granules of neutrophils and catalyzes the production of hypochlorous acid from chloride and hydrogen peroxide during the phagocytic respiratory burst.

(Choices A and B) Both the "currant jelly" sputum seen in pneumonia caused by *Klebsiella pneumoniae* and the "rusty" color occasionally seen in pneumococcal pneumonia are due to extravasation of red blood cells and hemoglobin into the sputum caused by extensive inflammation and necrosis.

(Choice C) *Pseudomonas* pneumonia can cause a blue-green pigment due to the production of pyocyanin, but *Pseudomonas* is not a common cause of CAP in otherwise healthy adults.

(Choice D) Respiratory epithelium sloughing and mucopolysaccharide production can contribute to the formation of sputum in patients with respiratory infection but does not contribute to sputum's green color.

Educational objective:
The green discoloration of pus or sputum seen during common bacterial infections is due to the presence of myeloperoxidase, a blue-green heme-based enzyme that is released from neutrophil azurophilic granules and forms hypochlorous acid (bleach).

References

- Myeloperoxidase in human neutrophil host defence.

Pathophysiology	Pulmonary & Critical Care	Community acquired pneumonia
Subject	System	Topic

Copyright © UWorld. All rights reserved.

https://t.me/USMLEWorldStep1

Explanation

This m
comm
Strept
risk. I
produc

Neutro
blue-g
the pro

(Choi
"rusty"
hemog

(Choi
Pseud

(Choi
of sput

Educa
The gr
myelo
forms

Refere
- My

Pathoph
Subject

Exhibit Display

Right lower lobe pneumonia

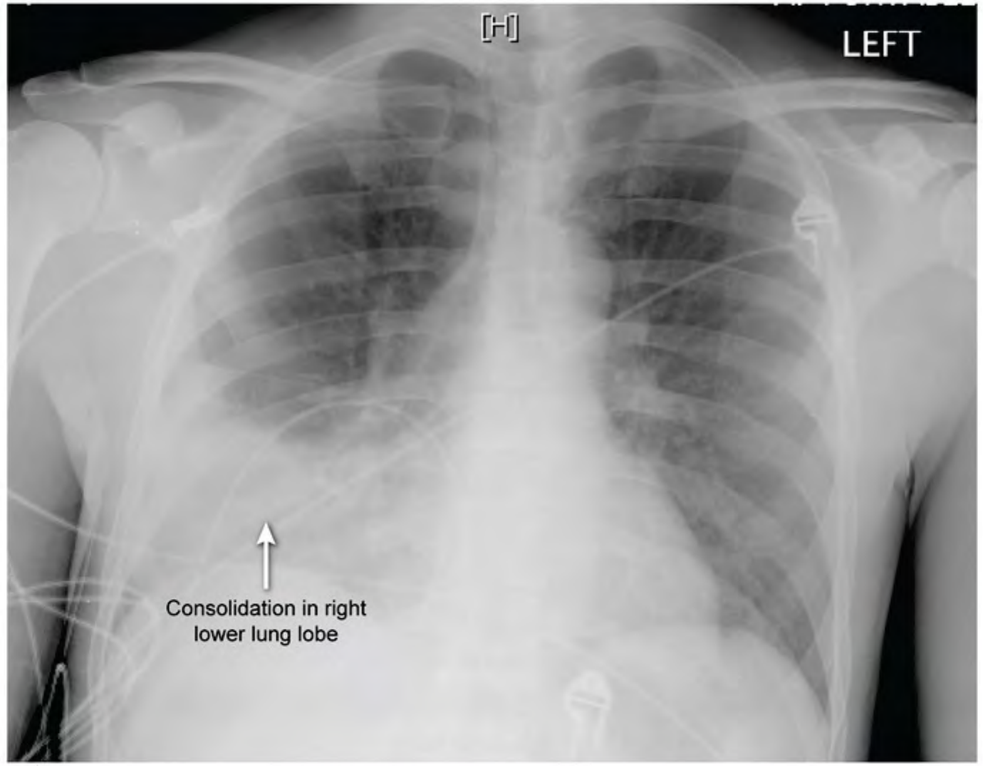

©UWorld

Zoom In | Zoom Out | Reset | New | Existing | My Notebook

Copyright © UWorld. All rights reserved.

https://t.me/USMLEWorldStep1

A 6-year-old boy playing in a dusty field in windy weather inhales many small particles that become lodged in his terminal bronchioles. Which of the following respiratory components is most important in clearing these particles?

- A. Ciliated cells
- B. Goblet cells
- C. Macrophages
- D. Submucosal glands
- E. Type I pneumocytes
- F. Type II pneumocytes

Submit

https://t.me/USMLEWorldStep1

A 6-year-old boy playing in a dusty field in windy weather inhales many small particles that become lodged in his terminal bronchioles. Which of the following respiratory components is most important in clearing these particles?

- ✓ A. Ciliated cells (58%)
- B. Goblet cells (4%)
- ✗ C. Macrophages (32%)
- D. Submucosal glands (0%)
- E. Type I pneumocytes (1%)
- F. Type II pneumocytes (2%)

Incorrect
Correct answer
A

58%
Answered correctly

03 secs
Time Spent

2023
Version

Explanation

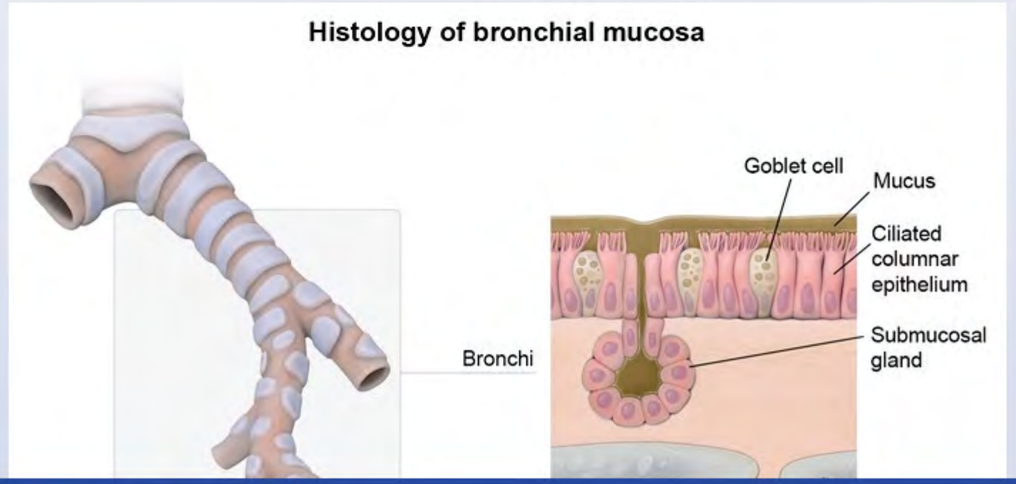

https://t.me/USMLEWorldStep1

A 6-year-old boy playing in a dusty field in windy weather inhales many small particles that become lodged in his
termin

Exhibit Display

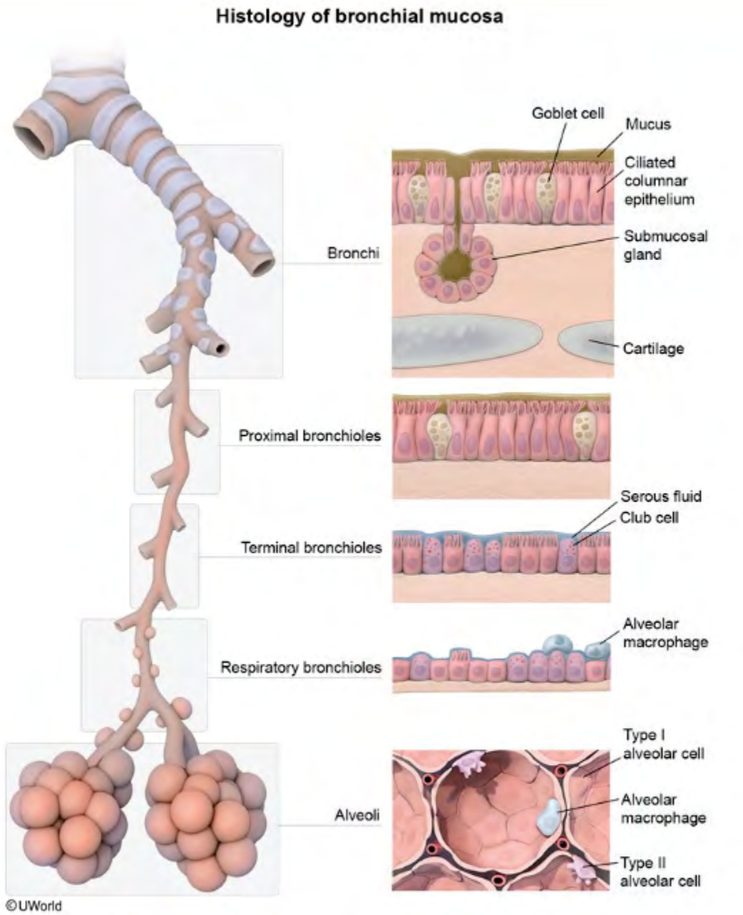

Zoom In | Zoom Out | Reset | New | Existing | My Notebook

Inco
Corre
A

Expl

https://t.me/USMLEWorldStep1

©UWorld

Mucociliary clearance is responsible for removing the vast majority of inhaled particles that lodge within the bronchial tree. **Ciliated mucosal epithelium** lines the pulmonary airways from the trachea to the proximal portions of the respiratory bronchioles. Mucus and fluid secreted onto this epithelial surface act to trap particles suspended in the inspired air. The trapped particles are constantly swept upward from the bronchioles toward the pharynx by cilia that collectively beat in the direction of the pharynx. The mucus and debris are then swallowed or expectorated upon reaching the pharynx.

The **terminal bronchioles** are covered by ciliated cuboidal epithelium and club cells, which help with mucociliary clearance in this region.

(Choice B) Goblet cells are mucus-secreting cells that are interspersed throughout the respiratory mucosa from the trachea down to the larger bronchioles. However, they are not found within the terminal bronchioles. This region is lined by a surfactant-containing fluid secreted by club cells that is continuous with the more proximal mucous layer.

(Choice C) Clearance of particles that lodge distal to the terminal bronchioles is dependent on phagocytosis by alveolar macrophages. These cells can destroy some inhaled particles (eg, bacteria) by lysosomal degradation. Nondigestible material must be transported by macrophages to the pulmonary lymphatics or to the terminal bronchioles (for clearance by the mucociliary system).

(Choice D) Submucosal mucous and mucoserous glands help form the mucous layer in the larger airways. They are found within the trachea and bronchi but not in the bronchioles.

(Choices E and F) Type I and type II pneumocytes line the alveolar ducts and alveoli. Type I pneumocytes are thin cells stretched across the alveolar wall that mediate gas exchange. Type II pneumocytes produce surfactant and divide and differentiate into type I pneumocytes to replace damaged cells.

Educational objective:
Most inhaled particles that lodge in the bronchial tree are removed via proximal transport by ciliated epithelial cells (mucociliary clearance). Mucus-secreting cells are present to the level of the larger bronchioles, after which club cells become the prominent secretory cell type.

https://t.me/USMLEWorldStep1

An 18-month-old boy is brought to the physician by his parents for fever, runny nose, and sore throat. The physician reassures the parents and recommends supportive care with plenty of fluids. He sends them home with instructions to follow up if the boy's symptoms worsen. Two days later, the infant is brought to the emergency department with persistent fever, brassy cough, and difficulty breathing. Physical examination reveals stridor. Which of the following pathogens is most likely responsible for this patient's condition?

- A. Rhinovirus
- B. Paramyxovirus
- C. Togavirus
- D. Parvovirus
- E. Calicivirus

Submit

https://t.me/USMLEWorldStep1

An 18-month-old boy is brought to the physician by his parents for fever, runny nose, and sore throat. The physician reassures the parents and recommends supportive care with plenty of fluids. He sends them home with instructions to follow up if the boy's symptoms worsen. Two days later, the infant is brought to the emergency department with persistent fever, brassy cough, and difficulty breathing. Physical examination reveals stridor. Which of the following pathogens is most likely responsible for this patient's condition?

- A. Rhinovirus (9%)
- ✓ B. Paramyxovirus (81%)
- ✗ C. Togavirus (3%)
- D. Parvovirus (4%)
- E. Calicivirus (1%)

Incorrect
Correct answer
B

81%
Answered correctly

03 secs
Time Spent

2023
Version

Explanation

Important respiratory tract infections in children		
Clinical illness	**Presentation**	**Common etiologic agents**
Nasopharyngitis (common cold)	Nasal congestion & discharge, sneezing, cough & sore throat	• Rhinovirus • Influenza virus • Coronavirus
Laryngotracheitis	Upper respiratory tract symptoms followed by hoarseness, barking cough, stridor & respiratory	• Parainfluenza virus

https://t.me/USMLEWorldStep1

Important respiratory tract infections in children		
Clinical illness	**Presentation**	**Common etiologic agents**
Nasopharyngitis (common cold)	Nasal congestion & discharge, sneezing, cough & sore throat	• Rhinovirus • Influenza virus • Coronavirus
Laryngotracheitis (croup)	Upper respiratory tract symptoms followed by hoarseness, barking cough, stridor & respiratory distress	• Parainfluenza virus
Diphtheria	Sore throat, cervical lymphadenopathy, coalescing pseudomembrane	• *Corynebacterium diphtheriae*
Epiglottitis	Sore throat, dysphagia, drooling & respiratory distress	• *Haemophilus influenzae*
Bronchiolitis	Upper respiratory tract symptoms followed by wheezing, cough & respiratory distress	• Respiratory syncytial virus

This child initially had fever, rhinitis, and pharyngitis, which are symptoms typical of an upper respiratory tract infection (URI). Most URIs (with or without pharyngitis) are caused by viruses, with roughly 15%-30% of childhood cases of pharyngitis and 5%-15% of adulthood cases of pharyngitis caused by bacteria.

When a child with a history of recent URI develops a brassy, barking cough and breathing difficulties, it is likely that acute laryngotracheitis (croup) has developed. The dyspnea associated with croup occurs when inflamed subglottic tissue obstructs the upper airway. The characteristic stridor of croup is a sign of significant upper airway

https://t.me/USMLEWorldStep1

Bronchiolitis	wheezing, cough & respiratory distress	virus

This child initially had fever, rhinitis, and pharyngitis, which are symptoms typical of an upper respiratory tract infection (URI). Most URIs (with or without pharyngitis) are caused by viruses, with roughly 15%-30% of childhood cases of pharyngitis and 5%-15% of adulthood cases of pharyngitis caused by bacteria.

When a child with a history of recent URI develops a brassy, barking cough and breathing difficulties, it is likely that acute laryngotracheitis (croup) has developed. The dyspnea associated with croup occurs when inflamed subglottic tissue obstructs the upper airway. The characteristic stridor of croup is a sign of significant upper airway obstruction. Croup is typically caused by the standard URI viruses, with the parainfluenza viruses (members of *Paramyxoviridae*) most commonly responsible.

(Choice A) Rhinovirus is the most common viral cause of upper respiratory infections but is an uncommon cause of viral croup.

(Choice C) Togaviruses are responsible for rubella (German measles) and Eastern and Western equine encephalitis.

(Choice D) Parvoviruses are responsible for aplastic crises in sickle cell anemia, erythema infectiosum (fifth disease), and hydrops fetalis.

(Choice E) Caliciviruses (Norwalk virus) are responsible for viral gastroenteritis.

Educational objective:
Brassy, barking cough; dyspnea; and recent history of upper respiratory infection in a child are suggestive of viral laryngotracheitis (croup). The most common cause of croup is parainfluenza virus.

Microbiology	Pulmonary & Critical Care	Laryngotracheobronchitis
Subject	System	Topic

Copyright © UWorld. All rights reserved.

https://t.me/USMLEWorldStep1

A 12-year-old boy is brought to the clinic for a follow-up examination. The patient was admitted to the hospital 3 months ago after a nonfatal drowning event that resulted in severe acute respiratory distress syndrome. He was intubated and mechanically ventilated for 1 week and then discharged 2 weeks later. The patient currently feels well and reports mild dyspnea with exertion. Which of the following parameters is most likely increased in this patient compared to a child with normal cardiopulmonary function?

- A. Alveolar-arterial oxygen difference
- B. Diffusion capacity of the lung
- C. Forced vital capacity
- D. Left atrial pressure
- E. Lung compliance

Submit

https://t.me/USMLEWorldStep1

A 12-year-old boy is brought to the clinic for a follow-up examination. The patient was admitted to the hospital 3 months ago after a nonfatal drowning event that resulted in severe acute respiratory distress syndrome. He was intubated and mechanically ventilated for 1 week and then discharged 2 weeks later. The patient currently feels well and reports mild dyspnea with exertion. Which of the following parameters is most likely increased in this patient compared to a child with normal cardiopulmonary function?

- ✓ A. Alveolar-arterial oxygen difference (61%)
- B. Diffusion capacity of the lung (12%)
- C. Forced vital capacity (7%)
- D. Left atrial pressure (5%)
- E. Lung compliance (13%)

Correct | 61% Answered correctly | 03 secs Time Spent | 2023 Version

Explanation

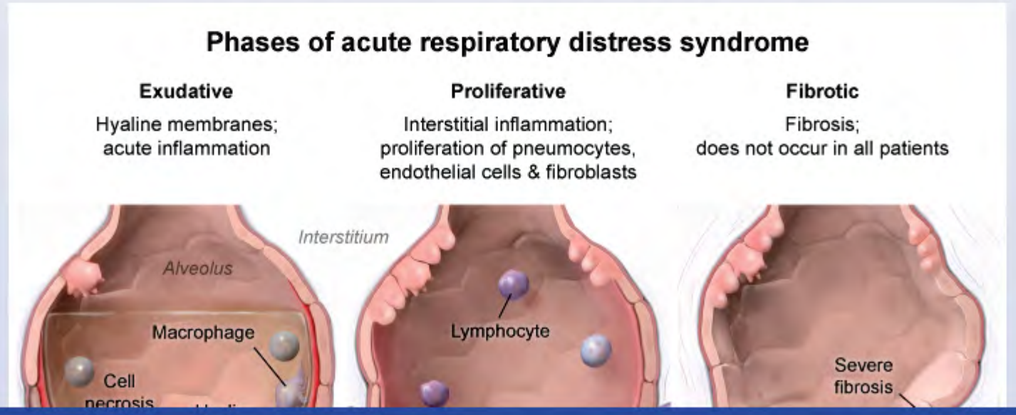

https://t.me/USMLEWorldStep1

A 12-year-old boy is brought to the clinic for a follow-up examination. The patient was admitted to the hospital 3 month
intuba
well ar
patien

Exhibit Display

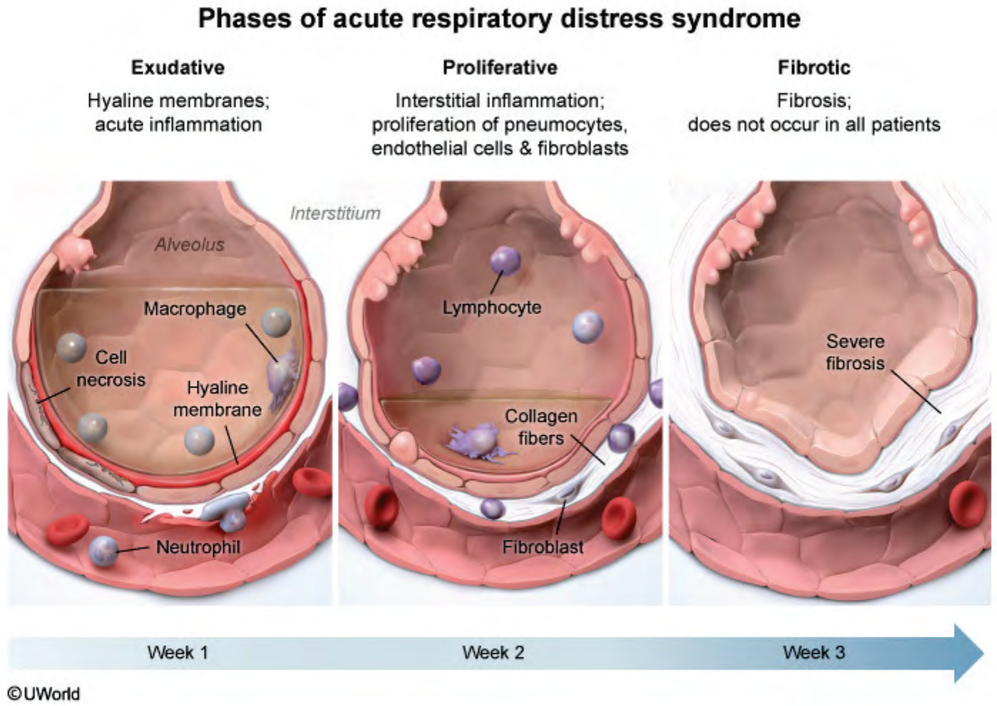

Zoom In | Zoom Out | Reset | New | Existing | My Notebook

https://t.me/USMLEWorldStep1

Acute respiratory distress syndrome (ARDS) refers to inflammatory lung damage triggered by alveolar injury (eg, aspiration of water) or intense systemic inflammation (eg, sepsis, pancreatitis). ARDS has a mortality rate of approximately 40%; those who survive often have **reduced lung function** that persists for months or years and is sometimes permanent.

The pathogenesis of ARDS can progress through 3 phases, although most patients move through only the first 2. The **exudative phase** (phase 1) involves inflammatory disruption of the alveolar-capillary membrane with leakage of protein-rich fluid from the alveolar capillaries into the alveoli and surrounding interstitium. Gas exchange is acutely impaired by alveolar edema and by hyaline membranes that develop on the alveolar surface. After 1-2 weeks, ARDS progresses to the **proliferative phase** (phase 2), during which endothelial cells, pneumocytes, and fibroblasts proliferate in an attempt to repair damage. Collagen is deposited in the interstitium and may lead to scarring.

The majority of ARDS survivors have a persistent **reduction in diffusion capacity** that eventually normalizes after several years **(Choice B)**. These patients may remain in a prolonged proliferative phase in which interstitial collagen deposition and remodeling impair gas diffusion across the alveolar-capillary membrane, causing an **increased alveolar-arterial oxygen gradient** that manifests clinically with mild dyspnea. A small percentage of surviving patients likely enter and remain in the fibrotic phase (phase 3) of ARDS, during which severe interstitial fibrosis develops and manifests as an irreversible reduction in diffusion capacity with marked clinical symptoms (eg, severe dyspnea).

(Choices C and E) Collagen deposition during recovery from ARDS typically leads to decreased lung compliance, which in some patients manifests as a restrictive defect with reductions in both forced vital capacity and forced expiratory volume in 1 second on pulmonary function testing. The reductions in expiratory lung volumes typically normalize within 6 months.

(Choice D) The pulmonary edema in ARDS is noncardiogenic, meaning it does not result from heart failure and involves normal left atrial pressure (estimated by pulmonary capillary wedge pressure) during both the acute disease and recovery.

Educational objective:
Survivors of acute respiratory distress syndrome commonly have reduced lung function that persists for months or

https://t.me/USMLEWorldStep1

sometimes permanent.

The pathogenesis of ARDS can progress through 3 phases, although most patients move through only the first 2. The **exudative phase** (phase 1) involves inflammatory disruption of the alveolar-capillary membrane with leakage of protein-rich fluid from the alveolar capillaries into the alveoli and surrounding interstitium. Gas exchange is acutely impaired by alveolar edema and by hyaline membranes that develop on the alveolar surface. After 1-2 weeks, ARDS progresses to the **proliferative phase** (phase 2), during which endothelial cells, pneumocytes, and fibroblasts proliferate in an attempt to repair damage. Collagen is deposited in the interstitium and may lead to scarring.

The majority of ARDS survivors have a persistent **reduction in diffusion capacity** that eventually normalizes after several years **(Choice B)**. These patients may remain in a prolonged proliferative phase in which interstitial collagen deposition and remodeling impair gas diffusion across the alveolar-capillary membrane, causing an **increased alveolar-arterial oxygen gradient** that manifests clinically with mild dyspnea. A small percentage of surviving patients likely enter and remain in the fibrotic phase (phase 3) of ARDS, during which severe interstitial fibrosis develops and manifests as an irreversible reduction in diffusion capacity with marked clinical symptoms (eg, severe dyspnea).

(Choices C and E) Collagen deposition during recovery from ARDS typically leads to decreased lung compliance, which in some patients manifests as a restrictive defect with reductions in both forced vital capacity and forced expiratory volume in 1 second on pulmonary function testing. The reductions in expiratory lung volumes typically normalize within 6 months.

(Choice D) The pulmonary edema in ARDS is noncardiogenic, meaning it does not result from heart failure and involves normal left atrial pressure (estimated by pulmonary capillary wedge pressure) during both the acute disease and recovery.

Educational objective:
Survivors of acute respiratory distress syndrome commonly have reduced lung function that persists for months or years and is sometimes permanent. The majority of patients have reduced diffusion capacity that eventually normalizes after several years, whereas a small percentage develop extensive fibrosis with a marked and permanent reduction in diffusion capacity.

https://t.me/USMLEWorldStep1

A 6-year-old boy is brought to the office by his mother due to recurrent episodes of sinusitis. He also has a chronic cough that never seems to go away. The mother says that his previous pediatrician performed a "sweat test" to help determine the cause of his frequent infections, but results were normal. DNA testing was inconclusive. Despite these results, the new physician suspects that the patient has an inherited disorder and orders nasal transepithelial potential difference measurements. In this test, an isotonic solution of sodium chloride is applied to the nasal mucosal surface, and the electrical potential overlying the mucosa is compared with that of the interstitial fluid. The results show a transepithelial potential difference that is more negative than normal. This patient's nasal mucosa is most likely to demonstrate which of the following physiologic changes?

- A. Decreased bicarbonate secretion
- B. Increased chloride secretion
- C. Increased mucus water content
- D. Increased sodium absorption
- E. Intracellular potassium depletion

Submit

https://t.me/USMLEWorldStep1

A 6-year-old boy is brought to the office by his mother due to recurrent episodes of sinusitis. He also has a chronic cough that never seems to go away. The mother says that his previous pediatrician performed a "sweat test" to help determine the cause of his frequent infections, but results were normal. DNA testing was inconclusive. Despite these results, the new physician suspects that the patient has an inherited disorder and orders nasal transepithelial potential difference measurements. In this test, an isotonic solution of sodium chloride is applied to the nasal mucosal surface, and the electrical potential overlying the mucosa is compared with that of the interstitial fluid. The results show a transepithelial potential difference that is more negative than normal. This patient's nasal mucosa is most likely to demonstrate which of the following physiologic changes?

- (●) A. Decreased bicarbonate secretion
- ( ) B. Increased chloride secretion
- ( ) C. Increased mucus water content
- ( ) D. Increased sodium absorption
- ( ) E. Intracellular potassium depletion

Submit

https://t.me/USMLEWorldStep1

A 6-year-old boy is brought to the office by his mother due to recurrent episodes of sinusitis. He also has a chronic cough that never seems to go away. The mother says that his previous pediatrician performed a "sweat test" to help determine the cause of his frequent infections, but results were normal. DNA testing was inconclusive. Despite these results, the new physician suspects that the patient has an inherited disorder and orders nasal transepithelial potential difference measurements. In this test, an isotonic solution of sodium chloride is applied to the nasal mucosal surface, and the electrical potential overlying the mucosa is compared with that of the interstitial fluid. The results show a transepithelial potential difference that is more negative than normal. This patient's nasal mucosa is most likely to demonstrate which of the following physiologic changes?

- ✗ A. Decreased bicarbonate secretion (6%)
- B. Increased chloride secretion (38%)
- C. Increased mucus water content (7%)
- ✓ D. Increased sodium absorption (40%)
- E. Intracellular potassium depletion (7%)

Incorrect
Correct answer
D

40%
Answered correctly

19 mins, 26 secs
Time Spent

2023
Version

Explanation

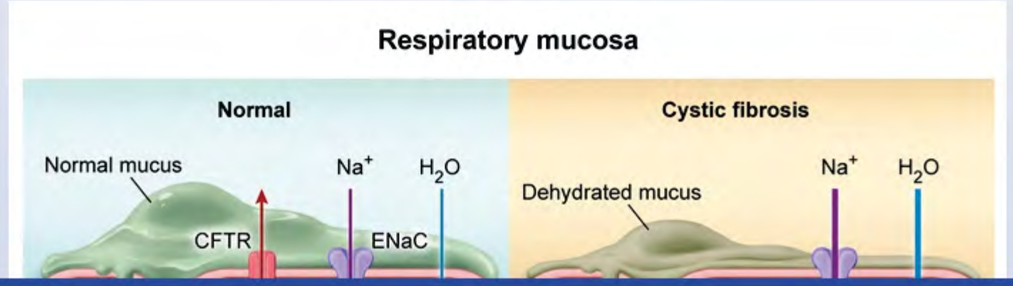

https://t.me/USMLEWorldStep1

fluid. The results show a transepithelial potential difference that is more negative than normal. This patient's nasal

mucos

Exhibit Display

Respiratory mucosa

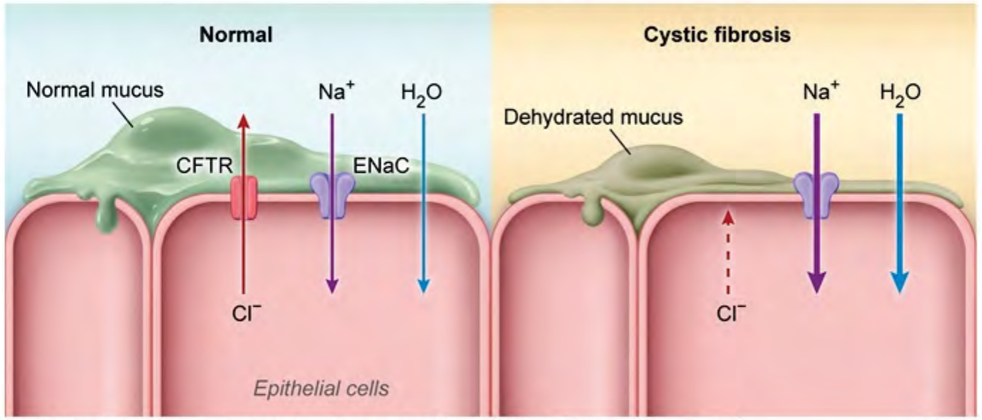

CFTR = cystic fibrosis transmembrane conductance regulator; **ENaC** = epithelial sodium channel. ©UWorld

Zoom In | Zoom Out | Reset | New | Existing | My Notebook

Epithelial cells
CFTR = cystic fibrosis transmembrane conductance regulator; **ENaC** = epithelial sodium channel. ©UWorld

Chronic cough and recurrent sinusitis in a young patient should raise suspicion for **cystic fibrosis** (CF). The

https://t.me/USMLEWorldStep1

CFTR = cystic fibrosis transmembrane conductance regulator; **ENaC** = epithelial sodium channel. ©UWorld

Chronic cough and recurrent sinusitis in a young patient should raise suspicion for **cystic fibrosis** (CF). The diagnosis of CF typically is based on elevated sweat chloride concentrations, characteristic clinical findings (**recurrent sinopulmonary infections**, pancreatic insufficiency), and/or a positive family history. However, patients with mild mutations of the CF transmembrane conductance regulator (*CFTR*) gene may have normal sweat testing. In these cases, a useful diagnostic adjunct involves measuring the nasal transepithelial potential difference.

In intestinal and **respiratory epithelia**, the CFTR channel secretes chloride ions into the lumen and also has a tonic inhibitory effect on the opening of the epithelial sodium channel (ENaC), which decreases sodium reabsorption into the cell. This high luminal salt content helps retain water in the lumen, forming well-hydrated mucus. During the **nasal transepithelial potential difference** test, a saline solution is applied to the nose. Because patients with CF have **increased sodium absorption** via the ENaC, sodium is absorbed intracellularly but chloride in the saline solution is retained in the lumen. The higher relative amounts of negatively charged chloride on the epithelial surface result in a **more negative** transepithelial voltage difference.

CFTR channel functioning is reversed in sweat ducts compared with that in respiratory and intestinal glands. CFTR reduces the salt content of sweat by reabsorbing luminal chloride and stimulating ENaC to increase sodium absorption from the lumen into the cells. *CFTR* mutations therefore result in the production of sweat with high chloride and sodium content.

(Choice A) *CFTR* mutations lower the rate of bicarbonate secretion in the pancreatic ducts, promoting mucin precipitation and the formation of intraductal concretions that cause exocrine pancreatic insufficiency. However, this effect is not related to the nasal transepithelial potential difference test.

(Choice B) *CFTR* mutations impair the passive transport of chloride along its concentration gradient, decreasing chloride secretion by respiratory epithelial cells.

(Choice C) The water content of mucus is decreased (not increased) in patients with CF, resulting in dehydrated mucus that predisposes to the formation of mucus plugs and chronic sinopulmonary infections.

(Choice E) *CFTR* mutations do not significantly alter transmembrane potassium transport.

https://t.me/USMLEWorldStep1

difference.

In intestinal and **respiratory epithelia**, the CFTR channel secretes chloride ions into the lumen and also has a tonic inhibitory effect on the opening of the epithelial sodium channel (ENaC), which decreases sodium reabsorption into the cell. This high luminal salt content helps retain water in the lumen, forming well-hydrated mucus. During the **nasal transepithelial potential difference** test, a saline solution is applied to the nose. Because patients with CF have **increased sodium absorption** via the ENaC, sodium is absorbed intracellularly but chloride in the saline solution is retained in the lumen. The higher relative amounts of negatively charged chloride on the epithelial surface result in a **more negative** transepithelial voltage difference.

CFTR channel functioning is reversed in sweat ducts compared with that in respiratory and intestinal glands. CFTR reduces the salt content of sweat by reabsorbing luminal chloride and stimulating ENaC to increase sodium absorption from the lumen into the cells. *CFTR* mutations therefore result in the production of sweat with high chloride and sodium content.

(Choice A) *CFTR* mutations lower the rate of bicarbonate secretion in the pancreatic ducts, promoting mucin precipitation and the formation of intraductal concretions that cause exocrine pancreatic insufficiency. However, this effect is not related to the nasal transepithelial potential difference test.

(Choice B) *CFTR* mutations impair the passive transport of chloride along its concentration gradient, decreasing chloride secretion by respiratory epithelial cells.

(Choice C) The water content of mucus is decreased (not increased) in patients with CF, resulting in dehydrated mucus that predisposes to the formation of mucus plugs and chronic sinopulmonary infections.

(Choice E) *CFTR* mutations do not significantly alter transmembrane potassium transport.

Educational objective:
In cystic fibrosis, impairment of the cystic fibrosis transmembrane conductance regulator (CFTR) protein reduces chloride secretion and increases sodium absorption by the respiratory epithelia, resulting in dehydrated mucus. When saline is applied to the nasal mucosa, the increased sodium absorption in patients with CF causes a more negative nasal transepithelial potential difference, which can be used to diagnose cystic fibrosis.

References

https://t.me/USMLEWorldStep1

difference.

In intestinal and **respiratory epithelia**, the CFTR channel secretes chloride ions into the lumen and also has a

tonic i

reabso

mucus

Becau

but ch

chloric

CFTR

CFTR

absorp

chloric

(Choi

precip

this ef

(Choi

chloric

(Choi

mucus

(Choi

Educa

In cyst

chloric

When

negati

References

Exhibit Display

Sweat ducts

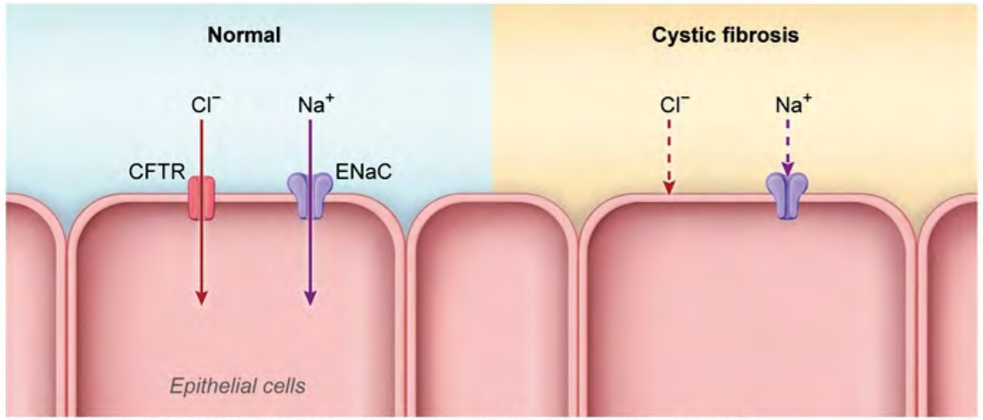

CFTR = cystic fibrosis transmembrane conductance regulator; **ENaC** = epithelial sodium channel. ©UWorld

Zoom In | Zoom Out | Reset | New | Existing | My Notebook

https://t.me/USMLEWorldStep1

Researchers are studying pulmonary gas exchange in various physiological and pathological states using animal models. In one experiment, the partial pressure of oxygen (PO_2) in the upper airways is determined to be 150 mm Hg while breathing ambient air at rest. Analysis of the respiratory gases in a particular lung segment reveals the following:

Alveolar PO_2	104 mm Hg
Pulmonary venous PO_2	70 mm Hg
Pulmonary venous PCO_2	40 mm Hg

Which of the following best explains these respiratory gas findings?

- A. Bronchopulmonary shunting
- B. Diffusion impairment
- C. Normal alveolar ventilation and perfusion
- D. Intrapulmonary shunting
- E. Poor alveolar ventilation

Submit

https://t.me/USMLEWorldStep1

Researchers are studying pulmonary gas exchange in various physiological and pathological states using animal models. In one experiment, the partial pressure of oxygen (PO_2) in the upper airways is determined to be 150 mm Hg while breathing ambient air at rest. Analysis of the respiratory gases in a particular lung segment reveals the following:

Alveolar PO_2	104 mm Hg
Pulmonary venous PO_2	70 mm Hg
Pulmonary venous PCO_2	40 mm Hg

Which of the following best explains these respiratory gas findings?

- ✗ A. Bronchopulmonary shunting (10%)
- ✓ B. Diffusion impairment (43%)
- C. Normal alveolar ventilation and perfusion (26%)
- D. Intrapulmonary shunting (11%)
- E. Poor alveolar ventilation (7%)

Incorrect
Correct answer
B

43%
Answered correctly

03 secs
Time Spent

2023
Version

Explanation

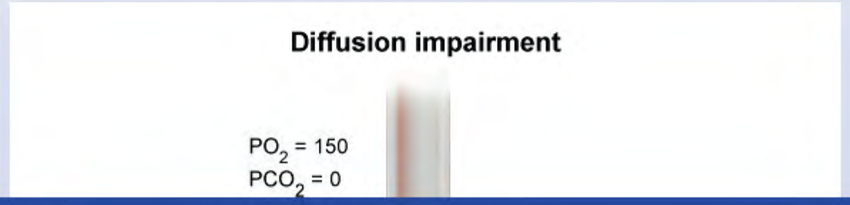

https://t.me/USMLEWorldStep1

Researchers are studying pulmonary gas exchange in various physiological and pathological states using animal
model
Hg wh
followi

Which

Incc
Corre
B

Expl

Exhibit Display

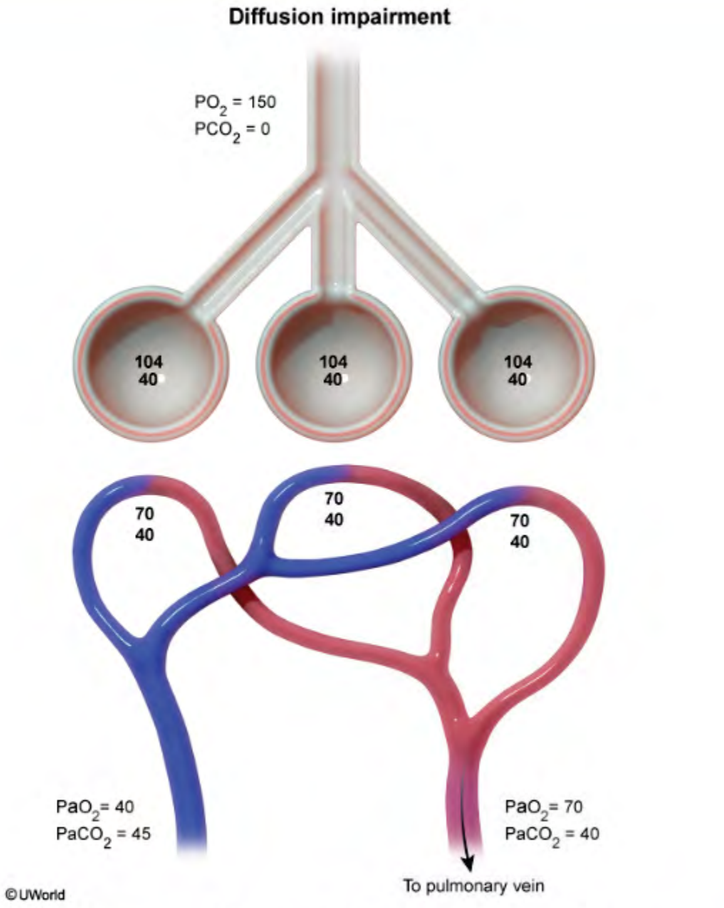

Zoom In Zoom Out Reset New | Existing My Notebook

PO_2 = 150
PCO_2 = 0

https://t.me/USMLEWorldStep1

Exhibit Display

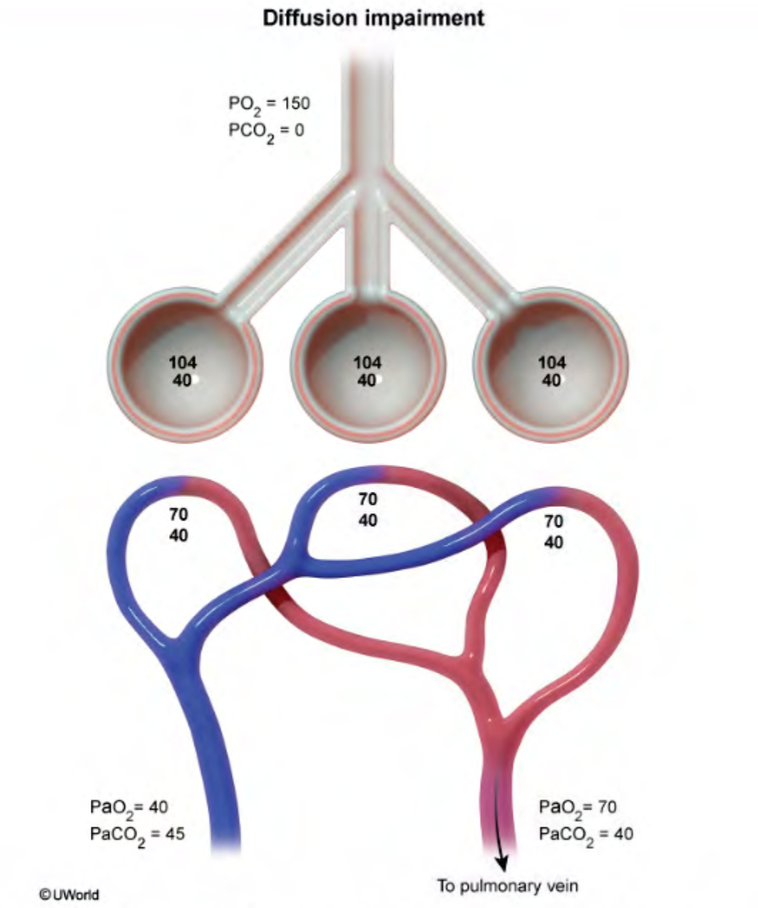

Zoom In | Zoom Out | Reset | New | Existing | My Notebook

Under
approx
mm H
concer
and sy

Transf

resting conditions, diffusion of O_2 and CO_2 is a quick process, with blood needing to traverse only one-third of the

https://t.me/USMLEWorldStep1

Under normal conditions, the PO_2 of inspired ambient air is approximately 160 mm Hg. This value decreases to approximately 150 mm Hg in the trachea due to the partial pressure of water vapor. Normal **alveolar PO_2 is 104 mm Hg**, which lies between the tracheal (150 mm Hg) and systemic venous blood (40 mm Hg) PO_2 concentrations. Likewise, normal **alveolar PCO_2 is 40 mm Hg**, also between its respective tracheal (0 mm Hg) and systemic venous blood concentrations (45 mm Hg).

Transfer of O_2 and CO_2 between the blood and the alveoli depends on both perfusion and diffusion. Under normal resting conditions, diffusion of O_2 and CO_2 is a quick process, with blood needing to traverse only one-third of the total pulmonary capillary length to completely equilibrate. In this setting, gas exchange is perfusion-limited (ie, diffusion is fast enough that the total gas exchange depends only on the amount of blood supplied to the alveoli).

Diffusion-limited gas exchange takes place when diffusion across the alveolar membrane is relatively slow enough to become the major limitation to gas exchange. This can occur with exercise (due to extremely high perfusion volumes that the diffusion rate cannot keep up with) or with pathologic conditions that disrupt the alveolar membrane (eg, pulmonary fibrosis, emphysema) and slow diffusion. **CO_2 diffuses 20 times faster than O_2**, even when the alveolar membrane is somewhat disrupted; therefore, alveolar and capillary CO_2 concentrations typically fully equilibrate while alveolar and capillary O_2 concentrations do not.

In this experiment, there is a **large PO_2 gradient** between the alveoli (104 mm Hg) and the pulmonary venous blood (70 mm Hg) but pulmonary venous **PCO_2 is normal** (40 mm Hg), indicating incomplete gas exchange most likely due to diffusion impairment.

(Choice A) Bronchopulmonary shunting describes the normal small drop in PO_2 and small increase in PCO_2 that occurs due to the pulmonary veins receiving deoxygenated blood from the bronchial circulation. However, this normally only results in about a 4 mm Hg drop in PO_2 within the pulmonary veins.

(Choice C) In normal alveolar ventilation and perfusion, the alveolar and pulmonary capillary PO_2 rapidly reach equilibrium at 104 mm Hg.

(Choice D) Intrapulmonary shunting can occur when the alveoli fill with fluid (eg, pneumonia, pulmonary edema) or collapse (eg, atelectasis) and alveolar ventilation is essentially zero. This patient's alveolar PO_2 of 104 mm Hg is

https://t.me/USMLEWorldStep1

Diffusion-limited gas exchange takes place when diffusion across the alveolar membrane is relatively slow enough to become the major limitation to gas exchange. This can occur with exercise (due to extremely high perfusion volumes that the diffusion rate cannot keep up with) or with pathologic conditions that disrupt the alveolar membrane (eg, pulmonary fibrosis, emphysema) and slow diffusion. **CO_2 diffuses 20 times faster than O_2**, even when the alveolar membrane is somewhat disrupted; therefore, alveolar and capillary CO_2 concentrations typically fully equilibrate while alveolar and capillary O_2 concentrations do not.

In this experiment, there is a **large PO_2 gradient** between the alveoli (104 mm Hg) and the pulmonary venous blood (70 mm Hg) but pulmonary venous **PCO_2 is normal** (40 mm Hg), indicating incomplete gas exchange most likely due to diffusion impairment.

(Choice A) Bronchopulmonary shunting describes the normal small drop in PO_2 and small increase in PCO_2 that occurs due to the pulmonary veins receiving deoxygenated blood from the bronchial circulation. However, this normally only results in about a 4 mm Hg drop in PO_2 within the pulmonary veins.

(Choice C) In normal alveolar ventilation and perfusion, the alveolar and pulmonary capillary PO_2 rapidly reach equilibrium at 104 mm Hg.

(Choice D) Intrapulmonary shunting can occur when the alveoli fill with fluid (eg, pneumonia, pulmonary edema) or collapse (eg, atelectasis) and alveolar ventilation is essentially zero. This patient's alveolar PO_2 of 104 mm Hg is not consistent with shunting (alveolar PO_2 equilibrates with venous blood at 40 mm Hg when ventilation is zero).

(Choice E) Poor alveolar ventilation (ie, hypoventilation) does not affect gas exchange between the alveoli and the blood; therefore, no O_2 gradient is created.

Educational objective:
Gas exchange between the alveoli and pulmonary capillary blood depends on both perfusion and diffusion. The exchange of O_2 and CO_2 in a normal individual at rest is perfusion-limited, so alveolar and capillary partial pressures are equal. Situations in which O_2 exchange becomes diffusion-limited (eg, emphysema, pulmonary fibrosis) cause a large gradient between alveolar and capillary PO_2; PCO_2 is less affected due to the greater diffusing capacity of CO_2.

https://t.me/USMLEWorldStep1

PaO_2= 40

PaO_2= 70

Exhibit Display

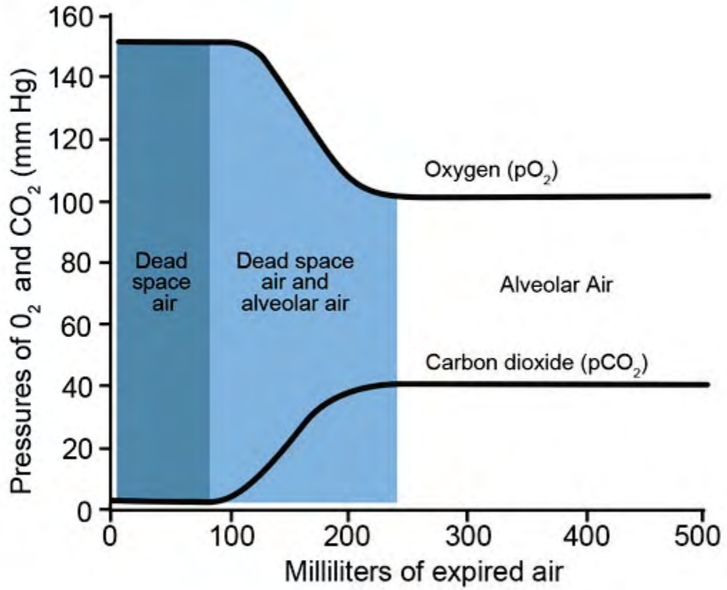

Zoom In | Zoom Out | Reset | New | Existing | My Notebook

Under
approx
mm H
concer
and sy

Transf
resting
total p
diffusi

Diffus
enoug
perfus
memb
when
fully e

In this
blood
likely

(Choi
occurs
norma

(Choice C) In normal alveolar ventilation and perfusion, the alveolar and pulmonary capillary PO_2 rapidly reach

https://t.me/USMLEWorldStep1

PaO_2= 40

PaO_2= 70

Exhibit Display

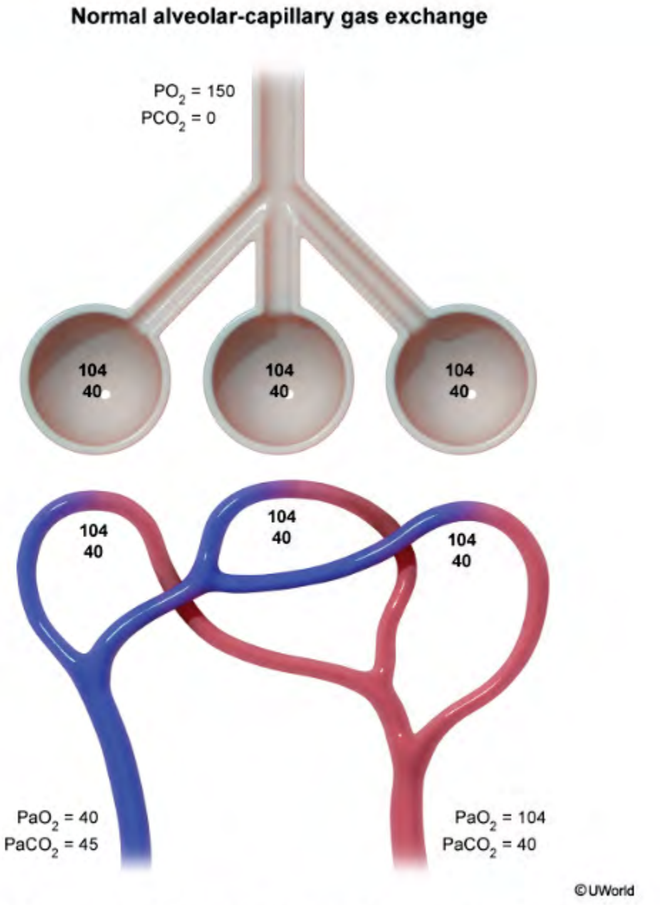

Zoom In | Zoom Out | Reset | New | Existing | My Notebook

Under
approx
mm H
concer
and sy

Transf
resting
total p
diffusi

Diffus
enoug
perfus
memb
when
fully e

In this
blood
likely

(Choi
occurs
norma

(Choice C) In normal alveolar ventilation and perfusion, the alveolar and pulmonary capillary PO_2 rapidly reach

https://t.me/USMLEWorldStep1

Under normal conditions, the PO_2 of inspired ambient air is approximately 160 mm Hg. This value decreases to

approx

mm H

concer

and sy

Transf

resting

total p

diffusi

Diffus

enoug

perfus

memb

when

fully e

In this

blood

likely

(Choi

occurs

norma

(Choi

equilib

(Choi

or collapse (eg, atelectasis) and alveolar ventilation is essentially zero. This patient's alveolar PO_2 of 104 mm Hg is

Exhibit Display

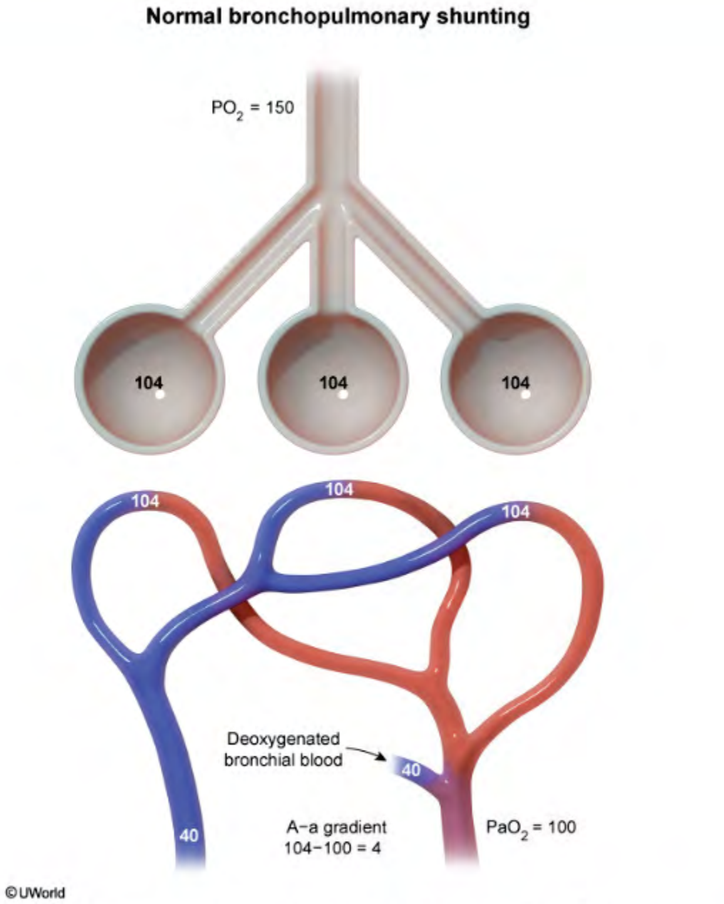

Zoom In | Zoom Out | Reset | New | Existing | My Notebook

https://t.me/USMLEWorldStep1

Transfer of O_2 and CO_2 between the blood and the alveoli depends on both perfusion and diffusion. Under normal resting conditions, diffusion of O_2 and CO_2 is a quick process, with blood needing to traverse only one-third of the total p
diffusi

Diffus
enoug
perfus
memb
when
fully e

In this
blood
likely

(Choi
occurs
norma

(Choi
equilib

(Choi
or coll
not co

(Choi
blood;

Educa
Gas exchange between the alveoli and pulmonary capillary blood depends on both perfusion and diffusion. The exchange of O_2 and CO_2 in a normal individual at rest is perfusion-limited, so alveolar and capillary partial

Exhibit Display

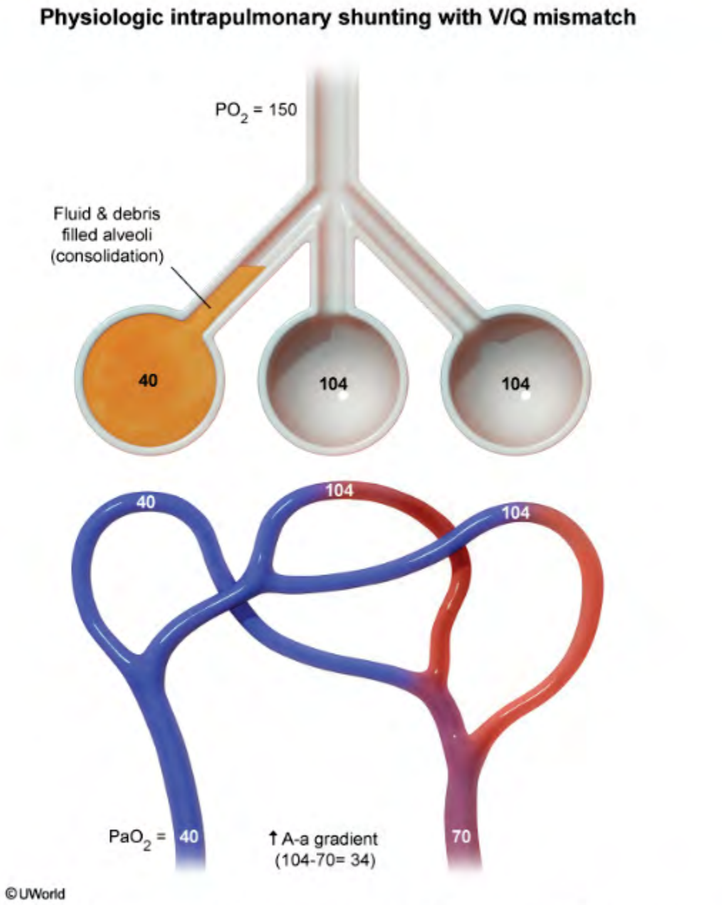

Zoom In | Zoom Out | Reset | New | Existing | My Notebook

https://t.me/USMLEWorldStep1

Diffusion-limited gas exchange takes place when diffusion across the alveolar membrane is relatively slow
enoug
perfus
memb
when
fully e

In this
blood
likely

(Choi
occurs
norma

(Choi
equilib

(Choi
or coll
not co

(Choi
blood;

Educa
Gas e
excha
pressu
fibrosi
diffusing capacity of CO_2.

Exhibit Display

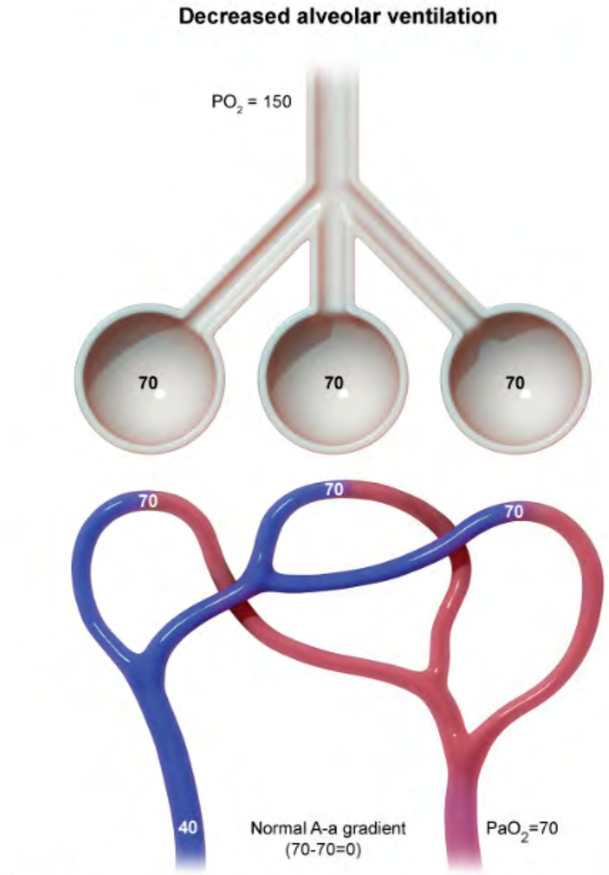

Zoom In | Zoom Out | Reset | New | Existing | My Notebook

https://t.me/USMLEWorldStep1

A 45-year-old man comes to the emergency department due to 2 weeks of chest pain and cough. He has a history of advanced HIV and has taken his antiretroviral medications inconsistently over the past few months. Temperature is 38.1 C (100.6 F). Crackles are heard on pulmonary examination. CD4 cell count is 98/mm^3. Chest x-ray reveals lung nodules and hilar lymphadenopathy. A bronchoscopy is performed. Mucicarmine staining of the patient's bronchoalveolar fluid reveals budding yeast forms with thick capsules. The microorganism responsible for this patient's pulmonary infection most frequently causes which of the following?

- A. Esophagitis
- B. Interstitial pneumonia
- C. Meningoencephalitis
- D. Oral plaques
- E. Sinusitis
- F. Skin infection

Submit

https://t.me/USMLEWorldStep1

A 45-year-old man comes to the emergency department due to 2 weeks of chest pain and cough. He has a history of advanced HIV and has taken his antiretroviral medications inconsistently over the past few months. Temperature is 38.1 C (100.6 F). Crackles are heard on pulmonary examination. CD4 cell count is 98/mm^3. Chest x-ray reveals lung nodules and hilar lymphadenopathy. A bronchoscopy is performed. Mucicarmine staining of the patient's bronchoalveolar fluid reveals budding yeast forms with thick capsules. The microorganism responsible for this patient's pulmonary infection most frequently causes which of the following?

- ✗ A. Esophagitis (2%)
- B. Interstitial pneumonia (24%)
- ✓ C. Meningoencephalitis (56%)
- D. Oral plaques (9%)
- E. Sinusitis (1%)
- F. Skin infection (4%)

Incorrect
Correct answer
C

56%
Answered correctly

04 secs
Time Spent

2023
Version

Explanation

Budding **yeasts** with **thick capsules** that stain with **mucicarmine** are characteristic of ***Cryptococcus neoformans***, which typically affects immunocompromised patients (ie, opportunistic pathogen). *C neoformans* is present in soil and pigeon droppings; it is transmitted by the respiratory route but not acquired via person-to-person contact. Inhaled yeast forms enter the lungs, and in immunocompetent persons, they are cleared by a macrophage response directed by T cells. In individuals with an impaired cellular immune response, *C neoformans* can disseminate and cause **symptomatic** disease, most commonly **meningoencephalitis**.

Cryptococcal meningoencephalitis is typically seen in patients with HIV, sarcoidosis, or leukemia and in those on

https://t.me/USMLEWorldStep1

Budding **yeasts** with **thick capsules** that stain with **mucicarmine** are characteristic of ***Cryptococcus neoformans***, which typically affects immunocompromised patients (ie, opportunistic pathogen). *C neoformans* is present in soil and pigeon droppings; it is transmitted by the respiratory route but not acquired via person-to-person contact. Inhaled yeast forms enter the lungs, and in immunocompetent persons, they are cleared by a macrophage response directed by T cells. In individuals with an impaired cellular immune response, *C neoformans* can disseminate and cause **symptomatic** disease, most commonly **meningoencephalitis**.

Cryptococcal meningoencephalitis is typically seen in patients with HIV, sarcoidosis, or leukemia and in those on high-dose corticosteroid therapy. Headache, nausea, vomiting, and confusion are common symptoms. Diagnosis can be made by examining cerebrospinal fluid (CSF), which shows round, budding, encapsulated yeasts. With India ink staining, the thick polysaccharide capsules classically appear as peripheral clearings or halos. Serologic testing (latex agglutination) is used to detect the C neoformans capsular antigen in CSF.

(Choices A and D) Esophagitis in a patient with HIV is most commonly caused by *Candida* infection; it presents with odynophagia and is diagnosed by endoscopy with biopsy. Oral thrush due to *Candida*, which manifests as white oral plaques, is associated with diabetes mellitus, immunosuppression (eg, HIV), and treatment with antibiotics and corticosteroids.

(Choice B) Although *C neoformans* enters the body through the lungs, pulmonary symptoms are often not prominent. Some patients may develop cough, dyspnea, or pleuritic chest pain, but pulmonary cryptococcosis is a less common manifestation than cryptococcal meningoencephalitis. In contrast, *Pneumocystis jirovecii* is a frequent cause of pneumonia in immunocompromised individuals, but microscopy would show cup- or crescent-shaped organisms (not budding yeast with thick, mucicarmine-positive capsules).

(Choice E) Mucormycosis, which classically affects the paranasal sinuses, occurs in immunocompromised patients and is strongly associated with diabetes mellitus and diabetic ketoacidosis. *Aspergillus fumigatus* is another fungus that may cause sinusitis.

(Choice F) Cutaneous cryptococcal disease (eg, papules, pustules) is rare. Dimorphic fungi *Blastomyces* and *Histoplasma* may cause cutaneous lesions, but the yeast forms do not have mucicarmine-positive capsules.

Educational objective:

https://t.me/USMLEWorldStep1

contact. Inhaled yeast forms enter the lungs, and in immunocompetent persons, they are cleared by a macrophage response directed by T cells. In individuals with an impaired cellular immune response, *C neoformans* can disseminate and cause **symptomatic** disease, most commonly **meningoencephalitis**.

Cryptococcal meningoencephalitis is typically seen in patients with HIV, sarcoidosis, or leukemia and in those on high-dose corticosteroid therapy. Headache, nausea, vomiting, and confusion are common symptoms. Diagnosis can be made by examining cerebrospinal fluid (CSF), which shows round, budding, encapsulated yeasts. With India ink staining, the thick polysaccharide capsules classically appear as peripheral clearings or halos. Serologic testing (latex agglutination) is used to detect the C neoformans capsular antigen in CSF.

(Choices A and D) Esophagitis in a patient with HIV is most commonly caused by *Candida* infection; it presents with odynophagia and is diagnosed by endoscopy with biopsy. Oral thrush due to *Candida*, which manifests as white oral plaques, is associated with diabetes mellitus, immunosuppression (eg, HIV), and treatment with antibiotics and corticosteroids.

(Choice B) Although *C neoformans* enters the body through the lungs, pulmonary symptoms are often not prominent. Some patients may develop cough, dyspnea, or pleuritic chest pain, but pulmonary cryptococcosis is a less common manifestation than cryptococcal meningoencephalitis. In contrast, *Pneumocystis jirovecii* is a frequent cause of pneumonia in immunocompromised individuals, but microscopy would show cup- or crescent-shaped organisms (not budding yeast with thick, mucicarmine-positive capsules).

(Choice E) Mucormycosis, which classically affects the paranasal sinuses, occurs in immunocompromised patients and is strongly associated with diabetes mellitus and diabetic ketoacidosis. *Aspergillus fumigatus* is another fungus that may cause sinusitis.

(Choice F) Cutaneous cryptococcal disease (eg, papules, pustules) is rare. Dimorphic fungi *Blastomyces* and *Histoplasma* may cause cutaneous lesions, but the yeast forms do not have mucicarmine-positive capsules.

Educational objective:
Meningoencephalitis is the most common symptomatic presentation of *Cryptococcus neoformans* infection and typically occurs in immunocompromised patients. Microscopically, *C neoformans* appears as budding yeasts with thick polysaccharide capsules, which can be demonstrated using mucicarmine or India ink staining.

https://t.me/USMLEWorldStep1

Budding **yeasts** with **thick capsules** that stain with **mucicarmine** are characteristic of ***Cryptococcus***

neofo

preser

contac

macro

neofor

Crypto

high-d

can be

India i

testing

(Choi

with o

white

antibio

(Choi

promir

less c

freque

shape

(Choi

patien

anothe

(Choi

Histop

Educational objective:

Exhibit Display

Cryptococcus neoformans

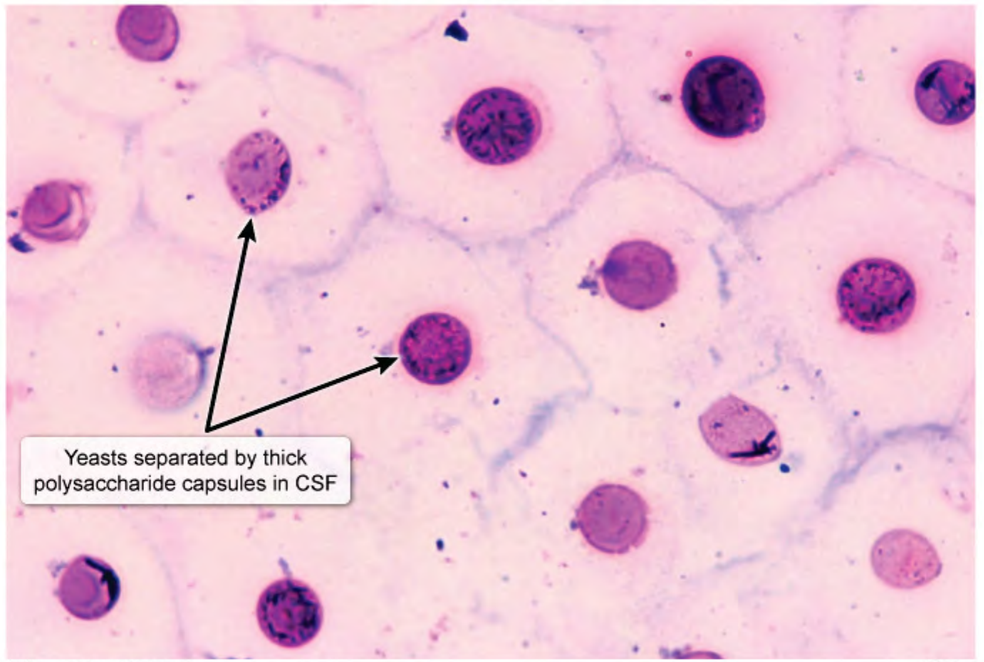

CSF = cerebrospinal fluid.

©UWorld

Zoom In | Zoom Out | Reset | New | Existing | My Notebook

https://t.me/USMLEWorldStep1

Budding **yeasts** with **thick capsules** that stain with **mucicarmine** are characteristic of ***Cryptococcus***

neofo

preser

contac

macro

neofor

Crypto

high-d

can be

India i

testing

(Choi

with o

white

antibio

(Choi

promi

less c

freque

shape

(Choi

patien

anothe

(Choi

Histop

Educational objective:

Exhibit Display

Cryptococcus

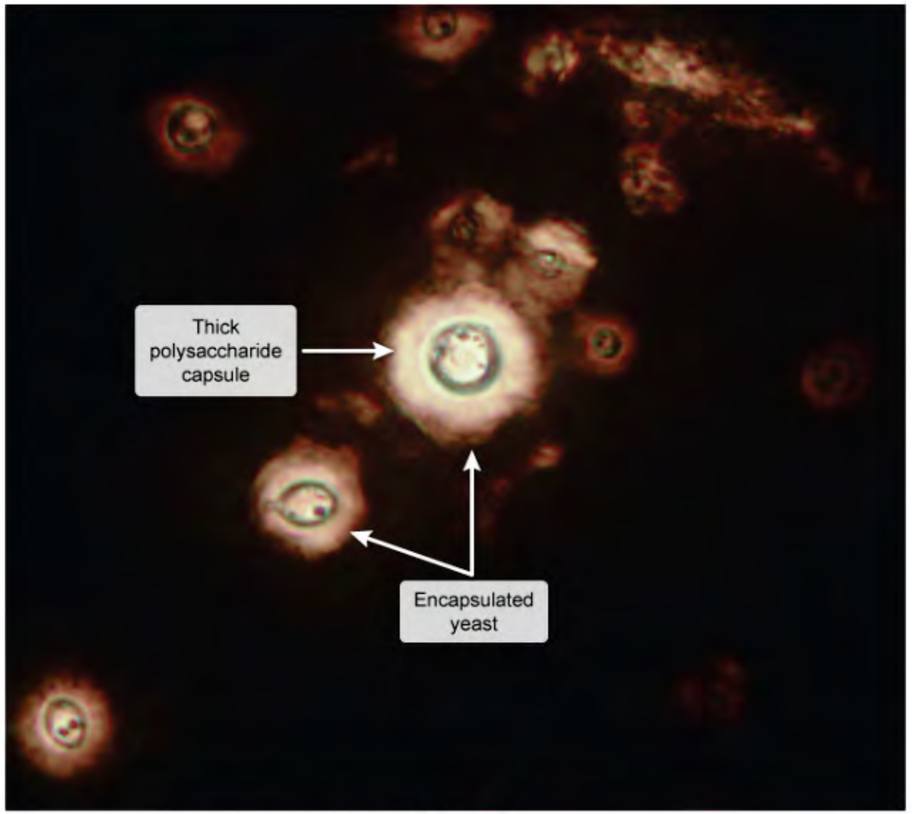

India ink stain

©UWorld

Zoom In | Zoom Out | Reset | New | Existing | My Notebook

https://t.me/USMLEWorldStep1

A 13-year-old girl is admitted for fever, cough, and malaise for the past two days. She has no history of sick contacts and all her immunizations are up to date. Her leukocyte count is 21,000/mm^3 with 7% band forms. Upright chest x-ray findings are shown in the image below:

Which of the following is the most likely location of the pathologic process in this patient?

- A. Left lower lung lobe
- B. Left pleural space
- C. Right middle lung lobe

https://t.me/USMLEWorldStep1

A 13-year-old girl is admitted for fever, cough, and malaise for the past two days. She has no history of sick
contac
Uprigh

Exhibit Display

Zoom In Zoom Out Reset New | Existing My Notebook

Which

C. Right middle lung lobe

https://t.me/USMLEWorldStep1

Which of the following is the most likely location of the pathologic process in this patient?

- A. Left lower lung lobe
- B. Left pleural space
- C. Right middle lung lobe
- D. Right pleural space
- E. Right upper lung lobe

Submit

https://t.me/USMLEWorldStep1

Which of the following is the most likely location of the pathologic process in this patient?

- A. Left lower lung lobe (11%)
- ✗ B. Left pleural space (6%)
- C. Right middle lung lobe (34%)
- D. Right pleural space (2%)
- ✓ E. Right upper lung lobe (45%)

Incorrect
Correct answer
E

45%
Answered correctly

25 secs
Time Spent

2023
Version

https://t.me/USMLEWorldStep1

Incorrect
Correct answer
E

45%
Answered correctly

25 secs
Time Spent

2023
Version

Expl

Exhibit Display

Right upper lobe pneumonia

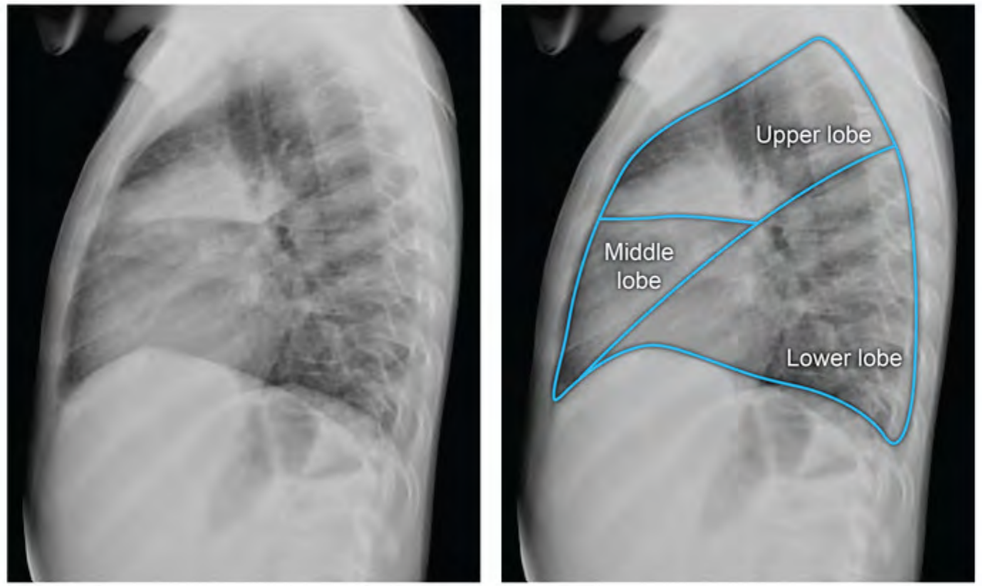

©UWorld

Zoom In | Zoom Out | Reset | New | Existing | My Notebook

This p
that is
substa
border
portion
sharply defined because the consolidation cannot directly spread across the fissure to another lobe.

https://t.me/USMLEWorldStep1

This patient has fever, productive cough, leukocytosis with left shift, and an area of **consolidation** on chest x-ray that is consistent with **lobar pneumonia**. Pulmonary consolidation occurs when the air in alveoli is replaced with a substance (eg, edema, pus, blood, cellular debris) that results in a region of **opacification** on radiographs. The borders of a consolidation tend to be indistinct as the alveoli become more sporadically involved at the peripheral portions of the disease process. However, if the consolidation abuts a fissure (eg, oblique, horizontal), it can be **sharply defined** because the consolidation cannot directly spread across the fissure to another lobe.

This patient's consolidation is sharply defined **inferiorly by the horizontal fissure**, which is present only in the **right lung** and separates the right upper lobe from the right middle lobe. Although multiple radiographic views are usually required for localization of a lung lesion, this patient's findings on lateral radiograph are consistent with **right upper lobe pneumonia**. Other features that can help localize a lobar pneumonia include:

- Right lung
  - Middle lobe consolidation can be sharply defined superiorly by the horizontal fissure and/or sharply defined inferiorly by the oblique fissure **(Choice C)**.
  - Lower lobe consolidation can be sharply defined superiorly by the oblique fissure.
- Left lung
  - Left upper lobe and left lower lobe consolidations can be sharply defined by the oblique fissure but would not be sharply defined by a horizontal fissure because there is no middle lobe in the left lung **(Choice A)**.

(Choices B and D) In an upright chest x-ray, large accumulations of fluid in the pleural space (eg, pleural effusion) can blunt the costophrenic angles and spread across lung fissures to involve the area around more than one lung lobe.

Educational objective:
Pulmonary consolidation is caused by the accumulation of material (eg, fluid, cellular debris) in the alveoli, which can be visualized on radiographs as an area of opacification with indistinct borders. A sharply defined horizontal or oblique line indicates that the consolidation abuts one of the lung fissures. Consolidation that is sharply defined inferiorly by the horizontal fissure is consistent with right upper lobe pneumonia.

Anatomy Pulmonary & Critical Care Lung anatomy

https://t.me/USMLEWorldStep1

This patient has fever, productive cough, leukocytosis with left shift, and an area of **consolidation** on chest x-ray

that is

substa

border

portion

sharp

This p

right l

usuall

right u

- R

- L

(Choi

can bl

lobe.

Educa

Pulmo

can be

obliqu

inferio

Exhibit Display

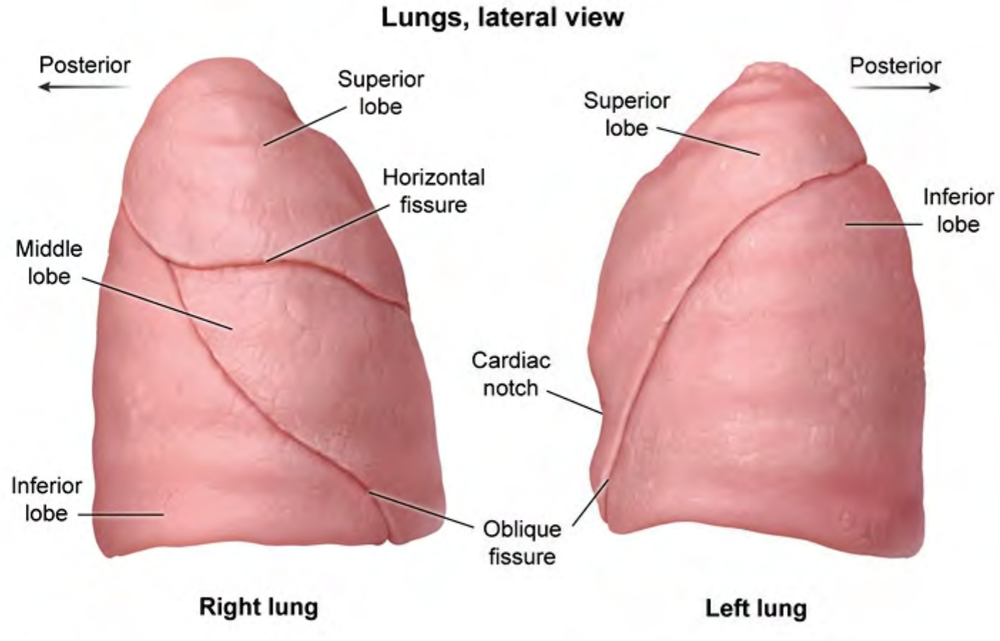

Zoom In | Zoom Out | Reset | New | Existing | My Notebook

Anatomy | Pulmonary & Critical Care | Lung anatomy

https://t.me/USMLEWorldStep1

This patient has fever, productive cough, leukocytosis with left shift, and an area of **consolidation** on chest x-ray that is
substa
border
portion
sharp

This p
right l
usually
right u

- R
- L

(Choic
can bl
lobe.

Educa
Pulmo
can be
obliqu
inferio

Anatomy Pulmonary & Critical Care Lung anatomy

Exhibit Display

Right upper lobe pneumonia

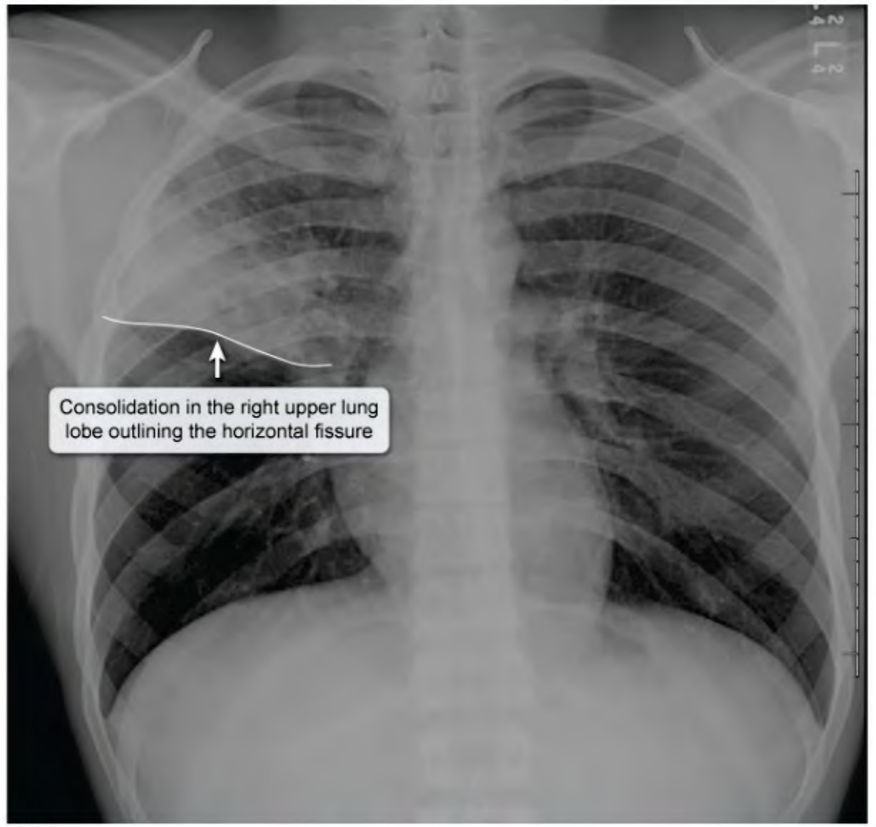

©UWorld

Zoom In Zoom Out Reset New | Existing My Notebook

https://t.me/USMLEWorldStep1

This patient has fever, productive cough, leukocytosis with left shift, and an area of **consolidation** on chest x-ray

that is

substa

border

portion

sharp

This p

right l

usually

right u

- R

- L

(Choi

can bl

lobe.

Educa

Pulmo

can be

obliqu

inferio

Exhibit Display

Right middle lobe pneumonia

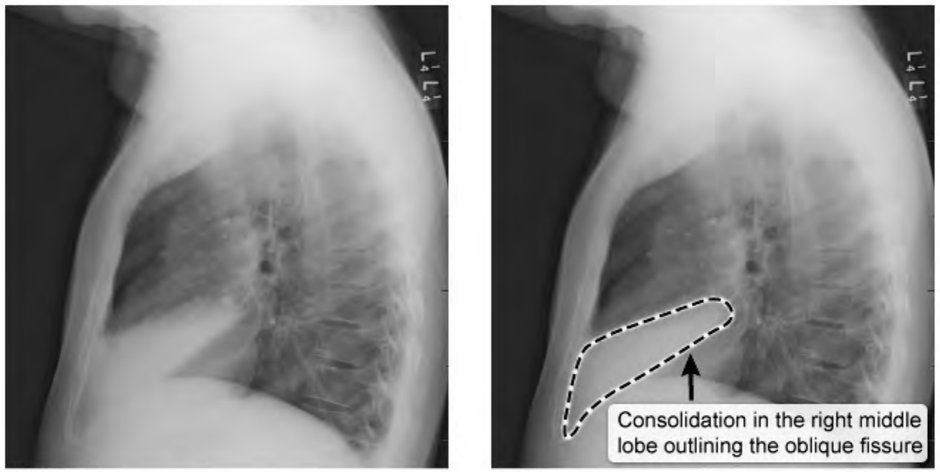

© UWorld

Zoom In | Zoom Out | Reset | New | Existing | My Notebook

Anatomy Pulmonary & Critical Care Lung anatomy

https://t.me/USMLEWorldStep1

This patient has fever, productive cough, leukocytosis with left shift, and an area of **consolidation** on chest x-ray

that is

substa

border

portion

sharp

This p

right l

usuall

right u

- R

- L

(Choi

can bl

lobe.

Educa

Pulmo

can be

obliqu

inferio

Exhibit Display

Unilateral left pleural effusion | Unilateral pleural effusion (secondary to malignancy)

Unilateral pleural effusion

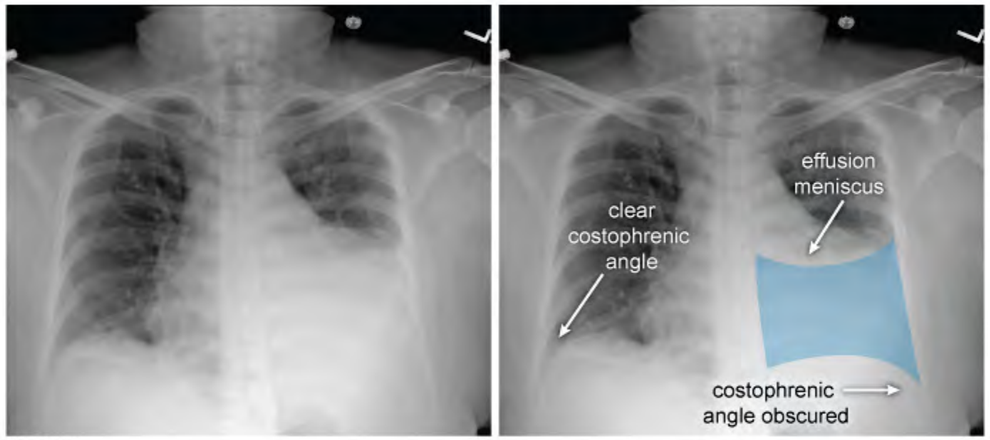

©UWorld

Zoom In | Zoom Out | Reset | New | Existing | My Notebook

Anatomy | Pulmonary & Critical Care | Lung anatomy

https://t.me/USMLEWorldStep1

This patient has fever, productive cough, leukocytosis with left shift, and an area of **consolidation** on chest x-ray

that is

substa

border

portion

sharp

This p

right l

usuall

right u

- R

- L

(Choi

can bl

lobe.

Educa

Pulmo

can be

obliqu

inferio

Exhibit Display

Unilateral left pleural effusion | Unilateral pleural effusion (secondary to malignancy)

Unilateral pleural effusion

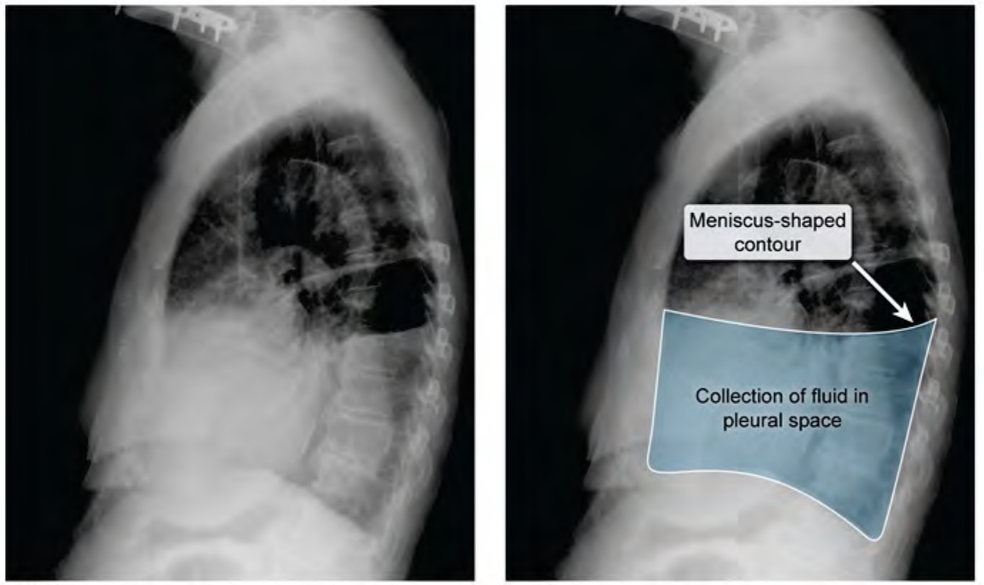

©UWorld

Zoom In | Zoom Out | Reset | New | Existing | My Notebook

Anatomy | Pulmonary & Critical Care | Lung anatomy

https://t.me/USMLEWorldStep1

Researchers develop a novel agent to treat extrinsic asthma. In a clinical trial, patients with moderate to severe asthma treated with this medication experience fewer exacerbations. They are also found to have lower levels of serum IgE, even after exposure to triggering allergens. Analysis of genomic DNA shows reduced IgE isotype switching in activated B lymphocytes. The new medication most likely inhibits which of the following cytokines?

- A. IL-1
- B. IL-3
- C. IL-4
- D. IL-5
- E. Interferon-gamma
- F. Transforming growth factor-beta

Submit

https://t.me/USMLEWorldStep1

Researchers develop a novel agent to treat extrinsic asthma. In a clinical trial, patients with moderate to severe asthma treated with this medication experience fewer exacerbations. They are also found to have lower levels of serum IgE, even after exposure to triggering allergens. Analysis of genomic DNA shows reduced IgE isotype switching in activated B lymphocytes. The new medication most likely inhibits which of the following cytokines?

- A. IL-1 (2%)
- ✗ B. IL-3 (3%)
- ✓ C. IL-4 (67%)
- D. IL-5 (22%)
- E. Interferon-gamma (2%)
- F. Transforming growth factor-beta (1%)

Incorrect
Correct answer
C

67%
Answered correctly

03 secs
Time Spent

2023
Version

Explanation

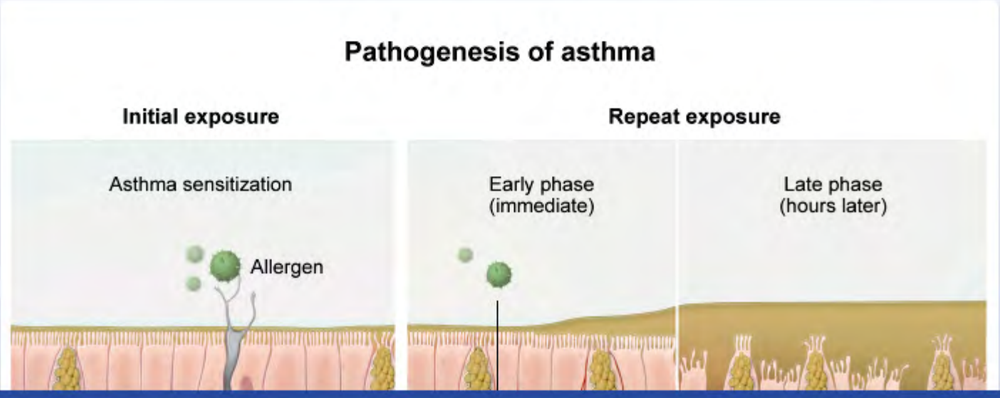

https://t.me/USMLEWorldStep1

Researchers develop a novel agent to treat extrinsic asthma. In a clinical trial, patients with moderate to severe asthm
serum
switch

Exhibit Display

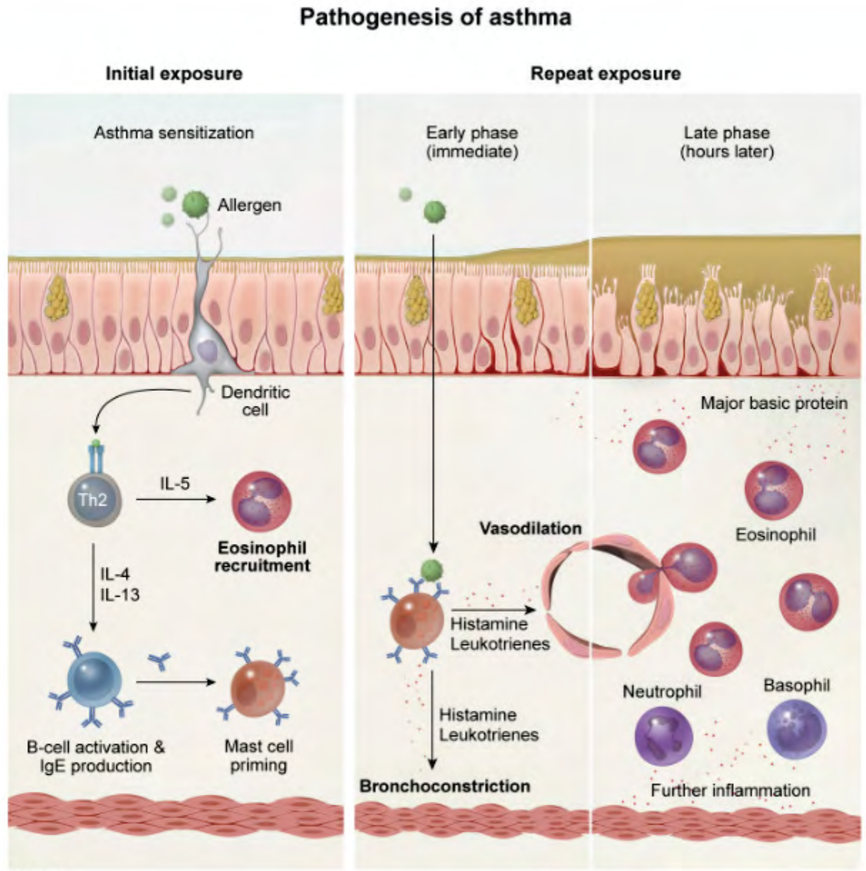

Zoom In | Zoom Out | Reset | New | Existing | My Notebook

https://t.me/USMLEWorldStep1

There are 2 classes of $CD4^+$ T-helper cells, Th1 cells and Th2 cells. Th1 cells contribute to cell-mediated adaptive immunity (targeting intracellular pathogens) and type IV (delayed-type) hypersensitivity reactions. On the other hand, **Th2 cells** play a prominent role in allergic response and **type I hypersensitivity reactions**.

One hypothesis for the **pathogenesis of asthma** is an excess of Th2 cell activity relative to Th1 cell activity, resulting in excessive IgE production, an abnormal propensity for type I hypersensitivity reactions, and associated chronic eosinophilic bronchitis. In the asthma **sensitization phase**, inhaled antigens stimulate Th2 cells to secrete **IL-4** and other lymphokines to stimulate B-cell antibody production as part of humoral adaptive immunity. Th2 cells also release **IL-13**, which, together with IL-4, promotes B-cell immunoglobulin class switching to IgE and leads to mast cell priming.

Repeat exposure to inhaled antigens leads to mast cell degranulation of inflammatory substances (eg, histamine, leukotrienes) and further activation of eosinophils with release of tissue-damaging substances (eg, major basic protein).

(Choice A) IL-1 is predominantly involved in the Th1 response and stimulates fever and acute inflammation. It also induces lymphokine secretion to recruit other leukocytes, including lymphocytes.

(Choice B) IL-3 is secreted by both Th1 and Th2 cells and promotes the growth and differentiation of bone marrow stem cells.

(Choice D) IL-5 is secreted by activated Th2 cells and stimulates the growth and differentiation of eosinophils. However, IL-5 promotes the class switching of B-cell immunoglobulin synthesis to IgA rather than to IgE.

(Choice E) Interferon-gamma secreted by Th1 cells activates macrophages and, along with IL-2, stimulates $CD8^+$ cytotoxic T cells. It also inhibits the differentiation of Th2 cells.

(Choice F) Transforming growth factor-beta (TGF-β) is involved in tissue regeneration and repair. It can be produced by T lymphocytes, platelets, macrophages, endothelial cells, smooth muscle cells, fibroblasts, and keratinocytes.

Educational objective:
An excess of Th2 cell activity relative to Th1 cell activity may underlie the pathogenesis of asthma. In the asthma sensitization phase, inhaled antigens stimulate Th2 cells to secrete IL-4 and IL-13, which together promote B

https://t.me/USMLEWorldStep1

One hypothesis for the **pathogenesis of asthma** is an excess of Th2 cell activity relative to Th1 cell activity, resulting in excessive IgE production, an abnormal propensity for type I hypersensitivity reactions, and associated chronic eosinophilic bronchitis. In the asthma **sensitization phase**, inhaled antigens stimulate Th2 cells to secrete **IL-4** and other lymphokines to stimulate B-cell antibody production as part of humoral adaptive immunity. Th2 cells also release **IL-13**, which, together with IL-4, promotes B-cell immunoglobulin class switching to IgE and leads to mast cell priming.

Repeat exposure to inhaled antigens leads to mast cell degranulation of inflammatory substances (eg, histamine, leukotrienes) and further activation of eosinophils with release of tissue-damaging substances (eg, major basic protein).

(Choice A) IL-1 is predominantly involved in the Th1 response and stimulates fever and acute inflammation. It also induces lymphokine secretion to recruit other leukocytes, including lymphocytes.

(Choice B) IL-3 is secreted by both Th1 and Th2 cells and promotes the growth and differentiation of bone marrow stem cells.

(Choice D) IL-5 is secreted by activated Th2 cells and stimulates the growth and differentiation of eosinophils. However, IL-5 promotes the class switching of B-cell immunoglobulin synthesis to IgA rather than to IgE.

(Choice E) Interferon-gamma secreted by Th1 cells activates macrophages and, along with IL-2, stimulates $CD8^+$ cytotoxic T cells. It also inhibits the differentiation of Th2 cells.

(Choice F) Transforming growth factor-beta (TGF-β) is involved in tissue regeneration and repair. It can be produced by T lymphocytes, platelets, macrophages, endothelial cells, smooth muscle cells, fibroblasts, and keratinocytes.

Educational objective:
An excess of Th2 cell activity relative to Th1 cell activity may underlie the pathogenesis of asthma. In the asthma sensitization phase, inhaled antigens stimulate Th2 cells to secrete IL-4 and IL-13, which together promote B-lymphocyte class switching for IgE synthesis, leading to mast cell priming. Th2 cells also secrete IL-5, which activates eosinophils.

https://t.me/USMLEWorldStep1

A 62-year-old man comes to the emergency department due to sudden-onset of high fever, shaking chills, shortness of breath, and productive cough. The patient has smoked a pack of cigarettes daily for 40 years. Examination shows dullness to percussion over the left side of the chest. Chest x-ray reveals consolidation in the left upper lobe. Gram stain of the sputum shows numerous polymorphonuclear leukocytes and gram-positive cocci in pairs. When cultured on a blood agar plate under aerobic conditions, the bacterial colonies are surrounded by a zone of incomplete hemolysis. The organism responsible for this patient's condition is most likely to exhibit which of the following virulence features?

- A. Inhibition of host protein synthesis
- B. Motility within host tissue
- C. Prevention of phagosome-lysosome fusion
- D. Resistance to phagocytosis
- E. Survival in extreme environments

Submit

https://t.me/USMLEWorldStep1
Show all

A 62-year-old man comes to the emergency department due to sudden-onset of high fever, shaking chills, shortness of breath, and productive cough. The patient has smoked a pack of cigarettes daily for 40 years. Examination shows dullness to percussion over the left side of the chest. Chest x-ray reveals consolidation in the left upper lobe. Gram stain of the sputum shows numerous polymorphonuclear leukocytes and gram-positive cocci in pairs. When cultured on a blood agar plate under aerobic conditions, the bacterial colonies are surrounded by a zone of incomplete hemolysis. The organism responsible for this patient's condition is most likely to exhibit which of the following virulence features?

- ✗ A. Inhibition of host protein synthesis (6%)
- B. Motility within host tissue (2%)
- C. Prevention of phagosome-lysosome fusion (10%)
- ✓ D. Resistance to phagocytosis (76%)
- E. Survival in extreme environments (3%)

Incorrect
Correct answer
D

76%
Answered correctly

05 secs
Time Spent

2023
Version

Explanation

Lobar pneumonia typically presents with acute-onset fever, cough, and lobar consolidation on chest x-ray. Although a number of different bacterial pathogens cause lobar pneumonia (eg, *Haemophilus influenzae*, *Moraxella catarrhalis*, *Staphylococcus aureus*), the most common cause is ***Streptococcus pneumoniae***.

S pneumoniae is a gram-positive diplococci that exhibits partial (α) hemolysis on blood agar (green colonies) and is bile-soluble and Optochin-sensitive. Its major virulence factor is a thick **polysaccharide capsule** that encases the

https://t.me/USMLEWorldStep1
Show all

Lobar pneumonia typically presents with acute-onset fever, cough, and lobar consolidation on chest x-ray. Although a number of different bacterial pathogens cause lobar pneumonia (eg, *Haemophilus influenzae*, *Moraxella catarrhalis*, *Staphylococcus aureus*), the most common cause is ***Streptococcus pneumoniae***.

S pneumoniae is a gram-positive diplococci that exhibits partial (α) hemolysis on blood agar (green colonies) and is bile-soluble and Optochin-sensitive. Its major virulence factor is a thick **polysaccharide capsule** that encases the organism and **prevents phagocytosis** and complement binding. Under the microscope, the capsule swells and appears as a halo around the blue-stained bacterial cells when specific anti-capsular antibodies and methylene blue dye are added ("quellung reaction").

Infection with *S pneumoniae* leads to the generation of anti-capsular antibodies that are protective against future infection with that strain. However, over 90 different antigenic variations (serotypes) of capsular polysaccharides have been identified, so future infection can occur with a strain that has not yet been encountered. Therefore, patients at high risk for invasive pneumococcal disease (eg, HIV, extremes of age) are generally given the pneumococcal **vaccine**, which induces **immunity** against the **most common strains**.

Other virulence factors of *S pneumoniae* include IgA protease (inactivates secretory IgA), adhesins (necessary for adhesion to epithelial cells), and pneumolysin (cytotoxin that causes pores in cell membranes and cell lysis).

(Choice A) Certain bacterial exotoxins (eg, Shiga toxin) enter the host cell and cleave a nucleobase from the host ribosome, thereby inhibiting host protein synthesis. Others (eg, diphtheria toxin) prevent protein elongation. *S pneumoniae* does not directly inhibit host protein synthesis.

(Choice B) Motility within host tissue can be provided by flagella. *S pneumoniae* is a nonmotile organism.

(Choice C) Facultative intracellular bacteria such as *Mycobacterium tuberculosis* and *Listeria monocytogenes* have virulence factors that prevent the bacteria from being destroyed by the phagolysosome of macrophages. *S pneumoniae* is not an intracellular pathogen.

(Choice E) Spores are resistant to chemical disinfectants, irradiation, desiccation, and temperatures as high as

https://t.me/USMLEWorldStep1
Show all

bile-soluble and Optochin-sensitive. Its major virulence factor is a thick **polysaccharide capsule** that encases the organism and **prevents phagocytosis** and complement binding. Under the microscope, the capsule swells and appears as a halo around the blue-stained bacterial cells when specific anti-capsular antibodies and methylene blue dye are added ("quellung reaction").

Infection with *S pneumoniae* leads to the generation of anti-capsular antibodies that are protective against future infection with that strain. However, over 90 different antigenic variations (serotypes) of capsular polysaccharides have been identified, so future infection can occur with a strain that has not yet been encountered. Therefore, patients at high risk for invasive pneumococcal disease (eg, HIV, extremes of age) are generally given the pneumococcal **vaccine**, which induces **immunity** against the **most common strains**.

Other virulence factors of *S pneumoniae* include IgA protease (inactivates secretory IgA), adhesins (necessary for adhesion to epithelial cells), and pneumolysin (cytotoxin that causes pores in cell membranes and cell lysis).

(Choice A) Certain bacterial exotoxins (eg, Shiga toxin) enter the host cell and cleave a nucleobase from the host ribosome, thereby inhibiting host protein synthesis. Others (eg, diphtheria toxin) prevent protein elongation. *S pneumoniae* does not directly inhibit host protein synthesis.

(Choice B) Motility within host tissue can be provided by flagella. *S pneumoniae* is a nonmotile organism.

(Choice C) Facultative intracellular bacteria such as *Mycobacterium tuberculosis* and *Listeria monocytogenes* have virulence factors that prevent the bacteria from being destroyed by the phagolysosome of macrophages. *S pneumoniae* is not an intracellular pathogen.

(Choice E) Spores are resistant to chemical disinfectants, irradiation, desiccation, and temperatures as high as 120 C (248 F). *Bacillus* and *Clostridium* species commonly produce spores, but *S pneumoniae* does not.

Educational objective:
The primary virulence factor of *Streptococcus pneumoniae* is a polysaccharide capsule that inhibits opsonization and phagocytosis. The polysaccharide capsule of the most virulent strains is targeted by the pneumococcal vaccine, which confers immunity against those subtypes.

https://t.me/USMLEWorldStep1
Show all

Explanation

Exhibit Display

Lobar
Althou
Morax

S pne
bile-sc
organi
appea
blue d

Infecti
infecti
have b
patien
pneum

Other
adhes

(Choi
riboso
pneum

(Choi

(Choi
have v
pneumoniae is not an intracellular pathogen.

Microbiologic laboratory identification of streptococci

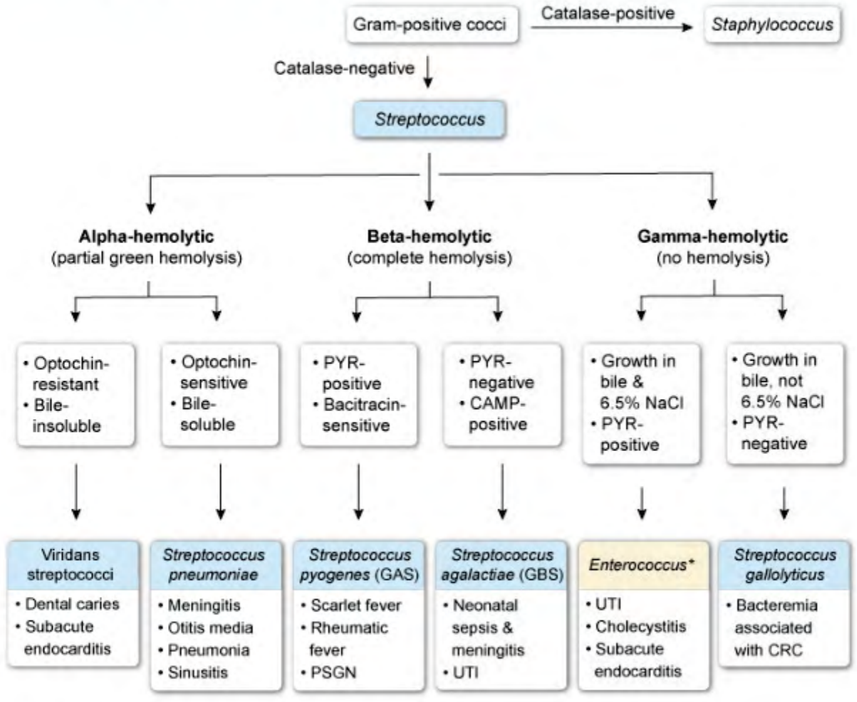

*Formerly group D streptococci

CAMP = Christie, Atkins & Munch-Petersen test; **CRC** = colorectal cancer; **NaCl** = sodium chloride; **PSGN** = poststreptococcal glomerulonephritis; **PYR** = pyrrolidonyl arylamidase; **UTI** = urinary tract infection.

©UWorld

Zoom In Zoom Out Reset New | Existing My Notebook

https://t.me/USMLEWorldStep1

Explanation

Exhibit Display

Streptococcus pneumoniae

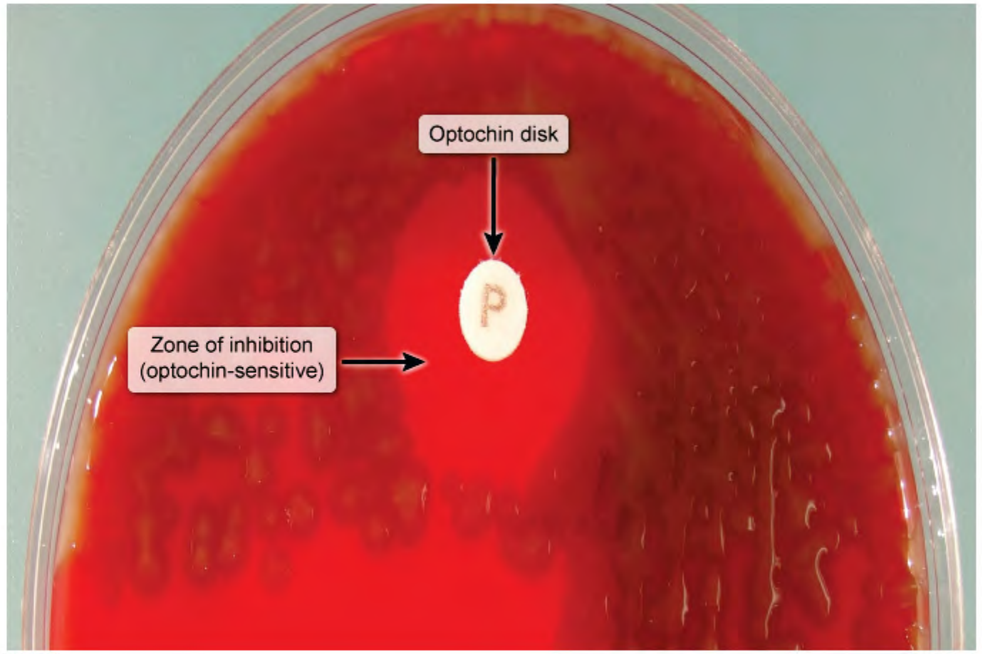

©UWorld

Zoom In | Zoom Out | Reset | New | Existing | My Notebook

Lobar
Althou
Morax

S pne
bile-sc
organi
appea
blue d

Infecti
infecti
have b
patien
pneum

Other
adhes

(Choi
riboso
pneum

(Choi

(Choi
have v
pneumoniae is not an intracellular pathogen.

https://t.me/USMLEWorldStep1

A 64-year-old woman comes to the emergency department with a 4-day history of productive cough and breathlessness. Her medical conditions include polymyalgia rheumatica, for which she takes low-dose prednisone. Physical examination shows dullness to percussion and decreased breath sounds over the right lower lobe. The abdomen is soft, nondistended, and nontender. Chest x-ray shows a right lower lobe parenchymal opacity and a moderate right pleural effusion. Thoracentesis is performed, yielding serosanguinous fluid. Pleural fluid and serum findings are as follows:

	Pleural fluid	Serum
Total protein	4.5 g/dL	6.5 g/dL
Lactate dehydrogenase	40 U/L	60 U/L

Which of the following is contributing most to the pathogenesis of this patient's pleural effusion?

- A. Decreased plasma oncotic pressure
- B. Decreased thoracic lymphatic flow
- C. Increased intraabdominal hydrostatic pressure
- D. Increased intrapleural negative pressure
- E. Increased pleural vascular permeability
- F. Increased thoracic hydrostatic pressure

Submit

https://t.me/USMLEWorldStep1
Show all

A 64-year-old woman comes to the emergency department with a 4-day history of productive cough and breathlessness. Her medical conditions include polymyalgia rheumatica, for which she takes low-dose prednisone. Physical examination shows dullness to percussion and decreased breath sounds over the right lower lobe. The abdomen is soft, nondistended, and nontender. Chest x-ray shows a right lower lobe parenchymal opacity and a moderate right pleural effusion. Thoracentesis is performed, yielding serosanguinous fluid. Pleural fluid and serum findings are as follows:

	Pleural fluid	Serum
Total protein	4.5 g/dL	6.5 g/dL
Lactate dehydrogenase	40 U/L	60 U/L

Which of the following is contributing most to the pathogenesis of this patient's pleural effusion?

- ✗ A. Decreased plasma oncotic pressure (11%)
- B. Decreased thoracic lymphatic flow (8%)
- C. Increased intraabdominal hydrostatic pressure (1%)
- D. Increased intrapleural negative pressure (2%)
- ✓ E. Increased pleural vascular permeability (64%)
- F. Increased thoracic hydrostatic pressure (12%)

Incorrect
Correct answer
E

64%
Answered correctly

04 secs
Time Spent

2023
Version

Explanation

https://t.me/USMLEWorldStep1

Exudative & transudative pleural effusions		
	Exudate	**Transudate**
Light criteria	Pleural protein/serum protein >0.5 **OR** Pleural LDH/serum LDH >0.6 **OR** Pleural LDH greater than two-thirds upper limit of normal of serum LDH	Exudate criteria not met
Pathophysiology	Inflammatory increase in membrane permeability	Change in hydrostatic or oncotic pressure
Common causes	• Infection (eg, pneumonia, TB) • Malignancy • Rheumatologic disease	• Heart failure • Cirrhosis (hepatic hydrothorax) • Nephrotic syndrome
LDH = lactate dehydrogenase; **TB** = tuberculosis.		

Under normal physiologic conditions, **pleural fluid** enters the pleural space from parietal pleural microvessels and is removed by lymphatics at a constant rate. Pathologic states that disrupt pleural capillary hydrostatic or oncotic pressure, decrease pleural space pressure, reduce lymphatic drainage, or increase vascular membrane permeability can lead to **pleural effusion**. Pleural effusions that develop due to **pressure changes** (eg, heart failure, cirrhosis, nephrotic syndrome) are typically **transudative**, whereas those that develop due to **inflammation** and consequent **increased vascular membrane permeability** (eg, infection, malignancy, rheumatologic disease)

https://t.me/USMLEWorldStep1
Show all

Under normal physiologic conditions, **pleural fluid** enters the pleural space from parietal pleural microvessels and is removed by lymphatics at a constant rate. Pathologic states that disrupt pleural capillary hydrostatic or oncotic pressure, decrease pleural space pressure, reduce lymphatic drainage, or increase vascular membrane permeability can lead to **pleural effusion**. Pleural effusions that develop due to **pressure changes** (eg, heart failure, cirrhosis, nephrotic syndrome) are typically **transudative**, whereas those that develop due to **inflammation** and consequent **increased vascular membrane permeability** (eg, infection, malignancy, rheumatologic disease), are typically **exudative**.

The Light criteria are used to differentiate transudative and exudative pleural effusions and aid in the differential diagnosis. Transudative effusions have a low fluid-to-serum ratio of total protein and lactate dehydrogenase and low absolute levels of lactate dehydrogenase. In contrast, **exudative effusions** have a **high fluid-to-serum ratio** of **total protein (>0.5)** or **lactate dehydrogenase (>0.6)** or high absolute levels of lactate dehydrogenase (>2/3 the serum upper limit of normal).

This patient with a pleural fluid-to-serum total protein ratio >0.5 has an exudative effusion likely due to pneumonia (ie, parapneumonic effusion).

(Choice A) Decreased plasma oncotic pressure occurs in conditions that cause hypoalbuminemia (eg, cirrhosis, nephrotic syndrome) and can lead to transudative pleural effusion.

(Choice B) Decreased thoracic lymphatic flow (eg, due to malignant involvement of lymphatic ducts) can cause a chylous effusion (chylothorax). Although this type of effusion is usually exudative by Light criteria, the fluid is typically milky white (rather than serosanguinous) in gross appearance due to high triglyceride (ie, chylomicron) content.

(Choice C) Increased intraabdominal hydrostatic pressure occurs with abdominal ascites that develops due to portal hypertension (eg, cirrhosis). The ascites can be forced into the right-sided pleural cavity through fenestrations in the diaphragm, resulting in a transudative pleural effusion known as hepatic hydrothorax.

(Choice D) Increased intrapleural negative pressure occurs in large-volume atelectasis (lung collapse) and can

https://t.me/USMLEWorldStep1
Show all

low absolute levels of lactate dehydrogenase. In contrast, **exudative effusions** have a **high fluid-to-serum ratio** of **total protein (>0.5)** or **lactate dehydrogenase (>0.6)** or high absolute levels of lactate dehydrogenase (>2/3 the serum upper limit of normal).

This patient with a pleural fluid-to-serum total protein ratio >0.5 has an exudative effusion likely due to pneumonia (ie, parapneumonic effusion).

(Choice A) Decreased plasma oncotic pressure occurs in conditions that cause hypoalbuminemia (eg, cirrhosis, nephrotic syndrome) and can lead to transudative pleural effusion.

(Choice B) Decreased thoracic lymphatic flow (eg, due to malignant involvement of lymphatic ducts) can cause a chylous effusion (chylothorax). Although this type of effusion is usually exudative by Light criteria, the fluid is typically milky white (rather than serosanguinous) in gross appearance due to high triglyceride (ie, chylomicron) content.

(Choice C) Increased intraabdominal hydrostatic pressure occurs with abdominal ascites that develops due to portal hypertension (eg, cirrhosis). The ascites can be forced into the right-sided pleural cavity through fenestrations in the diaphragm, resulting in a transudative pleural effusion known as hepatic hydrothorax.

(Choice D) Increased intrapleural negative pressure occurs in large-volume atelectasis (lung collapse) and can lead to a transudative pleural effusion.

(Choice F) Increased hydrostatic pressure in the pulmonary venous system occurs in heart failure and leads to transudative pleural effusion.

Educational objective:
Transudative effusions are typically caused by alterations in hydrostatic or oncotic pressure (eg, heart failure, cirrhosis, nephrotic syndrome), whereas exudative effusions typically result from inflammation and consequent increased vascular membrane permeability (eg, infection, malignancy, rheumatologic disease). Exudative effusions are characterized by a high ratio of pleural fluid to serum total protein (>0.5) or lactate dehydrogenase (>0.6), or high absolute levels of lactate dehydrogenase.

https://t.me/USMLEWorldStep1
Show all

Light criteria	Pleural LDH/serum LDH >0.6	Exudate criteria not

Exhibit Display

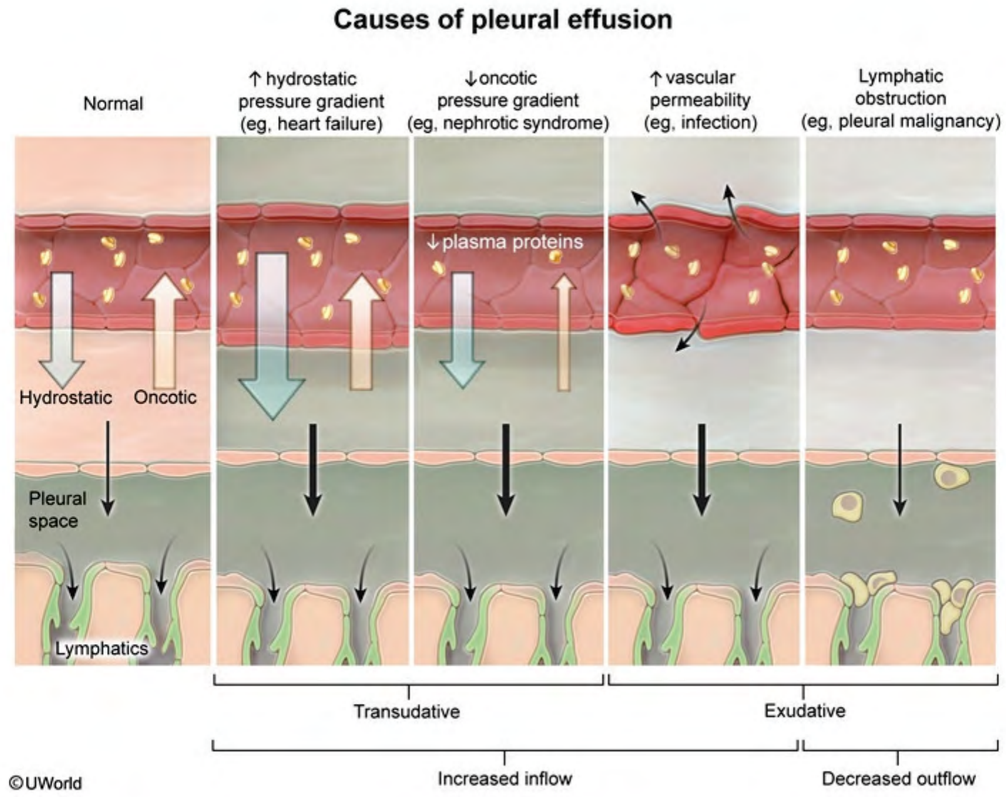

Zoom In | Zoom Out | Reset | New | Existing | My Notebook

Under
is rem
pressu
perme
failure
and co
are typ

The Li
diagno
low ab
of **tota**
the se

https://t.me/USMLEWorldStep1

Show all

A 61-year-old man comes to the office due to worsening cough for the past several months. He initially had a morning cough productive of minimal sputum, but now the cough occurs throughout the day with large amounts of yellowish sputum. The patient also has breathlessness on moderate exertion. He has had 3 hospitalizations over the past year for respiratory infections. The patient has smoked a pack of cigarettes daily for the past 30 years and has had multiple unsuccessful attempts to quit. Oxygen saturation is 88% at rest and decreases to 84% with moderate exertion. Which of the following additional findings is most likely to be seen in this patient?

- A. Decreased functional residual capacity
- B. Decreased right ventricular afterload
- C. Increased erythropoietin production
- D. Increased expiratory flow rates
- E. Increased left ventricular compliance

Submit

https://t.me/USMLEWorldStep1
Show all

A 61-year-old man comes to the office due to worsening cough for the past several months. He initially had a morning cough productive of minimal sputum, but now the cough occurs throughout the day with large amounts of yellowish sputum. The patient also has breathlessness on moderate exertion. He has had 3 hospitalizations over the past year for respiratory infections. The patient has smoked a pack of cigarettes daily for the past 30 years and has had multiple unsuccessful attempts to quit. Oxygen saturation is 88% at rest and decreases to 84% with moderate exertion. Which of the following additional findings is most likely to be seen in this patient?

- ✗ A. Decreased functional residual capacity (18%)
- B. Decreased right ventricular afterload (3%)
- ✓ C. Increased erythropoietin production (69%)
- D. Increased expiratory flow rates (3%)
- E. Increased left ventricular compliance (2%)

Incorrect
Correct answer
C

69%
Answered correctly

04 secs
Time Spent

2023
Version

Explanation

This patient with progressive dyspnea and productive cough in the setting of significant smoking history likely has **chronic obstructive pulmonary disease** (COPD). His recent hospitalizations for respiratory infections likely represent COPD exacerbations.

Hypoxemia (ie, low arterial oxygen saturation) is a common complication of advanced COPD and occurs via 2 major mechanisms:

- Emphysematous destruction of the alveolar walls reduces the pulmonary capillary bed surface area, resulting

https://t.me/USMLEWorldStep1
Show all

This patient with progressive dyspnea and productive cough in the setting of significant smoking history likely has **chronic obstructive pulmonary disease** (COPD). His recent hospitalizations for respiratory infections likely represent COPD exacerbations.

Hypoxemia (ie, low arterial oxygen saturation) is a common complication of advanced COPD and occurs via 2 major mechanisms:

- Emphysematous destruction of the alveolar walls reduces the pulmonary capillary bed surface area, resulting in **decreased diffusing capacity**.
- Airway obstruction (eg, bronchial inflammation, mucus secretion, emphysematous airway collapse) decreases air exchange, resulting in increased **ventilation-perfusion mismatching**.

Persistent tissue hypoxia is sensed by specialized **peritubular fibroblasts** in the renal cortex, which respond by increasing secretion of **erythropoietin** (EPO). This hormone is released into the circulation, where it acts on the bone marrow to increase production of red blood cells, bolstering the oxygen-carrying capacity of the blood. The resulting increase in hematocrit, known as **secondary polycythemia**, is an expected finding in conditions that cause significant chronic hypoxemia (eg, COPD, interstitial lung disease, residence at high altitude).

(Choice A) Air trapping leads to an increase in the functional residual capacity in patients with COPD.

(Choice B) Hypoxic vasoconstriction in advanced COPD increases pulmonary vascular resistance and leads to increased right ventricular afterload.

(Choice D) Airway obstruction in COPD leads to decreased expiratory flow rates. This is apparent as reduced in forced expiratory volume in 1 second.

(Choice E) Left ventricular compliance is increased in conditions that lead to eccentric left ventricular hypertrophy (eg, dilated cardiomyopathy). It is not significantly affected in COPD.

Educational objective:
In response to chronic hypoxemia (eg advanced chronic obstructive pulmonary disease), specialized peritubular fibroblasts in the renal cortex release erythropoietin. This hormone stimulates red blood cell production (ie

https://t.me/USMLEWorldStep1
Show all

Hypoxemia (ie, low arterial oxygen saturation) is a common complication of advanced COPD and occurs via 2 major mechanisms:

- Emphysematous destruction of the alveolar walls reduces the pulmonary capillary bed surface area, resulting in **decreased diffusing capacity**.
- Airway obstruction (eg, bronchial inflammation, mucus secretion, emphysematous airway collapse) decreases air exchange, resulting in increased **ventilation-perfusion mismatching**.

Persistent tissue hypoxia is sensed by specialized **peritubular fibroblasts** in the renal cortex, which respond by increasing secretion of **erythropoietin** (EPO). This hormone is released into the circulation, where it acts on the bone marrow to increase production of red blood cells, bolstering the oxygen-carrying capacity of the blood. The resulting increase in hematocrit, known as **secondary polycythemia**, is an expected finding in conditions that cause significant chronic hypoxemia (eg, COPD, interstitial lung disease, residence at high altitude).

(Choice A) Air trapping leads to an increase in the functional residual capacity in patients with COPD.

(Choice B) Hypoxic vasoconstriction in advanced COPD increases pulmonary vascular resistance and leads to increased right ventricular afterload.

(Choice D) Airway obstruction in COPD leads to decreased expiratory flow rates. This is apparent as reduced in forced expiratory volume in 1 second.

(Choice E) Left ventricular compliance is increased in conditions that lead to eccentric left ventricular hypertrophy (eg, dilated cardiomyopathy). It is not significantly affected in COPD.

Educational objective:
In response to chronic hypoxemia (eg advanced chronic obstructive pulmonary disease), specialized peritubular fibroblasts in the renal cortex release erythropoietin. This hormone stimulates red blood cell production (ie, secondary polycythemia) by the bone marrow, improving the oxygen-carrying capacity of the blood.

Pathophysiology Pulmonary & Critical Care Polycythemia

https://t.me/USMLEWorldStep1
Show all

Expl

Exhibit Display

This p
chron
repres

Hypox
major

- E
  in
- A
  a

Persis
increa
bone r
resulti
cause

(Choi

(Choi
increa

(Choi
forced

(Choice E) Left ventricular compliance is increased in conditions that lead to eccentric left ventricular hypertrophy (eg, dilated cardiomyopathy). It is not significantly affected in COPD.

Hypoxic induction of erythropoiesis

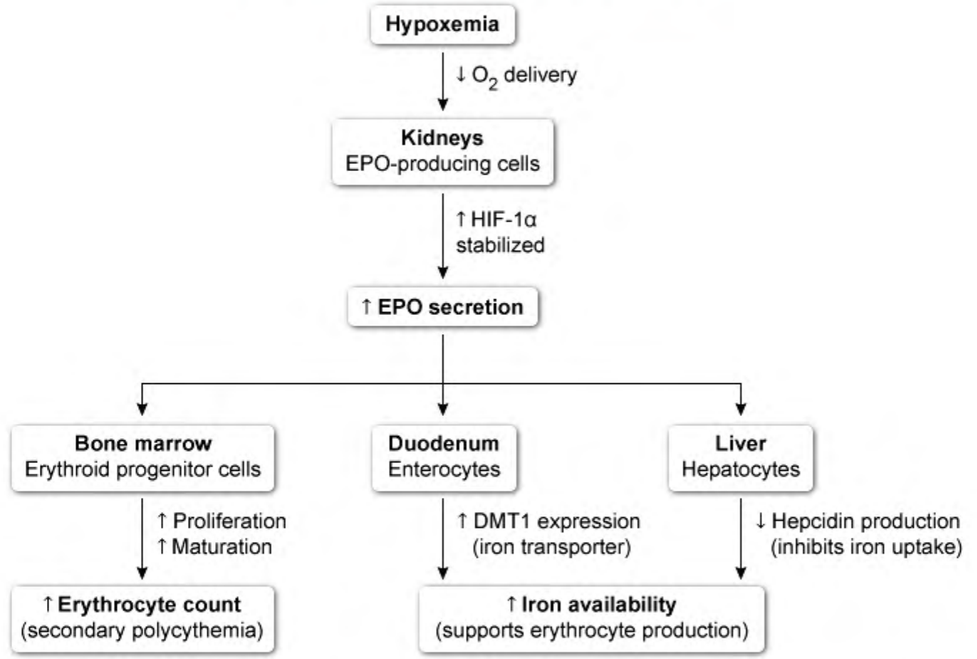

DMT1 = divalent metal transporter 1; **EPO** = erythropoietin; **HIF** = hypoxia-inducible factor.

©UWorld

Zoom In Zoom Out Reset New | Existing My Notebook

https://t.me/USMLEWorldStep1

Show all

Expl

Exhibit Display

This p
chron
repres

Hypox
major

- E
  in
- A
  a

Persis
increa
bone r
resulti
cause

(Choi

(Choi
increa

(Choi
forced

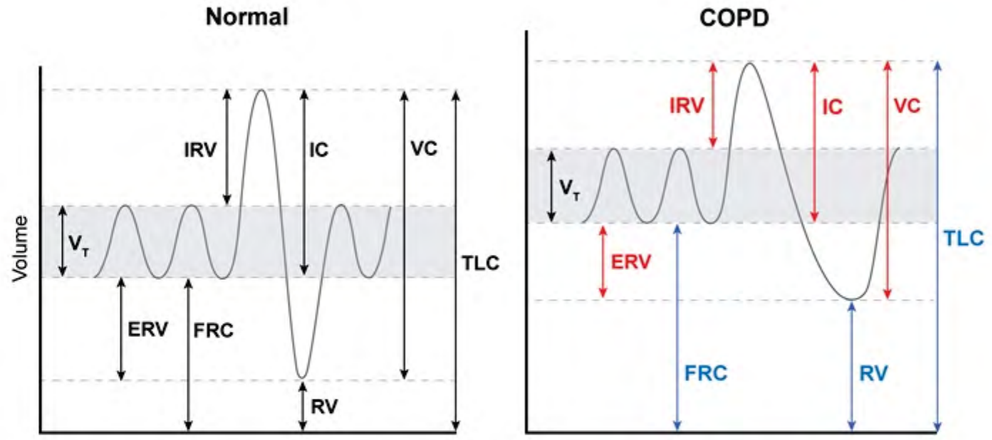

COPD = chronic obstructive pulmonary disease; **ERV** = expiratory reserve volume; **FRC** = functional residual capacity; **IC** = inspiratory capacity; **IRV** = inspiratory reserve volume; **RV** = residual volume; **TLC** = total lung capacity; **VC** = vital capacity; V_T = tidal volume.
©UWorld

Zoom In Zoom Out Reset New | Existing My Notebook

(Choice E) Left ventricular compliance is increased in conditions that lead to eccentric left ventricular hypertrophy (eg, dilated cardiomyopathy). It is not significantly affected in COPD.

https://t.me/USMLEWorldStep1
Show all

Researchers are studying the structure and function of hemoglobin. Arterial and venous blood samples are obtained from enrolled volunteers with no health problems. Red blood cells are isolated from whole blood by differential centrifugation, and the contents of the intact red blood cells are analyzed. It is found that the concentration of chloride is much lower in the red blood cells in the arterial sample compared to the venous sample. The activity of which of the following enzymes is most likely responsible for the observed finding?

- A. Bisphosphoglycerate mutase
- B. Carbonic anhydrase
- C. Glucose-6-phosphate dehydrogenase
- D. Na^+-K^+ ATPase
- E. Pyruvate kinase

Submit

https://t.me/USMLEWorldStep1
Show all

Researchers are studying the structure and function of hemoglobin. Arterial and venous blood samples are obtained from enrolled volunteers with no health problems. Red blood cells are isolated from whole blood by differential centrifugation, and the contents of the intact red blood cells are analyzed. It is found that the concentration of chloride is much lower in the red blood cells in the arterial sample compared to the venous sample. The activity of which of the following enzymes is most likely responsible for the observed finding?

- A. Bisphosphoglycerate mutase (8%)
- ✓ B. Carbonic anhydrase (75%)
- C. Glucose-6-phosphate dehydrogenase (3%)
- D. Na^+-K^+ ATPase (11%)
- E. Pyruvate kinase (1%)

Correct

75% Answered correctly

03 secs Time Spent

2023 Version

Explanation

Red blood cell chloride shifting

https://t.me/USMLEWorldStep1
Show all

Researchers are studying the structure and function of hemoglobin. Arterial and venous blood samples are obtain
differe
concer
sampl

Cor

Expl

Exhibit Display

Red blood cell chloride shifting

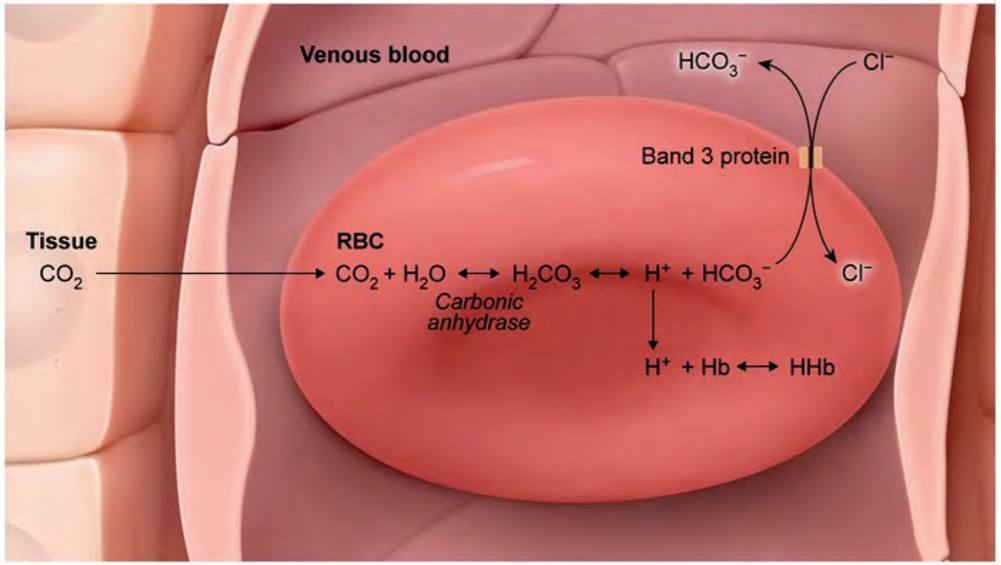

©UWorld

Zoom In | Zoom Out | Reset | New | Existing | My Notebook

Tissue RBC

https://t.me/USMLEWorldStep1

Show all

©UWorld

Hemoglobin is only found within **red blood cells** (RBCs), and it is responsible not only for O_2 delivery to the tissues, but also for carrying CO_2 from the tissues to the lungs. Hemoglobin carries CO_2 in the form of carbaminohemoglobin, which is created as follows:

$$CO_2 + Hb\text{-}NH_3 = 2H^+ + Hb\text{-}NH\text{-}CO_2$$

However, only a small percentage of total blood CO_2 is carried by hemoglobin. The majority of total **blood CO_2** is **carried in the plasma** as **bicarbonate ion (HCO_3^-)** via the following process:

- The CO_2 produced by tissue metabolism enters RBCs and is hydrated by the enzyme **carbonic anhydrase** to form carbonic acid (H_2CO_3).
- H_2CO_3 then undergoes spontaneous conversion to HCO_3^- and H^+.
- The excess HCO_3^- is then transferred out of RBCs into the plasma via **band 3 protein** in exchange for chloride ions (Cl^-) to maintain electrical neutrality. This exchange is known as "**chloride shift**" and is the principal cause of high RBC chloride content in venous blood.

(Choice A) Bisphosphoglycerate (BPG) mutase converts 1,3-BPG to 2,3-BPG. In RBCs, 2,3-BPG combines with hemoglobin to decrease its affinity for O_2 and facilitate O_2 unloading in the tissues.

(Choices C and E) Glucose-6-phosphate dehydrogenase is the first enzyme in the pentose phosphate pathway (produces NADPH) and pyruvate kinase catalyzes the final step of glycolysis (produces ATP). Deficiency of either glucose-6-phosphate dehydrogenase or pyruvate kinase typically leads to shortened RBC lifespan and episodic hemolysis triggered by oxidative stressors.

(Choice D) Na^+/K^+-ATPase is responsible for the maintenance of ionic concentration gradients across the plasma membrane in many cells in the body. This energy-requiring pump is electrogenic as it extrudes 3 sodium ions for every 2 potassium ions that enter the cell, which creates negative intracellular potential.

Educational objective:

https://t.me/USMLEWorldStep1
Show all

carried in the plasma as **bicarbonate ion (HCO_3^-)** via the following process:

- The CO_2 produced by tissue metabolism enters RBCs and is hydrated by the enzyme **carbonic anhydrase** to form carbonic acid (H_2CO_3).
- H_2CO_3 then undergoes spontaneous conversion to HCO_3^- and H^+.
- The excess HCO_3^- is then transferred out of RBCs into the plasma via **band 3 protein** in exchange for chloride ions (Cl^-) to maintain electrical neutrality. This exchange is known as "**chloride shift**" and is the principal cause of high RBC chloride content in venous blood.

(Choice A) Bisphosphoglycerate (BPG) mutase converts 1,3-BPG to 2,3-BPG. In RBCs, 2,3-BPG combines with hemoglobin to decrease its affinity for O_2 and facilitate O_2 unloading in the tissues.

(Choices C and E) Glucose-6-phosphate dehydrogenase is the first enzyme in the pentose phosphate pathway (produces NADPH) and pyruvate kinase catalyzes the final step of glycolysis (produces ATP). Deficiency of either glucose-6-phosphate dehydrogenase or pyruvate kinase typically leads to shortened RBC lifespan and episodic hemolysis triggered by oxidative stressors.

(Choice D) Na^+/K^+-ATPase is responsible for the maintenance of ionic concentration gradients across the plasma membrane in many cells in the body. This energy-requiring pump is electrogenic as it extrudes 3 sodium ions for every 2 potassium ions that enter the cell, which creates negative intracellular potential.

Educational objective:
The majority of CO_2 produced in the tissues is transported to the lungs as bicarbonate ion (HCO_3^-). Within red blood cells (RBCs), the enzyme carbonic anhydrase forms HCO_3^- from CO_2 and water. The excess HCO_3^- is then transferred out of RBCs into the plasma via exchange with chloride ions (Cl^-). This exchange is known as "chloride shift" and is the principal cause of high RBC chloride content in venous blood.

Physiology	Pulmonary & Critical Care	Respiratory physiology
Subject	System	Topic

https://t.me/USMLEWorldStep1
Show all

A 63-year-old man hospitalized for chronic obstructive pulmonary disease exacerbation develops hypercapnic respiratory failure. He is transferred to the intensive care unit, where he undergoes intubation after premedication with muscle relaxant X and an appropriate sedative. The patient is then started on mechanical ventilation; however, he remains apneic longer than expected. Anesthesiology is consulted, and the patient's neuromuscular blockade is assessed by electrically stimulating a peripheral nerve 4 times in quick succession and observing the muscular response. The procedure is repeated 30 minutes later and the results are shown below.

Muscle relaxant X is most likely to be which of the following medications?

- A. Dantrolene
- B. Midazolam
- C. Pancuronium
- D. Succinylcholine
- E. Tubocurarine

Submit

https://t.me/USMLEWorldStep1

A 63-year-old man hospitalized for chronic obstructive pulmonary disease exacerbation develops hypercapnic respira
with m
howev
blocka
muscu

Muscle

Sub

Exhibit Display

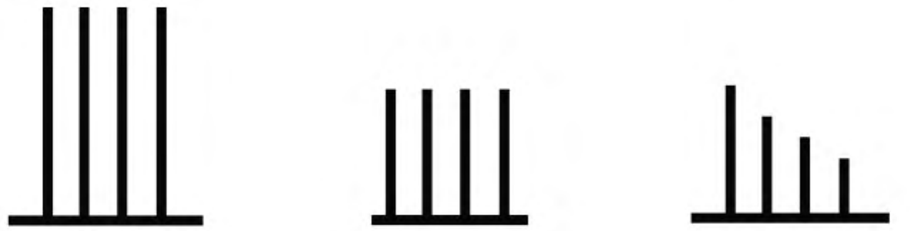

Normal (control) response

Patient's initial response

Patient's response 30 minutes later

©UWorld

Zoom In Zoom Out Reset New | Existing My Notebook

https://t.me/USMLEWorldStep1

A 63-year-old man hospitalized for chronic obstructive pulmonary disease exacerbation develops hypercapnic respiratory failure. He is transferred to the intensive care unit, where he undergoes intubation after premedication with muscle relaxant X and an appropriate sedative. The patient is then started on mechanical ventilation; however, he remains apneic longer than expected. Anesthesiology is consulted, and the patient's neuromuscular blockade is assessed by electrically stimulating a peripheral nerve 4 times in quick succession and observing the muscular response. The procedure is repeated 30 minutes later and the results are shown below.

Muscle relaxant X is most likely to be which of the following medications?

- A. Dantrolene (6%)
- ✕ B. Midazolam (4%)
- C. Pancuronium (10%)
- ✓ D. Succinylcholine (71%)
- E. Tubocurarine (7%)

Incorrect
Correct answer
D

71%
Answered correctly

57 secs
Time Spent

2023
Version

Explanation

https://t.me/USMLEWorldStep1

Neuromuscular monitoring with train-of-four stimulation

Exhibit Display

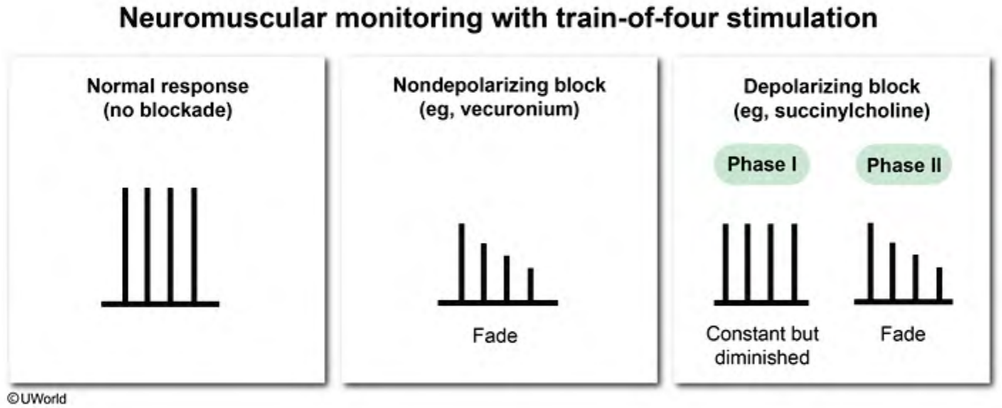

Zoom In Zoom Out Reset New | Existing My Notebook

Train-
neuror
the mu
indicat

When
acetyl
streng
as a re
presyn
functic
stimul
stimul
results
inactiv

Succin
duratic
Howev

succinylcholine more slowly. In these patients, the paralysis can last for **hours** and they must be maintained on

https://t.me/USMLEWorldStep1

Train-of-four (TOF) stimulation is used during anesthesia to assess the degree of paralysis induced by neuromuscular junction (NMJ)-blocking agents. A peripheral nerve is stimulated 4 times in quick succession and the muscular response is recorded. The height of each bar represents the strength of each twitch; higher bars indicate the activation of increasing numbers of individual muscle fibers (myocytes).

When a **nondepolarizing NMJ blocker** (eg, vecuronium) is administered, competitive inhibition of postsynaptic acetylcholine receptors at the motor endplate prevents some of these fibers from activating, decreasing the strength of the twitch. TOF stimulation shows a **progressive reduction** in each of the 4 responses (fading pattern) as a result of less acetylcholine being released with each subsequent impulse (due to the additional effect of presynaptic acetylcholine receptor blockade). In contrast, **depolarizing blockers** (eg, **succinylcholine**) initially function by preventing repolarization of the motor endplate and show **equal reduction** of all 4 twitches during TOF stimulation **(phase I blockade)**. The responses remain equal because the presynaptic acetylcholine receptor stimulation helps to mobilize presynaptic acetylcholine vesicles for release. Persistent exposure to succinylcholine results in eventual transition to **phase II blockade** as the acetylcholine receptors become desensitized and inactivated (ie, functionally similar to nondepolarizing blockade).

Succinylcholine is commonly administered for **rapid-sequence intubation** due to its rapid onset (<1 minute). The duration of action is determined by its metabolism by plasma cholinesterase and is typically <10 minutes. However, some patients are homozygous for an atypical plasma cholinesterase, which breaks down succinylcholine more slowly. In these patients, the paralysis can last for **hours** and they must be maintained on mechanical ventilation until spontaneous respirations resume.

(Choice A) Dantrolene relaxes skeletal muscle by reducing the release of Ca^{2+} from the sarcoplasmic reticulum. Dantrolene is used to treat malignant hyperthermia and neuroleptic malignant syndrome. It is not routinely used as a neuromuscular paralytic agent.

(Choice B) Benzodiazepines are effective for sedation, but they have no direct action at the NMJ and do not provide sufficient muscle paralysis to facilitate intubation.

(Choices C and E) Pancuronium and tubocurarine are nondepolarizing NMJ blockers. Unlike depolarizing NMJ drugs, these agents do not function in distinct phases and their TOF responses always display a fading pattern. Neostigmine administration reverses nondepolarizing NMJ blockade.

https://t.me/USMLEWorldStep1

strength of the twitch. TOF stimulation shows a **progressive reduction** in each of the 4 responses (fading pattern) as a result of less acetylcholine being released with each subsequent impulse (due to the additional effect of presynaptic acetylcholine receptor blockade). In contrast, **depolarizing blockers** (eg, **succinylcholine**) initially function by preventing repolarization of the motor endplate and show **equal reduction** of all 4 twitches during TOF stimulation **(phase I blockade)**. The responses remain equal because the presynaptic acetylcholine receptor stimulation helps to mobilize presynaptic acetylcholine vesicles for release. Persistent exposure to succinylcholine results in eventual transition to **phase II blockade** as the acetylcholine receptors become desensitized and inactivated (ie, functionally similar to nondepolarizing blockade).

Succinylcholine is commonly administered for **rapid-sequence intubation** due to its rapid onset (<1 minute). The duration of action is determined by its metabolism by plasma cholinesterase and is typically <10 minutes. However, some patients are homozygous for an atypical plasma cholinesterase, which breaks down succinylcholine more slowly. In these patients, the paralysis can last for **hours** and they must be maintained on mechanical ventilation until spontaneous respirations resume.

(Choice A) Dantrolene relaxes skeletal muscle by reducing the release of Ca^{2+} from the sarcoplasmic reticulum. Dantrolene is used to treat malignant hyperthermia and neuroleptic malignant syndrome. It is not routinely used as a neuromuscular paralytic agent.

(Choice B) Benzodiazepines are effective for sedation, but they have no direct action at the NMJ and do not provide sufficient muscle paralysis to facilitate intubation.

(Choices C and E) Pancuronium and tubocurarine are nondepolarizing NMJ blockers. Unlike depolarizing NMJ drugs, these agents do not function in distinct phases and their TOF responses always display a fading pattern. Neostigmine administration reverses nondepolarizing NMJ blockade.

Educational objective:
Succinylcholine is a fast-acting, depolarizing neuromuscular blocking agent used for rapid-sequence intubation that causes equal reduction of all 4 twitches during train-of-four stimulation (phase I blockade). Prolonged administration of succinylcholine or use in patients with abnormal plasma cholinesterase activity causes transition to a phase II (nondepolarizing) block, seen as a progressive reduction in each of the 4 twitches.

https://t.me/USMLEWorldStep1

A 45-year-old man comes to the urgent care clinic because of fever, severe headache, myalgia, and pleuritic chest pain. He has had these symptoms for several days. Physical examination shows fever and mild tachycardia. Lung auscultation reveals mild crackles. Radiographic examination is consistent with segmental pulmonary infiltrates. The patient fails to respond to empiric antibacterial antibiotic therapy. Microscopic examination of lung tissue obtained from this patient shows spherules packed with endospores. This patient's history is most likely to reveal which of the following?

- A. Recent travel to Arizona
- B. Exposure to pigeon droppings
- C. Cave exploration in Ohio
- D. Previous cavitary tuberculosis
- E. Chemotherapy for leukemia
- F. Long history of asthma

Submit

https://t.me/USMLEWorldStep1

A 45-year-old man comes to the urgent care clinic because of fever, severe headache, myalgia, and pleuritic chest pain. He has had these symptoms for several days. Physical examination shows fever and mild tachycardia. Lung auscultation reveals mild crackles. Radiographic examination is consistent with segmental pulmonary infiltrates. The patient fails to respond to empiric antibacterial antibiotic therapy. Microscopic examination of lung tissue obtained from this patient shows spherules packed with endospores. This patient's history is most likely to reveal which of the following?

- ✓ A. Recent travel to Arizona (69%)
- B. Exposure to pigeon droppings (10%)
- C. Cave exploration in Ohio (15%)
- D. Previous cavitary tuberculosis (1%)
- E. Chemotherapy for leukemia (2%)
- F. Long history of asthma (0%)

Correct

69% Answered correctly

04 secs Time Spent

2023 Version

Explanation

Coccidioides immitis is a dimorphic fungus that has a mold form (hyphae) at 25° C–30° C and an endospore form (spherules containing endospores, a unique characteristic of *Coccidioides*) at body temperature (37° C–40° C). *C. immitis* is endemic to the southwestern United States (i.e., southern and central California, Arizona, New Mexico, and western Texas), northern Mexico, and some regions of Central and South America. Patients with coccidioidomycosis are likely to live in or have recently traveled to an endemic area.

C. immitis is transmitted by spore inhalation. Spores are formed by fragmentation of hyphae. Once inside the lungs, the spores turn into spherules that contain endospores. The spherules subsequently rupture and release

https://t.me/USMLEWorldStep1

Coccidioides immitis is a dimorphic fungus that has a mold form (hyphae) at 25° C–30° C and an endospore form (spherules containing endospores, a unique characteristic of *Coccidioides*) at body temperature (37° C–40° C). *C. immitis* is endemic to the southwestern United States (i.e., southern and central California, Arizona, New Mexico, and western Texas), northern Mexico, and some regions of Central and South America. Patients with coccidioidomycosis are likely to live in or have recently traveled to an endemic area.

C. immitis is transmitted by spore inhalation. Spores are formed by fragmentation of hyphae. Once inside the lungs, the spores turn into spherules that contain endospores. The spherules subsequently rupture and release endospores that disseminate to other organs and tissues. Each endospore is capable of forming a new spherule.

In immunocompetent hosts, *C. immitis* causes lung disease, which can be asymptomatic or cause flu-like symptoms (e.g., cough, fever, and myalgia) accompanied by erythema nodosum. In total, *C. immitis* can present in five ways: acute pneumonia (most common), chronic progressive pneumonia, pulmonary nodules and cavities, extrapulmonary nonmeningeal disease, and meningitis. The more severe manifestations are largely reserved for immunocompromised hosts.

(Choice B) The yeast form of *Cryptococcus neoformans* is present in pigeon droppings. This fungus causes pulmonary disease and meningoencephalitis in immunocompromised patients.

(Choice C) *Histoplasma capsulatum* is endemic to the Mississippi and Ohio River basins and found in bird and bat droppings. Patients with histoplasmosis often have a history of cleaning bird coops or caving.

(Choice D) *Aspergillus fumigatus* can colonize old lung cavities (e.g., those formed by tuberculosis) to form a "fungal ball" (i.e., aspergilloma). Symptoms include cough, dyspnea, and hemoptysis.

(Choice E) Neutropenic patients are at high risk for developing opportunistic mycoses. *Candida albicans*, *A. fumigatus*, *Mucor,* and *Rhizopus* species can cause severe disease in this population.

(Choice F) Patients with asthma are at risk for developing an allergic reaction to *A. fumigatus* called allergic bronchopulmonary aspergillosis. Signs and symptoms include cough, dyspnea, wheezing, fever, and migratory pulmonary infiltrates.

Educational objective:

https://t.me/USMLEWorldStep1

immitis is endemic to the southwestern United States (i.e., southern and central California, Arizona, New Mexico, and western Texas), northern Mexico, and some regions of Central and South America. Patients with coccidioidomycosis are likely to live in or have recently traveled to an endemic area.

C. immitis is transmitted by spore inhalation. Spores are formed by fragmentation of hyphae. Once inside the lungs, the spores turn into spherules that contain endospores. The spherules subsequently rupture and release endospores that disseminate to other organs and tissues. Each endospore is capable of forming a new spherule.

In immunocompetent hosts, *C. immitis* causes lung disease, which can be asymptomatic or cause flu-like symptoms (e.g., cough, fever, and myalgia) accompanied by erythema nodosum. In total, *C. immitis* can present in five ways: acute pneumonia (most common), chronic progressive pneumonia, pulmonary nodules and cavities, extrapulmonary nonmeningeal disease, and meningitis. The more severe manifestations are largely reserved for immunocompromised hosts.

(Choice B) The yeast form of *Cryptococcus neoformans* is present in pigeon droppings. This fungus causes pulmonary disease and meningoencephalitis in immunocompromised patients.

(Choice C) *Histoplasma capsulatum* is endemic to the Mississippi and Ohio River basins and found in bird and bat droppings. Patients with histoplasmosis often have a history of cleaning bird coops or caving.

(Choice D) *Aspergillus fumigatus* can colonize old lung cavities (e.g., those formed by tuberculosis) to form a "fungal ball" (i.e., aspergilloma). Symptoms include cough, dyspnea, and hemoptysis.

(Choice E) Neutropenic patients are at high risk for developing opportunistic mycoses. *Candida albicans*, *A. fumigatus*, *Mucor,* and *Rhizopus* species can cause severe disease in this population.

(Choice F) Patients with asthma are at risk for developing an allergic reaction to *A. fumigatus* called allergic bronchopulmonary aspergillosis. Signs and symptoms include cough, dyspnea, wheezing, fever, and migratory pulmonary infiltrates.

Educational objective:
Coccidioides immitis is a dimorphic fungus endemic to the southwestern United States. It exists in the environment as a mold (with hyphae) that forms spores. These spores are inhaled and turn into spherules in the lungs.

References

https://t.me/USMLEWorldStep1

A 47-year-old man comes to the office due to worsening shortness of breath for several months. The patient has no fever, weight loss, or cough. He has no other medical conditions and takes no medications. The patient does not use tobacco, alcohol, or illicit drugs. Vital signs are normal. Pulmonary examination demonstrates wheezing and poor air movement. Laboratory results are as follows:

Platelets	160,000/mm^3
Leukocytes	6,500/mm^3
Creatinine	0.8 mg/dL
Total bilirubin	1.3 mg/dL
Aspartate aminotransferase (SGOT)	112 U/L
Alanine aminotransferase (SGPT)	124 U/L

A liver biopsy is subsequently performed. Light microscopy of the tissue specimen after treatment with diastase and periodic acid–Schiff staining is shown in the exhibit. Given these findings, which of the following is the most likely cause of this patient's shortness of breath?

- A. Bronchial hyperreactivity
- B. Interalveolar septal destruction
- C. Interstitial infiltration
- D. Intraalveolar substance accumulation
- E. Pulmonary congestion
- F. Pulmonary vascular obstruction

Submit

https://t.me/USMLEWorldStep1

A 47-year-old man comes to the office due to worsening shortness of breath for several months. The patient has
no fev
not us
and pc

A liver
and pe
likely c

Sub

Exhibit Display

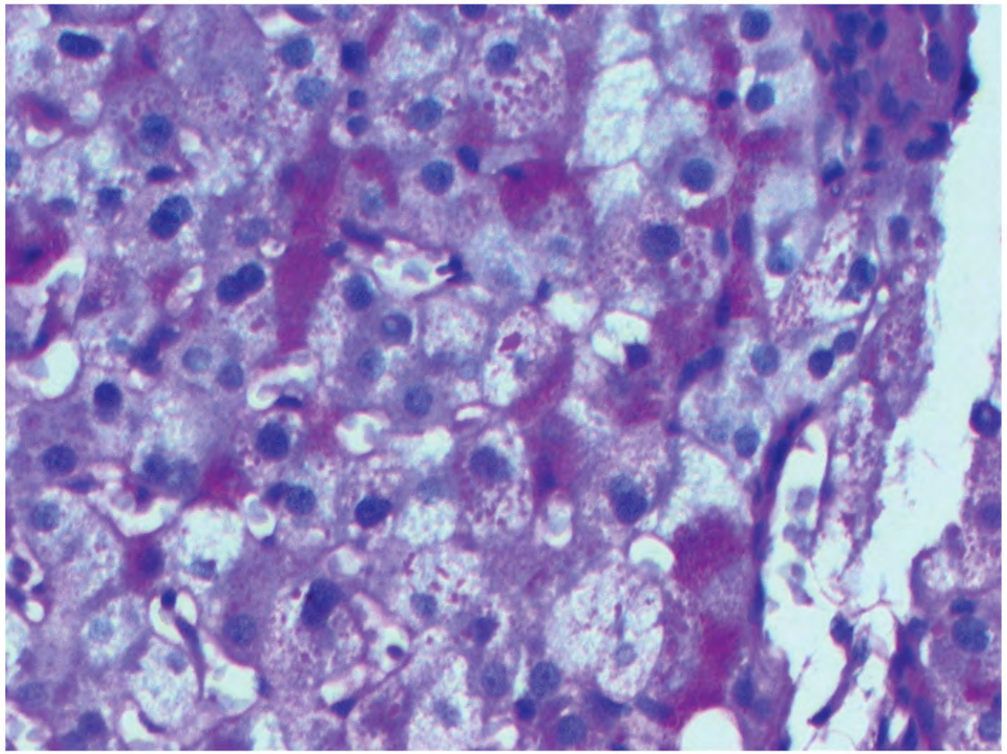

Zoom In Zoom Out Reset New | Existing My Notebook

https://t.me/USMLEWorldStep1

A 47-year-old man comes to the office due to worsening shortness of breath for several months. The patient has no fever, weight loss, or cough. He has no other medical conditions and takes no medications. The patient does not use tobacco, alcohol, or illicit drugs. Vital signs are normal. Pulmonary examination demonstrates wheezing and poor air movement. Laboratory results are as follows:

Platelets	160,000/mm^3
Leukocytes	6,500/mm^3
Creatinine	0.8 mg/dL
Total bilirubin	1.3 mg/dL
Aspartate aminotransferase (SGOT)	112 U/L
Alanine aminotransferase (SGPT)	124 U/L

A liver biopsy is subsequently performed. Light microscopy of the tissue specimen after treatment with diastase and periodic acid–Schiff staining is shown in the exhibit. Given these findings, which of the following is the most likely cause of this patient's shortness of breath?

- A. Bronchial hyperreactivity (4%)
- ✓ B. Interalveolar septal destruction (43%)
- C. Interstitial infiltration (14%)
- D. Intraalveolar substance accumulation (19%)
- E. Pulmonary congestion (12%)
- F. Pulmonary vascular obstruction (4%)

Correct

43% Answered correctly

14 secs Time Spent

2023 Version

https://t.me/USMLEWorldStep1

Alpha-1 antitrypsin deficiency	
Etiology	• Autosomal codominant inheritance • ↓ Alpha-1 antitrypsin leads to unchecked elastase activity
Clinical presentation	• Early-onset (age ≤45) panacinar emphysema • Basilar lung areas predominantly affected • Smoking accelerates disease • Associated liver dysfunction or cirrhosis
Diagnosis	• Obstructive pattern on PFT: ↓ FEV1/FVC ratio, ↓ DLCO • ↓ Serum alpha-1 antitrypsin level & genetic testing
DLCO = diffusing capacity of the lung for carbon monoxide; **PFT** = pulmonary function testing.	

This patient has **alpha-1 antitrypsin** (AAT) **deficiency**, an autosomal codominant disorder that can affect the lungs and liver. Produced primarily in the liver, AAT is a serum protein that inhibits several different proteolytic enzymes (in particular, neutrophil elastase), thereby reducing tissue damage caused by inflammation. Most patients with AAT deficiency are homozygous for the Z allele, which causes decreased secretion of AAT secondary to abnormal protein folding.

Individuals with AAT deficiency classically develop early-onset panacinar emphysema due to unchecked **destruction of the interalveolar septa** (which contain large amounts of elastin). Smoking plays a synergistic role in the disease process by inducing lung inflammation and permanently inactivating AAT through oxidation of a crucial methionine residue. Therefore, smokers with AAT deficiency tend to develop dyspnea at a median age of 36 versus a median age of 51 in nonsmokers.

Patients with particular genetic mutations (including the Z allele) are at risk for developing liver disease due to **intrahepatocyte accumulation** of polymerized AAT molecules; **cirrhosis** is the second most common cause of death behind emphysema in patients with AAT deficiency. Histologically, intracellular granules of unsecreted AAT are seen within the periportal hepatocytes. These globules resist digestion by diastase (an enzyme that breaks

https://t.me/USMLEWorldStep1

This patient has **alpha-1 antitrypsin** (AAT) **deficiency**, an autosomal codominant disorder that can affect the lungs and liver. Produced primarily in the liver, AAT is a serum protein that inhibits several different proteolytic enzymes (in particular, neutrophil elastase), thereby reducing tissue damage caused by inflammation. Most patients with AAT deficiency are homozygous for the Z allele, which causes decreased secretion of AAT secondary to abnormal protein folding.

Individuals with AAT deficiency classically develop early-onset panacinar emphysema due to unchecked **destruction of the interalveolar septa** (which contain large amounts of elastin). Smoking plays a synergistic role in the disease process by inducing lung inflammation and permanently inactivating AAT through oxidation of a crucial methionine residue. Therefore, smokers with AAT deficiency tend to develop dyspnea at a median age of 36 versus a median age of 51 in nonsmokers.

Patients with particular genetic mutations (including the Z allele) are at risk for developing liver disease due to **intrahepatocyte accumulation** of polymerized AAT molecules; **cirrhosis** is the second most common cause of death behind emphysema in patients with AAT deficiency. Histologically, intracellular granules of unsecreted AAT are seen within the periportal hepatocytes. These globules resist digestion by diastase (an enzyme that breaks down glycogen) and appear reddish-pink with the periodic acid–Schiff stain.

(Choice A) Bronchial hyperreactivity is a hallmark of chronic asthma.

(Choice C) Interstitial infiltration is a finding in interstitial pneumonitis.

(Choice D) Intraalveolar substance accumulation is a finding in pulmonary alveolar proteinosis.

(Choice E) Pulmonary congestion is a finding in congestive heart failure.

(Choice F) Pulmonary vascular obstruction occurs in pulmonary embolism or vasculopathy.

Educational objective:
Alpha-1 antitrypsin (AAT) is a serum protein that inhibits neutrophil elastase, thereby reducing tissue damage caused by inflammation. Patients with AAT deficiency typically develop early-onset emphysema; those with specific mutations (including the Z allele) are also at risk for liver disease due to accumulation of unsecreted, polymerized AAT (reddish-pink globules on periodic acid–Schiff stain) in the periportal hepatocytes.

https://t.me/USMLEWorldStep1

Clinical presentation	• Basilar lung areas predominantly affected • Smoking accelerates disease

Exhibit Display

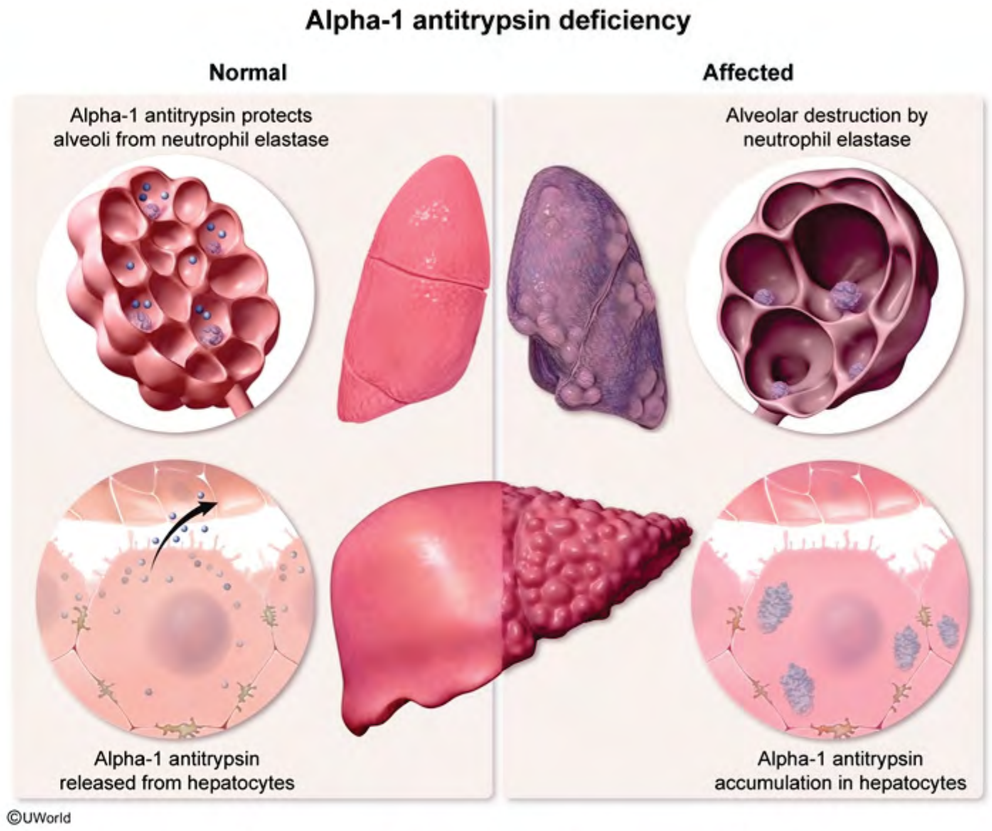

Zoom In | Zoom Out | Reset | New | Existing | My Notebook

This p
lungs
enzym
patien
to abn

Individ
destru
in the
crucial
36 ver

Patien
intrah
death
are se
down

(Choi

(Choi

(Choice D) Intraalveolar substance accumulation is a finding in pulmonary alveolar proteinosis.

(Choice E) Pulmonary congestion is a finding in congestive heart failure.

https://t.me/USMLEWorldStep1

Clinical presentation	• Basilar lung areas predominantly affected • Smoking accelerates disease

Exhibit Display

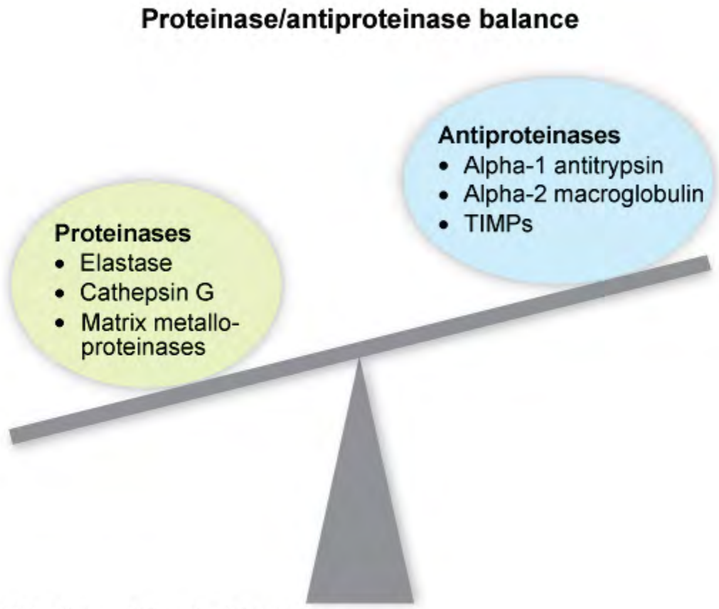

TIMPs = tissue inhibitors of metalloproteinase.
©UWorld

Zoom In | Zoom Out | Reset | New | Existing | My Notebook

This p
lungs
enzym
patien
to abn

Individ
destru
in the
crucial
36 ver

Patien
intrah
death
are se
down

(Choi

(Choi

(Choice D) Intraalveolar substance accumulation is a finding in pulmonary alveolar proteinosis.

(Choice E) Pulmonary congestion is a finding in congestive heart failure.

https://t.me/USMLEWorldStep1

Clinical presentation	• Basilar lung areas predominantly affected • Smoking accelerates disease

Exhibit Display

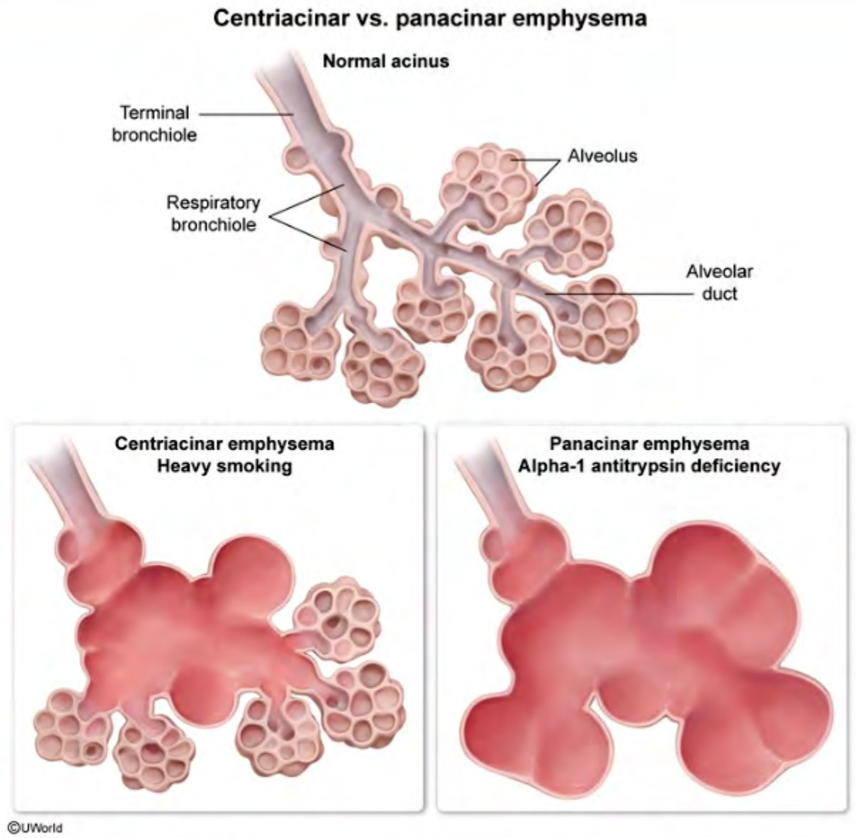

Zoom In | Zoom Out | Reset | New | Existing | My Notebook

This p
lungs
enzym
patien
to abn

Individ
destru
in the
crucial
36 ver

Patien
intrah
death
are se
down

(Choi

(Choi

(Choice D) Intraalveolar substance accumulation is a finding in pulmonary alveolar proteinosis.

(Choice E) Pulmonary congestion is a finding in congestive heart failure.

https://t.me/USMLEWorldStep1

Clinical presentation	• Basilar lung areas predominantly affected • Smoking accelerates disease

Exhibit Display

Alpha-1 antitrypsin deficiency

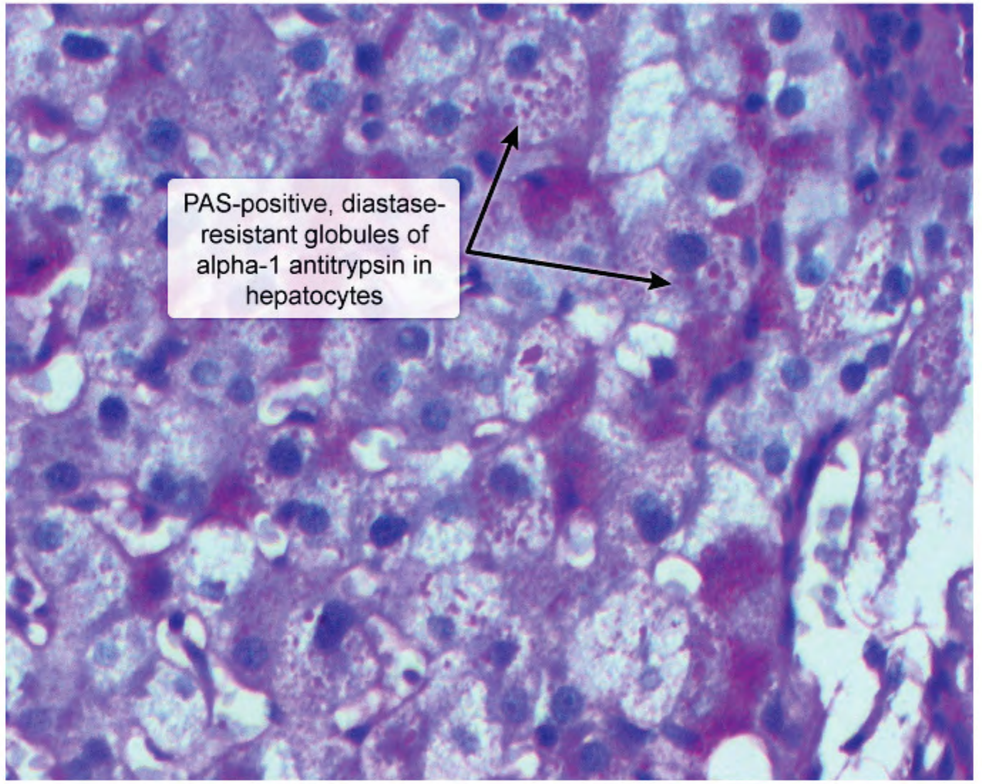

Periodic acid-Schiff (PAS) stain with diastase digestion

©UWorld

Zoom In | Zoom Out | Reset | New | Existing | My Notebook

This p
lungs
enzym
patien
to abn

Individ
destru
in the
crucial
36 ver

Patien
intrah
death
are se
down

(Choi

(Choi

(Choi

(Choice E) Pulmonary congestion is a finding in congestive heart failure.

https://t.me/USMLEWorldStep1

A neonate at 38 weeks gestation is delivered vaginally following an uncomplicated pregnancy. Immediately after delivery, the neonate has respiratory distress. Examination shows cyanosis, tachypnea, and poor perfusion. The patient is emergently intubated, and mechanical ventilation is initiated. A nasogastric tube is also inserted. On auscultation, asymmetric aeration with decreased left-sided breath sounds are noted. The abdomen is scaphoid. A chest x-ray is shown in the exhibit. Which of the following is the most likely cause of this patient's respiratory distress?

- A. Dilated airspaces with bronchiolar metaplasia
- B. Increased pulmonary capillary wedge pressure
- C. Loss of negative intrapleural pressure
- D. Pulmonary surfactant deficiency
- E. Underdevelopment of pulmonary tissue

Submit

https://t.me/USMLEWorldStep1

A neonate at 38 weeks gestation is delivered vaginally following an uncomplicated pregnancy. Immediately after
deliver
patien
auscul
A ches
distres

Sub

Exhibit Display

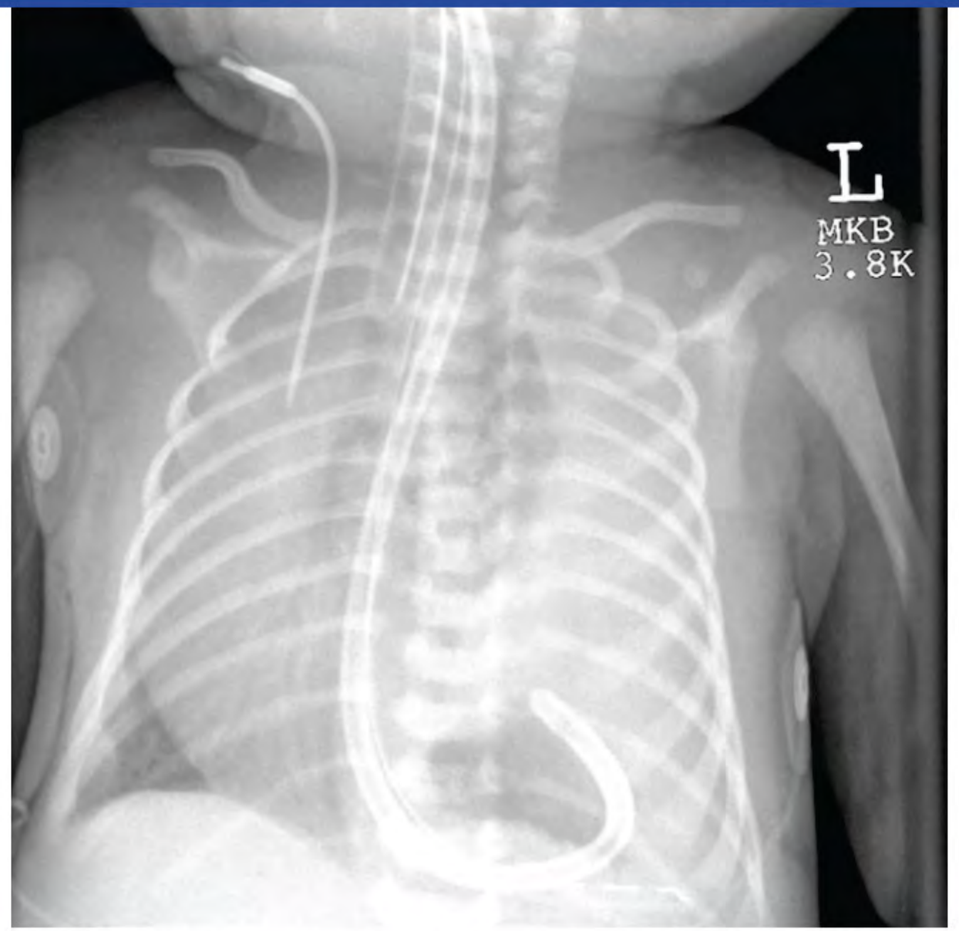

Zoom In Zoom Out Reset New | Existing My Notebook

https://t.me/USMLEWorldStep1

A neonate at 38 weeks gestation is delivered vaginally following an uncomplicated pregnancy. Immediately after delivery, the neonate has respiratory distress. Examination shows cyanosis, tachypnea, and poor perfusion. The patient is emergently intubated, and mechanical ventilation is initiated. A nasogastric tube is also inserted. On auscultation, asymmetric aeration with decreased left-sided breath sounds are noted. The abdomen is scaphoid. A chest x-ray is shown in the exhibit. Which of the following is the most likely cause of this patient's respiratory distress?

- A. Dilated airspaces with bronchiolar metaplasia
- B. Increased pulmonary capillary wedge pressure
- C. Loss of negative intrapleural pressure
- D. Pulmonary surfactant deficiency
- E. Underdevelopment of pulmonary tissue

Submit

https://t.me/USMLEWorldStep1

A neonate at 38 weeks gestation is delivered vaginally following an uncomplicated pregnancy. Immediately after
deliver
patien
auscul
A ches
distres

Sub

Exhibit Display

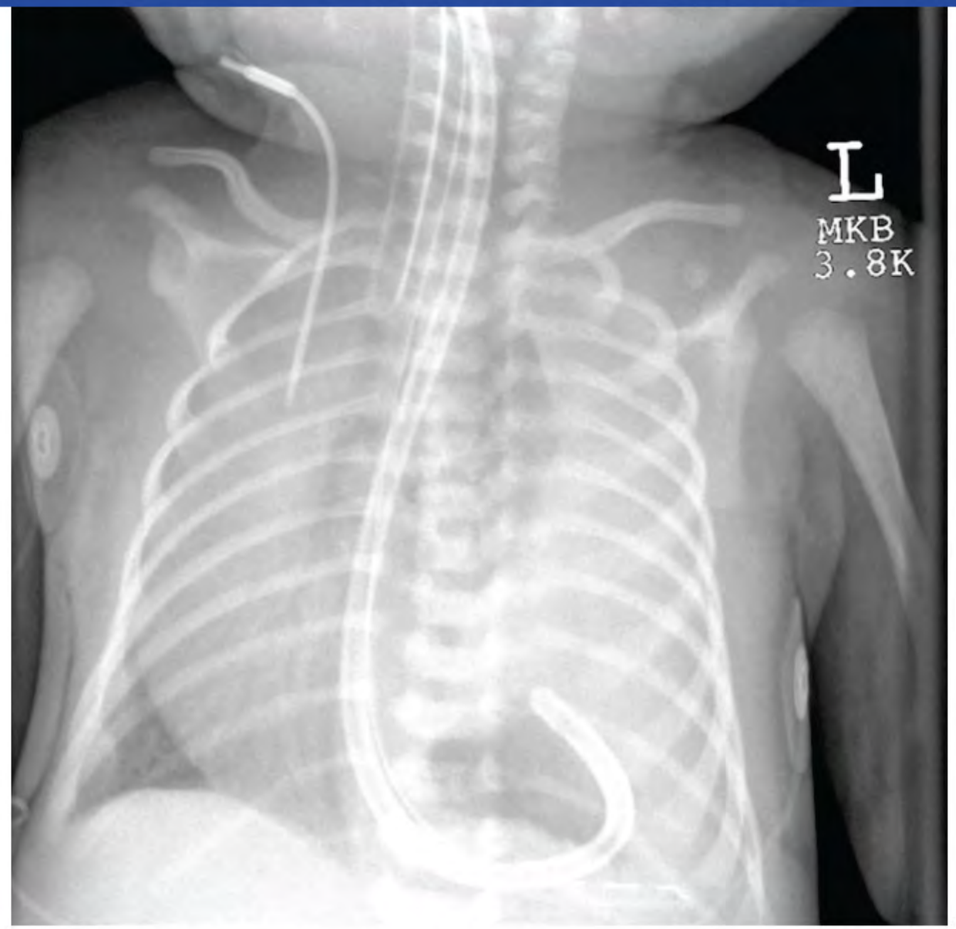

Zoom In Zoom Out Reset New | Existing My Notebook

https://t.me/USMLEWorldStep1

A neonate at 38 weeks gestation is delivered vaginally following an uncomplicated pregnancy. Immediately after delivery, the neonate has respiratory distress. Examination shows cyanosis, tachypnea, and poor perfusion. The patient is emergently intubated, and mechanical ventilation is initiated. A nasogastric tube is also inserted. On auscultation, asymmetric aeration with decreased left-sided breath sounds are noted. The abdomen is scaphoid. A chest x-ray is shown in the exhibit. Which of the following is the most likely cause of this patient's respiratory distress?

- A. Dilated airspaces with bronchiolar metaplasia (2%)
- ✕ B. Increased pulmonary capillary wedge pressure (3%)
- C. Loss of negative intrapleural pressure (26%)
- D. Pulmonary surfactant deficiency (13%)
- ✓ E. Underdevelopment of pulmonary tissue (53%)

Incorrect
Correct answer
E

53%
Answered correctly

02 mins, 15 secs
Time Spent

2023
Version

Explanation

Congenital diaphragmatic hernia

https://t.me/USMLEWorldStep1

Congenital diaphragmatic hernia

Exhibit Display

Congenital diaphragmatic hernia

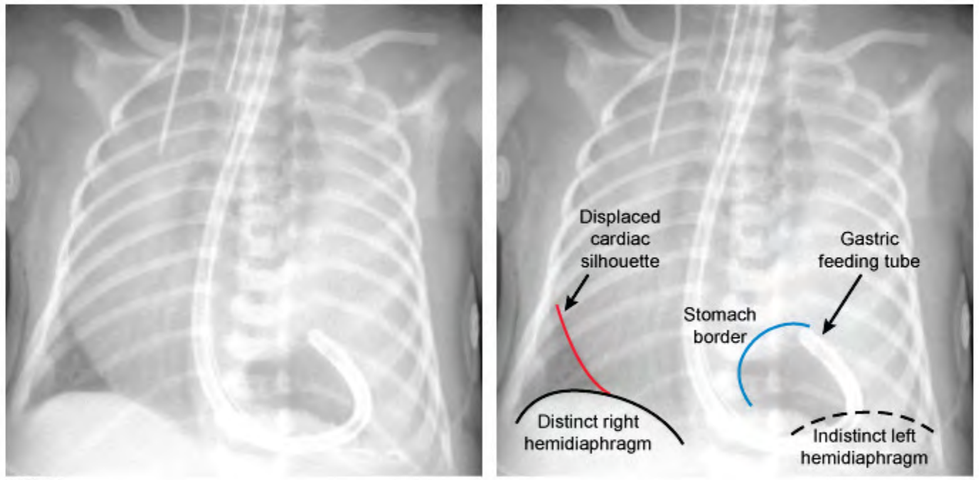

©UWorld

Zoom In | Zoom Out | Reset | New | Existing | My Notebook

This n
concer
incomp
cavity
underc

Neona
unilate
finding
hemid
instea

(Choi

respira

complicated by bronchopulmonary dysplasia, characterized by dilation of airspaces with bronchiolar metaplasia.

Patients with CDH may also develop bronchopulmonary dysplasia, but this is a late complication (age >30 days)

https://t.me/USMLEWorldStep1

This neonate has respiratory distress with **asymmetric breath sounds** and a scaphoid abdomen, findings concerning for **congenital diaphragmatic hernia** (CDH). This condition develops in the first trimester due to incomplete fusion of the pleuroperitoneal folds, which permits herniation of abdominal contents into the thoracic cavity (most commonly the left side). Compression of the developing lung results in **pulmonary hypoplasia**, or underdevelopment of lung tissue.

Neonates typically develop respiratory distress (eg, tachypnea, retractions) within hours of birth and decreased unilateral breath sounds; a **scaphoid abdomen** from superiorly shifted abdominal viscera is common. Chest x-ray findings include the presence of **thoracic bowel loops** with minimal or absent lung markings and an indistinct hemidiaphragm on the affected side. In addition, the distal end of a **feeding tube** may be seen within the **thorax** instead of the abdomen.

(Choices A and D) Pulmonary surfactant deficiency occurs in premature (not term) neonates and causes respiratory distress syndrome (RDS). X-ray reveals ground glass opacities and air bronchograms. RDS can be complicated by bronchopulmonary dysplasia, characterized by dilation of airspaces with bronchiolar metaplasia. Patients with CDH may also develop bronchopulmonary dysplasia, but this is a late complication (age >30 days) and is not present at birth.

(Choice B) Pulmonary capillary wedge pressure reflects left ventricular end-diastolic pressure and is increased in left-sided congenital heart disease (eg, aortic stenosis). Poor perfusion would be expected, but a scaphoid abdomen and abnormally placed feeding tube would not be seen.

(Choice C) Pneumothorax is characterized by loss of negative intrapleural pressure and can cause asymmetric breath sounds and respiratory distress. Although a mediastinal shift can also be seen on imaging, a visceral pleural edge with the absence of distal lung markings would be expected.

Educational objective:
Congenital diaphragmatic hernia (herniation of abdominal contents into the thorax) causes pulmonary hypoplasia from compression of the lungs. Neonates present with respiratory distress shortly after birth. X-ray findings include thoracic bowel loops; the distal end of a feeding tube may also be seen within the thorax.

References

https://t.me/USMLEWorldStep1

This neonate has respiratory distress with **asymmetric breath sounds** and a scaphoid abdomen, findings

conce
incom
cavity
under

Neona
unilate
finding
hemid
instea

(Choi
respira
compli
Patien
and is

(Choi
left-sic
abdom

(Choi
breath
pleura

Educa
Conge
from c
include

References

Exhibit Display

Respiratory distress syndrome

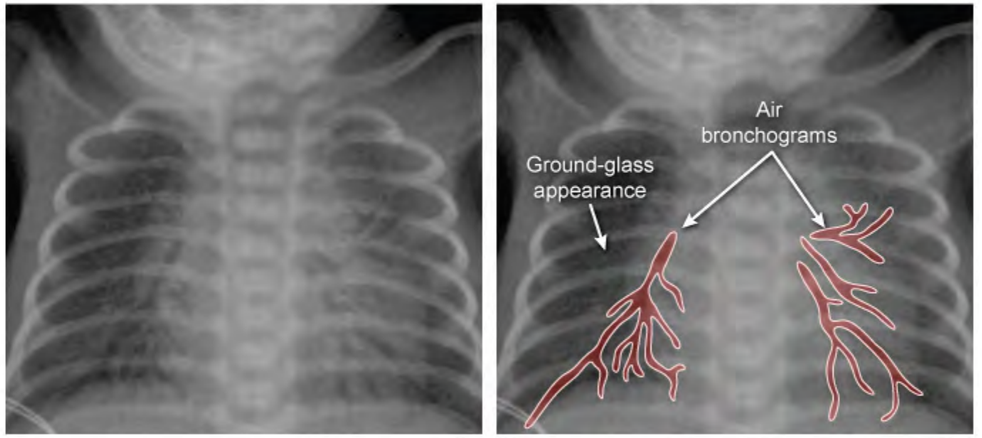

Diffuse alveolar collapse (atelectasis) due to surfactant deficiency

©UWorld

Zoom In | Zoom Out | Reset | New | Existing | My Notebook

https://t.me/USMLEWorldStep1

This neonate has respiratory distress with **asymmetric breath sounds** and a scaphoid abdomen, findings

concer
incom
cavity
underc

Neona
unilate
finding
hemid
instea

(Choi
respira
compli
Patien
and is

(Choi
left-sic
abdom

(Choi
breath
pleura

Educa
Conge
from c
include

References

Exhibit Display

Pneumothorax

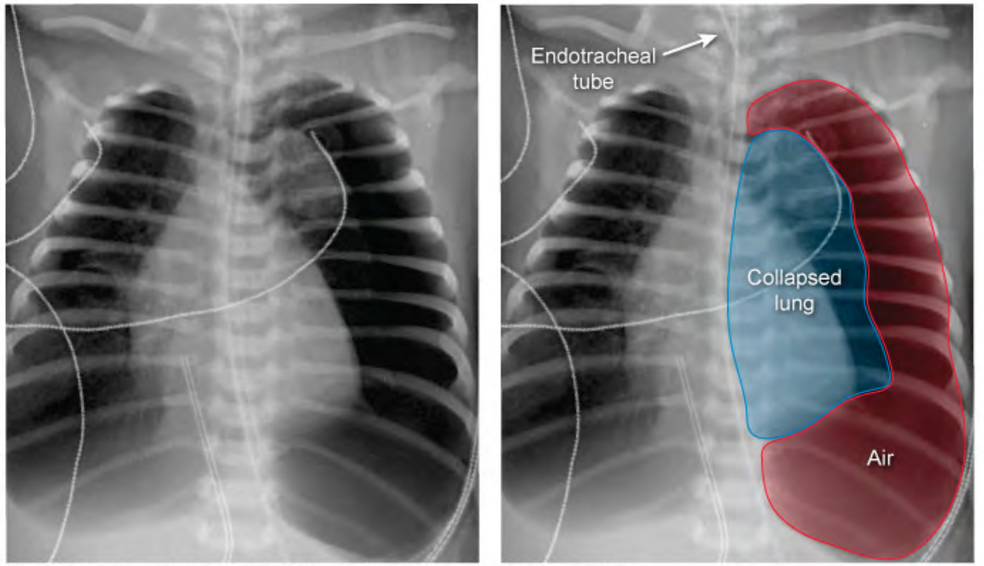

*Iatrogenic pneumothorax in a neonate due to mechanical ventilation (barotrauma)

©UWorld

Zoom In
Zoom Out
Reset
New
Existing
My Notebook

https://t.me/USMLEWorldStep1

A 76-year-old man has had worsening shortness of breath, cough, and weight loss for the past several months. He is a lifelong nonsmoker. Chest imaging reveals irregular pleural thickening. A surgical biopsy is planned, but the patient refuses, choosing to receive hospice care instead. He dies several weeks later. Autopsy examination is performed, and a photograph of the cut lung section is shown below.

Histopathological examination of the abnormal tissue is most likely to reveal which of the following findings?

- A. Caseating granulomas with giant cells
- B. Central areas of whorled collagen fibers
- C. Small round cells positive for chromogranin
- D. Spindle cells positive for cytokeratin
- E. Thick, fibrinous exudate and pus

Submit

https://t.me/USMLEWorldStep1

A 76-year-old man has had worsening shortness of breath, cough, and weight loss for the past several months. He is a life patien perfor

Exhibit Display

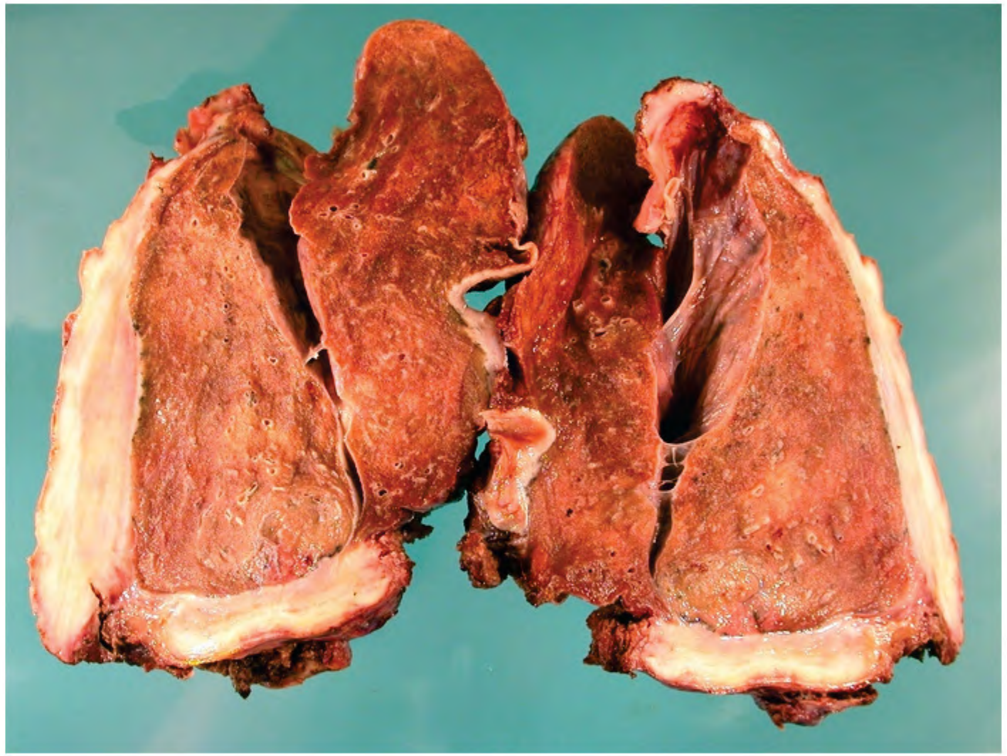

Zoom In | Zoom Out | Reset | New | Existing | My Notebook

Histop

C. Small round cells positive for chromogranin

https://t.me/USMLEWorldStep1

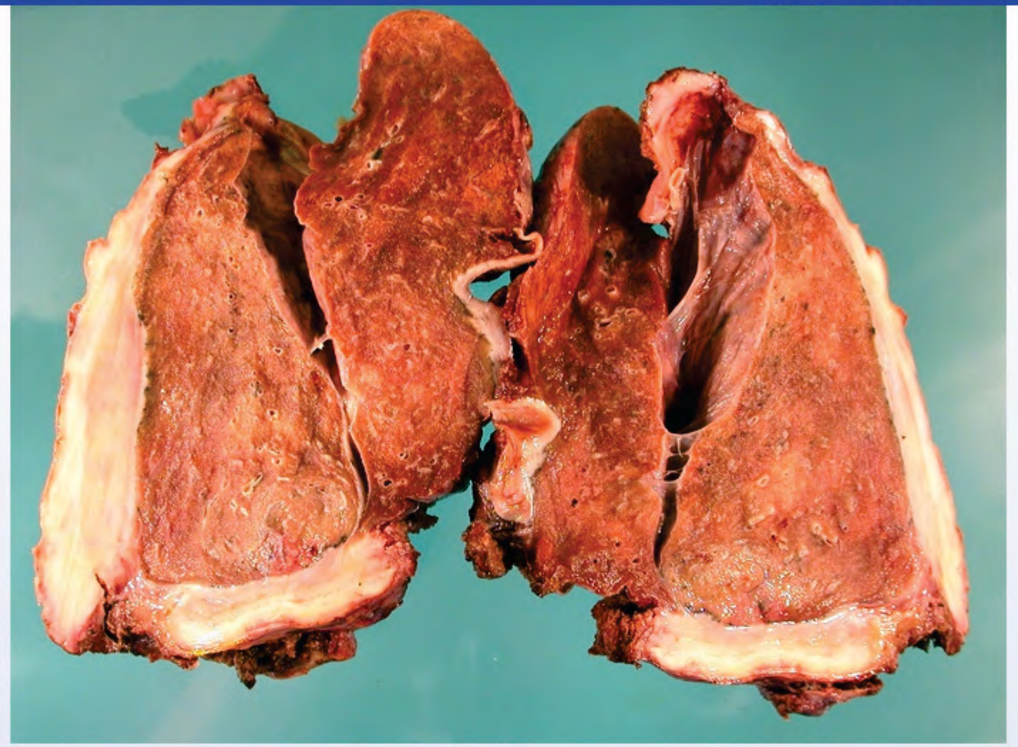

Histopathological examination of the abnormal tissue is most likely to reveal which of the following findings?

- A. Caseating granulomas with giant cells
- B. Central areas of whorled collagen fibers
- C. Small round cells positive for chromogranin
- D. Spindle cells positive for cytokeratin
- E. Thick, fibrinous exudate and pus

Submit

https://t.me/USMLEWorldStep1

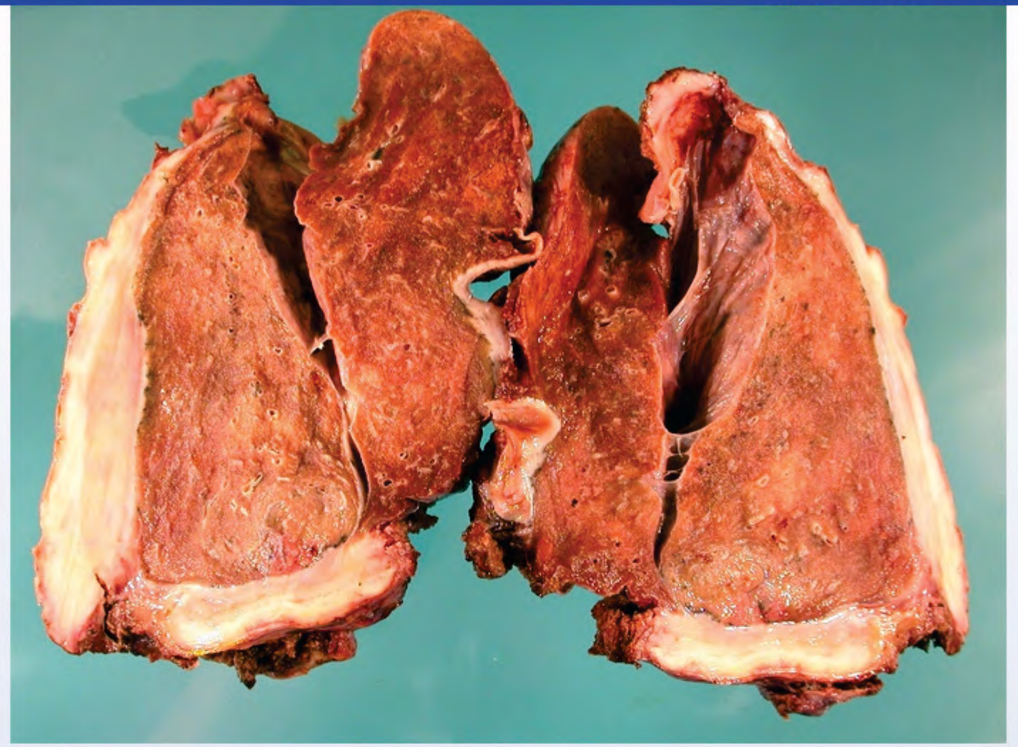

Histopathological examination of the abnormal tissue is most likely to reveal which of the following findings?

- A. Caseating granulomas with giant cells (6%)
- ✗ B. Central areas of whorled collagen fibers (30%)
- C. Small round cells positive for chromogranin (9%)
- ✓ D. Spindle cells positive for cytokeratin (37%)
- E. Thick, fibrinous exudate and pus (15%)

Incorrect
Correct answer
D

37%
Answered correctly

13 secs
Time Spent

2023
Version

https://t.me/USMLEWorldStep1

✓ D. Spindle cells positive for cytokeratin (37%)

Exhibit Display

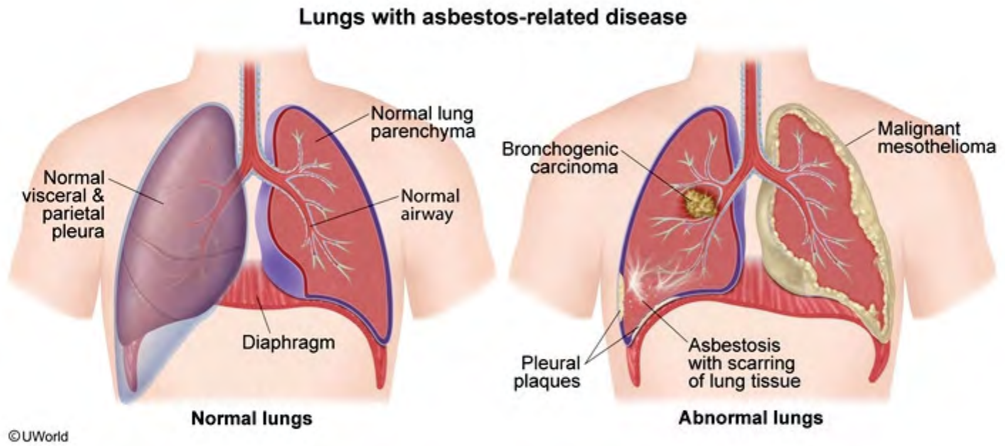

Zoom In | Zoom Out | Reset | New | Existing | My Notebook

exposure is the primary risk factor; individuals with occupational exposure (eg, mining, shipbuilding, insulation installation) are at increased risk.

https://t.me/USMLEWorldStep1

This nonsmoking patient with dyspnea, cough, and weight loss has pleural thickening on imaging; gross pathology of the lungs demonstrates an encasement of the lungs in a rind-like, calcified mass. This presentation is consistent with **mesothelioma**, a rare, malignant neoplasm arising from the mesothelial cells that line body cavities (eg, pleural, peritoneal, pericardial).

In early mesothelioma, multiple nodules form on the parietal pleura and gradually grow to encase the lung parenchyma (which is typically uninvolved). Pleural effusions are common and frequently hemorrhagic. Mesotheliomas typically present with slowly progressive dyspnea, cough, chest pain, and weight loss. **Asbestos** exposure is the primary risk factor; individuals with occupational exposure (eg, mining, shipbuilding, insulation installation) are at increased risk.

Histologically, mesothelioma can appear as cuboidal or flattened cells (epithelium-like) or **spindle cells** (stromal-like). Immunohistochemistry is an important diagnostic marker; nearly all cases of mesothelioma will stain positive for **cytokeratins** and many will also typically stain positive for **calretinin**. Electron microscopy usually shows polygonal tumor cells with numerous long, slender microvilli and **abundant tonofilaments**.

(Choice A) Tuberculosis is characterized by caseating granulomas with giant cell formation; patients typically have hilar adenopathy and upper lobe infiltrates. Tuberculosis occurs most commonly in immunosuppressed patients or those at high exposure risk (eg, health care workers, incarcerated individuals).

(Choice B) Silicosis is associated with inhaled silica (eg, mining, sand blasting); histology demonstrates nodules composed of whorled collagen fibers and dust-laden macrophages. Imaging demonstrates innumerable upper lobe–predominant nodes within the pulmonary parenchyma.

(Choice C) Small cell lung cancer is characterized by small round cells; however, this malignancy typically arises in the central airways (not the pleura). Neuroendocrine markers, including chromogranin and synaptophysin, are typically positive.

(Choice E) Empyema—composed of a thick, fibrinous exudate and pus—typically occurs when bacteria infect the pleural space (typically from an associated pneumonia). Patients often present with fever, chills, and (occasionally) sepsis, not months of weight loss and dyspnea.

Educational objective:

https://t.me/USMLEWorldStep1

Mesotheliomas typically present with slowly progressive dyspnea, cough, chest pain, and weight loss. **Asbestos** exposure is the primary risk factor; individuals with occupational exposure (eg, mining, shipbuilding, insulation installation) are at increased risk.

Histologically, mesothelioma can appear as cuboidal or flattened cells (epithelium-like) or **spindle cells** (stromal-like). Immunohistochemistry is an important diagnostic marker; nearly all cases of mesothelioma will stain positive for **cytokeratins** and many will also typically stain positive for **calretinin**. Electron microscopy usually shows polygonal tumor cells with numerous long, slender microvilli and **abundant tonofilaments**.

(Choice A) Tuberculosis is characterized by caseating granulomas with giant cell formation; patients typically have hilar adenopathy and upper lobe infiltrates. Tuberculosis occurs most commonly in immunosuppressed patients or those at high exposure risk (eg, health care workers, incarcerated individuals).

(Choice B) Silicosis is associated with inhaled silica (eg, mining, sand blasting); histology demonstrates nodules composed of whorled collagen fibers and dust-laden macrophages. Imaging demonstrates innumerable upper lobe–predominant nodes within the pulmonary parenchyma.

(Choice C) Small cell lung cancer is characterized by small round cells; however, this malignancy typically arises in the central airways (not the pleura). Neuroendocrine markers, including chromogranin and synaptophysin, are typically positive.

(Choice E) Empyema—composed of a thick, fibrinous exudate and pus—typically occurs when bacteria infect the pleural space (typically from an associated pneumonia). Patients often present with fever, chills, and (occasionally) sepsis, not months of weight loss and dyspnea.

Educational objective:
Mesothelioma is a neoplasm arising from mesothelial cells and is strongly associated with asbestos exposure. In early mesothelioma, multiple nodules form on the parietal pleura and gradually encase the lung parenchyma. Immunohistochemistry is important for diagnosis; nearly all mesotheliomas stain positive for cytokeratins and many also stain positive for calretinin.

Pathophysiology	Pulmonary & Critical Care	Asbestos
Subject	System	Topic

https://t.me/USMLEWorldStep1

A pharmaceutical researcher develops a therapy to treat a protein misfolding disorder. Specifically, a mutation in this disorder leads to abnormal protein folding and subsequent intracellular degradation of the protein before it can reach the cell membrane. With the new combination drug therapy, the first drug corrects the processing and trafficking of the protein, enabling it to reach the cell surface membrane. Once the protein has reached the cell surface, its function is enhanced by the second drug. This therapy is most likely to be helpful in which of the following conditions?

- A. Alzheimer disease
- B. Creutzfeldt-Jakob disease
- C. Cystic fibrosis
- D. Phenylketonuria
- E. Sickle cell anemia

Submit

https://t.me/USMLEWorldStep1

A pharmaceutical researcher develops a therapy to treat a protein misfolding disorder. Specifically, a mutation in this disorder leads to abnormal protein folding and subsequent intracellular degradation of the protein before it can reach the cell membrane. With the new combination drug therapy, the first drug corrects the processing and trafficking of the protein, enabling it to reach the cell surface membrane. Once the protein has reached the cell surface, its function is enhanced by the second drug. This therapy is most likely to be helpful in which of the following conditions?

- ✗ A. Alzheimer disease (8%)
- B. Creutzfeldt-Jakob disease (9%)
- ✓ C. Cystic fibrosis (78%)
- D. Phenylketonuria (1%)
- E. Sickle cell anemia (1%)

Incorrect
Correct answer
C

78%
Answered correctly

04 secs
Time Spent

2023
Version

Explanation

ΔF508 mutations & CFTR post-translational processing

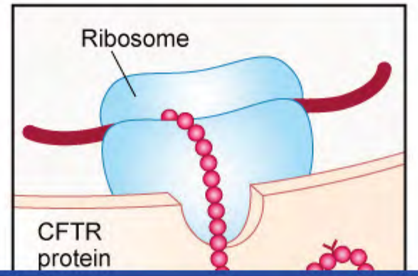

https://t.me/USMLEWorldStep1

A pharmaceutical researcher develops a therapy to treat a protein misfolding disorder. Specifically, a mutation in this di
reach
traffick
surfac
followi

Exhibit Display

ΔF508 mutations & CFTR post-translational processing

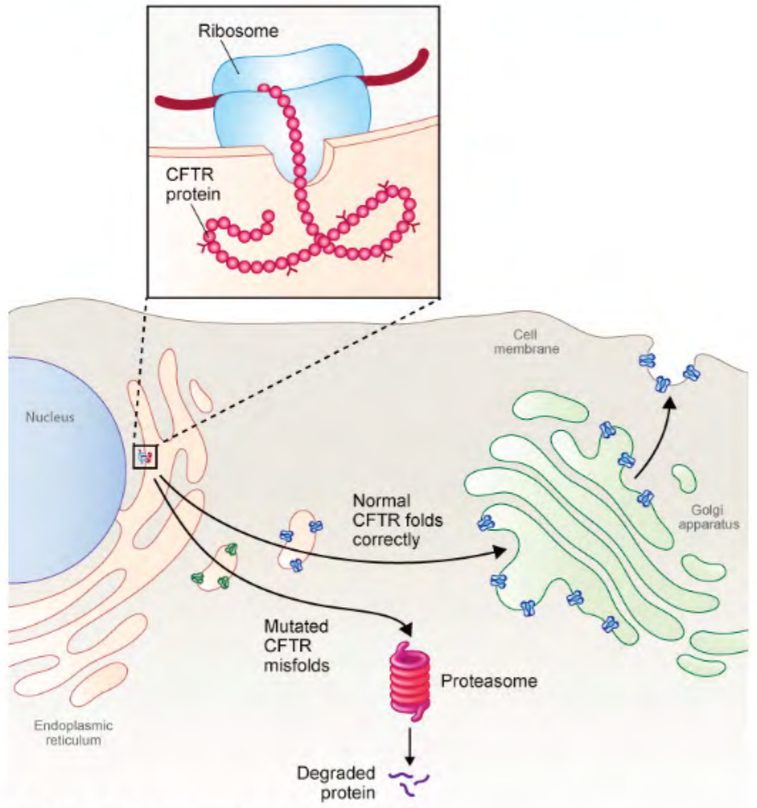

CFTR = cystic fibrosis transmembrane conductance regulator.
©UWorld

Zoom In | Zoom Out | Reset | New | Existing | My Notebook

https://t.me/USMLEWorldStep1

Cystic fibrosis (CF) is caused by mutations in the cystic fibrosis transmembrane regulator (CFTR) protein. **ΔF508** is the most common CFTR gene mutation in patients with CF. This deletion causes **abnormal protein folding** and failure of glycosylation. The CFTR protein is then **targeted for degradation** by the proteasome before reaching the cell surface, causing an almost complete **absence from the apical membrane** of exocrine ductal epithelial cells. The rare CFTR proteins that do reach the cell membrane are abnormal, as the ΔF508 mutation also reduces channel opening.

Lumacaftor and ivacaftor are CFTR-modulating medications that can potentially help patients with CF by restoring CFTR proteins to the membrane and also by enhancing protein function (eg, chloride transport) at the membrane, respectively. The combination of these 2 medications in patients with homozygous ΔF508 mutations has been shown to improve predicted forced expiratory volume (FEV) and decrease rates of pulmonary exacerbations.

(Choice A) Polymorphisms in apolipoprotein E (APOE) are common in patients with Alzheimer disease (AD). The polymorphism leads to a conformational protein change that alters lipid binding, inhibits neurite growth, and leads to accumulation of amyloid-β, a peptide that aggregates in the brain in patients with AD. APOE is not a target of degradation or a transmembrane protein.

(Choice B) Creutzfeldt-Jakob disease is a neurodegenerative disease caused by prions, which are contagious pathogens comprised of small, misfolded proteins that induce abnormal folding of normal proteins. Aggregates of misfolded proteins are difficult to degrade and result in apoptosis and neuronal loss.

(Choice D) Phenylketonuria results from mutations in the hepatocyte enzyme phenylalanine hydroxylase. This enzyme is not normally transported to the cell surface.

(Choice E) Sickle cell anemia results from mutations in the β-globin gene, leading to production of hemoglobin S, which can polymerize in states of low oxygen content. Hemoglobin S is not a transmembrane protein.

Educational objective:
ΔF508 is the most common mutation in the cystic fibrosis transmembrane regulator (CFTR) protein in patients with cystic fibrosis. This mutation leads to protein misfolding and failure of glycosylation, followed by proteasome-mediated degradation and significantly decreased number of transmembrane CFTR proteins.

References

https://t.me/USMLEWorldStep1

A 28-year-old man comes to the clinic due to cough and shortness of breath. The patient has a history of intermittent asthma controlled with an as-needed albuterol inhaler. Over the last month, he has noticed increased severity and frequency of his symptoms. The patient occasionally wakes up at night with coughing spells and has had to use his albuterol inhaler several times per week due to shortness of breath. An inhaled corticosteroid is prescribed to achieve better symptom control. In addition to an anti-inflammatory effect, which of the following effects also directly occurs as a result of this therapy?

- A. Decreased production of lung surfactants
- B. Decreased viscosity of bronchial mucus
- C. Increased activity of phosphodiesterases
- D. Increased quantity of surface-bound IgE
- E. Increased responsiveness of beta-2 receptors

Submit

https://t.me/USMLEWorldStep1

A 28-year-old man comes to the clinic due to cough and shortness of breath. The patient has a history of intermittent asthma controlled with an as-needed albuterol inhaler. Over the last month, he has noticed increased severity and frequency of his symptoms. The patient occasionally wakes up at night with coughing spells and has had to use his albuterol inhaler several times per week due to shortness of breath. An inhaled corticosteroid is prescribed to achieve better symptom control. In addition to an anti-inflammatory effect, which of the following effects also directly occurs as a result of this therapy?

- A. Decreased production of lung surfactants (3%)
- ✗ B. Decreased viscosity of bronchial mucus (24%)
- C. Increased activity of phosphodiesterases (9%)
- D. Increased quantity of surface-bound IgE (2%)
- ✓ E. Increased responsiveness of beta-2 receptors (60%)

Incorrect
Correct answer
E

60%
Answered correctly

04 secs
Time Spent

2023
Version

Explanation

Asthma is a complex disease involving both chronic inflammation and airway hyperreactivity. **Inhaled corticosteroids** (eg, fluticasone, budesonide) are a mainstay of asthma therapy. Corticosteroids reduce inflammation by inhibiting nuclear transcription of inflammatory genes (in part leading to downregulation of the enzyme phospholipase A2) to decrease the production of leukotrienes and other inflammatory mediators.

Although corticosteroids have no direct effect on bronchodilation, these drugs provide an additional benefit in asthma by **potentiating the bronchodilatory effect** of beta-2 agonists (eg, albuterol). This is accomplished by stimulating the **upregulation of beta-2 receptors** in **bronchial smooth muscle**, increasing cellular responsiveness to adrenergic stimulus. This medication effect is similar to the permissive effect of endogenous

https://t.me/USMLEWorldStep1

Asthma is a complex disease involving both chronic inflammation and airway hyperreactivity. **Inhaled corticosteroids** (eg, fluticasone, budesonide) are a mainstay of asthma therapy. Corticosteroids reduce inflammation by inhibiting nuclear transcription of inflammatory genes (in part leading to downregulation of the enzyme phospholipase A2) to decrease the production of leukotrienes and other inflammatory mediators.

Although corticosteroids have no direct effect on bronchodilation, these drugs provide an additional benefit in asthma by **potentiating the bronchodilatory effect** of beta-2 agonists (eg, albuterol). This is accomplished by stimulating the **upregulation of beta-2 receptors** in **bronchial smooth muscle**, increasing cellular responsiveness to adrenergic stimulus. This medication effect is similar to the permissive effect of endogenous cortisol on blood pressure, which involves upregulation of alpha-1 receptors and increased responsiveness of vascular smooth muscle cells to epinephrine.

(Choice A) Corticosteroids increase, rather than decrease, the production of lung surfactants and may be used to help prevent infant respiratory distress syndrome in premature infants.

(Choice B) Guaifenesin reduces the viscosity (ie, thickness) of respiratory tract mucus and is often used in the symptomatic management of viral upper respiratory tract infections. Decreased mucus viscosity is not a direct effect of corticosteroids.

(Choice C) Theophylline provides benefit in asthma by stimulating bronchodilation via inhibition of phosphodiesterase-3 and may also create an anti-inflammatory effect via inhibition of phosphodiesterase-4. Corticosteroids may somewhat decrease phosphodiesterase activity but likely do not have a significant effect.

(Choice D) Omalizumab is a monoclonal antibody that treats asthma by binding to free IgE to decrease IgE binding to surface receptors on mast cells and basophils. This inhibits the degranulation of inflammatory mediators. The anti-inflammatory effects of corticosteroids may also contribute to a decrease, rather than an increase, in surface-bound IgE.

Educational objective:
Corticosteroids (eg, fluticasone, budesonide) have multiple beneficial effects in the treatment of asthma. In addition to their anti-inflammatory effect, corticosteroids upregulate beta-2 receptors on bronchial smooth muscle to increase cellular responsiveness to adrenergic stimuli and potentiate the bronchodilatory response to inhaled beta-

https://t.me/USMLEWorldStep1

enzyme phospholipase A2) to decrease the production of leukotrienes and other inflammatory mediators.

Although corticosteroids have no direct effect on bronchodilation, these drugs provide an additional benefit in asthma by **potentiating the bronchodilatory effect** of beta-2 agonists (eg, albuterol). This is accomplished by stimulating the **upregulation of beta-2 receptors** in **bronchial smooth muscle**, increasing cellular responsiveness to adrenergic stimulus. This medication effect is similar to the permissive effect of endogenous cortisol on blood pressure, which involves upregulation of alpha-1 receptors and increased responsiveness of vascular smooth muscle cells to epinephrine.

(Choice A) Corticosteroids increase, rather than decrease, the production of lung surfactants and may be used to help prevent infant respiratory distress syndrome in premature infants.

(Choice B) Guaifenesin reduces the viscosity (ie, thickness) of respiratory tract mucus and is often used in the symptomatic management of viral upper respiratory tract infections. Decreased mucus viscosity is not a direct effect of corticosteroids.

(Choice C) Theophylline provides benefit in asthma by stimulating bronchodilation via inhibition of phosphodiesterase-3 and may also create an anti-inflammatory effect via inhibition of phosphodiesterase-4. Corticosteroids may somewhat decrease phosphodiesterase activity but likely do not have a significant effect.

(Choice D) Omalizumab is a monoclonal antibody that treats asthma by binding to free IgE to decrease IgE binding to surface receptors on mast cells and basophils. This inhibits the degranulation of inflammatory mediators. The anti-inflammatory effects of corticosteroids may also contribute to a decrease, rather than an increase, in surface-bound IgE.

Educational objective:
Corticosteroids (eg, fluticasone, budesonide) have multiple beneficial effects in the treatment of asthma. In addition to their anti-inflammatory effect, corticosteroids upregulate beta-2 receptors on bronchial smooth muscle to increase cellular responsiveness to adrenergic stimuli and potentiate the bronchodilatory response to inhaled beta-2 agonists (eg, albuterol).

References

- Glucocorticosteroids increase beta 2-adrenergic receptor transcription in human lung.

https://t.me/USMLEWorldStep1

E

Exp

Asthm
cortic
inflam
enzym

Althou
asthm
stimul
respor
cortisc
vascul

(Choi
help p

(Choi
sympt
effect

(Choi
phosp
Cortic

(Choi
bindin
media
increase, in surface-bound IgE.

Educational objective:

Exhibit Display

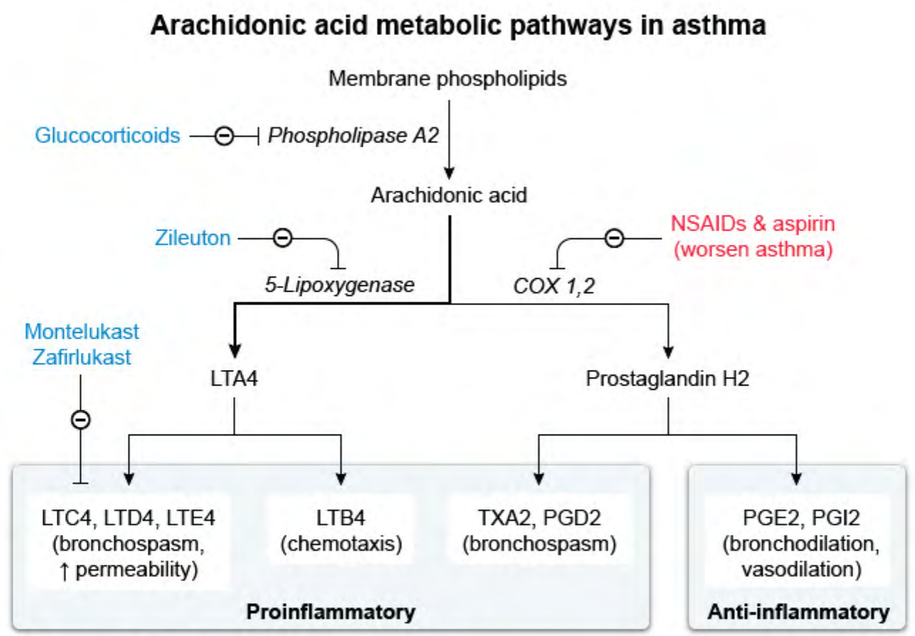

Zoom In Zoom Out Reset New | Existing My Notebook

https://t.me/USMLEWorldStep1

A 54-year-old woman comes to the office due to worsening nonproductive cough and dyspnea for the past several months. She also reports anorexia and an unintentional weight loss of 7 kg (15.4 lb). The patient has no prior medical conditions, takes no medications, and is a lifelong nonsmoker. Physical examination shows decreased breath sounds on the left side. Chest x-ray reveals a large left-sided pleural effusion. Thoracentesis yields fluid with a large number of red blood cells and numerous atypical cells staining positive for mucin. Which of the following is the most likely primary mechanism of this patient's pleural effusion?

- A. Decreased plasma oncotic pressure
- B. Disruption of the thoracic lymphatic duct
- C. Increased intercostal venous pressure
- D. Increased pulmonary capillary pressure
- E. Occlusion of pleural lymphatic stoma

Submit

https://t.me/USMLEWorldStep1

A 54-year-old woman comes to the office due to worsening nonproductive cough and dyspnea for the past several months. She also reports anorexia and an unintentional weight loss of 7 kg (15.4 lb). The patient has no prior medical conditions, takes no medications, and is a lifelong nonsmoker. Physical examination shows decreased breath sounds on the left side. Chest x-ray reveals a large left-sided pleural effusion. Thoracentesis yields fluid with a large number of red blood cells and numerous atypical cells staining positive for mucin. Which of the following is the most likely primary mechanism of this patient's pleural effusion?

- A. Decreased plasma oncotic pressure (8%)
- ✕ B. Disruption of the thoracic lymphatic duct (23%)
- C. Increased intercostal venous pressure (5%)
- D. Increased pulmonary capillary pressure (20%)
- ✓ E. Occlusion of pleural lymphatic stoma (41%)

Incorrect
Correct answer
E

41%
Answered correctly

04 secs
Time Spent

2023
Version

Explanation

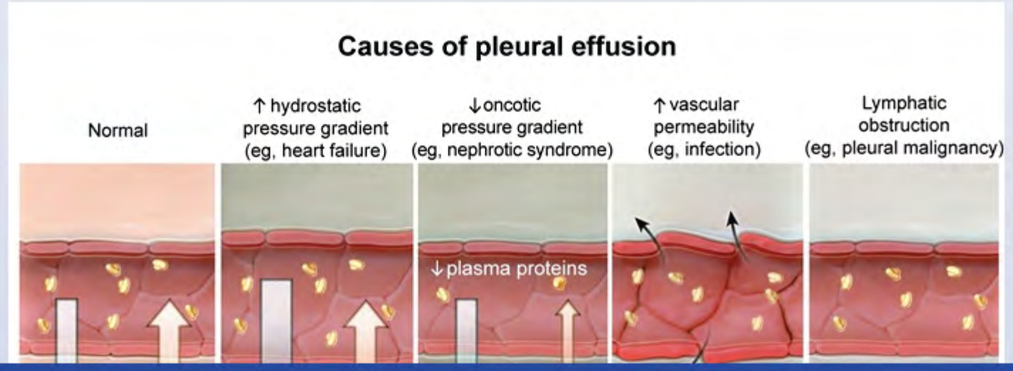

https://t.me/USMLEWorldStep1

A 54-year-old woman comes to the office due to worsening nonproductive cough and dyspnea for the past several
month
medic
breath
with a
followi

Inco
Corre
E

Expl

Exhibit Display

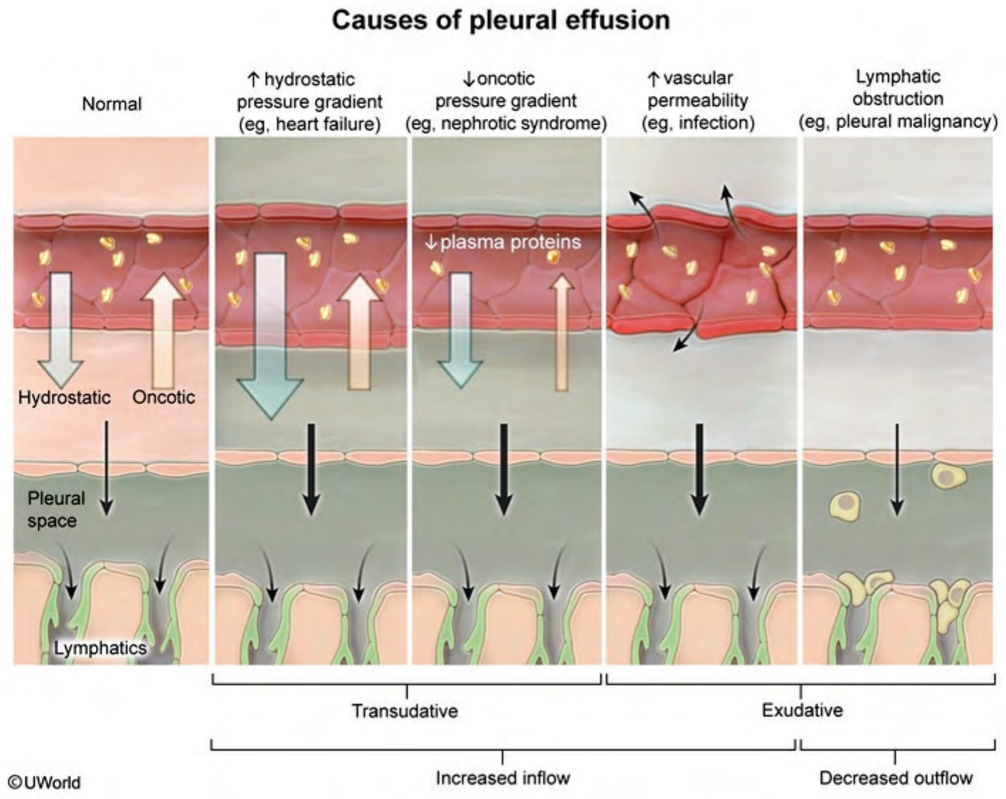

Zoom In | Zoom Out | Reset | New | Existing | My Notebook

https://t.me/USMLEWorldStep1



This patient's several-month history of nonproductive cough, shortness of breath, and weight loss combined with a large left-sided pleural effusion on chest x-ray raises suspicion for malignancy. Thoracentesis yielding a high erythrocyte concentration (a common finding in malignant effusions) and **atypical mucin cells** is consistent with **adenocarcinoma**; lung adenocarcinoma and breast adenocarcinoma are 2 of the most common causes of **malignant pleural effusion**.

Malignant effusions are **exudative** by Light criteria and can occur via several mechanisms:

- Localized lung inflammation can cause **increased vascular permeability**, resulting in **increased inflow of fluid** into the pleural space.
- Once malignant cells have metastasized to the pleural space, they can **occlude the pleural lymphatic stoma** located on the parietal surface and **prevent pleural fluid reabsorption**. This is likely the primary mechanism of effusion in this patient with evidence of pleural metastasis (ie, atypical mucin cells in pleural fluid).
- Disruption of the thoracic lymphatic duct is an occasional cause of malignant effusion that leads to a chylothorax (milky white pleural fluid with high triglyceride content). This mechanism is most commonly seen with lymphoma; it can sometimes occur due to mass effect of lung cancer on the thoracic duct, but this is relatively uncommon **(Choice B)**.

(Choice A) Decreased plasma oncotic pressure (ie, hypoalbuminemia) is a common cause of transudative pleural effusion. Although hypoalbuminemia due to malnutrition may complicate malignancy and could contribute to pleural effusion, it is unlikely to be the primary mechanism in this patient with evidence of pleural metastatic disease.

(Choices C and D) Increased hydrostatic pressure in the pulmonary capillaries and intercostal veins can cause transudative pleural effusion in patients with decompensated heart failure or other causes of intravascular volume overload (eg, renal failure).

https://t.me/USMLEWorldStep1

large left-sided pleural effusion on chest x-ray raises suspicion for malignancy. Thoracentesis yielding a high erythrocyte concentration (a common finding in malignant effusions) and **atypical mucin cells** is consistent with **adenocarcinoma**; lung adenocarcinoma and breast adenocarcinoma are 2 of the most common causes of **malignant pleural effusion**.

Malignant effusions are **exudative** by Light criteria and can occur via several mechanisms:

- Localized lung inflammation can cause **increased vascular permeability**, resulting in **increased inflow of fluid** into the pleural space.
- Once malignant cells have metastasized to the pleural space, they can **occlude the pleural lymphatic stoma** located on the parietal surface and **prevent pleural fluid reabsorption**. This is likely the primary mechanism of effusion in this patient with evidence of pleural metastasis (ie, atypical mucin cells in pleural fluid).
- Disruption of the thoracic lymphatic duct is an occasional cause of malignant effusion that leads to a chylothorax (milky white pleural fluid with high triglyceride content). This mechanism is most commonly seen with lymphoma; it can sometimes occur due to mass effect of lung cancer on the thoracic duct, but this is relatively uncommon **(Choice B)**.

(Choice A) Decreased plasma oncotic pressure (ie, hypoalbuminemia) is a common cause of transudative pleural effusion. Although hypoalbuminemia due to malnutrition may complicate malignancy and could contribute to pleural effusion, it is unlikely to be the primary mechanism in this patient with evidence of pleural metastatic disease.

(Choices C and D) Increased hydrostatic pressure in the pulmonary capillaries and intercostal veins can cause transudative pleural effusion in patients with decompensated heart failure or other causes of intravascular volume overload (eg, renal failure).

Educational objective:
Malignant pleural effusions are usually exudative by Light criteria and can occur via several mechanisms, including an inflammation-induced increase in vascular permeability (leading to increased inflow) and blockage of pleural fluid reabsorption by parietal pleura lymphatics (leading to decreased outflow).

https://t.me/USMLEWorldStep1

Exhibit Display

Exudative & transudative pleural effusions

	Exudate	Transudate
Light criteria	Pleural protein/serum protein >0.5 **OR** Pleural LDH/serum LDH >0.6 **OR** Pleural LDH greater than two-thirds upper limit of normal of serum LDH	Exudate criteria not met
Pathophysiology	Inflammatory increase in membrane permeability	Change in hydrostatic or oncotic pressure
Common causes	• Infection (eg, pneumonia, TB) • Malignancy • Rheumatologic disease	• Heart failure • Cirrhosis (hepatic hydrothorax) • Nephrotic syndrome

LDH = lactate dehydrogenase; **TB** = tuberculosis.

New | Existing | My Notebook

Educational objective:

https://t.me/USMLEWorldStep1

large left-sided pleural effusion on chest x-ray raises suspicion for malignancy. Thoracentesis yielding a high erythrocyte concentration (a common finding in malignant effusions) and **atypical mucin cells** is consistent with **adeno** **malig**

Malign

- L **fl**
- C **s** m fl
- D cl w re

(Choi effusic pleura diseas

(Choi transu overlo

Educa Malign an infl fluid reabsorption by parietal pleura lymphatics (leading to decreased outflow).

Exhibit Display

Exudative & transudative pleural effusions

	Exudate	Transudate
Light criteria	Pleural protein/serum protein >0.5 **OR** Pleural LDH/serum LDH >0.6 **OR** Pleural LDH greater than two-thirds upper limit of normal of serum LDH	Exudate criteria not met
Pathophysiology	Inflammatory increase in membrane permeability	Change in hydrostatic or oncotic pressure
Common causes	• Infection (eg, pneumonia, TB) • Malignancy • Rheumatologic disease	• Heart failure • Cirrhosis (hepatic hydrothorax) • Nephrotic syndrome

LDH = lactate dehydrogenase; **TB** = tuberculosis.

New | Existing | My Notebook

https://t.me/USMLEWorldStep1

A 15-year-old boy is evaluated for fever, headache, malaise, and cough 3 weeks after returning from summer camp. Lung auscultation is unremarkable. Chest x-ray reveals nodular infiltrates. The patient's blood samples are collected for analysis in anticoagulated tubes, which are transported submerged in ice; when taken out several minutes later, turbidity and clumping are noted. Warming the tube to body temperature leads to rapid dissolution of the clumps. Which of the following organisms is most likely responsible for this patient's condition?

- A. *Coccidioides immitis*
- B. *Coxiella burnetii*
- C. *Haemophilus influenzae*
- D. *Histoplasma capsulatum*
- E. *Klebsiella pneumoniae*
- F. *Legionella pneumophila*
- G. *Mycobacterium kansasii*
- H. *Mycoplasma pneumoniae*
- I. *Pneumocystis jirovecii*
- J. *Streptococcus pneumoniae*

Submit

https://t.me/USMLEWorldStep1

A 15-year-old boy is evaluated for fever, headache, malaise, and cough 3 weeks after returning from summer camp. Lung auscultation is unremarkable. Chest x-ray reveals nodular infiltrates. The patient's blood samples are collected for analysis in anticoagulated tubes, which are transported submerged in ice; when taken out several minutes later, turbidity and clumping are noted. Warming the tube to body temperature leads to rapid dissolution of the clumps. Which of the following organisms is most likely responsible for this patient's condition?

- A. *Coccidioides immitis* (2%)
- ✗ B. *Coxiella burnetii* (1%)
- C. *Haemophilus influenzae* (3%)
- D. *Histoplasma capsulatum* (4%)
- E. *Klebsiella pneumoniae* (1%)
- F. *Legionella pneumophila* (3%)
- G. *Mycobacterium kansasii* (1%)
- ✓ H. *Mycoplasma pneumoniae* (79%)
- I. *Pneumocystis jirovecii* (0%)
- J. *Streptococcus pneumoniae* (2%)

Incorrect
Correct answer
H

79%
Answered correctly

04 secs
Time Spent

2023
Version

Explanation

Mycoplasma pneumoniae infection is common in adolescents and usually presents with tracheobronchitis or walking pneumonia. The pathogen attaches to the respiratory epithelium using surface antigens (**I-antigen**) that are also present on the plasma membrane of erythrocytes. Therefore, patients with *M pneumoniae* typically

https://t.me/USMLEWorldStep1

I. *Pneumocystis jirovecii* (0%)

J. *Streptococcus pneumoniae* (2%)

Incorrect
Correct answer
H

79%
Answered correctly

04 secs
Time Spent

2023
Version

Explanation

Mycoplasma pneumoniae infection is common in adolescents and usually presents with tracheobronchitis or walking pneumonia. The pathogen attaches to the respiratory epithelium using surface antigens (**I-antigen**) that are also present on the plasma membrane of erythrocytes. Therefore, patients with *M pneumoniae* typically develop cross-reactive IgM antibodies that can attach to red blood cells, activate the complement system, and cause erythrocyte lysis. These cross-reacting antibodies are called **cold agglutinins** because they bind to erythrocytes most strongly at temperatures **below core body temperature**. Testing for cold agglutinins can be done at the bedside by drawing blood into an edetate disodium–containing tube and placing it in a cup of ice. Removing the tube after several seconds will reveal clumping/agglutination that resolves as the tube warms.

Cold agglutinins are often asymptomatic, but some patients develop mild intravascular **hemolytic anemia** that usually resolves after 6-8 weeks (when IgM antibody titers fall). Patients who have infectious mononucleosis and certain hematologic malignancies also commonly develop cold agglutinins.

Educational objective:
Infection with *Mycoplasma pneumoniae* can result in the formation of cold agglutinins, which are IgM antibodies (primarily) that bind red blood cells and cause clumping/agglutinations at low body temperatures. Other illnesses resulting in cold agglutinin formation include infectious mononucleosis and certain hematologic malignancies.

Microbiology	Pulmonary & Critical Care	Community acquired pneumonia
Subject	System	Topic

Copyright © UWorld. All rights reserved.

https://t.me/USMLEWorldStep1

I. *Pneumocystis jirovecii* (0%)

Exhibit Display

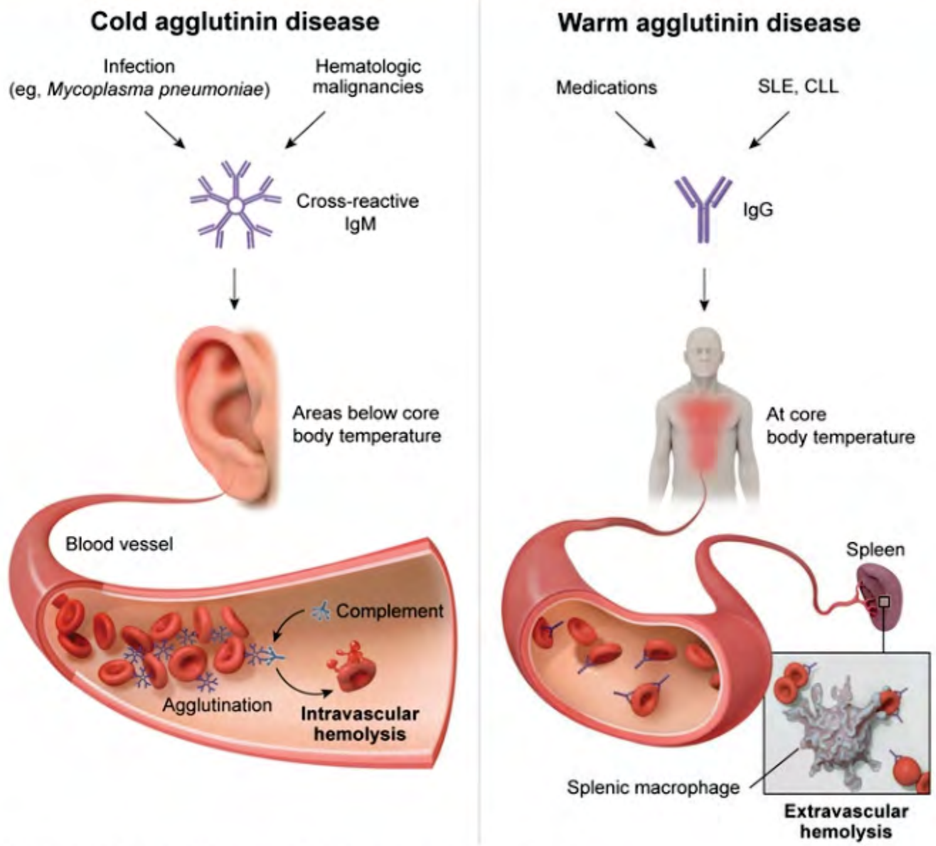

CLL = chronic lymphocytic leukemia; **SLE** = systemic lupus erythematosus.

©UWorld

Zoom In | Zoom Out | Reset | New | Existing | My Notebook

Copyright © UWorld. All rights reserved.

A 9-month-old girl is brought to the emergency department due to fever and cough. Her symptoms began approximately 2 days ago and have been worsening. The patient is otherwise healthy except for an episode of acute otitis media 3 weeks ago that resolved following a course of oral amoxicillin. She lives with her mother, father, and grandmother who have been in good health. Her mother smokes cigarettes. Temperature is 38.5 C (101.3 F) and respirations are 34/min. Pulse oximetry is 95% on room air. Pulmonary examination reveals mild subcostal retractions and focal crackles in the left lower lobe. Which of the following underlying factors is most likely contributing to this patient's current condition?

- A. Decreased presence of lung monocytes
- B. Exaggerated airway reactivity
- C. Impaired mucociliary function
- D. Inhibited B cell maturation
- E. Reduced alveolar surface area

Submit

https://t.me/USMLEWorldStep1

A 9-month-old girl is brought to the emergency department due to fever and cough. Her symptoms began approximately 2 days ago and have been worsening. The patient is otherwise healthy except for an episode of acute otitis media 3 weeks ago that resolved following a course of oral amoxicillin. She lives with her mother, father, and grandmother who have been in good health. Her mother smokes cigarettes. Temperature is 38.5 C (101.3 F) and respirations are 34/min. Pulse oximetry is 95% on room air. Pulmonary examination reveals mild subcostal retractions and focal crackles in the left lower lobe. Which of the following underlying factors is most likely contributing to this patient's current condition?

- A. Decreased presence of lung monocytes (5%)
- ✗ B. Exaggerated airway reactivity (16%)
- ✓ C. Impaired mucociliary function (56%)
- D. Inhibited B cell maturation (14%)
- E. Reduced alveolar surface area (7%)

Incorrect
Correct answer
C

56%
Answered correctly

04 mins, 15 secs
Time Spent

2023
Version

Explanation

Risks of secondhand smoke exposure in children	
Risks	**Pathophysiology**
Respiratory disease (eg, pneumonia, asthma)	• Impaired mucociliary clearance of respiratory tract • Impaired phagocytosis by alveolar macrophages • Immune & inflammatory cell recruitment to lung tissue
Recurrent otitis media	• Impaired mucociliary clearance of eustachian tube

https://t.me/USMLEWorldStep1

Risks of secondhand smoke exposure in children	
Risks	**Pathophysiology**
Respiratory disease (eg, pneumonia, asthma)	• Impaired mucociliary clearance of respiratory tract • Impaired phagocytosis by alveolar macrophages • Immune & inflammatory cell recruitment to lung tissue
Recurrent otitis media	• Impaired mucociliary clearance of eustachian tube
Prematurity & low birth weight	• Transplacental exposure to components of tobacco smoke
Sudden infant death syndrome	• Likely related to impaired arousal & cardiovascular responses to stimuli

This patient has fever, cough, and focal crackles, which are findings consistent with **pneumonia**. Transmission typically occurs via droplet spread of a bacterium (eg, *Streptococcus pneumoniae*) with subsequent colonization of the nasopharynx and microaspiration into the lungs.

Respiratory defense mechanisms often prevent infection of the lower respiratory tract, and the first line of defense is the ciliated epithelium and mucus-producing cells that line the respiratory tract. Pathogens become entrapped in mucus and are transported upward and out of the nasopharynx by the sweeping cilia. Other defense mechanisms include binding by immunoglobulin (eg, secretory IgA, opsonizing IgG and IgM), phagocytosis by alveolar and interstitial macrophages, and cell-mediated cytotoxic activity.

Secondhand smoke exposure disrupts natural host defenses and increases the risk of pneumonia, particularly in **infants** who have a parent that smokes. Cigarette smoke induces mucus overproduction and **impairs ciliary function**, leading to delayed clearance of pathogens and respiratory secretions. In addition to respiratory infections, children with secondhand smoke exposure are also at increased risk for **asthma** and wheezing and are more likely to have **recurrent otitis media**.

(Choice A) A decreased number of monocytes may occur with bone marrow dysfunction, which would typically

https://t.me/USMLEWorldStep1

This patient has fever, cough, and focal crackles, which are findings consistent with **pneumonia**. Transmission typically occurs via droplet spread of a bacterium (eg, *Streptococcus pneumoniae*) with subsequent colonization of the nasopharynx and microaspiration into the lungs.

Respiratory defense mechanisms often prevent infection of the lower respiratory tract, and the first line of defense is the ciliated epithelium and mucus-producing cells that line the respiratory tract. Pathogens become entrapped in mucus and are transported upward and out of the nasopharynx by the sweeping cilia. Other defense mechanisms include binding by immunoglobulin (eg, secretory IgA, opsonizing IgG and IgM), phagocytosis by alveolar and interstitial macrophages, and cell-mediated cytotoxic activity.

Secondhand smoke exposure disrupts natural host defenses and increases the risk of pneumonia, particularly in **infants** who have a parent that smokes. Cigarette smoke induces mucus overproduction and **impairs ciliary function**, leading to delayed clearance of pathogens and respiratory secretions. In addition to respiratory infections, children with secondhand smoke exposure are also at increased risk for **asthma** and wheezing and are more likely to have **recurrent otitis media**.

(Choice A) A decreased number of monocytes may occur with bone marrow dysfunction, which would typically cause severe, disseminated infections (not seen in this patient). In addition, although the phagocytic function of alveolar macrophages (differentiated type of monocyte) is impaired in patients with cigarette smoke exposure, these cells are typically present in increased (not decreased) numbers.

(Choice B) Although cigarette smoke exposure is associated with increased risk of asthma, airway hyperreactivity causes bronchoconstriction and wheezing, not pneumonia as seen in this patient.

(Choice D) Inhibited B cell maturation, as seen with X-linked agammaglobulinemia, typically presents with recurrent sinopulmonary infections in young boys, not girls. In addition, cigarette smoke can increase (not decrease) IgE production due to allergic sensitization.

(Choice E) Reduced alveolar surface area occurs with emphysema, which is a late lung finding in patients who smoke. Emphysema would not be present in infancy and does not cause pneumonia.

Educational objective:
Infants with secondhand smoke exposure are at increased risk for pneumonia because cigarette smoke affects

https://t.me/USMLEWorldStep1

typically occurs via droplet spread of a bacterium (eg, *Streptococcus pneumoniae*) with subsequent colonization of the nasopharynx and microaspiration into the lungs.

Respiratory defense mechanisms often prevent infection of the lower respiratory tract, and the first line of defense is the ciliated epithelium and mucus-producing cells that line the respiratory tract. Pathogens become entrapped in mucus and are transported upward and out of the nasopharynx by the sweeping cilia. Other defense mechanisms include binding by immunoglobulin (eg, secretory IgA, opsonizing IgG and IgM), phagocytosis by alveolar and interstitial macrophages, and cell-mediated cytotoxic activity.

Secondhand smoke exposure disrupts natural host defenses and increases the risk of pneumonia, particularly in **infants** who have a parent that smokes. Cigarette smoke induces mucus overproduction and **impairs ciliary function**, leading to delayed clearance of pathogens and respiratory secretions. In addition to respiratory infections, children with secondhand smoke exposure are also at increased risk for **asthma** and wheezing and are more likely to have **recurrent otitis media**.

(Choice A) A decreased number of monocytes may occur with bone marrow dysfunction, which would typically cause severe, disseminated infections (not seen in this patient). In addition, although the phagocytic function of alveolar macrophages (differentiated type of monocyte) is impaired in patients with cigarette smoke exposure, these cells are typically present in increased (not decreased) numbers.

(Choice B) Although cigarette smoke exposure is associated with increased risk of asthma, airway hyperreactivity causes bronchoconstriction and wheezing, not pneumonia as seen in this patient.

(Choice D) Inhibited B cell maturation, as seen with X-linked agammaglobulinemia, typically presents with recurrent sinopulmonary infections in young boys, not girls. In addition, cigarette smoke can increase (not decrease) IgE production due to allergic sensitization.

(Choice E) Reduced alveolar surface area occurs with emphysema, which is a late lung finding in patients who smoke. Emphysema would not be present in infancy and does not cause pneumonia.

Educational objective:
Infants with secondhand smoke exposure are at increased risk for pneumonia because cigarette smoke affects alveolar macrophage function and impairs mucociliary clearance.

References

https://t.me/USMLEWorldStep1

death syndrome	• Likely related to impaired arousal & cardiovascular responses to stimuli

This p
typical
the na

Respir
is the
mucus
includ
interst

Secon
infant
functi
infecti
more l

(Choi
cause
alveol
these

(Choi
cause

(Choi
recurr
decrea

(Choi
smoke. Emphysema would not be present in infancy and does not cause pneumonia.

Educational objective:

Exhibit Display

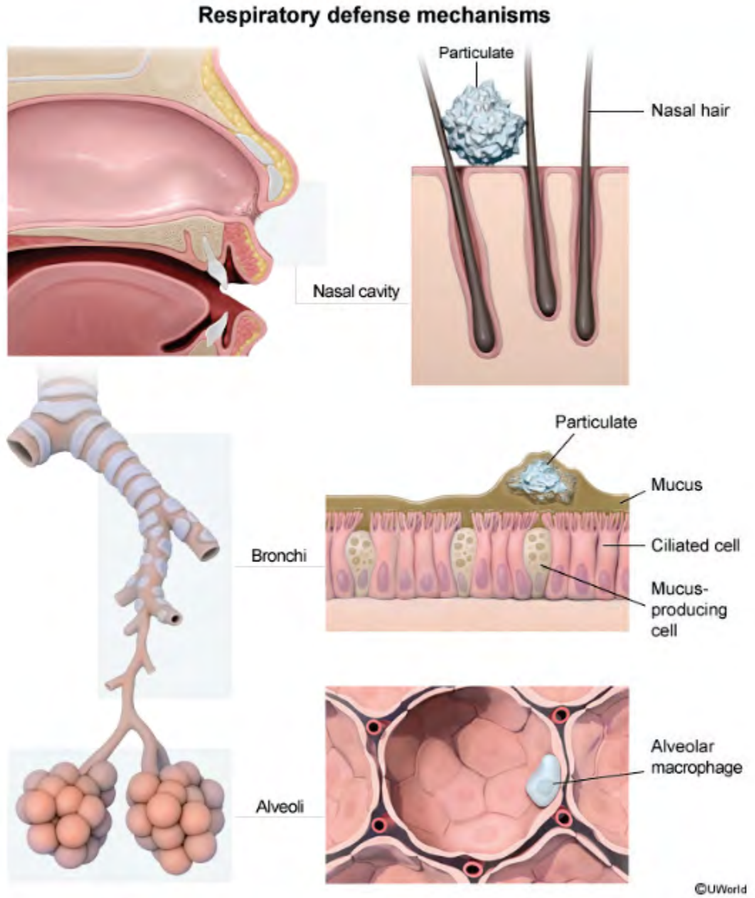

Zoom In Zoom Out Reset New | Existing My Notebook

https://t.me/USMLEWorldStep1

An 18-year-old, previously healthy man comes to the emergency department after being stabbed in the chest. The patient reports shortness of breath. Blood pressure is 136/84 mm Hg, pulse is 96/min, and respirations are 20/min. Oxygen saturation is 96%. Physical examination reveals a 2.5-cm stab wound on the right lateral chest wall. Breath sounds are decreased on the right side. Chest x-ray is shown in the exhibit. Which of the following changes have most likely occurred in this patient's right hemithorax and right lung compared to his preinjury state?

	Hemithorax volume	Inspiratory lung compliance
A.	Decreased	Increased
B.	Decreased	No change
C.	Increased	Decreased
D.	No change	Decreased
E.	No change	Increased

Submit

https://t.me/USMLEWorldStep1

An 18-year-old, previously healthy man comes to the emergency department after being stabbed in the chest. The
patien
20/mir
wall. E
chang

Sub

Exhibit Display

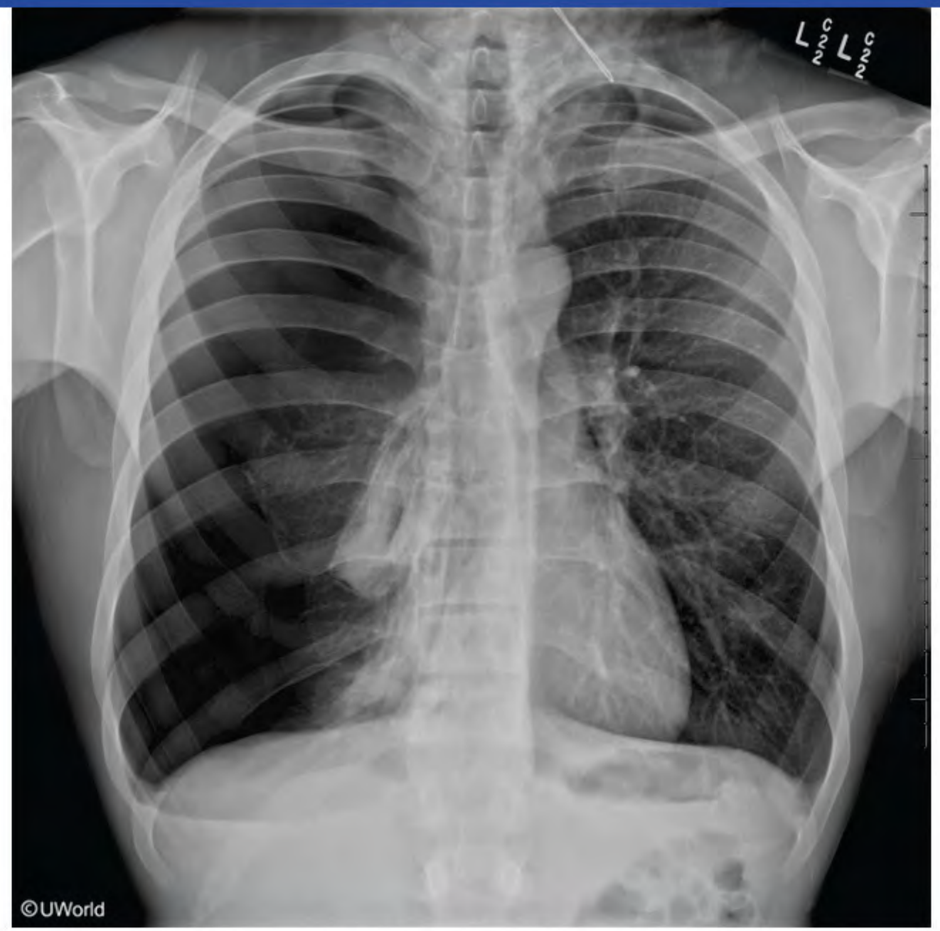

Zoom In | Zoom Out | Reset | New | Existing | My Notebook

https://t.me/USMLEWorldStep1

An 18-year-old, previously healthy man comes to the emergency department after being stabbed in the chest. The patient reports shortness of breath. Blood pressure is 136/84 mm Hg, pulse is 96/min, and respirations are 20/min. Oxygen saturation is 96%. Physical examination reveals a 2.5-cm stab wound on the right lateral chest wall. Breath sounds are decreased on the right side. Chest x-ray is shown in the exhibit. Which of the following changes have most likely occurred in this patient's right hemithorax and right lung compared to his preinjury state?

		Hemithorax volume	Inspiratory lung compliance	
	A.	Decreased	Increased	(5%)
	B.	Decreased	No change	(5%)
✓	C.	Increased	Decreased	(55%)
	D.	No change	Decreased	(30%)
	E.	No change	Increased	(2%)

Correct

55%
Answered correctly

01 min, 05 secs
Time Spent

2023
Version

Explanation

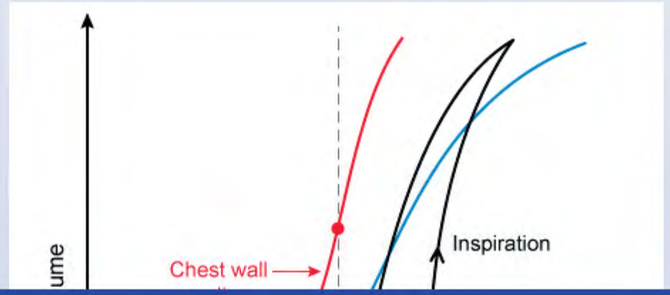

https://t.me/USMLEWorldStep1

B. Decreased No change (5%)

Exhibit Display

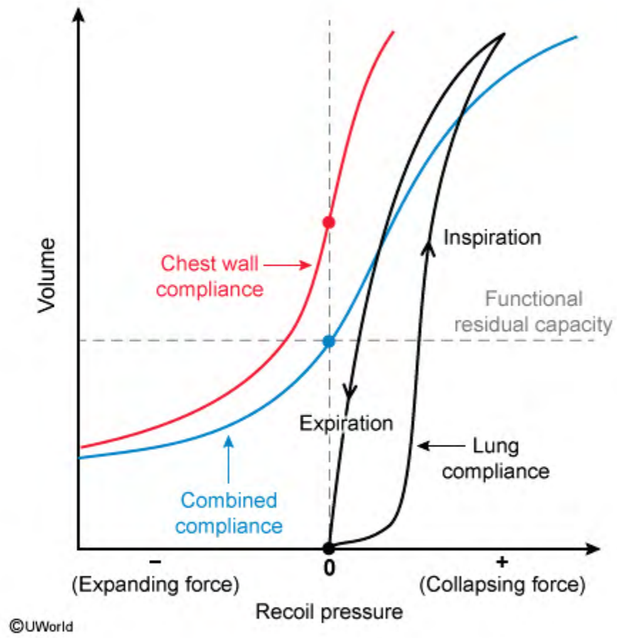

Zoom In Zoom Out Reset New | Existing My Notebook

This patient's chest x-ray shows no peripheral lung markings on the right side and a tissue mass representing the

https://t.me/USMLEWorldStep1

©UWorld

Recoil pressure

This patient's chest x-ray shows no peripheral lung markings on the right side and a tissue mass representing the collapsed right lung, findings consistent with **pneumothorax**; the stab wound likely breached the chest wall and pleura, allowing air to enter the intrapleural space.

The **lungs exert collapsing force** at all lung volumes, and the **chest wall exerts expanding force** at all but very high lung volumes. In the normal respiratory system, the lung and chest wall are in equilibrium (represented by the blue dot) at the functional residual capacity (FRC), and they move in concert throughout the respiratory cycle with the opposing forces working together to **maintain negative intrapleural pressure**.

When an abnormal communication pathway is created between the lung (or exterior chest) and the intrapleural space, intrapleural pressure equalizes with alveolar (ie, atmospheric) pressure, resulting in **loss of intrapleural negative pressure**. With the lung and chest wall no longer pulling each other in opposite directions, the chest wall springs outward to its equilibrium position (red dot), **increasing hemithorax volume**.

Loss of negative intrapleural pressure also causes the **lung to collapse** toward its equilibrium position (black dot). Compliance is defined as change in volume per change in pressure and is represented by the slope of the pressure-volume curve (eg, high compliance is illustrated by a steep-sloping curve). Lung compliance demonstrates hysteresis (ie, compliance differs during inspiration and expiration) due to the effects of alveolar surface tension. The flatness of the **inspiratory lung compliance** curve at very low lung volumes reflects the difficulty in inflating a collapsed lung and represents **decreased** compliance compared to that at the FRC.

Educational objective:
The lungs exert collapsing force, and the resting chest wall exerts expanding force. These opposing forces are in equilibrium at the functional residual capacity and generate sustained intrapleural negative pressure that allows the lung and chest wall to move together as a combined respiratory unit. Loss of intrapleural negative pressure (eg, pneumothorax) disrupts the combined system, causing the chest wall to spring outward to its equilibrium position, enlarging the hemithorax. Similarly, the lung collapses to its equilibrium position where inspiratory compliance is decreased.

References

- Physiology, pulmonary.

https://t.me/USMLEWorldStep1

©UWorld

Recoil pressure

This p
collaps
pleura

The **lu**
high lu
blue d
the op

When
space
negati
spring

Loss c
Compl
pressu
demor
surfac
difficul

Educa
The lu
equilib
lung a
pneum
enlarg
decrea

References

- Physiology, pulmonary

Exhibit Display

Large right pneumothorax

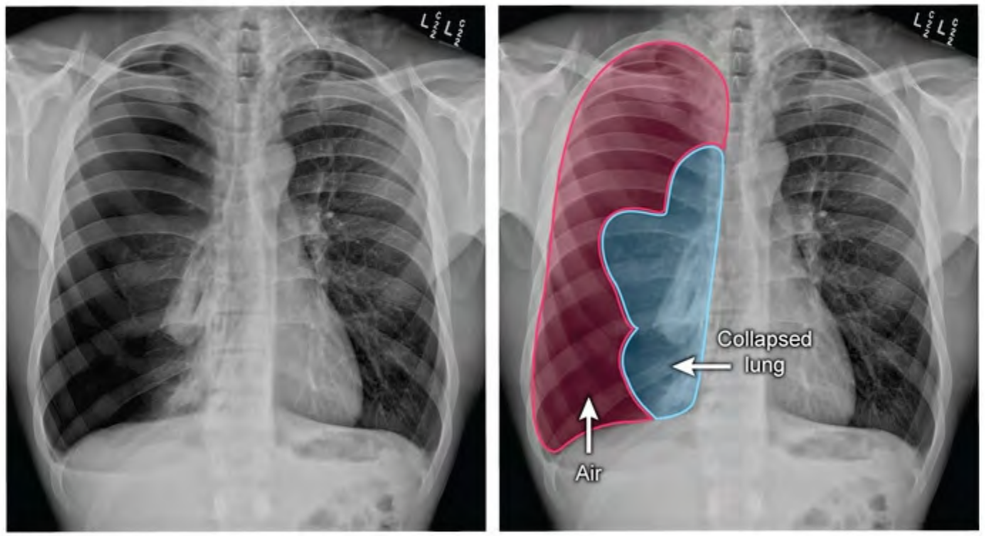

©UWorld

Zoom In | Zoom Out | Reset | New | Existing | My Notebook

https://t.me/USMLEWorldStep1

©UWorld

Recoil pressure

This p
collaps
pleura

The **lu**
high lu
blue d
the op

When
space
negati
spring

Loss c
Compl
pressu
demor
surfac
difficul

Educa
The lu
equilib
lung a
pneum
enlarg
decrea

References

- Physiology, pulmonary.

Exhibit Display

Pneumothorax | Pneumothorax

Traumatic open pneumothorax

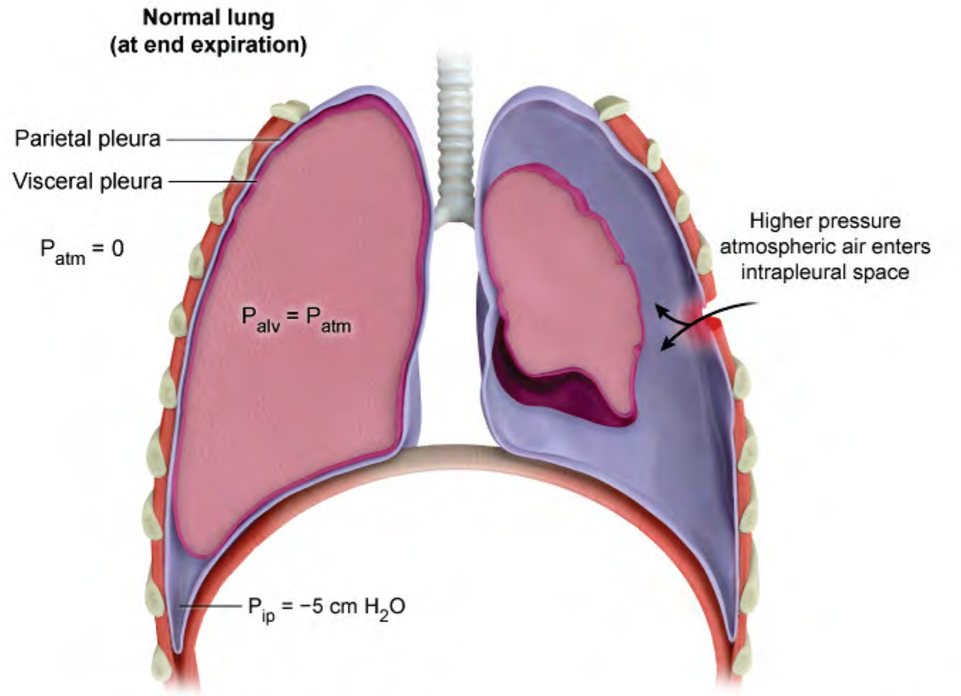

P_{atm} = atmospheric pressure; P_{alv} = alveolar pressure; P_{ip} = intrapleural pressure

©UWorld

Zoom In | Zoom Out | Reset | New | Existing | My Notebook

https://t.me/USMLEWorldStep1

©UWorld

Recoil pressure

This p
collaps
pleura

The **lu**
high lu
blue d
the op

When
space
negati
spring

Loss c
Compl
pressu
demor
surfac
difficul

Educa
The lu
equilib
lung a
pneum
enlarg
decrea

References

- Physiology, pulmonary.

Exhibit Display

Pneumothorax | Pneumothorax

Traumatic closed pneumothorax

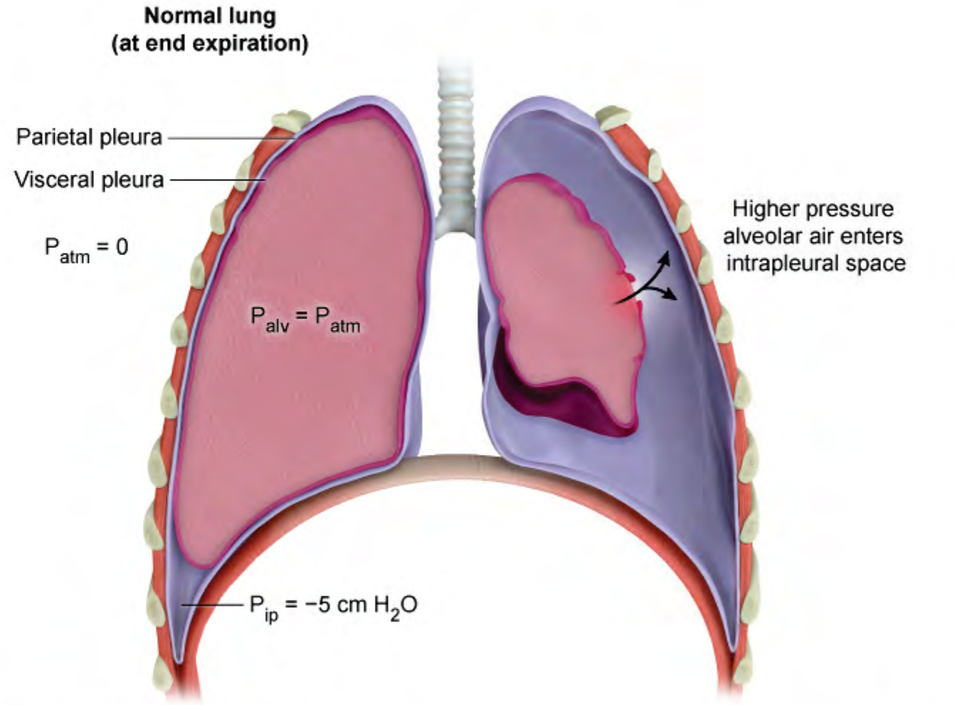

P_{atm} = atmospheric pressure; P_{alv} = alveolar pressure; P_{ip} = intrapleural pressure

©UWorld

Zoom In | Zoom Out | Reset | New | Existing | My Notebook

https://t.me/USMLEWorldStep1

A 68-year-old man is evaluated in the hospital due to a pleural effusion. He has a history of base of tongue squamous cell carcinoma with involvement of multiple left anterior cervical lymph nodes. Two days ago, the patient underwent surgery to remove the tumor and the anterior cervical lymph nodes. Today, he has increasing shortness of breath, and chest x-ray reveals a large left pleural effusion. Which of the following was most likely injured during this patient's surgical procedure?

- A. Esophagus
- B. Innominate artery
- C. Lung parenchyma
- D. Phrenic nerve
- E. Thoracic duct
- F. Trachea

Submit

https://t.me/USMLEWorldStep1

A 68-year-old man is evaluated in the hospital due to a pleural effusion. He has a history of base of tongue squamous cell carcinoma with involvement of multiple left anterior cervical lymph nodes. Two days ago, the patient underwent surgery to remove the tumor and the anterior cervical lymph nodes. Today, he has increasing shortness of breath, and chest x-ray reveals a large left pleural effusion. Which of the following was most likely injured during this patient's surgical procedure?

- ✗ A. Esophagus (1%)
- B. Innominate artery (3%)
- C. Lung parenchyma (13%)
- D. Phrenic nerve (20%)
- ✓ E. Thoracic duct (59%)
- F. Trachea (3%)

Incorrect
Correct answer
E

59%
Answered correctly

04 secs
Time Spent

2023
Version

Explanation

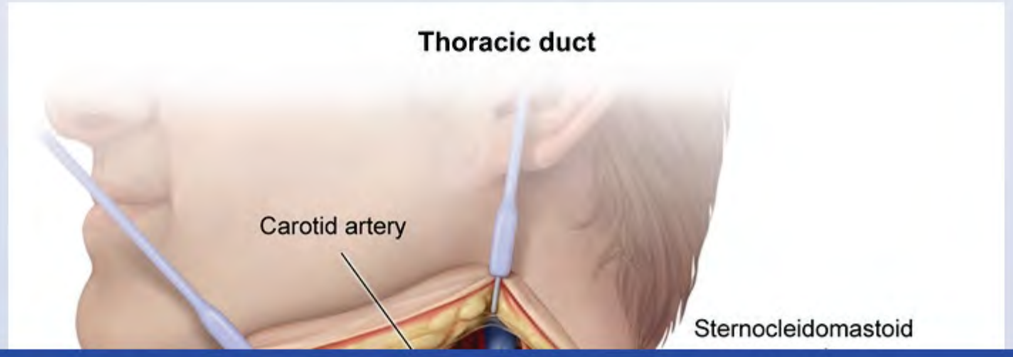

https://t.me/USMLEWorldStep1

D. Phrenic nerve (20%)

Exhibit Display

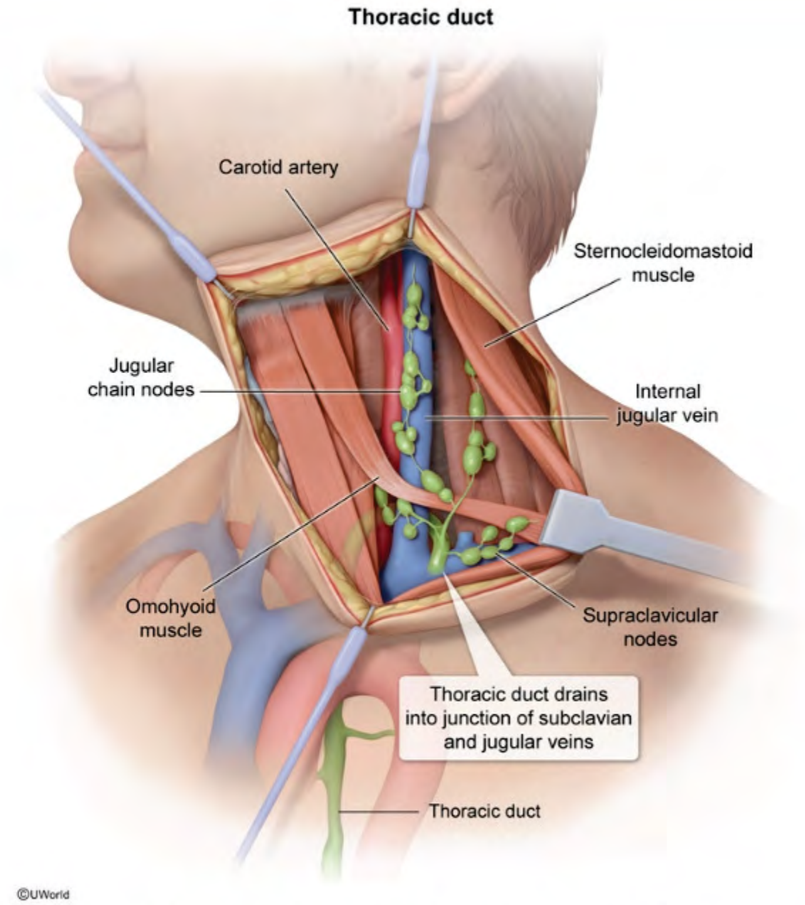

Zoom In | Zoom Out | Reset | New | Existing | My Notebook

https://t.me/USMLEWorldStep1

This patient with a pleural effusion 2 days after cervical lymph node removal most likely has a **chylothorax** due to intraoperative injury of the **thoracic duct**.

The thoracic duct is the largest lymphatic vessel. It originates at about the level of T12 in the abdomen where the lumbar and intestinal lymph trunks converge. It travels superiorly through the mediastinum (posterior to the esophagus) and drains into the **junction between the left subclavian and jugular veins** in the lower neck. It is most commonly injured during **thoracic procedures** (eg, esophagectomy) but can be injured in neck procedures as well (eg, cervical lymph node removal). Injury can result in leakage of lymph into either the neck or the thorax because a transected duct may retract into the chest.

The thoracic duct collects lymph from most of the body, including the abdominal viscera, the viscera of the left hemithorax, all tissue inferior to the umbilicus, and all left-sided tissues superior to the umbilicus (the right head, arm, and thorax drain into the much smaller right lymphatic duct).

(Choices A and F) The trachea and esophagus are deeper structures in the central neck that are covered by strap muscles; they are unlikely to be injured during removal of cervical lymph nodes in the lateral neck. In addition, although injury to the esophagus or trachea can cause pleural effusion, such injury is typically accompanied by air accumulation (eg, crepitus in the neck and/or pneumomediastinum).

(Choice B) The innominate artery is the first branch of the aortic arch, and it crosses the midtrachea from left to right (in the thorax). It does not travel through the left neck. In addition, injury to the innominate artery would cause massive blood loss, resulting in immediate hemodynamic instability.

(Choice C) The apex of the lung can project into the neck and be injured in some neck surgical procedures. However, injury would cause an acute pneumothorax rather than a slowly accumulating pleural effusion.

(Choice D) The phrenic nerve, which originates from C3-C5 and travels with the internal jugular vein, can be injured during neck procedures. However, such an injury would present with elevation of the hemidiaphragm.

Educational objective:
The thoracic duct carries lymph from most of the body and drains into the junction between the left subclavian and jugular veins. Although most commonly injured in thoracic procedures, it can also be injured in neck procedures where it travels through the neck. Injury may result in a chylothorax.

https://t.me/USMLEWorldStep1

A 71-year-old man with a long history of smoking is found to have a new, 4-cm, irregular, spiculated, rounded mass in the right upper lobe. CT-guided biopsy is performed. Follow-up chest x-ray after the procedure is shown in the exhibit. Physical examination of the right lung would most likely show which of the following findings?

	Percussion	Tactile fremitus	Breath sounds
○ A.	Dullness	Decreased	Decreased
○ B.	Dullness	Increased	Bronchial
○ C.	Dullness	Increased	Decreased
○ D.	Hyperresonance	Decreased	Bronchial
○ E.	Hyperresonance	Decreased	Decreased
○ F.	Hyperresonance	Decreased	Increased
○ G.	Resonance	Normal	Vesicular

Submit

https://t.me/USMLEWorldStep1

A 71-year-old man with a long history of smoking is found to have a new, 4-cm, irregular, spiculated, rounded mass in the
exhibit

Sub

Exhibit Display

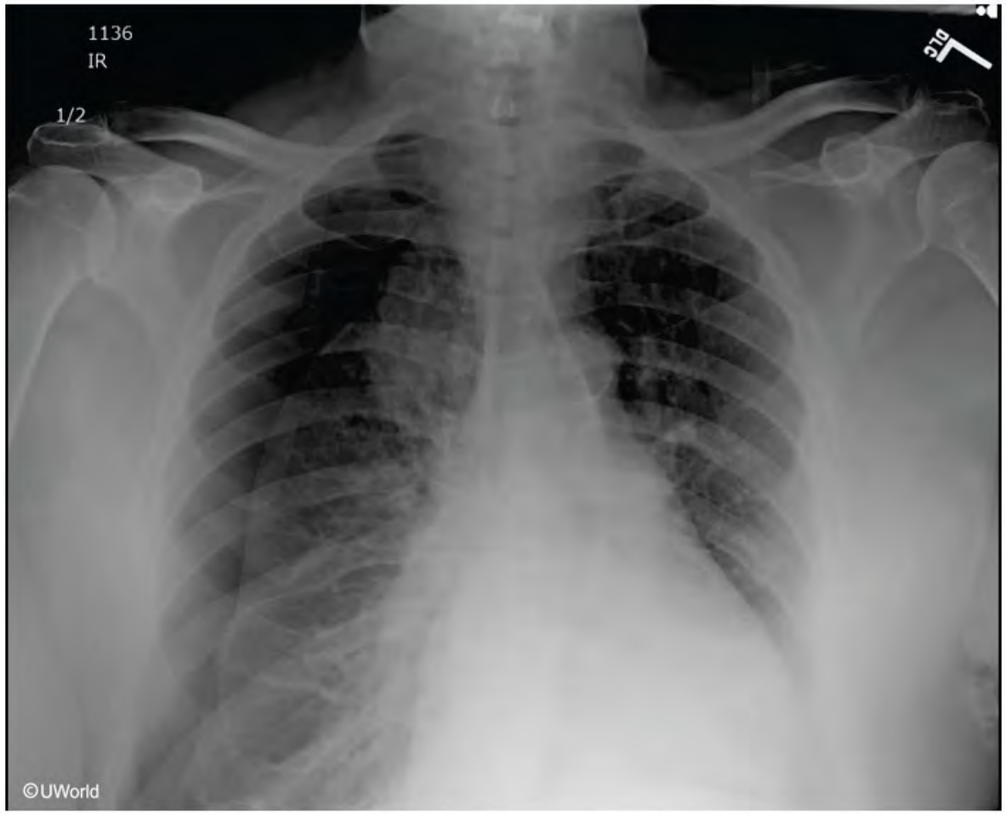

Zoom In Zoom Out Reset New | Existing My Notebook

https://t.me/USMLEWorldStep1

A 71-year-old man with a long history of smoking is found to have a new, 4-cm, irregular, spiculated, rounded mass in the right upper lobe. CT-guided biopsy is performed. Follow-up chest x-ray after the procedure is shown in the exhibit. Physical examination of the right lung would most likely show which of the following findings?

		Percussion	Tactile fremitus	Breath sounds	
	A.	Dullness	Decreased	Decreased	(14%)
	B.	Dullness	Increased	Bronchial	(4%)
✗	C.	Dullness	Increased	Decreased	(8%)
	D.	Hyperresonance	Decreased	Bronchial	(2%)
✓	E.	Hyperresonance	Decreased	Decreased	(65%)
	F.	Hyperresonance	Decreased	Increased	(1%)
	G.	Resonance	Normal	Vesicular	(1%)

Incorrect
Correct answer
E

65%
Answered correctly

12 secs
Time Spent

2023
Version

Explanation

Pulmonary auscultation examination findings			
Condition	**Breath sounds**	**Tactile fremitus**	**Percussion**
Normal lung	Normal	Normal	Resonance
Consolidation	Increased	Increased	Dullness

https://t.me/USMLEWorldStep1

Pulmonary auscultation examination findings			
Condition	**Breath sounds**	**Tactile fremitus**	**Percussion**
Normal lung	Normal	Normal	Resonance
Consolidation	Increased	Increased	Dullness
Pleural effusion	Decreased or absent	Decreased	Dullness
Pneumothorax	Decreased or absent	Decreased	Hyperresonance
Atelectasis	Decreased or absent	Decreased	Dullness

This patient's chest x-ray after lung biopsy shows a right **pneumothorax**, which is recognized by the **continuous line** in the right lung field with **no visible lung markings** peripheral to it. This line is the outer edge of the collapsed right lung; the dark space peripheral to the lung represents air in the chest cavity.

The following characteristic physical examination findings are expected with pneumothorax:

- Tactile fremitus represents airway vibrations generated by vocalized sound (eg, saying "ninety-nine") and is measured by the examiner placing hands on the patient's back. Because air in the chest cavity insulates and dampens airway vibrations before they reach the patient's back, **decreased tactile fremitus** is expected **(Choice C)**.
- Breath sounds are caused by air movement within the airways, and the intensity varies by lung location. Vesicular breath sounds are normal over the periphery; bronchial breath sounds are higher-intensity sounds that are normal over the hilum but indicate pathology (eg, lobar consolidation) over the periphery. Because the lung is partially collapsed, leading to less air movement, and sounds from the airways are insulated by air in the chest cavity, **decreased breath sound intensity** is expected **(Choices D and F)**.

https://t.me/USMLEWorldStep1

This patient's chest x-ray after lung biopsy shows a right **pneumothorax**, which is recognized by the **continuous line** in the right lung field with **no visible lung markings** peripheral to it. This line is the outer edge of the collapsed right lung; the dark space peripheral to the lung represents air in the chest cavity.

The following characteristic physical examination findings are expected with pneumothorax:

- Tactile fremitus represents airway vibrations generated by vocalized sound (eg, saying "ninety-nine") and is measured by the examiner placing hands on the patient's back. Because air in the chest cavity insulates and dampens airway vibrations before they reach the patient's back, **decreased tactile fremitus** is expected **(Choice C)**.
- Breath sounds are caused by air movement within the airways, and the intensity varies by lung location. Vesicular breath sounds are normal over the periphery; bronchial breath sounds are higher-intensity sounds that are normal over the hilum but indicate pathology (eg, lobar consolidation) over the periphery. Because the lung is partially collapsed, leading to less air movement, and sounds from the airways are insulated by air in the chest cavity, **decreased breath sound intensity** is expected **(Choices D and F)**.
- Resonance refers to the frequency of sound generated by percussion, and it varies with density. Because air alone is less dense than a composite of lung parenchyma and air (ie, normal lung), higher-than-normal sound frequency to percussion (ie, **hyperresonance**) is expected.

(Choice A) Like pneumothorax, fluid in the chest cavity (ie, pleural effusion) insulates airway vibrations and sounds, causing decreased tactile fremitus and breath sound intensity. However, because fluid is more dense than normal lung, dullness to percussion is expected. Atelectasis generates findings similar to those of pleural effusion; the collapsed lung reduces air movement and vibration within the airways, and the airless lung parenchyma is more dense than normal, air-filled lung.

(Choice B) Consolidated, fluid-filled lung (eg, lobar pneumonia) is more dense than normal lung. This leads to increased transmission of vibration and sound (ie, increased tactile fremitus and breath sound intensity) and dullness to percussion.

(Choice G) Normal lung demonstrates resonance to percussion, baseline tactile fremitus, and vesicular (normal-intensity) breath sounds.

https://t.me/USMLEWorldStep1

measured by the examiner placing hands on the patient's back. Because air in the chest cavity insulates and dampens airway vibrations before they reach the patient's back, **decreased tactile fremitus** is expected **(Choice C)**.

- Breath sounds are caused by air movement within the airways, and the intensity varies by lung location. Vesicular breath sounds are normal over the periphery; bronchial breath sounds are higher-intensity sounds that are normal over the hilum but indicate pathology (eg, lobar consolidation) over the periphery. Because the lung is partially collapsed, leading to less air movement, and sounds from the airways are insulated by air in the chest cavity, **decreased breath sound intensity** is expected **(Choices D and F)**.
- Resonance refers to the frequency of sound generated by percussion, and it varies with density. Because air alone is less dense than a composite of lung parenchyma and air (ie, normal lung), higher-than-normal sound frequency to percussion (ie, **hyperresonance**) is expected.

(Choice A) Like pneumothorax, fluid in the chest cavity (ie, pleural effusion) insulates airway vibrations and sounds, causing decreased tactile fremitus and breath sound intensity. However, because fluid is more dense than normal lung, dullness to percussion is expected. Atelectasis generates findings similar to those of pleural effusion; the collapsed lung reduces air movement and vibration within the airways, and the airless lung parenchyma is more dense than normal, air-filled lung.

(Choice B) Consolidated, fluid-filled lung (eg, lobar pneumonia) is more dense than normal lung. This leads to increased transmission of vibration and sound (ie, increased tactile fremitus and breath sound intensity) and dullness to percussion.

(Choice G) Normal lung demonstrates resonance to percussion, baseline tactile fremitus, and vesicular (normal-intensity) breath sounds.

Educational objective:
Pneumothorax is recognized on chest x-ray by a continuous line without lung markings peripheral to it. Decreased tactile fremitus, decreased breath sound intensity, and hyperresonance to percussion are expected on physical examination.

Pathophysiology Pulmonary & Critical Care Pneumothorax

https://t.me/USMLEWorldStep1

Pneumothorax	or absent	Decreased	Hyperresonance

Exhibit Display

This p
line in
collaps

The fo

- T
m
d
(
- B
V
th
th
in
- R
a
fr

(Choi
sound
norma
the co
more

(Choice B) Consolidated, fluid-filled lung (eg, lobar pneumonia) is more dense than normal lung. This leads to

Pneumothorax

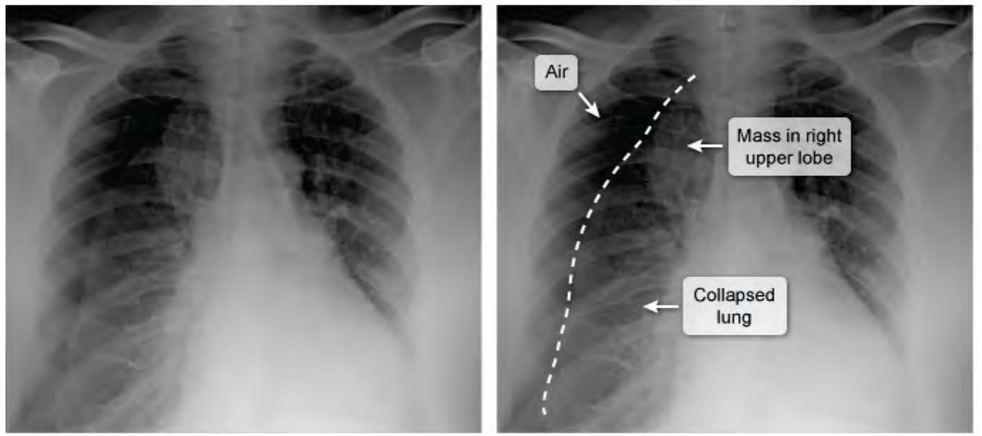

©UWorld

Zoom In | Zoom Out | Reset | New | Existing | My Notebook

https://t.me/USMLEWorldStep1

A 36-year-old man is hospitalized due to worsening fever, productive cough, and shortness of breath. He has no prior medical conditions but experienced an influenza-like illness during the previous week. Temperature is 38.3 C (102 F), blood pressure is 100/50 mm Hg, pulse is 122/min, and respirations are 26/min. Pulse oxymetry is 86% on room air. On physical examination, the patient is ill-appearing and lethargic. There are crackles over the right lower lung. Leukocyte count is 20,000 cells/mm^3. Chest imaging reveals extensive parenchymal consolidation and cavitations suggestive of abscesses in the right middle and lower lobes. The patient is endotracheally intubated for mechanical ventilation due to worsening respiratory failure. Culture of the tracheal aspirate grows gram-positive cocci in clusters. Which of the following bacterial virulence factors most likely contributed to this patient's necrotizing infection?

- A. Leukocidin
- B. Lipooligosaccharide
- C. M protein
- D. Polysaccharide capsule

Submit

https://t.me/USMLEWorldStep1

A 36-year-old man is hospitalized due to worsening fever, productive cough, and shortness of breath. He has no prior medical conditions but experienced an influenza-like illness during the previous week. Temperature is 38.3 C (102 F), blood pressure is 100/50 mm Hg, pulse is 122/min, and respirations are 26/min. Pulse oxymetry is 86% on room air. On physical examination, the patient is ill-appearing and lethargic. There are crackles over the right lower lung. Leukocyte count is 20,000 cells/mm^3. Chest imaging reveals extensive parenchymal consolidation and cavitations suggestive of abscesses in the right middle and lower lobes. The patient is endotracheally intubated for mechanical ventilation due to worsening respiratory failure. Culture of the tracheal aspirate grows gram-positive cocci in clusters. Which of the following bacterial virulence factors most likely contributed to this patient's necrotizing infection?

- ✓ A. Leukocidin (42%)
- B. Lipooligosaccharide (13%)
- C. M protein (15%)
- D. Polysaccharide capsule (29%)

Correct | 42% Answered correctly | 01 min, 09 secs Time Spent | 2023 Version

Explanation

Young, healthy individuals with recent influenza infection are at risk for rapidly progressive, **necrotizing pneumonia** (eg, pulmonary cavitations/abscesses) due to infection with ***Staphylococcus aureus***, a gram-positive cocci that grows in grapelike clusters. *S aureus* colonizes the nares and skin of up to 30% of individuals in the community setting. Although it typically behaves as a commensal organism, breakdowns in the cutaneous or mucosal barrier (eg, respiratory epithelial damage due to influenza) can create a portal of entry for the bacteria and lead to skin or soft-tissue infection (eg, boil) or deeper, life-threatening disease (eg, pneumonia, osteomyelitis).

The most virulent strains of *S aureus* have been infected with a bacteriophage that transmits genes for **Panton**

https://t.me/USMLEWorldStep1

Explanation

Young, healthy individuals with recent influenza infection are at risk for rapidly progressive, **necrotizing pneumonia** (eg, pulmonary cavitations/abscesses) due to infection with ***Staphylococcus aureus***, a gram-positive cocci that grows in grapelike clusters. *S aureus* colonizes the nares and skin of up to 30% of individuals in the community setting. Although it typically behaves as a commensal organism, breakdowns in the cutaneous or mucosal barrier (eg, respiratory epithelial damage due to influenza) can create a portal of entry for the bacteria and lead to skin or soft-tissue infection (eg, boil) or deeper, life-threatening disease (eg, pneumonia, osteomyelitis).

The most virulent strains of *S aureus* have been infected with a bacteriophage that transmits genes for **Panton-Valentine leukocidin** (PVL), a cytotoxin that destroys leukocytes and causes **tissue necrosis**. PVL is primarily seen in community-acquired strains of *S aureus* that are methicillin-resistant (methicillin-resistance is conferred by a different mobile genetic element [*mecA*]).

(Choice B) Lipooligosaccharide (a type of endotoxin) is part of the outer membrane of *Neisseria meningitidis*. Release of endotoxin into the bloodstream induces a strong proinflammatory response, which can result in rapid-onset sepsis and shock. Endotoxin is found in gram-negative, not gram-positive, organisms.

(Choice C) M protein coats the surface of *Streptococcus pyogenes*. It prevents phagocytosis, inhibits complement binding, and aids in epithelial attachment.

(Choice D) The virulence of *Streptococcus pneumoniae* is directly related to the presence of a polysaccharide capsule that protects the organism from phagocytosis (vaccines for *S pneumoniae* generate protective antibodies against capsular antigens). Although many strains of *S aureus* are encapsulated, PVL is a far more potent virulence factor in this organism.

Educational objective:
Staphylococcus aureus strains that express Panton-Valentine leukocidin (PVL), a protease that kills leukocytes and causes necrosis, are most likely to cause skin or soft-tissue abscess and invasive disease (eg, necrotizing pneumonia). PVL expression is most common in community-acquired, methicillin-resistant strains.

Microbiology Pulmonary & Critical Care Community-acquired pneumonia

https://t.me/USMLEWorldStep1

A 5-year-old boy is brought to the emergency department by his parents for severe respiratory distress. He has not received any immunizations due to parental preference, and his medical history is otherwise unremarkable. The patient appears very uncomfortable and anxious. He is leaning forward and making a loud, harsh sound with every inspiration. Temperature is 39.6 C (103.4 F). The patient is intubated immediately. During intubation, the epiglottis is visualized and appears markedly swollen and erythematous. Which of the following is a major virulence factor of the pathogen causing this patient's infection?

- A. Lecithinase
- B. M protein
- C. Polyribosylribitol phosphate
- D. Protein A
- E. Trehalose dimycolate

Submit

https://t.me/USMLEWorldStep1

A 5-year-old boy is brought to the emergency department by his parents for severe respiratory distress. He has not received any immunizations due to parental preference, and his medical history is otherwise unremarkable. The patient appears very uncomfortable and anxious. He is leaning forward and making a loud, harsh sound with every inspiration. Temperature is 39.6 C (103.4 F). The patient is intubated immediately. During intubation, the epiglottis is visualized and appears markedly swollen and erythematous. Which of the following is a major virulence factor of the pathogen causing this patient's infection?

- A. Lecithinase (11%)
- ✗ B. M protein (12%)
- ✓ C. Polyribosylribitol phosphate (55%)
- D. Protein A (15%)
- E. Trehalose dimycolate (4%)

Incorrect
Correct answer
C

55%
Answered correctly

03 secs
Time Spent

2023
Version

Explanation

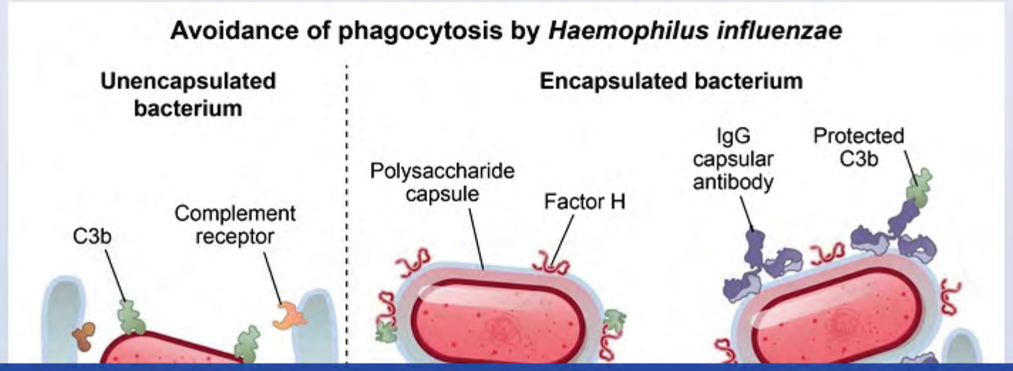

https://t.me/USMLEWorldStep1

A 5-year-old boy is brought to the emergency department by his parents for severe respiratory distress. He has not rec
The pa
every
epiglot
virulen

Inco
Corre
C

Expl

Exhibit Display

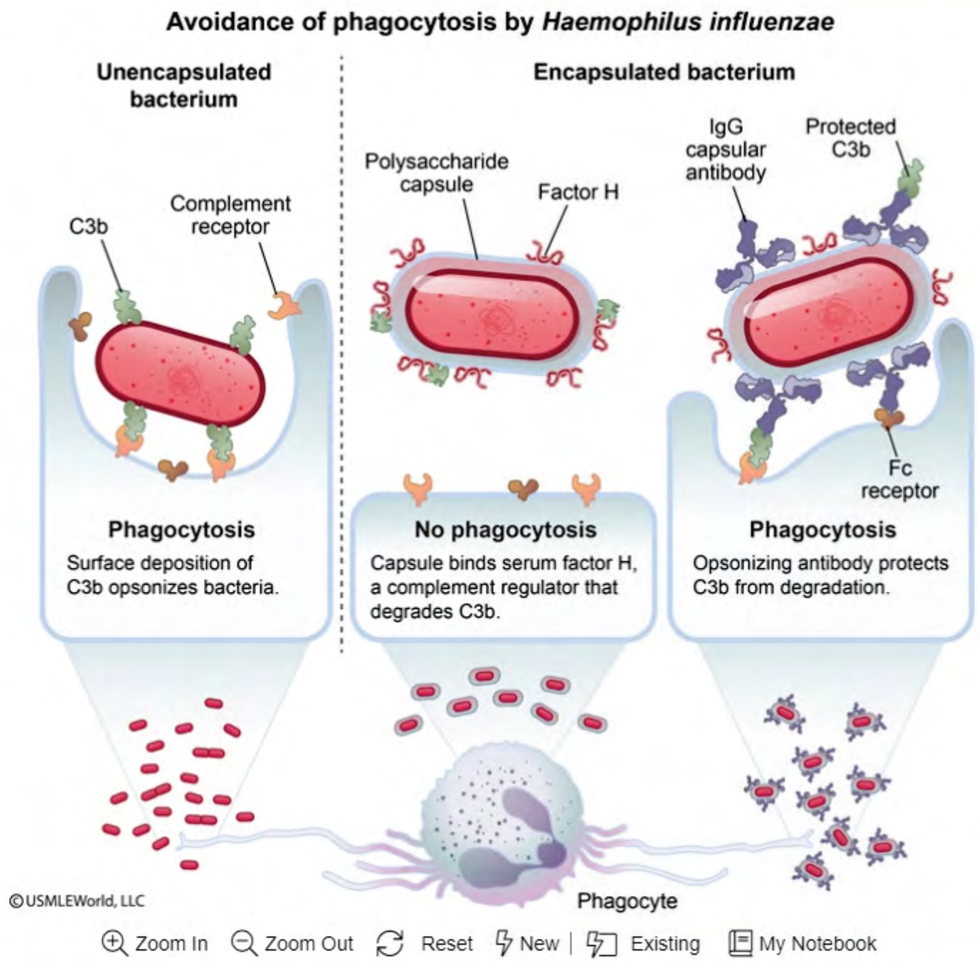

Zoom In Zoom Out Reset New | Existing My Notebook

https://t.me/USMLEWorldStep1

This child's **fever**, respiratory distress, and **inflamed epiglottis** are consistent with **epiglottitis**, which is most commonly caused by ***Haemophilus influenzae* type b** (Hib). The infected epiglottis swells, causing inspiratory **stridor**, dyspnea, and severe agitation. Epiglottitis is confirmed by direct visualization or radiographic evidence of a swollen epiglottis (ie, "thumbprint sign").

The major virulence factor of Hib is its polysaccharide **capsule**, which is composed of the polymer **polyribosylribitol phosphate** (PRP). The PRP capsule protects the bacterium against phagocytosis and complement-mediated lysis by binding **factor H**, a circulating regulator protein that normally prevents complement (C3b) deposition on host cells.

The conjugate Hib vaccine is composed of PRP conjugated to a protein toxoid. Immunization results in host development of anti-PRP antibody, which leads to improved opsonization and complement-mediated phagocytosis. Invasive Hib disease is rare in immunized patients, but it still occurs regularly in unimmunized children.

(Choice A) Lecithinase (toxin A) is produced by *Clostridium perfringens*, and hydrolyzes lecithin in cell membranes. This results in cell lysis and the development of gas gangrene.

(Choice B) M protein is found in the cell wall of *Streptococcus pyogenes*. It binds factor H to prevent opsonization and destruction of streptococci by the alternative complement pathway.

(Choice D) Protein A in the cell wall of *Staphylococcus aureus* helps prevent opsonization by binding the Fc region of immunoglobulins. *S aureus* is a common cause of tracheitis, which presents similarly to epiglottitis (eg, stridor, fever, respiratory distress) but does not cause a swollen epiglottis.

(Choice E) Trehalose dimycolate is a cell wall component and major virulence factor of *Mycobacterium tuberculosis*. It protects *M tuberculosis* from being killed by macrophages and stimulates granuloma formation.

Educational objective:
Polyribosylribitol phosphate is a capsule component and major virulence factor for *Haemophilus influenzae* type b (Hib). Hib is the most common cause of epiglottitis, which presents with fever, stridor, and dyspnea.

References

https://t.me/USMLEWorldStep1

This child's **fever**, respiratory distress, and **inflamed epiglottis** are consistent with **epiglottitis**, which is most comm
strido
a swol

The m
polyri
compl
(C3b)

The co
develo
phago
childre

(Choi
memb

(Choi
and de

(Choi
region
stridor

(Choi
tuberc

Educa
Polyrib
(Hib).

References

Exhibit Display

Epiglottitis

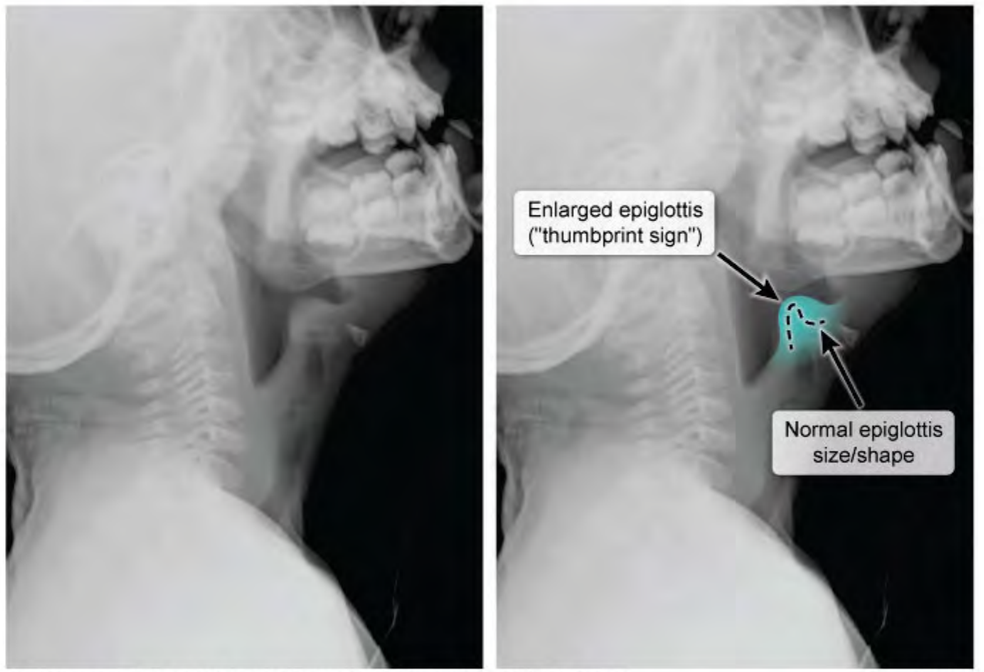

Inflamed and swollen epiglottis; most commonly caused by *Haemophilus influenzae* ©UWorld

Zoom In | Zoom Out | Reset | New | Existing | My Notebook

https://t.me/USMLEWorldStep1

A 29-year-old African American woman is being evaluated for exertional dyspnea and dry cough. She has no significant medical history and takes no medications. The patient works part-time as a bird keeper at a zoo. Chest x-ray reveals bilateral hilar adenopathy and reticular pulmonary infiltrates. Serum ACE levels and calcium levels are elevated. Purified protein derivative testing is negative. A bronchoscopy is scheduled to help determine the diagnosis. Which of the following is most likely to be the predominant cell type in this patient's bronchoalveolar lavage fluid?

- A. $CD4^+$ lymphocytes
- B. $CD8^+$ lymphocytes
- C. $CD22^+$ lymphocytes
- D. Eosinophils
- E. Mast cells
- F. Neutrophils

Submit

https://t.me/USMLEWorldStep1

A 29-year-old African American woman is being evaluated for exertional dyspnea and dry cough. She has no significant medical history and takes no medications. The patient works part-time as a bird keeper at a zoo. Chest x-ray reveals bilateral hilar adenopathy and reticular pulmonary infiltrates. Serum ACE levels and calcium levels are elevated. Purified protein derivative testing is negative. A bronchoscopy is scheduled to help determine the diagnosis. Which of the following is most likely to be the predominant cell type in this patient's bronchoalveolar lavage fluid?

- ✓ A. $CD4^+$ lymphocytes (63%)
- ✗ B. $CD8^+$ lymphocytes (12%)
- C. $CD22^+$ lymphocytes (3%)
- D. Eosinophils (9%)
- E. Mast cells (3%)
- F. Neutrophils (8%)

Incorrect
Correct answer
A

63%
Answered correctly

03 secs
Time Spent

2023
Version

Explanation

Common features of sarcoidosis	
Epidemiology	• Young adults • African Americans
	• Constitutional symptoms • Cough, dyspnea & chest pain • Extrapulmonary findings

https://t.me/USMLEWorldStep1

Explanation

Common features of sarcoidosis	
Epidemiology	• Young adults • African Americans

Clinical	• Constitutional symptoms
	• Cough, dyspnea & chest pain
	• Extrapulmonary findings
	  ◦ Skin lesions
	  ◦ Anterior/posterior uveitis
	  ◦ Löfgren syndrome
	• Parotid gland swelling

Imaging	• Bilateral hilar adenopathy • Pulmonary reticular infiltrates
Laboratory	• Hypercalcemia/hypercalciuria • Elevated serum ACE level
Pathology	• Biopsy showing noncaseating granulomas that stain negative for fungi & acid-fast bacilli

This patient's hilar adenopathy, hypercalcemia, and elevated ACE levels are suggestive of **sarcoidosis**, a condition characterized histologically by **noncaseating granulomas** composed of activated macrophages and T lymphocytes. Activated macrophages can ectopically produce ACE and **1-alpha-hydroxylase** (increases production of 1,25-dihydroxycholecalciferol, the active form of vitamin D). This results in high ACE levels and hypercalcemia commonly seen in patients with sarcoidosis. Any organ can be affected; however, the lungs (interstitial lung disease), lymph nodes (hilar adenopathy), skin (nodular rash), and eyes (anterior uveitis) are most commonly involved.

Sarcoidosis may resemble other interstitial lung diseases (eg, hypersensitivity pneumonitis, cryptogenic organizing

https://t.me/USMLEWorldStep1

This patient's hilar adenopathy, hypercalcemia, and elevated ACE levels are suggestive of **sarcoidosis**, a condition characterized histologically by **noncaseating granulomas** composed of activated macrophages and T lymphocytes. Activated macrophages can ectopically produce ACE and **1-alpha-hydroxylase** (increases production of 1,25-dihydroxycholecalciferol, the active form of vitamin D). This results in high ACE levels and hypercalcemia commonly seen in patients with sarcoidosis. Any organ can be affected; however, the lungs (interstitial lung disease), lymph nodes (hilar adenopathy), skin (nodular rash), and eyes (anterior uveitis) are most commonly involved.

Sarcoidosis may resemble other interstitial lung diseases (eg, hypersensitivity pneumonitis, cryptogenic organizing pneumonia). In such cases, quantification of the $CD4^+/CD8^+$ ratio in bronchoalveolar lavage (BAL) fluid may help in determining the diagnosis. Sarcoidosis is a **$CD4^+$ T-cell–mediated disease** in which large amounts of $CD4^+$ lymphocytes release interferon-gamma and TNF-alpha to drive macrophage activation and granuloma formation. Therefore, the BAL fluid in patients with pulmonary sarcoidosis demonstrates a lymphocytic predominance with a **high $CD4^+/CD8^+$ ratio** (>2:1).

(Choice B) $CD8^+$ cells predominate in the BAL fluid of patients with hypersensitivity pneumonitis. Although this patient has an exposure risk for hypersensitivity pneumonitis (bird handling), her hilar adenopathy as well as elevated serum calcium and ACE levels make sarcoidosis more likely.

(Choice C) CD19, CD20, and CD22 are markers for the B-cell lineage. Precursor B-cell lymphoblastic leukemia ($CD22^+$) may sometimes involve the pleura or present as diffuse, patchy pulmonary infiltrates. In such cases, the BAL fluid might contain $CD22^+$ lymphocytes; however, elevated ACE and calcium levels suggest sarcoidosis.

(Choice D) BAL fluid eosinophilia is found in eosinophilic pneumonias and tropical pulmonary eosinophilia. Although patients with hypersensitivity pneumonitis may have elevations in circulating eosinophils, they do not have elevated eosinophil counts in their BAL fluid.

(Choice E) Even though the quantity of mast cells in BAL fluid may be elevated in various pulmonary diseases, there are few, if any, conditions reported to have a predominance of such cells.

(Choice F) Neutrophils would predominate in patients with bacterial pneumonias.

Educational objective:

https://t.me/USMLEWorldStep1

commonly involved.

Sarcoidosis may resemble other interstitial lung diseases (eg, hypersensitivity pneumonitis, cryptogenic organizing pneumonia). In such cases, quantification of the $CD4^+/CD8^+$ ratio in bronchoalveolar lavage (BAL) fluid may help in determining the diagnosis. Sarcoidosis is a **$CD4^+$ T-cell–mediated disease** in which large amounts of $CD4^+$ lymphocytes release interferon-gamma and TNF-alpha to drive macrophage activation and granuloma formation. Therefore, the BAL fluid in patients with pulmonary sarcoidosis demonstrates a lymphocytic predominance with a **high $CD4^+/CD8^+$ ratio** (>2:1).

(Choice B) $CD8^+$ cells predominate in the BAL fluid of patients with hypersensitivity pneumonitis. Although this patient has an exposure risk for hypersensitivity pneumonitis (bird handling), her hilar adenopathy as well as elevated serum calcium and ACE levels make sarcoidosis more likely.

(Choice C) CD19, CD20, and CD22 are markers for the B-cell lineage. Precursor B-cell lymphoblastic leukemia ($CD22^+$) may sometimes involve the pleura or present as diffuse, patchy pulmonary infiltrates. In such cases, the BAL fluid might contain $CD22^+$ lymphocytes; however, elevated ACE and calcium levels suggest sarcoidosis.

(Choice D) BAL fluid eosinophilia is found in eosinophilic pneumonias and tropical pulmonary eosinophilia. Although patients with hypersensitivity pneumonitis may have elevations in circulating eosinophils, they do not have elevated eosinophil counts in their BAL fluid.

(Choice E) Even though the quantity of mast cells in BAL fluid may be elevated in various pulmonary diseases, there are few, if any, conditions reported to have a predominance of such cells.

(Choice F) Neutrophils would predominate in patients with bacterial pneumonias.

Educational objective:
Sarcoidosis is a $CD4^+$ T-cell mediated disease, in which large numbers of $CD4^+$ lymphocytes release interferon-gamma and tumor necrosis factor-alpha to drive macrophage activation and granuloma formation. Bronchoalveolar lavage fluid in pulmonary sarcoidosis demonstrates a lymphocytic predominance with a high $CD4^+/CD8^+$ ratio.

Pathology	Pulmonary & Critical Care	Sarcoidosis
Subject	System	Topic

https://t.me/USMLEWorldStep1

A 44-year-old man is evaluated due to progressive dyspnea over the past several years. The patient has no associated chest pain or palpitations. Physical examination shows a prolonged expiratory phase without wheezes or rhonchi. CT scan of the chest demonstrates bilateral lower lobe–predominant emphysema. Further testing reveals that the patient has a protease inhibitor deficiency, which has led to increased elastin fiber breakdown. Elastin fibers within alveolar walls normally allow the lung to stretch during active inspiration and recoil during passive expiration. Which of the following most likely contributes to this property of elastin?

- A. Abundant interchain disulfide bridges
- B. Chain assembly to form a triple helix
- C. Heavy post-translational hydroxylation
- D. High content of polar amino acids
- E. Interchain cross-links involving lysine

Submit

https://t.me/USMLEWorldStep1

A 44-year-old man is evaluated due to progressive dyspnea over the past several years. The patient has no associated chest pain or palpitations. Physical examination shows a prolonged expiratory phase without wheezes or rhonchi. CT scan of the chest demonstrates bilateral lower lobe–predominant emphysema. Further testing reveals that the patient has a protease inhibitor deficiency, which has led to increased elastin fiber breakdown. Elastin fibers within alveolar walls normally allow the lung to stretch during active inspiration and recoil during passive expiration. Which of the following most likely contributes to this property of elastin?

- A. Abundant interchain disulfide bridges (23%)
- ✕ B. Chain assembly to form a triple helix (14%)
- C. Heavy post-translational hydroxylation (8%)
- D. High content of polar amino acids (7%)
- ✓ E. Interchain cross-links involving lysine (45%)

Incorrect
Correct answer
E

45%
Answered correctly

04 secs
Time Spent

2023
Version

Explanation

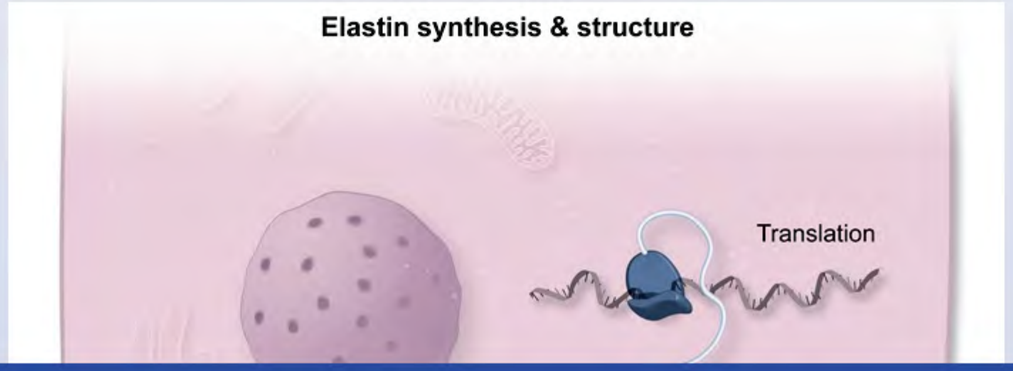

https://t.me/USMLEWorldStep1

A 44-year-old man is evaluated due to progressive dyspnea over the past several years. The patient has no associ
or rhor
reveal
Elastir
passiv

Incc
Corre
E

Expl

Exhibit Display

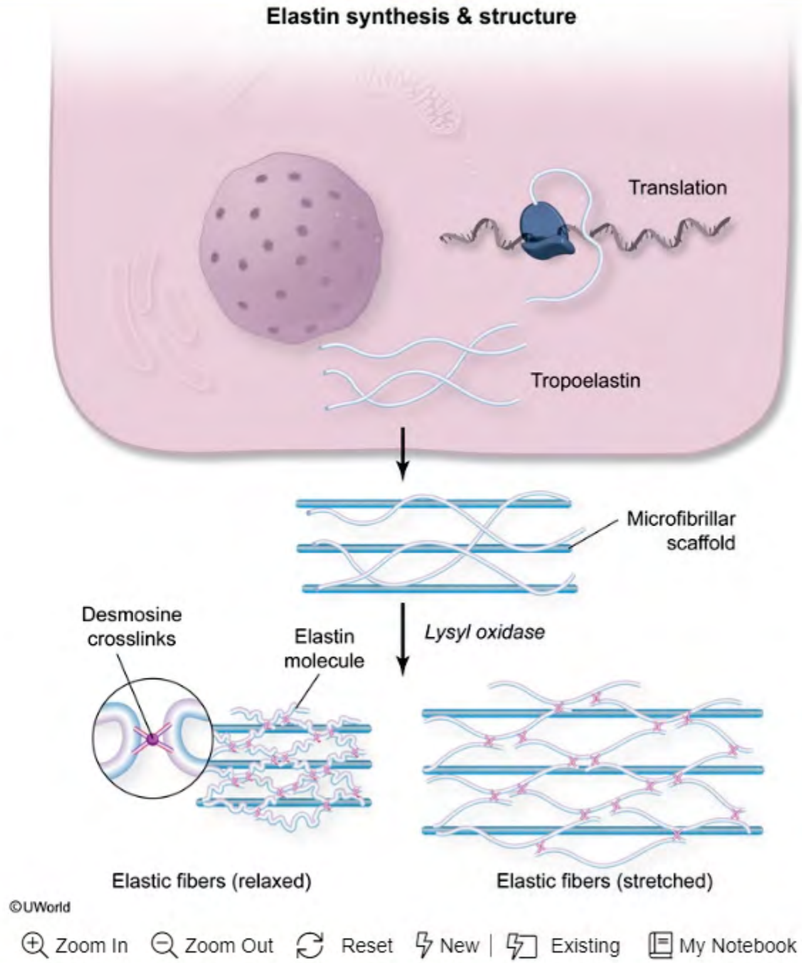

Zoom In | Zoom Out | Reset | New | Existing | My Notebook

https://t.me/USMLEWorldStep1

Elastic fibers (relaxed)

Elastic fibers (stretched)

©UWorld

This patient's emphysema is likely due to **alpha-1 antitrypsin deficiency**. Neutrophil-secreted elastase is an endogenous proteolytic enzyme that hydrolyzes elastin within alveolar walls. The liver synthesizes alpha-1 antitrypsin, a protein that inhibits neutrophil elastase and prevents alveolar wall degradation, particularly in the lower airways. Patients with alpha-1 antitrypsin deficiency consequently develop excessive alveolar **elastin degradation**, which clinically manifests with **early-onset**, lower lobe–predominant emphysema.

Elastin is a fibrous connective tissue protein that provides elasticity to the skin, blood vessels, and pulmonary alveoli. The fibers can stretch to several times their length and recoil back to their original size once stretching forces are withdrawn. Elastin assembly is closely related to that of collagen. Similar to collagen, elastin is synthesized as a large polypeptide precursor (tropoelastin) composed of about 700, mostly nonpolar, amino acids (eg, glycine, alanine, valine) **(Choice D)**. Elastin also contains proline and lysine residues; however, in contrast to those found in collagen, few of these amino acids are hydroxylated **(Choice C)**.

After tropoelastin is formed, it is secreted into the extracellular space where it interacts with microfibrils (fibrillin) that function as a scaffold. Next, **lysyl oxidase**, a copper-dependent enzyme, oxidatively deaminates some of the lysine residues of tropoelastin, facilitating the formation of **desmosine cross-links** between neighboring polypeptides that hold the elastin molecules together. These cross-links, along with the high content of nonpolar (hydrophobic) amino acids, account for the **rubber-like properties** of elastin.

(Choices A and B) Disulfide bridges are formed during collagen, not elastin, synthesis. After post-translational hydroxylation and glycosylation of procollagen molecules, disulfide bond formation between the C-terminal propeptide regions of 3 alpha chains brings the chains into a favorable alignment for triple helix assembly.

Educational objective:

The rubber-like properties of elastin are due to high content of nonpolar (hydrophobic) amino acids and extensive cross-linking between elastin monomers facilitated by lysyl oxidase. Patients with alpha-1 antitrypsin deficiency can develop early-onset, lower lobe–predominant emphysema due to excessive alveolar elastin degradation.

References

https://t.me/USMLEWorldStep1

Exhibit Display

Alpha-1-antitrypsin deficiency | Alpha-1-antitrypsin deficiency

Zoom In | Zoom Out | Reset | New | Existing | My Notebook

This p
endog
antitry
lower
degra

Elastin
alveoli
forces
synthe
(eg, gl
those

After t
that fu
lysine
polype
(hydro

(Choic
hydrox
propep

Educa
The ru
cross-
can de

References

https://t.me/USMLEWorldStep1

Exhibit Display

Alpha-1-antitrypsin deficiency | Alpha-1-antitrypsin deficiency

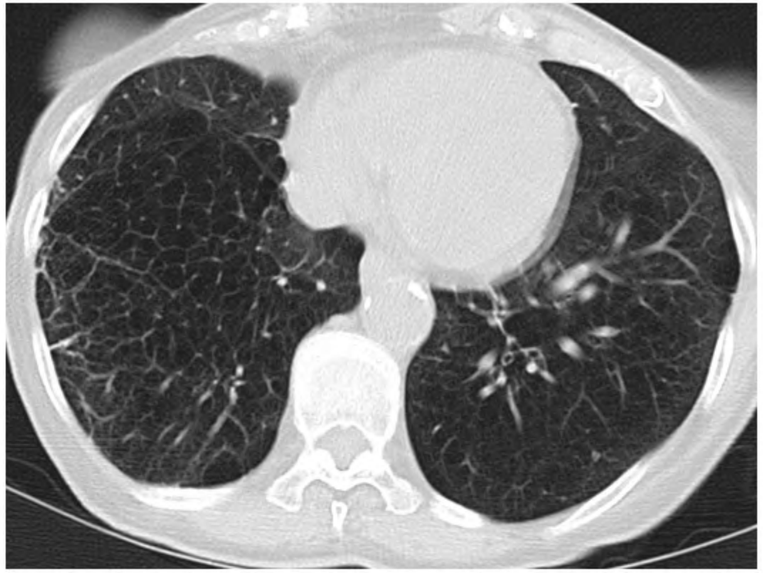

Zoom In | Zoom Out | Reset | New | Existing | My Notebook

This p
endog
antitry
lower
degra

Elastin
alveoli
forces
synthe
(eg, gl
those

After t
that fu
lysine
polype
(hydro

(Choi
hydrox
propep

Educa
The ru
cross-
can de

References

https://t.me/USMLEWorldStep1

A 61-year-old man with a history of chronic obstructive pulmonary disease and HIV infection is evaluated for cough and hemoptysis. CT scan shows multiple bilateral nodular lesions. Bronchoscopy shows a cherry-red, slightly raised lesion. Biopsy of the lesion is shown in the image below:

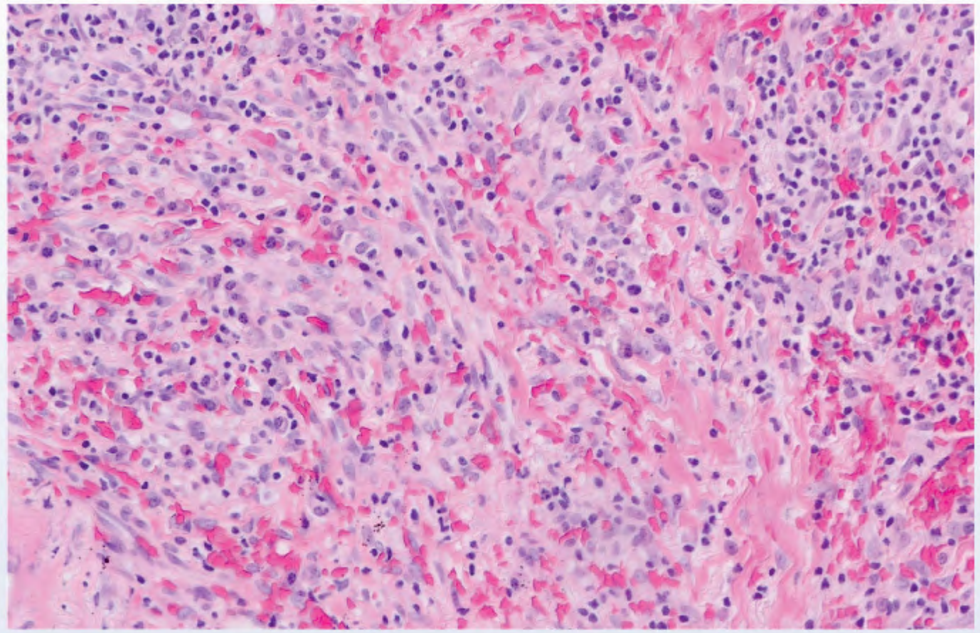

Which of the following is the most likely diagnosis?

- A. Adenocarcinoma
- B. Carcinoid tumor
- C. Infection with cytomegalovirus
- D. Infection with human herpesvirus 8
- E. Infection with *Pneumocystis jirovecii*
- F. Squamous cell carcinoma

https://t.me/USMLEWorldStep1

raised lesion. Biopsy of the lesion is shown in the image below:

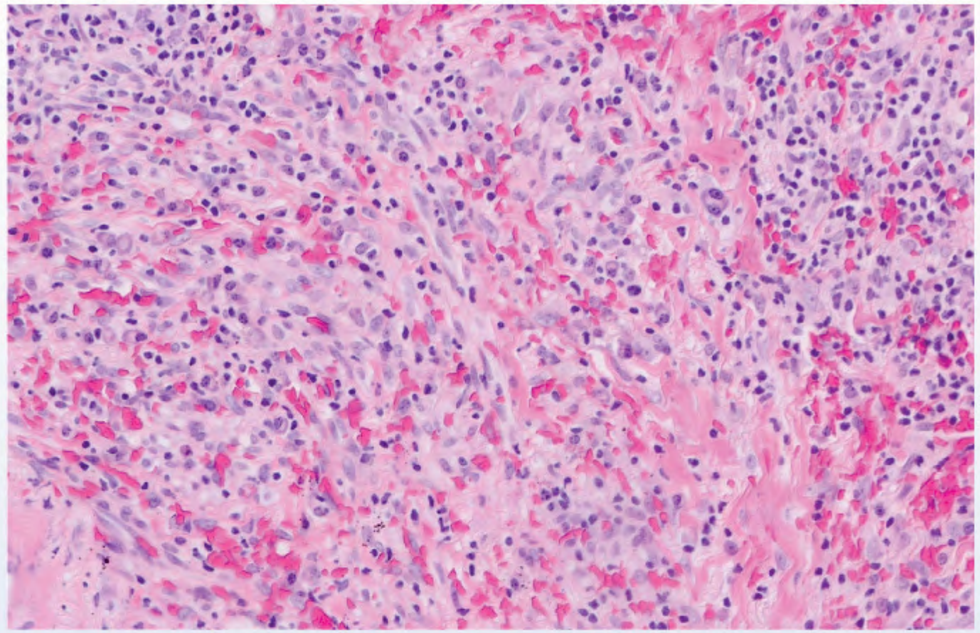

Which of the following is the most likely diagnosis?

- A. Adenocarcinoma (3%)
- ✗ B. Carcinoid tumor (9%)
- C. Infection with cytomegalovirus (14%)
- ✓ D. Infection with human herpesvirus 8 (43%)
- E. Infection with *Pneumocystis jirovecii* (22%)
- F. Squamous cell carcinoma (6%)

Incorrect
Correct answer
D

43%
Answered correctly

08 secs
Time Spent

2023
Version

https://t.me/USMLEWorldStep1

Explanation

Kaposi sarcoma	
Etiology	• Endothelial tumor caused by human herpesvirus type 8 • Most common malignancy in patients with untreated HIV • Endemic in certain African & Mediterranean regions
Manifestations	• Cutaneous lesions: ◦ Violaceous, red, or brown flat lesions → papules ◦ Most common along skin folds ◦ Pruritus, pain & friability are rare ◦ Lymphedema distal to lesions • Visceral lesions: ◦ Lungs & gastrointestinal tract most common ◦ May cause life-threatening bleeding
Histopathology	• Proliferation of spindle-shaped endothelial cells • Slit-like vascular spaces • Extravasated red blood cells

This patient with cough and hemoptysis has endobronchial biopsy findings consistent with **Kaposi sarcoma** (KS), a vascular tumor strongly associated with **human herpesvirus 8** infection. KS often occurs in patients who are immunosuppressed (ie, impaired T-cell control of the virus). Risk factors include **HIV infection** and immunosuppressive therapy following transplant. **Corticosteroid use** (eg, chronic obstructive pulmonary disease exacerbations) can also precipitate or worsen KS.

Although **skin** involvement is a characteristic initial finding (eg, purple papules on the lower extremities), some

https://t.me/USMLEWorldStep1

This patient with cough and hemoptysis has endobronchial biopsy findings consistent with **Kaposi sarcoma** (KS), a vascular tumor strongly associated with **human herpesvirus 8** infection. KS often occurs in patients who are immunosuppressed (ie, impaired T-cell control of the virus). Risk factors include **HIV infection** and immunosuppressive therapy following transplant. **Corticosteroid use** (eg, chronic obstructive pulmonary disease exacerbations) can also precipitate or worsen KS.

Although **skin** involvement is a characteristic initial finding (eg, purple papules on the lower extremities), some patients may present with **pulmonary** disease. Depending on the location of the tumor, patients may have dyspnea, cough, **hemoptysis** (due to tumor bleeding), airway obstruction, and/or pleural effusions. Chest imaging often reveals reticular opacities or nodular densities. Bronchoscopy may show **endobronchial** macules and papules that are classically **cherry-red** or violaceous.

Histopathology of KS characteristically shows a proliferation of **spindle-shaped endothelial cells** forming **slit-like vascular spaces** with inflammation. The abnormal vascular spaces are leaky, allowing red blood cell extravasation.

(Choice A) Pulmonary adenocarcinoma often presents with cough, hemoptysis, and weight loss. However, it tends to be located peripherally and would be less likely to form an endobronchial lesion. Histopathology often shows infiltrative glands lined by malignant mucin-producing epithelial cells.

(Choice B) Pulmonary carcinoid tumor is a well-differentiated neuroendocrine tumor that often arises in the proximal airways and grows endobronchially, causing cough and hemoptysis. However, histopathology shows uniform, polygonal cells with eosinophilic cytoplasm and granular (ie, salt and pepper) chromatin.

(Choice C) Pulmonary cytomegalovirus infection typically occurs in immunocompromised patients and may cause cough, shortness of breath, and fever. However, histopathology of infected cells shows viral cytopathic effect, including cell enlargement and nuclear and cytoplasmic inclusions.

(Choice E) *Pneumocystis jirovecii* is a fungus that causes pulmonary infection in immunocompromised patients and may lead to cough, dyspnea, and fatigue. However, histopathology shows intraalveolar exudate and cup- or crescent-shaped organisms that can be highlighted with a silver stain.

(Choice F) Squamous cell lung carcinoma often arises in the proximal airways and can cause cough and

https://t.me/USMLEWorldStep1

papules that are classically **cherry-red** or violaceous.

Histopathology of KS characteristically shows a proliferation of **spindle-shaped endothelial cells** forming **slit-like vascular spaces** with inflammation. The abnormal vascular spaces are leaky, allowing red blood cell extravasation.

(Choice A) Pulmonary adenocarcinoma often presents with cough, hemoptysis, and weight loss. However, it tends to be located peripherally and would be less likely to form an endobronchial lesion. Histopathology often shows infiltrative glands lined by malignant mucin-producing epithelial cells.

(Choice B) Pulmonary carcinoid tumor is a well-differentiated neuroendocrine tumor that often arises in the proximal airways and grows endobronchially, causing cough and hemoptysis. However, histopathology shows uniform, polygonal cells with eosinophilic cytoplasm and granular (ie, salt and pepper) chromatin.

(Choice C) Pulmonary cytomegalovirus infection typically occurs in immunocompromised patients and may cause cough, shortness of breath, and fever. However, histopathology of infected cells shows viral cytopathic effect, including cell enlargement and nuclear and cytoplasmic inclusions.

(Choice E) *Pneumocystis jirovecii* is a fungus that causes pulmonary infection in immunocompromised patients and may lead to cough, dyspnea, and fatigue. However, histopathology shows intraalveolar exudate and cup- or crescent-shaped organisms that can be highlighted with a silver stain.

(Choice F) Squamous cell lung carcinoma often arises in the proximal airways and can cause cough and hemoptysis. However, histopathology shows infiltrative nests of malignant cells with squamous differentiation (eg, intercellular bridges, keratin production).

Educational objective:
Kaposi sarcoma (KS), a vascular tumor associated with human herpesvirus 8, often arises in immunosuppressed patients (eg, HIV infection). KS typically involves the skin but can also affect the viscera, including the gastrointestinal tract (eg, abdominal pain) and pulmonary system (eg, cough, hemoptysis). Biopsy shows spindle-shaped endothelial cells forming slit-like vascular spaces, extravasated red blood cells, and inflammation.

Pathology	Pulmonary & Critical Care	Kaposi sarcoma
Subject	System	Topic

https://t.me/USMLEWorldStep1

immunosuppressive therapy following transplant. **Corticosteroid use** (eg, chronic obstructive pulmonary disease

exace

Althou
patien
dyspn
often r
papule

Histop
vascu
extrav

(Choi
tends
shows

(Choi
proxim
uniform

(Choi
cough
includi

(Choi
and m
cresce

(Choi
hemop
intercellular bridges, keratin production).

Educational objective:

Exhibit Display

Kaposi sarcoma

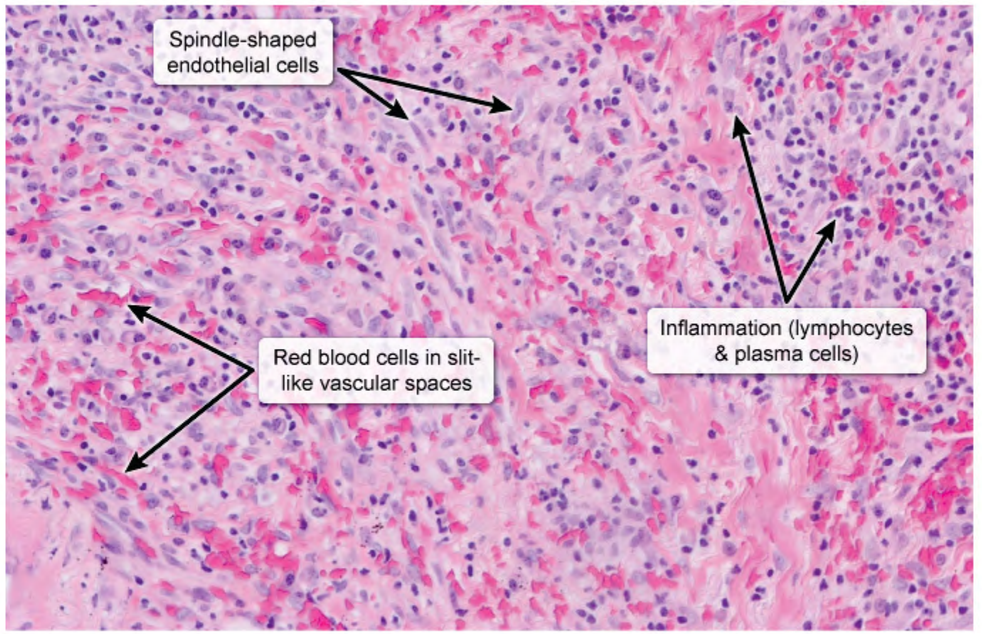

©UWorld

Zoom In | Zoom Out | Reset | New | Existing | My Notebook

https://t.me/USMLEWorldStep1

immunosuppressive therapy following transplant. **Corticosteroid use** (eg, chronic obstructive pulmonary disease
exace
Althou
patien
dyspn
often r
papule
Histop
vascu
extrav
(Choi
tends
shows
(Choi
proxim
uniform
(Choi
cough
includi
(Choi
and m
cresce
(Choi
hemop
intercellular bridges, keratin production).

Educational objective:

Exhibit Display

Pulmonary adenocarcinoma

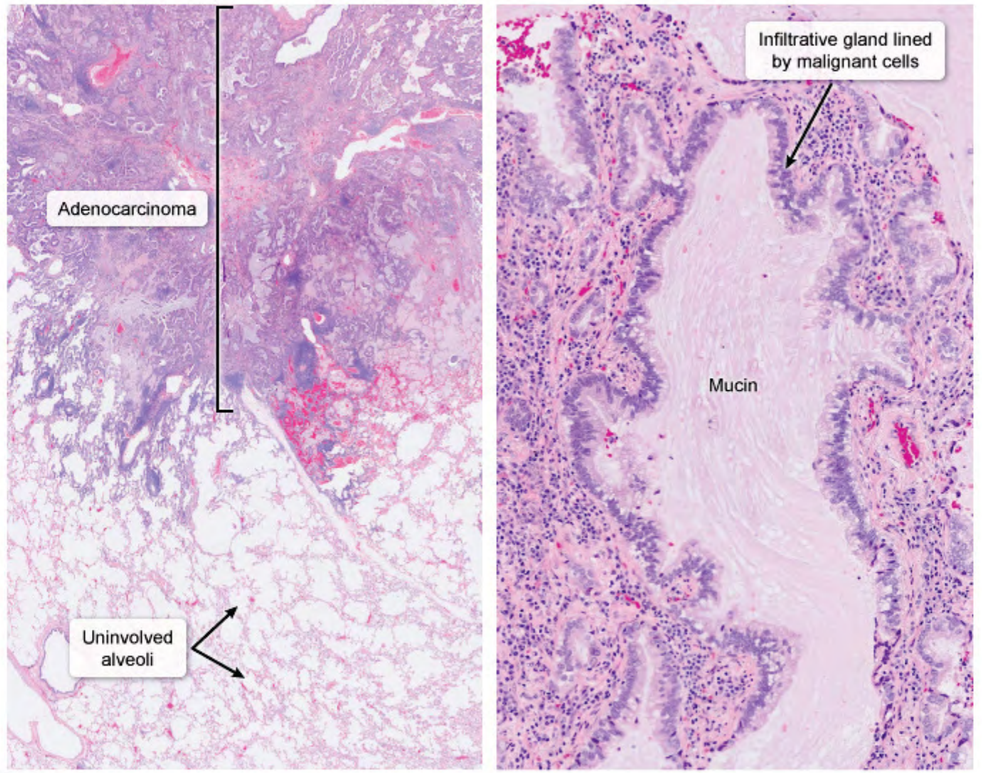

©UWorld

Zoom In Zoom Out Reset New | Existing My Notebook

https://t.me/USMLEWorldStep1

immunosuppressive therapy following transplant. **Corticosteroid use** (eg, chronic obstructive pulmonary disease
exace
Althou
patien
dyspn
often r
papule
Histop
vascu
extrav
(Choi
tends
shows
(Choi
proxim
uniform
(Choi
cough
includi
(Choi
and m
cresce
(Choi
hemop
intercellular bridges, keratin production).

Educational objective:

Exhibit Display

Pulmonary carcinoid tumor

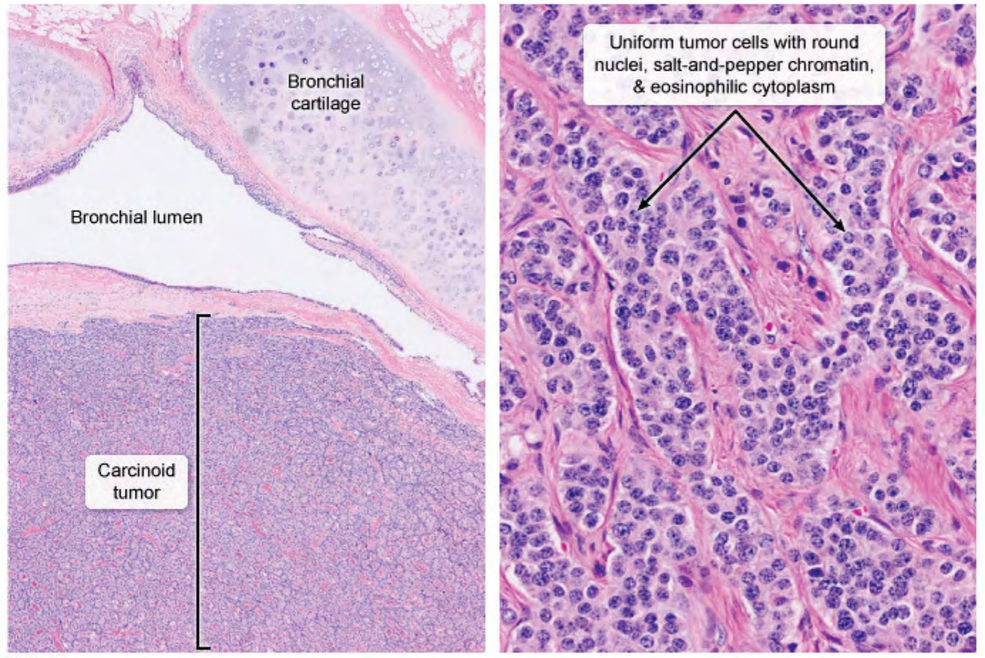

©UWorld

Zoom In Zoom Out Reset New | Existing My Notebook

https://t.me/USMLEWorldStep1

immunosuppressive therapy following transplant. **Corticosteroid use** (eg, chronic obstructive pulmonary disease

exace

Althou
patien
dyspn
often r
papule

Histop
vascu
extrav

(Choi
tends
shows

(Choi
proxim
uniform

(Choi
cough
includi

(Choi
and m
cresce

(Choi
hemop
intercellular bridges, keratin production).

Educational objective:

Exhibit Display

Cytomegalovirus

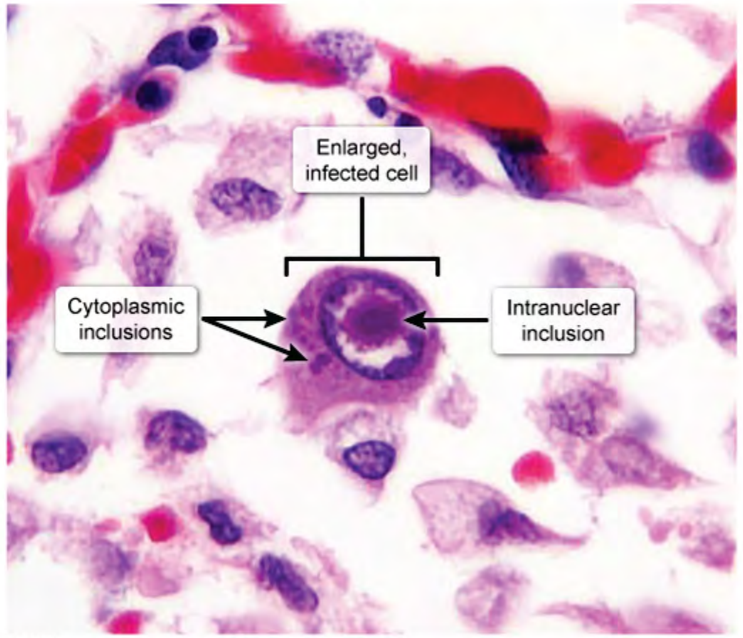

©UWorld

Zoom In Zoom Out Reset New | Existing My Notebook

https://t.me/USMLEWorldStep1

immunosuppressive therapy following transplant. **Corticosteroid use** (eg, chronic obstructive pulmonary disease exacer

Althou
patien
dyspn
often r
papule

Histop
vascu
extrav

(Choi
tends
shows

(Choi
proxim
uniform

(Choi
cough
includi

(Choi
and m
cresce

(Choi
hemop
intercellular bridges, keratin production).

Educational objective:

Exhibit Display

Pneumocystis jirovecii

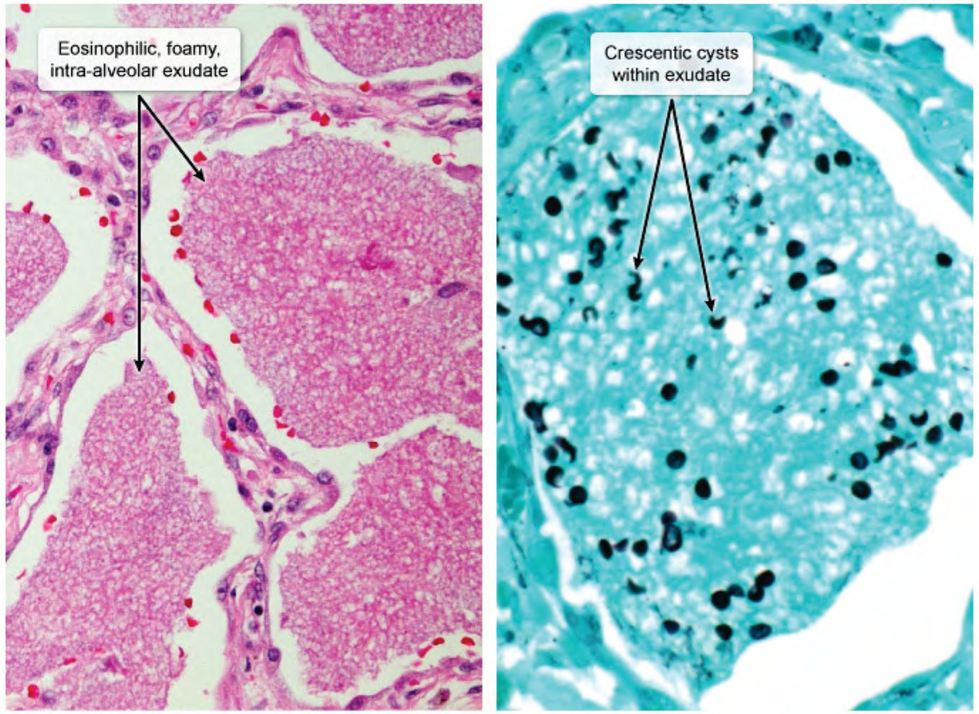

©UWorld

Hematoxylin & eosin stain

Silver stain

Zoom In | Zoom Out | Reset | New | Existing | My Notebook

https://t.me/USMLEWorldStep1

immunosuppressive therapy following transplant. **Corticosteroid use** (eg, chronic obstructive pulmonary disease
exace
Althou
patien
dyspn
often r
papule
Histop
vascu
extrav
(Choi
tends
shows
(Choi
proxim
uniform
(Choi
cough
includi
(Choi
and m
cresce
(Choi
hemop
interc
Educational objective:

Exhibit Display

Squamous cell lung carcinoma

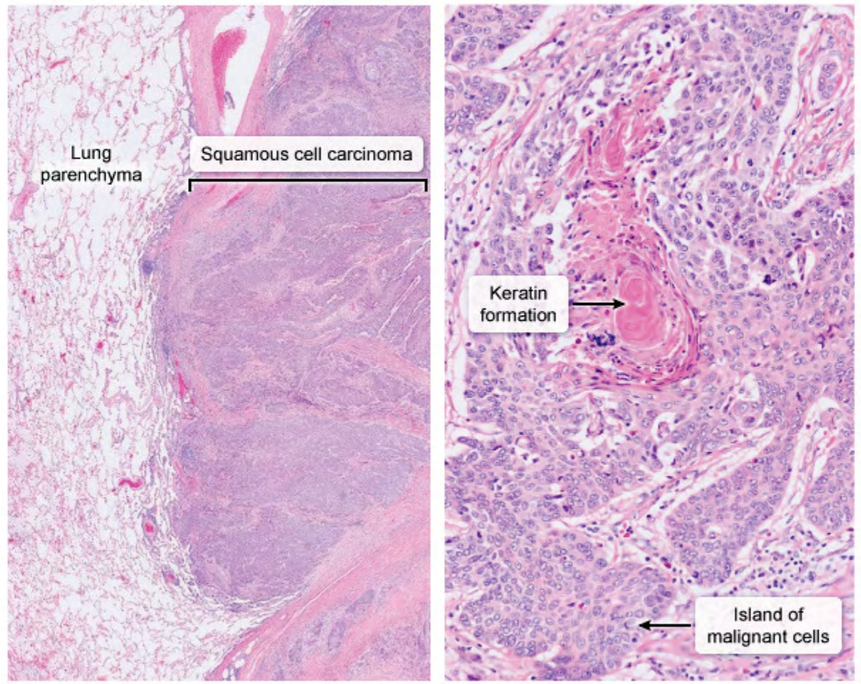

©UWorld

Zoom In Zoom Out Reset New | Existing My Notebook

https://t.me/USMLEWorldStep1

A 66-year-old man hospitalized 3 days ago for left lower lobe pneumonia is evaluated for persistent fever. He has been receiving the appropriate intravenous antibiotics as determined by antibiotic susceptibility testing of his sputum cultures. The patient has a history of diabetes mellitus and hypertension. His temperature is 38 C (100.4 F) and pulse is 87/min. Examination shows dullness to percussion and decreased breath sounds over the left lower lung. Imaging studies reveal a loculated, left-sided pleural effusion. A tube is placed to drain the fluid via an incision at the 5th intercostal space in the midaxillary line. Which of the following muscles is most likely to be dissected during the procedure?

- A. External oblique
- B. Infraspinatus
- C. Latissimus dorsi
- D. Pectoralis major
- E. Serratus anterior

Submit

https://t.me/USMLEWorldStep1

A 66-year-old man hospitalized 3 days ago for left lower lobe pneumonia is evaluated for persistent fever. He has been receiving the appropriate intravenous antibiotics as determined by antibiotic susceptibility testing of his sputum cultures. The patient has a history of diabetes mellitus and hypertension. His temperature is 38 C (100.4 F) and pulse is 87/min. Examination shows dullness to percussion and decreased breath sounds over the left lower lung. Imaging studies reveal a loculated, left-sided pleural effusion. A tube is placed to drain the fluid via an incision at the 5th intercostal space in the midaxillary line. Which of the following muscles is most likely to be dissected during the procedure?

- ✗ A. External oblique (10%)
- B. Infraspinatus (0%)
- C. Latissimus dorsi (14%)
- D. Pectoralis major (11%)
- ✓ E. Serratus anterior (61%)

Incorrect
Correct answer
E

61%
Answered correctly

53 secs
Time Spent

2023
Version

Explanation

Chest tube placement

https://t.me/USMLEWorldStep1

B. Infraspinatus (0%)

Exhibit Display

Chest tube placement

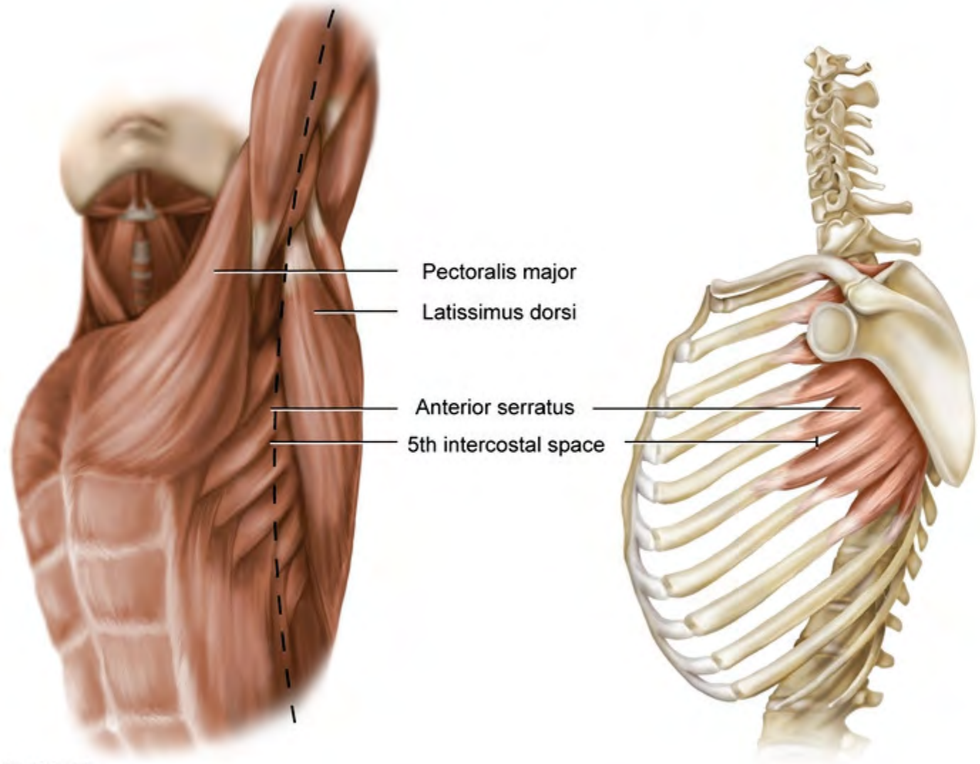

©UWorld

Zoom In | Zoom Out | Reset | New | Existing | My Notebook

https://t.me/USMLEWorldStep1

©UWorld

This patient most likely has empyema requiring drainage with a **chest tube**. The technique involves placing the chest tube through the skin and subcutaneous fat into the **4th or 5th intercostal space** in the anterior axillary or **midaxillary** line. The tube traverses through the **serratus anterior** muscle, intercostal (external, internal, innermost) muscles, and parietal pleura to reach the pleural cavity.

The serratus anterior originates as multiple branches from the side of the chest along the 1st-8th ribs and inserts along the entire length of the medial scapular border. The muscle is divided into 3 parts (superior, intermediate, inferior) depending on the insertion site at the scapula. The inferior part of the muscle facilitates arm elevation by pulling the lower end of the scapula forward (scapular rotation). All 3 muscle parts can help with respiration by lifting the ribs when the shoulder girdle is fixed.

(Choice A) The external oblique originates from the lateral ribs (5-12) and extends anteriorly across the abdomen to insert into the linea alba, pubis, and iliac crest of the hip bones. The muscle is usually inferior to the chest tube insertion site.

(Choice B) The infraspinatus is a rotator cuff muscle that attaches medially to the infraspinous fossa of the scapula and laterally to the greater tubercle of the humerus. The muscle stabilizes the shoulder joint in addition to externally rotating the humerus.

(Choice C) The latissimus dorsi is a back muscle that helps with multiple shoulder movements (eg, extension, adduction). It originates from the spinous processes of T7-L5, the 9th-12th ribs, and the inferior angle of the scapula. The muscle inserts into the humerus and is located posterior to the chest tube insertion site.

(Choice D) The pectoralis major arises from the anterior clavicle, sternum, costal cartilages, and aponeurosis of the external oblique muscle. It attaches on the lateral lip of the bicipital groove of the humerus and serves to adduct and internally rotate the humerus. The muscle is anterior to the chest tube insertion site.

Educational objective:
A chest tube for drainage of pleural effusion is placed through the skin and subcutaneous fat into the 4th or 5th intercostal space in the anterior axillary or midaxillary line. The tube traverses through the serratus anterior muscle, intercostal muscles, and parietal pleura.

https://t.me/USMLEWorldStep1

©UWorld

This p
chest
midax
innerm

The se
along
inferio
pulling
lifting

(Choi
to inse
inserti

(Choi
scapul
extern

(Choi
adduc
scapul

(Choi
the ex
adduc

Educa
A ches
interco
muscle, intercostal muscles, and parietal pleura.

Exhibit Display

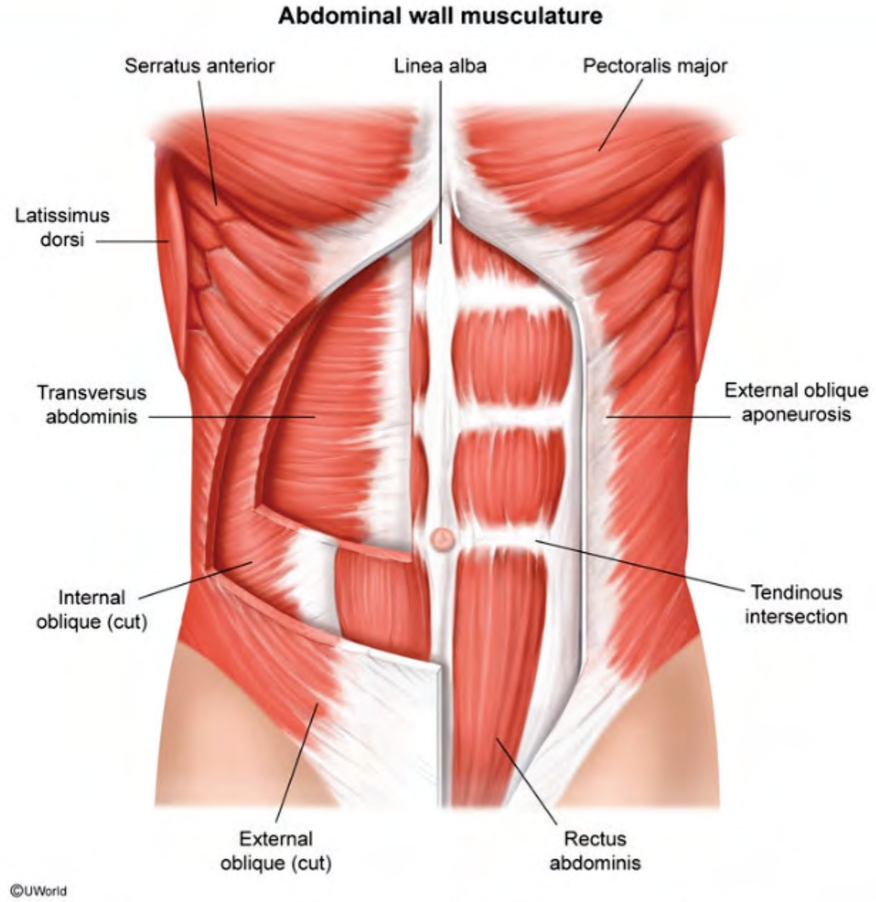

Zoom In | Zoom Out | Reset | New | Existing | My Notebook

https://t.me/USMLEWorldStep1

©UWorld

This p
chest
midax
innerm

The se
along
inferio
pulling
lifting

(Choi
to inse
inserti

(Choi
scapul
extern

(Choi
adduc
scapul

(Choi
the ex
adduc

Educa
A ches
interco
muscle, intercostal muscles, and parietal pleura.

Exhibit Display

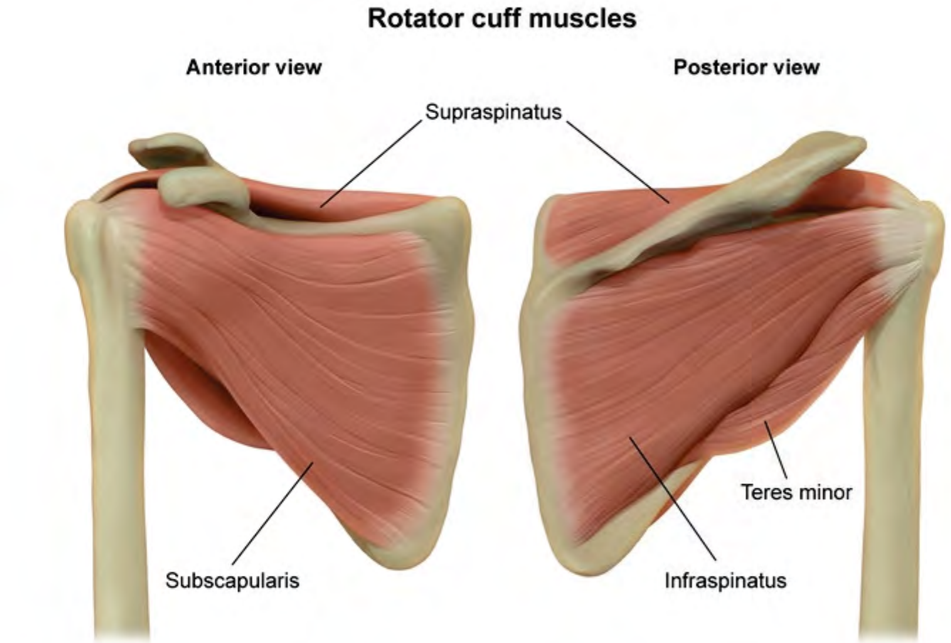

Zoom In
Zoom Out
Reset
New
Existing
My Notebook

https://t.me/USMLEWorldStep1

A 31-year-old man comes to the office due to progressive dyspnea over the past several months. The patient states that the shortness of breath improved initially with supine positioning, but lately, it is present even on recumbency and during minimal exertion. He reports recurrent episodes of nosebleeds since childhood but has no other medical conditions. Temperature is 36.7 C (98.1 F), blood pressure is 110/50 mm Hg, pulse is 102/min, and respirations are 20/min. Oxygen saturation is 96% on room air. Cardiac examination reveals an accentuated S2 over the upper left sternal border. The lungs are clear to auscultation. There is digital clubbing. Skin examination findings are shown in the exhibit. Which of the following is the most likely underlying cause of this patient's dyspnea?

- A. Airway obstruction
- B. Endocardial infection
- C. Pulmonary fibrosis
- D. Valvular dysfunction
- E. Vascular malformation

Submit

https://t.me/USMLEWorldStep1

A 31-year-old man comes to the office due to progressive dyspnea over the past several months. The patient states
recum
other r
respira
over th
finding
dyspn

Sub

Exhibit Display

Zoom In Zoom Out Reset New | Existing My Notebook

https://t.me/USMLEWorldStep1

A 31-year-old man comes to the office due to progressive dyspnea over the past several months. The patient states that the shortness of breath improved initially with supine positioning, but lately, it is present even on recumbency and during minimal exertion. He reports recurrent episodes of nosebleeds since childhood but has no other medical conditions. Temperature is 36.7 C (98.1 F), blood pressure is 110/50 mm Hg, pulse is 102/min, and respirations are 20/min. Oxygen saturation is 96% on room air. Cardiac examination reveals an accentuated S2 over the upper left sternal border. The lungs are clear to auscultation. There is digital clubbing. Skin examination findings are shown in the exhibit. Which of the following is the most likely underlying cause of this patient's dyspnea?

- A. Airway obstruction (3%)
- B. Endocardial infection (6%)
- ✗ C. Pulmonary fibrosis (21%)
- D. Valvular dysfunction (17%)
- ✓ E. Vascular malformation (50%)

Incorrect
Correct answer
E

50%
Answered correctly

15 secs
Time Spent

2023
Version

Explanation

Hereditary hemorrhagic telangiectasia (Rendu-Osler-Weber syndrome)	
Pathogenesis	• Autosomal dominant mutations impairing TGF-β signaling • Disrupted angiogenesis & loss of vascular integrity

https://t.me/USMLEWorldStep1

Hereditary hemorrhagic telangiectasia (Rendu-Osler-Weber syndrome)	
Pathogenesis	• Autosomal dominant mutations impairing TGF-β signaling • Disrupted angiogenesis & loss of vascular integrity
Clinical features	• Mucocutaneous (oral, skin) telangiectasia • Recurrent epistaxis • Visceral organ AVMs: gastrointestinal tract (bleeding), lung (hemoptysis), brain (hemorrhagic stroke), liver
Complications	• High-output heart failure* • Pulmonary hypertension* • Paradoxic embolism** • Iron deficiency anemia
*Secondary to high-volume, systemic AVMs. **Bacterial translocation or embolization through pulmonary AVMs. **AVMs** = arteriovenous malformations; **TGF-β** = transforming growth factor-β.	

This young adult has a history of recurrent epistaxis, cutaneous telangiectasias, and signs of pulmonary vascular disease. These findings are consistent with **hereditary hemorrhagic telangiectasia** (HHT) (Rendu-Osler-Weber syndrome). HHT is caused by autosomal dominant mutations of genes involved in angiogenesis (eg, *ENG*, *ACVRL1*), leading to multiorgan **arteriovenous malformations** (AVMs). In the lungs, HHT is associated with **pulmonary AVMs**, which may present with cyanosis, digital clubbing, hemoptysis, and **platypnea** (dyspnea aggravated by upright posture). The mechanism of platypnea is a gravitational increase in perfusion through the

https://t.me/USMLEWorldStep1

This young adult has a history of recurrent epistaxis, cutaneous telangiectasias, and signs of pulmonary vascular disease. These findings are consistent with **hereditary hemorrhagic telangiectasia** (HHT) (Rendu-Osler-Weber syndrome). HHT is caused by autosomal dominant mutations of genes involved in angiogenesis (eg, *ENG*, *ACVRL1*), leading to multiorgan **arteriovenous malformations** (AVMs). In the lungs, HHT is associated with **pulmonary AVMs**, which may present with cyanosis, digital clubbing, hemoptysis, and **platypnea** (dyspnea aggravated by upright posture). The mechanism of platypnea is a gravitational increase in perfusion through the arteriovenous (AV) communications in the lower lung, worsening V/Q mismatch.

HHT can induce **pulmonary hypertension** (progressive dyspnea, loud P2 [pulmonic component of S2]) in some patients. This is usually due to extensive **systemic AVMs** (eg, hepatic) provoking **chronic, high-output heart failure** (widened pulse pressure, tachycardia) that elevates mean pulmonary arterial pressure. HHT vascular gene mutations can also induce hypertrophic remodeling, leading to occlusion of the small precapillary pulmonary arteries, contributing to development of pulmonary hypertension.

(Choice A) Obstructive airway disease (eg, cystic fibrosis, bronchiectasis) may cause digital clubbing and a loud P2 (pulmonary hypertension due to lung disease). However, lung examination would be abnormal (eg, wheezing, decreased air movement). Furthermore, this patient's recurrent epistaxis, cutaneous angiomas, and platypnea are more suggestive of HHT.

(Choices B and D) Infective endocarditis may cause digital clubbing and cutaneous lesions. Dermal findings include Osler nodes, Janeway lesions, and splinter hemorrhages. Involvement of the aortic valve can cause aortic regurgitation, resulting in widened pulse pressure and heart failure. However, recurrent epistaxis, telangiectasias, and platypnea are more consistent with HHT.

(Choice C) Pulmonary fibrosis can cause progressive dyspnea, digital clubbing, and a loud P2 (pulmonary hypertension due to lung disease). However, idiopathic pulmonary fibrosis affects individuals in late adulthood, and lung examination would reveal inspiratory crackles.

Educational objective:
Hereditary hemorrhagic telangiectasia presents with mucocutaneous telangiectasias, epistaxis, and visceral arteriovenous malformations (AVMs) (eg, liver, lung, brain). Lung involvement includes pulmonary AVMs (eg, digital clubbing, platypnea) and pulmonary hypertension (eg, a loud P2) due to high-output heart failure from

https://t.me/USMLEWorldStep1

ACVRL1), leading to multiorgan **arteriovenous malformations** (AVMs). In the lungs, HHT is associated with **pulmonary AVMs**, which may present with cyanosis, digital clubbing, hemoptysis, and **platypnea** (dyspnea aggravated by upright posture). The mechanism of platypnea is a gravitational increase in perfusion through the arteriovenous (AV) communications in the lower lung, worsening V/Q mismatch.

HHT can induce **pulmonary hypertension** (progressive dyspnea, loud P2 [pulmonic component of S2]) in some patients. This is usually due to extensive **systemic AVMs** (eg, hepatic) provoking **chronic, high-output heart failure** (widened pulse pressure, tachycardia) that elevates mean pulmonary arterial pressure. HHT vascular gene mutations can also induce hypertrophic remodeling, leading to occlusion of the small precapillary pulmonary arteries, contributing to development of pulmonary hypertension.

(Choice A) Obstructive airway disease (eg, cystic fibrosis, bronchiectasis) may cause digital clubbing and a loud P2 (pulmonary hypertension due to lung disease). However, lung examination would be abnormal (eg, wheezing, decreased air movement). Furthermore, this patient's recurrent epistaxis, cutaneous angiomas, and platypnea are more suggestive of HHT.

(Choices B and D) Infective endocarditis may cause digital clubbing and cutaneous lesions. Dermal findings include Osler nodes, Janeway lesions, and splinter hemorrhages. Involvement of the aortic valve can cause aortic regurgitation, resulting in widened pulse pressure and heart failure. However, recurrent epistaxis, telangiectasias, and platypnea are more consistent with HHT.

(Choice C) Pulmonary fibrosis can cause progressive dyspnea, digital clubbing, and a loud P2 (pulmonary hypertension due to lung disease). However, idiopathic pulmonary fibrosis affects individuals in late adulthood, and lung examination would reveal inspiratory crackles.

Educational objective:
Hereditary hemorrhagic telangiectasia presents with mucocutaneous telangiectasias, epistaxis, and visceral arteriovenous malformations (AVMs) (eg, liver, lung, brain). Lung involvement includes pulmonary AVMs (eg, digital clubbing, platypnea) and pulmonary hypertension (eg, a loud P2) due to high-output heart failure from underlying systemic AVMs.

Pathophysiology	Pulmonary & Critical Care	Av malformation
Subject	System	Topic

https://t.me/USMLEWorldStep1

**Bacterial translocation or embolization through pulmonary AVMs.

Exhibit Display

Telangiectasia

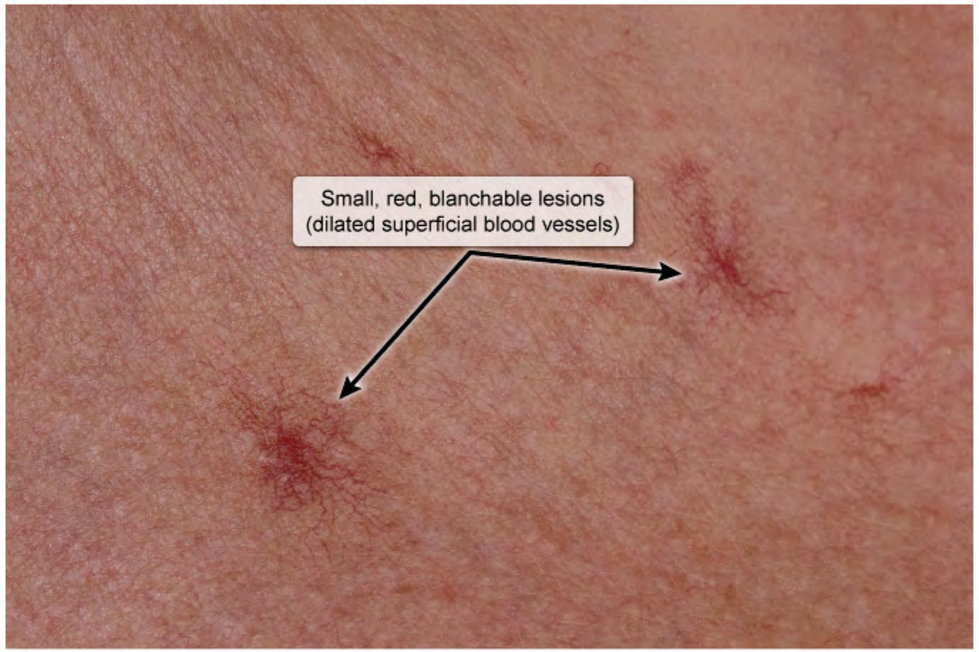

Zoom In | Zoom Out | Reset | New | Existing | My Notebook

This y
diseas
syndro
ACVR
pulmo
aggrav
arterio

HHT c
patien
failure
mutati
arterie

(Choi
P2 (pu
decrea
more s

(Choi
include
regurg
and pl

(Choi
hypert
lung examination would reveal inspiratory crackles.

Educational objective:

https://t.me/USMLEWorldStep1

**Bacterial translocation or embolization through pulmonary AVMs.

Exhibit Display

Osler node

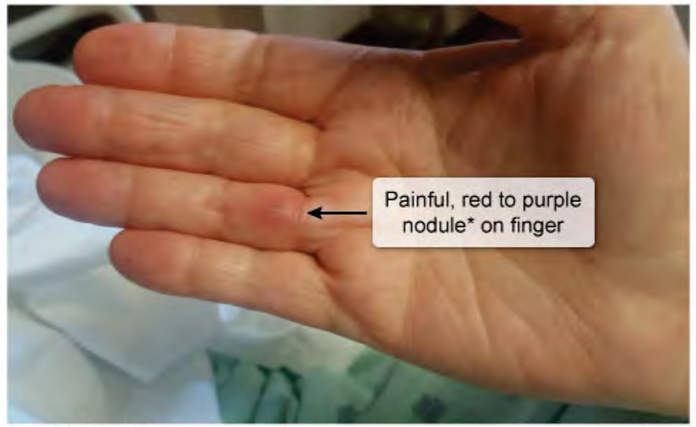

*Manifestation of infective endocarditis.

©UWorld

Zoom In | Zoom Out | Reset | New | Existing | My Notebook

This y
diseas
syndro
ACVR
pulmo
aggrav
arterio

HHT c
patien
failure
mutati
arterie

(Choi
P2 (pu
decrea
more s

(Choi
include
regurg
and pl

(Choi
hypert
lung examination would reveal inspiratory crackles.

Educational objective:

https://t.me/USMLEWorldStep1

**Bacterial translocation or embolization through pulmonary AVMs.

Exhibit Display

Janeway lesions

*Manifestation of infective endocarditis.

©UWorld

Zoom In | Zoom Out | Reset | New | Existing | My Notebook

This y
diseas
syndro
ACVR
pulmo
aggrav
arterio

HHT c
patien
failure
mutati
arterie

(Choi
P2 (pu
decrea
more s

(Choi
include
regurg
and pl

(Choi
hypert
lung examination would reveal inspiratory crackles.

Educational objective:

https://t.me/USMLEWorldStep1

**Bacterial translocation or embolization through pulmonary AVMs.

Exhibit Display

Splinter hemorrhage

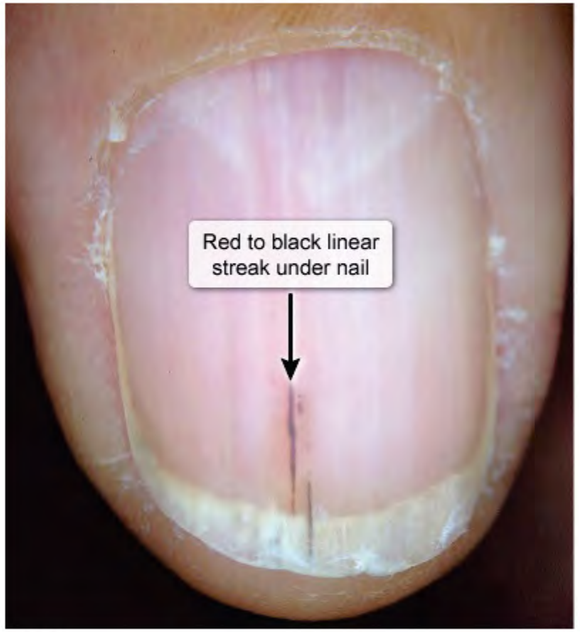

©UWorld

Zoom In | Zoom Out | Reset | New | Existing | My Notebook

This y
diseas
syndro
ACVR
pulmo
aggrav
arterio

HHT c
patien
failure
mutati
arterie

(Choi
P2 (pu
decrea
more s

(Choi
include
regurg
and pl

(Choi
hypert
lung examination would reveal inspiratory crackles.

Educational objective:

https://t.me/USMLEWorldStep1

Fourth-year medical students are recruited for a research study assessing their ability to interpret biopsy samples obtained during routine clinical practice. As part of the study, they are given samples of normal respiratory mucosa and asked to identify the cell types present after staining with hematoxylin and eosin. The students observe that the respiratory epithelium changes in composition as the airways continue distally from the trachea to the alveolar ducts. Which of the following features is last to disappear?

- A. Cartilage
- B. Cilia
- C. Goblet cells
- D. Mucous glands
- E. Serous glands

Submit

https://t.me/USMLEWorldStep1

Fourth-year medical students are recruited for a research study assessing their ability to interpret biopsy samples obtained during routine clinical practice. As part of the study, they are given samples of normal respiratory mucosa and asked to identify the cell types present after staining with hematoxylin and eosin. The students observe that the respiratory epithelium changes in composition as the airways continue distally from the trachea to the alveolar ducts. Which of the following features is last to disappear?

- A. Cartilage (7%)
- ✓ B. Cilia (51%)
- C. Goblet cells (19%)
- D. Mucous glands (11%)
- E. Serous glands (10%)

Correct | 51% Answered correctly | 03 secs Time Spent | 2023 Version

Explanation

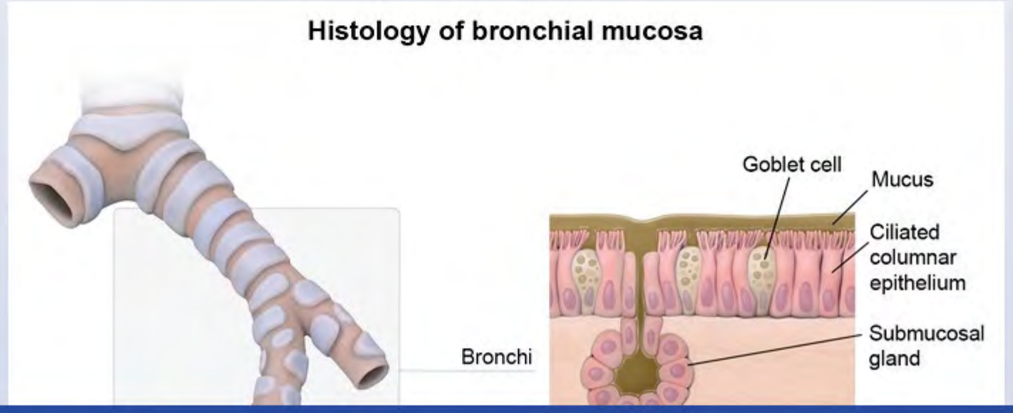

https://t.me/USMLEWorldStep1

Fourth-year medical students are recruited for a research study assessing their ability to interpret biopsy samples obtain
and as
the res
ducts.

Exhibit Display

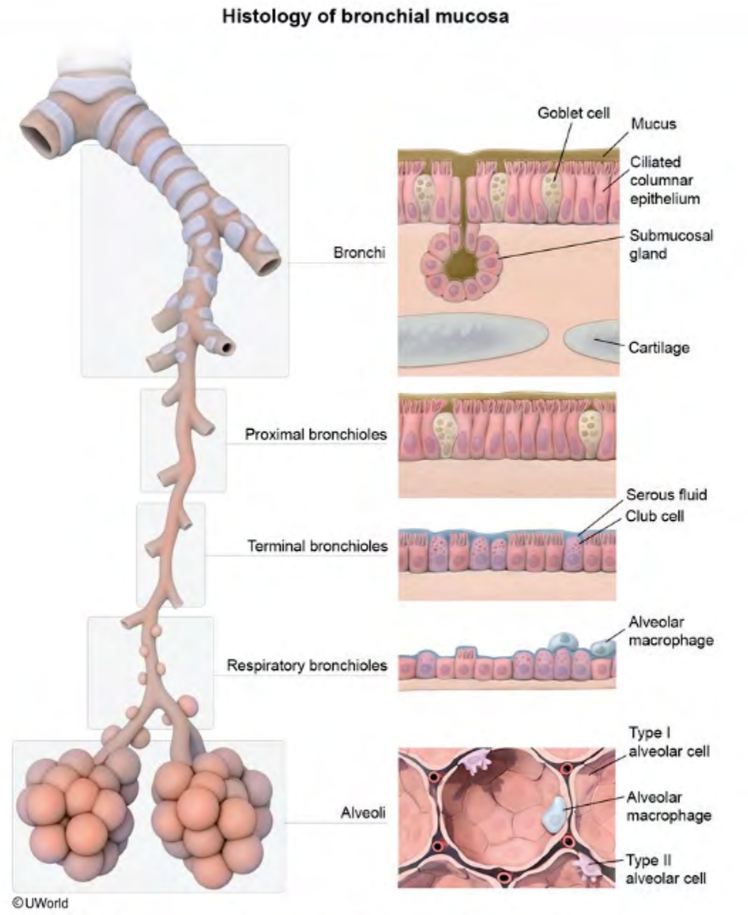

Zoom In | Zoom Out | Reset | New | Existing | My Notebook

Bronchi
gland

https://t.me/USMLEWorldStep1



©UWorld

Ciliated mucosal epithelium lines the pulmonary airways from the trachea to the respiratory bronchioles. The airway epithelium gradually changes from pseudostratified ciliated columnar to ciliated simple cuboidal by the level of the terminal bronchioles. **Ciliated cells** continue to be present through the proximal portions of the **respiratory bronchioles**, but are not present in the alveolar ducts or in the alveoli themselves. This arrangement is important because cilia function to propel mucus toward the pharynx. The presence of cilia beyond the most distal mucus-producing cells (goblet cells end before the terminal bronchioles) prevents bronchiolar mucus accumulation and airflow obstruction.

(Choice A) The rings of hyaline cartilage that encircle the trachea are replaced by cartilaginous plates in the bronchi. These rings and plates help keep the larger airways open and end at the termination of the smallest bronchi (they are not found in bronchioles).

(Choice C) Goblet cells are mucus-secreting cells that are present from the trachea down to the larger bronchioles. They are not found within the terminal bronchioles, which are lined by club cells.

(Choices D and E) The submucosal mucous glands and serous glands are found from the trachea to the distal-most bronchi and produce mucinous components that help trap inhaled particles. They are not present within the bronchioles.

Educational objective:
Bronchi have a ciliated pseudostratified columnar epithelium with mucin-secreting goblet cells and submucosal mucoserous glands. The airway epithelium gradually changes to ciliated simple cuboidal by the level of the terminal bronchioles. Bronchioles lack glands and cartilage, and the number of goblet cells decreases distally, ending before the terminal bronchioles. Ciliated epithelium persists up to the respiratory bronchioles.

Histology	Pulmonary & Critical Care	Respiratory mucosa
Subject	System	Topic

Copyright © UWorld. All rights reserved.

https://t.me/USMLEWorldStep1

A 43-year-old patient comes to the physician due to dyspnea. The black curve shown below represents the pressure/volume relationship in normal lung tissue. The blue curve represents the pressure/volume relationship in the patient's lung tissue.

Which of the following is the most likely cause of this patient's symptoms?

- A. Alpha-1 antitrypsin deficiency
- B. Bronchial asthma
- C. Fibromyalgia
- D. Idiopathic pulmonary arterial hypertension
- E. Pulmonary fibrosis

Submit

https://t.me/USMLEWorldStep1

A 43-year-old patient comes to the physician due to dyspnea. The black curve shown below represents the pressu
the pa

Exhibit Display

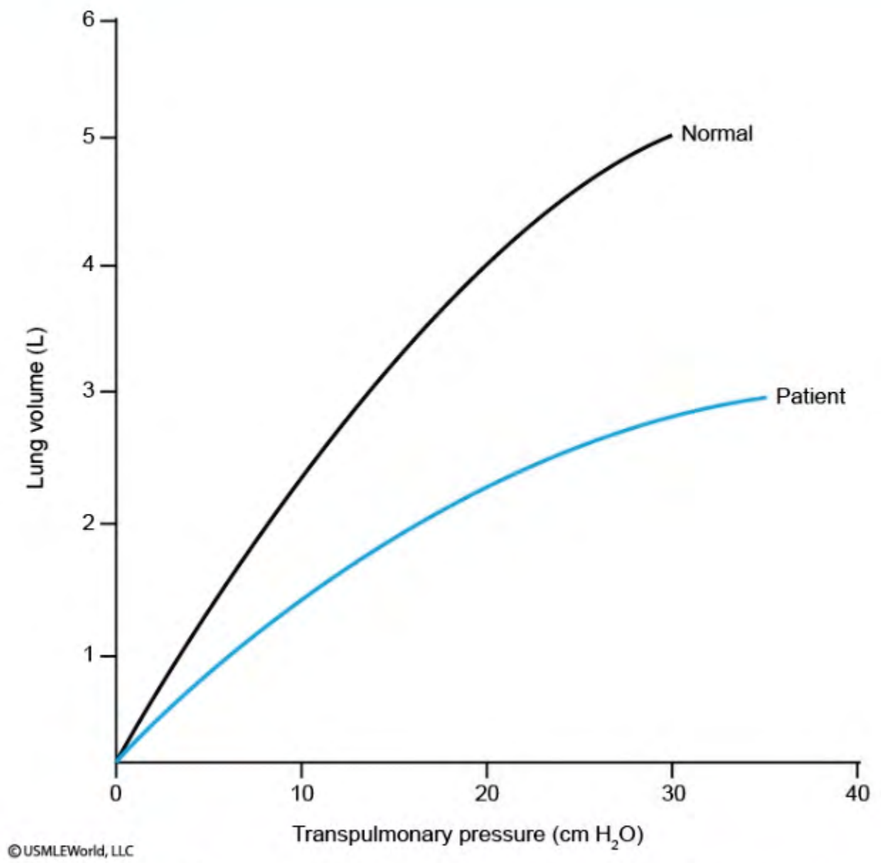

Zoom In Zoom Out Reset New | Existing My Notebook

©USMLEWorld, LLC

Which of the following is the most likely cause of this patient's symptoms?

https://t.me/USMLEWorldStep1

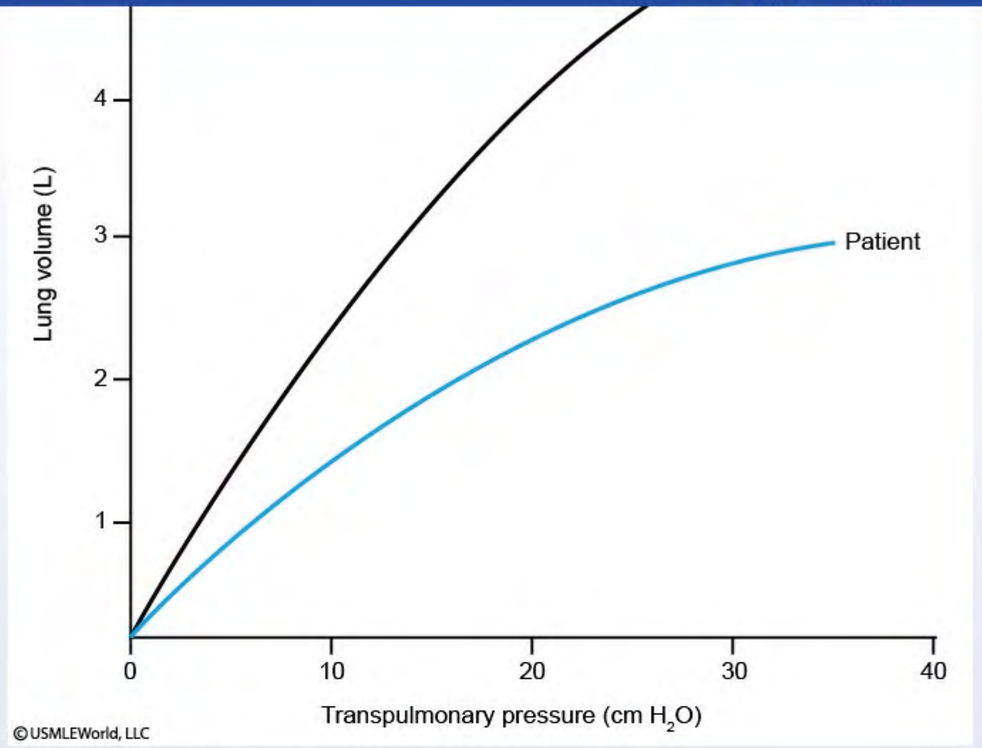

Which of the following is the most likely cause of this patient's symptoms?

- A. Alpha-1 antitrypsin deficiency
- B. Bronchial asthma
- C. Fibromyalgia
- D. Idiopathic pulmonary arterial hypertension
- E. Pulmonary fibrosis

Submit

https://t.me/USMLEWorldStep1

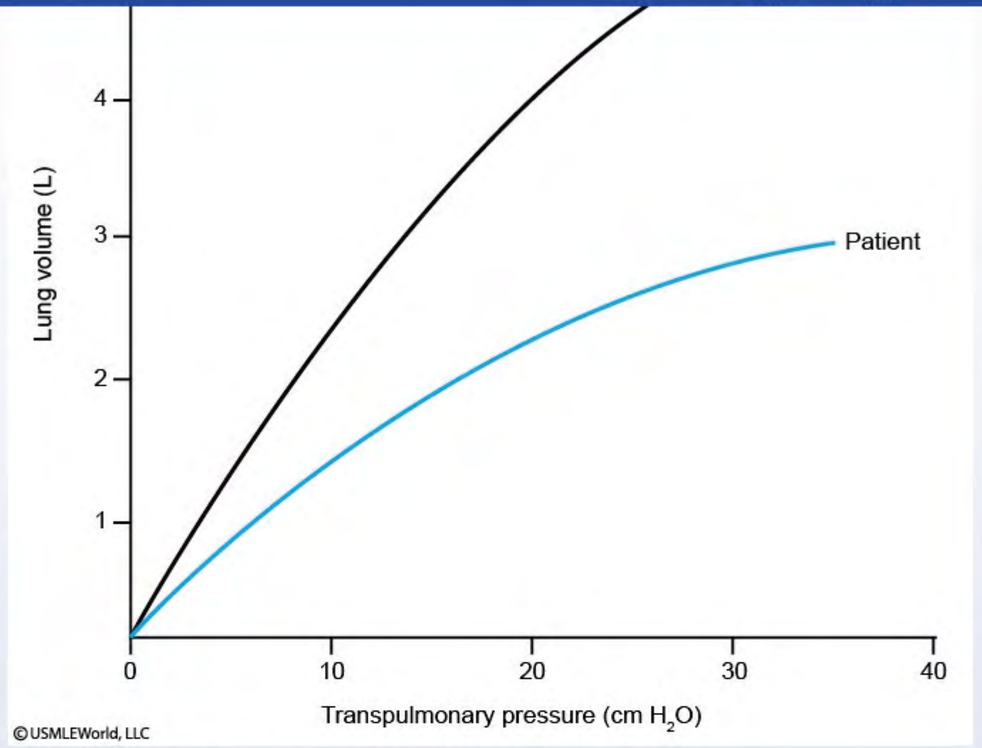

Which of the following is the most likely cause of this patient's symptoms?

- ✗ A. Alpha-1 antitrypsin deficiency (4%)
- B. Bronchial asthma (2%)
- C. Fibromyalgia (0%)
- D. Idiopathic pulmonary arterial hypertension (1%)
- ✓ E. Pulmonary fibrosis (90%)

Incorrect
Correct answer
E

90%
Answered correctly

15 secs
Time Spent

2023
Version

https://t.me/USMLEWorldStep1

Explanation

Exhibit Display

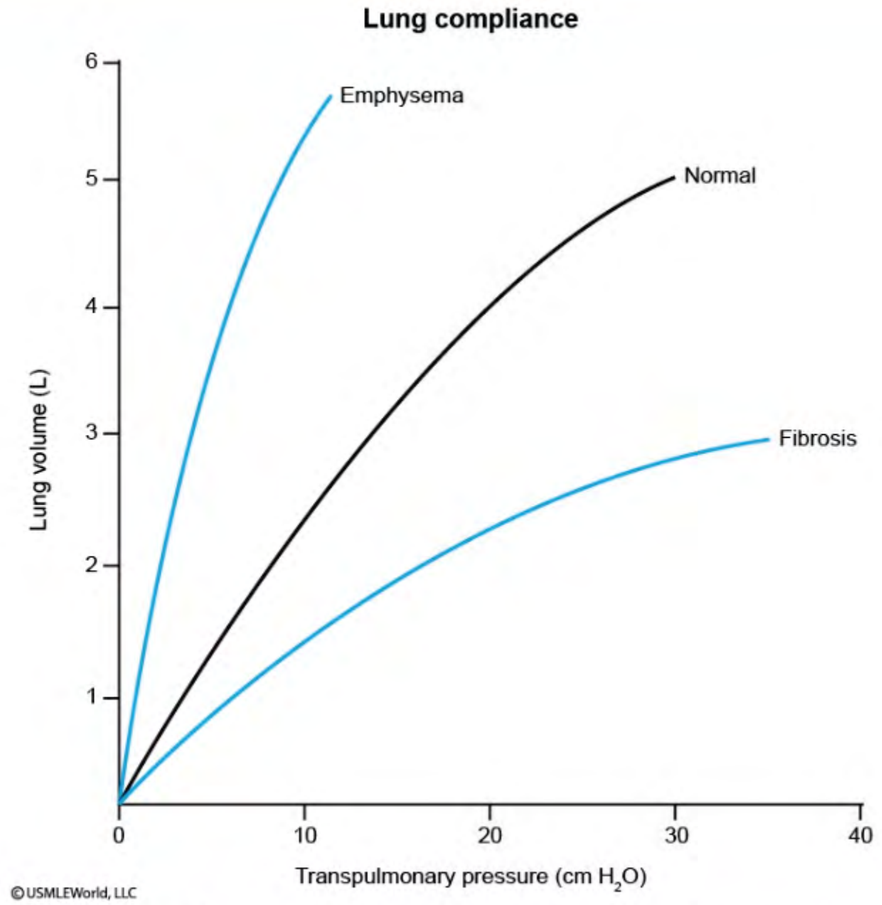

Zoom In Zoom Out Reset New | Existing My Notebook

The pr
given volume the pressure will be significantly increased). Reduced pulmonary parenchymal compliance is the hallmark of **pulmonary fibrosis**.

https://t.me/USMLEWorldStep1

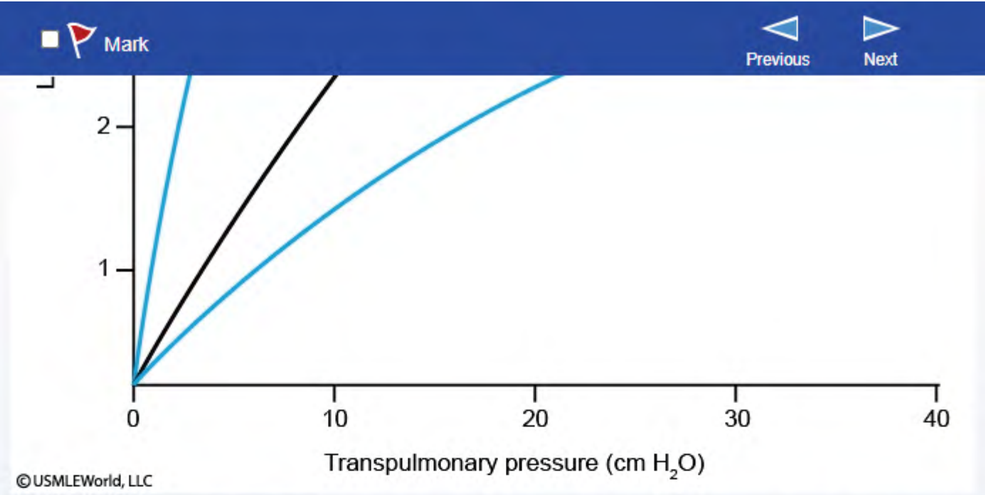

The pressure/volume relationship in this patient's lungs depicts dramatically **reduced compliance** (ie, for any given volume the pressure will be significantly increased). Reduced pulmonary parenchymal compliance is the hallmark of **pulmonary fibrosis**.

(Choice A) Alpha-1 antitrypsin deficiency causes panacinar emphysema and liver cirrhosis. In **emphysema**, the lung parenchyma has **increased compliance**.

(Choice B) Asthma decreases peak expiratory flow rates and FEV_1 during pulmonary function testing, but it does not decrease lung compliance.

(Choice C) Fibromyalgia causes diffuse chronic axial musculoskeletal pain and tenderness. The lung parenchyma is normal.

(Choice D) Idiopathic pulmonary arterial hypertension does not significantly affect lung compliance.

Educational objective:
Reduction in the slope of the curve depicting lung volume versus distending pressure indicates decreased lung compliance (the hallmark of pulmonary fibrosis).

Physiology	Pulmonary & Critical Care	Interstitial lung disease
Subject	System	Topic

Copyright © UWorld. All rights reserved.

A 41-year-old man comes to the emergency department due to 3 weeks of low-grade fever, productive cough, and a 4.5-kg (10-lb) weight loss. The patient drinks 10-12 beers a day. On physical examination, he appears cachectic. Poor dentition and clubbing of the fingers are noted. A foul-smelling sputum sample is expectorated and sent for Gram stain and culture. CT scan of the chest is shown in the image below:

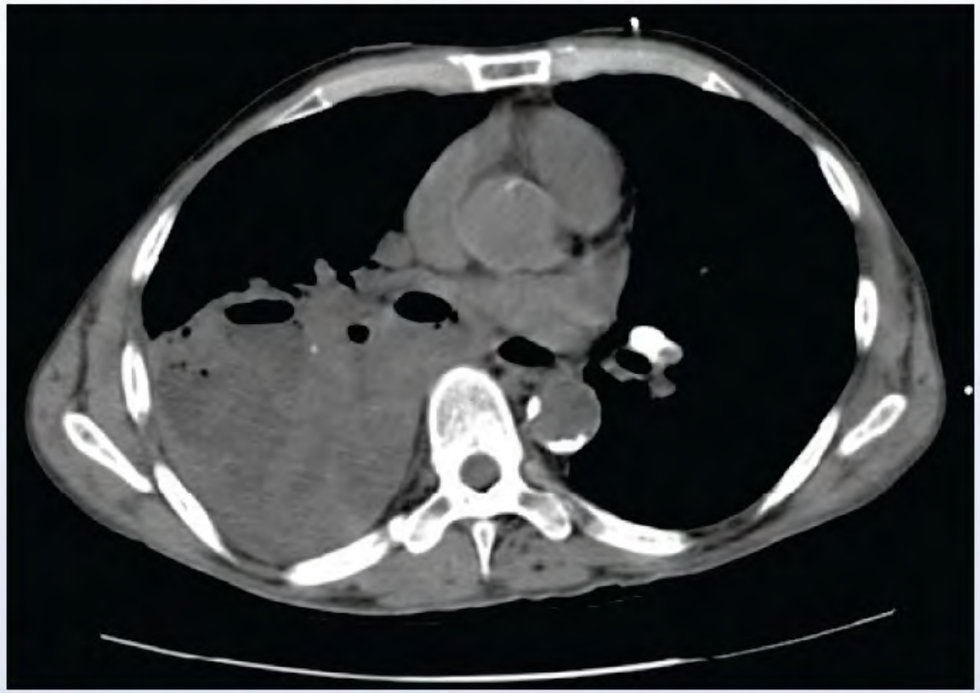

Empiric antimicrobial therapy should include coverage against which of the following pathogens?

- A. Cell wall–deficient bacteria
- B. Intestinal gram-negative flora
- C. Resident skin microbiota
- D. Staphylococci resistant to beta-lactams

https://t.me/USMLEWorldStep1

A 41-year-old man comes to the emergency department due to 3 weeks of low-grade fever, productive cough, and
a 4.5-k
cache
and se

Exhibit Display

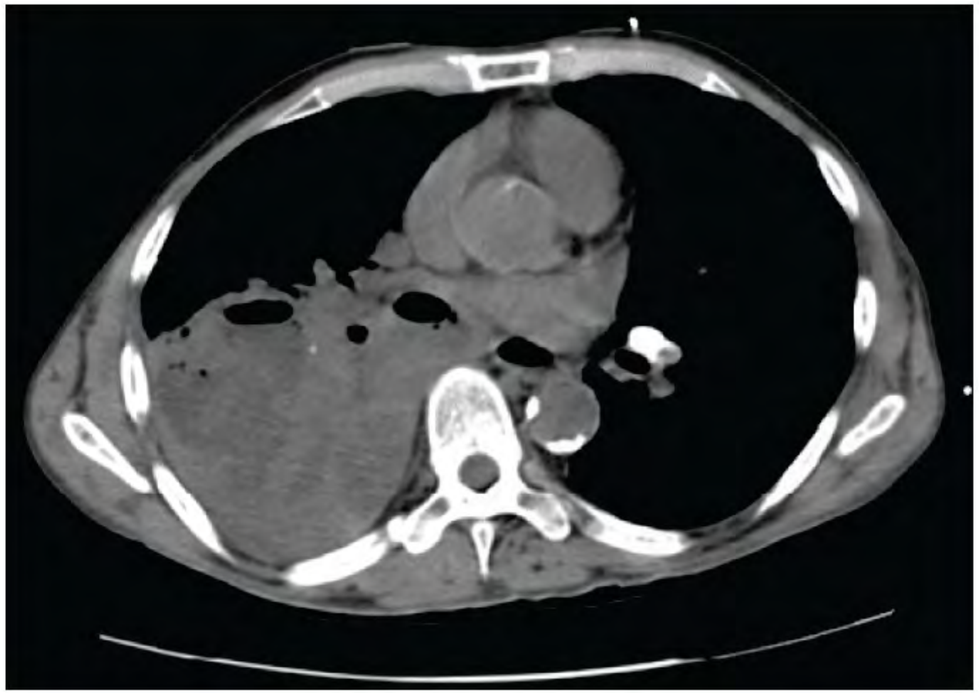

Zoom In | Zoom Out | Reset | New | Existing | My Notebook

Empiri

D. Staphylococci resistant to beta-lactams

https://t.me/USMLEWorldStep1

and sent for Gram stain and culture. CT scan of the chest is shown in the image below:

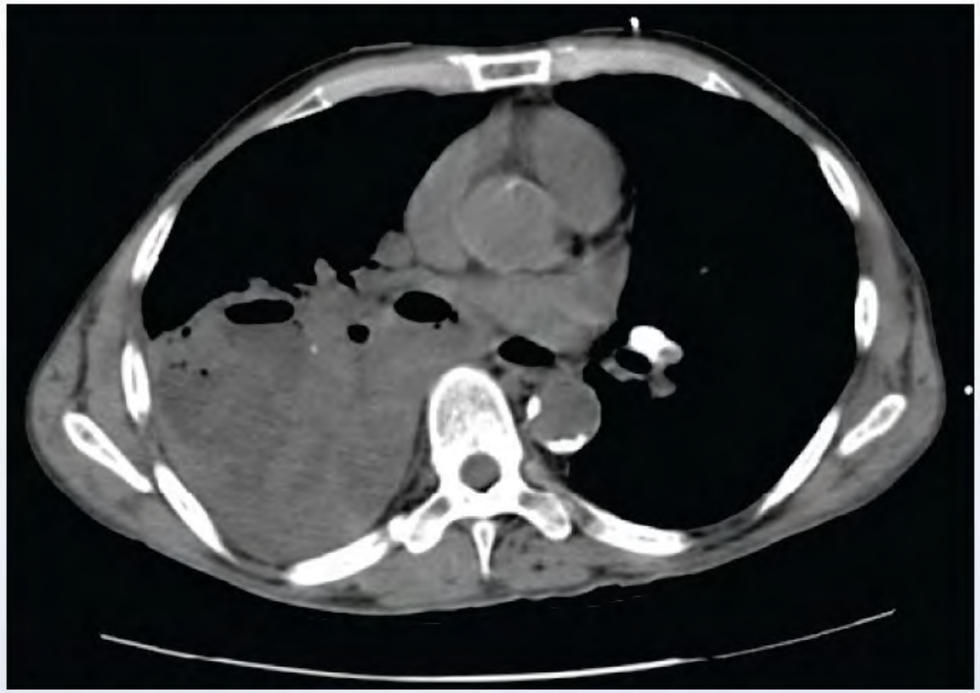

Empiric antimicrobial therapy should include coverage against which of the following pathogens?

- A. Cell wall–deficient bacteria
- B. Intestinal gram-negative flora
- C. Resident skin microbiota
- D. Staphylococci resistant to beta-lactams
- E. Aerobic and anaerobic organisms

Submit

https://t.me/USMLEWorldStep1

and sent for Gram stain and culture. CT scan of the chest is shown in the image below:

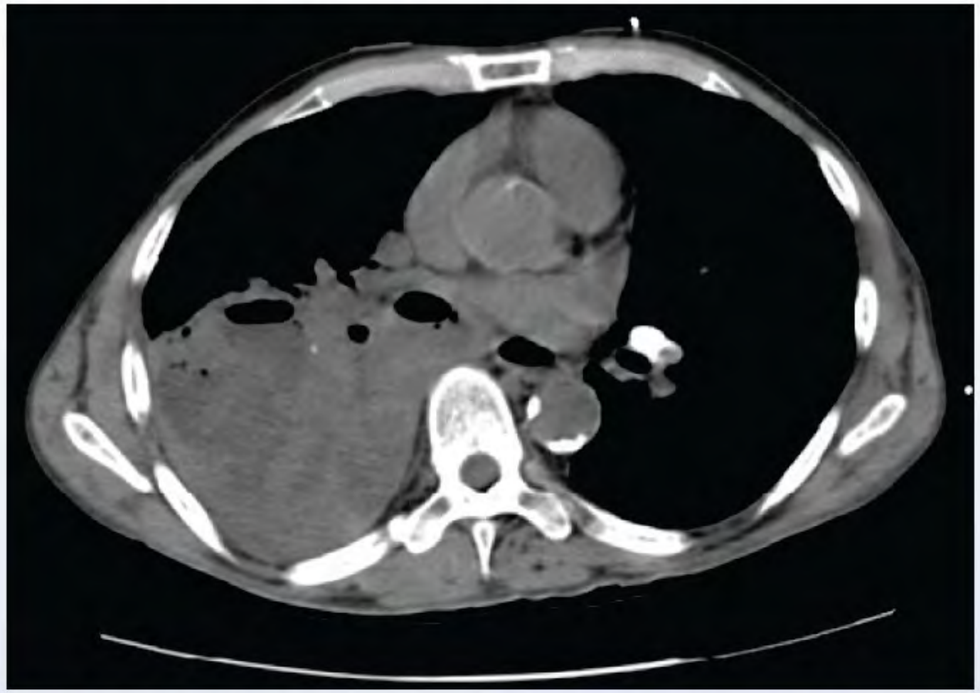

Empiric antimicrobial therapy should include coverage against which of the following pathogens?

- A. Cell wall–deficient bacteria (8%)
- ✗ B. Intestinal gram-negative flora (24%)
- C. Resident skin microbiota (1%)
- D. Staphylococci resistant to beta-lactams (7%)
- ✓ E. Aerobic and anaerobic organisms (58%)

Incorrect
Correct answer
E

58%
Answered correctly

20 secs
Time Spent

2023
Version

https://t.me/USMLEWorldStep1

Incorrect
Correct answer
E

58%
Answered correctly

20 secs
Time Spent

2023
Version

Expl

Exhibit Display

Lung abscess

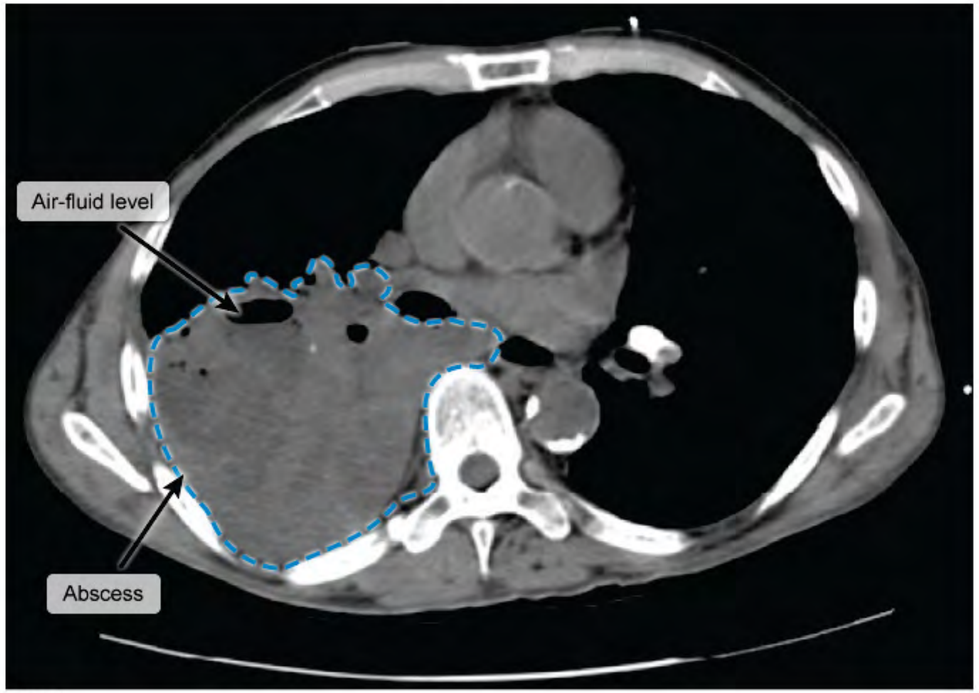

©UWorld

Zoom In | Zoom Out | Reset | New | Existing | My Notebook

This p
fluid le
alveoli
reflexes) or episodes of dysphagia (eg, previous stroke, esophageal stricture). Periodontal disease is frequently

https://t.me/USMLEWorldStep1

©UWorld

This patient's excessive alcohol consumption, subacute pulmonary symptoms, and dense lung opacity with an air-fluid level are consistent with **lung abscess**. Most cases are due to **aspiration of oropharyngeal flora** into the alveoli during reduced levels of consciousness from drug or **alcohol use disorder** (which impairs cough and gag reflexes) or episodes of dysphagia (eg, previous stroke, esophageal stricture). Periodontal disease is frequently present, which increases the concentration of anaerobic bacteria in the gingival crevices. Most lung abscesses are **polymicrobial** and involve both upper respiratory **aerobic** organisms and oral cavity **anaerobes** (eg, *Bacteroides, Prevotella*, *Fusobacterium*, *Peptostreptococcus*).

Manifestations are typically **subacute** and include fever, cough with **foul-smelling sputum**, night sweats, and weight loss; digital clubbing sometimes occurs. Diagnosis is usually made when chest imaging reveals a dense fluid collection or cavitary infiltrate (often with an **air-fluid level**) in dependent portions of the lung (eg, superior portion of lower lobe).

Treatment with ampicillin/sulbactam or a carbapenem is considered first-line therapy due to excellent coverage of oral anaerobes and aerobic gram-positive organisms (eg, *Streptococcus pneumoniae*). Clindamycin was used in the past but is now reserved for those with penicillin allergies due to high risk of *Clostridioides difficile* infection.

(Choice A) *Mycoplasma pneumoniae* is a cell wall–deficient bacteria that causes atypical pneumonia. Patients frequently have subacute cough and low-grade fever, but chest imaging usually demonstrates bilateral reticulo-nodular opacities. The presence of foul-smelling sputum and a cavitary infiltrate with an air-fluid level makes lung abscess much more likely.

(Choice B) Although gram-negative intestinal flora (eg, *Klebsiella pneumoniae*) can cause lung abscess, empiric treatment must also target upper respiratory anaerobic organisms because they are present in most lung abscesses.

(Choice C) Skin flora (eg, coagulase-negative staphylococci) are common causes of blood culture contaminants, but they do not typically cause pulmonary infection.

(Choice D) Methicillin-resistant *Staphylococcus aureus* can cause hospital-acquired or post–viral pneumonia complicated by lung abscess formation. However, purulent, foul-smelling sputum is highly indicative of anaerobic involvement; in addition, *S aureus* is a less common cause of lung abscess in patients at high risk for aspiration

https://t.me/USMLEWorldStep1

Prevotella, *Fusobacterium*, *Peptostreptococcus*).

Manifestations are typically **subacute** and include fever, cough with **foul-smelling sputum**, night sweats, and weight loss; digital clubbing sometimes occurs. Diagnosis is usually made when chest imaging reveals a dense fluid collection or cavitary infiltrate (often with an **air-fluid level**) in dependent portions of the lung (eg, superior portion of lower lobe).

Treatment with ampicillin/sulbactam or a carbapenem is considered first-line therapy due to excellent coverage of oral anaerobes and aerobic gram-positive organisms (eg, *Streptococcus pneumoniae*). Clindamycin was used in the past but is now reserved for those with penicillin allergies due to high risk of *Clostridioides difficile* infection.

(Choice A) *Mycoplasma pneumoniae* is a cell wall–deficient bacteria that causes atypical pneumonia. Patients frequently have subacute cough and low-grade fever, but chest imaging usually demonstrates bilateral reticulonodular opacities. The presence of foul-smelling sputum and a cavitary infiltrate with an air-fluid level makes lung abscess much more likely.

(Choice B) Although gram-negative intestinal flora (eg, *Klebsiella pneumoniae*) can cause lung abscess, empiric treatment must also target upper respiratory anaerobic organisms because they are present in most lung abscesses.

(Choice C) Skin flora (eg, coagulase-negative staphylococci) are common causes of blood culture contaminants, but they do not typically cause pulmonary infection.

(Choice D) Methicillin-resistant *Staphylococcus aureus* can cause hospital-acquired or post–viral pneumonia complicated by lung abscess formation. However, purulent, foul-smelling sputum is highly indicative of anaerobic involvement; in addition, *S aureus* is a less common cause of lung abscess in patients at high risk for aspiration (eg, alcohol/drug use).

Educational objective:
Patients with alcohol use disorder are at increased risk for lung abscess due to the aspiration of oral flora during periods of unconsciousness. Most cases involve a mixture of upper respiratory aerobes and oral cavity anaerobes (eg, *Bacteroides*, *Prevotella*, *Fusobacterium*, *Peptostreptococcus*). Manifestations include subacute fever, cough, and foul-smelling sputum.

https://t.me/USMLEWorldStep1

A 54-year-old woman is brought to the emergency department after a generalized tonic-clonic seizure. The patient had fever, night sweats, fatigue, and productive cough during the previous week. She underwent a renal transplant 2 years ago and takes immunosuppressive therapy. On examination, she is febrile and postictal. There are scattered lung crackles and normal heart sounds. Leukocyte count is elevated, and chest x-ray reveals patchy bronchopneumonia with several nodules. Brain imaging shows multifocal abscesses. Sputum Gram stain reveals filamentous, branching gram-positive rods as shown below:

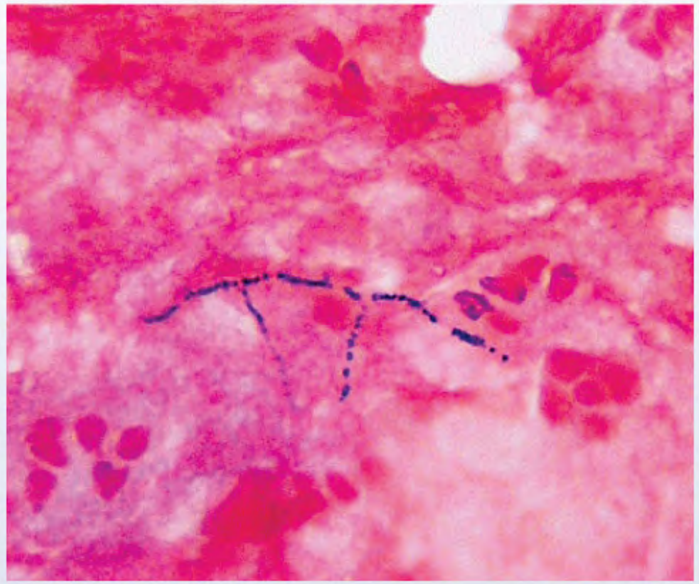

This pathogen is likely to demonstrate which of the following characteristics?

- A. Anaerobic growth
- B. Angioinvasion
- C. Intracellular multiplication
- D. Partial acid fastness
- E. Phospholipase production

https://t.me/USMLEWorldStep1

A 54-year-old woman is brought to the emergency department after a generalized tonic-clonic seizure. The patient had fe
2 year
scatte
bronch
filame

Exhibit Display

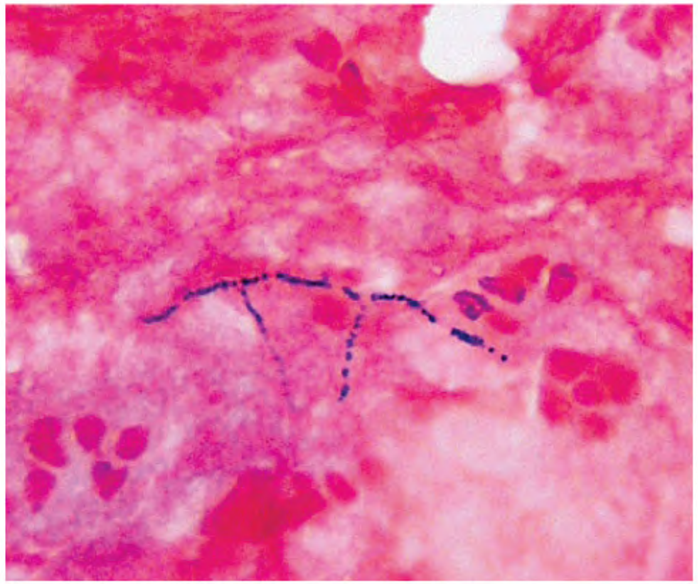

Zoom In Zoom Out Reset New | Existing My Notebook

This p

D. Partial acid-fastness
E. Phospholipase production

https://t.me/USMLEWorldStep1

2 years ago and takes immunosuppressive therapy. On examination, she is febrile and postictal. There are scattered lung crackles and normal heart sounds. Leukocyte count is elevated, and chest x-ray reveals patchy bronchopneumonia with several nodules. Brain imaging shows multifocal abscesses. Sputum Gram stain reveals filamentous, branching gram-positive rods as shown below:

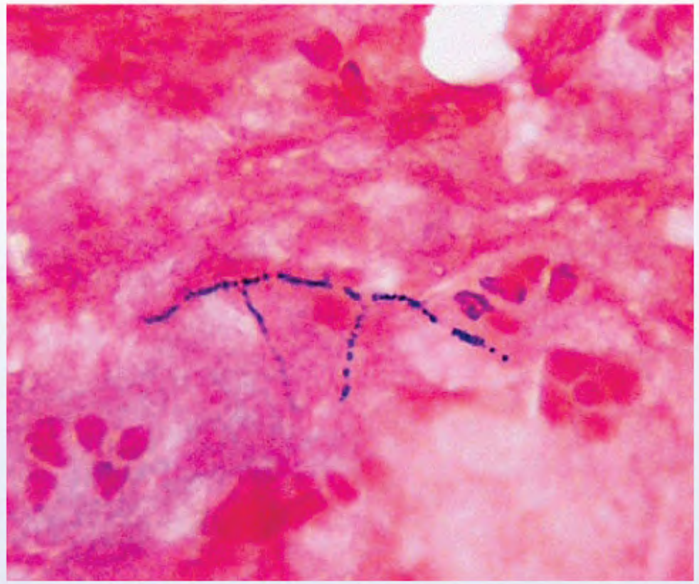

This pathogen is likely to demonstrate which of the following characteristics?

- A. Anaerobic growth
- B. Angioinvasion
- C. Intracellular multiplication
- D. Partial acid fastness
- E. Phospholipase production

Submit

https://t.me/USMLEWorldStep1

2 years ago and takes immunosuppressive therapy. On examination, she is febrile and postictal. There are scattered lung crackles and normal heart sounds. Leukocyte count is elevated, and chest x-ray reveals patchy bronchopneumonia with several nodules. Brain imaging shows multifocal abscesses. Sputum Gram stain reveals filamentous, branching gram-positive rods as shown below:

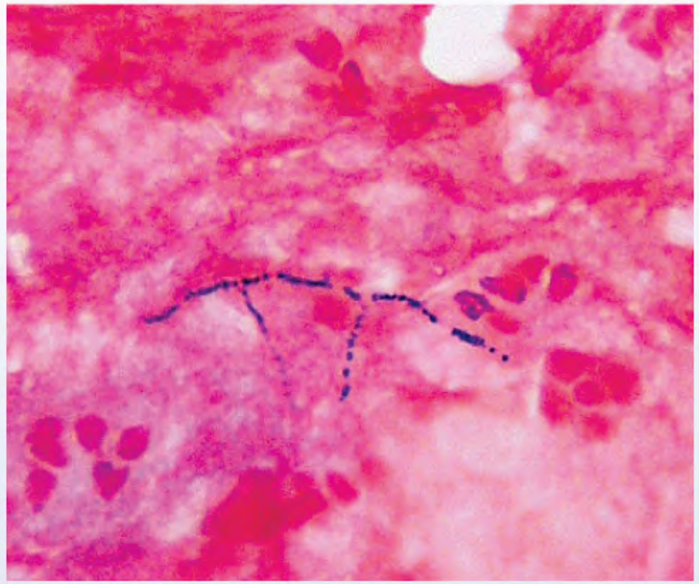

This pathogen is likely to demonstrate which of the following characteristics?

- A. Anaerobic growth (17%)
- B. Angioinvasion (7%)
- ✗ C. Intracellular multiplication (6%)
- ✓ D. Partial acid fastness (64%)
- E. Phospholipase production (4%)

Incorrect
Correct answer
D

64%
Answered correctly

13 mins, 27 secs
Time Spent

2023
Version

https://t.me/USMLEWorldStep1

Nocardiosis	
Microbiology	• Gram-positive rod (beaded or branching) • Partially acid-fast • Aerobic
Epidemiology	• Endemic in soil • Disease from spore inhalation or traumatic inoculation into skin • Immunocompromised or elderly patients
Clinical features	• Pneumonia: similar to tuberculosis • CNS involvement: brain abscess • Cutaneous involvement
Treatment	• Trimethoprim-sulfamethoxazole • Surgical drainage of abscesses

This patient with bronchopneumonia, brain abscesses, and branching, filamentous bacteria on sputum culture likely has ***Nocardia*** infection. *Nocardia* is a ubiquitous organism found in soil that is transmitted by inhalation or inoculation into the skin. Because the pathogen has minimal virulence, those with **impaired cell-mediated immunity** (eg, immunosuppressive therapy, AIDS) are at greatest risk. **Bronchopneumonia** is the most common manifestation. Patients usually have cough, purulent sputum, and pulmonary nodules or cavitations. Spread through the bloodstream to the brain occurs in up to 50% of cases and can lead to multiloculated brain abscesses and seizures.

The microscopic appearances of *Nocardia* and *Actinomyces* are similar; both organisms are gram-positive and grow in **branching filaments** that resemble the hyphae of fungus. However, unlike *Actinomyces*, *Nocardia* has **mycolic acid** in its cell wall, which causes it to stain **partially acid-fast**.

(Choice A) *Actinomyces* is an anaerobic organism that primarily causes cervicofacial infections characterized by chronic, nonpainful, mandibular swelling with abscesses, draining sinuses, and sulfur granules.

(Choice B) *Aspergillus* species can cause angioinvasive pneumonia (classic triad of fever, pleuritic chest pain

https://t.me/USMLEWorldStep1

This patient with bronchopneumonia, brain abscesses, and branching, filamentous bacteria on sputum culture likely has ***Nocardia*** infection. *Nocardia* is a ubiquitous organism found in soil that is transmitted by inhalation or inoculation into the skin. Because the pathogen has minimal virulence, those with **impaired cell-mediated immunity** (eg, immunosuppressive therapy, AIDS) are at greatest risk. **Bronchopneumonia** is the most common manifestation. Patients usually have cough, purulent sputum, and pulmonary nodules or cavitations. Spread through the bloodstream to the brain occurs in up to 50% of cases and can lead to multiloculated brain abscesses and seizures.

The microscopic appearances of *Nocardia* and *Actinomyces* are similar; both organisms are gram-positive and grow in **branching filaments** that resemble the hyphae of fungus. However, unlike *Actinomyces*, *Nocardia* has **mycolic acid** in its cell wall, which causes it to stain **partially acid-fast**.

(Choice A) *Actinomyces* is an anaerobic organism that primarily causes cervicofacial infections characterized by chronic, nonpainful, mandibular swelling with abscesses, draining sinuses, and sulfur granules.

(Choice B) *Aspergillus* species can cause angioinvasive pneumonia (classic triad of fever, pleuritic chest pain, and hemoptysis) in patients who are immunocompromised. However, sputum microscopy typically reveals septate hyaline hyphae, not branching, filamentous, gram-positive bacteria.

(Choice C) *Mycobacterium tuberculosis* is an acid-fast mycobacterium that is inhaled into the lungs and replicates intracellularly. Although *M tuberculosis* can grow in long, serpentine cords due to the presence of cord factor, it does not grow in thin, branching filaments. In addition, the presence of brain abscesses makes *Nocardia* far more likely.

(Choice E) *Clostridium perfringens* is a common cause of food poisoning and can also cause gas gangrene/myonecrosis through the generation of a phospholipase exotoxin. Although *C perfringens* is a gram-positive bacillus, it does not form branching filaments in culture.

Educational objective:
Nocardia is a filamentous, branching, gram-positive bacteria that is partially acid-fast. It most commonly causes pneumonia and brain abscesses in immunocompromised patients.

https://t.me/USMLEWorldStep1

This patient with bronchopneumonia, brain abscesses, and branching, filamentous bacteria on sputum culture likely h
inocula
immu
manife
throug
and se

The m
grow i
mycol

(Choi
chroni

(Choi
and he
hyalin

(Choi
intrace
does r
likely.

(Choi
gangre
positiv

Educa
Nocar
pneumonia and brain abscesses in immunocompromised patients.

Exhibit Display

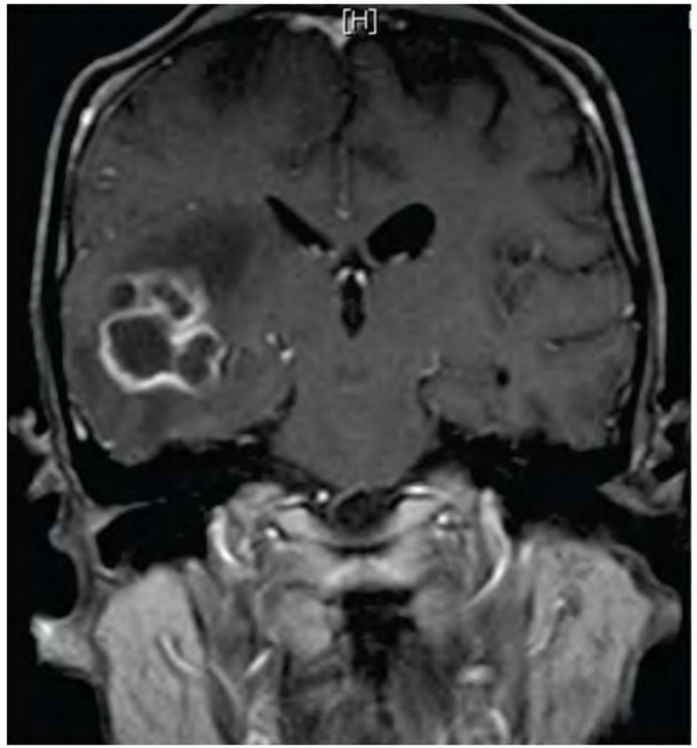

Zoom In Zoom Out Reset New | Existing My Notebook

https://t.me/USMLEWorldStep1

This patient with bronchopneumonia, brain abscesses, and branching, filamentous bacteria on sputum culture likely h
inocula
immu
manife
throug
and se

The m
grow i
mycol

(Choi
chroni

(Choi
and he
hyalin

(Choi
intrace
does r
likely.

(Choi
gangre
positiv

Educa
Nocar
pneumonia and brain abscesses in immunocompromised patients.

Exhibit Display

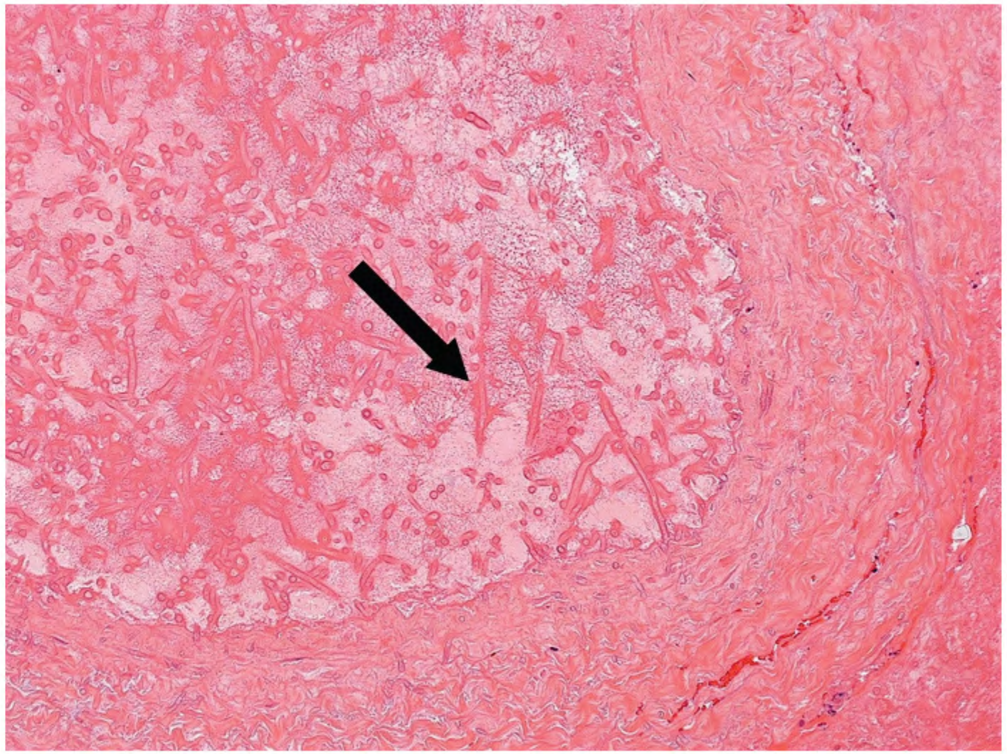

Zoom In | Zoom Out | Reset | New | Existing | My Notebook

https://t.me/USMLEWorldStep1

A 56-year-old construction worker comes to the office after receiving a letter from his employer advising him of significant exposure to asbestos during a building project 25 years ago. He is currently asymptomatic and feels well. Medical conditions include hypertension and osteoarthritis, for which he takes amlodipine daily and ibuprofen as needed. The patient quit smoking 10 years ago and does not use alcohol or illicit drugs. Physical examination is within normal limits. Chest imaging is normal. He is concerned about his risk of developing cancer. Due to his occupational exposure, this patient is at greatest risk of malignancy arising from which of the following?

- A. Bronchial epithelium
- B. Hematopoietic stem cells
- C. Liver parenchyma
- D. Nasopharyngeal epithelium
- E. Pancreatic ductal cells
- F. Pleura mesothelium
- G. Urinary bladder epithelium

Submit

https://t.me/USMLEWorldStep1

A 56-year-old construction worker comes to the office after receiving a letter from his employer advising him of significant exposure to asbestos during a building project 25 years ago. He is currently asymptomatic and feels well. Medical conditions include hypertension and osteoarthritis, for which he takes amlodipine daily and ibuprofen as needed. The patient quit smoking 10 years ago and does not use alcohol or illicit drugs. Physical examination is within normal limits. Chest imaging is normal. He is concerned about his risk of developing cancer. Due to his occupational exposure, this patient is at greatest risk of malignancy arising from which of the following?

- ✓ A. Bronchial epithelium (61%)
- ✗ B. Hematopoietic stem cells (0%)
- C. Liver parenchyma (1%)
- D. Nasopharyngeal epithelium (0%)
- E. Pancreatic ductal cells (0%)
- F. Pleura mesothelium (36%)
- G. Urinary bladder epithelium (0%)

Incorrect
Correct answer
A

61%
Answered correctly

03 secs
Time Spent

2023
Version

Explanation

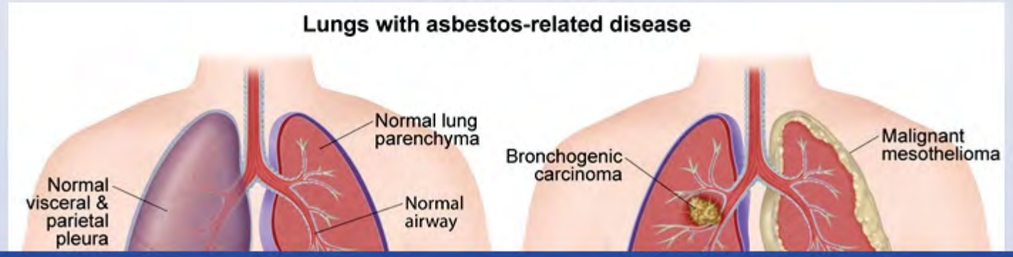

https://t.me/USMLEWorldStep1

A 56-year-old construction worker comes to the office after receiving a letter from his employer advising him of
signifi
well. M
as nee
is with
occupa

Exhibit Display

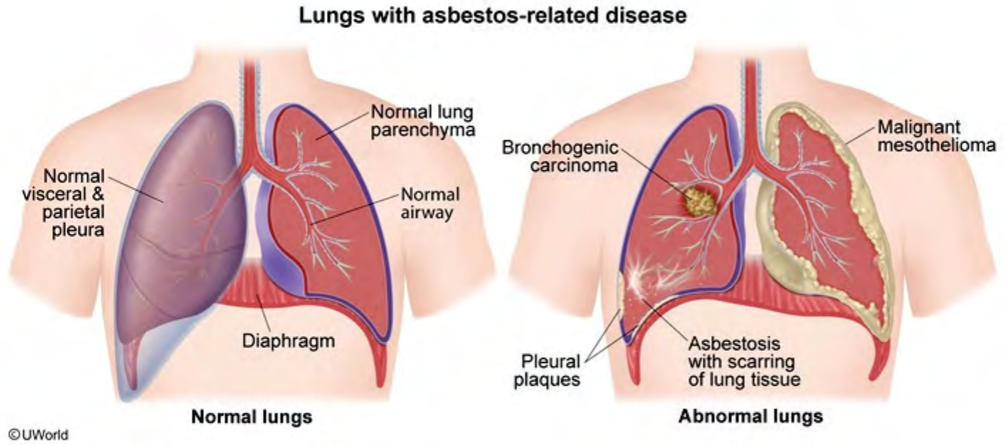

Zoom In | Zoom Out | Reset | New | Existing | My Notebook

https://t.me/USMLEWorldStep1

Asbestos is a fiber composed of hydrated magnesium silicates commonly used in the shipbuilding, construction, and textile industries. Inhalation of fine asbestos fibers causes epithelial cell injury, activation of macrophages, and chronic interstitial inflammation and fibrosis.

The major clinical manifestations of asbestos exposure include the following:

- **Pleural disease** includes pleural effusions and pleural plaques. Pleural plaques are a hallmark of asbestos exposure that typically affect the parietal pleura along the lower lungs and diaphragm. The plaques are composed of discrete circumscribed areas of dense collagen that frequently become calcified.
- **Asbestosis** is characterized by progressive **pulmonary fibrosis** that is most predominant in the lower lobes and by the presence of **asbestos bodies** (golden-brown beaded rods with translucent centers).
- **Bronchogenic carcinoma** is the **most common malignancy** associated with asbestos exposure. Smoking and asbestos exposure have a synergistic effect on the development of lung carcinoma, increasing the risk from 6-fold in nonsmoking patients with asbestos exposure to 60-fold in asbestos-exposed patients who smoke regularly.
- **Malignant mesothelioma** is a rare malignancy of the pleura for which asbestos is the only known environmental risk factor. It is **less common than bronchogenic carcinoma** in asbestos-exposed patients **(Choice F)**. However, mesothelioma is more specific for heavy asbestos exposure.

(Choice B) Direct-acting alkylating agents and benzene exposure are associated with acute leukemias, which occur due to malignant proliferation of hematopoietic stem cells.

(Choice C) Aflatoxin exposure, which can occur after exposure to contaminated crops (eg, peanuts, corn), is a chemical risk factor associated with hepatocellular cancer, although viral hepatitis, cirrhosis, and alcohol abuse are more common risk factors.

(Choice D) Epstein-Barr viral infection and heavy alcohol use, particularly when combined with smoking, increase the risk of nasopharyngeal cancer.

(Choice E) Pancreatic cancer is strongly associated with tobacco use and obesity. However, this patient's asbestos exposure places him at higher risk of developing bronchogenic carcinoma.

https://t.me/USMLEWorldStep1

composed of discrete circumscribed areas of dense collagen that frequently become calcified.

- **Asbestosis** is characterized by progressive **pulmonary fibrosis** that is most predominant in the lower lobes and by the presence of **asbestos bodies** (golden-brown beaded rods with translucent centers).
- **Bronchogenic carcinoma** is the **most common malignancy** associated with asbestos exposure. Smoking and asbestos exposure have a synergistic effect on the development of lung carcinoma, increasing the risk from 6-fold in nonsmoking patients with asbestos exposure to 60-fold in asbestos-exposed patients who smoke regularly.
- **Malignant mesothelioma** is a rare malignancy of the pleura for which asbestos is the only known environmental risk factor. It is **less common than bronchogenic carcinoma** in asbestos-exposed patients **(Choice F)**. However, mesothelioma is more specific for heavy asbestos exposure.

(Choice B) Direct-acting alkylating agents and benzene exposure are associated with acute leukemias, which occur due to malignant proliferation of hematopoietic stem cells.

(Choice C) Aflatoxin exposure, which can occur after exposure to contaminated crops (eg, peanuts, corn), is a chemical risk factor associated with hepatocellular cancer, although viral hepatitis, cirrhosis, and alcohol abuse are more common risk factors.

(Choice D) Epstein-Barr viral infection and heavy alcohol use, particularly when combined with smoking, increase the risk of nasopharyngeal cancer.

(Choice E) Pancreatic cancer is strongly associated with tobacco use and obesity. However, this patient's asbestos exposure places him at higher risk of developing bronchogenic carcinoma.

(Choice G) Beta-naphthylamine is used in aniline dyes and the rubber industry; it is associated with increased incidence of bladder carcinoma.

Educational objective:
Patients with a long history of asbestos exposure are at risk for developing asbestosis, pleural disease, and malignancies such as bronchogenic carcinoma and mesothelioma. Bronchogenic carcinoma is the most common malignancy in this population, although mesothelioma is more specific for asbestos exposure.

https://t.me/USMLEWorldStep1

A 64-year-old man is evaluated for worsening cough and shortness of breath. The patient has a history of hypertension and type 2 diabetes mellitus. He smokes a pack of cigarettes daily and drinks alcohol occasionally. Temperature is 38 C (100.4 F), blood pressure is 140/82 mm Hg, and pulse is 92/min. Lung auscultation reveals abnormal breath sounds. Chest x-ray is shown below.

Which of the following is the most likely cause of the observed pulmonary findings in this patient?

- A. Elevated pulmonary capillary hydrostatic pressure
- B. Exaggerated reactivity and inflammation of the airways
- C. Excessive fibroblast proliferation and extracellular matrix deposition
- D. Leakage of protein-rich fluid in the alveolar airspaces
- E. Mucous gland hyperplasia and inflammation in the large airways

Submit

https://t.me/USMLEWorldStep1

A 64-year-old man is evaluated for worsening cough and shortness of breath. The patient has a history of hypert
Tempe
abnorr

Exhibit Display

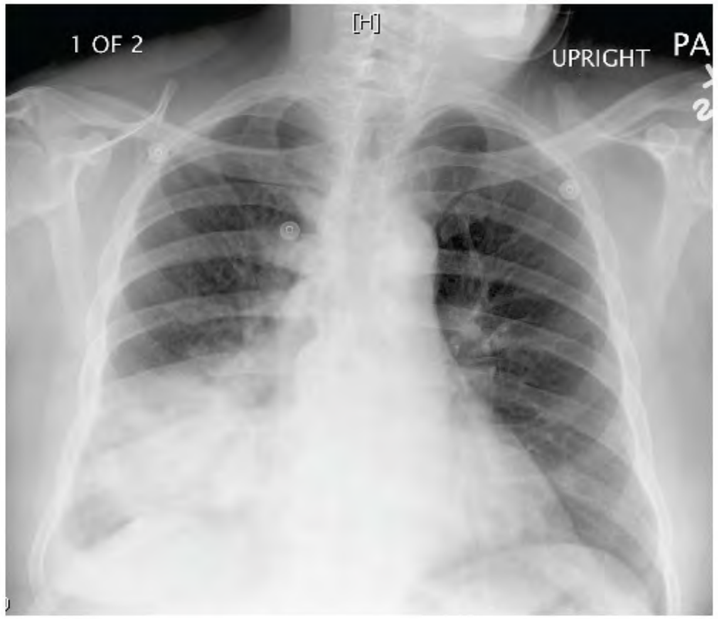

Zoom In Zoom Out Reset New | Existing My Notebook

Which

E. Mucous gland hyperplasia and inflammation in the large airways

https://t.me/USMLEWorldStep1

hypertension and type 2 diabetes mellitus. He smokes a pack of cigarettes daily and drinks alcohol occasionally. Temperature is 38 C (100.4 F), blood pressure is 140/82 mm Hg, and pulse is 92/min. Lung auscultation reveals abnormal breath sounds. Chest x-ray is shown below.

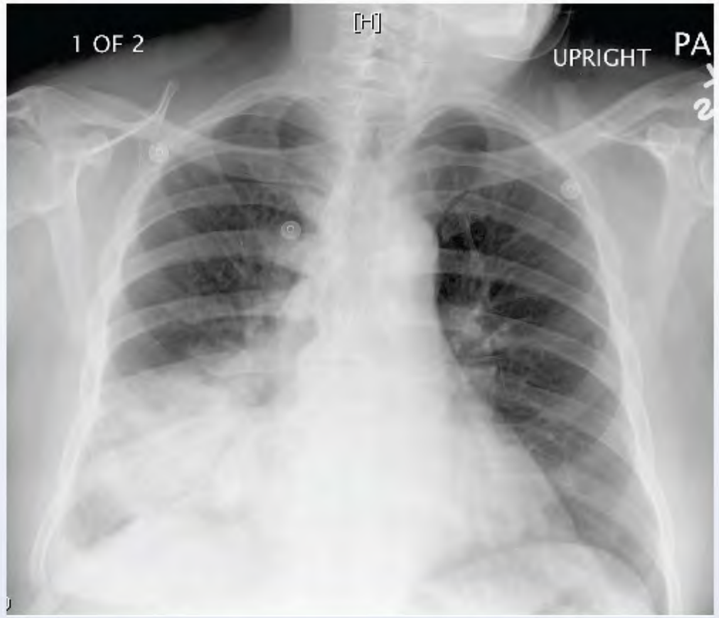

Which of the following is the most likely cause of the observed pulmonary findings in this patient?

- A. Elevated pulmonary capillary hydrostatic pressure
- B. Exaggerated reactivity and inflammation of the airways
- C. Excessive fibroblast proliferation and extracellular matrix deposition
- D. Leakage of protein-rich fluid in the alveolar airspaces
- E. Mucous gland hyperplasia and inflammation in the large airways

Submit

https://t.me/USMLEWorldStep1

hypertension and type 2 diabetes mellitus. He smokes a pack of cigarettes daily and drinks alcohol occasionally. Temperature is 38 C (100.4 F), blood pressure is 140/82 mm Hg, and pulse is 92/min. Lung auscultation reveals abnormal breath sounds. Chest x-ray is shown below.

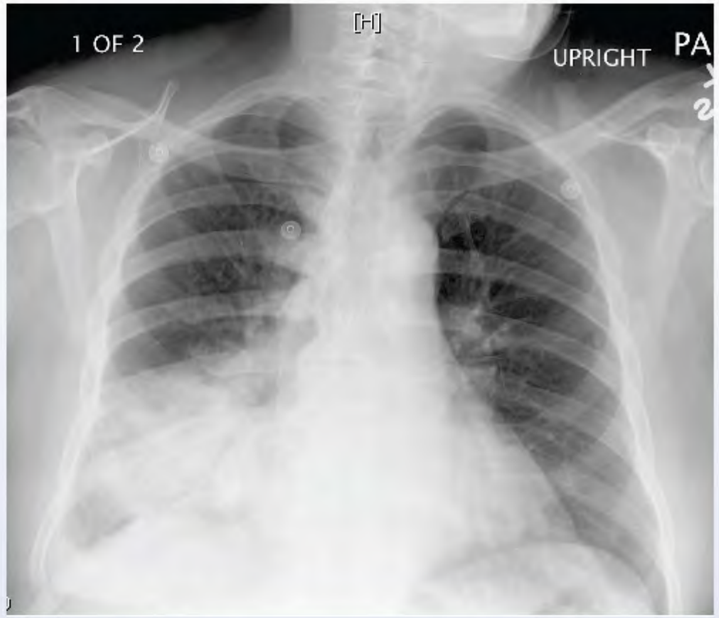

Which of the following is the most likely cause of the observed pulmonary findings in this patient?

- A. Elevated pulmonary capillary hydrostatic pressure (18%)
- ✗ B. Exaggerated reactivity and inflammation of the airways (9%)
- C. Excessive fibroblast proliferation and extracellular matrix deposition (8%)
- ✓ D. Leakage of protein-rich fluid in the alveolar airspaces (45%)
- E. Mucous gland hyperplasia and inflammation in the large airways (18%)

Incorrect
Correct answer
D

45%
Answered correctly

15 secs
Time Spent

2023
Version

https://t.me/USMLEWorldStep1

B. Exaggerated reactivity and inflammation of the airways (9%)

Exhibit Display

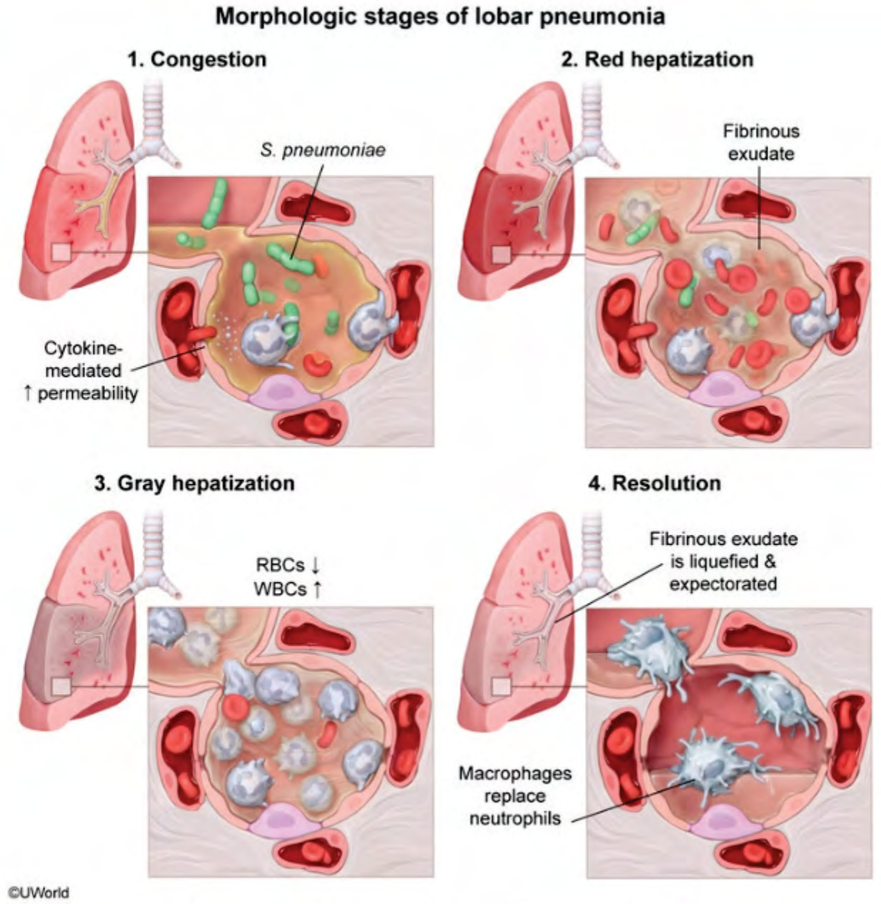

Zoom In | Zoom Out | Reset | New | Existing | My Notebook

https://t.me/USMLEWorldStep1

This patient has cough, shortness of breath, fever, and a right lower lobe infiltrate on chest x-ray, indicating **lobar pneumonia** likely due to a community-acquired pathogen (eg, *Streptococcus pneumoniae*). Lobar pneumonia is characterized by a step-wise inflammatory response, as follows:

1. **Congestion** (day 0-2) – Neutrophils respond to bacterial components (eg, peptidoglycan) by releasing cytokines that **increase the permeability** of the pulmonary capillary endothelium, which allows circulating immune cells to more easily migrate to the area. Increased capillary permeability also leads to the accumulation of erythrocytes and **abundant proteinaceous fluid** in the alveolar space, resulting in the affected lobe becoming heavy and red.
2. **Red hepatization** (day 2-4) – The proteinaceous fluid transforms into fibrin strands, resulting in a confluent exudate of fibrin, neutrophils, and erythrocytes. On gross examination, the lobe appears **liver-like**: Red, firm, and airless.
3. **Gray hepatization** (day 4-7) – Red cell disintegration along with increased leukocyte infiltration causes the lung to appear gray rather than red. Neutrophils begin to be replaced by **macrophages** that begin the repair process.
4. **Resolution** (>7 days) – Macrophages secrete digestive enzymes that liquefy the fibrinous exudate, which is reabsorbed, expectorated, or phagocytized by macrophages. The lung parenchyma regains its normal appearance by approximately 3 weeks.

Besides lobar pneumonia, there are 2 other major morphologic categories of pneumonia. **Bronchopneumonia** is an infection of the terminal bronchioles that results in patchy consolidation of a number of lobules. Interstitial pneumonia is an infection of the interstitial tissue of the lung with minimal or no alveolar infiltrate; atypical pneumonias (eg, *Mycoplasma pneumoniae*, *Chlamydia pneumoniae*) are often associated with an interstitial infiltrate.

(Choice A) Cardiogenic pulmonary edema is characterized by the accumulation of fluid in the alveoli due to elevations in hydrostatic pressure within the pulmonary capillaries. Examination often reveals bibasilar crackles and chest x-ray typically shows perihilar alveolar edema with cephalization of the pulmonary vessels.

(Choice B) Asthma is characterized by smooth muscle inflammation of the airways leading to intermittent

https://t.me/USMLEWorldStep1

reabsorbed, expectorated, or phagocytized by macrophages. The lung parenchyma regains its normal appearance by approximately 3 weeks.

Besides lobar pneumonia, there are 2 other major morphologic categories of pneumonia. **Bronchopneumonia** is an infection of the terminal bronchioles that results in patchy consolidation of a number of lobules. Interstitial pneumonia is an infection of the interstitial tissue of the lung with minimal or no alveolar infiltrate; atypical pneumonias (eg, *Mycoplasma pneumoniae*, *Chlamydia pneumoniae*) are often associated with an interstitial infiltrate.

(Choice A) Cardiogenic pulmonary edema is characterized by the accumulation of fluid in the alveoli due to elevations in hydrostatic pressure within the pulmonary capillaries. Examination often reveals bibasilar crackles and chest x-ray typically shows perihilar alveolar edema with cephalization of the pulmonary vessels.

(Choice B) Asthma is characterized by smooth muscle inflammation of the airways leading to intermittent bronchoconstriction and airflow obstruction. Although cough and shortness of breath can occur during asthma exacerbations, fever and a lobar infiltrate are not typical.

(Choice C) Idiopathic pulmonary fibrosis is associated with pulmonary fibroblast proliferation and extracellular matrix deposition leading to progressive destruction of the pulmonary architecture. Patients typically present with slowly worsening dyspnea, nonproductive cough, and bilateral "Velcro"-sounding crackles. Fever is uncommon and chest x-ray usually reveals increased reticular (interstitial) markings.

(Choice E) Chronic bronchitis is associated with goblet cell metaplasia and inflammation in the large airways. The hypersecretion of mucous can lead to chronic productive cough, dyspnea, and wheezes on examination. Lobar infiltrate is uncommon as the alveoli are not primarily affected.

Educational objective:
Lobar pneumonia is marked by the cytokine-mediated accumulation of neutrophils and proteinaceous material in the alveoli. Over several days, the proteinaceous material becomes fibrinous, neutrophils are replaced by macrophages, and macrophages digest the fibrinous exudate, thereby restoring normal lung histology.

References

- Pathophysiology of community acquired pneumonia.

https://t.me/USMLEWorldStep1

accumulation of erythrocytes and **abundant proteinaceous fluid** in the alveolar space, resulting in the affected lobe becoming heavy and red.

2. **R**
3. **G**
4. **R**

Beside
an infe
pneum
pneum
infiltrat

(Choi
elevati
and ch

(Choi
bronch
exacer

(Choi
matrix
slowly worsening dyspnea, nonproductive cough, and bilateral "velcro"-sounding crackles. Fever is uncommon and chest x-ray usually reveals increased reticular (interstitial) markings.

Exhibit Display

Zoom In | Zoom Out | Reset | New | Existing | My Notebook

https://t.me/USMLEWorldStep1

accumulation of erythrocytes and **abundant proteinaceous fluid** in the alveolar space, resulting in the affected lobe becoming heavy and red.

2. **R**
3. **G**
4. **R**

Beside
an infe
pneum
pneum
infiltrat

(Choi
elevati
and ch

(Choi
bronch
exacer

(Choi
matrix
slowly
and chest x-ray usually reveals increased reticular (interstitial) markings.

Exhibit Display

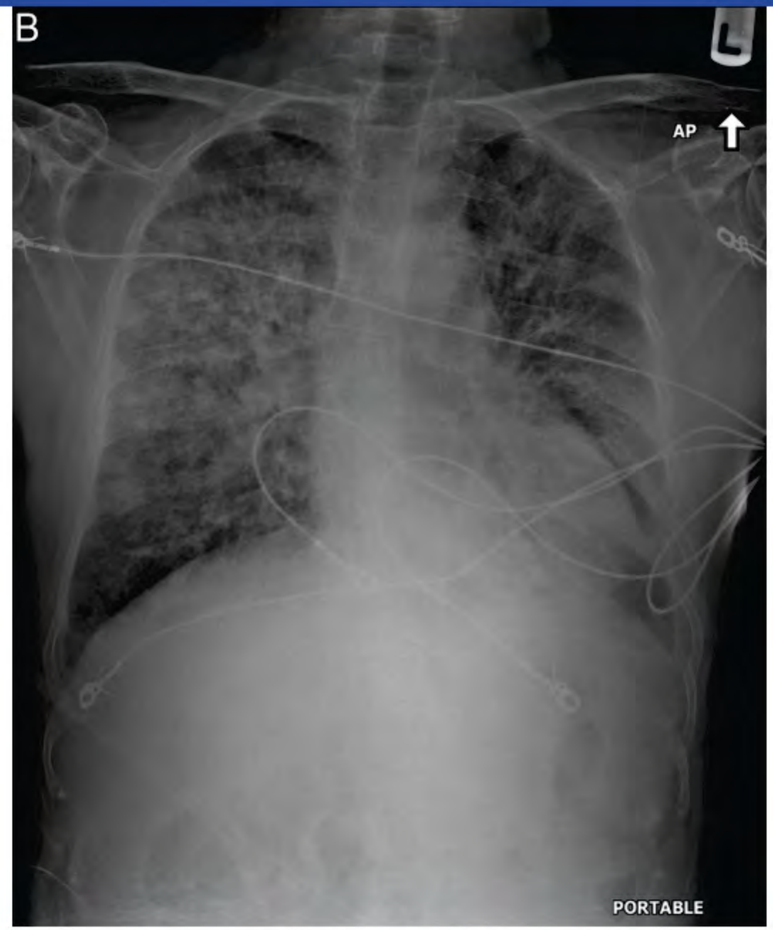

Zoom In | Zoom Out | Reset | New | Existing | My Notebook

https://t.me/USMLEWorldStep1

lung to appear gray rather than red. Neutrophils begin to be replaced by **macrophages** that begin the repair process.

Exhibit Display

Pulmonary fibrosis

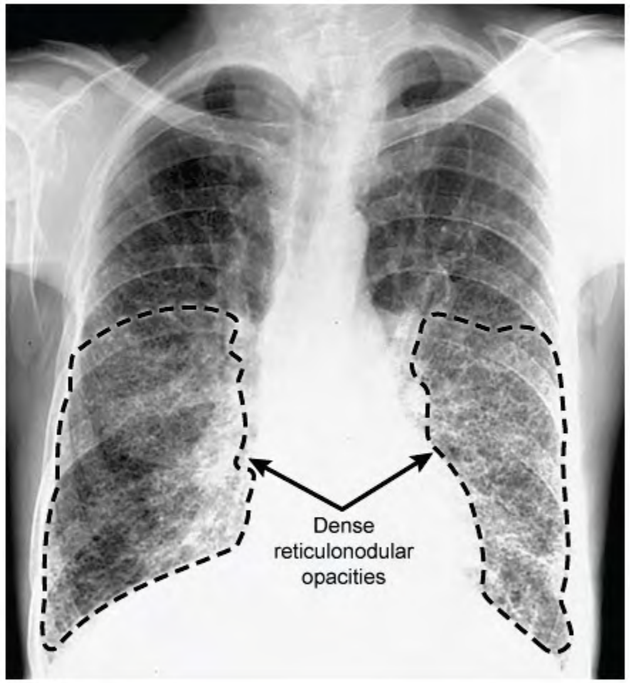

©UWorld

Zoom In | Zoom Out | Reset | New | Existing | My Notebook

4. R
re
a

Beside
an infe
pneum
pneum
infiltrat

(Choi
elevati
and ch

(Choi
bronch
exacer

(Choi
matrix
slowly
and ch

(Choi
hypers
infiltrat

Educa
Lobar
the alveoli. Over several days, the proteinaceous material becomes fibrinous, neutrophils are replaced by

https://t.me/USMLEWorldStep1

A 77-year-old man comes to the emergency department due to cough, shortness of breath, sharp chest pains, night sweats, and fatigue for 4 days. Temperature is 38.3 C (101 F), blood pressure is 110/62 mm Hg, pulse is 106/min, and respirations are 24/min. The patient appears ill. Neck veins are nondistended. There is decreased chest expansion on the right side. Auscultation reveals decreased breath sounds over the right lung base. Chest imaging shows a right lower lobe infiltrate and a small, free-flowing pleural effusion on the right side. Thoracentesis is performed. Laboratory results are as follows:

Pleural fluid analysis	
Leukocytes	620/mm^3
pH	normal
Glucose	normal
Pleural fluid/plasma lactate dehydrogenase ratio	0.7

Which of the following processes best explains this patient's pleural fluid findings?

- A. Elevated pulmonary capillary hydrostatic pressure
- B. Movement of sterile exudate into the pleural space
- C. Obstruction of lymphatic pleural fluid drainage
- D. Reduced pleural capillary oncotic pressure

Submit

https://t.me/USMLEWorldStep1

A 77-year-old man comes to the emergency department due to cough, shortness of breath, sharp chest pains, night sweats, and fatigue for 4 days. Temperature is 38.3 C (101 F), blood pressure is 110/62 mm Hg, pulse is 106/min, and respirations are 24/min. The patient appears ill. Neck veins are nondistended. There is decreased chest expansion on the right side. Auscultation reveals decreased breath sounds over the right lung base. Chest imaging shows a right lower lobe infiltrate and a small, free-flowing pleural effusion on the right side. Thoracentesis is performed. Laboratory results are as follows:

Pleural fluid analysis	
Leukocytes	620/mm^3
pH	normal
Glucose	normal
Pleural fluid/plasma lactate dehydrogenase ratio	0.7

Which of the following processes best explains this patient's pleural fluid findings?

- ✗ A. Elevated pulmonary capillary hydrostatic pressure (13%)
- ✓ B. Movement of sterile exudate into the pleural space (49%)
- C. Obstruction of lymphatic pleural fluid drainage (30%)
- D. Reduced pleural capillary oncotic pressure (6%)

Incorrect
Correct answer
B

49%
Answered correctly

03 secs
Time Spent

2023
Version

Explanation

Parapneumonic effusions

https://t.me/USMLEWorldStep1

Parapneumonic effusions		
	Uncomplicated	**Complicated***
Etiology	Sterile exudate in pleural space	Bacterial invasion of pleural space
Radiologic appearance	Small to moderate & free flowing	Moderate to large, free flowing or loculated
Pleural fluid characteristics	• pH ≥7.2 • Glucose ≥60 mg/dL • WBCs ≤50,000/mm^3	• pH <7.2 • Glucose <60 mg/dL • WBCs >50,000/mm^3
Treatment	Antibiotics	Antibiotics + drainage
*Empyema represents advanced progression of a complicated effusion. **WBC** = white blood cell.		

This patient's presentation with fever and several days of cough, shortness of breath, and sharp chest pain is consistent with **community-acquired pneumonia** (CAP). The right lower lobe infiltrate on chest x-ray supports the diagnosis of CAP and reveals an associated **parapneumonic effusion**, which develops in approximately 40% of bacterial pneumonia cases.

Parapneumonic effusions result from an inflammatory increase in vascular membrane permeability and therefore are **exudative** by Light criteria, which is confirmed by this patient's pleural fluid/serum lactate dehydrogenase ratio >0.6. Most parapneumonic effusions are **uncomplicated**, resulting from **movement of sterile exudate** into the pleural space and exhibiting **normal pH and glucose concentration** (near that of serum) as well as relatively **low leukocyte count** (eg, <50,000/mm^3) (as in this patient). Complicated parapneumonic effusions involve inflammatory disruption of the visceral pleura membrane with bacterial seeding of the pleural space. These effusions are recognized by low pH and glucose levels (due to bacteria metabolizing glucose and producing acidic wastes) and high leukocyte count.

https://t.me/USMLEWorldStep1

This patient's presentation with fever and several days of cough, shortness of breath, and sharp chest pain is consistent with **community-acquired pneumonia** (CAP). The right lower lobe infiltrate on chest x-ray supports the diagnosis of CAP and reveals an associated **parapneumonic effusion**, which develops in approximately 40% of bacterial pneumonia cases.

Parapneumonic effusions result from an inflammatory increase in vascular membrane permeability and therefore are **exudative** by Light criteria, which is confirmed by this patient's pleural fluid/serum lactate dehydrogenase ratio >0.6. Most parapneumonic effusions are **uncomplicated**, resulting from **movement of sterile exudate** into the pleural space and exhibiting **normal pH and glucose concentration** (near that of serum) as well as relatively **low leukocyte count** (eg, <50,000/mm^3) (as in this patient). Complicated parapneumonic effusions involve inflammatory disruption of the visceral pleura membrane with bacterial seeding of the pleural space. These effusions are recognized by low pH and glucose levels (due to bacteria metabolizing glucose and producing acidic wastes) and high leukocyte count.

(Choices A and D) Changes in hydrostatic or oncotic pressure drive the development of transudative (not exudative) pleural effusions. Elevated pulmonary capillary hydrostatic pressure is the cause of pleural effusion in decompensated heart failure, and reduced pleural capillary oncotic pressure contributes to pleural effusion in conditions that cause hypoalbuminemia (eg, malnutrition, nephrotic syndrome). The pleural fluid/serum lactate dehydrogenase ratio is <0.6 with transudative effusions.

(Choice C) Fluid drains from the pleural cavity via lymphatics on the parietal surface; therefore, lymphatic obstruction (eg, due to malignant spread within the pleural space) can cause a pleural effusion. These effusions are usually exudative by Light criteria due to malignancy-associated inflammation. However, this patient's clinical presentation is more consistent with CAP.

Educational objective:
Parapneumonic effusions are exudative by Light criteria and are classified into uncomplicated and complicated. Uncomplicated parapneumonic effusions result from movement of sterile exudate into the pleural space, whereas complicated parapneumonic effusions involve inflammatory disruption of the visceral pleural membrane with bacterial translocation into the pleural space.

References

https://t.me/USMLEWorldStep1

characteristics	• Glucose ≥60 mg/dL • WBCs <50 000/mm^3	• Glucose <60 mg/dL • WBCs >50 000/mm^3

Exhibit Display

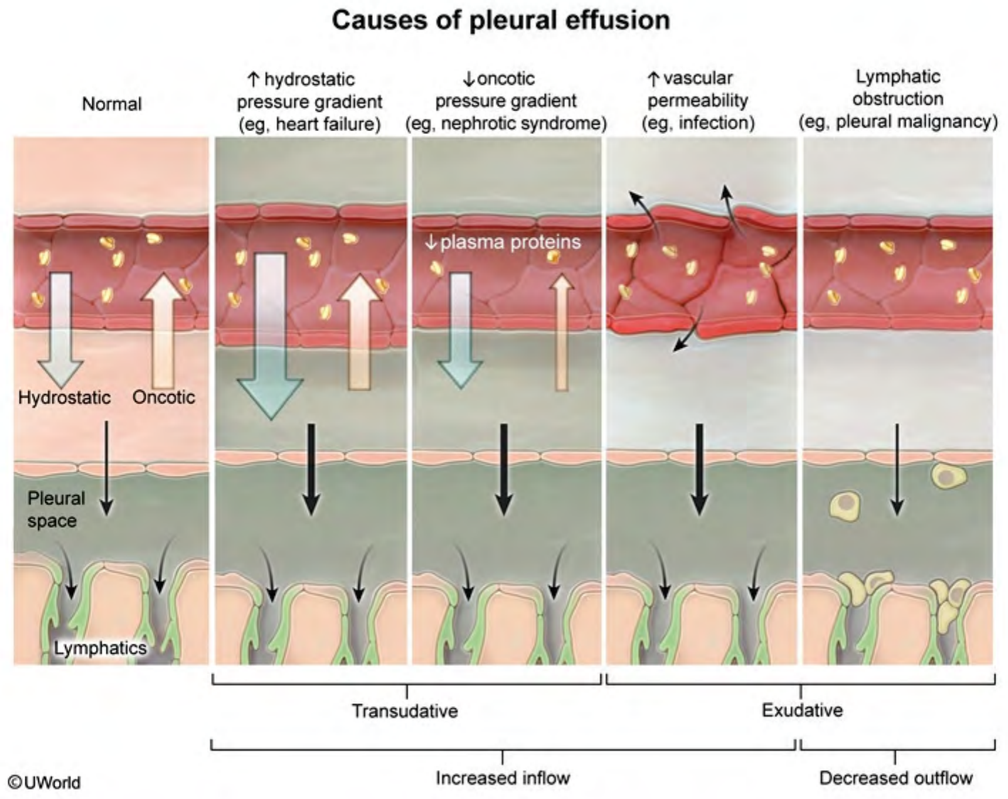

Zoom In | Zoom Out | Reset | New | Existing | My Notebook

This p
consis
the dia
of bac

Parap
are **ex**
>0.6.
pleura
leuko
inflam
effusic
waste

(Choi
exuda
decom
conditi
dehyd

(Choi
obstru

are usually exudative by Light criteria due to malignancy-associated inflammation. However, this patient's clinical presentation is more consistent with CAP.

https://t.me/USMLEWorldStep1

characteristics	• Glucose ≥60 mg/dL • WBCs <50 000/mm^3	• Glucose <60 mg/dL • WBCs >50 000/mm^3

Exhibit Display

Exudative & transudative pleural effusions

	Exudate	Transudate
Light criteria	Pleural protein/serum protein >0.5 **OR** Pleural LDH/serum LDH >0.6 **OR** Pleural LDH greater than two-thirds upper limit of normal of serum LDH	Exudate criteria not met
Pathophysiology	Inflammatory increase in membrane permeability	Change in hydrostatic or oncotic pressure
Common causes	• Infection (eg, pneumonia, TB) • Malignancy • Rheumatologic disease	• Heart failure • Cirrhosis (hepatic hydrothorax) • Nephrotic syndrome

LDH = lactate dehydrogenase; **TB** = tuberculosis.

New | Existing | My Notebook

This p
consis
the dia
of bac

Parap
are **ex**
>0.6.
pleura
leuko
inflam
effusic
waste

(Choi
exuda
decom
conditi
dehyd

(Choi
obstru

are usually exudative by Light criteria due to malignancy-associated inflammation. However, this patient's clinical presentation is more consistent with CAP.

https://t.me/USMLEWorldStep1

A 45-year-old hospitalized man is evaluated for shortness of breath and hypoxemia. The patient was admitted 3 days ago after a motor vehicle collision. At that time, evaluation revealed a femur fracture but no other injuries, and the patient underwent open reduction and internal fixation of the fracture. This morning, he suddenly began experiencing shortness of breath and sharp chest pain. The patient has no significant medical history and has been receiving morphine for pain control. He has smoked a pack of cigarettes daily for 15 years and drinks alcohol occasionally. Temperature is 36.1 C (97 F), blood pressure is 120/70 mm Hg, and pulse is 98/min. BMI is 42 kg/m^2. Chest x-ray is unremarkable, and arterial blood gas analysis on room air shows a pH of 7.51, $PaCO_2$ of 30 mm Hg, and PaO_2 of 65 mm Hg. Which of the following is the primary cause of hypoxemia in this patient?

- A. Alveolar hypoventilation
- B. Decreased blood oxygen-carrying capacity
- C. Increased tissue oxygen extraction
- D. Primary diffusion impairment
- E. Ventilation/perfusion mismatch

Submit

https://t.me/USMLEWorldStep1

A 45-year-old hospitalized man is evaluated for shortness of breath and hypoxemia. The patient was admitted 3 days ago after a motor vehicle collision. At that time, evaluation revealed a femur fracture but no other injuries, and the patient underwent open reduction and internal fixation of the fracture. This morning, he suddenly began experiencing shortness of breath and sharp chest pain. The patient has no significant medical history and has been receiving morphine for pain control. He has smoked a pack of cigarettes daily for 15 years and drinks alcohol occasionally. Temperature is 36.1 C (97 F), blood pressure is 120/70 mm Hg, and pulse is 98/min. BMI is 42 kg/m^2. Chest x-ray is unremarkable, and arterial blood gas analysis on room air shows a pH of 7.51, $PaCO_2$ of 30 mm Hg, and PaO_2 of 65 mm Hg. Which of the following is the primary cause of hypoxemia in this patient?

- A. Alveolar hypoventilation (6%)
- ✗ B. Decreased blood oxygen-carrying capacity (1%)
- C. Increased tissue oxygen extraction (1%)
- D. Primary diffusion impairment (5%)
- ✓ E. Ventilation/perfusion mismatch (85%)

Incorrect
Correct answer
E

85%
Answered correctly

04 secs
Time Spent

2023
Version

Explanation

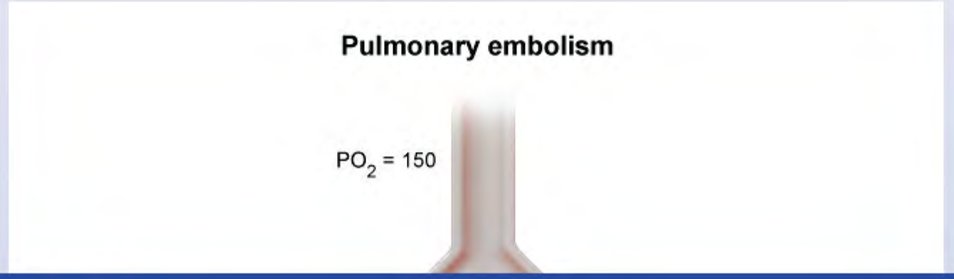

https://t.me/USMLEWorldStep1

Incorrect
Correct answer
E

85%
04 secs
2023

Exhibit Display

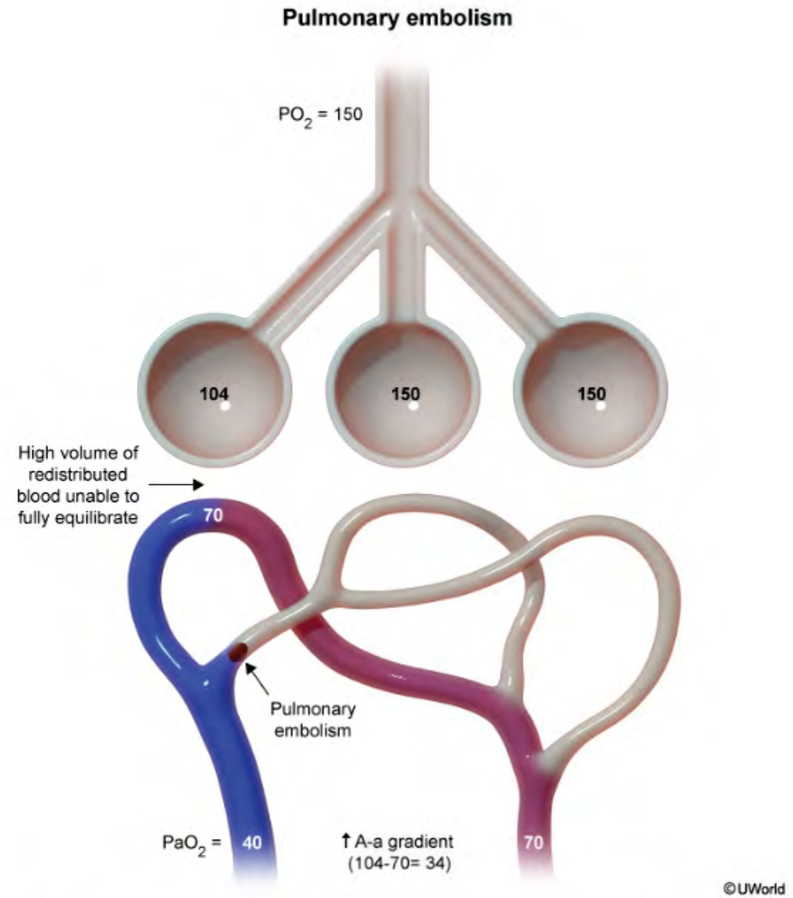

Zoom In | Zoom Out | Reset | New | Existing | My Notebook

https://t.me/USMLEWorldStep1

Sudden-onset shortness of breath and chest pain in a hospitalized patient should raise suspicion for **pulmonary embolism** (PE). This patient has 2 important risk factors for PE: **Immobilization** (causes venous stasis) and **recent surgery** (inflammation induces a hypercoagulable state). The risk of PE is high after large orthopedic procedures; prophylactic anticoagulation reduces but does not eliminate this risk. Thrombi most commonly originate in the deep veins of the pelvis and lower extremities before embolizing to the lungs. Although the risk of fat embolism is also increased following a long-bone fracture, this patient lacks the typical skin rash and neurologic findings (eg, confusion).

Thrombotic occlusion of the pulmonary circulation leads to redistribution of blood flow in the lungs, resulting in a **ventilation/perfusion (V/Q) mismatch**. With many well-ventilated alveoli now inaccessible to blood flow (dead-space ventilation), the remaining accessible alveoli are unable to fully oxygenate the volume of blood that continues to flow through the pulmonary circulation, and **hypoxemia** results. As with any V/Q mismatch that affects only part of the lungs, supplemental oxygen can help correct the hypoxemia by increasing the alveolar partial pressure of oxygen, allowing accessible alveoli to transfer additional oxygen to the blood.

(Choice A) Alveolar hypoventilation refers to a global decrease in the alveolar partial pressure of oxygen caused by a decrease in tidal volume or respiratory rate. Patients also develop respiratory acidosis due to decreased CO_2 excretion. This patient's respiratory alkalosis is more typical of V/Q mismatch with subsequent hyperventilation, as V/Q mismatch does not hinder CO_2 removal as much as blood oxygenation.

(Choice B) Decreased blood oxygen-carrying capacity (ie, decreased hemoglobin concentration) can occur due to postoperative bleeding. Although a decrease in hemoglobin can lead to tissue hypoxia, the measured PaO_2 (indicative of dissolved oxygen content rather than hemoglobin-bound oxygen content) will not be affected.

(Choice C) Increased tissue oxygen extraction would cause venous oxygen levels to decrease but would not typically affect the arterial oxygen content.

(Choice D) Hypoxemia due to a primary defect that impairs gas diffusion between the alveoli and pulmonary capillaries can occur in chronic lung diseases, including pulmonary fibrosis and emphysema.

Educational objective:
Pulmonary embolism is common in hospitalized and postoperative patients, and classically presents with sudden-

https://t.me/USMLEWorldStep1

procedures; prophylactic anticoagulation reduces but does not eliminate this risk. Thrombi most commonly originate in the deep veins of the pelvis and lower extremities before embolizing to the lungs. Although the risk of fat embolism is also increased following a long-bone fracture, this patient lacks the typical skin rash and neurologic findings (eg, confusion).

Thrombotic occlusion of the pulmonary circulation leads to redistribution of blood flow in the lungs, resulting in a **ventilation/perfusion (V/Q) mismatch**. With many well-ventilated alveoli now inaccessible to blood flow (dead-space ventilation), the remaining accessible alveoli are unable to fully oxygenate the volume of blood that continues to flow through the pulmonary circulation, and **hypoxemia** results. As with any V/Q mismatch that affects only part of the lungs, supplemental oxygen can help correct the hypoxemia by increasing the alveolar partial pressure of oxygen, allowing accessible alveoli to transfer additional oxygen to the blood.

(Choice A) Alveolar hypoventilation refers to a global decrease in the alveolar partial pressure of oxygen caused by a decrease in tidal volume or respiratory rate. Patients also develop respiratory acidosis due to decreased CO_2 excretion. This patient's respiratory alkalosis is more typical of V/Q mismatch with subsequent hyperventilation, as V/Q mismatch does not hinder CO_2 removal as much as blood oxygenation.

(Choice B) Decreased blood oxygen-carrying capacity (ie, decreased hemoglobin concentration) can occur due to postoperative bleeding. Although a decrease in hemoglobin can lead to tissue hypoxia, the measured PaO_2 (indicative of dissolved oxygen content rather than hemoglobin-bound oxygen content) will not be affected.

(Choice C) Increased tissue oxygen extraction would cause venous oxygen levels to decrease but would not typically affect the arterial oxygen content.

(Choice D) Hypoxemia due to a primary defect that impairs gas diffusion between the alveoli and pulmonary capillaries can occur in chronic lung diseases, including pulmonary fibrosis and emphysema.

Educational objective:
Pulmonary embolism is common in hospitalized and postoperative patients, and classically presents with sudden-onset shortness of breath and pleuritic chest pain. It causes hypoxemia due to ventilation/perfusion mismatch; arterial PCO_2 is usually normal or decreased.

Physiology Pulmonary & Critical Care Pulmonary embolism

https://t.me/USMLEWorldStep1

procedures; prophylactic anticoagulation reduces but does not eliminate this risk. Thrombi most commonly originate in the deep veins of the pelvis and lower extremities before embolizing to the lungs. Although the risk of fat em
finding

Throm
ventila
space
contin
affects
partial

(Choi
by a d
excret
V/Q m

(Choi
postop
(indica

(Choi
typical

(Choi
capilla

Educa
Pulmo
onset
arteria

Physiology Pulmonary & Critical Care Pulmonary embolism

Exhibit Display

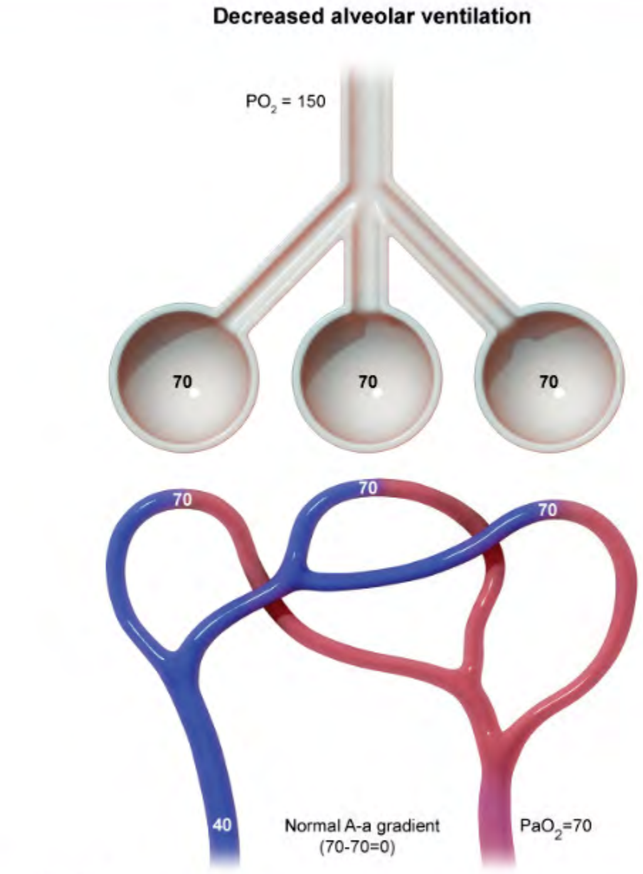

Zoom In Zoom Out Reset New | Existing My Notebook

https://t.me/USMLEWorldStep1

procedures; prophylactic anticoagulation reduces but does not eliminate this risk. Thrombi most commonly originate in the deep veins of the pelvis and lower extremities before embolizing to the lungs. Although the risk of fat em
finding

Throm
ventil
space
contin
affects
partial

(Choi
by a d
excret
V/Q m

(Choi
postop
(indica

(Choi
typical

(Choi
capilla

Educa
Pulmo
onset
arteria

Physiology Pulmonary & Critical Care Pulmonary embolism

Exhibit Display

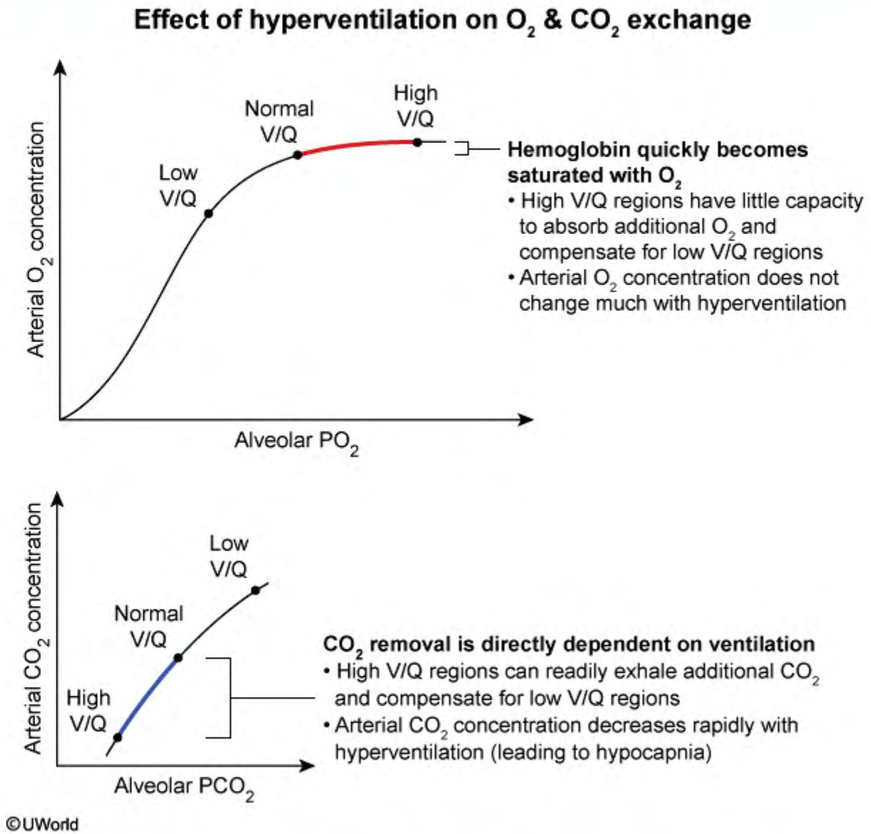

Zoom In Zoom Out Reset New | Existing My Notebook

https://t.me/USMLEWorldStep1

procedures; prophylactic anticoagulation reduces but does not eliminate this risk. Thrombi most commonly originate in the deep veins of the pelvis and lower extremities before embolizing to the lungs. Although the risk of fat em
finding

Throm
ventila
space
contin
affects
partial

(Choi
by a d
excret
V/Q m

(Choi
postop
(indica

(Choi
typical

(Choi
capilla

Educa
Pulmo
onset
arteria

Physiology Pulmonary & Critical Care Pulmonary embolism

Exhibit Display

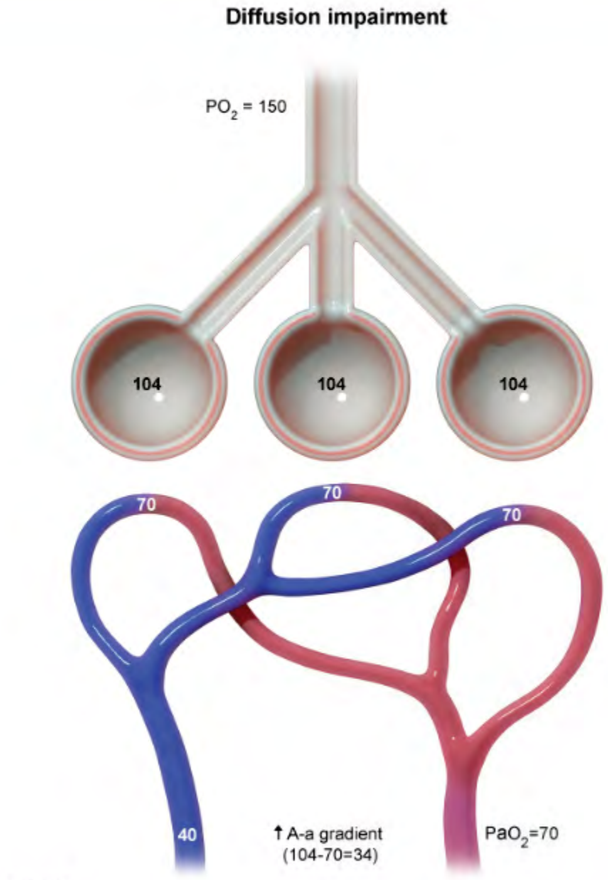

Zoom In Zoom Out Reset New | Existing My Notebook

https://t.me/USMLEWorldStep1

A 68-year-old woman comes to the emergency department due to cough and shortness of breath. She has a history of chronic obstructive pulmonary disease and often coughs up clear sputum in the morning. Over the past 4 days, the cough has worsened significantly, and the patient now is producing thick, greenish sputum. She also feels winded when walking short distances or doing light housework. She is a former smoker with a 40-pack-year history. Temperature is 37.2 C (99 F), blood pressure is 130/70 mm Hg, pulse is 90/min, and respirations are 22/min. The patient is breathing with pursed lips. The expiration phase is prolonged. Vesicular breath sounds with diffuse wheezes are heard on lung auscultation. Chest x-ray shows hyperinflated lungs with a flattened diaphragm. There are no alveolar opacities or pleural effusions. Respiratory viral panel results are negative. Infection with which of the following pathogens most likely triggered this patient's worsening symptoms?

- A. *Bordetella pertussis*
- B. *Haemophilus influenzae*
- C. *Klebsiella pneumoniae*
- D. *Legionella pneumophila*
- E. *Staphylococcus aureus*
- F. *Streptococcus pyogenes*

Submit

https://t.me/USMLEWorldStep1

A 68-year-old woman comes to the emergency department due to cough and shortness of breath. She has a history of chronic obstructive pulmonary disease and often coughs up clear sputum in the morning. Over the past 4 days, the cough has worsened significantly, and the patient now is producing thick, greenish sputum. She also feels winded when walking short distances or doing light housework. She is a former smoker with a 40-pack-year history. Temperature is 37.2 C (99 F), blood pressure is 130/70 mm Hg, pulse is 90/min, and respirations are 22/min. The patient is breathing with pursed lips. The expiration phase is prolonged. Vesicular breath sounds with diffuse wheezes are heard on lung auscultation. Chest x-ray shows hyperinflated lungs with a flattened diaphragm. There are no alveolar opacities or pleural effusions. Respiratory viral panel results are negative. Infection with which of the following pathogens most likely triggered this patient's worsening symptoms?

- ✗ A. *Bordetella pertussis* (5%)
- ✓ B. *Haemophilus influenzae* (35%)
- C. *Klebsiella pneumoniae* (17%)
- D. *Legionella pneumophila* (17%)
- E. *Staphylococcus aureus* (18%)
- F. *Streptococcus pyogenes* (6%)

Incorrect
Correct answer
B

35%
Answered correctly

03 secs
Time Spent

2023
Version

Explanation

Acute exacerbation of chronic obstructive pulmonary disease	
	• Infectious (70%) ◦ Viral: rhinovirus, influenza, RSV

https://t.me/USMLEWorldStep1

Acute exacerbation of chronic obstructive pulmonary disease	

Precipitants	• Infectious (70%)
	  ◦ Viral: rhinovirus, influenza, RSV
	  ◦ Bacterial: *Haemophilus influenzae* (nontypeable), *Moraxella catarrhalis*, *Streptococcus pneumoniae*
	• Noninfectious (30%)*

Pathophysiology & presentation	• Inflammation/infection mainly** contained within bronchi (vs alveoli) • ↓ Expiratory airflow, ↑ hyperinflation, ↑ V/Q mismatch (hypoxia, hypercapnia) • Cardinal symptoms: ↑ dyspnea, ↑ sputum volume &/or purulence
Management	• Maximize expiratory flow (inhaled bronchodilators) • Reduce airway inflammation (systemic glucocorticoids) • Treat potential underlying infection (± antibiotics &/or antivirals)
*For example, spontaneous sterile inflammation (underlying disease), pulmonary embolism, inhaled irritants. **In some cases, acute exacerbation of chronic obstructive pulmonary disease is precipitated by community-acquired pneumonia (alveolar opacities, fever, or leukocytosis). **RSV** = respiratory syncytial virus; **V/Q** = ventilation/perfusion.	

This patient with a history of chronic obstructive pulmonary disease (COPD) has increasing dyspnea and purulent sputum production consistent with an **acute exacerbation (AECOPD)**. Precipitants of AECOPD can be divided into infectious and noninfectious causes. Infectious etiologies account for roughly two-thirds of all cases of AECOPD:

- The 3 bacteria most commonly isolated during AECOPD are **nontypeable *Haemophilus influenzae***, *Moraxella catarrhalis*, and *Streptococcus pneumoniae*.
- The 3 most common viral triggers of AECOPD are human rhinovirus, influenza, and respiratory syncytial virus.

https://t.me/USMLEWorldStep1

This patient with a history of chronic obstructive pulmonary disease (COPD) has increasing dyspnea and purulent sputum production consistent with an **acute exacerbation (AECOPD)**. Precipitants of AECOPD can be divided into infectious and noninfectious causes. Infectious etiologies account for roughly two-thirds of all cases of AECOPD:

- The 3 bacteria most commonly isolated during AECOPD are **nontypeable *Haemophilus influenzae***, *Moraxella catarrhalis*, and *Streptococcus pneumoniae*.
- The 3 most common viral triggers of AECOPD are human rhinovirus, influenza, and respiratory syncytial virus.

Infection results in direct damage to respiratory ciliated epithelium, cytokine-mediated airway inflammation, and mucus hypersecretion, all of which worsen the baseline symptoms of COPD. The presence of purulent (eg, greenish, malodorous) sputum merely denotes the influx of activated neutrophils (myeloperoxidase produces the green hue) and does not reliably distinguish between viral or bacterial infection.

(Choice A) *Bordetella pertussis* causes whooping cough, which is characterized by extremely severe, paroxysmal, nonproductive cough. Although vaccinated adults can have an attenuated form of pertussis, it preferentially affects the trachea (rather than the lower bronchi) and is therefore a rare cause of AECOPD.

(Choices C and D) *Klebsiella pneumoniae* and *Legionella pneumophila* are important causes of nosocomial (health care–associated) pneumonia but can also cause community-acquired pneumonia in susceptible individuals (eg, alcohol use disorder, immunosuppression). In both cases, alveolar opacification would be expected on chest x-ray. *Klebsiella* pneumonia is characterized by hemorrhagic lung necrosis (currant-jelly sputum) and early abscess formation. *Legionella* pneumonia is characterized by pulmonary symptoms and a febrile gastroenteritis.

(Choice E) *Staphylococcus aureus* is a common cause of postviral (eg, postinfluenza) pneumonia but a very uncommon cause of AECOPD. It presents with alveolar opacification on x-ray accompanied by a severe systemic inflammatory response (fever, leukocytosis, hypotension). Overgrowth of *S aureus* within the airways of patients with cystic fibrosis can induce acute exacerbations of bronchiectasis.

(Choice F) *Streptococcus pyogenes* is a common cause of acute bacterial pharyngitis (strep throat) but does not usually affect the airways to cause a COPD exacerbation.

https://t.me/USMLEWorldStep1

- The 3 bacteria most commonly isolated during AECOPD are **nontypeable *Haemophilus influenzae***, *Moraxella catarrhalis*, and *Streptococcus pneumoniae*.
- The 3 most common viral triggers of AECOPD are human rhinovirus, influenza, and respiratory syncytial virus.

Infection results in direct damage to respiratory ciliated epithelium, cytokine-mediated airway inflammation, and mucus hypersecretion, all of which worsen the baseline symptoms of COPD. The presence of purulent (eg, greenish, malodorous) sputum merely denotes the influx of activated neutrophils (myeloperoxidase produces the green hue) and does not reliably distinguish between viral or bacterial infection.

(Choice A) *Bordetella pertussis* causes whooping cough, which is characterized by extremely severe, paroxysmal, nonproductive cough. Although vaccinated adults can have an attenuated form of pertussis, it preferentially affects the trachea (rather than the lower bronchi) and is therefore a rare cause of AECOPD.

(Choices C and D) *Klebsiella pneumoniae* and *Legionella pneumophila* are important causes of nosocomial (health care–associated) pneumonia but can also cause community-acquired pneumonia in susceptible individuals (eg, alcohol use disorder, immunosuppression). In both cases, alveolar opacification would be expected on chest x-ray. *Klebsiella* pneumonia is characterized by hemorrhagic lung necrosis (currant-jelly sputum) and early abscess formation. *Legionella* pneumonia is characterized by pulmonary symptoms and a febrile gastroenteritis.

(Choice E) *Staphylococcus aureus* is a common cause of postviral (eg, postinfluenza) pneumonia but a very uncommon cause of AECOPD. It presents with alveolar opacification on x-ray accompanied by a severe systemic inflammatory response (fever, leukocytosis, hypotension). Overgrowth of *S aureus* within the airways of patients with cystic fibrosis can induce acute exacerbations of bronchiectasis.

(Choice F) *Streptococcus pyogenes* is a common cause of acute bacterial pharyngitis (strep throat) but does not usually affect the airways to cause a COPD exacerbation.

Educational objective:
Viral and bacterial respiratory infections are the leading cause of acute exacerbations of chronic obstructive pulmonary disease. The most common bacterial pathogens include nontypeable *Haemophilus influenzae*, *Streptococcus pneumoniae*, and *Moraxella catarrhalis*.

https://t.me/USMLEWorldStep1

A 56-year-old man comes to the office after 2 episodes of low-volume hemoptysis. He describes the episodes as "streaks of blood" in his sputum. The patient has had a chronic cough over the last several years, most prominently in the morning. He has also had several recent respiratory infections. The patient has smoked a pack of cigarettes daily for the last 40 years. Chest x-ray shows hyperinflated lungs but no infiltrates or masses. Bronchoscopy is performed and several suspicious foci of bronchial mucosa are biopsied. Microscopic examination of the bronchial mucosa reveals patches of stratified squamous epithelium. The development of this patient's mucosal lesions most closely resembles which of the following disease processes?

- A. Barrett esophagus
- B. Cervical cancer
- C. Hypertrophic cardiomyopathy
- D. Interstitial cystitis
- E. Minimal change disease

Submit

https://t.me/USMLEWorldStep1

A 56-year-old man comes to the office after 2 episodes of low-volume hemoptysis. He describes the episodes as "streaks of blood" in his sputum. The patient has had a chronic cough over the last several years, most prominently in the morning. He has also had several recent respiratory infections. The patient has smoked a pack of cigarettes daily for the last 40 years. Chest x-ray shows hyperinflated lungs but no infiltrates or masses. Bronchoscopy is performed and several suspicious foci of bronchial mucosa are biopsied. Microscopic examination of the bronchial mucosa reveals patches of stratified squamous epithelium. The development of this patient's mucosal lesions most closely resembles which of the following disease processes?

- ✓ A. Barrett esophagus (72%)
- B. Cervical cancer (21%)
- C. Hypertrophic cardiomyopathy (1%)
- D. Interstitial cystitis (3%)
- E. Minimal change disease (1%)

Correct

72% Answered correctly

03 secs Time Spent

2023 Version

Explanation

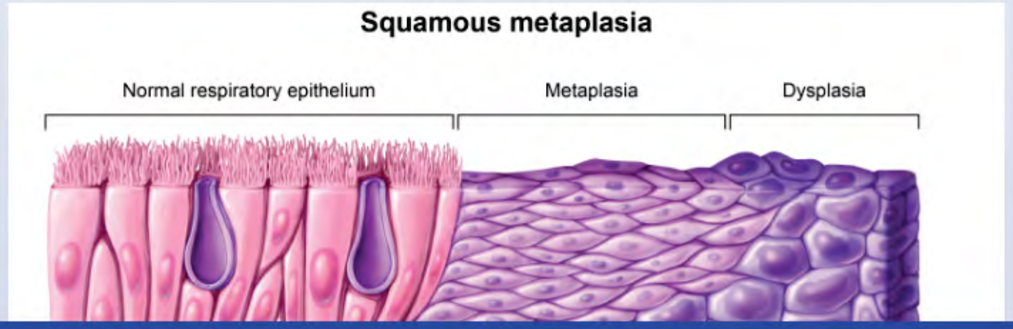

https://t.me/USMLEWorldStep1

Exhibit Display

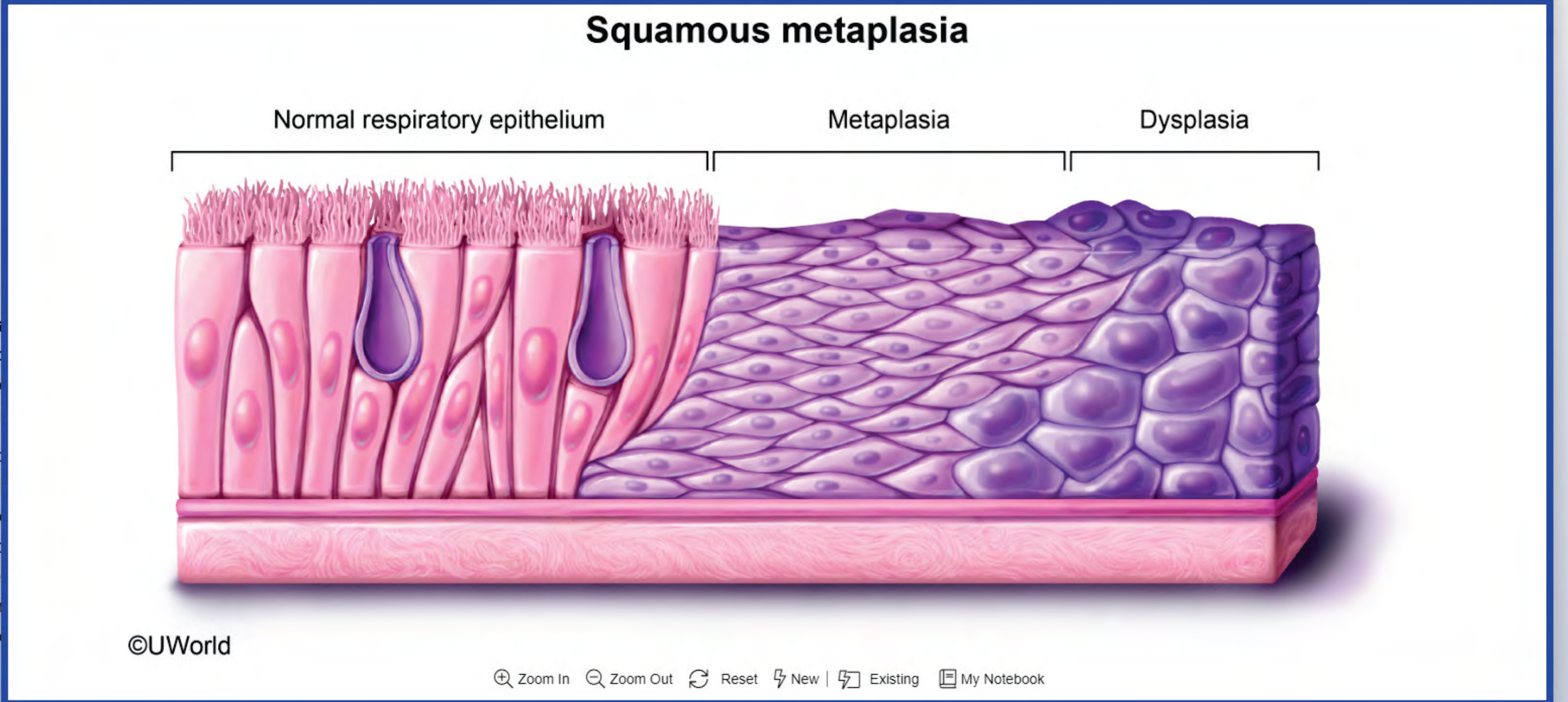

Norma
the orc
inhale
cleara

In resp
epithe
stratifi
irritatic
and in
discon
carcin

Other
by inte
of the cervix.

(Choice B) Cervical squamous cell carcinoma (CSCC) is almost always caused by oncogenic strains of human

https://t.me/USMLEWorldStep1

Normal bronchi are lined mainly by **pseudostratified ciliated columnar cells** that propel inhaled particles toward the oropharynx for removal by swallowing or expectoration. Interspersed goblet cells produce mucus that traps inhaled debris. The ciliated and goblet cells of respiratory epithelium are together responsible for mucociliary clearance.

In response to **chronic irritation**, such as **smoking**, the respiratory epithelium may be replaced with squamous epithelium. This change of cell types is called **squamous metaplasia** and is seen histologically as a transition to stratified polygonal epithelial cells. This transition is initially adaptive because squamous cells are more resistant to irritation than columnar cells. However, the lack of cilia and goblet cells prevents effective mucociliary clearance and increases the risk of respiratory infections. Squamous bronchial metaplasia is reversible and may resolve on discontinuation of smoking, but persistent irritant exposure can cause progression to dysplasia or squamous cell carcinoma.

Other examples of metaplasia include Barrett esophagus, in which esophageal squamous epithelium is replaced by intestinal columnar epithelium with goblet cells in response to chronic acid exposure, and squamous metaplasia of the cervix.

(Choice B) Cervical squamous cell carcinoma (CSCC) is almost always caused by oncogenic strains of human papillomavirus (HPV) that integrate into the host cell genome. Although HPV infects the metaplastic epithelium at the cervical transformation zone, development of CSCC is primarily driven by the expression of viral genes that inactivate host tumor-suppressor proteins.

(Choice C) Hypertrophic cardiomyopathy is an autosomal dominant disease caused by defects in the contractile proteins of the cardiac sarcomere. These abnormalities lead to disordered myocardial fibers, left ventricular outflow obstruction, arrhythmia, and increased risk of sudden death.

(Choice D) Interstitial cystitis is characterized by urinary frequency and urgency, and pelvic pain. Gross findings include erythema and ulceration of the bladder mucosa. Histopathology shows inflammatory infiltrates and fibrosis.

(Choice E) Minimal change disease is associated with effacement of the processes of glomerular podocytes and is visible only on electron microscopy. The underlying cell type is not altered.

Educational objective:

https://t.me/USMLEWorldStep1

stratified polygonal epithelial cells. This transition is initially adaptive because squamous cells are more resistant to irritation than columnar cells. However, the lack of cilia and goblet cells prevents effective mucociliary clearance and increases the risk of respiratory infections. Squamous bronchial metaplasia is reversible and may resolve on discontinuation of smoking, but persistent irritant exposure can cause progression to dysplasia or squamous cell carcinoma.

Other examples of metaplasia include Barrett esophagus, in which esophageal squamous epithelium is replaced by intestinal columnar epithelium with goblet cells in response to chronic acid exposure, and squamous metaplasia of the cervix.

(Choice B) Cervical squamous cell carcinoma (CSCC) is almost always caused by oncogenic strains of human papillomavirus (HPV) that integrate into the host cell genome. Although HPV infects the metaplastic epithelium at the cervical transformation zone, development of CSCC is primarily driven by the expression of viral genes that inactivate host tumor-suppressor proteins.

(Choice C) Hypertrophic cardiomyopathy is an autosomal dominant disease caused by defects in the contractile proteins of the cardiac sarcomere. These abnormalities lead to disordered myocardial fibers, left ventricular outflow obstruction, arrhythmia, and increased risk of sudden death.

(Choice D) Interstitial cystitis is characterized by urinary frequency and urgency, and pelvic pain. Gross findings include erythema and ulceration of the bladder mucosa. Histopathology shows inflammatory infiltrates and fibrosis.

(Choice E) Minimal change disease is associated with effacement of the processes of glomerular podocytes and is visible only on electron microscopy. The underlying cell type is not altered.

Educational objective:
Squamous bronchial metaplasia is a reversible, adaptive response to chronic irritation, such as smoking. The normal columnar epithelium is replaced by squamous epithelium, which is more resistant to irritation but has reduced mucociliary clearance. Metaplasia also occurs with Barrett esophagus, in which esophageal squamous epithelium is replaced by intestinal columnar epithelium with goblet cells in response to chronic acid exposure.

Pathology	Pulmonary & Critical Care	Barretts esophagus
Subject	System	Topic

https://t.me/USMLEWorldStep1

Exhibit Display

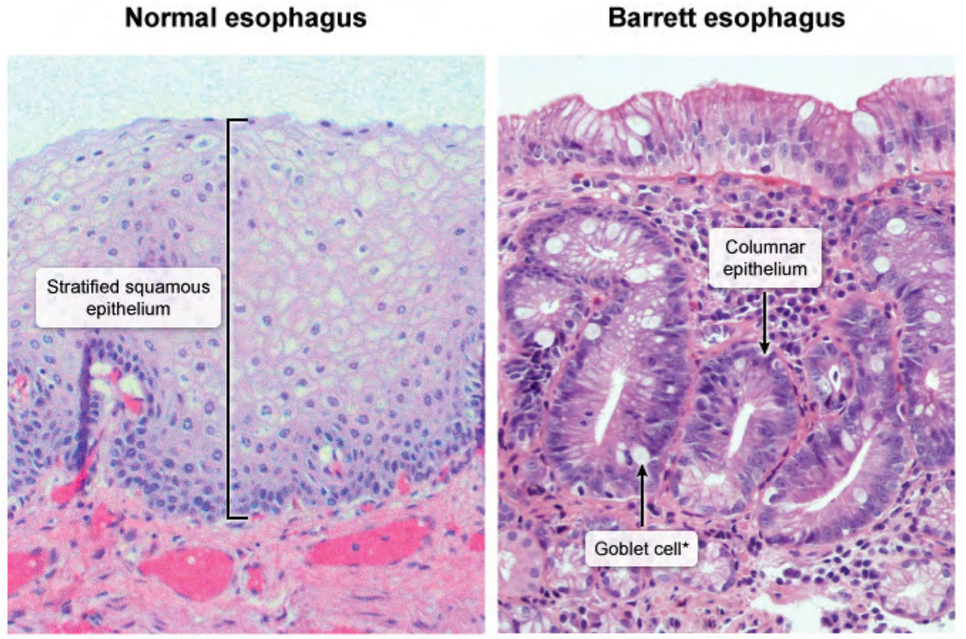

*Intestinal metaplasia: normal squamous epithelium replaced by columnar epithelium with goblet cells. ©UWorld

Zoom In Zoom Out Reset New | Existing My Notebook

Norma
the orc
inhale
cleara

In resp
epithe
stratifi
irritatic
and in
discon
carcin

Other
by inte
of the

(Choic
papillo
the ce
inactiv

(Choic
protein
outflow obstruction, arrhythmia, and increased risk of sudden death.

(Choice D) Interstitial cystitis is characterized by urinary frequency and urgency, and pelvic pain. Gross findings

https://t.me/USMLEWorldStep1

A 45-year-old man is evaluated for persistent cough and progressive dyspnea on exertion. The patient has no medical issues but has been exposed to large quantities of coal dust while working as a miner for the past 15 years. Chest imaging reveals small, nodular opacities in the upper lobes. Lung biopsy shows fine carbon particles within the patient's respiratory bronchioles and alveolar ducts. Which of the following mechanisms is most directly responsible for clearing the foreign particles from this patient's respiratory tract?

- A. Coughing and sneezing
- B. Immunologic memory
- C. Mucociliary transport
- D. Phagocytosis
- E. Upper airway trapping

Submit

https://t.me/USMLEWorldStep1
Show all

A 45-year-old man is evaluated for persistent cough and progressive dyspnea on exertion. The patient has no medical issues but has been exposed to large quantities of coal dust while working as a miner for the past 15 years. Chest imaging reveals small, nodular opacities in the upper lobes. Lung biopsy shows fine carbon particles within the patient's respiratory bronchioles and alveolar ducts. Which of the following mechanisms is most directly responsible for clearing the foreign particles from this patient's respiratory tract?

- A. Coughing and sneezing (3%)
- B. Immunologic memory (0%)
- ✗ C. Mucociliary transport (36%)
- ✓ D. Phagocytosis (58%)
- E. Upper airway trapping (1%)

Incorrect
Correct answer
D

58%
Answered correctly

03 secs
Time Spent

2023
Version

Explanation

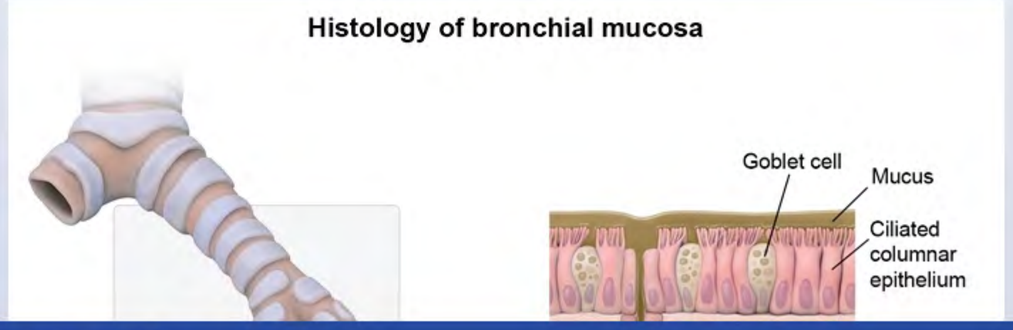

https://t.me/USMLEWorldStep1
Show all

Incorrect
Correct answer
D

58%
03 secs
2023

Expl

Exhibit Display

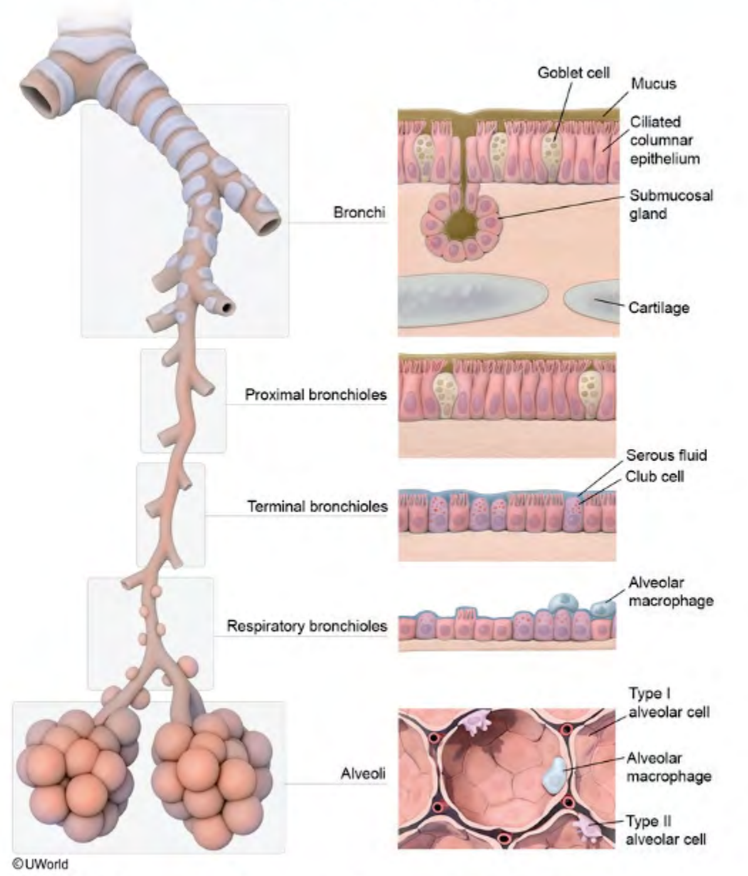

Zoom In | Zoom Out | Reset | New | Existing | My Notebook

https://t.me/USMLEWorldStep1

Show all

This patient has **coal worker pneumoconiosis**, a form of interstitial lung fibrosis secondary to long-term inhalation of coal particles.

Inorganic dust is constantly being inhaled and must be cleared by the respiratory tract to prevent disease. The clearance mechanisms used by the lungs vary depending on the size of the particles. Larger particles become trapped by mucus secretions in the trachea, bronchi, and proximal bronchioles; these trapped particles are swept upward toward the pharynx by the collective beating of ciliated cells. The **finest particles** (<2 μm) can travel past the highly ciliated airways into the **respiratory bronchioles and alveoli**, where they are phagocytized by **alveolar macrophages**.

Engulfment of inorganic dust causes **macrophage activation** and the release of a number of cytokines that induce pulmonary inflammation. Growth factors, including platelet-derived growth factor and insulin-like growth factor, are also released and stimulate fibroblasts to proliferate and produce collagen. This production results in **progressive interstitial lung fibrosis** that characterizes the pneumoconioses.

(Choices A and E) The largest dust particles become trapped in the upper airways (eg, nasal passages, pharynx) and are cleared through coughing and sneezing.

(Choice B) Immunologic memory can help with the clearance of previously encountered microorganisms but would not contribute to the removal of inorganic dust particles.

(Choice C) Mucociliary transport is the primary means of eliminating particles that lodge in the bronchi and bronchioles (typically, medium-sized particles).

Educational objective:
The pneumoconioses are diseases resulting from the inhalation of fine dust particles that reach the respiratory bronchioles and alveoli. Particles that lodge in this region are normally cleared by alveolar macrophages. High particulate burden can cause the excessive release of cytokines from macrophages, resulting in progressive pulmonary fibrosis.

https://t.me/USMLEWorldStep1
Show all

A 43-year-old man is brought to the emergency department after being found unresponsive by his wife. She says he was in his usual state of health when she left home a few hours ago. The patient has a history of depression and type 2 diabetes mellitus. He was recently laid off from work. Blood pressure is 100/60 mm Hg and pulse is 64/min. On physical examination, the patient is responsive to deep sternal rub and has mildly dry mucous membranes. Arterial blood gas analysis reveals the following:

pH	7.22
$PaCO_2$	60 mm Hg
HCO_3^-	24 mEq/L

Which of the following is the most likely current acid-base status in this patient?

- A. Metabolic acidosis with respiratory compensation
- B. Metabolic alkalosis with respiratory compensation
- C. Respiratory acidosis with renal compensation
- D. Respiratory alkalosis with renal compensation
- E. Uncompensated metabolic acidosis
- F. Uncompensated respiratory acidosis

Submit

https://t.me/USMLEWorldStep1
Show all

A 43-year-old man is brought to the emergency department after being found unresponsive by his wife. She says he was in his usual state of health when she left home a few hours ago. The patient has a history of depression and type 2 diabetes mellitus. He was recently laid off from work. Blood pressure is 100/60 mm Hg and pulse is 64/min. On physical examination, the patient is responsive to deep sternal rub and has mildly dry mucous membranes. Arterial blood gas analysis reveals the following:

pH	7.22
$PaCO_2$	60 mm Hg
HCO_3^-	24 mEq/L

Which of the following is the most likely current acid-base status in this patient?

- ✗ A. Metabolic acidosis with respiratory compensation (3%)
- B. Metabolic alkalosis with respiratory compensation (0%)
- C. Respiratory acidosis with renal compensation (8%)
- D. Respiratory alkalosis with renal compensation (0%)
- E. Uncompensated metabolic acidosis (4%)
- ✓ F. Uncompensated respiratory acidosis (82%)

Incorrect
Correct answer
F

82%
Answered correctly

03 secs
Time Spent

2023
Version

Explanation

https://t.me/USMLEWorldStep1
Show all

Incorrect
Corre
F

Expl

Exhibit Display

Arterial blood gas interpretation of acid-base disorders

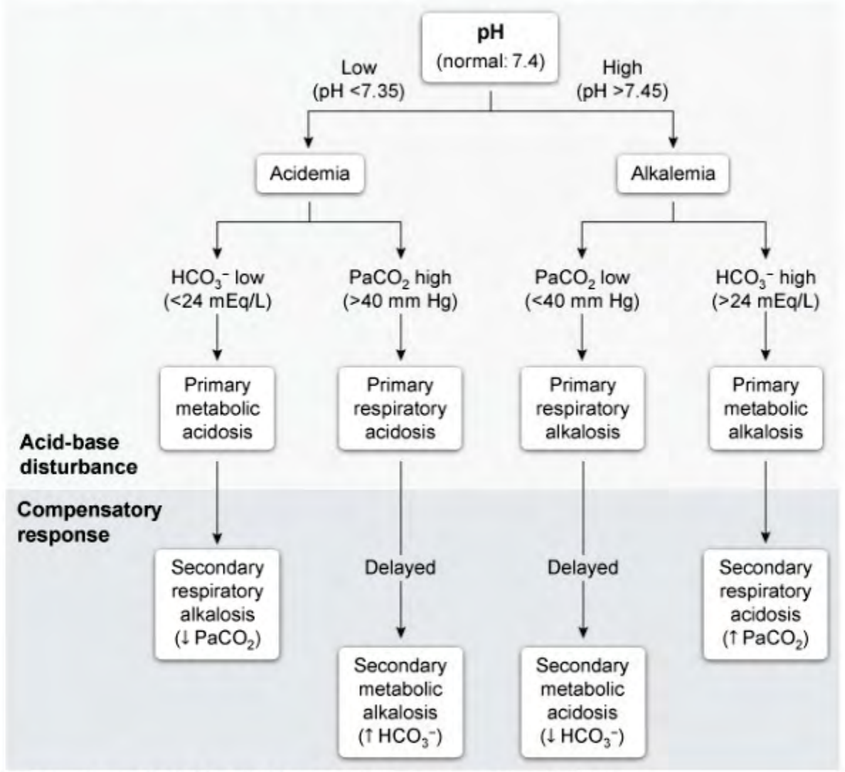

* The normal ranges for $PaCO_2$ and HCO_3^- vary slightly around 40 mm Hg and 24 mEq/L.
For simplicity, these numbers should be used as a normal baseline for acid-base calculations.

HCO_3^- = bicarbonate; **$PaCO_2$** = partial pressure of carbon dioxide in arterial blood.

©UWorld

Zoom In | Zoom Out | Reset | New | Existing | My Notebook

https://t.me/USMLEWorldStep1

Show all

HCO_3^- = bicarbonate; $PaCO_2$ = partial pressure of carbon dioxide in arterial blood.

©UWorld

The assessment of an arterial blood gas follows a stepwise process:

1. Evaluate the **pH** (normal: 7.4): A value <7.35 signifies acidosis whereas a value >7.45 indicates alkalosis. This patient has an arterial blood pH of 7.22, which is consistent with **acidosis**.
2. Identify the **primary process**: Differentiate respiratory from metabolic processes by determining the $PaCO_2$ (normal: 40) and HCO_3^- (normal: 24).
   - Respiratory acidosis occurs due to the retention of CO_2 in the lungs and presents with a low pH and a high $PaCO_2$.
   - Metabolic acidosis develops due to depletion of HCO_3^- and is characterized by a low pH and a low HCO_3^-.

   This patient has a pH of 7.22 (low) and a $PaCO_2$ of 60 mm Hg (high), which is consistent with **respiratory acidosis**.
3. Identify compensation: Because increased $PaCO_2$ leads to an increased hydrogen ion concentration in the body, the kidneys begin to compensate by increasing resorption of HCO_3^- to help buffer the excess acid. The **renal compensation** begins after several hours and takes several days to complete. After approximately 72 hours, the expected compensatory increase in HCO_3^- is approximately 4 mEq/L for every 10 mm Hg elevation in $PaCO_2$.

This patient has a HCO_3^- of 24 mEq/L, which is normal and indicates **respiratory acidosis without compensation**. Causes of respiratory acidosis without compensation include any disorder that causes **acute hypoventilation** (eg, opioid overdose with depression of respiratory drive).

(Choices A and E) Metabolic acidosis is indicated by low pH and low serum HCO_3^-. The respiratory compensation involves hyperventilation to breathe off CO_2 and help increase pH. Respiratory compensation for metabolic disturbances begins right away and is usually maximized within hours; therefore, full (or nearly full)

https://t.me/USMLEWorldStep1
Show all

This patient has a pH of 7.22 (low) and a $PaCO_2$ of 60 mm Hg (high), which is consistent with **respiratory acidosis**.

3. Identify compensation: Because increased $PaCO_2$ leads to an increased hydrogen ion concentration in the body, the kidneys begin to compensate by increasing resorption of HCO_3^- to help buffer the excess acid. The **renal compensation** begins after several hours and takes several days to complete. After approximately 72 hours, the expected compensatory increase in HCO_3^- is approximately 4 mEq/L for every 10 mm Hg elevation in $PaCO_2$.

This patient has a HCO_3^- of 24 mEq/L, which is normal and indicates **respiratory acidosis without compensation**. Causes of respiratory acidosis without compensation include any disorder that causes **acute hypoventilation** (eg, opioid overdose with depression of respiratory drive).

(Choices A and E) Metabolic acidosis is indicated by low pH and low serum HCO_3^-. The respiratory compensation involves hyperventilation to breathe off CO_2 and help increase pH. Respiratory compensation for metabolic disturbances begins right away and is usually maximized within hours; therefore, full (or nearly full) compensation is expected in both the acute and chronic setting unless the patient's breathing is compromised.

(Choice B) Metabolic alkalosis is indicated by high pH and high HCO_3^-. The respiratory compensation involves hypoventilation to retain CO_2 and decrease pH.

(Choice C) This patient's low pH and high $PaCO_2$ are consistent with respiratory acidosis, but the normal HCO_3^- indicates that renal compensation has not yet occurred.

(Choice D) Respiratory alkalosis is indicated by high pH and low $PaCO_2$. The metabolic compensation involves increased HCO_3^- excretion by the kidneys to help decrease pH and requires approximately 72 hours to complete.

Educational objective:
Respiratory acidosis presents with low pH and high $PaCO_2$. HCO_3^- initially remains near normal but becomes elevated over several days as renal compensation develops.

https://t.me/USMLEWorldStep1
Show all

2. Identify the **primary process**. Differentiate respiratory from metabolic processes by determining the $PaCO_2$ (normal: 40) and HCO_3^- (normal: 24).

Exhibit Display

Appropriate compensatory $PaCO_2$ or HCO_3^- changes in acid-base disorders	
Metabolic acidosis (acute or chronic)	Expected $PaCO_2 = (1.5 \times HCO_3^-) + 8 \pm 2$ (Winters formula)
Metabolic alkalosis (acute or chronic)	~7 mm Hg ↑ in $PaCO_2$ per 10 mEq/L ↑ in HCO_3^-
Respiratory acidosis (chronic only*)	~4 mEq/L ↑ in HCO_3^- per 10 mm Hg ↑ in $PaCO_2$
Respiratory alkalosis (chronic only*)	~4 mEq/L ↓ in HCO_3^- per 10 mm Hg ↓ in $PaCO_2$
*Compensation for respiratory disturbances is minimal in the acute setting. The full level of chronic compensation is achieved after ~72 hr. For simplicity, normal baseline $PaCO_2$ & HCO_3^- should be considered 40 mm Hg & 24 mEq/L, respectively.	

New | Existing | My Notebook

T
a
3. Ic
b
re
h
in

This p
comp
hypov

(Choic
compe
metab
compe

(Choic
hypov

(Choice C) This patient's low pH and high $PaCO_2$ are consistent with respiratory acidosis, but the normal HCO_3^-

https://t.me/USMLEWorldStep1
Show all

A 63-year-old man comes to the emergency department due to fever and cough. A medical student interviews and examines the patient and notes that he has had 3 months of fevers, night sweats, and productive cough. Chest x-ray reveals a right apical lung lesion, and the patient is subsequently placed in respiratory isolation. The medical student was in close contact with the patient during the initial interview and the patient coughed frequently during their interaction. The student had a negative tuberculin skin test prior to beginning the rotation. If this patient's infectious disease is transmitted to the student, which of the following processes is most likely to occur during the first week after exposure?

- A. Epithelioid transformation of macrophages
- B. Interferon secretion by activated T lymphocytes
- C. Intracellular bacterial proliferation
- D. Mounting response by B lymphocytes
- E. Scattered areas of caseous necrosis

Submit

https://t.me/USMLEWorldStep1
Show all

A 63-year-old man comes to the emergency department due to fever and cough. A medical student interviews and examines the patient and notes that he has had 3 months of fevers, night sweats, and productive cough. Chest x-ray reveals a right apical lung lesion, and the patient is subsequently placed in respiratory isolation. The medical student was in close contact with the patient during the initial interview and the patient coughed frequently during their interaction. The student had a negative tuberculin skin test prior to beginning the rotation. If this patient's infectious disease is transmitted to the student, which of the following processes is most likely to occur during the first week after exposure?

- A. Epithelioid transformation of macrophages (13%)
- ✗ B. Interferon secretion by activated T lymphocytes (33%)
- ✓ C. Intracellular bacterial proliferation (45%)
- D. Mounting response by B lymphocytes (6%)
- E. Scattered areas of caseous necrosis (1%)

Incorrect
Correct answer
C

45%
Answered correctly

03 secs
Time Spent

2023
Version

Explanation

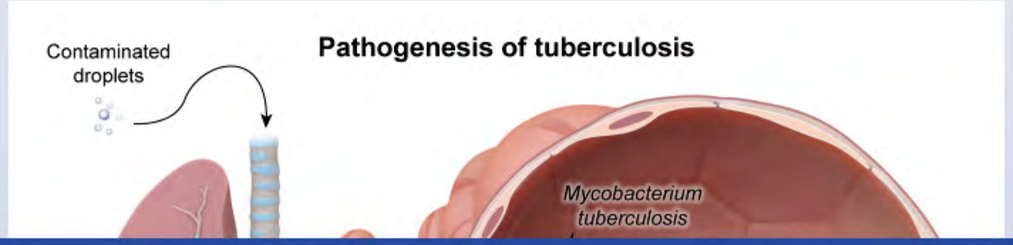

https://t.me/USMLEWorldStep1
Show all

Correct answer
C

Answered correctly
Time Spent
Version

Exhibit Display

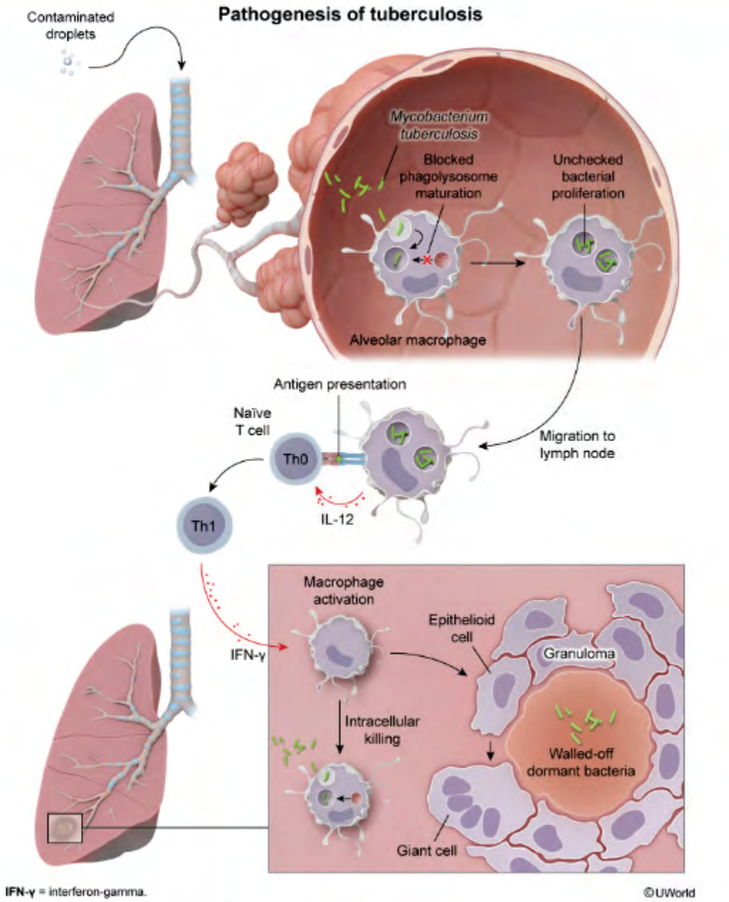

Zoom In | Zoom Out | Reset | New | Existing | My Notebook

https://t.me/USMLEWorldStep1

Show all

IFN-γ = interferon-gamma.

©UWorld

Mycobacterium tuberculosis is a facultative intracellular, acid-fast bacillus that is transmitted via aerosolized droplets. The pathogen is frequently inhaled into the lower lobe of the lung where it replicates within the alveoli. Alveolar macrophages phagocytose the organism but are initially unable to eliminate it due to microbial virulence factors (eg, cord factor) that prevent phagolysosome fusion and acidification. This allows *M tuberculosis* to **replicate** in an unchecked fashion **within** the phagosomes of alveolar **macrophages** for the first few weeks of the infection.

After a few weeks, antigen-presenting cells in the draining lymphatic system display mycobacterial antigens and release interleukin-12, which stimulates naïve CD4 lymphocytes to differentiate into T helper type 1 (T_H1) cells. T_h1 cells release interferon-gamma **(Choice B)**, which **activates macrophages** and causes them to:

- Form fully acidified phagolysosomes that are capable of destroying intracellular mycobacteria
- Differentiate into epithelioid cells and multinucleated Langhans giant cells that surround extracellular mycobacteria within granulomas **(Choice A)**. These cells release digestive enzymes and generate reactive oxygen species, which helps limit mycobacterial proliferation but also cause caseating necrosis and (in some patients) cavitary lung lesions **(Choice E)**.

(Choice D) Although B lymphocytes form antibodies against *M tuberculosis*, antibodies play a minimal role in the elimination of facultative intracellular organisms (intracellular bacteria are shielded from immunoglobulins).

Educational objective:
Primary tuberculosis infection is marked by initial unchecked *Mycobacterium tuberculosis* replication within the alveolar space and alveolar macrophages. After a few weeks, CD4 lymphocytes are stimulated to release interferon-gamma, which activates macrophages and allows them to destroy the mycobacteria.

References

- The tuberculous granuloma: an unsuccessful host defence mechanism providing a safety shelter for the

https://t.me/USMLEWorldStep1
Show all

A 19-year-old woman is brought to the emergency department after a motor vehicle collision. The patient's medical history includes celiac disease and 3 episodes of pneumonia. Her blood pressure is 80/45 mm Hg and pulse is 130/min. Physical examination reveals pallor, and ultrasound shows a splenic laceration. She receives a blood transfusion with O-negative packed red blood cells. During transfusion, the patient develops facial swelling, generalized hives, and shortness of breath. Which of the following is the most likely diagnosis in this patient?

- A. ABO incompatibility
- B. C1 inhibitor deficiency
- C. Leukocyte adhesion deficiency
- D. Selective IgA deficiency
- E. Severe combined immune deficiency

Submit

https://t.me/USMLEWorldStep1
Show all

A 19-year-old woman is brought to the emergency department after a motor vehicle collision. The patient's medical history includes celiac disease and 3 episodes of pneumonia. Her blood pressure is 80/45 mm Hg and pulse is 130/min. Physical examination reveals pallor, and ultrasound shows a splenic laceration. She receives a blood transfusion with O-negative packed red blood cells. During transfusion, the patient develops facial swelling, generalized hives, and shortness of breath. Which of the following is the most likely diagnosis in this patient?

- ✗ A. ABO incompatibility (18%)
- B. C1 inhibitor deficiency (18%)
- C. Leukocyte adhesion deficiency (2%)
- ✓ D. Selective IgA deficiency (59%)
- E. Severe combined immune deficiency (2%)

Incorrect
Correct answer
D

59%
Answered correctly

03 secs
Time Spent

2023
Version

Explanation

Selective IgA deficiency	
Clinical features	• Usually asymptomatic • Recurrent sinopulmonary, gastrointestinal infections • Autoimmune disease • Anaphylaxis during transfusions
Diagnosis	• Low or absent serum IgA levels

https://t.me/USMLEWorldStep1
Show all

Explanation

Selective IgA deficiency	
Clinical features	• Usually asymptomatic • Recurrent sinopulmonary, gastrointestinal infections • Autoimmune disease • Anaphylaxis during transfusions
Diagnosis	• Low or absent serum IgA levels • Normal IgG & IgM levels

This patient has a history of recurrent pneumonia, a diagnosis of celiac disease, and an anaphylactic reaction during blood transfusion. These findings are highly suggestive of **selective IgA deficiency**, the most common primary immunodeficiency. Although most patients with IgA deficiency are asymptomatic, some may have recurrent **sinopulmonary** (eg, sinusitis, pneumonia) and **gastrointestinal** infections (eg, *Giardia*) due to absence of secretory IgA. Concomitant **autoimmune** disorders (eg, celiac disease) are also common.

Patients with severe IgA deficiency can form IgE antibodies directed against IgA (anti-IgA antibodies). Serum IgA levels are low or undetectable due to failure of B cells to differentiate into IgA-secreting plasma cells; serum IgG and IgM levels are normal. When transfused with **blood products** (eg, red blood cells, platelets, fresh frozen plasma) containing small amounts of IgA, these patients can develop potentially fatal **anaphylaxis**. Therefore, patients with severe IgA deficiency should wear medical alert bracelets and receive blood products that are washed of residual plasma or from an IgA-deficient donor.

(Choice A) Acute hemolytic reactions occur when a patient's preexisting IgM or IgG antibody cross-reacts with antigens (eg, A, B, Rh, Kell) in transfused blood. Reactions range from fever and chills to severe hemolysis and circulatory collapse. However, anaphylaxis is IgE-mediated and does not result from ABO incompatibility.

(Choice B) C1 inhibitor deficiency causes hereditary angioedema that can be triggered by transfusions. Affected

https://t.me/USMLEWorldStep1
Show all

This patient has a history of recurrent pneumonia, a diagnosis of celiac disease, and an anaphylactic reaction during blood transfusion. These findings are highly suggestive of **selective IgA deficiency**, the most common primary immunodeficiency. Although most patients with IgA deficiency are asymptomatic, some may have recurrent **sinopulmonary** (eg, sinusitis, pneumonia) and **gastrointestinal** infections (eg, *Giardia*) due to absence of secretory IgA. Concomitant **autoimmune** disorders (eg, celiac disease) are also common.

Patients with severe IgA deficiency can form IgE antibodies directed against IgA (anti-IgA antibodies). Serum IgA levels are low or undetectable due to failure of B cells to differentiate into IgA-secreting plasma cells; serum IgG and IgM levels are normal. When transfused with **blood products** (eg, red blood cells, platelets, fresh frozen plasma) containing small amounts of IgA, these patients can develop potentially fatal **anaphylaxis**. Therefore, patients with severe IgA deficiency should wear medical alert bracelets and receive blood products that are washed of residual plasma or from an IgA-deficient donor.

(Choice A) Acute hemolytic reactions occur when a patient's preexisting IgM or IgG antibody cross-reacts with antigens (eg, A, B, Rh, Kell) in transfused blood. Reactions range from fever and chills to severe hemolysis and circulatory collapse. However, anaphylaxis is IgE-mediated and does not result from ABO incompatibility.

(Choice B) C1 inhibitor deficiency causes hereditary angioedema that can be triggered by transfusions. Affected patients have angioedema but do not have urticaria or wheezing, both of which are present in this patient.

(Choice C) Leukocyte adhesion deficiency results in poor leukocyte adherence and transmigration through the vasculature. Affected patients present with recurrent skin and mucosal infections but are not at an increased risk for anaphylaxis during transfusion.

(Choice E) Severe combined immune deficiency results from failure of T cell development and leads to a severe defect of cell-mediated and humoral immunity. This disease causes severe bacterial, viral, and fungal infections beginning in infancy.

Educational objective:
Selective IgA deficiency is the most common primary immune deficiency and can present with recurrent

https://t.me/USMLEWorldStep1
Show all

during blood transfusion. These findings are highly suggestive of **selective IgA deficiency**, the most common primary immunodeficiency. Although most patients with IgA deficiency are asymptomatic, some may have recurrent **sinopulmonary** (eg, sinusitis, pneumonia) and **gastrointestinal** infections (eg, *Giardia*) due to absence of secretory IgA. Concomitant **autoimmune** disorders (eg, celiac disease) are also common.

Patients with severe IgA deficiency can form IgE antibodies directed against IgA (anti-IgA antibodies). Serum IgA levels are low or undetectable due to failure of B cells to differentiate into IgA-secreting plasma cells; serum IgG and IgM levels are normal. When transfused with **blood products** (eg, red blood cells, platelets, fresh frozen plasma) containing small amounts of IgA, these patients can develop potentially fatal **anaphylaxis**. Therefore, patients with severe IgA deficiency should wear medical alert bracelets and receive blood products that are washed of residual plasma or from an IgA-deficient donor.

(Choice A) Acute hemolytic reactions occur when a patient's preexisting IgM or IgG antibody cross-reacts with antigens (eg, A, B, Rh, Kell) in transfused blood. Reactions range from fever and chills to severe hemolysis and circulatory collapse. However, anaphylaxis is IgE-mediated and does not result from ABO incompatibility.

(Choice B) C1 inhibitor deficiency causes hereditary angioedema that can be triggered by transfusions. Affected patients have angioedema but do not have urticaria or wheezing, both of which are present in this patient.

(Choice C) Leukocyte adhesion deficiency results in poor leukocyte adherence and transmigration through the vasculature. Affected patients present with recurrent skin and mucosal infections but are not at an increased risk for anaphylaxis during transfusion.

(Choice E) Severe combined immune deficiency results from failure of T cell development and leads to a severe defect of cell-mediated and humoral immunity. This disease causes severe bacterial, viral, and fungal infections beginning in infancy.

Educational objective:
Selective IgA deficiency is the most common primary immune deficiency and can present with recurrent sinopulmonary and gastrointestinal infections as well as autoimmune disease. Patients with severe IgA deficiency can have anaphylaxis during transfusion of blood products that contain small amounts of IgA.

https://t.me/USMLEWorldStep1
Show all

Selective IgA deficiency

Exhibit Display

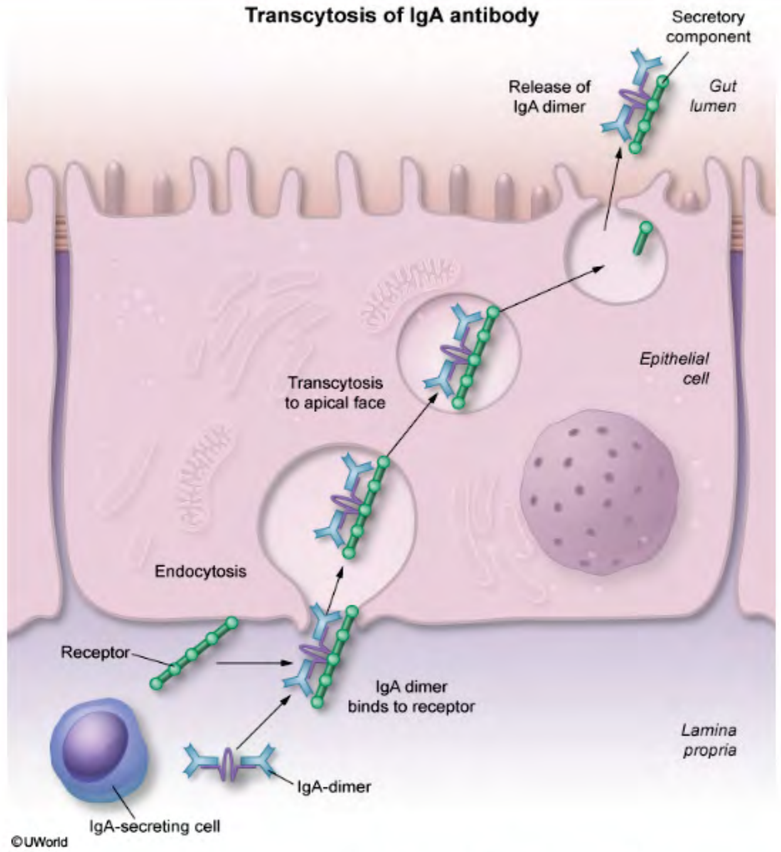

Zoom In | Zoom Out | Reset | New | Existing | My Notebook

This p
during
primar
recurr
of sec

Patien
levels
and Ig
plasm
patien
washe

(Choi
antige
circula

(Choi
patien

(Choice C) Leukocyte adhesion deficiency results in poor leukocyte adherence and transmigration through the

https://t.me/USMLEWorldStep1
Show all

A 54-year-old woman comes to the emergency department due to a 2-day history of fevers, chills, and severe fatigue. She has no chronic medical problems and takes no medication. Temperature is 38.9 C (102 F), blood pressure is 80/50 mm Hg, pulse is 130/min, and respirations are 20/min. The patient's left flank is tender to palpation. Cardiovascular examination reveals tachycardia, decreased capillary refill, and an estimated jugular venous pressure of 3 cm H_2O above the sternal notch. Laboratory results are as follows:

Complete blood count	
Hemoglobin	12 g/dL
Platelets	240,000/mm^3
Leukocytes	19,000/mm^3
Neutrophils	90%
Eosinophils	1%
Lymphocytes	9%
Serum chemistry	
Blood urea nitrogen	24 mg/dL
Creatinine	1.7 mg/dL
Urinalysis	
Nitrites	positive
White blood cells	100+/hpf

Which of the following is most likely decreased in this patient?

A. C-reactive protein

https://t.me/USMLEWorldStep1
Show all

Platelets	240,000/mm³
Leukocytes	19,000/mm³
Neutrophils	90%
Eosinophils	1%
Lymphocytes	9%
Serum chemistry	
Blood urea nitrogen	24 mg/dL
Creatinine	1.7 mg/dL
Urinalysis	
Nitrites	positive
White blood cells	100+/hpf

Which of the following is most likely decreased in this patient?

- A. C-reactive protein
- B. Endotoxin
- C. IL-1
- D. Nitric oxide
- E. Vasopressin

Submit

https://t.me/USMLEWorldStep1
Show all

Platelets	240,000/mm³
Leukocytes	19,000/mm³
Neutrophils	90%
Eosinophils	1%
Lymphocytes	9%

Serum chemistry

Blood urea nitrogen	24 mg/dL
Creatinine	1.7 mg/dL

Urinalysis

Nitrites	positive
White blood cells	100+/hpf

Which of the following is most likely decreased in this patient?

- A. C-reactive protein (5%)
- ✗ B. Endotoxin (3%)
- C. IL-1 (3%)
- D. Nitric oxide (39%)
- ✓ E. Vasopressin (48%)

Incorrect
Correct answer
E

48%
Answered correctly

06 secs
Time Spent

2023
Version

https://t.me/USMLEWorldStep1
Show all

This patient with pyelonephritis (eg, flank pain, pyuria) has likely developed sepsis (eg, fever, peripheral blood leukocytosis). **Sepsis** is a florid host **inflammatory response** to an infectious pathogen that can lead to widespread dysfunction of multiple organ systems. Cardiovascular manifestations include profound **vasodilation** resulting in low systemic vascular resistance and hypotension. Refractory hypotension (ie, vasoplegia) despite adequate intravascular volume (ie, normal jugular venous pressure), as in this patient, indicates progression to **septic shock**.

Septic shock is an extreme manifestation of sepsis, in which vasodilatory mediators overwhelm endogenous vasoconstrictor mechanisms. Key vasodilators include **nitric oxide** and prostaglandins; their production is **upregulated** by acute-phase cytokines such as tumor necrosis factor-α, **IL-1**, and IL-6 released from innate immune cells and endothelium exposed to bacterial cell wall glycoproteins and endotoxins **(Choices C and D)**.

The normal physiologic response to hypotension is compensatory secretion of vasopressin (antidiuretic hormone) by the posterior pituitary. In addition to promoting water retention (via renal collecting duct V_2 receptors), vasopressin is one of the most potent vasoconstrictors (via arteriolar smooth muscle V_1 receptors). In septic shock, however, **vasopressin is suppressed**, possibly due to impaired baroreceptor reflexes and/or depletion of endogenous stores.

For this reason, infusion of vasopressin can be helpful during treatment of septic shock, often decreasing the need for other pharmacologic vasoconstrictor agents (eg, norepinephrine).

(Choice A) C-reactive protein is an acute-phase protein produced in the liver in response to inflammation; it activates the classical complement pathway and promotes phagocytosis, thereby facilitating clearance of bacteria and cellular debris. Levels of C-reactive protein are elevated in sepsis.

(Choice B) Endotoxin (lipopolysaccharide) is a cell wall component of gram-negative bacteria that triggers an acute inflammatory response by binding to toll-like receptor 4 on immune cells. The vast majority of urinary tract infections are caused by gram-negative bacteria, and nitrite production is generally exclusive to gram-negative bacteria; therefore, endotoxin concentrations are likely markedly elevated in this patient.

Educational objective:

https://t.me/USMLEWorldStep1
Show all

resulting in low systemic vascular resistance and hypotension. Refractory hypotension (ie, vasoplegia) despite adequate intravascular volume (ie, normal jugular venous pressure), as in this patient, indicates progression to **septic shock**.

Septic shock is an extreme manifestation of sepsis, in which vasodilatory mediators overwhelm endogenous vasoconstrictor mechanisms. Key vasodilators include **nitric oxide** and prostaglandins; their production is **upregulated** by acute-phase cytokines such as tumor necrosis factor-α, **IL-1**, and IL-6 released from innate immune cells and endothelium exposed to bacterial cell wall glycoproteins and endotoxins **(Choices C and D)**.

The normal physiologic response to hypotension is compensatory secretion of vasopressin (antidiuretic hormone) by the posterior pituitary. In addition to promoting water retention (via renal collecting duct V_2 receptors), vasopressin is one of the most potent vasoconstrictors (via arteriolar smooth muscle V_1 receptors). In septic shock, however, **vasopressin is suppressed**, possibly due to impaired baroreceptor reflexes and/or depletion of endogenous stores.

For this reason, infusion of vasopressin can be helpful during treatment of septic shock, often decreasing the need for other pharmacologic vasoconstrictor agents (eg, norepinephrine).

(Choice A) C-reactive protein is an acute-phase protein produced in the liver in response to inflammation; it activates the classical complement pathway and promotes phagocytosis, thereby facilitating clearance of bacteria and cellular debris. Levels of C-reactive protein are elevated in sepsis.

(Choice B) Endotoxin (lipopolysaccharide) is a cell wall component of gram-negative bacteria that triggers an acute inflammatory response by binding to toll-like receptor 4 on immune cells. The vast majority of urinary tract infections are caused by gram-negative bacteria, and nitrite production is generally exclusive to gram-negative bacteria; therefore, endotoxin concentrations are likely markedly elevated in this patient.

Educational objective:
Septic shock is a dysfunctional host response to an infectious pathogen resulting from massive upregulation of vasodilators. A vasopressin deficit contributes to unbalanced vasodilation and refractory hypotension.

References

https://t.me/USMLEWorldStep1
Show all

Exhibit Display

Septic organ dysfunction	
CNS	• Delirium ("septic encephalopathy")
Cardiovascular	• Vasodilation & distributive shock • Capillary leak (edema) • Myocardial depression (severe)
Pulmonary	• Noncardiogenic pulmonary edema (ARDS)
Renal	• Acute kidney injury (ATN)
Hematologic	• Disseminated intravascular coagulation • Acute bone marrow suppression (eg, thrombocytopenia)
Endocrine	• Glucose dysregulation (hypoglycemia, hyperglycemia) • Primary adrenal insufficiency
Gastrointestinal & hepatic	• Cholestatic & hepatocellular liver injury • Paralytic ileus
Neuromuscular	• Polyneuropathy & myopathy
ARDS = acute respiratory distress syndrome; **ATN** = acute tubular necrosis.	

New | Existing | My Notebook

This p
leukoc
widesp
resulti
adequ
septic

Septic
vasoc
upreg
immun

The nc
by the
vasopr
shock,
endog

For thi
for oth

(Choi
activat
and ce

(Choice B) Endotoxin (lipopolysaccharide) is a cell wall component of gram-negative bacteria that triggers an acute inflammatory response by binding to toll-like receptor 4 on immune cells. The vast majority of urinary tract

https://t.me/USMLEWorldStep1
Show all

resulting in low systemic vascular resistance and hypotension. Refractory hypotension (ie, vasoplegia) despite adequate intravascular volume (ie, normal jugular venous pressure), as in this patient, indicates progression to **septic**

Septic
vasoc
upreg
immun

The n
by the
vasop
shock,
endog

For thi
for oth

(Choi
activat
and ce

(Choi
acute
infecti
bacter

Educa
Septic
vasodilators. A vasopressin deficit contributes to unbalanced vasodilation and refractory hypotension.

References

Exhibit Display

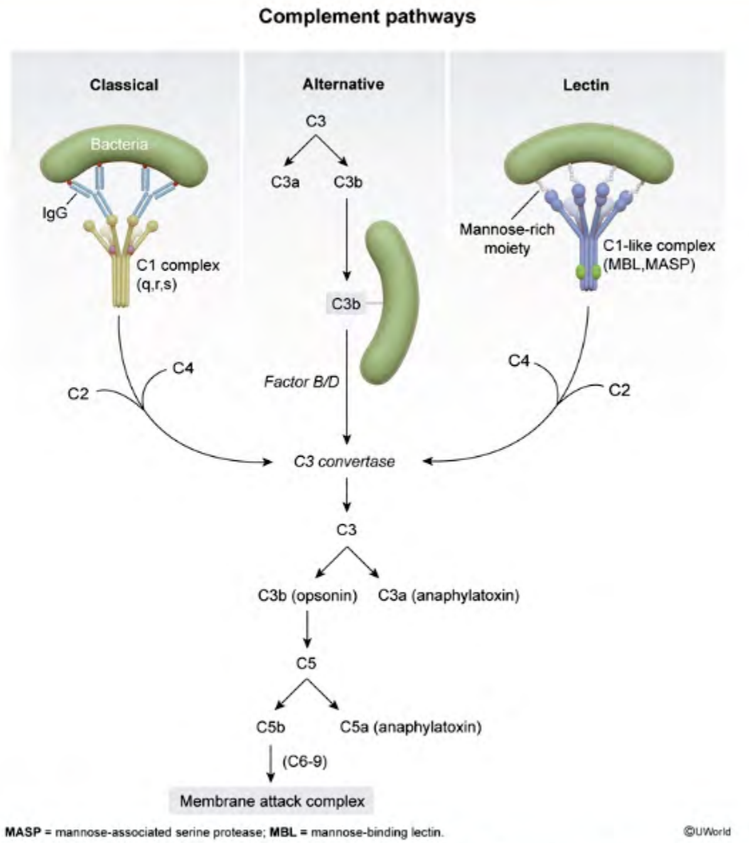

Zoom In | Zoom Out | Reset | New | Existing | My Notebook

https://t.me/USMLEWorldStep1

A 23-year-old man undergoes exercise physiology testing at sea level. He jogs on a treadmill to achieve a moderate-intensity physical activity level based on a target heart rate of 50%-70% of his estimated maximum heart rate. An increase in which of the following is expected at the peak of his exertion?

- A. Arterial blood mean CO_2 content
- B. Arterial blood mean O_2 content
- C. Hemoglobin affinity for O_2
- D. pH of the arterial blood
- E. Physiologic dead space
- F. Venous blood mean CO_2 content
- G. Venous blood mean O_2 content

Submit

https://t.me/USMLEWorldStep1
Show all

A 23-year-old man undergoes exercise physiology testing at sea level. He jogs on a treadmill to achieve a moderate-intensity physical activity level based on a target heart rate of 50%-70% of his estimated maximum heart rate. An increase in which of the following is expected at the peak of his exertion?

- A. Arterial blood mean CO_2 content (5%)
- B. Arterial blood mean O_2 content (7%)
- ✗ C. Hemoglobin affinity for O_2 (3%)
- D. pH of the arterial blood (3%)
- E. Physiologic dead space (1%)
- ✓ F. Venous blood mean CO_2 content (75%)
- G. Venous blood mean O_2 content (2%)

Incorrect
Correct answer
F

75%
Answered correctly

04 secs
Time Spent

2023
Version

Explanation

Long-distance running and other forms of physical exercise cause **increased oxidative metabolism** of glucose and fatty acids in the skeletal muscle. This markedly increases the rates of O_2 consumption and CO_2 production, which must be balanced by increases in skeletal muscle perfusion and alveolar ventilation.

The cardiovascular response to exercise involves vasoconstriction in the splanchnic circulation and **vasodilation in skeletal muscle**, shunting blood toward exercising muscle. The vasodilation is predominant, resulting in overall **decreased systemic vascular resistance**. There is also an increase in heart rate and stroke volume that

https://t.me/USMLEWorldStep1
Show all

Long-distance running and other forms of physical exercise cause **increased oxidative metabolism** of glucose and fatty acids in the skeletal muscle. This markedly increases the rates of O_2 consumption and CO_2 production, which must be balanced by increases in skeletal muscle perfusion and alveolar ventilation.

The cardiovascular response to exercise involves vasoconstriction in the splanchnic circulation and **vasodilation in skeletal muscle**, shunting blood toward exercising muscle. The vasodilation is predominant, resulting in overall **decreased systemic vascular resistance**. There is also an increase in heart rate and stroke volume that markedly **increases cardiac output** and O_2 delivery to the tissues. Increased O_2 extraction by the tissues leads to a concomitant **increase in CO_2 production**, which is absorbed by the systemic capillaries and transported in high quantities via venous blood to the lungs, where it is expired.

(Choices A and B) Mean values for arterial O_2 and CO_2 content remain essentially constant during exercise, even during periods of intense exertion. This is likely accomplished via tight regulation of increases in alveolar ventilation and gas exchange efficiency.

(Choices C and D) Tissue pH typically decreases during exercise due to production of carbonic and lactic acid in active skeletal muscle. The acidic pH causes a decrease in hemoglobin affinity for O_2 (ie, right shift in the O_2-hemoglobin dissociation curve) to facilitate unloading of O_2 in the tissues. Although venous pH may decrease significantly during moderate exercise, there is typically little change in arterial pH due to respiratory compensation.

(Choice E) Physiologic dead space (ie, the air in the respiratory system that does not participate in gas exchange) is decreased during exercise due to a decrease in pulmonary vascular resistance that allows perfusion of additional pulmonary capillary beds.

(Choice G) The mean O_2 content of venous blood remains the same or decreases with exercise because the rate of O_2 extraction by the tissues outpaces the rate of oxygen delivery (cardiac output). In most healthy individuals, cardiac output is the major limiting factor to O_2 consumption during exercise.

Educational objective:
During physical exercise, there is increased skeletal muscle CO_2 production that increases the CO_2 content of

https://t.me/USMLEWorldStep1
Show all

The cardiovascular response to exercise involves vasoconstriction in the splanchnic circulation and **vasodilation in skeletal muscle**, shunting blood toward exercising muscle. The vasodilation is predominant, resulting in overall **decreased systemic vascular resistance**. There is also an increase in heart rate and stroke volume that markedly **increases cardiac output** and O_2 delivery to the tissues. Increased O_2 extraction by the tissues leads to a concomitant **increase in CO_2 production**, which is absorbed by the systemic capillaries and transported in high quantities via venous blood to the lungs, where it is expired.

(Choices A and B) Mean values for arterial O_2 and CO_2 content remain essentially constant during exercise, even during periods of intense exertion. This is likely accomplished via tight regulation of increases in alveolar ventilation and gas exchange efficiency.

(Choices C and D) Tissue pH typically decreases during exercise due to production of carbonic and lactic acid in active skeletal muscle. The acidic pH causes a decrease in hemoglobin affinity for O_2 (ie, right shift in the O_2-hemoglobin dissociation curve) to facilitate unloading of O_2 in the tissues. Although venous pH may decrease significantly during moderate exercise, there is typically little change in arterial pH due to respiratory compensation.

(Choice E) Physiologic dead space (ie, the air in the respiratory system that does not participate in gas exchange) is decreased during exercise due to a decrease in pulmonary vascular resistance that allows perfusion of additional pulmonary capillary beds.

(Choice G) The mean O_2 content of venous blood remains the same or decreases with exercise because the rate of O_2 extraction by the tissues outpaces the rate of oxygen delivery (cardiac output). In most healthy individuals, cardiac output is the major limiting factor to O_2 consumption during exercise.

Educational objective:
During physical exercise, there is increased skeletal muscle CO_2 production that increases the CO_2 content of venous blood. Arterial O_2 and CO_2 content remains constant via increases in alveolar ventilation and gas exchange efficiency. Venous O_2 content remains constant or is decreased due to increased O_2 extraction by the tissues that matches or exceeds the rate of oxygen delivery (ie, O_2 consumption during exercise is limited by cardiac output).

https://t.me/USMLEWorldStep1
Show all

A 72-year-old woman comes to the office due to a persistent cough over the last 2 months that is occasionally associated with scant, white sputum. She has also lost 4.5 kg (10 lb) since the onset of her symptoms. The patient is an ex-smoker with a 25-pack-year history. She was diagnosed with mild chronic obstructive pulmonary disease several years ago, and she uses albuterol as needed for episodes of wheezing and shortness of breath. Physical examination shows scattered wheezes bilaterally. Chest CT scan reveals a mass in the right lung. Light microscopy of the mass is shown below:

Which of the following is the most likely diagnosis?

- A. Adenocarcinoma of the lung
- B. Mesothelioma
- C. Pulmonary tuberculosis
- D. Small cell lung cancer
- E. Squamous cell lung cancer

Submit

https://t.me/USMLEWorldStep1
Show all

A 72-year-old woman comes to the office due to a persistent cough over the last 2 months that is occasionally
associ
patien
diseas
Physic
micros

Exhibit Display

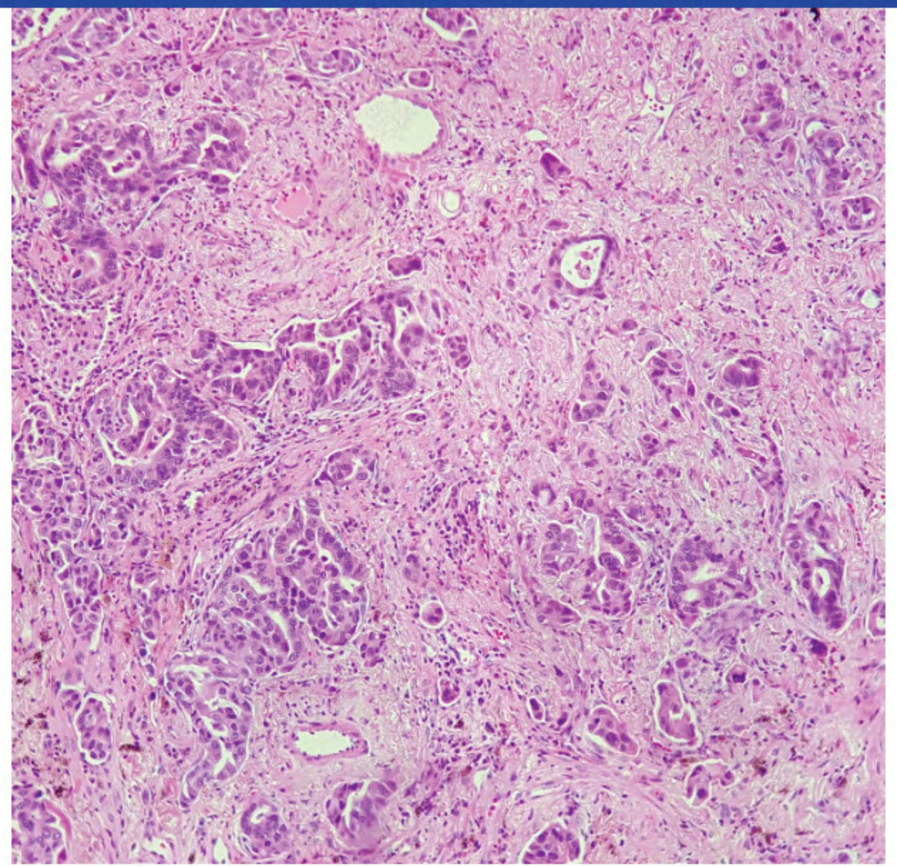

Zoom In Zoom Out Reset New | Existing My Notebook

https://t.me/USMLEWorldStep1

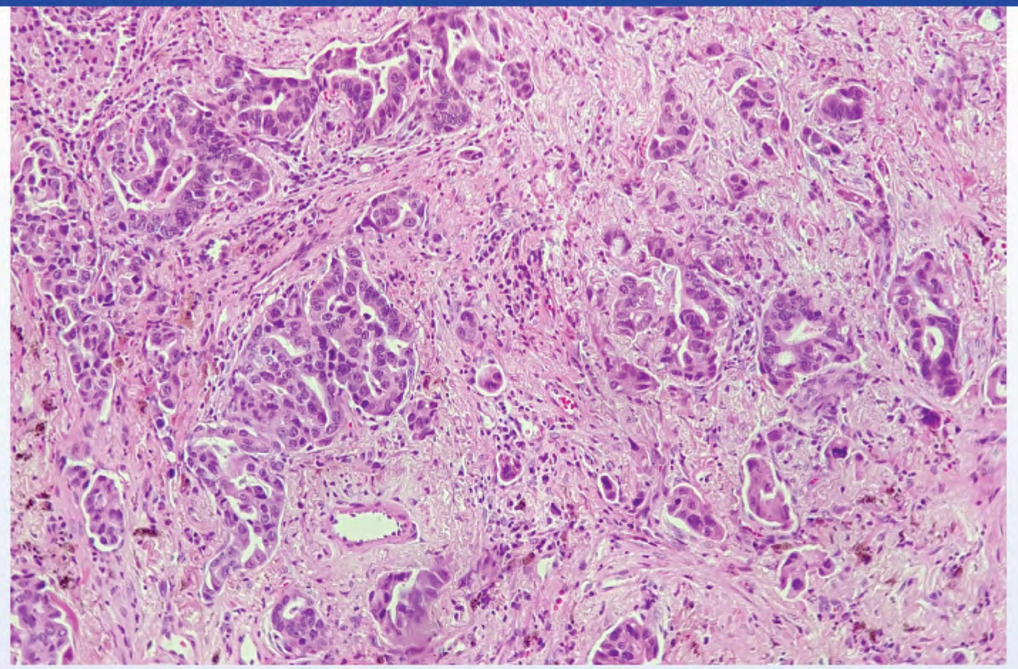

Which of the following is the most likely diagnosis?

- A. Adenocarcinoma of the lung
- B. Mesothelioma
- C. Pulmonary tuberculosis
- D. Small cell lung cancer
- E. Squamous cell lung cancer

Submit

https://t.me/USMLEWorldStep1
Show all

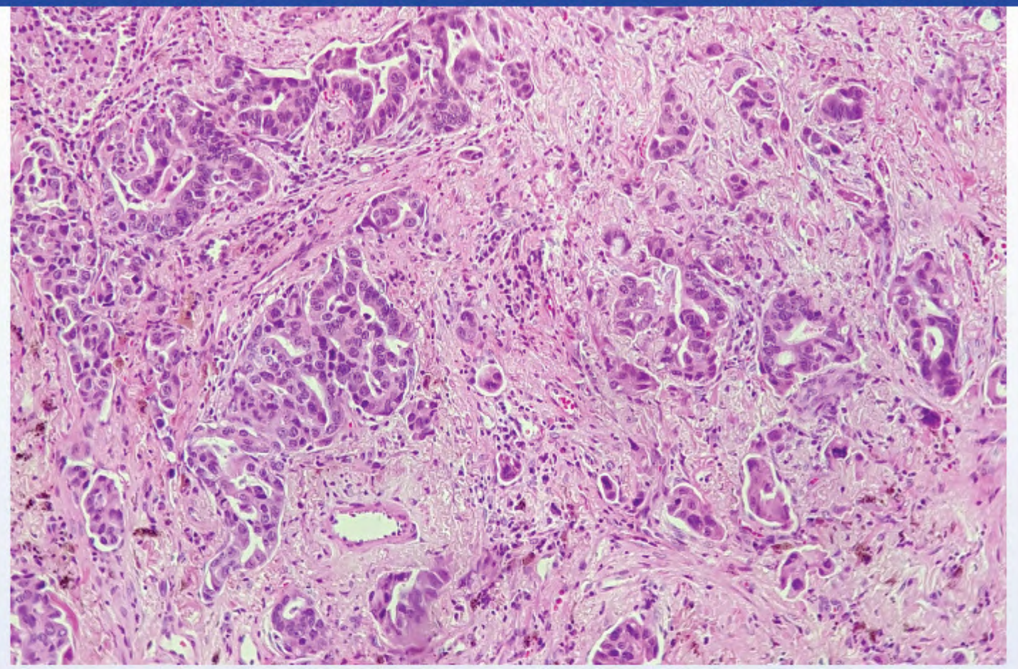

Which of the following is the most likely diagnosis?

- ✓ A. Adenocarcinoma of the lung (65%)
- B. Mesothelioma (1%)
- C. Pulmonary tuberculosis (0%)
- D. Small cell lung cancer (13%)
- E. Squamous cell lung cancer (18%)

Correct

65%
Answered correctly

10 secs
Time Spent

2023
Version

https://t.me/USMLEWorldStep1
Show all

Adenocarcinoma of the lung Normal lung

Exhibit Display

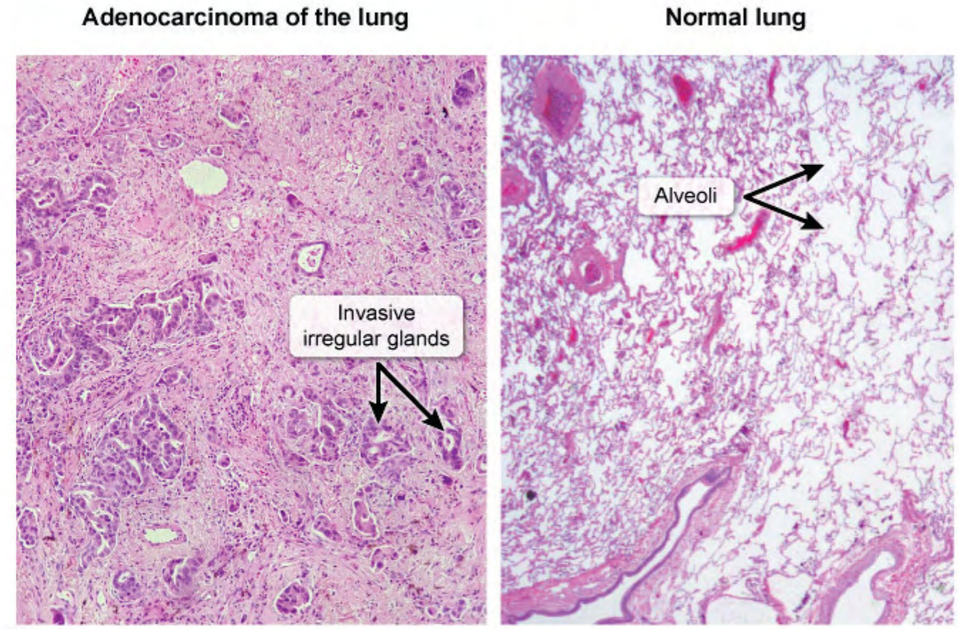

Zoom In Zoom Out Reset New | Existing My Notebook

This p
primar
most f
the alv
nuclei

Clinica
unexp
Imagir

(Choice B) Mesothelioma is a rare malignancy associated with asbestos exposure; it arises from mesothelial cells and is located in the pleura (not the lung parenchyma, as in this patient). Histopathology demonstrates cuboidal or

https://t.me/USMLEWorldStep1

©UWorld

This patient's histologic findings are consistent with **adenocarcinoma of the lung**, the most common type of primary lung cancer in the United States. It is also the most common type seen in **nonsmokers**, although like most forms of lung cancer, the **risk is increased** with prolonged **smoking** history. Adenocarcinoma arises from the alveolar epithelium and is characterized by invasive cells with abundant cytoplasm and eccentrically placed nuclei that form **irregular glandular elements**; mucin production is common.

Clinical manifestations are similar to other types of lung cancer and include cough, dyspnea, hemoptysis, and unexplained weight loss. **Mucinous** forms can produce copious amounts of watery sputum (**bronchorrhea**). Imaging shows a discrete mass or pneumonia-like consolidation, typically located on the **periphery** of the lung.

(Choice B) Mesothelioma is a rare malignancy associated with asbestos exposure; it arises from mesothelial cells and is located in the pleura (not the lung parenchyma, as in this patient). Histopathology demonstrates cuboidal or spindle cells that stain positive for cytokeratin.

(Choice C) Pulmonary tuberculosis typically presents with a cavitary lesion in the upper lungs, often associated with hilar adenopathy. Histology demonstrates caseating granulomas with multinucleated giant cells.

(Choice D) Small cell lung cancer is an aggressive malignancy strongly associated with smoking; it often arises in the major bronchi. Histopathology demonstrates small, blue cells with scant cytoplasm, indistinct nucleoli, and granular chromatin (salt and pepper pattern).

(Choice E) Squamous cell lung cancer is associated with smoking and typically arises centrally within a bronchial lumen. Histopathology demonstrates invasive squamous cells with intercellular bridges and keratin pearls.

Educational objective:
Adenocarcinoma, the most common pulmonary malignancy, is characterized histopathologically by invasive glandular cells with abundant cytoplasm and eccentrically placed nuclei; mucin production is common. Imaging typically demonstrates a discrete mass or pneumonia-like consolidation at the periphery of the lung.

Pathology Pulmonary & Critical Care Lung cancer

https://t.me/USMLEWorldStep1

©UWorld

This p
primar
most f
the alv
nuclei

Clinica
unexp
Imagir

(Choi
and is
spindl

(Choi
with hi

(Choi
the ma
granul

(Choi
lumen

Educa
Adeno
glandu
typical

Exhibit Display

Lung cancer

Tumor type	Incidence	Location	Clinical associations
Adenocarcinoma	40%-50%	Peripheral	• Clubbing • Hypertrophic osteoarthropathy
Squamous cell carcinoma	20%-25%	Central	• Hypercalcemia • Necrosis & cavitation
Small cell carcinoma	10%-15%	Central	• Cushing syndrome • SIADH • Lambert-Eaton syndrome
Large cell carcinoma	5%-10%	Peripheral	• Gynecomastia • Galactorrhea

SIADH = syndrome of inappropriate antidiuretic hormone.

New | Existing | My Notebook

Pathology | Pulmonary & Critical Care | Lung cancer

https://t.me/USMLEWorldStep1

©UWorld

This p
primar
most f
the alv
nuclei

Clinica
unexp
Imagir

(Choi
and is
spindl

(Choi
with hi

(Choi
the ma
granul

(Choi
lumen

Educa
Adeno
glandu
typical

Exhibit Display

Caseating granuloma

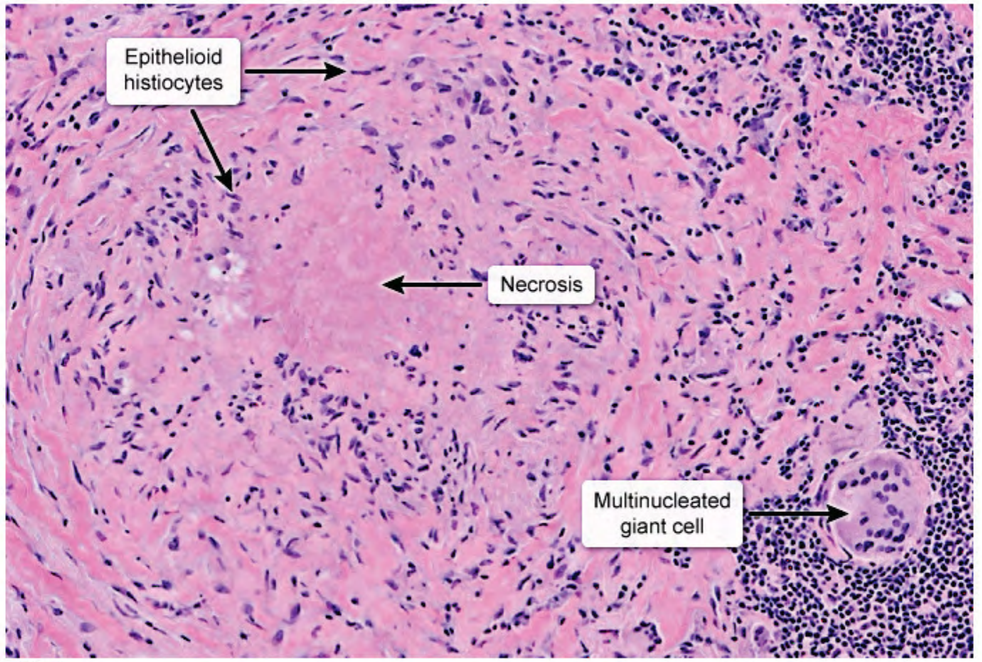

©UWorld

Zoom In | Zoom Out | Reset | New | Existing | My Notebook

Pathology | Pulmonary & Critical Care | Lung cancer

https://t.me/USMLEWorldStep1
Show all

©UWorld

This p
primar
most f
the alv
nuclei

Clinica
unexp
Imagir

(Choi
and is
spindl

(Choi
with hi

(Choi
the ma
granul

(Choi
lumen

Educa
Adeno
glandu
typical

Exhibit Display

Small cell lung carcinoma

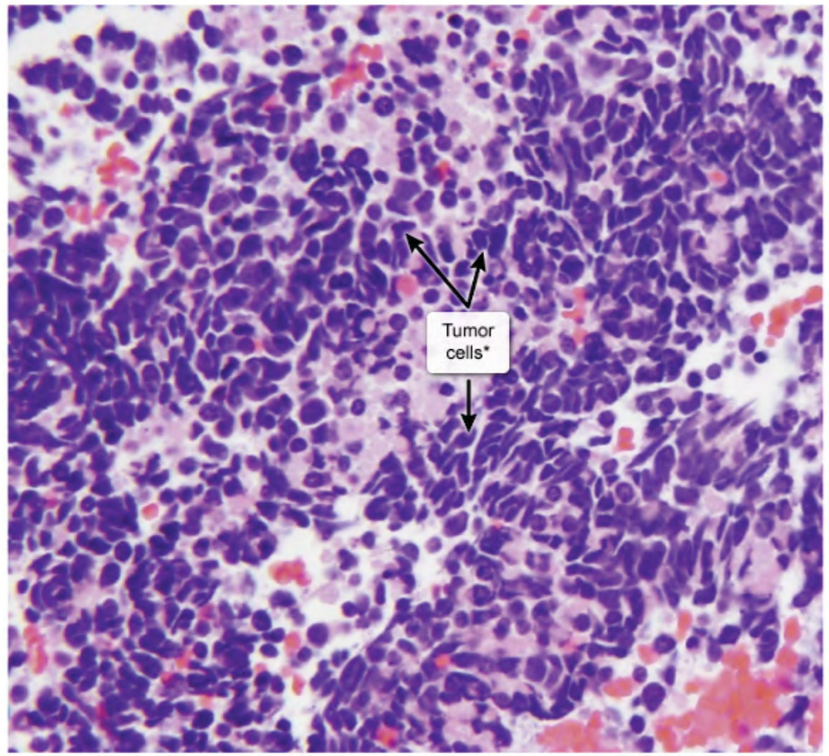

*Hyperchromatic nuclei, scant cytoplasm, and indistinct nucleoli

©UWorld

Zoom In | Zoom Out | Reset | New | Existing | My Notebook

Pathology | Pulmonary & Critical Care | Lung cancer

https://t.me/USMLEWorldStep1

©UWorld

This p
primar
most f
the alv
nuclei

Clinica
unexp
Imagir

(Choi
and is
spindl

(Choi
with hi

(Choi
the ma
granul

(Choi
lumen

Educa
Adeno
glandu
typical

Exhibit Display

Squamous cell carcinoma of the lung

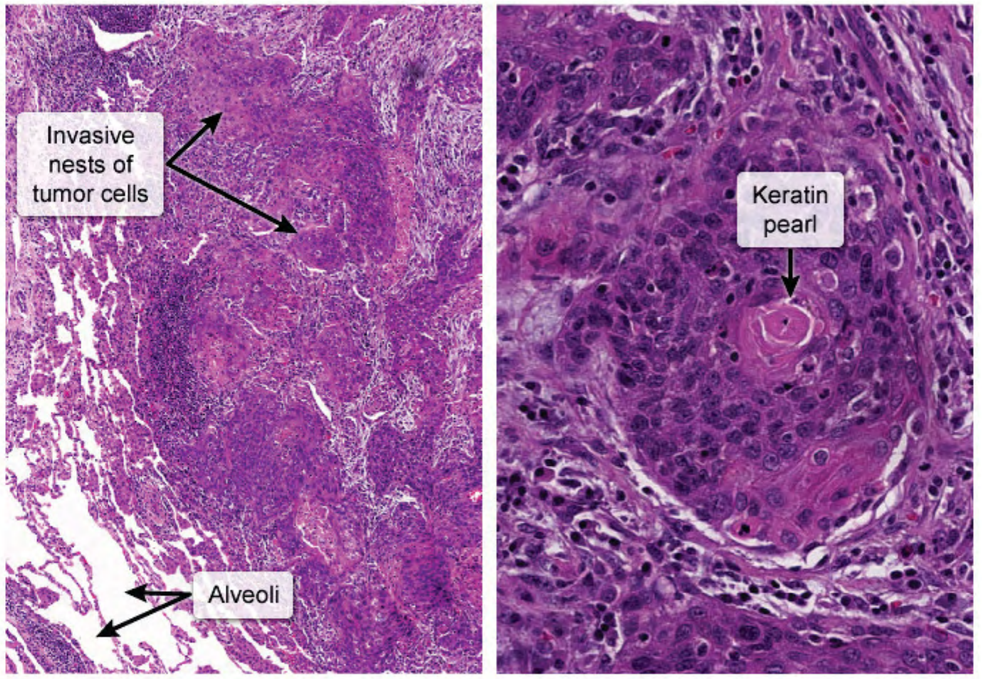

©UWorld

Zoom In | Zoom Out | Reset | New | Existing | My Notebook

Pathology | Pulmonary & Critical Care | Lung cancer

https://t.me/USMLEWorldStep1

A 44-year-old man comes to the office due to excessive daytime sleepiness and loud snoring. He undergoes polysomnography for evaluation of obstructive sleep apnea. During the study, sensors are attached to monitor ocular movements, muscle electrical potentials, brain activity, airflow, and cardiac rhythm. Based on the ocular and muscle readings, the patient's sleep stages are classified into rapid eye movement (REM) or non-REM. In addition, the patient's body position is tracked by video. He tosses and turns throughout the night, sleeping on his back, side, and stomach. Frequent episodes of obstructive apnea and hypopnea are detected. The highest degree of obstructive apnea is likely to be seen during which of the following categories of sleep?

- A. Non-REM sleep in the lateral position
- B. Non-REM sleep in the prone position
- C. Non-REM sleep in the supine position
- D. REM sleep in the lateral position
- E. REM sleep in the supine position

Submit

https://t.me/USMLEWorldStep1
Show all

A 44-year-old man comes to the office due to excessive daytime sleepiness and loud snoring. He undergoes polysomnography for evaluation of obstructive sleep apnea. During the study, sensors are attached to monitor ocular movements, muscle electrical potentials, brain activity, airflow, and cardiac rhythm. Based on the ocular and muscle readings, the patient's sleep stages are classified into rapid eye movement (REM) or non-REM. In addition, the patient's body position is tracked by video. He tosses and turns throughout the night, sleeping on his back, side, and stomach. Frequent episodes of obstructive apnea and hypopnea are detected. The highest degree of obstructive apnea is likely to be seen during which of the following categories of sleep?

- A. Non-REM sleep in the lateral position (0%)
- ✗ B. Non-REM sleep in the prone position (6%)
- C. Non-REM sleep in the supine position (31%)
- D. REM sleep in the lateral position (1%)
- ✓ E. REM sleep in the supine position (59%)

Incorrect
Correct answer
E

59%
Answered correctly

03 secs
Time Spent

2023
Version

Explanation

The gold standard for diagnosis of obstructive sleep apnea (OSA) is a supervised in-lab polysomnography (sleep study). During the study, multiple channels of data are recorded, including eye movements, muscle activation, airflow, thoracic and abdominal motion, cardiac rhythm, and body position. OSA is present when there is decreased or absent airflow despite thoracoabdominal effort.

Episodes of obstruction are caused by repetitive collapse of the upper airway. **Relaxation** of the tongue,

https://t.me/USMLEWorldStep1
Show all

Correct answer
E

Answered correctly

Time Spent

Version

Explanation

The gold standard for diagnosis of obstructive sleep apnea (OSA) is a supervised in-lab polysomnography (sleep study). During the study, multiple channels of data are recorded, including eye movements, muscle activation, airflow, thoracic and abdominal motion, cardiac rhythm, and body position. OSA is present when there is decreased or absent airflow despite thoracoabdominal effort.

Episodes of obstruction are caused by repetitive collapse of the upper airway. **Relaxation** of the tongue, oropharyngeal dilator (eg, genioglossus), and soft palatal musculature contributes to this collapse. Muscle tone and collapsibility are greatly influenced by **rapid eye movement** (REM) sleep and **body position**:

- During **REM**, there is generalized tonic inhibition of all striated muscles except the diaphragm. REM-induced paralysis of upper airway muscles increases the propensity to obstruction **(Choices A, B, and C)**. REM is identified during polysomnography by the simultaneous presence of ocular movements, suppressed skeletal muscle activity, and electroencephalogram showing high-frequency waves resembling wakefulness.
- During **supine** sleep, upper airway obstruction is more likely due to the effect of gravity promoting collapse of the upper airway. Conversely, airway patency is improved in the upright (eg, recliner), lateral, and prone positions **(Choice D)**.

Therefore, the severity of obstructive apnea is highest during **REM supine sleep**.

Educational objective:
Obstructive sleep apnea is due to upper airway muscle relaxation leading to repetitive pharyngeal collapse. The degree of collapse is highest when muscle tone is globally inhibited during rapid eye movement sleep. Collapse is also greatest in the supine position due to the effect of gravity on the upper airway structures.

Pathophysiology Pulmonary & Critical Care Obstructive sleep apnea

https://t.me/USMLEWorldStep1
Show all

Correct answer
E

Answered correctly

Time Spent

Version

Exhibit Display

Expl

The g
study)
airflow
decrea

Episod
oropha
and co

- D
  p
  ic
  m
- D
  th
  p

Theref

Educa
Obstru
degree
also g

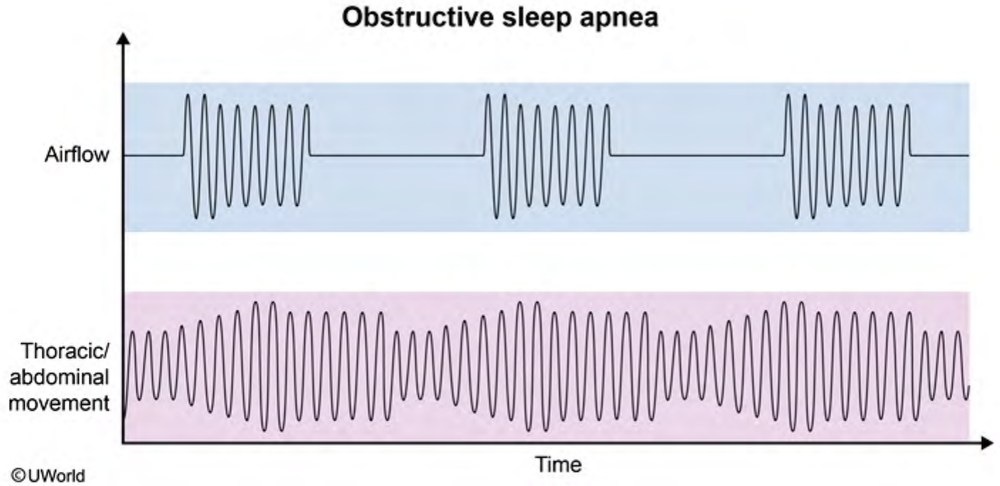

Zoom In
Zoom Out
Reset
New | Existing
My Notebook

Pathophysiology
Pulmonary & Critical Care
Obstructive sleep apnea

https://t.me/USMLEWorldStep1

Show all

Correct answer
E

Answered correctly

Time Spent

Version

Exhibit Display

Expl

The g
study)
airflow
decrea

Episod
oropha
and co

- D
  p
  ic
  m
- D
  th
  p

Theret

Educa
Obstru
degree
also g

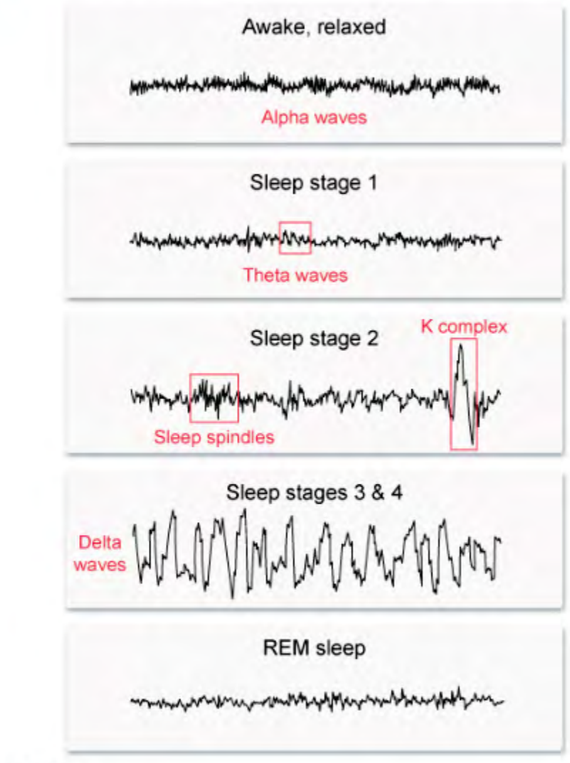

Zoom In Zoom Out Reset New | Existing My Notebook

Pathophysiology Pulmonary & Critical Care Obstructive sleep apnea

https://t.me/USMLEWorldStep1

Show all

A 46-year-old man comes to the emergency department due to shortness of breath, cough, and fever. The patient began experiencing mild upper respiratory illness a week ago. He has a history of asthma and was using inhaled bronchodilators more frequently since the onset of respiratory illness. Over the past 2 days, he has had worsening breathlessness, productive cough, and high fever. The patient has no other medical conditions. Temperature is 38.9 C (102 F), blood pressure is 90/60 mm Hg, pulse is 120/min, and respirations are 28/min. On physical examination, the patient appears in severe respiratory distress with intercostal retractions. Lung auscultation reveals bilateral wheezing. Prompt endotracheal intubation for respiratory support is planned. Prior to endotracheal intubation, intravenous ketamine is administered for induction of anesthesia. Which of the following characteristics is the most likely reason for use of this anesthetic agent in this patient?

- A. Direct GABA agonism
- B. Lower lipid solubility
- C. Metabolism by plasma enzymes
- D. Neuromuscular blockade effect
- E. Sympathomimetic activity

Submit

https://t.me/USMLEWorldStep1
Show all

A 46-year-old man comes to the emergency department due to shortness of breath, cough, and fever. The patient began experiencing mild upper respiratory illness a week ago. He has a history of asthma and was using inhaled bronchodilators more frequently since the onset of respiratory illness. Over the past 2 days, he has had worsening breathlessness, productive cough, and high fever. The patient has no other medical conditions. Temperature is 38.9 C (102 F), blood pressure is 90/60 mm Hg, pulse is 120/min, and respirations are 28/min. On physical examination, the patient appears in severe respiratory distress with intercostal retractions. Lung auscultation reveals bilateral wheezing. Prompt endotracheal intubation for respiratory support is planned. Prior to endotracheal intubation, intravenous ketamine is administered for induction of anesthesia. Which of the following characteristics is the most likely reason for use of this anesthetic agent in this patient?

- A. Direct GABA agonism (9%)
- ✗ B. Lower lipid solubility (18%)
- C. Metabolism by plasma enzymes (3%)
- D. Neuromuscular blockade effect (23%)
- ✓ E. Sympathomimetic activity (44%)

Incorrect
Correct answer
E

44%
Answered correctly

03 secs
Time Spent

2023
Version

Explanation

This hemodynamically unstable patient has severe **bronchospasm** and impending respiratory failure and requires intubation. Prior to intubation, anesthesia must be induced. Three medications are commonly used because of their rapid onset of action and short duration of effect.

https://t.me/USMLEWorldStep1
Show all

Explanation

This hemodynamically unstable patient has severe **bronchospasm** and impending respiratory failure and requires intubation. Prior to intubation, anesthesia must be induced. Three medications are commonly used because of their rapid onset of action and short duration of effect.

- **Propofol:** A highly lipophilic GABA agonist that may be used for **long-term sedation**. Disadvantages include vasodilation, which can result in **hypotension** and an increase in serum triglycerides and lipase.
- **Etomidate:** A GABA agonist that has the advantage of being the most **hemodynamically neutral**. It does not cause changes in heart rate, blood pressure, or cardiac output. However, it inhibits cortisol synthesis, which can lead to (reversible) **adrenocortical suppression**. Because of this, it is often avoided in patients with septic shock, and it should not be used as maintenance of sedation after induction.
- **Ketamine:** An N-methyl-D-aspartate (NMDA) antagonist that is similar to PCP; it **preserves the respiratory drive** during induction of anesthesia. In contrast to propofol and etomidate, it also provides an analgesic effect. Ketamine stimulates the release of catecholamines (ie, **sympathomimetic**), which can cause **bronchodilation** but also increase the heart rate, myocardial contractility, and cerebral blood flow, potentially putting the patient at risk for cardiovascular events or increased intracranial pressure.

In this patient with an acute asthma attack, **ketamine** was likely chosen because it stimulates release of catecholamines that increase sympathomimetic activity and may **improve bronchospasm**.

(Choice A) Propofol and etomidate are both GABA agonists, but ketamine works at the NMDA receptor.

(Choice B) Both ketamine and etomidate are much less lipophilic than propofol.

(Choice C) Both ketamine and etomidate are metabolized primarily by the liver. Propofol is also metabolized by the liver, but the effect is terminated by its redistribution rather than metabolism.

(Choice D) Neuromuscular blockade is often used to facilitate intubation. None of the three commonly used

https://t.me/USMLEWorldStep1
Show all

- **Propofol:** A highly lipophilic GABA agonist that may be used for **long-term sedation**. Disadvantages include vasodilation, which can result in **hypotension** and an increase in serum triglycerides and lipase.
- **Etomidate:** A GABA agonist that has the advantage of being the most **hemodynamically neutral**. It does not cause changes in heart rate, blood pressure, or cardiac output. However, it inhibits cortisol synthesis, which can lead to (reversible) **adrenocortical suppression**. Because of this, it is often avoided in patients with septic shock, and it should not be used as maintenance of sedation after induction.
- **Ketamine:** An N-methyl-D-aspartate (NMDA) antagonist that is similar to PCP; it **preserves the respiratory drive** during induction of anesthesia. In contrast to propofol and etomidate, it also provides an analgesic effect. Ketamine stimulates the release of catecholamines (ie, **sympathomimetic**), which can cause **bronchodilation** but also increase the heart rate, myocardial contractility, and cerebral blood flow, potentially putting the patient at risk for cardiovascular events or increased intracranial pressure.

In this patient with an acute asthma attack, **ketamine** was likely chosen because it stimulates release of catecholamines that increase sympathomimetic activity and may **improve bronchospasm**.

(Choice A) Propofol and etomidate are both GABA agonists, but ketamine works at the NMDA receptor.

(Choice B) Both ketamine and etomidate are much less lipophilic than propofol.

(Choice C) Both ketamine and etomidate are metabolized primarily by the liver. Propofol is also metabolized by the liver, but the effect is terminated by its redistribution rather than metabolism.

(Choice D) Neuromuscular blockade is often used to facilitate intubation. None of the three commonly used induction anesthetics cause significant neuromuscular blockade, so an additional medication (eg, succinylcholine, rocuronium) is used if needed.

Educational objective:
Ketamine can be used for anesthesia induction. The side effects of increased catecholamine release (eg, bronchodilation) are often exploited in patients with bronchospasm.

https://t.me/USMLEWorldStep1
Show all

A 32-year-old woman comes to the emergency department with lightheadedness and shortness of breath, which started while shopping at a supermarket. During the last 6 months, she had increasing shortness of breath and had to adjust her daily activities. The patient has no other medical problems and does not use tobacco, alcohol, or illicit drugs. There is no family history of heart disease, stroke, or blood clots. Her BMI is 25 kg/m^2. After initial assessment, the patient reports that she feels "fine," refuses further evaluation, and insists on being discharged. She dies a month later. At autopsy, her heart has the following appearance (RV, right ventricle; LV, left ventricle):

Which of the following is the most likely diagnosis?

- A. Bicuspid aortic valve with acquired aortic stenosis
- B. Dilated cardiomyopathy
- C. Essential hypertension
- D. Myocardial infarction
- E. Pulmonary arterial hypertension
- F. Wolff-Parkinson-White syndrome

Submit

https://t.me/USMLEWorldStep1
Show all

A 32-year-old woman comes to the emergency department with lightheadedness and shortness of breath, which started
had to
illicit d
assess
She di

Exhibit Display

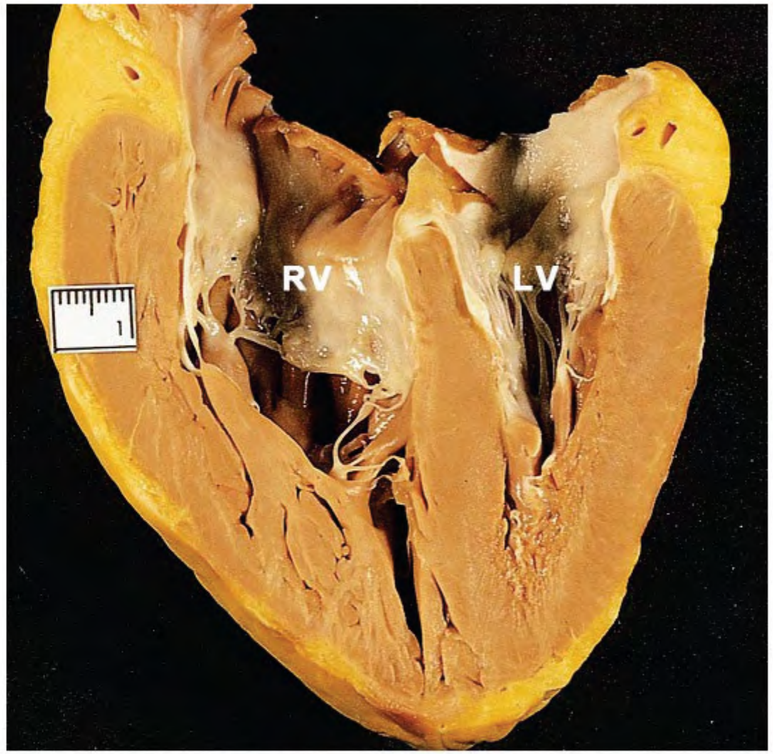

Displayed with permission from Springer Healthcare Ltd. © Copyright 2000 by Current Medicine

Zoom In | Zoom Out | Reset | New | Existing | My Notebook

Which of the following is the most likely diagnosis?

https://t.me/USMLEWorldStep1
Show all

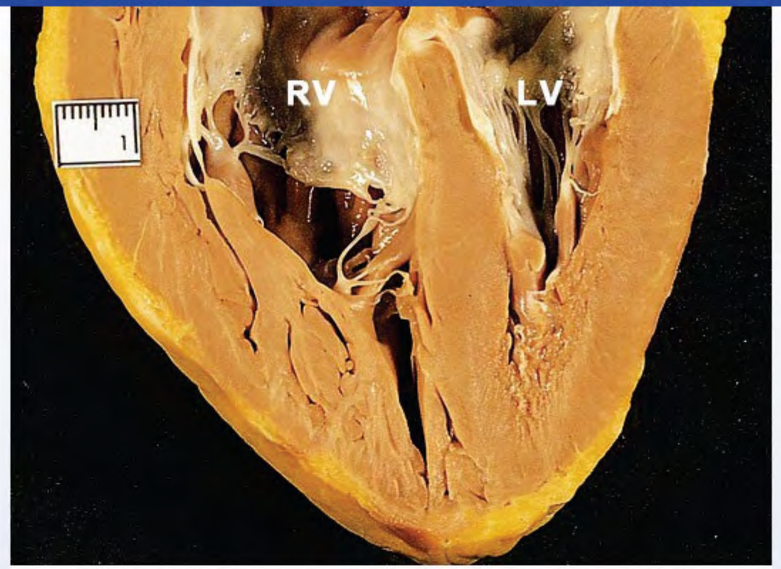

Displayed with permission from Springer Healthcare Ltd. © Copyright 2000 by Current Medicine

Which of the following is the most likely diagnosis?

- A. Bicuspid aortic valve with acquired aortic stenosis (5%)
- ✕ B. Dilated cardiomyopathy (3%)
- C. Essential hypertension (4%)
- D. Myocardial infarction (2%)
- ✓ E. Pulmonary arterial hypertension (80%)
- F. Wolff-Parkinson-White syndrome (3%)

Incorrect
Correct answer
E

80%
Answered correctly

09 secs
Time Spent

2023
Version

https://t.me/USMLEWorldStep1
Show all

Autopsy reveals significant **thickening of the right ventricular free wall** (almost 2 cm in thickness; normal: 3-4 mm) compared to the left ventricle. This finding of severe right ventricular hypertrophy in a young woman with **progressive dyspnea** and sudden death is suggestive of **pulmonary arterial hypertension** (PAH).

Pulmonary hypertension can be caused by a number of conditions, including chronic lung disease and left heart failure. Pulmonary hypertension due to primary processes affecting the lung vasculature is referred to as PAH, a condition that most often affects women ages 20-40. PAH is characterized by intimal hyperplasia and fibrosis, medial hypertrophy, and formation of capillary tufts.

Long-standing pulmonary hypertension eventually leads to hypertrophy and/or dilation of the right ventricle (**cor pulmonale**). Patients typically present with progressive dyspnea, exertional angina, or syncope. As PAH progresses, signs of right-sided heart failure (eg, hepatomegaly, ascites, peripheral edema) can become prominent. The most common cause of death in patients with PAH is right heart failure with circulatory collapse and respiratory failure.

(Choices A and C) Aortic stenosis and essential hypertension cause left ventricular wall thickening and hypertrophy, not right ventricular hypertrophy.

(Choice B) Dilated cardiomyopathy typically increases the size of one or both ventricular chambers. This patient's ventricular cavities are small and normal in size, not enlarged. Moreover, the left ventricle is relatively normal in shape (elliptical, with a long axis approximately twice that of lateral short axis dimensions), which is not the case with left ventricular dilation.

(Choice D) Myocardial infarctions occur more frequently in older patients (age >65). Morphological changes in the myocardium include an area of reddish-blue discoloration that evolves into a yellow-tan discrete infarct with eventual formation of a white scar.

(Choice F) Wolff-Parkinson-White (WPW) syndrome should be suspected in any case of sudden cardiac death in an otherwise healthy young individual. WPW syndrome is an electrophysiological abnormality of atrioventricular (AV) node conduction that is discernible on histology as small accessory AV impulse conduction pathway(s) anatomically separate from the AV node. There are no consistent gross morphological changes to the ventricles

https://t.me/USMLEWorldStep1
Show all

medial hypertrophy, and formation of capillary tufts.

Long-standing pulmonary hypertension eventually leads to hypertrophy and/or dilation of the right ventricle (**cor pulmonale**). Patients typically present with progressive dyspnea, exertional angina, or syncope. As PAH progresses, signs of right-sided heart failure (eg, hepatomegaly, ascites, peripheral edema) can become prominent. The most common cause of death in patients with PAH is right heart failure with circulatory collapse and respiratory failure.

(Choices A and C) Aortic stenosis and essential hypertension cause left ventricular wall thickening and hypertrophy, not right ventricular hypertrophy.

(Choice B) Dilated cardiomyopathy typically increases the size of one or both ventricular chambers. This patient's ventricular cavities are small and normal in size, not enlarged. Moreover, the left ventricle is relatively normal in shape (elliptical, with a long axis approximately twice that of lateral short axis dimensions), which is not the case with left ventricular dilation.

(Choice D) Myocardial infarctions occur more frequently in older patients (age >65). Morphological changes in the myocardium include an area of reddish-blue discoloration that evolves into a yellow-tan discrete infarct with eventual formation of a white scar.

(Choice F) Wolff-Parkinson-White (WPW) syndrome should be suspected in any case of sudden cardiac death in an otherwise healthy young individual. WPW syndrome is an electrophysiological abnormality of atrioventricular (AV) node conduction that is discernible on histology as small accessory AV impulse conduction pathway(s) anatomically separate from the AV node. There are no consistent gross morphological changes to the ventricles.

Educational objective:
Pulmonary hypertension should be suspected in young and otherwise healthy patients with fatigue, progressive dyspnea, atypical chest pain, or unexplained syncope. Long-standing pulmonary hypertension leads to hypertrophy and/or dilation of the right ventricle (cor pulmonale).

References

- Management of pulmonary arterial hypertension

https://t.me/USMLEWorldStep1
Show all

D. Myocardial infarction (2%)

Exhibit Display

Classification of pulmonary hypertension	

Pulmonary arterial hypertension (group 1)	• Primary change in pulmonary arteries
	  ◦ Hereditary (eg, *BMPR2* mutation)
	  ◦ Connective tissue disease (eg, RA, SS)
	  ◦ HIV infection
	• Treatment targeted at endothelial dysfunction

Pulmonary hypertension (groups 2-5)	• Secondary to another disease process
	  ◦ Left-sided heart failure (group 2)
	  ◦ Chronic lung disease/hypoxia (group 3)
	  ◦ Chronic pulmonary thromboembolism (group 4)
	  ◦ Other (eg, sarcoidosis) (group 5)
	• Treatment aimed at underlying disease

RA = rheumatoid arthritis; **SS** = systemic sclerosis.	

New | Existing | My Notebook

https://t.me/USMLEWorldStep1

D. Myocardial infarction (2%)

Exhibit Display

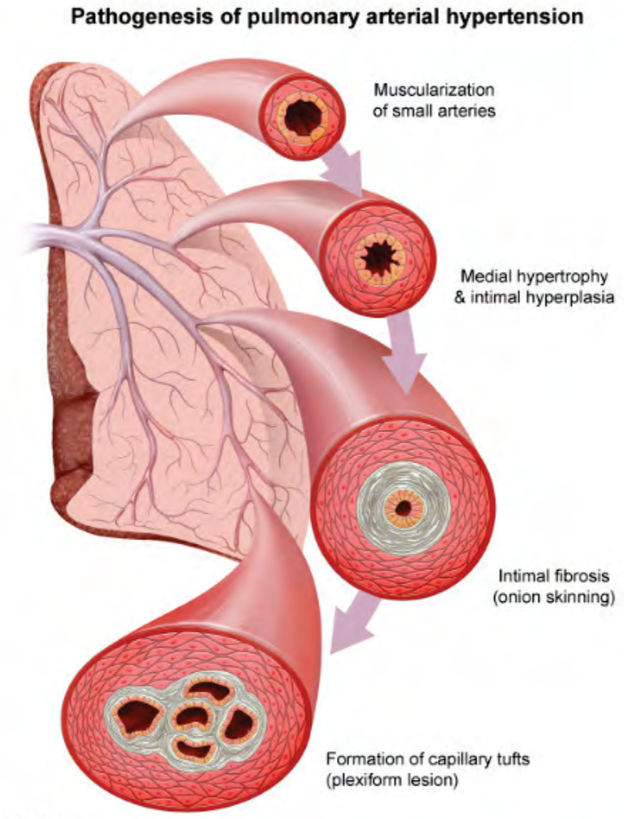

Zoom In | Zoom Out | Reset | New | Existing | My Notebook

(Choice B) Dilated cardiomyopathy typically increases the size of one or both ventricular chambers. This patient's

https://t.me/USMLEWorldStep1

Show all

A 32-year-old man comes to the hospital due to 1 week of progressive shortness of breath and cough. He also reports sharp right-sided chest pain that is worsened by deep inspiration. Examination reveals decreased tactile fremitus, dullness on percussion, and decreased breath sounds over the right lower lung. Chest x-ray shows consolidation of the right lower lobe and a right-sided effusion. A thoracentesis is performed, during which the needle is inserted along the upper border of the 10th rib at the right midaxillary line. Which of the following structures is most at risk of being injured as a result of the intervention?

- A. Hepatic veins
- B. Intercostal artery
- C. Intercostal nerve
- D. Right hepatic lobe
- E. Right lower lung lobe

Submit

https://t.me/USMLEWorldStep1

A 32-year-old man comes to the hospital due to 1 week of progressive shortness of breath and cough. He also reports sharp right-sided chest pain that is worsened by deep inspiration. Examination reveals decreased tactile fremitus, dullness on percussion, and decreased breath sounds over the right lower lung. Chest x-ray shows consolidation of the right lower lobe and a right-sided effusion. A thoracentesis is performed, during which the needle is inserted along the upper border of the 10th rib at the right midaxillary line. Which of the following structures is most at risk of being injured as a result of the intervention?

- ✗ A. Hepatic veins (1%)
- B. Intercostal artery (6%)
- C. Intercostal nerve (25%)
- ✓ D. Right hepatic lobe (44%)
- E. Right lower lung lobe (22%)

Incorrect
Correct answer
D

44%
Answered correctly

05 secs
Time Spent

2023
Version

Explanation

https://t.me/USMLEWorldStep1

Expl

Exhibit Display

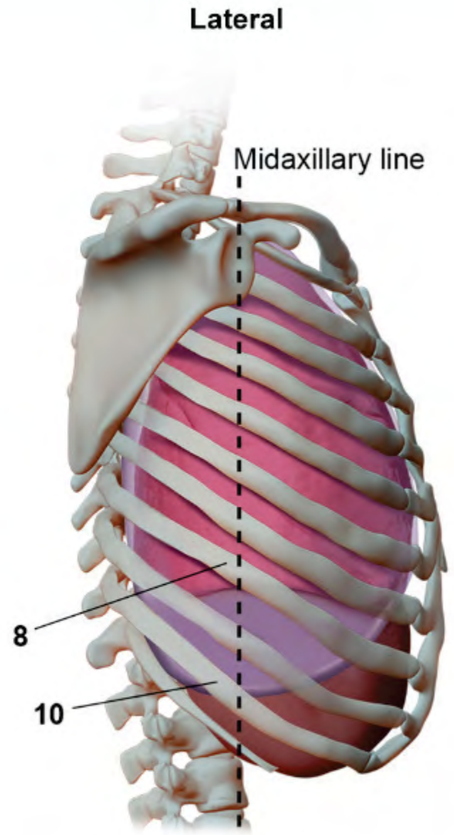

Zoom In | Zoom Out | Reset | New | Existing | My Notebook

©UWorld

The visceral pleura covers the surface of the lung, whereas the parietal pleura lines the inner surface of the chest wall and diaphragm. The parietal pleura generally **extends** approximately **2 ribs below** the inferior margin of the **lungs**. The potential space at the reflection of the costal pleura onto diaphragmatic pleura is called the costodiaphragmatic recess, where pleural fluid accumulates when the body is erect.

Thoracentesis is typically performed between the 6th and 8th ribs along the midclavicular line, the 8th and 10th ribs along the midaxillary line (above image), and the 10th and 12th ribs along the paravertebral line. This allows pleural fluid to be drained without risking lung injury (which can occur at higher insertion sites). However, insertion of a needle **below the 9th** rib still **risks penetrating abdominal structures**.

In this case, thoracentesis is being performed along the **upper border of the 10th rib** at the right midaxillary line, putting the patient at risk of **liver injury** if the needle is inserted too deep.

(Choice A) Hepatic veins are found deep in the liver parenchyma and are not likely to be injured during thoracentesis.

(Choices B and C) The intercostal vein, artery, and nerve lie in the subcostal groove along the lower border of the rib. Thoracentesis should be performed just above the upper border of the rib to prevent injury to the intercostal vessels.

(Choice E) The lower border of the right lung is located 2 intercostal spaces above the pleural border. Therefore, the lung is less likely to be injured by insertion of a needle into the 10th intercostal space at the midaxillary line.

Educational objective:
Thoracentesis should be performed below the 6th rib in the midclavicular line, the 8th rib along the midaxillary line, or the 10th rib along the paravertebral line in order to minimize the risk of lung injury. Insertion of a needle lower than 9th rib increases the risk of penetrating abdominal structures. The needle should also be inserted along the upper border of the rib to prevent injury to the intercostal vessels.

Anatomy	Pulmonary & Critical Care	Thoracentesis
Subject	System	Topic

Copyright © UWorld. All rights reserved.

https://t.me/USMLEWorldStep1

©UWorld

The visceral pleura covers the surface of the lung, whereas the parietal pleura lines the inner surface of the chest wall ar
lungs
costoc
Thora
ribs al
pleura
of a ne
In this
putting
(Choi
thorac
(Choi
rib. Th
vessel
(Choi
the lur
Educa
Thorac
or the
than 9
upper

Anatom
Subject

Exhibit Display

Topography of the lungs			
Lower border of pleura	**Midclavicular line**	**Midaxillary line**	**Paravertebral line**
Lungs (& visceral pleura)	6th rib	8th rib	10th rib
Parietal pleura	8th rib	10th rib Right - upper border Left - lower border	12th rib

New | Existing | My Notebook

Copyright © UWorld. All rights reserved.

https://t.me/USMLEWorldStep1

©UWorld

The visceral pleura covers the surface of the lung, whereas the parietal pleura lines the inner surface of the chest wall ar
lungs
costoc

Thora
ribs al
pleura
of a ne

In this
putting

(Choi
thorac

(Choi
rib. Th
vessel

(Choi
the lur

Educa
Thorac
or the
than 9
upper

Anatom
Subject

Exhibit Display

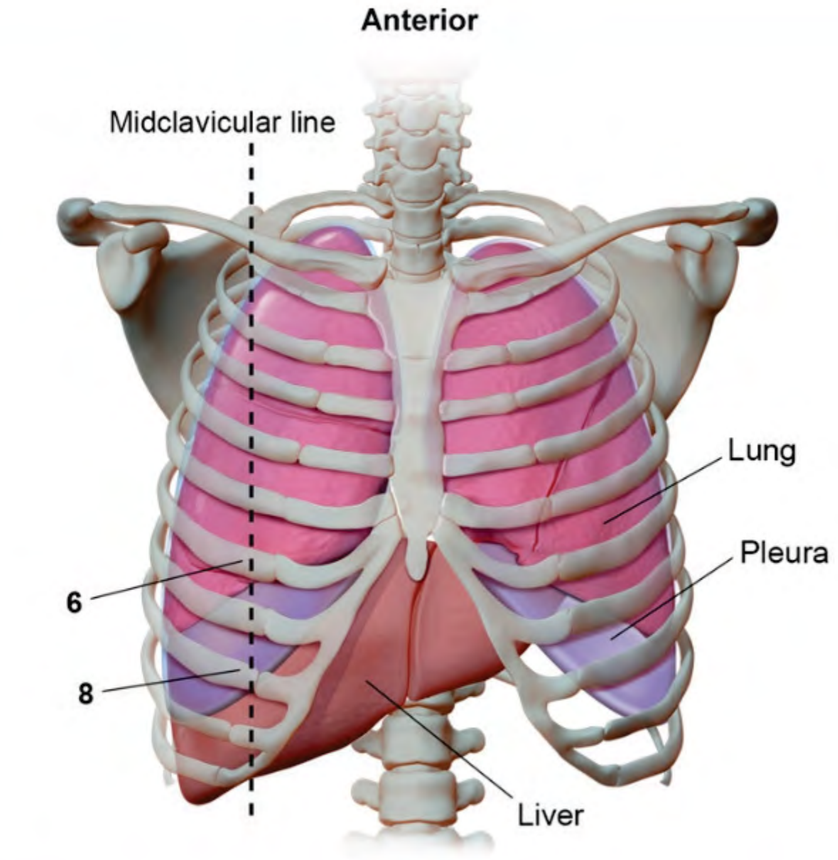

©UWorld

Zoom In | Zoom Out | Reset | New | Existing | My Notebook

Copyright © UWorld. All rights reserved.

https://t.me/USMLEWorldStep1

©UWorld

The visceral pleura covers the surface of the lung, whereas the parietal pleura lines the inner surface of the chest wall ar
lungs
costoc

Thora
ribs al
pleura
of a ne

In this
putting

(Choi
thorac

(Choi
rib. Th
vessel

(Choi
the lur

Educa
Thorac
or the
than 9
upper

Anatom
Subject

Copyright © UWorld. All rights reserved.

Exhibit Display

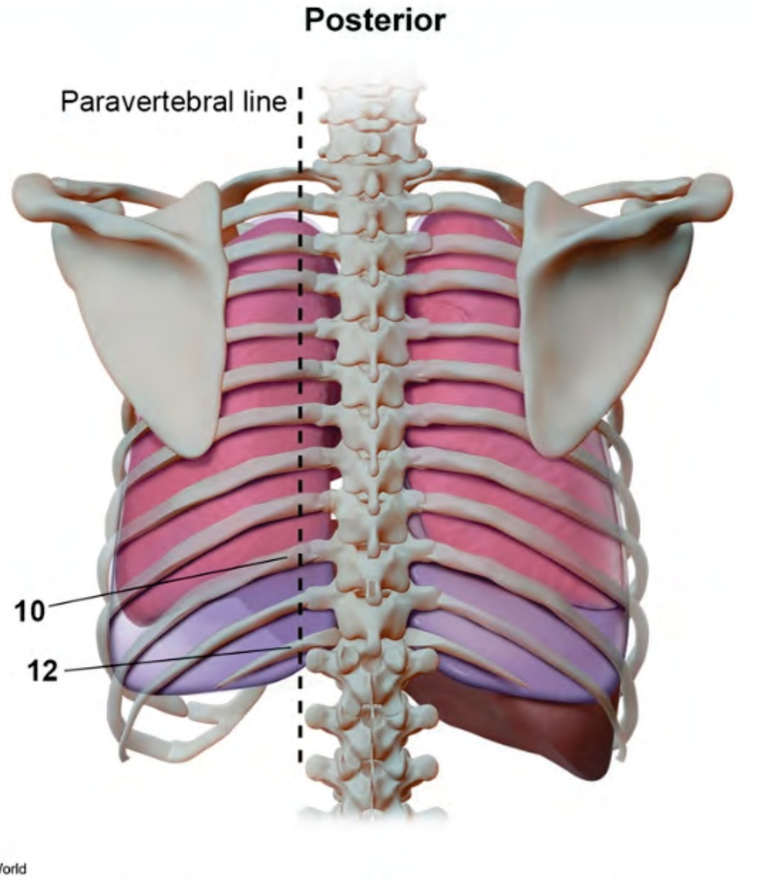

Zoom In | Zoom Out | Reset | New | Existing | My Notebook

https://t.me/USMLEWorldStep1

A 54-year-old man comes to the emergency department due to fevers, shaking chills, and cough productive of copious sputum. He began having fever, cough, and sharp chest pains 10 days ago and was prescribed oral antibiotics by his primary care physician after a chest x-ray revealed a right lower lobe infiltrate. The patient has not been taking the medication as advised, and his symptoms have progressively worsened. Temperature is 39 C (102.2 F), blood pressure is 114/62 mm Hg, and pulse is 116/min. Physical examination reveals crackles in the right lower lung. Repeat chest x-ray reveals a round density with an air-fluid level in the lower lobe of the right lung. Which of the following is the most important contributor to the observed lung lesion in this patient?

- A. Interferon-gamma production by CD4 lymphocytes
- B. Interleukin-12 secretion by dendritic cells
- C. Lysosomal content release by neutrophils
- D. Major basic protein release by eosinophils
- E. Transforming growth factor-beta secretion by macrophages

Submit

https://t.me/USMLEWorldStep1

A 54-year-old man comes to the emergency department due to fevers, shaking chills, and cough productive of copious sputum. He began having fever, cough, and sharp chest pains 10 days ago and was prescribed oral antibiotics by his primary care physician after a chest x-ray revealed a right lower lobe infiltrate. The patient has not been taking the medication as advised, and his symptoms have progressively worsened. Temperature is 39 C (102.2 F), blood pressure is 114/62 mm Hg, and pulse is 116/min. Physical examination reveals crackles in the right lower lung. Repeat chest x-ray reveals a round density with an air-fluid level in the lower lobe of the right lung. Which of the following is the most important contributor to the observed lung lesion in this patient?

- A. Interferon-gamma production by CD4 lymphocytes (30%)
- ✗ B. Interleukin-12 secretion by dendritic cells (3%)
- ✓ C. Lysosomal content release by neutrophils (47%)
- D. Major basic protein release by eosinophils (2%)
- E. Transforming growth factor-beta secretion by macrophages (16%)

Incorrect
Correct answer
C

47%
Answered correctly

03 secs
Time Spent

2023
Version

Explanation

Lung abscess is a necrotic infection of the pulmonary parenchyma that usually presents with several days of fever, cough productive of **copious sputum** (often foul-smelling), and chest x-ray evidence of cavitation with air-fluid level. Most cases are due to aspiration of anaerobic bacteria from the oropharynx, but lung abscess can also develop in the setting of untreated pneumonia.

Neutrophils are the key player in the formation of lung abscess. They are recruited from the systemic circulation by chemokines and are subsequently activated by microbial molecules (eg, lipopolysaccharide, peptidoglycan, bacterial DNA) and opsonizing factors (eg, IgG, complement) to phagocytize and destroy the pathogenic bacteria.

https://t.me/USMLEWorldStep1

Lung abscess is a necrotic infection of the pulmonary parenchyma that usually presents with several days of fever, cough productive of **copious sputum** (often foul-smelling), and chest x-ray evidence of cavitation with air-fluid level. Most cases are due to aspiration of anaerobic bacteria from the oropharynx, but lung abscess can also develop in the setting of untreated pneumonia.

Neutrophils are the key player in the formation of lung abscess. They are recruited from the systemic circulation by chemokines and are subsequently activated by microbial molecules (eg, lipopolysaccharide, peptidoglycan, bacterial DNA) and opsonizing factors (eg, IgG, complement) to phagocytize and destroy the pathogenic bacteria. Activated neutrophils also **release cytotoxic granules** (lysosomes) containing myeloperoxidase and other digestive enzymes that destroy extracellular bacteria and recruit additional immune components to the area. However, these enzymes also cause significant damage to the pulmonary parenchyma and can result in **liquefying necrosis** of lung tissue and (potentially) lung abscess.

(Choices A and B) Dendritic and other antigen-presenting cells release interleukin-12, which stimulates differentiation of Th1 helper cells and production of interferon-gamma by T-cells. Interferon-gamma activates macrophages, leading to the development of mature phagolysosomes capable of destroying phagocytosed bacteria. Macrophages are particularly important for the elimination of certain intracellular infections such as *Mycobacterium tuberculosis*. Although tuberculosis can be associated with pulmonary cavitation, the cavitations usually form in the upper lobes and generally take months to develop.

(Choice D) Major basic protein is the predominant component of eosinophilic granules and plays a crucial role in the elimination of parasites. Lung abscess formation is primarily mediated by neutrophils, not eosinophils.

(Choice E) Transforming growth factor-beta is secreted by inflammatory cells and results in the recruitment of fibroblasts and the deposition of connective tissue. This cytokine contributes to scar formation after injury and plays a role in the fibrosis seen with chronic inflammation.

Educational objective:
Abscess formation is largely driven by neutrophil recruitment and activation leading to the release of cytotoxic granules that kill bacteria but also cause liquefying necrosis of surrounding tissue.

References

https://t.me/USMLEWorldStep1

Correct answer
C

Answered correctly

Time Spent

Version

Exhibit Display

Expl

Lung
fever,
fluid le
develo

Neutr
by che
bacter
Activa
digesti
Howev
liquef

(Choi
differe
macro
bacter
Mycob
usuall

(Choi
the eli

(Choi
fibrobl
plays a role in the fibrosis seen with chronic inflammation.

Educational objective:

Lung abscess

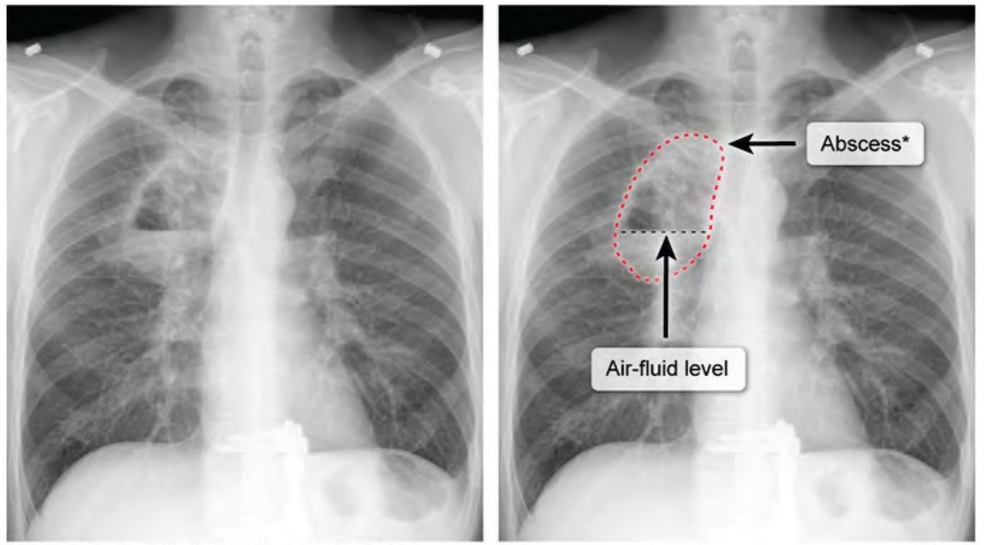

*Usually polymicrobial infection with anaerobic bacteria.

©UWorld

Zoom In
Zoom Out
Reset
New | Existing
My Notebook

https://t.me/USMLEWorldStep1

Correct answer
C

Answered correctly

Time Spent

Version

Exhibit Display

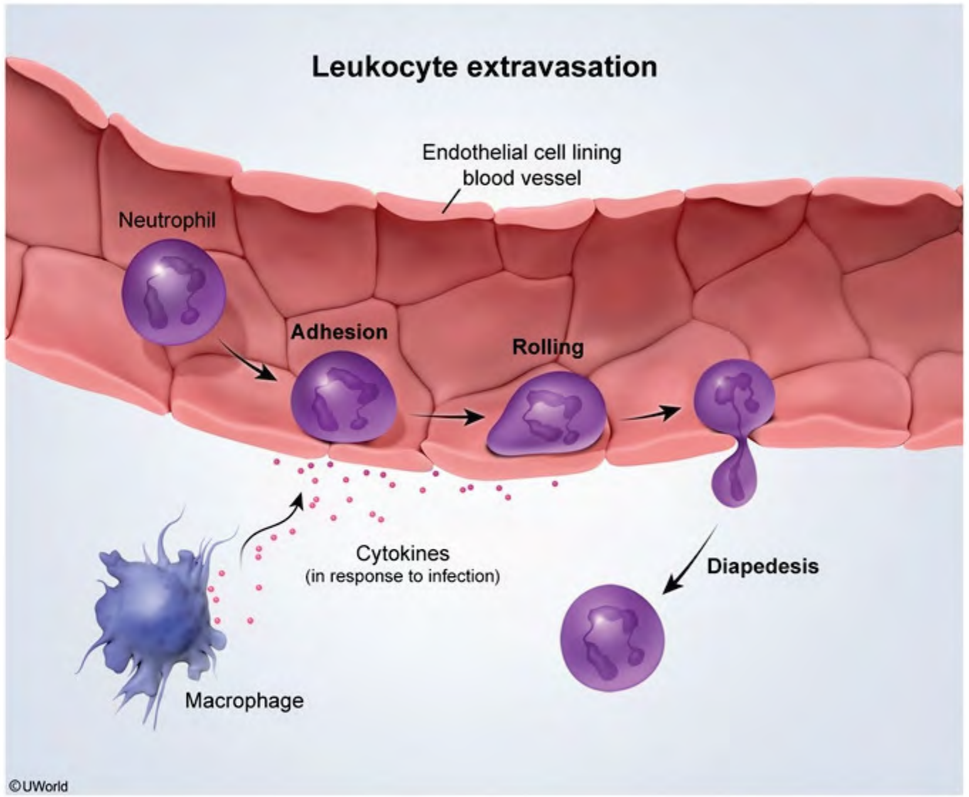

Zoom In | Zoom Out | Reset | New | Existing | My Notebook

Expl

Lung
fever,
fluid le
develo

Neutr
by che
bacter
Activa
digesti
Howev
liquef

(Choi
differe
macro
bacter
Mycob
usuall

(Choi
the eli

(Choi
fibrobl
plays a role in the fibrosis seen with chronic inflammation.

Educational objective:

https://t.me/USMLEWorldStep1

Correct answer
C

Answered correctly

Time Spent

Version

Exhibit Display

Expl

Lung
fever,
fluid le
develo

Neutr
by che
bacter
Activa
digesti
Howev
liquef

(Choi
differe
macro
bacter
Mycob
usuall

(Choi
the eli

(Choi
fibrobl
plays a role in the fibrosis seen with chronic inflammation.

Educational objective:

Pulmonary tuberculosis

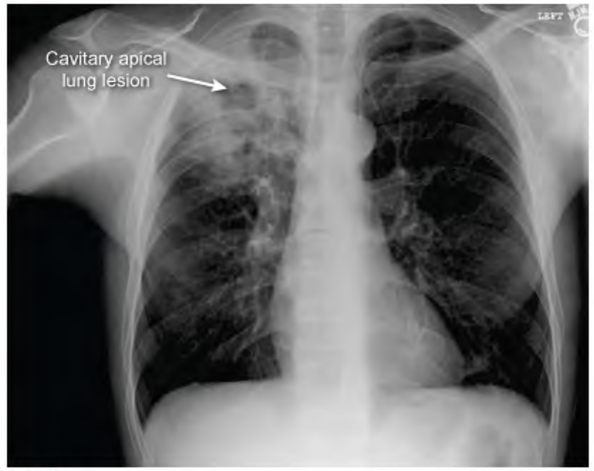

©UWorld

Zoom In | Zoom Out | Reset | New | Existing | My Notebook

https://t.me/USMLEWorldStep1

A 17-year-old girl is brought to the emergency department due to hemoptysis and severe respiratory distress. The patient has been on several oral antibiotics for pneumonia over the past week and has required numerous similar treatments in the past. She has been coughing up blood for the past day, which has become progressively worse. Temperature is 37.0 C (98.6 F), blood pressure is 90/60 mm Hg, pulse is 120/min, and respirations are 42/min. Pulmonary examination reveals diffusely reduced air flow, rales, and intercostal retractions. Copious red blood is produced while coughing during the examination and progresses rapidly. Despite aggressive management, the patient ultimately expires. An autopsy is performed and a gross lung specimen is shown in the image below:

Which of the following is the most likely etiology of this patient's hemoptysis?

- A. Bleeding from hypertrophied bronchial arteries
- B. Blood loss from hypertrophied pulmonary arteries
- C. Diffuse alveolar hemorrhage due to vasculitis
- D. Formation of a fistula between the tracheobronchial tree and aorta
- E. Hemorrhage from a highly vascular endobronchial tumor

Submit

https://t.me/USMLEWorldStep1

A 17-year-old girl is brought to the emergency department due to hemoptysis and severe respiratory distress. The
patien
treatm
Tempe
Pulmo
produc
patien

Exhibit Display

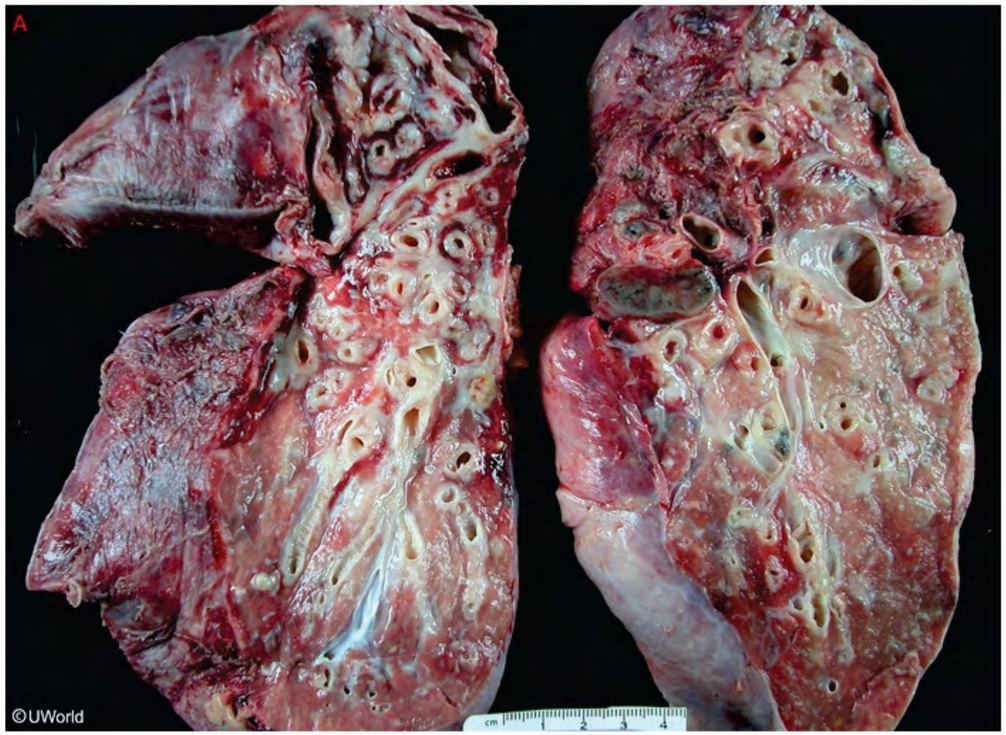

Zoom In | Zoom Out | Reset | New | Existing | My Notebook

Which

A. Bleeding from hypertrophied bronchial arteries

https://t.me/USMLEWorldStep1

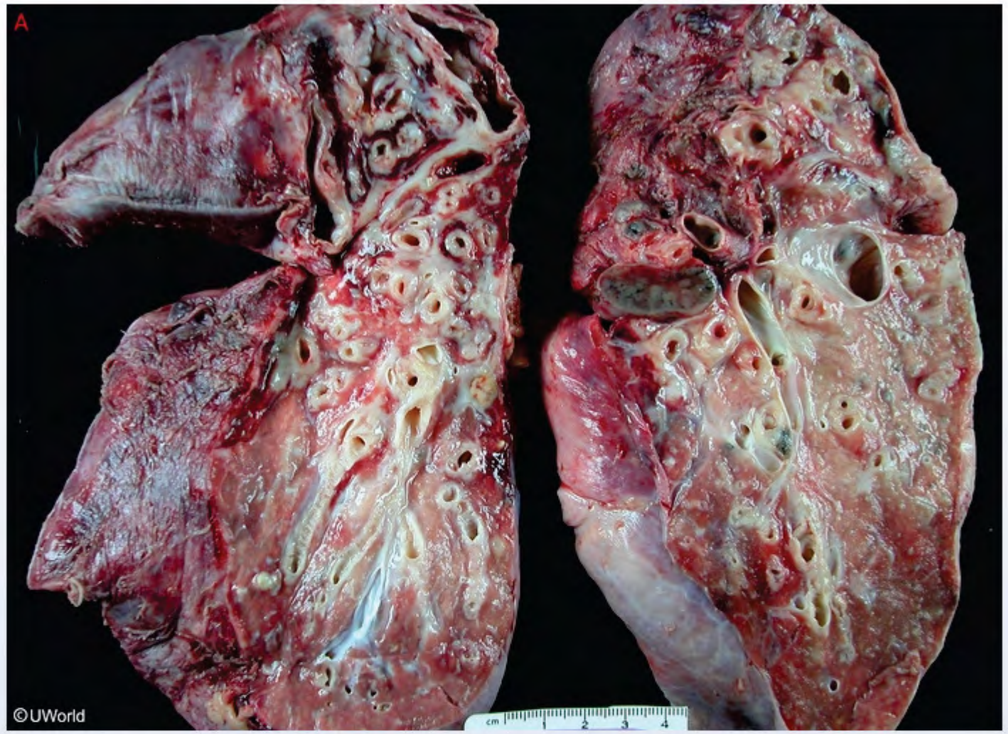

Which of the following is the most likely etiology of this patient's hemoptysis?

- A. Bleeding from hypertrophied bronchial arteries
- B. Blood loss from hypertrophied pulmonary arteries
- C. Diffuse alveolar hemorrhage due to vasculitis
- D. Formation of a fistula between the tracheobronchial tree and aorta
- E. Hemorrhage from a highly vascular endobronchial tumor

Submit

https://t.me/USMLEWorldStep1

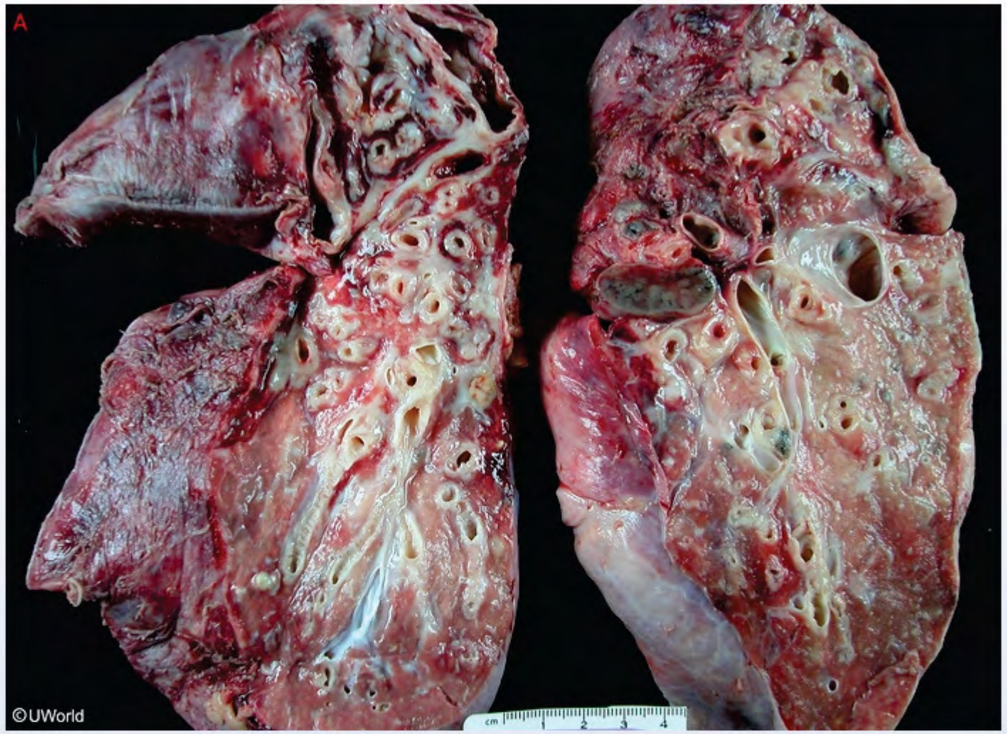

Which of the following is the most likely etiology of this patient's hemoptysis?

- ✓ A. Bleeding from hypertrophied bronchial arteries (37%)
- ✗ B. Blood loss from hypertrophied pulmonary arteries (14%)
- C. Diffuse alveolar hemorrhage due to vasculitis (29%)
- D. Formation of a fistula between the tracheobronchial tree and aorta (7%)
- E. Hemorrhage from a highly vascular endobronchial tumor (10%)

Incorrect
Correct answer
A

37%
Answered correctly

15 secs
Time Spent

2023
Version

https://t.me/USMLEWorldStep1

D. Formation of a fistula between the tracheobronchial tree and aorta (7%)

Exhibit Display

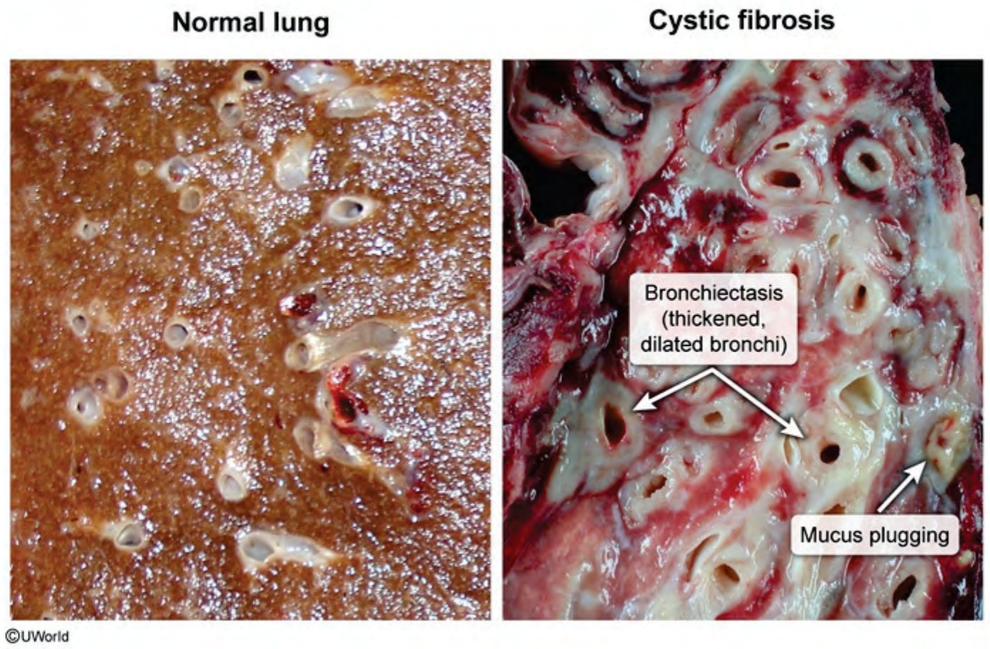

Zoom In | Zoom Out | Reset | New | Existing | My Notebook

This p
underl
widened airways and mucus plugging. Bronchiectasis is often associated with cystic fibrosis and immunodeficiency disorders, which causes chronic and recurrent **airway inflammation** and infection. This

https://t.me/USMLEWorldStep1

This patient's fatal, **massive hemoptysis** is suggestive of hemorrhage from the bronchial arteries. A common underlying cause of massive hemoptysis is **bronchiectasis**, as indicated by this patient's autopsy showing **thick, widened airways** and mucus plugging. Bronchiectasis is often associated with cystic fibrosis and immunodeficiency disorders, which causes chronic and recurrent **airway inflammation** and infection. This stimulates neovascularization and **bronchial artery hypertrophy**. The dilated, fragile, and tortuous vessels are in close proximity to the bronchioles and **prone to rupture** with increased airway pressure, such as during **coughing** (eg, acute pulmonary exacerbation).

Normally, blood supply to the lungs consists of the pulmonary circulation and the **bronchial circulation**. Pulmonary arteries deliver deoxygenated blood from the right ventricle to the lung parenchyma (ie, respiratory bronchioles to alveoli) to be oxygenated and returned to the heart; bronchial arteries arise from the aorta and supply the endobronchial tree (ie, bronchi to terminal bronchioles) with oxygenated blood. Although bleeding from the low-pressure pulmonary circulation is more common, hemorrhage from the **high-pressure**, systemic bronchial circulation is usually responsible for massive, **life-threatening** hemoptysis.

(Choices B and C) Hemoptysis due to hypertrophied pulmonary arteries or diffuse alveolar hemorrhage (ie, alveolar capillary vasculitis) involves bleeding from the pulmonary circulation, which is a low-pressure system that is unlikely to result in life-threatening hemoptysis. In addition, bronchiectasis is not associated with either condition.

(Choice D) A fistula between the tracheobronchial tree and aorta is usually fatal and can occur with chronic vascular or airway inflammation, typically due to an implanted medical device or stent. A fistula is an uncommon cause of hemoptysis that would not cause dilated bronchial walls on pathology.

(Choice E) Carcinoid tumors are highly vascular endobronchial tumors that commonly present with hemoptysis. However, autopsy would show a discrete mass (not bronchiectasis).

Educational objective:
Massive, life-threatening hemoptysis is typically due to hemorrhage from the high-pressure bronchial circulation. Bronchiectasis is a common etiology because chronic airway inflammation causes hypertrophied bronchial arteries that are prone to rupture with coughing.

https://t.me/USMLEWorldStep1

immunodeficiency disorders, which causes chronic and recurrent **airway inflammation** and infection. This

stimula

close

(eg, ac

Norma

Pulmo

bronch

supply

the lov

circula

(Choi

alveola

is unlik

conditi

(Choi

vascul

cause

(Choi

Howev

Educa

Massiv

Bronch

that ar

Refere

- The

Exhibit Display

Blood supply in the lungs

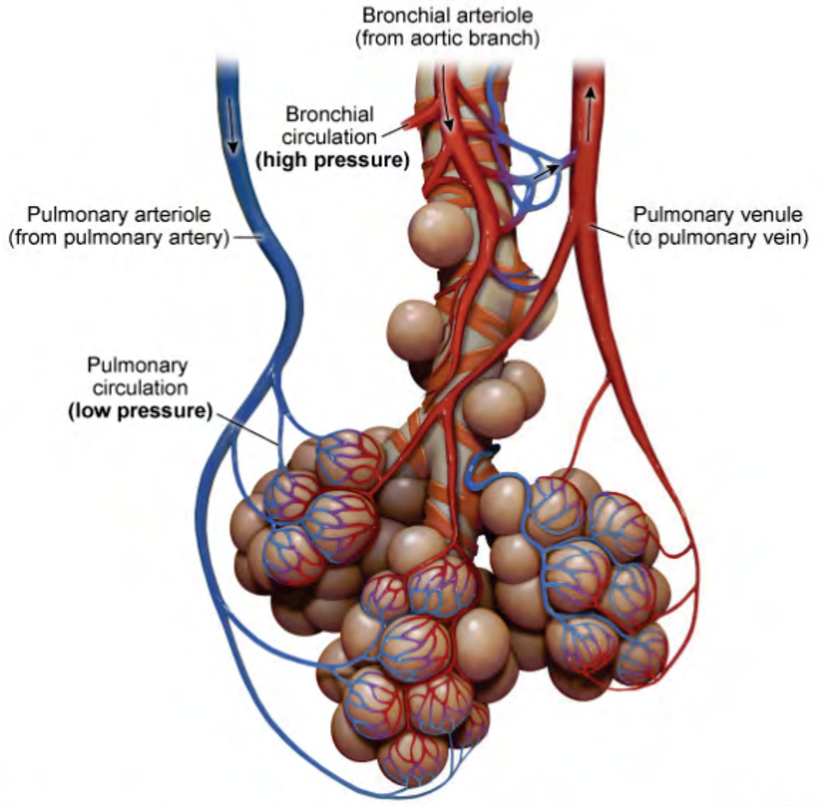

Zoom In | Zoom Out | Reset | New | Existing | My Notebook

https://t.me/USMLEWorldStep1

The concentrations of 2 substances in the amniotic fluid of pregnant women are graphed below.

The two curves most likely correspond to which of the following?

	Curve 1	Curve 2
A.	Albumin	Phosphatidylcholine
B.	Phosphatidylcholine	Sphingomyelin
C.	Phosphatidylglycerol	Phosphatidylcholine
D.	Sphingomyelin	Albumin
E.	Sphingomyelin	Phosphatidylglycerol

Submit

https://t.me/USMLEWorldStep1

The concentrations of 2 substances in the amniotic fluid of pregnant women are graphed below.

Exhibit Display

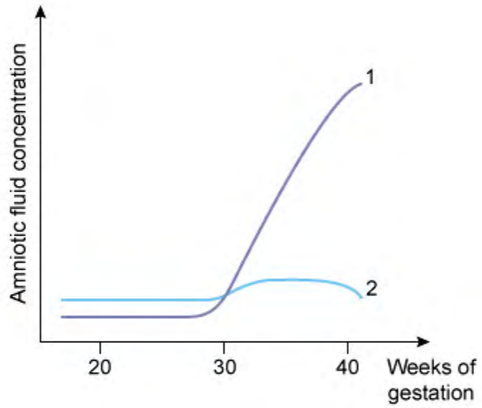

Zoom In Zoom Out Reset New | Existing My Notebook

The tw

Sub

https://t.me/USMLEWorldStep1

The concentrations of 2 substances in the amniotic fluid of pregnant women are graphed below.

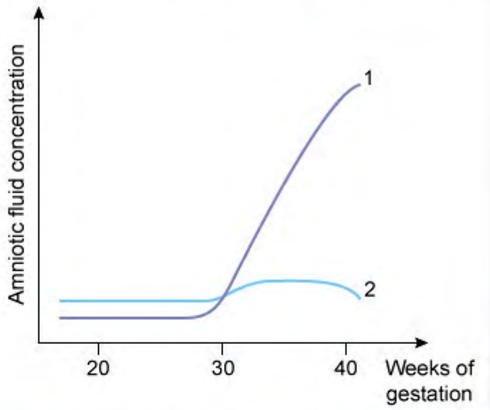

The two curves most likely correspond to which of the following?

	Curve 1	Curve 2	
✗ A.	Albumin	Phosphatidylcholine	(5%)
✓ B.	Phosphatidylcholine	Sphingomyelin	(66%)
C.	Phosphatidylglycerol	Phosphatidylcholine	(5%)
D.	Sphingomyelin	Albumin	(8%)
E.	Sphingomyelin	Phosphatidylglycerol	(14%)

Incorrect
Correct answer
B

66%
Answered correctly

08 secs
Time Spent

2023
Version

Explanation

https://t.me/USMLEWorldStep1

Fetal lung maturity assessment		
Test	**Physiology**	**Indicator of lung maturity**
Lamellar body count	• Store, transport & secrete surfactant • Increases >20 weeks gestation	• High lamellar body count
Lecithin*/sphingomyelin (L/S) ratio	• Lipid components of surfactant • Lecithin increases >30 weeks gestation	• L/S ratio >2
Phosphatidylglycerol	• Lipid component of surfactant • Increases >35 weeks gestation	• Presence of phosphatidylglycerol
*Also called phosphatidylcholine.		

Surfactant is an essential lipoprotein complex that **decreases alveolar surface tension** and facilitates alveolar expansion. Quantity and quality of surfactant increases throughout gestation and correlates with greater **fetal lung maturity**.

Assessment of fetal lung maturity is not often indicated because infants of gestational age <32 weeks can be presumed to have immature lungs while those who are full term typically do not. However, a subset of patients may benefit from an evaluation of lung maturity to weigh the risks and benefits to the mother and fetus of preterm delivery versus continuing a medically complex pregnancy.

Several markers of surfactant production and quality within amniotic fluid can help guide estimations of fetal lung maturity:

- Lamellar bodies are organelles within type 2 pneumocytes that store, transport, and secrete surfactant into the air-liquid interface of the alveoli. Increased lamellar body counts within the amniotic fluid are associated with increased surfactant production and lung maturity.
- Phosphatidylcholine (also known as lecithin [L]) and sphingomyelin (S) are lipid components of surfactant. They are produced in approximately equal amounts until the middle of the third trimester, at which point the

https://t.me/USMLEWorldStep1

Surfactant is an essential lipoprotein complex that **decreases alveolar surface tension** and facilitates alveolar expansion. Quantity and quality of surfactant increases throughout gestation and correlates with greater **fetal lung maturity**.

Assessment of fetal lung maturity is not often indicated because infants of gestational age <32 weeks can be presumed to have immature lungs while those who are full term typically do not. However, a subset of patients may benefit from an evaluation of lung maturity to weigh the risks and benefits to the mother and fetus of preterm delivery versus continuing a medically complex pregnancy.

Several markers of surfactant production and quality within amniotic fluid can help guide estimations of fetal lung maturity:

- Lamellar bodies are organelles within type 2 pneumocytes that store, transport, and secrete surfactant into the air-liquid interface of the alveoli. Increased lamellar body counts within the amniotic fluid are associated with increased surfactant production and lung maturity.
- Phosphatidylcholine (also known as lecithin [L]) and sphingomyelin (S) are lipid components of surfactant. They are produced in approximately equal amounts until the middle of the third trimester, at which point the **phosphatidylcholine concentration increases** sharply while the **sphingomyelin level remains low**, as represented by curves 1 and 2, respectively **(Choices C and E)**. This change in composition (L/S >2) later in gestation reflects production of a more **mature surfactant**.
- Phosphatidylglycerol is a phospholipid component of surfactant that increases late in the third trimester, and its presence suggests advanced lung maturity.

(Choices A and D) Amniotic fluid albumin concentrations normally decrease from mid-gestation to term. Albumin is not a clinically significant marker of fetal development.

Educational objective:
Fetal lung maturity correlates with increased quantity and improved quality of surfactant production. Amniotic fluid markers of maturity during late gestation include increased phosphatidylcholine (lecithin) and phosphatidylglycerol and low sphingomyelin.

References

https://t.me/USMLEWorldStep1

Phosphatidylglycerol	• Lipid component of surfactant • Increases >35 weeks gestation	• Presence of phosphatidylglycerol

*Al

Surfa
expan
matur

Asses
presur
may b
deliver

Severa
maturi

- L
  a
  in
- P
  T
  p
  re
  g
- P
  its

(Choi
is not

Educational objective:
Fetal lung maturity correlates with increased quantity and improved quality of surfactant production. Amniotic fluid

Exhibit Display

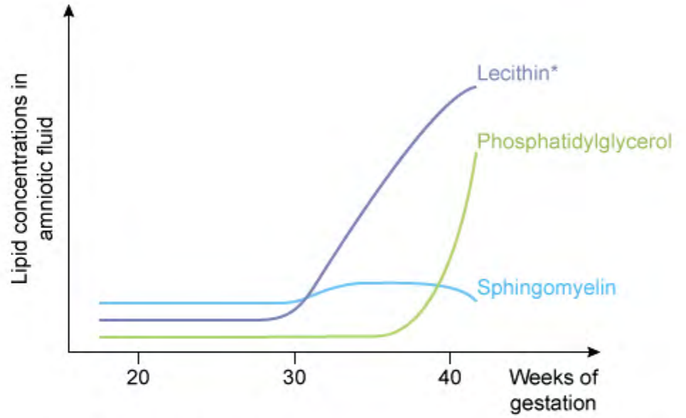

*Also known as phosphatidylcholine.

©UWorld

Zoom In | Zoom Out | Reset | New | Existing | My Notebook

https://t.me/USMLEWorldStep1

A pharmaceutical researcher is studying a new drug being developed for treatment of asthma that works by reversing irritant-induced bronchoconstriction. Laboratory guinea pigs are divided into 2 groups: a postvagotomy (complete transection of the vagus nerve) group and a normal study group. Both groups are exposed to irritants without receiving the study medication, and changes in bronchial diameters are recorded. Subsequently, both groups are exposed again to the irritants but are also given the study drug.

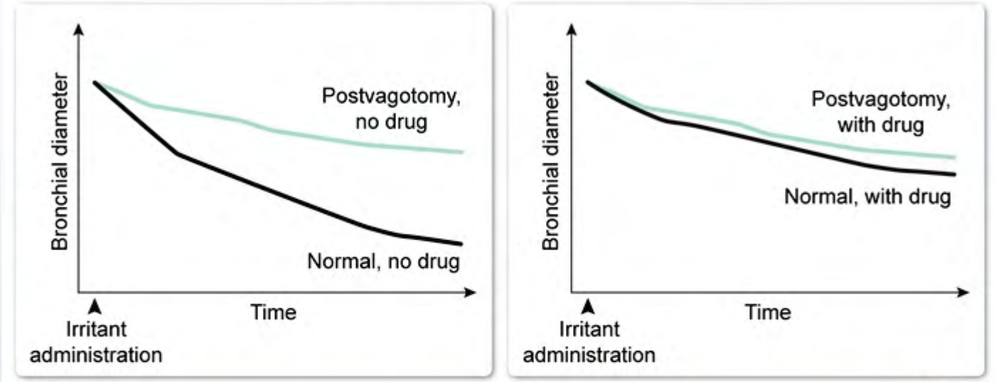

©UWorld

The study drug is most likely similar to which of the following medications?

- A. Albuterol
- B. Flunisolide
- C. Ipratropium
- D. Nifedipine
- E. Theophylline
- F. Zileuton

Submit

https://t.me/USMLEWorldStep1

A pharmaceutical researcher is studying a new drug being developed for treatment of asthma that works by
revers
(comp
withou
groups

The st

Submit

Exhibit Display

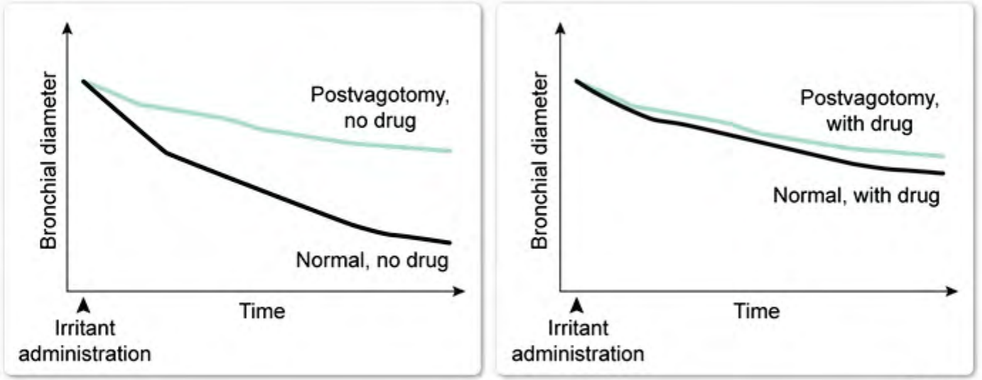

©UWorld

Zoom In | Zoom Out | Reset | New | Existing | My Notebook

https://t.me/USMLEWorldStep1

A pharmaceutical researcher is studying a new drug being developed for treatment of asthma that works by reversing irritant-induced bronchoconstriction. Laboratory guinea pigs are divided into 2 groups: a postvagotomy (complete transection of the vagus nerve) group and a normal study group. Both groups are exposed to irritants without receiving the study medication, and changes in bronchial diameters are recorded. Subsequently, both groups are exposed again to the irritants but are also given the study drug.

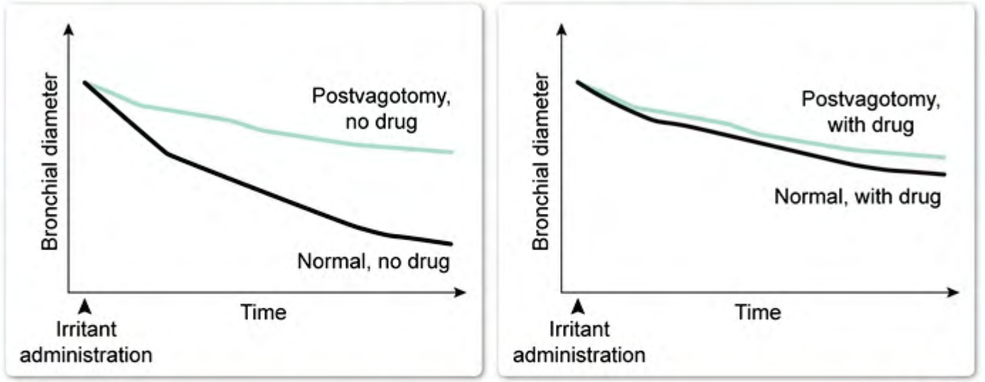

©UWorld

The study drug is most likely similar to which of the following medications?

- A. Albuterol (30%)
- ✗ B. Flunisolide (1%)
- ✓ C. Ipratropium (55%)
- D. Nifedipine (1%)
- E. Theophylline (7%)
- F. Zileuton (4%)

Incorrect
Correct answer
C

55%
Answered correctly

09 secs
Time Spent

2023
Version

https://t.me/USMLEWorldStep1

The figure on the left shows a decrease in bronchial diameter of normal lungs following administration of an irritant but minimal change in bronchial diameter of lungs without an intact vagus nerve. This implies that the bronchoconstriction is mediated by the **parasympathetic** nervous system. When the vagus nerve is stimulated (eg, via an inhaled irritant), **acetylcholine** is released and produces **bronchoconstriction** by acting on muscarinic receptors. The figure on the right demonstrates minimal decrease in bronchial diameter in normal lungs following administration of the irritant, suggesting that the study medication blocks the action of acetylcholine. **Ipratropium**, an anticholinergic and derivative of atropine, has this effect.

Ipratropium and other anticholinergic drugs used for **obstructive lung disease** (eg, tiotropium) are less potent bronchodilators than beta-2 adrenergic agonists but can enhance the bronchodilatory effect of these agents. In addition, ipratropium and similar drugs block the parasympathetic stimulation of tracheobronchial submucosal glands, decreasing mucus secretion and providing further benefit in treating asthma and chronic obstructive pulmonary disease (COPD).

(Choice A) Albuterol is a short-acting selective beta-2 adrenergic agonist that is the first-line treatment for asthma and COPD. The bronchodilatory effects of albuterol are independent of parasympathetic innervation.

(Choice B) Inhaled glucocorticoids (eg, flunisolide) have potent local anti-inflammatory effects in the airway and are used in the treatment of persistent asthma and COPD with frequent exacerbations.

(Choice D) Nifedipine causes bronchodilation by blocking calcium influx into bronchial smooth muscle cells; however, the drug is generally not used in treating obstructive lung disease.

(Choice E) Methylxanthines, such as theophylline and aminophylline, cause bronchodilation by blocking phosphodiesterase activity, thereby increasing the intracellular concentration of cyclic AMP.

(Choice F) Zileuton inhibits 5-lipoxygenase and thereby decreases the production of leukotrienes to reduce bronchoconstriction and improve asthma symptoms.

Educational objective:
Ipratropium, an anticholinergic agent and derivative of atropine, treats obstructive lung disease by blocking acetylcholine at muscarinic receptors, which prevents bronchoconstriction and reduces mucus secretion from tracheobronchial submucosal glands.

https://t.me/USMLEWorldStep1

Respiratory physiologists conduct a study to assess the airway resistance of the lower respiratory tract in healthy volunteers. During the experiment, they measure total cross sectional airflow resistance as it changes between each airway generation. Which of the following graphs is most likely to be observed in this study?

A.

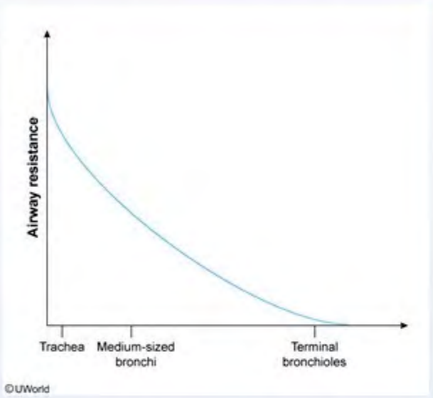

B.

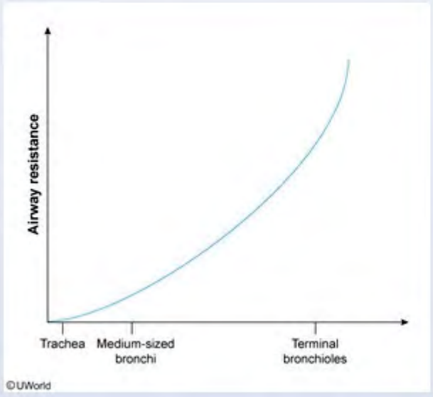

C.

https://t.me/USMLEWorldStep1

C.

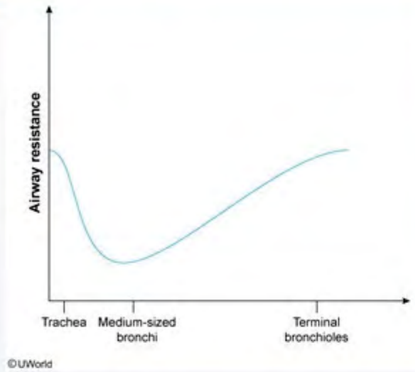

D.

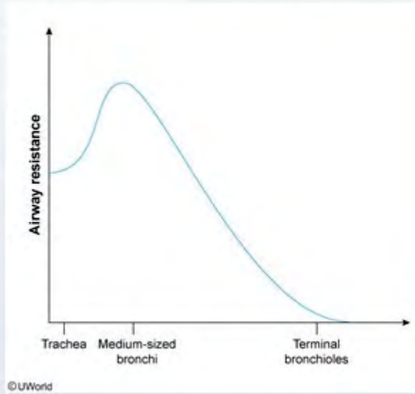

E.

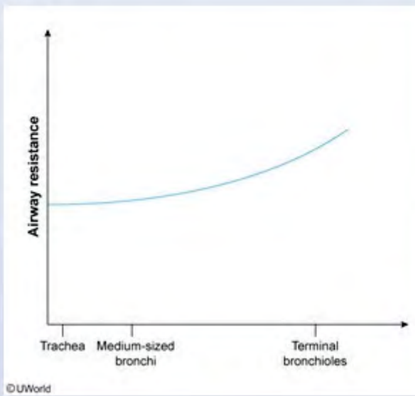

https://t.me/USMLEWorldStep1

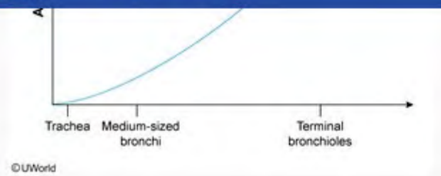

C. (6%)

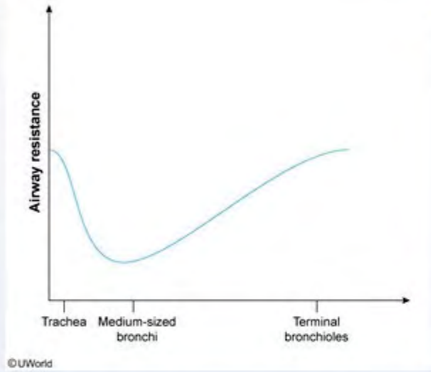

✓ D. (49%)

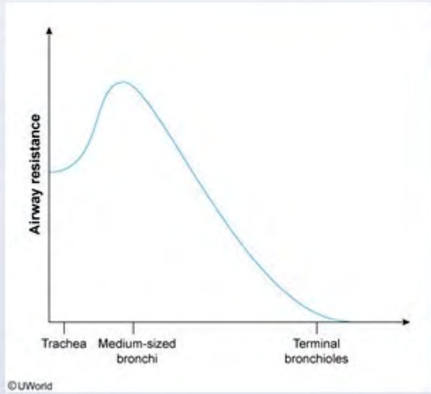

✗ E. (10%)

https://t.me/USMLEWorldStep1

Exhibit Display

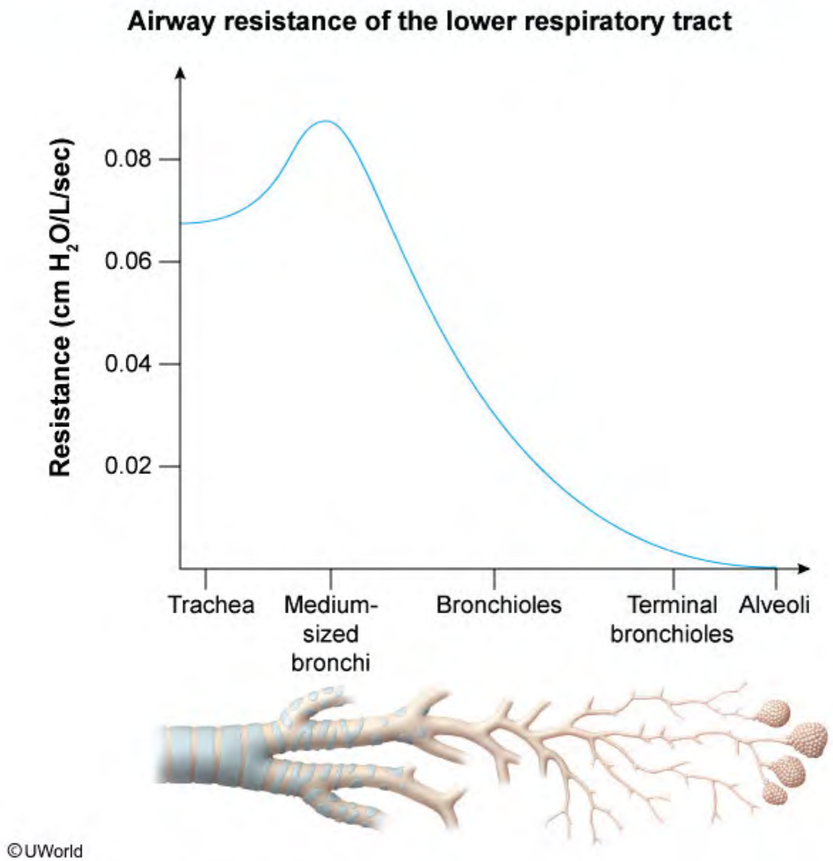

Zoom In | Zoom Out | Reset | New | Existing | My Notebook

sized bronchi

bronchioles

https://t.me/USMLEWorldStep1

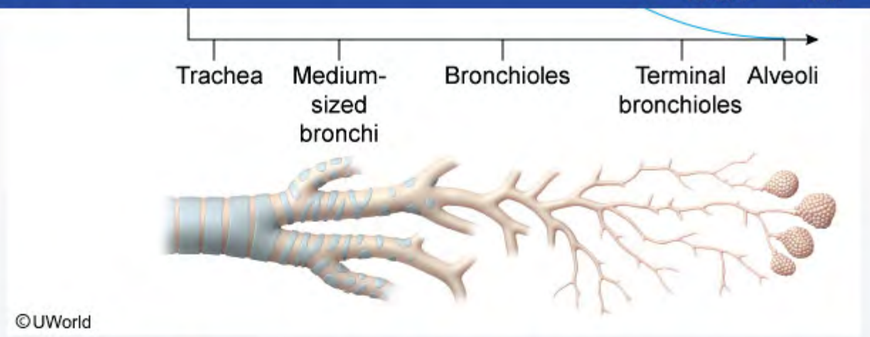

The upper respiratory tract (eg, nasal passages, mouth, pharynx, larynx) accounts for about half of total airway resistance. The remainder comes from the **lower respiratory tract**, which begins at the trachea and proceeds through roughly 23 generations of airway bifurcation before reaching the alveoli (ie, the trachea divides into approximately 8×10^6 [2^{23}] smaller airways before reaching the alveoli). Because the **airways** at each level of the lower respiratory tract are **arranged in parallel**, airway resistance is determined by the total cross-sectional area of all the airways at that level; the **greater the total cross-sectional area**, the **lower the airway resistance**.

The cross-sectional area of the trachea is relatively small (~3.5 cm^2), but the total area of the **first few generations of bronchi** is even smaller, leading to an **initial small increase in resistance** from the trachea to the bronchi. However, from the medium-sized bronchi on, the total cross-sectional area at each level of the lower respiratory tract increases in step-wise fashion, creating a **progressive decline in airway resistance**. By the time the alveoli are reached, the total cross-sectional area is massive (~5×10^5 cm^2) and airway resistance is essentially zero.

Educational objective:
The airway resistance at each level of the lower respiratory tract is inversely related to the total cross-sectional area of all the airways at that level. Airway resistance is high in the trachea and reaches a peak in the medium-sized bronchi, where total cross-sectional area is at a minimum. Airway resistance then progressively decreases as total cross-sectional area increases through the smaller bronchioles, terminal bronchioles, and alveoli.

Physiology	Pulmonary & Critical Care	Respiratory physiology
Subject	System	Topic

Copyright © UWorld. All rights reserved.

https://t.me/USMLEWorldStep1

A 56-year-old woman is brought to the emergency department due to a 2-day history of high fever, headache, mild confusion, and dry cough. She also has mild abdominal discomfort and watery diarrhea. The patient recently returned from a cruise to Hawaii. Her other medical problems include hypertension and hyperlipidemia. She has smoked 1 pack of cigarettes daily for over 20 years. Her temperature is 40 C (104 F), blood pressure is 104/63 mm Hg, pulse is 85/min, and respirations are 24/min. Lung examination reveals lower lobe crackles with no wheezing. Her abdomen is soft, non-distended, and non-tender. Chest x-ray shows bilateral lower lobe interstitial infiltrates. Which of the following additional findings is most likely to be present in this patient?

- A. Elevated circulating eosinophil count
- B. Gram-positive diplococci on sputum Gram stain
- C. Low serum sodium
- D. Positive polymerase chain reaction assay for influenza A RNA
- E. Presence of cold agglutinins

Submit

https://t.me/USMLEWorldStep1

A 56-year-old woman is brought to the emergency department due to a 2-day history of high fever, headache, mild confusion, and dry cough. She also has mild abdominal discomfort and watery diarrhea. The patient recently returned from a cruise to Hawaii. Her other medical problems include hypertension and hyperlipidemia. She has smoked 1 pack of cigarettes daily for over 20 years. Her temperature is 40 C (104 F), blood pressure is 104/63 mm Hg, pulse is 85/min, and respirations are 24/min. Lung examination reveals lower lobe crackles with no wheezing. Her abdomen is soft, non-distended, and non-tender. Chest x-ray shows bilateral lower lobe interstitial infiltrates. Which of the following additional findings is most likely to be present in this patient?

- ✗ A. Elevated circulating eosinophil count (11%)
- B. Gram-positive diplococci on sputum Gram stain (13%)
- ✓ C. Low serum sodium (47%)
- D. Positive polymerase chain reaction assay for influenza A RNA (10%)
- E. Presence of cold agglutinins (17%)

Incorrect
Correct answer
C

47%
Answered correctly

07 secs
Time Spent

2023
Version

Explanation

Characteristics of *Legionella* pneumonia	
Exposure to contaminated water	• Recent travel (especially cruise/hotel visit) • Hospital/nursing home stay
Clinical findings	• Fever >39 C (102.2 F) • Bradycardia relative to high fever • Headache & confusion

https://t.me/USMLEWorldStep1

Characteristics of *Legionella* pneumonia	
Exposure to contaminated water	• Recent travel (especially cruise/hotel visit) • Hospital/nursing home stay
Clinical findings	• Fever >39 C (102.2 F) • Bradycardia relative to high fever • Headache & confusion • Watery diarrhea
Laboratory findings	• Hyponatremia • Sputum Gram stain shows many neutrophils but few or no organisms
Diagnosis	• Culture of organism on BCYE • *Legionella* urine antigen test
BCYE = buffered charcoal yeast extract.	

Legionellosis can be divided into Pontiac fever (an acute, flu-like, self-limited disease) and the more common Legionnaires' disease. Legionnaires' disease should be suspected in patients with recent exposure to **contaminated water** (sporadic cases or common-source outbreaks in cruise ships, spas, hospitals, or air-conditioned hotels), radiographic evidence of pneumonia (typically patchy infiltrates that may progress to consolidation), **high fever** (>39 C [102.2 F]) sometimes associated with **relative bradycardia**, **neurologic** symptoms (eg, confusion, headache), and **gastrointestinal** (GI) symptoms (eg, diarrhea). Risk groups include the elderly or immunocompromised, smokers, and patients with chronic obstructive pulmonary disease.

Because *Legionella pneumophila* is a faintly staining gram-negative bacillus that is facultatively intracellular, Gram stain typically shows many neutrophils but few or no organisms. *Legionella* is often diagnosed by urinary antigen testing; it grows on selective medium (buffered charcoal yeast extract [BCYE]). The most common laboratory abnormality is **hyponatremia**, frequently associated with *Legionella* but not other causes of pneumonia. The

https://t.me/USMLEWorldStep1

Legionellosis can be divided into Pontiac fever (an acute, flu-like, self-limited disease) and the more common Legionnaires' disease. Legionnaires' disease should be suspected in patients with recent exposure to **contaminated water** (sporadic cases or common-source outbreaks in cruise ships, spas, hospitals, or air-conditioned hotels), radiographic evidence of pneumonia (typically patchy infiltrates that may progress to consolidation), **high fever** (>39 C [102.2 F]) sometimes associated with **relative bradycardia**, **neurologic** symptoms (eg, confusion, headache), and **gastrointestinal** (GI) symptoms (eg, diarrhea). Risk groups include the elderly or immunocompromised, smokers, and patients with chronic obstructive pulmonary disease.

Because *Legionella pneumophila* is a faintly staining gram-negative bacillus that is facultatively intracellular, Gram stain typically shows many neutrophils but few or no organisms. *Legionella* is often diagnosed by urinary antigen testing; it grows on selective medium (buffered charcoal yeast extract [BCYE]). The most common laboratory abnormality is **hyponatremia**, frequently associated with *Legionella* but not other causes of pneumonia. The hyponatremia may be related to inappropriate antidiuretic hormone secretion and/or renal tubulointerstitial disease impairing sodium reabsorption (possibly due to either direct effect of *Legionella*, cytokines, or natriuretic peptides). Elevated transaminases are also common.

(Choice A) This patient does not have asthma, making allergic bronchopulmonary aspergillosis (pulmonary infiltrates/bronchiectasis with eosinophilia and elevated IgE and anti-*Aspergillus* antibody titers) unlikely. Some helminthic infections are associated with pulmonary infiltrates and eosinophilia (Löffler). However, high fever, neurologic symptoms, and concurrent GI and pulmonary symptoms are unusual.

(Choices B and D) *Streptococcus pneumoniae* (gram-positive diplococci on Gram stain) is the most common overall cause of community-acquired pneumonia. Lobar consolidation is classic. Patients with influenza A typically experience the abrupt onset of fever, headache, myalgias, and malaise that gradually improve over 2-5 days, with a subset developing secondary bacterial pneumonia (exacerbation of fever and respiratory symptoms after initial improvement). However, dry cough, GI and neurologic symptoms, and interstitial infiltrates in the setting of a recent cruise make *Legionella* more likely.

(Choice E) *Mycoplasma pneumoniae* infection can result in cold agglutinin formation. However, *M pneumoniae* predominantly affects young adults and is more likely to cause tracheobronchitis than pneumonia. Clinical presentation is typically mild with bilateral infiltrates on chest x-ray appearing more severe than expected based on

https://t.me/USMLEWorldStep1

elderly or immunocompromised, smokers, and patients with chronic obstructive pulmonary disease.

Because *Legionella pneumophila* is a faintly staining gram-negative bacillus that is facultatively intracellular, Gram stain typically shows many neutrophils but few or no organisms. *Legionella* is often diagnosed by urinary antigen testing; it grows on selective medium (buffered charcoal yeast extract [BCYE]). The most common laboratory abnormality is **hyponatremia**, frequently associated with *Legionella* but not other causes of pneumonia. The hyponatremia may be related to inappropriate antidiuretic hormone secretion and/or renal tubulointerstitial disease impairing sodium reabsorption (possibly due to either direct effect of *Legionella*, cytokines, or natriuretic peptides). Elevated transaminases are also common.

(Choice A) This patient does not have asthma, making allergic bronchopulmonary aspergillosis (pulmonary infiltrates/bronchiectasis with eosinophilia and elevated IgE and anti-*Aspergillus* antibody titers) unlikely. Some helminthic infections are associated with pulmonary infiltrates and eosinophilia (Löffler). However, high fever, neurologic symptoms, and concurrent GI and pulmonary symptoms are unusual.

(Choices B and D) *Streptococcus pneumoniae* (gram-positive diplococci on Gram stain) is the most common overall cause of community-acquired pneumonia. Lobar consolidation is classic. Patients with influenza A typically experience the abrupt onset of fever, headache, myalgias, and malaise that gradually improve over 2-5 days, with a subset developing secondary bacterial pneumonia (exacerbation of fever and respiratory symptoms after initial improvement). However, dry cough, GI and neurologic symptoms, and interstitial infiltrates in the setting of a recent cruise make *Legionella* more likely.

(Choice E) *Mycoplasma pneumoniae* infection can result in cold agglutinin formation. However, *M pneumoniae* predominantly affects young adults and is more likely to cause tracheobronchitis than pneumonia. Clinical presentation is typically mild with bilateral infiltrates on chest x-ray appearing more severe than expected based on clinical findings.

Educational objective:
Legionella pneumophila is a facultative intracellular gram-negative bacillus that can cause a systemic infection. Symptoms frequently include high fever, cough, confusion, and diarrhea. The most common laboratory abnormality seen with *Legionella* pneumonia is hyponatremia, and sputum Gram stain often shows many neutrophils but few or no organisms.

https://t.me/USMLEWorldStep1

A 62-year-old man comes to the clinic due to a 6-month history of progressive exertional dyspnea. The patient has an occasional cough but has no palpitations, orthopnea, chest pain, or lower extremity swelling. Past medical history is insignificant. He works as an attorney, does not use tobacco, and drinks alcohol only on social occasions. His symptoms continue to progress, and the patient dies of respiratory failure 3 years after the initial clinic visit. Autopsy findings include heterogenous lung parenchyma with predominantly subpleural areas of dense collagen deposition, lymphocyte infiltration, and fibroblast proliferation intermixed with areas of normal lung tissue. Which of the following is the most likely diagnosis?

- A. Alpha-1 antitrypsin deficiency
- B. Asbestosis
- C. Chronic bronchitis
- D. Chronic hypersensitivity pneumonitis
- E. Cryptogenic organizing pneumonia
- F. Idiopathic pulmonary fibrosis

Submit

https://t.me/USMLEWorldStep1

A 62-year-old man comes to the clinic due to a 6-month history of progressive exertional dyspnea. The patient has an occasional cough but has no palpitations, orthopnea, chest pain, or lower extremity swelling. Past medical history is insignificant. He works as an attorney, does not use tobacco, and drinks alcohol only on social occasions. His symptoms continue to progress, and the patient dies of respiratory failure 3 years after the initial clinic visit. Autopsy findings include heterogenous lung parenchyma with predominantly subpleural areas of dense collagen deposition, lymphocyte infiltration, and fibroblast proliferation intermixed with areas of normal lung tissue. Which of the following is the most likely diagnosis?

- A. Alpha-1 antitrypsin deficiency (2%)
- ✗ B. Asbestosis (11%)
- C. Chronic bronchitis (0%)
- D. Chronic hypersensitivity pneumonitis (5%)
- E. Cryptogenic organizing pneumonia (5%)
- ✓ F. Idiopathic pulmonary fibrosis (74%)

Incorrect
Correct answer
F

74%
Answered correctly

37 secs
Time Spent

2023
Version

Explanation

The described histopathologic findings are consistent with **idiopathic pulmonary fibrosis** (IPF). Microscopic findings are heterogeneous and include:

- **Patchy** areas of interstitial fibrosis with chronic interstitial inflammation intermixed with normal lung
- Early lesions consist of **fibroblastic foci** that become increasingly collagenous with time
- **Honeycomb pattern** with fibrotic walls and cystic spaces lined by bronchiolar epithelium
- Fibrosis most prominent in the **subpleural** and perilobular regions

https://t.me/USMLEWorldStep1

The described histopathologic findings are consistent with **idiopathic pulmonary fibrosis** (IPF). Microscopic findings are heterogeneous and include:

- **Patchy** areas of interstitial fibrosis with chronic interstitial inflammation intermixed with normal lung
- Early lesions consist of **fibroblastic foci** that become increasingly collagenous with time
- **Honeycomb pattern** with fibrotic walls and cystic spaces lined by bronchiolar epithelium
- Fibrosis most prominent in the **subpleural** and perilobular regions

Importantly, there should also be no other findings consistent with another disease process (eg, granulomas).

The precise etiology of IPF is unclear, but risk factors include cigarette smoking, environmental pollutants, chronic aspiration, older age, and certain genetic factors (eg, telomerase mutations). Patients typically have dyspnea, nonproductive cough, finger clubbing, and inspiratory crackles. The onset is insidious, prognosis is poor, and no curative treatment exists.

(Choice A) Alpha-1 antitrypsin deficiency causes alveolar wall destruction, resulting in panacinar emphysema. Patients tend to present at a young age with dyspnea, productive cough, and wheezing. Emphysematous changes (eg, bullae) are seen predominantly at the lung bases, and histologic findings include large alveoli with thin septa.

(Choice B) Asbestosis usually occurs in patients with occupational exposures (eg, shipbuilding). Microscopy may show fibrosis and honeycombing, but asbestosis can be differentiated from IPF by the presence of asbestos bodies (brown, beaded rods coated with iron-containing material) and ferruginous bodies (inorganic particles with a similar ferrous material). Pleural plaques are also common.

(Choice C) Chronic bronchitis causes significant sputum production over a prolonged period and is often related to smoking. Histologic findings include mild lymphocytic infiltrates and mucous gland hyperplasia with mucus-filled bronchioles.

(Choice D) Chronic hypersensitivity pneumonitis is due to repeated exposure to an inciting agent (eg, birds, fungi, chemicals). Cough and dyspnea occur shortly after exposure to the antigen and may progress to respiratory failure. Histologic findings include noncaseating granulomas, peribronchiolar fibrosis, and patchy lymphocytic infiltrates.

https://t.me/USMLEWorldStep1

Importantly, there should also be no other findings consistent with another disease process (eg, granulomas).

The precise etiology of IPF is unclear, but risk factors include cigarette smoking, environmental pollutants, chronic aspiration, older age, and certain genetic factors (eg, telomerase mutations). Patients typically have dyspnea, nonproductive cough, finger clubbing, and inspiratory crackles. The onset is insidious, prognosis is poor, and no curative treatment exists.

(Choice A) Alpha-1 antitrypsin deficiency causes alveolar wall destruction, resulting in panacinar emphysema. Patients tend to present at a young age with dyspnea, productive cough, and wheezing. Emphysematous changes (eg, bullae) are seen predominantly at the lung bases, and histologic findings include large alveoli with thin septa.

(Choice B) Asbestosis usually occurs in patients with occupational exposures (eg, shipbuilding). Microscopy may show fibrosis and honeycombing, but asbestosis can be differentiated from IPF by the presence of asbestos bodies (brown, beaded rods coated with iron-containing material) and ferruginous bodies (inorganic particles with a similar ferrous material). Pleural plaques are also common.

(Choice C) Chronic bronchitis causes significant sputum production over a prolonged period and is often related to smoking. Histologic findings include mild lymphocytic infiltrates and mucous gland hyperplasia with mucus-filled bronchioles.

(Choice D) Chronic hypersensitivity pneumonitis is due to repeated exposure to an inciting agent (eg, birds, fungi, chemicals). Cough and dyspnea occur shortly after exposure to the antigen and may progress to respiratory failure. Histologic findings include noncaseating granulomas, peribronchiolar fibrosis, and patchy lymphocytic infiltrates.

(Choice E) Cryptogenic organizing pneumonia is another interstitial lung disease of unclear etiology that typically presents with dry cough, dyspnea, and fatigue. However, histologic findings include fibroblastic plugs in the alveolar sacs and ducts, often extending into adjacent alveoli in a characteristic butterfly pattern.

Educational objective:
Histologic findings of idiopathic pulmonary fibrosis are most prominent in the lung periphery and include a heterogeneous mixture of chronic inflammation and patchy interstitial fibrosis, focal fibroblast proliferation, and formation of fibrotic cystic spaces in a honeycomb pattern.

https://t.me/USMLEWorldStep1

Exhibit Display

Idiopathic pulmonary fibrosis

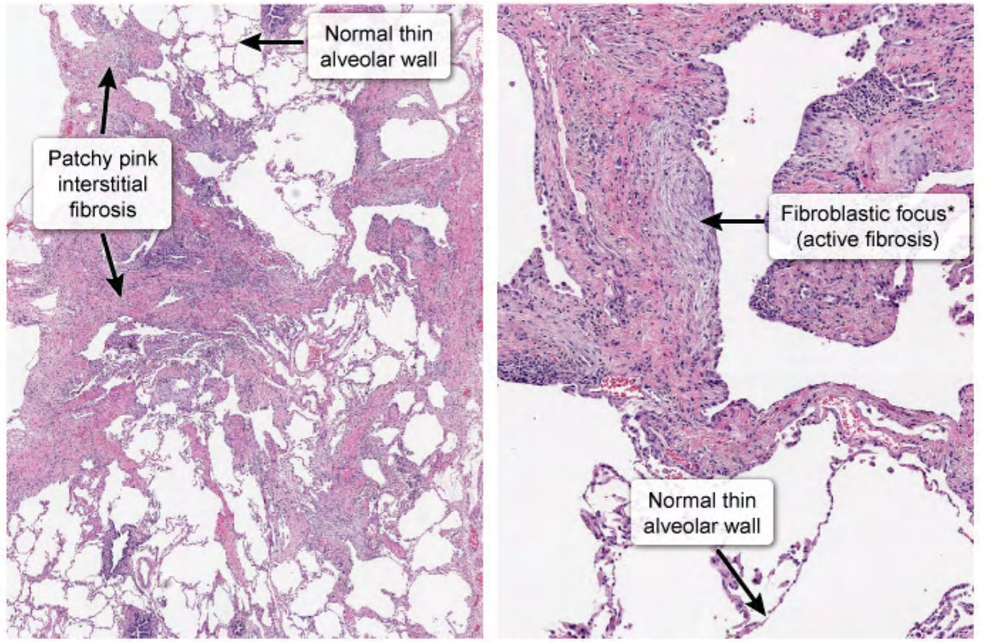

*Proliferation of fibroblasts and myofibroblasts with pale gray stroma

©UWorld

Zoom In | Zoom Out | Reset | New | Existing | My Notebook

The de
finding

- P
- E
- H
- F

Import

The pr
aspira
nonpr
curativ

(Choi
Patien
(eg, bu

(Choi
show f
(brown
ferrous

(Choice C) Chronic bronchitis causes significant sputum production over a prolonged period and is often related to smoking. Histologic findings include mild lymphocytic infiltrates and mucous gland hyperplasia with mucus-filled

https://t.me/USMLEWorldStep1

Exhibit Display

Lung with honeycomb change

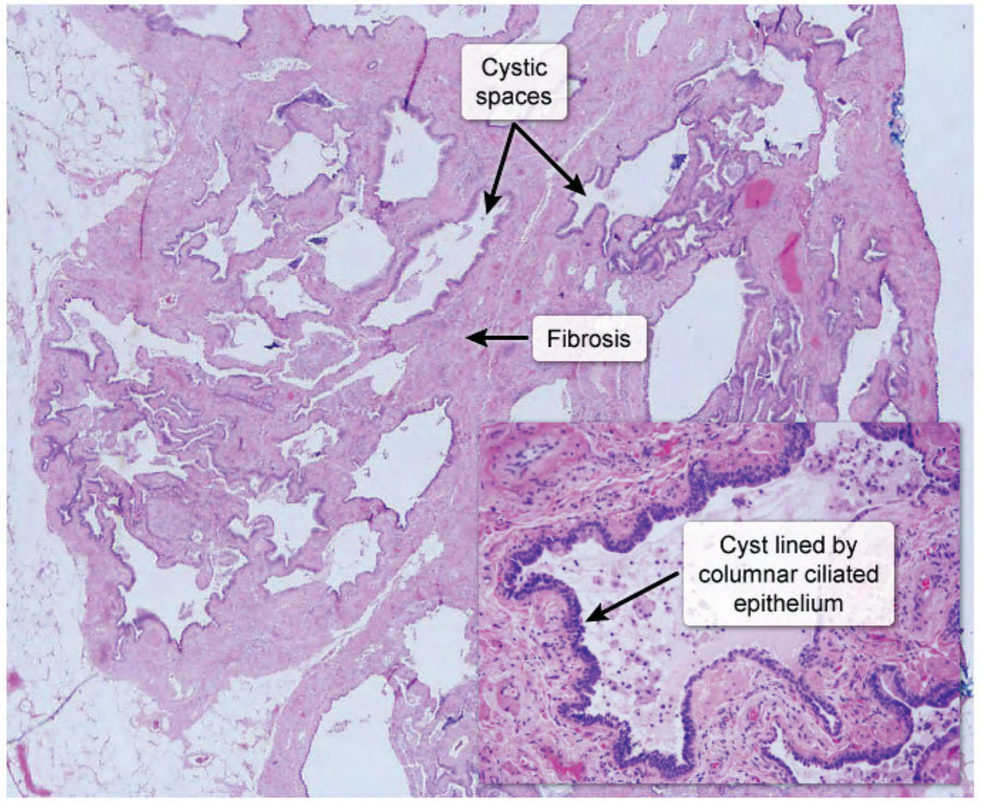

©UWorld

Zoom In | Zoom Out | Reset | New | Existing | My Notebook

Inco
Corre
F

Expl

The de
finding

- P
- E
- H
- F

Import

The pr
aspira
nonpr
curativ

(Choi
Patien
(eg, bu

(Choi
show f
(brown
ferrous

(Choice C) Chronic bronchitis causes significant sputum production over a prolonged period and is often related to smoking. Histologic findings include mild lymphocytic infiltrates and mucous gland hyperplasia with mucus-filled

https://t.me/USMLEWorldStep1

A 2-day-old boy develops abdominal distension and refuses to breastfeed. He was born via normal spontaneous vaginal delivery at 39 weeks gestation to a primigravid mother. Examination shows significant abdominal distension with palpable intestinal loops. The rectum has no stool and rectal tone is normal. During the examination, the infant has several episodes of dark green emesis. Plain films of the abdomen show air-fluid levels and small bowel dilation. Contrast enema fails to relieve the obstruction, and the patient is taken for emergency laparotomy, which shows an inspissated, green fecal mass obstructing the distal ileum. The infant recovers from the surgery uneventfully. Which of the following will be the most likely cause of mortality in this patient?

- A. Enterocolitis
- B. Liver cirrhosis
- C. Malabsorption
- D. Pneumonia
- E. Renal failure

Submit

https://t.me/USMLEWorldStep1

A 2-day-old boy develops abdominal distension and refuses to breastfeed. He was born via normal spontaneous vaginal delivery at 39 weeks gestation to a primigravid mother. Examination shows significant abdominal distension with palpable intestinal loops. The rectum has no stool and rectal tone is normal. During the examination, the infant has several episodes of dark green emesis. Plain films of the abdomen show air-fluid levels and small bowel dilation. Contrast enema fails to relieve the obstruction, and the patient is taken for emergency laparotomy, which shows an inspissated, green fecal mass obstructing the distal ileum. The infant recovers from the surgery uneventfully. Which of the following will be the most likely cause of mortality in this patient?

- ✗ A. Enterocolitis (22%)
- B. Liver cirrhosis (4%)
- C. Malabsorption (16%)
- ✓ D. Pneumonia (53%)
- E. Renal failure (2%)

Incorrect
Correct answer
D

53%
Answered correctly

04 secs
Time Spent

2023
Version

Explanation

Delayed passage of meconium		
	Hirschsprung disease	**Meconium ileus**
Pathophysiology	• Failure of neural crest cell migration	• Obstruction by inspissated stool
Level of obstruction	• Rectosigmoid	• Ileum
	• Increased tone	• Normal tone

https://t.me/USMLEWorldStep1

Explanation

Delayed passage of meconium		
	Hirschsprung disease	**Meconium ileus**
Pathophysiology	• Failure of neural crest cell migration	• Obstruction by inspissated stool
Level of obstruction	• Rectosigmoid	• Ileum
Rectal examination	• Increased tone • Positive squirt sign*	• Normal tone • Negative squirt sign*
Meconium consistency	• Normal	• Inspissated
Imaging	• Dilated proximal colon ± small bowel • Narrow rectosigmoid	• Dilated small bowel • Microcolon
Associated disorder	• Down syndrome	• Cystic fibrosis
*Expulsion of gas/stool on rectal examination.		

This patient's abdominal distension, bilious emesis, and x-ray findings (air-fluid levels, small bowel dilation) are consistent with **bowel obstruction**. The intraoperative finding of a green **inspissated mass** (dehydrated meconium) in the **distal ileum** points to the diagnosis of **meconium ileus** as the source of obstruction. Meconium ileus is a very specific finding for **cystic fibrosis** (CF). Although only 10%-20% of infants with CF will have meconium ileus at birth, almost all full-term infants with meconium ileus are eventually diagnosed with CF. Abnormalities in chloride, sodium, and water transport by the ductal epithelium of intestinal mucous glands cause isotonic dehydration of the lumen contents. This results in secretion of **abnormally viscous mucus** into the small bowel. In the United States, pneumonia, bronchiectasis, and cor pulmonale account for most deaths due to CF.

(Choice A) Patients with Hirschsprung disease (HD) typically present with signs of intestinal obstruction in the newborn period that are similar to meconium ileus. However, HD typically presents with increased rectal tone, "squirt sign" (forceful expulsion of stool after rectal examination), and obstruction at the rectosigmoid region with a

https://t.me/USMLEWorldStep1

This patient's abdominal distension, bilious emesis, and x-ray findings (air-fluid levels, small bowel dilation) are consistent with **bowel obstruction**. The intraoperative finding of a green **inspissated mass** (dehydrated meconium) in the **distal ileum** points to the diagnosis of **meconium ileus** as the source of obstruction. Meconium ileus is a very specific finding for **cystic fibrosis** (CF). Although only 10%-20% of infants with CF will have meconium ileus at birth, almost all full-term infants with meconium ileus are eventually diagnosed with CF. Abnormalities in chloride, sodium, and water transport by the ductal epithelium of intestinal mucous glands cause isotonic dehydration of the lumen contents. This results in secretion of **abnormally viscous mucus** into the small bowel. In the United States, pneumonia, bronchiectasis, and cor pulmonale account for most deaths due to CF.

(Choice A) Patients with Hirschsprung disease (HD) typically present with signs of intestinal obstruction in the newborn period that are similar to meconium ileus. However, HD typically presents with increased rectal tone, "squirt sign" (forceful expulsion of stool after rectal examination), and obstruction at the rectosigmoid region with a transition zone between the aganglionic rectum and proximal dilated colon. Enterocolitis (diarrhea, abdominal pain/distension, and fever) is the most common cause of mortality in patients with HD.

(Choice B) Focal biliary or multilobular cirrhosis due to plugging of bile canaliculi by dehydrated mucinous material develops in approximately 5% of CF patients. Death from cirrhotic liver failure is much less likely than terminal pneumonia.

(Choice C) Most patients with CF have exocrine pancreatic insufficiency, which causes malabsorption and steatorrhea. Infants often have large foul-smelling stools, abdominal distention, and poor weight gain. Consequences include deficiencies of fat-soluble vitamins, hypoproteinemia with generalized edema, and persistent diarrhea with rectal prolapse. However, pancreatic involvement is rarely fatal with pancreatic enzyme supplementation.

(Choice E) Although the CFTR protein is expressed in nephrons, patients with CF usually do not manifest serious renal dysfunction or failure. Patients with CF, however, are at elevated risk for nephrolithiasis and renal damage from nephrotoxic medications (eg, aminoglycosides).

Educational objective:
Meconium ileus is a distal small bowel obstruction due to abnormally dehydrated meconium in a patient with cystic fibrosis (CF). Persistent, treatment-resistant infectious pneumonias, bronchiectasis, and cor pulmonale account for

https://t.me/USMLEWorldStep1

ileus is a very specific finding for **cystic fibrosis** (CF). Although only 10%-20% of infants with CF will have meconium ileus at birth, almost all full-term infants with meconium ileus are eventually diagnosed with CF. Abnormalities in chloride, sodium, and water transport by the ductal epithelium of intestinal mucous glands cause isotonic dehydration of the lumen contents. This results in secretion of **abnormally viscous mucus** into the small bowel. In the United States, pneumonia, bronchiectasis, and cor pulmonale account for most deaths due to CF.

(Choice A) Patients with Hirschsprung disease (HD) typically present with signs of intestinal obstruction in the newborn period that are similar to meconium ileus. However, HD typically presents with increased rectal tone, "squirt sign" (forceful expulsion of stool after rectal examination), and obstruction at the rectosigmoid region with a transition zone between the aganglionic rectum and proximal dilated colon. Enterocolitis (diarrhea, abdominal pain/distension, and fever) is the most common cause of mortality in patients with HD.

(Choice B) Focal biliary or multilobular cirrhosis due to plugging of bile canaliculi by dehydrated mucinous material develops in approximately 5% of CF patients. Death from cirrhotic liver failure is much less likely than terminal pneumonia.

(Choice C) Most patients with CF have exocrine pancreatic insufficiency, which causes malabsorption and steatorrhea. Infants often have large foul-smelling stools, abdominal distention, and poor weight gain. Consequences include deficiencies of fat-soluble vitamins, hypoproteinemia with generalized edema, and persistent diarrhea with rectal prolapse. However, pancreatic involvement is rarely fatal with pancreatic enzyme supplementation.

(Choice E) Although the CFTR protein is expressed in nephrons, patients with CF usually do not manifest serious renal dysfunction or failure. Patients with CF, however, are at elevated risk for nephrolithiasis and renal damage from nephrotoxic medications (eg, aminoglycosides).

Educational objective:
Meconium ileus is a distal small bowel obstruction due to abnormally dehydrated meconium in a patient with cystic fibrosis (CF). Persistent, treatment-resistant infectious pneumonias, bronchiectasis, and cor pulmonale account for most deaths due to CF.

References

- Gastrointestinal Manifestations of Cystic Fibrosis

https://t.me/USMLEWorldStep1

An 81-year-old man comes to the office after an upper respiratory tract infection. His symptoms have largely resolved except for a mild, nonproductive cough that is especially bothersome at night. Medical history includes hypertension and knee osteoarthritis. The patient is still physically active and plays golf on the weekends. He is a retired insurance executive and has no known environmental exposures. He has no history of smoking. Physical examination is unremarkable, and chest x-ray is normal. Pulmonary function testing is considered in this patient. Compared to midlife, which of the following changes are most likely expected as a result of normal aging in this patient?

	Total lung capacity	Forced vital capacity	Residual volume
○ A.	↑	↑	↑
○ B.	Unchanged	↑	↑
○ C.	Unchanged	↓	↑
○ D.	↓	↑	↓
○ E.	↓	↓	↓

Submit

https://t.me/USMLEWorldStep1

An 81-year-old man comes to the office after an upper respiratory tract infection. His symptoms have largely resolved except for a mild, nonproductive cough that is especially bothersome at night. Medical history includes hypertension and knee osteoarthritis. The patient is still physically active and plays golf on the weekends. He is a retired insurance executive and has no known environmental exposures. He has no history of smoking. Physical examination is unremarkable, and chest x-ray is normal. Pulmonary function testing is considered in this patient. Compared to midlife, which of the following changes are most likely expected as a result of normal aging in this patient?

	Total lung capacity	Forced vital capacity	Residual volume	
A.	↑	↑	↑	(10%)
✗ B.	Unchanged	↑	↑	(3%)
✓ C.	Unchanged	↓	↑	(57%)
D.	↓	↑	↓	(5%)
E.	↓	↓	↓	(23%)

Incorrect
Correct answer
C

57%
Answered correctly

04 secs
Time Spent

2023
Version

Explanation



https://t.me/USMLEWorldStep1

E. (23%)

Exhibit Display

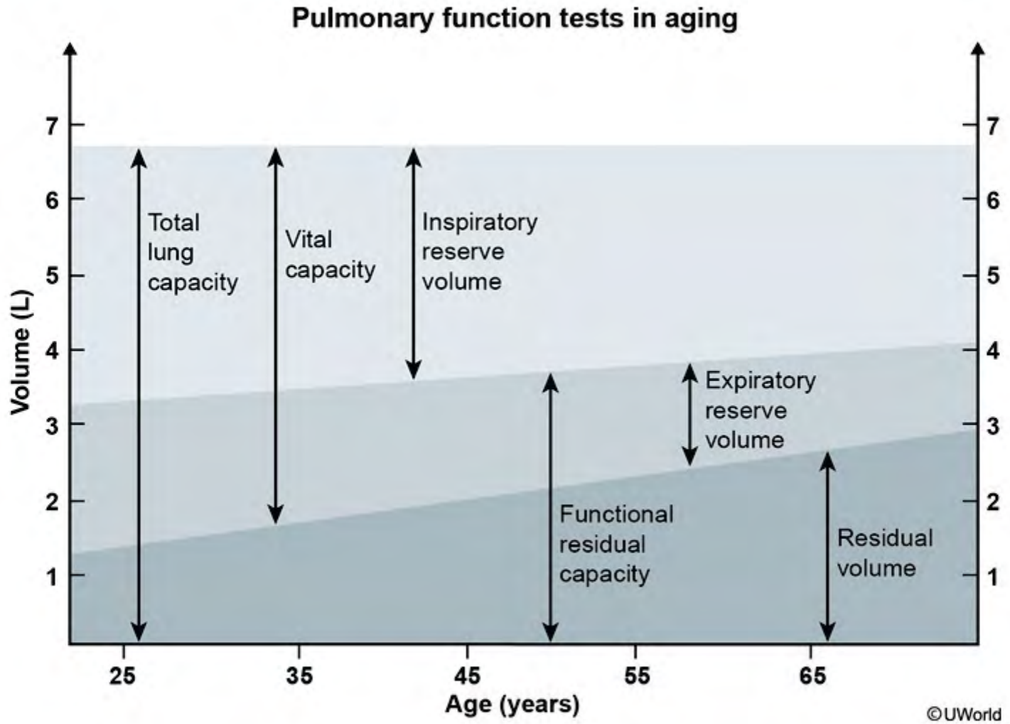

Zoom In | Zoom Out | Reset | New | Existing | My Notebook

Aging

decrea

curvat

elastic recoil, particularly in the alveolar ducts. The dilation of alveolar ducts is homogenous, as opposed to the

https://t.me/USMLEWorldStep1

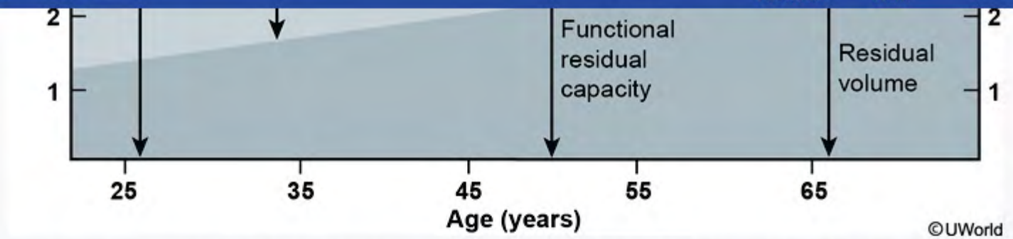

Aging is associated with a number of changes in pulmonary function. Patients age >35 experience steady decreases in chest wall compliance as a result of stiffening from rib calcification and from increased thoracic curvature due to osteoporosis and osteoarthritis. In contrast, lung compliance increases with age due to a loss of elastic recoil, particularly in the alveolar ducts. The dilation of alveolar ducts is homogenous, as opposed to the emphysema associated with chronic obstructive pulmonary disease, and is not associated with destruction of the alveolar walls.

Diminished elastic recoil and the collapse of supporting tissues around the airways cause a significant **increase** in **residual volume** (RV). However, **total lung capacity** (TLC) remains **unchanged** because the decreased chest wall compliance counterbalances increases in lung compliance **(Choices A, D, and E)**. In addition, as RV becomes a much higher proportion of TLC (due to air trapping), forced vital capacity also decreases **(Choice B)**. Other age-associated changes include decreases in forced expiratory volume in 1 second and diffusing capacity.

Educational objective:
Aging is associated with steady decreases in chest wall compliance but increases in lung compliance due to a loss of elastic recoil. This results in a marked increase in residual volume, a decrease in forced vital capacity, and relatively unchanged total lung capacity.

References

- Effect of aging on respiratory system physiology and immunology.
- Physiological changes in respiratory function associated with ageing.

Physiology	Pulmonary & Critical Care	Aging
Subject	System	Topic

Copyright © UWorld. All rights reserved.

A 44-year-old man comes to the emergency department due to sudden-onset shortness of breath that started a few hours ago. Last week, he sustained a crush injury after a motorcycle drove over his left foot, and he has been immobilized since then due to pain. The patient drinks alcohol occasionally and does not use tobacco or illicit drugs. Temperature is 36.1 C (97 F), blood pressure is 118/76 mm Hg, pulse is 102/min, and respirations are 28/min. BMI is 37 kg/m^2. On physical examination, heart rhythm is regular with normal S1 and S2. The lungs are clear to auscultation bilaterally. The dorsum of the left foot has resolving ecchymoses and swelling compared to when he was evaluated last week. The right calf is swollen and tender. Which of the following arterial blood gas values are most likely to be present in this patient?

	pH	PaO_2 (mm Hg)	$PaCO_2$ (mm Hg)	Serum HCO_3^- (mEq/L)
○ A.	7.30	101	23	11
○ B.	7.32	60	64	32
○ C.	7.38	80	40	23
○ D.	7.57	65	26	23
○ E.	7.47	96	24	17
○ F.	7.49	75	49	36

Submit

https://t.me/USMLEWorldStep1

A 44-year-old man comes to the emergency department due to sudden-onset shortness of breath that started a few hours ago. Last week, he sustained a crush injury after a motorcycle drove over his left foot, and he has been immobilized since then due to pain. The patient drinks alcohol occasionally and does not use tobacco or illicit drugs. Temperature is 36.1 C (97 F), blood pressure is 118/76 mm Hg, pulse is 102/min, and respirations are 28/min. BMI is 37 kg/m^2. On physical examination, heart rhythm is regular with normal S1 and S2. The lungs are clear to auscultation bilaterally. The dorsum of the left foot has resolving ecchymoses and swelling compared to when he was evaluated last week. The right calf is swollen and tender. Which of the following arterial blood gas values are most likely to be present in this patient?

		pH	PaO_2 (mm Hg)	$PaCO_2$ (mm Hg)	Serum HCO_3^- (mEq/L)	
	A.	7.30	101	23	11	(7%)
✗	B.	7.32	60	64	32	(21%)
	C.	7.38	80	40	23	(8%)
✓	D.	7.57	65	26	23	(44%)
	E.	7.47	96	24	17	(15%)
	F.	7.49	75	49	36	(3%)

Incorrect
Correct answer
D

44%
Answered correctly

03 secs
Time Spent

2023
Version

Explanation

Pulmonary embolism

https://t.me/USMLEWorldStep1

✓	D.	7.57	65	26	23	(44%)

Exhibit Display

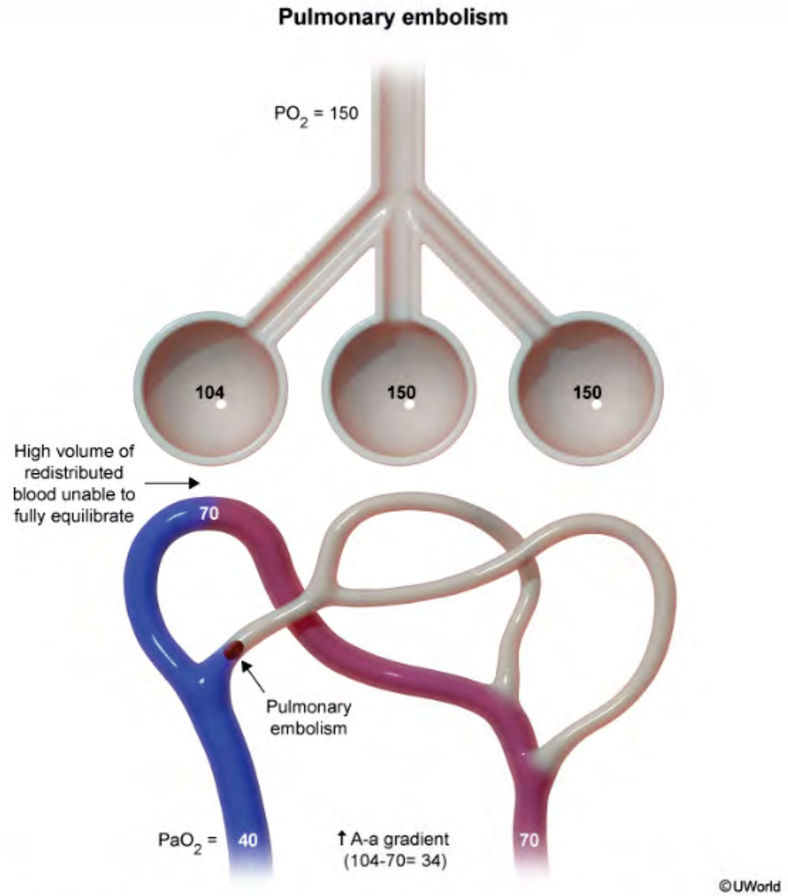

Zoom In | Zoom Out | Reset | New | Existing | My Notebook

https://t.me/USMLEWorldStep1

Sudden-onset **dyspnea** in the setting of recent **calf swelling** is strongly suggestive of **pulmonary embolism (PE)**. Dyspnea is the most common symptom of PE and risk factors include obesity, smoking, and prolonged immobilization. The embolus typically arises from a deep venous thrombus in the lower extremities (causes calf swelling) and lodges itself within the arterial blood supply of the lungs.

PE occludes or significantly reduces blood flow to a portion of the pulmonary parenchyma, resulting in increased **dead space ventilation** and redistribution of pulmonary blood flow away from the affected segments. This leads to increased **ventilation/perfusion (V/Q) mismatch** in the remainder of the lungs with consequent **hypoxemia**.

Stimulation of central respiratory drive occurs in response to dyspnea and inflammatory mediators released by ischemic pulmonary tissue. **Hyperventilation** does not significantly improve arterial oxygenation because hemoglobin is nearly fully saturated with O_2 in areas of normal V/Q ratio, allowing little capacity for high V/Q regions to increase blood O_2 content much further. In contrast, CO_2 removal is more directly dependent on ventilation, and high V/Q regions have large capacity to **exhale additional CO_2**. Therefore, the hyperventilation leads to hypocapnia (low $PaCO_2$) and **respiratory alkalosis**. The serum HCO_3^- is near normal in the acute setting, but metabolic compensation with renal bicarbonate loss takes place over the next 72 hours.

(Choice A) Low blood pH of 7.30 with low serum HCO_3^- indicates metabolic acidosis, which is compensated by hyperventilation leading to low $PaCO_2$.

(Choice B) A low pH of 7.32 with high $PaCO_2$ reflects respiratory acidosis. The high HCO_3^- indicates renal compensation by bicarbonate retention. Although PE may eventually lead to respiratory collapse with an acute increase in $PaCO_2$, a renal compensatory response would not be expected so abruptly.

(Choice C) These arterial blood gas values are considered normal, reflecting an absence of acid-base disturbance.

(Choice E) A high pH of 7.47 with low $PaCO_2$ reflects respiratory alkalosis. The low HCO_3^- indicates renal compensation, which is expected with chronic respiratory alkalosis but should not be present with acute PE. Normal PaO_2 can occasionally be present in acute PE but is less likely.

(Choice F) A high pH of 7.48 with high serum HCO_3^- reflects metabolic alkalosis, which is compensated by

https://t.me/USMLEWorldStep1

dead space ventilation and redistribution of pulmonary blood flow away from the affected segments. This leads to increased **ventilation/perfusion (V/Q) mismatch** in the remainder of the lungs with consequent **hypoxemia**.

Stimulation of central respiratory drive occurs in response to dyspnea and inflammatory mediators released by ischemic pulmonary tissue. **Hyperventilation** does not significantly improve arterial oxygenation because hemoglobin is nearly fully saturated with O_2 in areas of normal V/Q ratio, allowing little capacity for high V/Q regions to increase blood O_2 content much further. In contrast, CO_2 removal is more directly dependent on ventilation, and high V/Q regions have large capacity to **exhale additional CO_2**. Therefore, the hyperventilation leads to hypocapnia (low $PaCO_2$) and **respiratory alkalosis**. The serum HCO_3^- is near normal in the acute setting, but metabolic compensation with renal bicarbonate loss takes place over the next 72 hours.

(Choice A) Low blood pH of 7.30 with low serum HCO_3^- indicates metabolic acidosis, which is compensated by hyperventilation leading to low $PaCO_2$.

(Choice B) A low pH of 7.32 with high $PaCO_2$ reflects respiratory acidosis. The high HCO_3^- indicates renal compensation by bicarbonate retention. Although PE may eventually lead to respiratory collapse with an acute increase in $PaCO_2$, a renal compensatory response would not be expected so abruptly.

(Choice C) These arterial blood gas values are considered normal, reflecting an absence of acid-base disturbance.

(Choice E) A high pH of 7.47 with low $PaCO_2$ reflects respiratory alkalosis. The low HCO_3^- indicates renal compensation, which is expected with chronic respiratory alkalosis but should not be present with acute PE. Normal PaO_2 can occasionally be present in acute PE but is less likely.

(Choice F) A high pH of 7.48 with high serum HCO_3^- reflects metabolic alkalosis, which is compensated by hypoventilation leading to high $PaCO_2$.

Educational objective:
The combination of calf swelling, history of prolonged immobility, and sudden-onset dyspnea is strongly suggestive of acute pulmonary embolism (PE). PE typically presents with hypoxemia due to ventilation/perfusion mismatch and acute respiratory alkalosis (hypocapnia) due to hyperventilation.

https://t.me/USMLEWorldStep1

(104-70= 34)

©UWorld

Sudde
(PE).
immob
swellin

PE oc
dead
to incr

Stimul
ischen
hemog
region
ventila
leads
but me

(Choi
hyperv

(Choi
compe
increa

(Choi
disturb

(Choi
compe

Normal PaO_2 can occasionally be present in acute PE but is less likely.

Exhibit Display

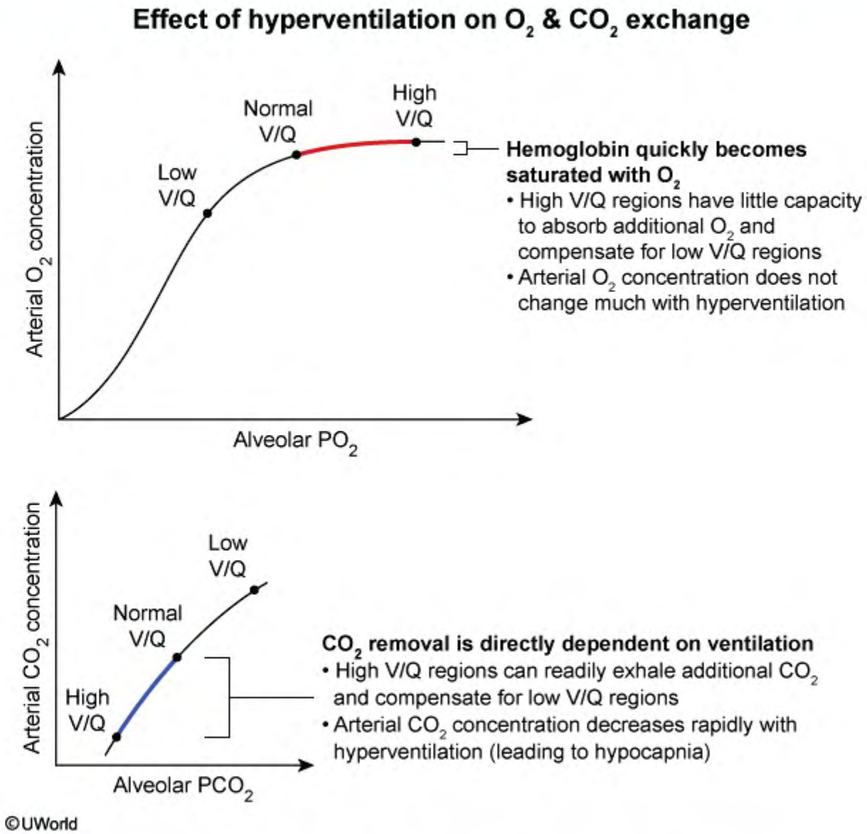

Zoom In | Zoom Out | Reset | New | Existing | My Notebook

https://t.me/USMLEWorldStep1

(104-70= 34)

©UWorld

Sudde
(PE).
immob
swellin

PE oc
dead
to incr

Stimul
ischen
hemog
region
ventila
leads
but me

(Choi
hyperv

(Choi
compe
increa

(Choi
disturb

(Choi
compe

Exhibit Display

Arterial blood gas interpretation of acid-base disorders

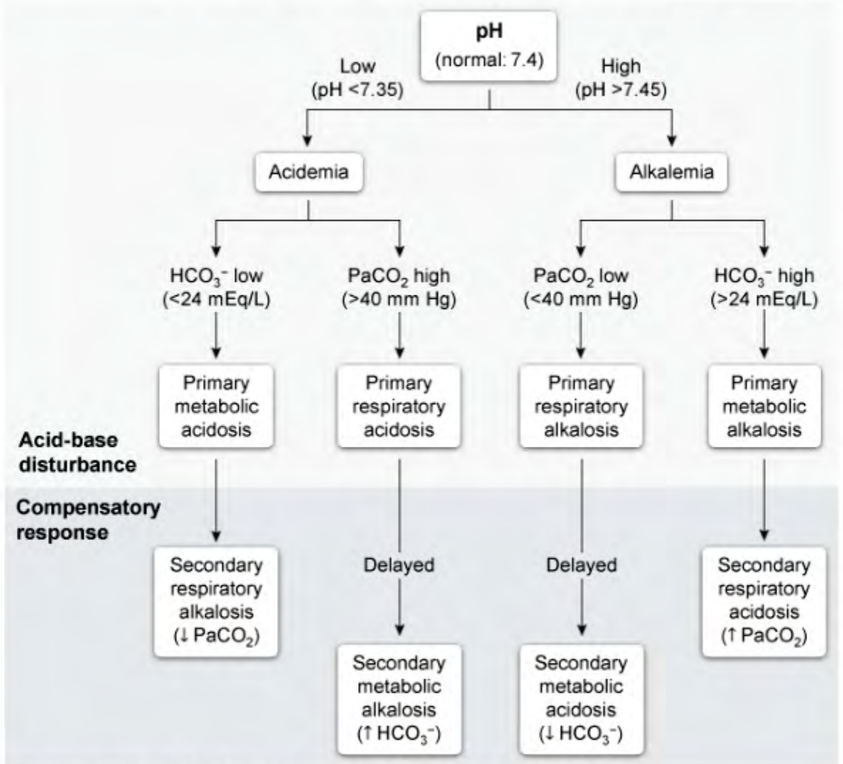

* The normal ranges for $PaCO_2$ and HCO_3^- vary slightly around 40 mm Hg and 24 mEq/L.
For simplicity, these numbers should be used as a normal baseline for acid-base calculations.

HCO_3^- = bicarbonate; **$PaCO_2$** = partial pressure of carbon dioxide in arterial blood.

©UWorld

Zoom In | Zoom Out | Reset | New | Existing | My Notebook

Normal PaO_2 can occasionally be present in acute PE but is less likely.

https://t.me/USMLEWorldStep1

A 64-year-old man is brought to the emergency department due to worsening shortness of breath. The patient is able to speak in short sentences only and becomes hypoxemic with minimal exertion. His medical history includes hypertension and dyslipidemia. He smoked a pack of cigarettes a day for 40 years and worked for 25 years as a nickel miner. His father died of chronic respiratory failure. While in the emergency department, he rapidly develops respiratory failure and is intubated. Despite appropriate treatment, he dies several days later in the intensive care unit. Autopsy is performed, and examination of the bronchi reveals thickened bronchial walls, inflammatory infiltrates, mucous gland enlargement, and patchy squamous metaplasia of the bronchial mucosa. Which of the following factors was likely the greatest contributor to this patient's pathological findings?

- A. Allergic
- B. Behavioral
- C. Genetic
- D. Infectious
- E. Neoplastic
- F. Occupational

Submit

https://t.me/USMLEWorldStep1

A 64-year-old man is brought to the emergency department due to worsening shortness of breath. The patient is able to speak in short sentences only and becomes hypoxemic with minimal exertion. His medical history includes hypertension and dyslipidemia. He smoked a pack of cigarettes a day for 40 years and worked for 25 years as a nickel miner. His father died of chronic respiratory failure. While in the emergency department, he rapidly develops respiratory failure and is intubated. Despite appropriate treatment, he dies several days later in the intensive care unit. Autopsy is performed, and examination of the bronchi reveals thickened bronchial walls, inflammatory infiltrates, mucous gland enlargement, and patchy squamous metaplasia of the bronchial mucosa. Which of the following factors was likely the greatest contributor to this patient's pathological findings?

- A. Allergic (1%)
- ✓ B. Behavioral (65%)
- C. Genetic (2%)
- D. Infectious (1%)
- E. Neoplastic (4%)
- F. Occupational (25%)

Correct

65% Answered correctly

04 secs Time Spent

2023 Version

Explanation

This patient with respiratory failure, hypoxemia, and thickened bronchial walls with inflammatory infiltrates and mucous gland enlargement likely had **chronic bronchitis**. Chronic bronchitis is characterized by chronic, productive cough with airflow limitation and is part of the spectrum of chronic obstructive pulmonary disease. It is most commonly caused by **tobacco smoking**. Chronic irritation by other inhaled environmental substances, such as air pollutants and grain, cotton, or silica dusts, can also contribute to its development. Biopsy typically shows

https://t.me/USMLEWorldStep1

This patient with respiratory failure, hypoxemia, and thickened bronchial walls with inflammatory infiltrates and mucous gland enlargement likely had **chronic bronchitis**. Chronic bronchitis is characterized by chronic, productive cough with airflow limitation and is part of the spectrum of chronic obstructive pulmonary disease. It is most commonly caused by **tobacco smoking**. Chronic irritation by other inhaled environmental substances, such as air pollutants and grain, cotton, or silica dusts, can also contribute to its development. Biopsy typically shows **thickened bronchial walls** with predominantly **lymphocytic infiltrates**, mucous gland enlargement with increased numbers of goblet cells (**increasing mucus production**), and patchy **squamous metaplasia** of the bronchial mucosa.

(Choice A) Patients with allergic asthma can develop pathologic remodeling of the bronchial wall, which includes thickening of the bronchial epithelium, basement membrane, and bronchial smooth muscle as well as edema, inflammatory infiltrates, and submucosal mucous gland enlargement. However, the infiltrates consist predominantly of eosinophils and mast cells. In addition, although asthma is a risk factor for chronic bronchitis, smoking is a much more common cause.

(Choice C) Genetic factors are not known to strongly predispose to chronic bronchitis. Genetic mutation causing alpha-1 antitrypsin deficiency can lead to panacinar emphysema; however, chronic bronchitis is not a significant component of the disease.

(Choice D) Repeated bronchial/bronchiolar bacterial and viral infections can contribute to the development of chronic bronchitis, although less significantly than can smoking. Tobacco smoke predisposes to infection by impairing ciliary clearance and directly damaging the respiratory epithelium.

(Choices E and F) Nickel is a carcinogen, and occupational exposure is associated with nasal and lung cancers. However, neoplastic transformation itself does not contribute to the development of chronic bronchitis. Although this patient's history of nickel mining is also suggestive of silica dust exposure, smoking is the most important risk factor for chronic bronchitis.

Educational objective:
Thickened bronchial walls, lymphocytic infiltration, mucous gland enlargement, and patchy squamous metaplasia of the bronchial mucosa are features of chronic bronchitis. Tobacco smoking is the leading cause of chronic bronchitis.

https://t.me/USMLEWorldStep1

A 48-year-old man comes to the office for an initial visit. He says that he feels well and has no known medical conditions. The patient has a 20-pack-year smoking history and does not use alcohol or recreational drugs. He is counseled on smoking cessation. During the discussion of how smoking affects lung function, the patient is shown a graph of the expected change in forced expiratory volume in 1 second (FEV_1) over time if he continues to smoke at the same rate (Curve D shown below). Which of the following curves most likely demonstrates the expected FEV_1 over time if this patient were to stop smoking now?

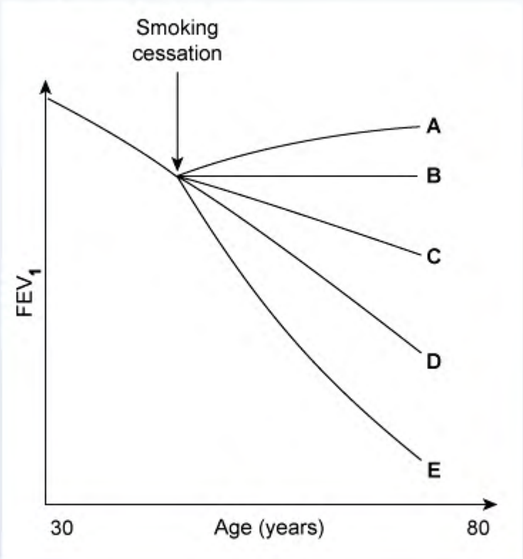

- A. A
- B. B
- C. C
- D. D
- E. E

https://t.me/USMLEWorldStep1

conditions. The patient has a 20-pack-year smoking history and does not use alcohol or recreational drugs. He is counseled on smoking cessation. During the discussion of how smoking affects lung function, the patient is shown a graph of the expected change in forced expiratory volume in 1 second (FEV_1) over time if he continues to smoke at the same rate (Curve D shown below). Which of the following curves most likely demonstrates the expected FEV_1 over time if this patient were to stop smoking now?

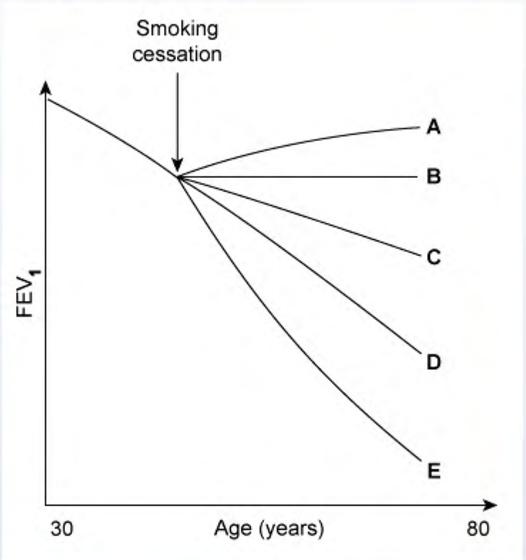

- ✗ A. A (17%)
- B. B (20%)
- ✓ C. C (53%)
- D. D (5%)
- E. E (3%)

Incorrect
Correct answer
C

53%
Answered correctly

07 secs
Time Spent

2023
Version

https://t.me/USMLEWorldStep1

Incorrect
Correct answer
C

53%
Answered correctly

07 secs
Time Spent

2023
Version

Exhibit Display

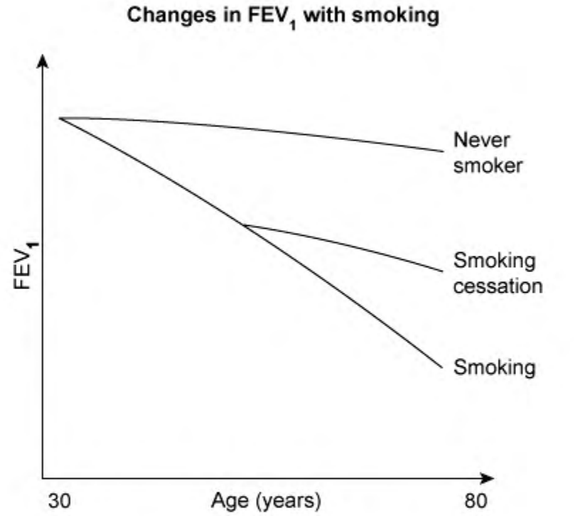

FEV_1 = forced expiratory volume in 1 second.
This is the maximal amount of air forcibly expelled during the 1st second following maximal inhalation.

©UWorld

Zoom In | Zoom Out | Reset | New | Existing | My Notebook

In hea
declin
smok

Cigare
damag
(chron

Together these conditions lead to expiratory flow limitation, typically measured as a **reduction in FEV_1**.

https://t.me/USMLEWorldStep1

the 1st second following maximal inhalation. ©UWorld

In healthy persons who never smoke, lung function peaks at approximately age 30. Afterward, there is a gradual decline in forced expiratory volume in 1 second (FEV_1) of approximately 25 mL/year. In the average person who **smokes tobacco**, the rate of lung **function declines** approximately **3 times faster**.

Cigarette smoke contains numerous toxins (eg, formaldehyde, acrolein) that provoke **inflammatory proteolytic damage** to the airways and alveoli. These changes are responsible for airway inflammation and narrowing (chronic bronchitis: ↑ airway resistance) and alveolar septal destruction (emphysema: ↓ elastic recoil pressure). Together these conditions lead to expiratory flow limitation, typically measured as a **reduction in FEV_1**.

Once lost, lung function is not recoverable. However, smoking **cessation** can markedly **slow the decline** in FEV_1. Within a year of complete abstinence, a successful quitter's rate of FEV_1 decline returns to that of normally aging nonsmokers. Therefore, after this patient quits smoking, the slope of his FEV_1 decline curve will decrease, but no function will be regained. This trajectory is best represented by **Curve C**.

(Choices A and B) FEV_1 declines persistently with age in all individuals past age 30. It is not physiologically possible for FEV_1 to increase with further aging. Pulmonary function decline in normal aging is mostly due to a gradual, spontaneous loss of lung elastin.

(Choice D) This curve represents the expected result if the patient continues smoking at his current level. With smoking cessation, the rate of FEV_1 decline would slow down rather than continue on the same accelerated trajectory.

(Choice E) This curve represents further acceleration of FEV_1 decline, which would occur if the patient increased his cigarette smoking.

Educational objective:
Cigarette smoking substantially accelerates the normal age-related decline of lung function that occurs after age 30. Smoking cessation does not restore lung function that has already been lost. However, it slows the decline in forced expiratory volume in 1 second, restoring its trajectory to that of normally aging nonsmokers.

References

- Smoking cessation: effects on symptoms, spirometry and future trends in COPD.

https://t.me/USMLEWorldStep1

30 Age (years) 80

Exhibit Display

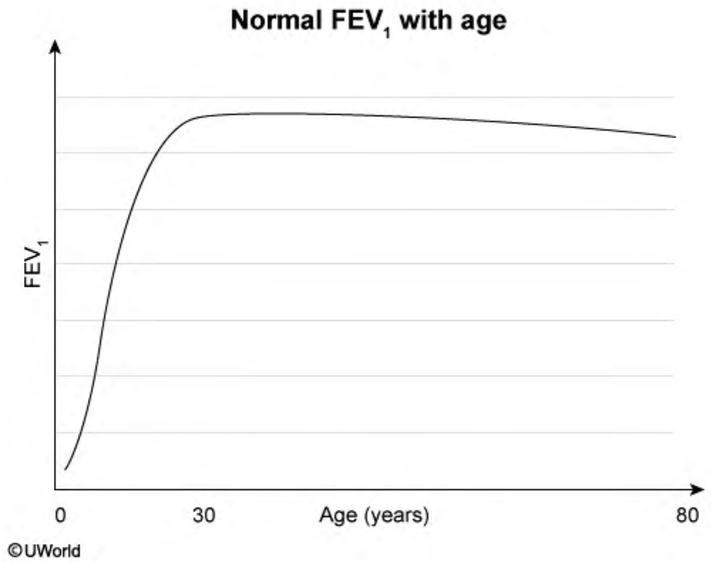

Zoom In Zoom Out Reset New | Existing My Notebook

In hea
decline
smok

Cigare
damag
(chron
Togeth

Once
Within
nonsm
functio

(Choi
possib
gradua

(Choi
smoki
traject

(Choi
his cig

Educa
Cigarette smoking substantially accelerates the normal age-related decline of lung function that occurs after age 30. Smoking cessation does not restore lung function that has already been lost. However, it slows the decline in

https://t.me/USMLEWorldStep1

30 Age (years) 80

Exhibit Display

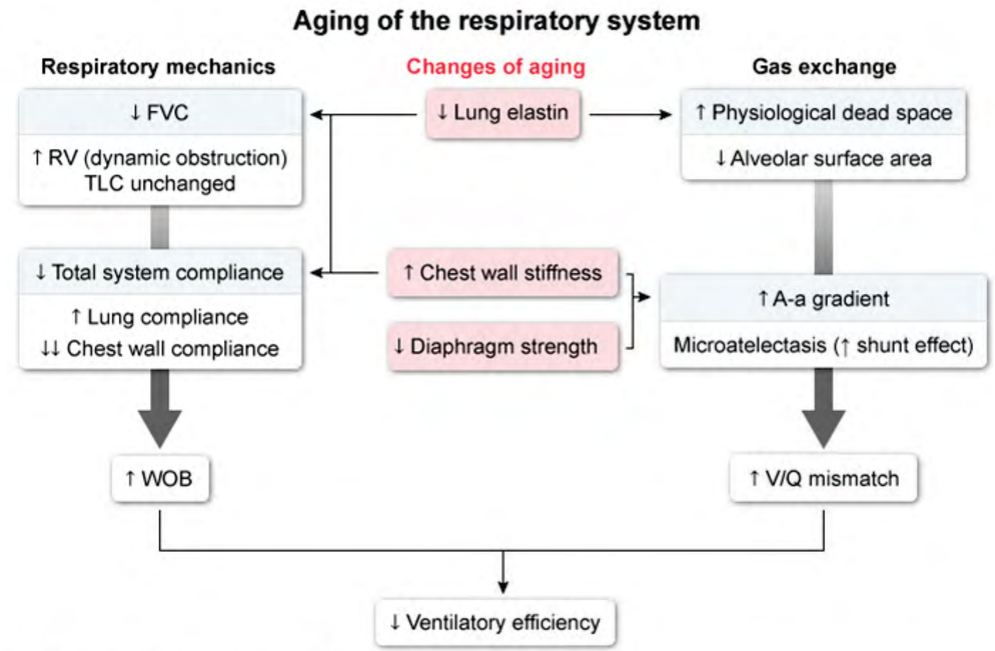

Zoom In Zoom Out Reset New | Existing My Notebook

In hea
decline
smok
Cigare
damag
(chron
Togeth
Once
Within
nonsm
functio
(Choi
possib
gradua
(Choi
smoki
traject
(Choi
his cig
Educa
Cigarette smoking substantially accelerates the normal age-related decline of lung function that occurs after age 30. Smoking cessation does not restore lung function that has already been lost. However, it slows the decline in

https://t.me/USMLEWorldStep1

A 10-year-old boy with a history of mild, persistent asthma is brought to the office for follow-up. His asthma symptoms are controlled with an inhaled beta-agonist and inhaled glucocorticoid therapy. There is no family history of asthma, but both his parents and older brother have short stature. The patient's mother is concerned about the use of glucocorticoids because she read on the Internet that they cause growth retardation. The patient's glucocorticoid medication is stopped, and he is started on a trial of inhaled cromolyn. Which of the following is the most likely site of action of this new medication?

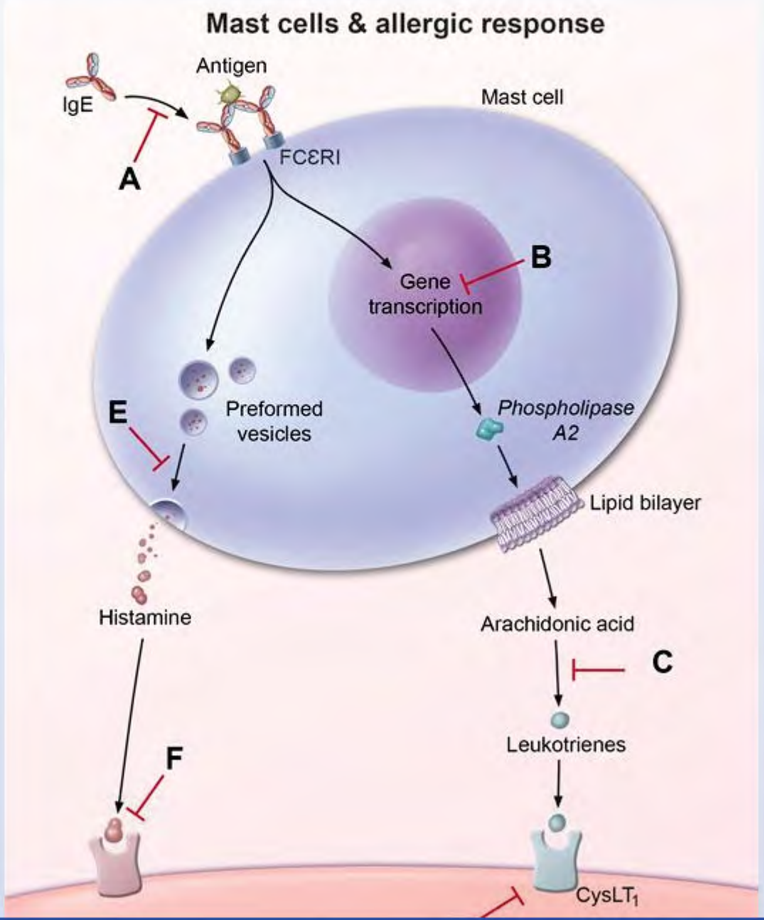

https://t.me/USMLEWorldStep1

A 10-year-old boy with a history of mild, persistent asthma is brought to the office for follow-up. His asthma sympt
history
about
patien
followi

Exhibit Display

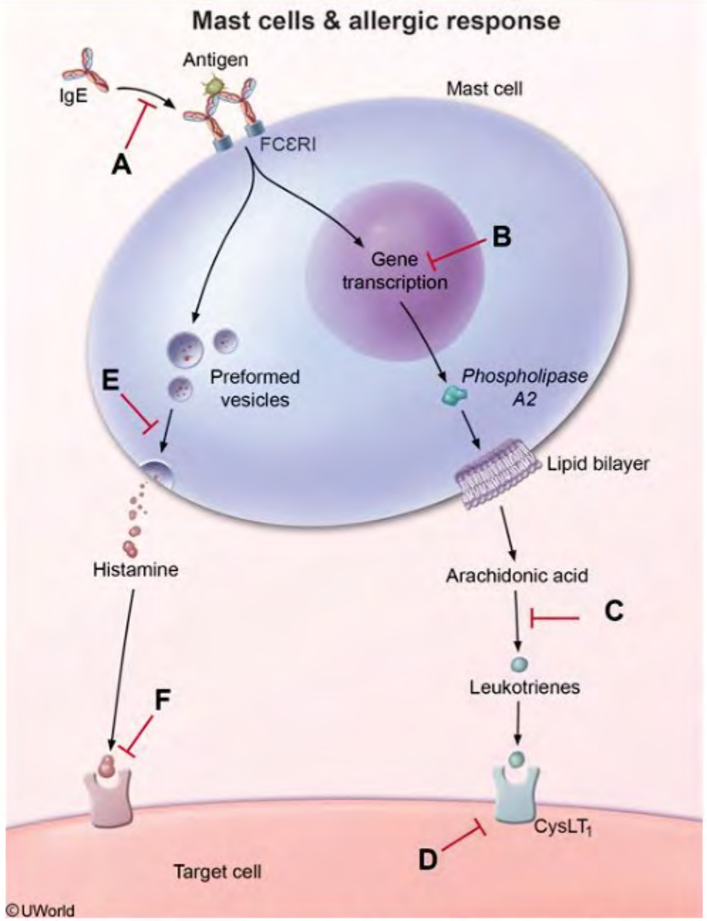

Zoom In | Zoom Out | Reset | New | Existing | My Notebook

https://t.me/USMLEWorldStep1

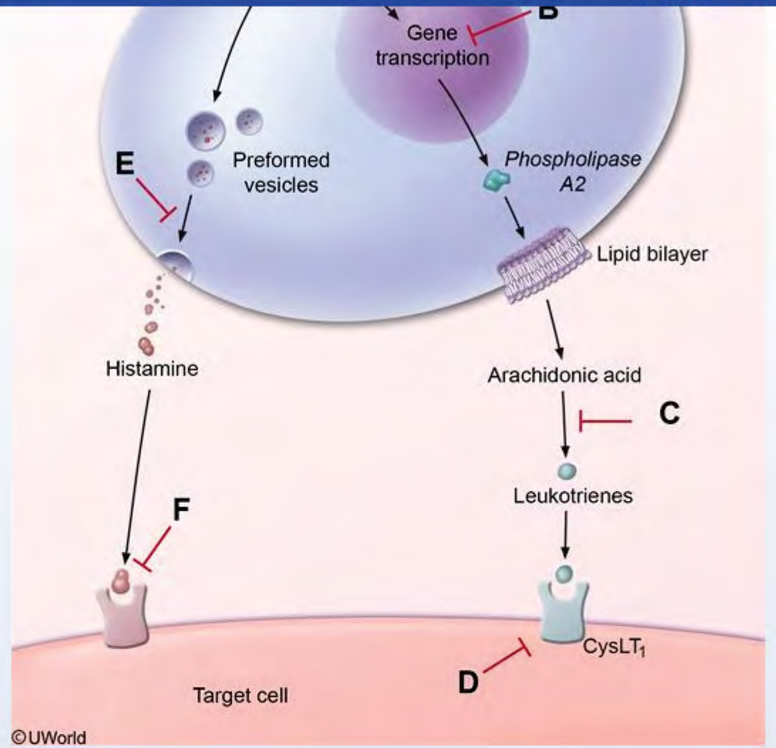

- A. A
- B. B
- C. C
- D. D
- E. E
- F. F

Submit

https://t.me/USMLEWorldStep1

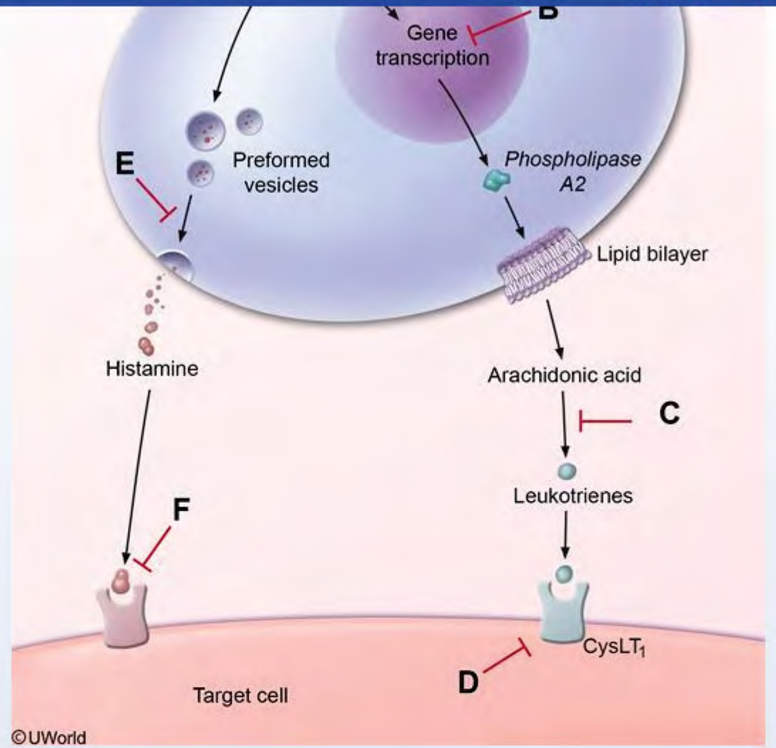

- A. A (11%)
- ✕ B. B (5%)
- C. C (5%)
- D. D (7%)
- ✓ E. E (65%)
- F. F (4%)

Incorrect
Correct answer
E

65%
Answered correctly

15 secs
Time Spent

2023
Version

https://t.me/USMLEWorldStep1

E. E (65%)

Exhibit Display

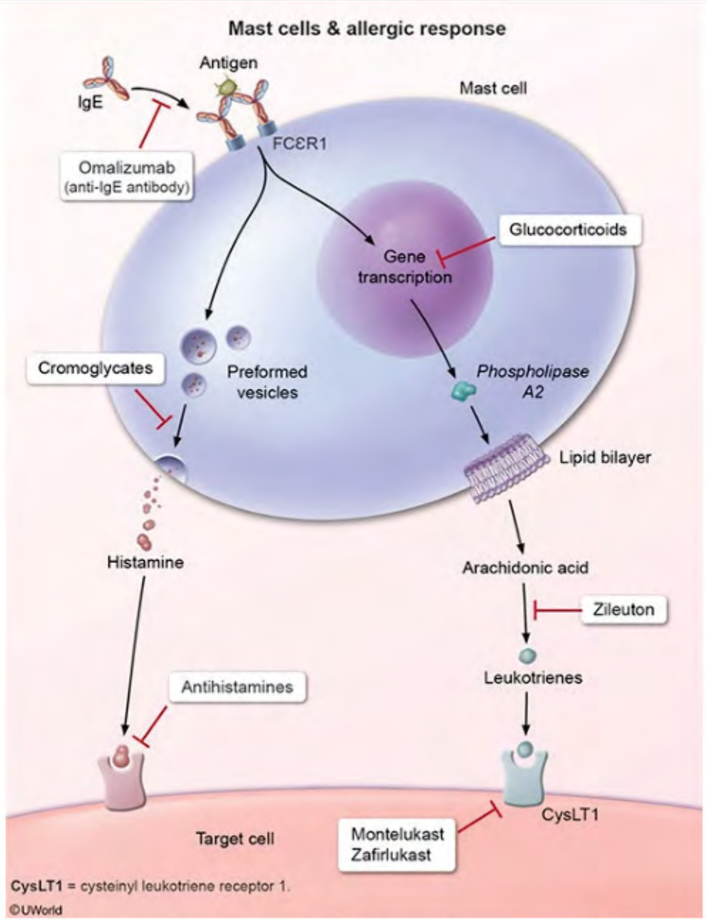

Zoom In Zoom Out Reset New | Existing My Notebook

https://t.me/USMLEWorldStep1

Acute **bronchial constriction** during an asthma exacerbation begins with **mast cell activation** secondary to allergen interaction with IgE antibodies or nonimmune triggers (eg, exercise, cold exposure, chemical irritants). This results in the release of chemical mediators that cause immediate bronchial constriction, bronchial wall edema, and increased mucus production (early phase reaction). These mediators recruit additional inflammatory cells (eg, eosinophils, basophils, neutrophils, T lymphocytes) that lead to bronchial obstruction, which occurs several hours after the triggering event (late phase reaction).

Cromolyn and nedocromil **inhibit mast cell degranulation** and prevent release of preformed chemical mediators. These medications do not influence bronchial constriction directly; therefore, they are typically used to prevent acute attacks, rather than to treat acute exacerbations. Even though these drugs are less efficacious than inhaled glucocorticoids, they are very effective prophylactic agents for patients with seasonal symptoms, aspirin hypersensitivity, and exercise-induced asthma.

(Choice A) The anti-IgE antibody, omalizumab, inhibits IgE binding to mast cells, preventing mast cell degranulation. Omalizumab is used in some patients with severe, persistent asthma to lower IgE levels and reduce allergen-induced bronchial constriction.

(Choice B) Cleavage of membrane phospholipids by the enzyme phospholipase A2 leads to the formation of arachidonic acid, which is in turn converted into prostaglandins and leukotrienes. By inhibiting phospholipase A2 synthesis, glucocorticoids inhibit the release of these downstream mediators, decreasing airway hyperresponsiveness and inflammation.

(Choices C and D) Zileuton is a selective inhibitor of the lipoxygenase pathway that leads to decreased formation of leukotrienes. Zafirlukast and montelukast are leukotriene receptor antagonists. These agents are typically used for chronic asthma prophylaxis.

(Choice F) Antihistamines are used to prevent and blunt an acute allergic response (as seen in allergic rhinitis) but have not been shown to improve bronchoconstriction in asthma.

Educational objective:
Cromolyn and nedocromil are mast cell-stabilizing agents that inhibit mast cell degranulation independent of the triggering stimulus. They are less effective than inhaled glucocorticoids and are considered second-line treatments

https://t.me/USMLEWorldStep1

edema, and increased mucus production (early phase reaction). These mediators recruit additional inflammatory cells (eg, eosinophils, basophils, neutrophils, T lymphocytes) that lead to bronchial obstruction, which occurs several hours after the triggering event (late phase reaction).

Cromolyn and nedocromil **inhibit mast cell degranulation** and prevent release of preformed chemical mediators. These medications do not influence bronchial constriction directly; therefore, they are typically used to prevent acute attacks, rather than to treat acute exacerbations. Even though these drugs are less efficacious than inhaled glucocorticoids, they are very effective prophylactic agents for patients with seasonal symptoms, aspirin hypersensitivity, and exercise-induced asthma.

(Choice A) The anti-IgE antibody, omalizumab, inhibits IgE binding to mast cells, preventing mast cell degranulation. Omalizumab is used in some patients with severe, persistent asthma to lower IgE levels and reduce allergen-induced bronchial constriction.

(Choice B) Cleavage of membrane phospholipids by the enzyme phospholipase A2 leads to the formation of arachidonic acid, which is in turn converted into prostaglandins and leukotrienes. By inhibiting phospholipase A2 synthesis, glucocorticoids inhibit the release of these downstream mediators, decreasing airway hyperresponsiveness and inflammation.

(Choices C and D) Zileuton is a selective inhibitor of the lipoxygenase pathway that leads to decreased formation of leukotrienes. Zafirlukast and montelukast are leukotriene receptor antagonists. These agents are typically used for chronic asthma prophylaxis.

(Choice F) Antihistamines are used to prevent and blunt an acute allergic response (as seen in allergic rhinitis) but have not been shown to improve bronchoconstriction in asthma.

Educational objective:
Cromolyn and nedocromil are mast cell-stabilizing agents that inhibit mast cell degranulation independent of the triggering stimulus. They are less effective than inhaled glucocorticoids and are considered second-line treatments for allergic rhinitis and bronchial asthma.

References

- The effects of anti-asthma drugs on mediator release from cultured human mast cells.

https://t.me/USMLEWorldStep1

Acute **bronchial constriction** during an asthma exacerbation begins with **mast cell activation** secondary to allerge
This re
edema
cells (
severa

Crom
media
prever
inhale
hypers

(Choi
degra
reduce

(Choi
arachi
synthe
hyperr

(Choi
of leuk
for chr

(Choi
but ha

Educa
Cromo
triggering stimulus. They are less effective than inhaled glucocorticoids and are considered second-line treatments

Exhibit Display

Arachidonic acid metabolic pathways in asthma

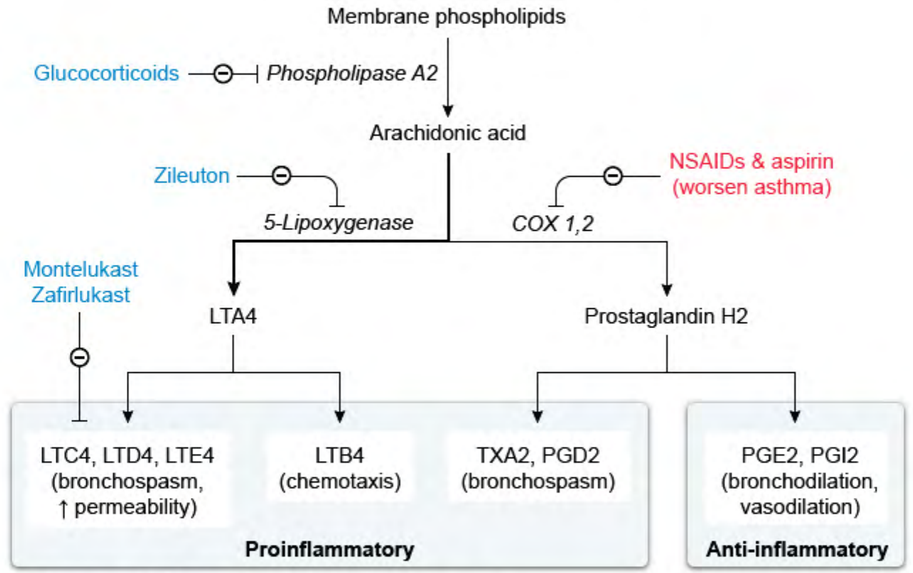

LT = leukotriene; **NSAIDs** = nonsteroidal anti-inflammatory drugs;
PG = prostaglandin; **TX** = thromboxane.

©UWorld

Zoom In | Zoom Out | Reset | New | Existing | My Notebook

triggering stimulus. They are less effective than inhaled glucocorticoids and are considered second-line treatments

https://t.me/USMLEWorldStep1

A 34-year-old woman comes to the office for evaluation of recurrent transient pulmonary infiltrates. The patient has a history of bronchial asthma and has had several exacerbations over the past few years, particularly during the winter months. She is currently asymptomatic. She has no other medical problems and has never traveled outside the United States. Her medications include albuterol as needed and medium-dose inhaled glucocorticoids. Temperature is 37.1 C (98.8 F). Physical examination is unremarkable. Complete blood count shows eosinophilia. A chest CT scan reveals proximal bronchiectasis. This patient's condition is most likely related to colonization with which of the following?

- A. Adenovirus
- B. *Aspergillus fumigatus*
- C. *Legionella pneumophila*
- D. *Pseudomonas aeruginosa*
- E. *Streptococcus pneumoniae*
- F. *Strongyloides stercoralis*

Submit

https://t.me/USMLEWorldStep1

A 34-year-old woman comes to the office for evaluation of recurrent transient pulmonary infiltrates. The patient has a history of bronchial asthma and has had several exacerbations over the past few years, particularly during the winter months. She is currently asymptomatic. She has no other medical problems and has never traveled outside the United States. Her medications include albuterol as needed and medium-dose inhaled glucocorticoids. Temperature is 37.1 C (98.8 F). Physical examination is unremarkable. Complete blood count shows eosinophilia. A chest CT scan reveals proximal bronchiectasis. This patient's condition is most likely related to colonization with which of the following?

- A. Adenovirus (5%)
- ✓ B. *Aspergillus fumigatus* (53%)
- C. *Legionella pneumophila* (4%)
- D. *Pseudomonas aeruginosa* (9%)
- E. *Streptococcus pneumoniae* (6%)
- F. *Strongyloides stercoralis* (20%)

Correct

53% Answered correctly

03 secs Time Spent

2023 Version

Explanation

Allergic bronchopulmonary aspergillosis (ABPA)	
History	• **A**sthma • Cystic fibrosis
Chest imaging	• Recurrent fleeting infiltrates • **B**ronchiectasis

https://t.me/USMLEWorldStep1

Explanation

Allergic bronchopulmonary aspergillosis (ABPA)	
History	• **A**sthma • Cystic fibrosis
Chest imaging	• Recurrent fleeting infiltrates • **B**ronchiectasis
Diagnosis	• **P**ositive ***Aspergillus*** skin test &/or IgE • Elevated serum IgE • Eosinophilia

Aspergillus fumigatus is a low virulence fungus that generally does not cause significant infections except in immunocompromised or debilitated patients. It may, however, colonize the bronchial mucosa. Patients with asthma or cystic fibrosis in particular may develop an allergic **hypersensitivity** reaction to the fungus. The result is **allergic bronchopulmonary aspergillosis (ABPA)**, which occurs in 5%-10% of corticosteroid-dependent **asthmatics**. Patients with ABPA have very high serum IgE levels, **eosinophilia**, and IgE plus IgG serum antibodies to *Aspergillus*. There is intense airway inflammation and mucus plugging with exacerbations and remissions. Repeated exacerbations may produce transient pulmonary infiltrates and proximal **bronchiectasis**.

(Choice A) Although viral respiratory infections can cause asthma exacerbations and adenovirus colonization of the lung may be associated with asthma chronicity, pure viral pneumonias do not progress to bronchiectasis.

(Choice C) Asthmatics do not have a predisposition to lung colonization with *Legionella*.

(Choice D) *Pseudomonas aeruginosa* is an opportunistic, aerobic gram-negative rod that is a frequent, and sometimes deadly, pulmonary pathogen in patients with cystic fibrosis or neutropenia.

(Choice E) Although asthma may be a risk factor for the development of pneumococcal lung colonization and pneumonia, pneumococcal disease generally results in resolution with preservation of lung lobular architecture. Potential complications of pneumococcal bronchopneumonia or lobar pneumonia include lung abscess, empyema,

https://t.me/USMLEWorldStep1

	Bronchiectasis
Diagnosis	• **P**ositive ***Aspergillus*** skin test &/or IgE • Elevated serum IgE • Eosinophilia

Aspergillus fumigatus is a low virulence fungus that generally does not cause significant infections except in immunocompromised or debilitated patients. It may, however, colonize the bronchial mucosa. Patients with asthma or cystic fibrosis in particular may develop an allergic **hypersensitivity** reaction to the fungus. The result is **allergic bronchopulmonary aspergillosis (ABPA)**, which occurs in 5%-10% of corticosteroid-dependent **asthmatics**. Patients with ABPA have very high serum IgE levels, **eosinophilia**, and IgE plus IgG serum antibodies to *Aspergillus*. There is intense airway inflammation and mucus plugging with exacerbations and remissions. Repeated exacerbations may produce transient pulmonary infiltrates and proximal **bronchiectasis**.

(Choice A) Although viral respiratory infections can cause asthma exacerbations and adenovirus colonization of the lung may be associated with asthma chronicity, pure viral pneumonias do not progress to bronchiectasis.

(Choice C) Asthmatics do not have a predisposition to lung colonization with *Legionella*.

(Choice D) *Pseudomonas aeruginosa* is an opportunistic, aerobic gram-negative rod that is a frequent, and sometimes deadly, pulmonary pathogen in patients with cystic fibrosis or neutropenia.

(Choice E) Although asthma may be a risk factor for the development of pneumococcal lung colonization and pneumonia, pneumococcal disease generally results in resolution with preservation of lung lobular architecture. Potential complications of pneumococcal bronchopneumonia or lobar pneumonia include lung abscess, empyema, and lung fibrosis. Bronchiectasis is not a common outcome of pneumococcal pulmonary disease.

(Choice F) Strongyloidiasis is typically asymptomatic but can sometimes cause pulmonary symptoms (eg, cough, asthma-like bronchospasm, hemoptysis) or a transient pneumonia as the larvae migrate through the lungs on their way to the laryngopharynx. However, progression to bronchiectasis is not commonly reported.

Educational objective:
Allergic bronchopulmonary aspergillosis (ABPA) due to *Aspergillus fumigatus* may complicate asthma. ABPA can result in transient recurrent pulmonary infiltrates and eventual proximal bronchiectasis.

https://t.me/USMLEWorldStep1

A 53-year-old man comes to the emergency department due to progressively worsening shortness of breath, nonproductive cough, and low-grade fevers over the past 2 weeks. He has not had a runny nose or sore throat and does not recall any sick contacts. He received a lung transplant for idiopathic pulmonary fibrosis 4 months ago. His medications include immunosuppressants and trimethoprim-sulfamethoxazole. Temperature is 37.8 C (100 F). Chest x-ray reveals diffuse interstitial infiltrates bilaterally. A decrease in pulmonary function is noted on testing. A lung biopsy specimen is shown below.

Which of the following best characterizes the organism most likely responsible for this patient's current condition?

- A. Enveloped double-stranded DNA virus
- B. Enveloped single-stranded RNA virus
- C. Filamentous gram-positive rods
- D. Nonenveloped double-stranded DNA virus
- E. Nonenveloped single-stranded RNA virus
- F. Trophic and cystic fungal forms

Submit

https://t.me/USMLEWorldStep1

A 53-year-old man comes to the emergency department due to progressively worsening shortness of breath, nonproductive cough, and low-grade fevers over the past 2 weeks. He has not had a runny nose or sore throat and does not recall any sick contacts. He received a lung transplant for idiopathic pulmonary fibrosis 4 months ago. His medications include immunosuppressants and trimethoprim-sulfamethoxazole. Temperature is 37.8 C (100 F). Chest x-ray reveals diffuse interstitial infiltrates bilaterally. A decrease in pulmonary function is noted on testing. A lung biopsy specimen is shown below.

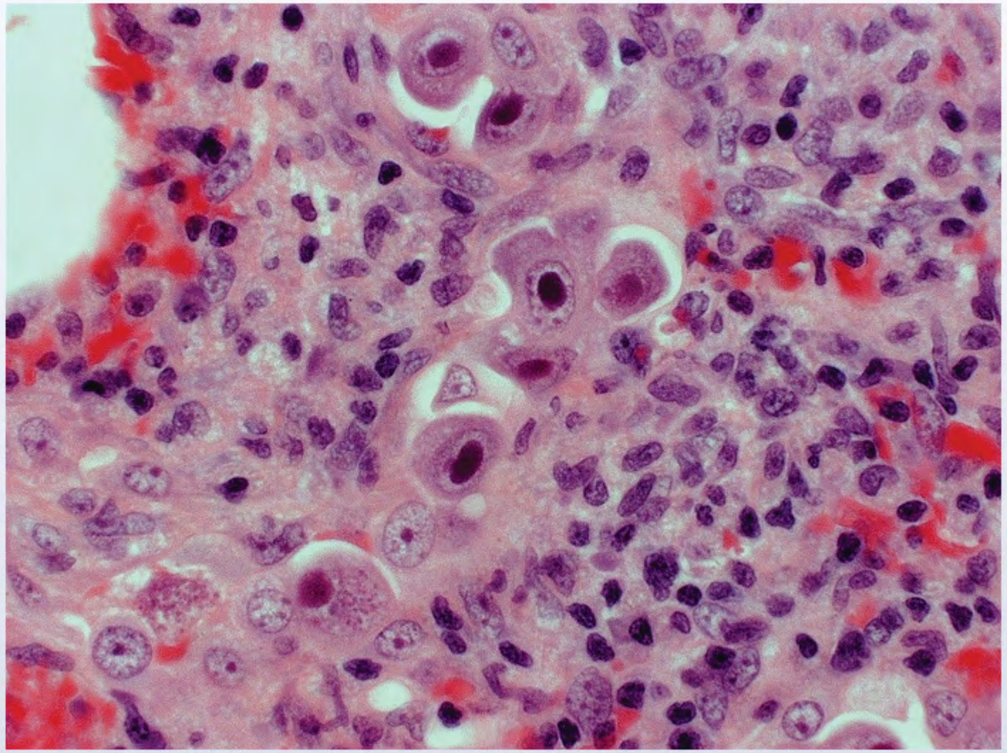

Which of the following best characterizes the organism most likely responsible for this patient's current condition?

- A. Enveloped double-stranded DNA virus
- B. Enveloped single-stranded RNA virus

https://t.me/USMLEWorldStep1

A 53-year-old man comes to the emergency department due to progressively worsening shortness of breath,
nonpr
and d
ago. H
(100 F
testing

Exhibit Display

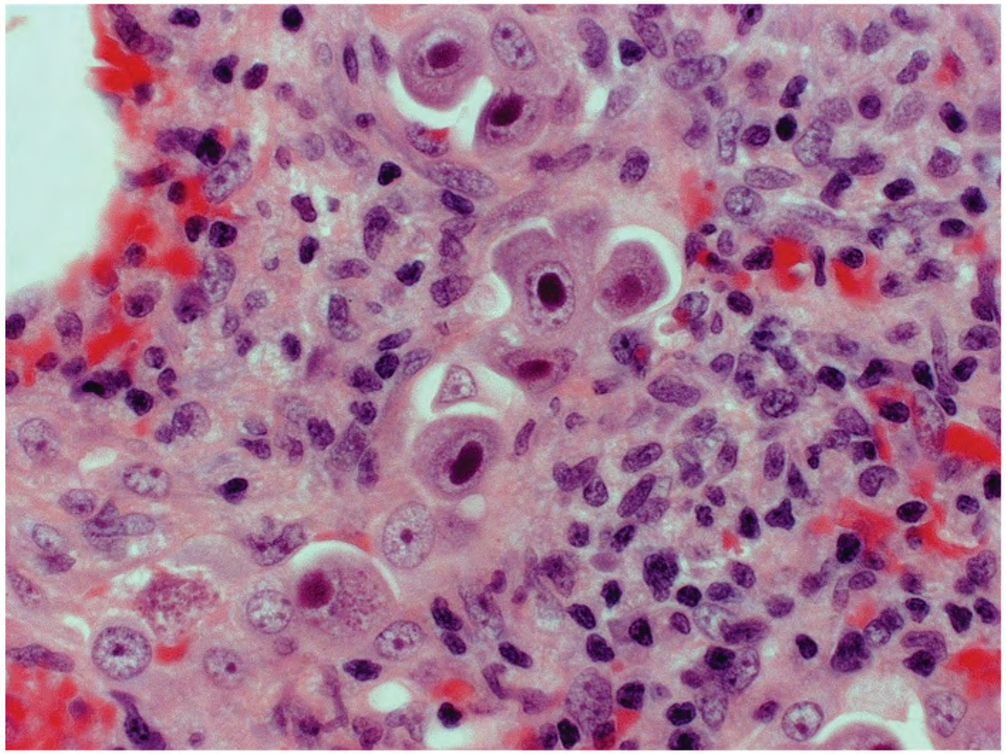

Zoom In Zoom Out Reset New | Existing My Notebook

Which

A. Enveloped double-stranded DNA virus

B. Enveloped single-stranded RNA virus

https://t.me/USMLEWorldStep1

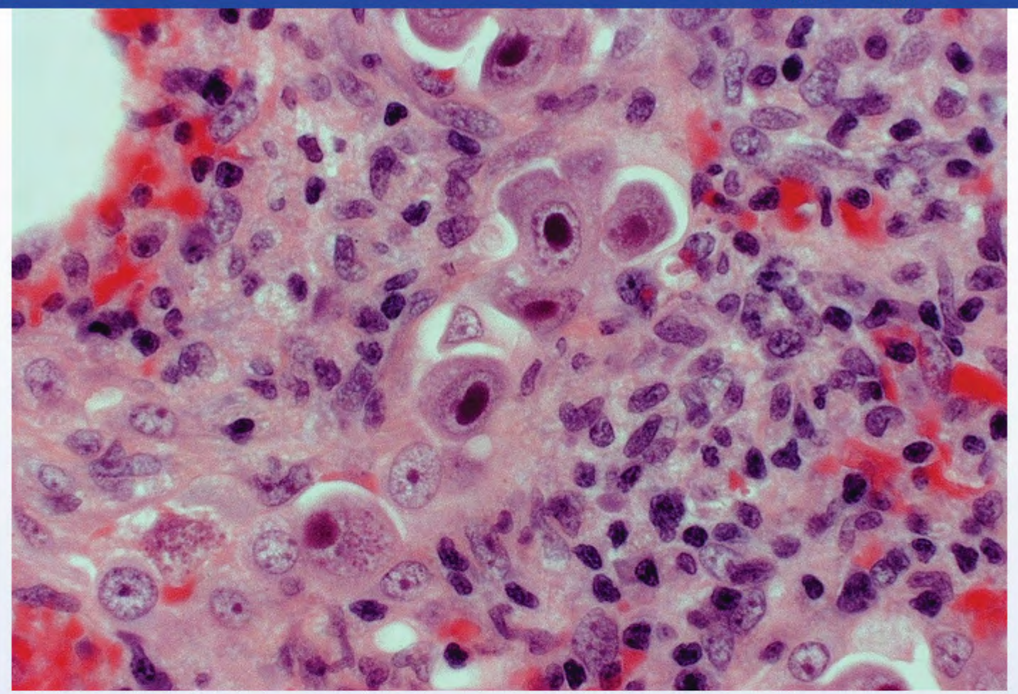

Which of the following best characterizes the organism most likely responsible for this patient's current condition?

- A. Enveloped double-stranded DNA virus
- B. Enveloped single-stranded RNA virus
- C. Filamentous gram-positive rods
- D. Nonenveloped double-stranded DNA virus
- E. Nonenveloped single-stranded RNA virus
- F. Trophic and cystic fungal forms

Submit

https://t.me/USMLEWorldStep1

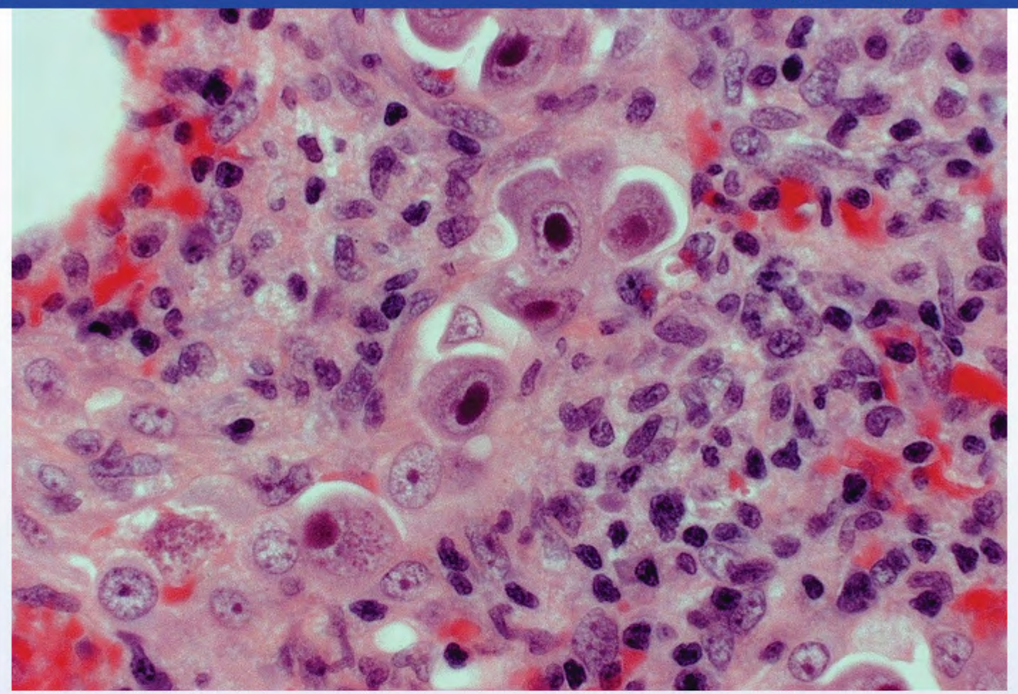

Which of the following best characterizes the organism most likely responsible for this patient's current condition?

- ✓ A. Enveloped double-stranded DNA virus (57%)
- ✗ B. Enveloped single-stranded RNA virus (6%)
- C. Filamentous gram-positive rods (4%)
- D. Nonenveloped double-stranded DNA virus (12%)
- E. Nonenveloped single-stranded RNA virus (3%)
- F. Trophic and cystic fungal forms (14%)

Incorrect
Correct answer
A

57%
Answered correctly

16 secs
Time Spent

2023
Version

https://t.me/USMLEWorldStep1

E. Nonenveloped single-stranded RNA virus (3%)

Exhibit Display

CMV pneumonitis

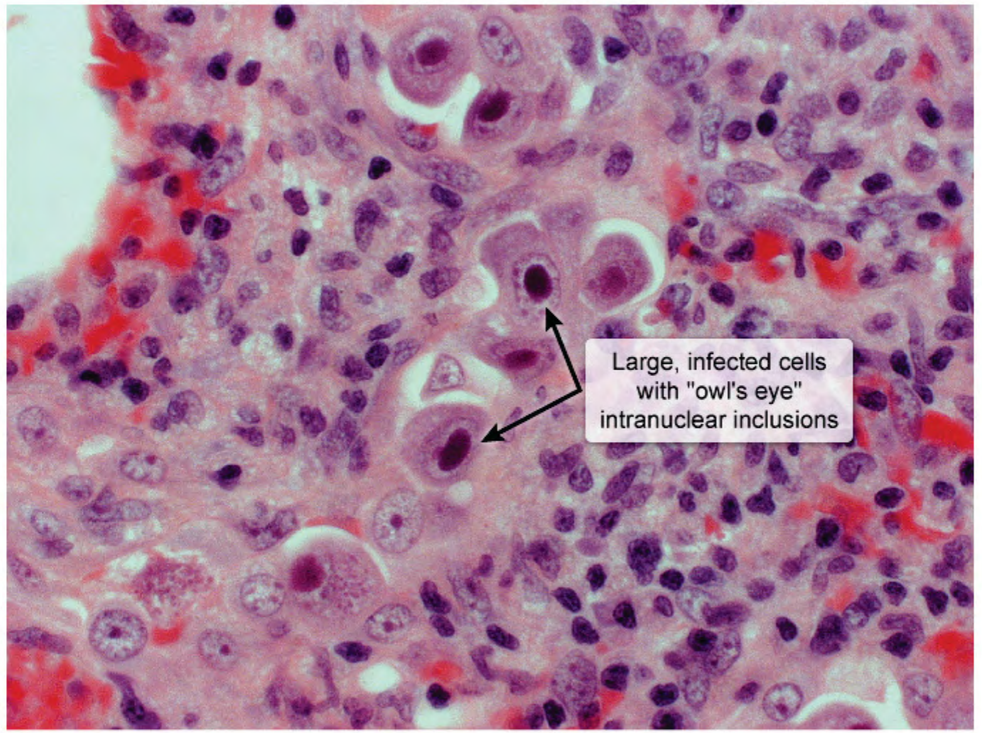

©UWorld

Zoom In | Zoom Out | Reset | New | Existing | My Notebook

©UWorld

https://t.me/USMLEWorldStep1

Transplant patients are at risk for a variety of unusual infections due to their immunocompromised state. **Cytomegalovirus** (CMV) is particularly common in patients with **lung transplants** (typically occurring within the first few months after transplant). Most but not all transplant centers practice universal prophylaxis for lung transplant recipients (eg, valganciclovir).

CMV is an **enveloped double-stranded DNA** virus belonging to the *Herpesviridae* family. Major risk groups for infections include transplant patients, patients with HIV, and fetuses (congenital infections). CMV **pneumonitis** is the most common form of tissue-invasive CMV following lung transplantation; other organ-specific disease manifestions (eg, esophagitis, colitis, and retinitis) occur more frequently in patients with HIV.

Biopsy findings consistent with CMV include enlarged cells with **intranuclear and intracytoplasmic inclusions** (viral particles); there is often a surrounding halo (**owl's eye**).

(Choices B, D, and E) Influenza viruses are enveloped single-stranded RNA viruses. Rhinovirus (a cause of the common cold) is a nonenveloped single-stranded RNA virus. Adenovirus is a nonenveloped double-stranded DNA virus. Although these viruses can cause respiratory illness, this patient's clinical features (2 weeks of progressive symptoms, impaired pulmonary function, no upper respiratory infection symptoms) and histologic findings make post-transplant CMV pneumonitis a more likely diagnosis, particularly given the lack of CMV prophylaxis.

(Choice C) Organs affected by *Nocardia* and *Actinomyces* show filamentous branching beaded gram-positive rods in Gram stain preparations. *Nocardia* is aerobic and positive for modified acid-fast stain; *Actinomyces* is anaerobic and negative for modified acid-fast stain.

(Choice F) Histopathologic and cytologic findings in *Pneumocystis jirovecii* pneumonia (PCP) include eosinophilic foamy alveolar material and cystic and trophic forms that can be stained with Giemsa or silver stain (producing a cup-in-saucer appearance). In addition, PCP is more common in patients with advanced HIV than in transplant patients and would be unlikely in this patient on PCP prophylaxis with trimethoprim-sulfamethoxazole.

Educational objective:
In a transplant patient, pneumonia with intranuclear and cytoplasmic inclusion bodies histologically points to opportunistic infection with cytomegalovirus, an enveloped virus that contains a double-stranded DNA genome.

References

https://t.me/USMLEWorldStep1

Transplant patients are at risk for a variety of unusual infections due to their immunocompromised state.

Cytom
first fe
transp

CMV i
infecti
the mo
manife

Biopsy
(viral p

(Choi
comm
virus.
sympt
post-tr

(Choi
rods ir
anaero

(Choi
foamy
cup-in
patien

Educa
In a tra
opport

References

Exhibit Display

Nocardia

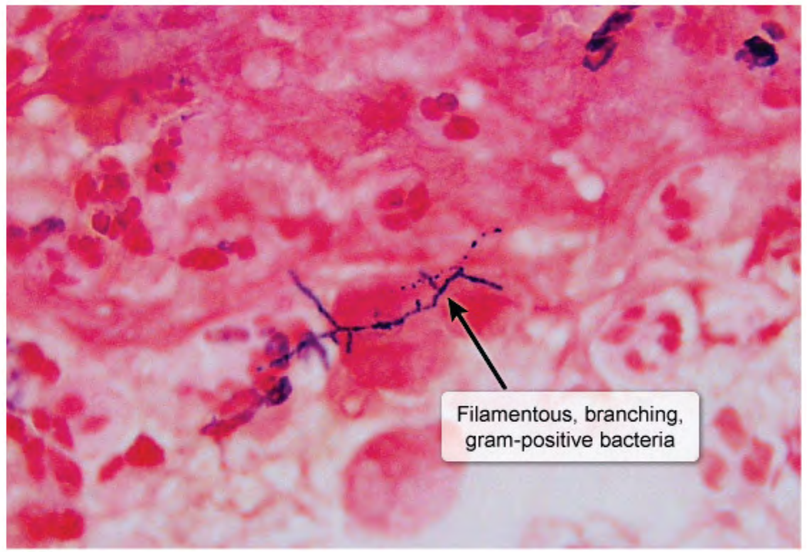

©UWorld

Zoom In | Zoom Out | Reset | New | Existing | My Notebook

https://t.me/USMLEWorldStep1

Transplant patients are at risk for a variety of unusual infections due to their immunocompromised state.

Cytom
first fe
transp

CMV i
infecti
the mo
manife

Biopsy
(viral p

(Choi
comm
virus.
sympt
post-tr

(Choi
rods ir
anaero

(Choi
foamy
cup-in
patien

Educa
In a tra
opport

References

Exhibit Display

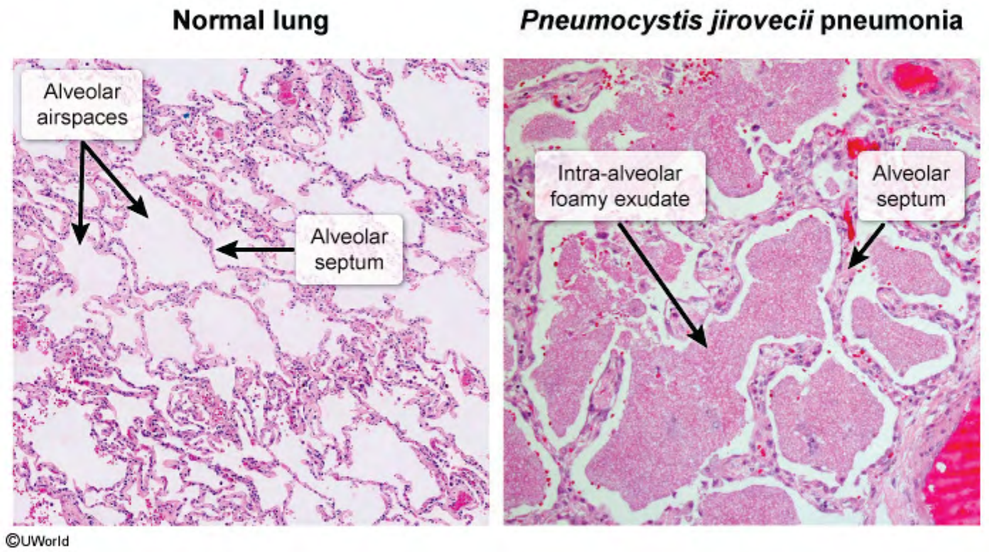

Zoom In | Zoom Out | Reset | New | Existing | My Notebook

https://t.me/USMLEWorldStep1

Transplant patients are at risk for a variety of unusual infections due to their immunocompromised state.

Cytom
first fe
transp

CMV i
infecti
the mo
manife

Biopsy
(viral p

(Choi
comm
virus.
sympt
post-tr

(Choi
rods ir
anaero

(Choi
foamy
cup-in
patien

Educa
In a tra
opport

References

Exhibit Display

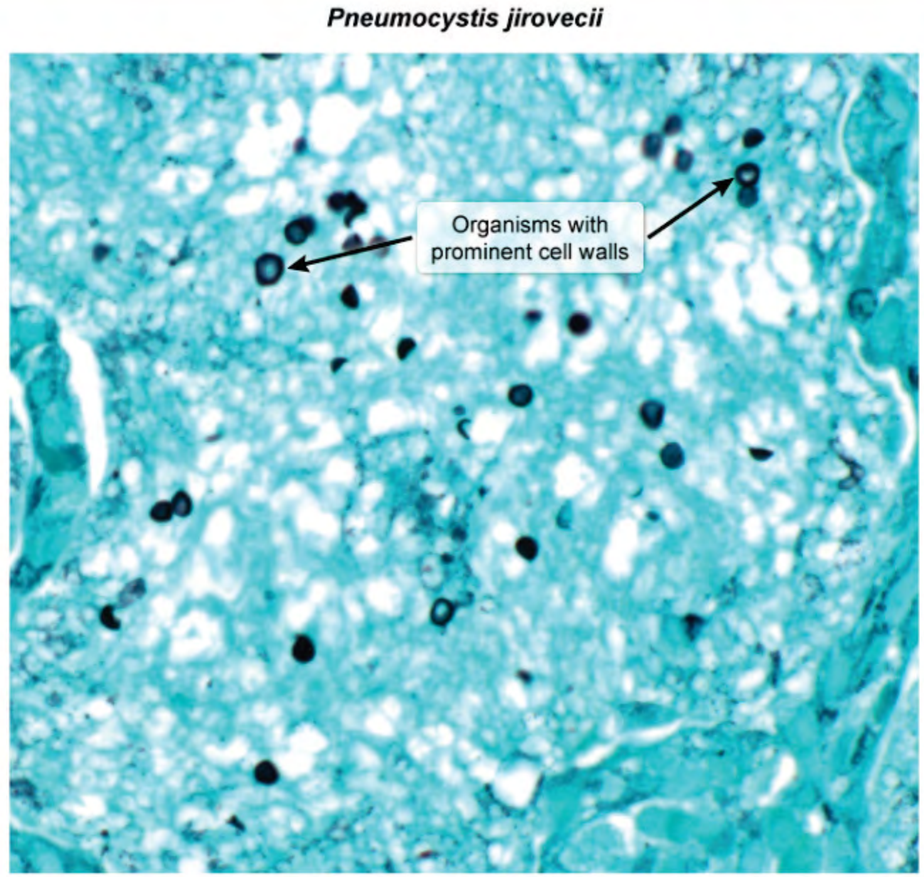

Zoom In | Zoom Out | Reset | New | Existing | My Notebook

https://t.me/USMLEWorldStep1

A 52-year-old man comes to the office with 3 weeks of cough, night sweats, and occasional hemoptysis. The patient also has type 2 diabetes mellitus and hypertension. He emigrated from Vietnam 15 years ago to start a job as an associate professor at a university. He has a 20 pack-year smoking history but quit 5 years ago. Sputum cultures grown on a selective medium demonstrate mycobacteria that grow in parallel chains forming serpentine cords under microscopy. This observed growth pattern most strongly correlates with which of the following bacterial characteristics?

- A. Acid-fastness
- B. Antibiotic resistance
- C. Pigmentation
- D. Replication rate
- E. Virulence

Submit

https://t.me/USMLEWorldStep1

A 52-year-old man comes to the office with 3 weeks of cough, night sweats, and occasional hemoptysis. The patient also has type 2 diabetes mellitus and hypertension. He emigrated from Vietnam 15 years ago to start a job as an associate professor at a university. He has a 20 pack-year smoking history but quit 5 years ago. Sputum cultures grown on a selective medium demonstrate mycobacteria that grow in parallel chains forming serpentine cords under microscopy. This observed growth pattern most strongly correlates with which of the following bacterial characteristics?

- A. Acid-fastness (38%)
- ✗ B. Antibiotic resistance (5%)
- C. Pigmentation (1%)
- D. Replication rate (10%)
- ✓ E. Virulence (44%)

Incorrect
Correct answer
E

44%
Answered correctly

03 secs
Time Spent

2023
Version

Explanation

Mycobacterium tuberculosis has a classical morphologic appearance under microscopy. The cells are arranged in long, slender, serpentine cords due to the presence of a hydrophobic surface glycolipid called **cord factor**.

Cord factor is composed of two mycolic acid molecules bound to the disaccharide trehalose (trehalose dimycolate). In vivo, cord factor forms cylindrical micelles that surround the organism and **prevent macrophage-mediated destruction** within the phagolysosome. It also forms a highly toxic crystalline monolayer on hydrophobic surfaces (oil-water/air-water interface [eg, edge of cavitation]) that helps drive the formation of **caseating granulomas** (a hallmark of *M tuberculosis* infection).

(Choice A) Mycolic acid is the primary component of the cell wall of all *Mycobacterium* species and is the source

https://t.me/USMLEWorldStep1

Mycobacterium tuberculosis has a classical morphologic appearance under microscopy. The cells are arranged in long, slender, serpentine cords due to the presence of a hydrophobic surface glycolipid called **cord factor**.

Cord factor is composed of two mycolic acid molecules bound to the disaccharide trehalose (trehalose dimycolate). In vivo, cord factor forms cylindrical micelles that surround the organism and **prevent macrophage-mediated destruction** within the phagolysosome. It also forms a highly toxic crystalline monolayer on hydrophobic surfaces (oil-water/air-water interface [eg, edge of cavitation]) that helps drive the formation of **caseating granulomas** (a hallmark of *M tuberculosis* infection).

(Choice A) Mycolic acid is the primary component of the cell wall of all *Mycobacterium* species and is the source of their acid-fastness (ability to retain dye in the presence of acid). Although mycolic acid is a component of cord factor, it alone does not cause *M tuberculosis* to grow in a serpentine pattern. Other less virulent mycobacteria (eg, *M avium*) are also acid-fast but have lower concentrations of cord factor and do not typically form serpentine chains.

(Choice B) *M tuberculosis* antibiotic resistance is due largely to mutations in the genes responsible for the synthesis of mycolic acid (isoniazid) and mycobacterial RNA polymerase (rifampin). Antibiotic resistance does not cause the bacteria to grow in a serpentine pattern.

(Choice C) Pigment production is characteristic of some mycobacteria, especially nontuberculous organisms such as *M marinum*, but is not associated with cord formation.

(Choice D) The slow growth rate of *M tuberculosis* contributes to the need for prolonged antibiotic regimens due to decreased antibiotic responsiveness. However, it does not affect the ability of the organism to form serpentine cords.

Educational objective:
Mycobacterium tuberculosis grows in long, serpentine cords due to the presence of cord factor, a surface glycolipid, on the cell wall. Cord factor is a primary virulence factor of *M tuberculosis*; it protects the bacteria from digestion by macrophages and also leads to the formation of caseating granulomas.

References

- Multiple roles of cord factor in the pathogenesis of primary, secondary, and cavitary tuberculosis, including a

https://t.me/USMLEWorldStep1

C. Pigmentation (1%)

Exhibit Display

Mycobacterium tuberculosis

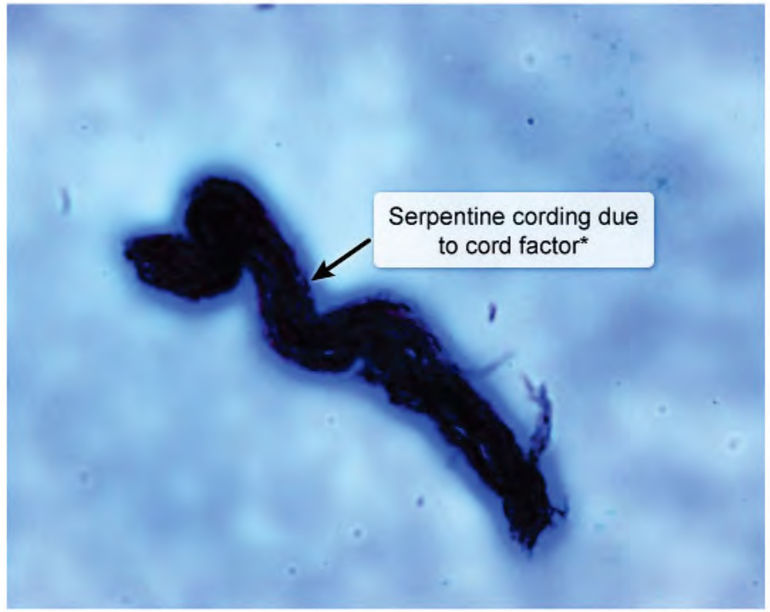

* Trehalose dimycolate (a cell wall glycolipid)

©UWorld

Zoom In | Zoom Out | Reset | New | Existing | My Notebook

Inco
Corre
E

Expl

Mycol
in long

Cord f
dimyc
media
hydrop
casea

(Choi
of thei
factor,
(eg, *M*
chains

(Choi
synthe
cause

(Choi
as *M marinum*, but is not associated with cord formation.

https://t.me/USMLEWorldStep1

A 55-year-old woman comes to the office due to a cough producing thick, yellowish sputum for the past 2 weeks. She has also had night sweats and increased fatigue over this time. Temperature is 38.3 C (101 F), blood pressure is 110/70 mm Hg, pulse is 88/min, and respirations are 20/min. There are crackles on lung auscultation. Chest imaging reveals a nonspecific pulmonary lesion. A transthoracic needle aspiration is performed. The specimen is cultured and grows several bacterial species, including *Peptostreptococcus* and *Fusobacterium*. Which of the following predisposing factors is most likely responsible for this patient's condition?

- A. Mitral valve prolapse
- B. Occult malignancy
- C. Penetrating chest trauma
- D. Seizure disorder
- E. Tobacco smoking
- F. Urinary infection

Submit

https://t.me/USMLEWorldStep1

A 55-year-old woman comes to the office due to a cough producing thick, yellowish sputum for the past 2 weeks. She has also had night sweats and increased fatigue over this time. Temperature is 38.3 C (101 F), blood pressure is 110/70 mm Hg, pulse is 88/min, and respirations are 20/min. There are crackles on lung auscultation. Chest imaging reveals a nonspecific pulmonary lesion. A transthoracic needle aspiration is performed. The specimen is cultured and grows several bacterial species, including *Peptostreptococcus* and *Fusobacterium*. Which of the following predisposing factors is most likely responsible for this patient's condition?

- A. Mitral valve prolapse (4%)
- ✗ B. Occult malignancy (7%)
- C. Penetrating chest trauma (6%)
- ✓ D. Seizure disorder (66%)
- E. Tobacco smoking (12%)
- F. Urinary infection (3%)

Incorrect
Correct answer
D

66%
Answered correctly

03 secs
Time Spent

2023
Version

Explanation

Peptostreptococcus and *Fusobacterium* are anaerobic bacteria that are part of normal mouth flora. The presence of these organisms in this patient's lung lesion is highly suggestive of a developing **lung abscess**. As an abscess evolves, it typically forms a cavitary lesion with an identifiable air-fluid level on imaging. Symptoms are often indolent and include fever, night sweats, weight loss, and a cough producing **foul-smelling sputum** (indicating anaerobes).

Lung abscesses are usually caused by one of the following:

- **Aspiration** of oral bacteria into the lower airways (most common). These abscesses are usually composed

https://t.me/USMLEWorldStep1

Peptostreptococcus and *Fusobacterium* are anaerobic bacteria that are part of normal mouth flora. The presence of these organisms in this patient's lung lesion is highly suggestive of a developing **lung abscess**. As an abscess evolves, it typically forms a cavitary lesion with an identifiable air-fluid level on imaging. Symptoms are often indolent and include fever, night sweats, weight loss, and a cough producing **foul-smelling sputum** (indicating anaerobes).

Lung abscesses are usually caused by one of the following:

- **Aspiration** of oral bacteria into the lower airways (most common) – These abscesses are usually composed of a combination of **anaerobic oral flora** (eg, *Peptostreptococcus, Prevotella, Bacteroides, Fusobacterium*) and aerobic organisms (eg, *Streptococcus*). Risk is greatest in those who have conditions associated with **loss of consciousness** or **impaired swallowing**, such as alcoholism, drug abuse, **neurologic disease** (eg, seizures, stroke), or anatomic abnormalities (eg, esophageal strictures or diverticula).
- Bacterial pneumonia – Lung abscess can occur in the setting of certain bacterial pneumonias such as those due to *Staphylococcus aureus*, *Escherichia coli*, *Klebsiella pneumoniae*, or *Pseudomonas aeruginosa*. Most cases arise in the hospital setting and occur in patients with immunosuppression, older age, or underlying lung disease.
- Bacteremia and/or infectious endocarditis – Hematogenous spread of an infection to the lung usually causes multiple, monomicrobial lung abscesses. The most common causative agents are *Staphylococcus* and *Streptococcus* species.

(Choice A) Mitral valve prolapse is a risk factor for development of subacute bacterial endocarditis (with *Streptococcus* species). Left-sided endocarditis could cause septic embolization to downstream organs (eg, spleen, brain) but would not send septic emboli to the lungs.

(Choice B) Bronchogenic carcinoma can cause bronchial obstruction and postobstructive pneumonia, which may lead to secondary abscess formation. However, these lung abscesses would be less likely to contain oral anaerobic flora.

(Choice C) Lung abscess may be associated with a prior penetrating trauma. *Staphylococcus* and *Streptococcus* species (introduced from the skin) are usually responsible

https://t.me/USMLEWorldStep1

due to *Staphylococcus aureus*, *Escherichia coli*, *Klebsiella pneumoniae*, or *Pseudomonas aeruginosa*. Most cases arise in the hospital setting and occur in patients with immunosuppression, older age, or underlying lung disease.

- Bacteremia and/or infectious endocarditis – Hematogenous spread of an infection to the lung usually causes multiple, monomicrobial lung abscesses. The most common causative agents are *Staphylococcus* and *Streptococcus* species.

(Choice A) Mitral valve prolapse is a risk factor for development of subacute bacterial endocarditis (with *Streptococcus* species). Left-sided endocarditis could cause septic embolization to downstream organs (eg, spleen, brain) but would not send septic emboli to the lungs.

(Choice B) Bronchogenic carcinoma can cause bronchial obstruction and postobstructive pneumonia, which may lead to secondary abscess formation. However, these lung abscesses would be less likely to contain oral anaerobic flora.

(Choice C) Lung abscess may be associated with a prior penetrating trauma. *Staphylococcus* and *Streptococcus* species (introduced from the skin) are usually responsible.

(Choice E) Tobacco smoking compromises pulmonary defenses and predisposes patients to developing community-acquired pneumonia due to common pathogens such as *Streptococcus pneumoniae* and *Mycoplasma pneumoniae*. These organisms are less likely to cause lung abscess.

(Choice F) Urinary infections can be associated with bacteremia, particularly in those with diabetes mellitus, advanced age, or structural urinary abnormalities. However, most urinary infections are caused by coliform bacteria (eg, *E coli*) from the lower gastrointestinal tract. Lung abscess is not a common complication of urinary infection, and *Peptostreptococcus* and *Fusobacterium* would be unusual urinary organisms.

Educational objective:
Lung abscess is most often due to aspiration of anaerobic oral bacteria such as *Peptostreptococcus, Prevotella, Bacteroides,* and *Fusobacterium* species. Risk factors for lung abscess include conditions that increase aspiration risk, such as alcoholism, drug abuse, seizure disorders, previous stroke, and dementia.

https://t.me/USMLEWorldStep1

F. Urinary infection (3%)

Exhibit Display

Lung abscess | Lung abscess

Lung abscess

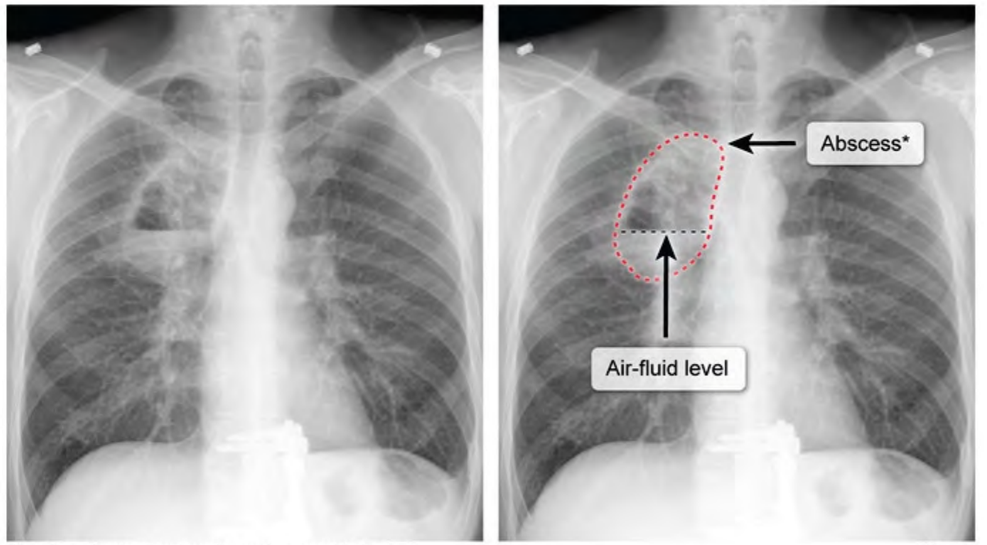

*Usually polymicrobial infection with anaerobic bacteria.

©UWorld

Zoom In | Zoom Out | Reset | New | Existing | My Notebook

(Choice A) Mitral valve prolapse is a risk factor for development of subacute bacterial endocarditis (with

https://t.me/USMLEWorldStep1

A 34-year-old man is being evaluated for acute hypoxemic respiratory failure. Two days ago, the patient was brought to the emergency department due to opioid and alcohol intoxication. While unconscious, he vomited profusely and then rapidly developed hypoxia and shortness of breath that has continued to worsen. Today, temperature is 38.4 C (101.1 F), blood pressure is 108/74 mm Hg, pulse is 120/min, and respirations are 26/min. Diffuse crackles are heard on auscultation. The extremities are warm, well perfused, and without edema. Chest x-ray reveals bilateral alveolar opacities. The results of arterial blood gas analysis on room air are as follows:

pH	7.25
Partial pressure of carbon dioxide in arterial blood	28 mm Hg
Partial pressure of oxygen in arterial blood	52 mm Hg

Which of the following pathologic processes is the primary contributor to this patient's lung findings?

- A. Diffuse alveolar hemorrhage due to autoantibodies
- B. Eosinophil invasion and hyaline membrane formation
- C. Lymphocyte-mediated granuloma formation around foreign antigens
- D. Release of reactive oxygen species and proteases by neutrophils

Submit

https://t.me/USMLEWorldStep1

A 34-year-old man is being evaluated for acute hypoxemic respiratory failure. Two days ago, the patient was brought to the emergency department due to opioid and alcohol intoxication. While unconscious, he vomited profusely and then rapidly developed hypoxia and shortness of breath that has continued to worsen. Today, temperature is 38.4 C (101.1 F), blood pressure is 108/74 mm Hg, pulse is 120/min, and respirations are 26/min. Diffuse crackles are heard on auscultation. The extremities are warm, well perfused, and without edema. Chest x-ray reveals bilateral alveolar opacities. The results of arterial blood gas analysis on room air are as follows:

pH	7.25
Partial pressure of carbon dioxide in arterial blood	28 mm Hg
Partial pressure of oxygen in arterial blood	52 mm Hg

Which of the following pathologic processes is the primary contributor to this patient's lung findings?

- ✗ A. Diffuse alveolar hemorrhage due to autoantibodies (1%)
- B. Eosinophil invasion and hyaline membrane formation (24%)
- C. Lymphocyte-mediated granuloma formation around foreign antigens (10%)
- ✓ D. Release of reactive oxygen species and proteases by neutrophils (62%)

Incorrect
Correct answer
D

62%
Answered correctly

06 secs
Time Spent

2023
Version

Explanation

https://t.me/USMLEWorldStep1

A. Diffuse alveolar hemorrhage due to autoantibodies (1%)

Exhibit Display

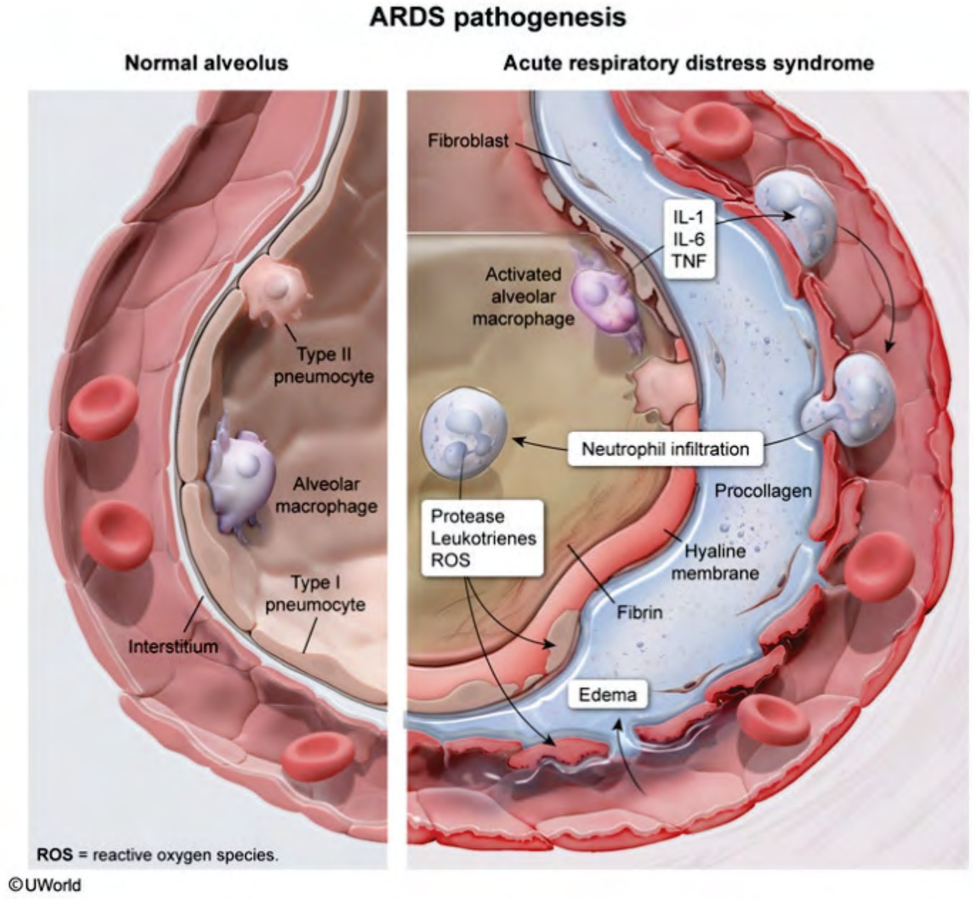

Zoom In | Zoom Out | Reset | New | Existing | My Notebook

https://t.me/USMLEWorldStep1

This patient has acute hypoxemic respiratory failure following an episode of emesis while unconscious. He most likely developed **acute respiratory distress syndrome** (ARDS) due to the aspiration of gastric contents.

Alveolar epithelial damage (eg, by gastric hydrochloric acid) causes **release of** damage-associated molecular patterns (**DAMPs**) (eg, mitochondrial DNA, extracellular histones) into the extracellular space. These DAMPs bind to pattern recognition receptors on innate immune cells, promoting the release of proinflammatory cytokines (eg, tumor necrosis factor-alpha, IL-1, IL-6) that recruit neutrophils to the alveoli. The **activated neutrophils** then release **proteases** and **reactive oxygen species** (ROS) that further damage the alveolar membrane.

The cascade of lung damage leads to failure of alveolar tight junctions and exudation of fibrinous proteinaceous fluid into the airspaces, resulting in **pulmonary edema**. Therefore, the origin of pulmonary edema in ARDS is **abnormal vascular permeability** rather than hydrostatic congestion due to left ventricular dysfunction (ie, noncardiogenic). Surfactant is depleted and dysfunctional, leading to alveolar collapse (increased surface tension causes alveolar walls to cling together), further impairing lung inflation. The flooding and collapse of alveoli produce diffuse crackles on lung auscultation and bilateral infiltrates on chest x-ray.

Several important clinical entities can **mimic ARDS**: diffuse alveolar hemorrhage (DAH), acute eosinophilic pneumonia (AEP), and acute hypersensitivity pneumonitis (HP). Like ARDS, these conditions present with acute severe hypoxemia, diffuse bilateral infiltrates, and fever. However, the pathophysiologic bases of these conditions are fundamentally different from that of ARDS.

(Choice A) DAH is characterized by widespread alveolar bleeding due typically to small-vessel vasculitis, which can be driven by autoantibodies (eg, against basement membrane collagen [anti-GBM disease]) causing pulmonary capillary necrosis with subsequent hemorrhage. ARDS is an innate immune response driven primarily by neutrophils rather than autoantibodies.

(Choice B) AEP is an idiopathic form of pneumonia caused by eosinophilic invasion of the lung tissue, often with hyaline membranes, a nonspecific finding of inflammatory fibrinous edema. ARDS also features prominent hyaline membranes, but the inflammation is driven by *neutrophils* rather than eosinophils.

(Choice C) HP is characterized by lymphocyte-driven granuloma formation in response to extrinsic antigens (eg, mold, bird dander). ARDS is characterized by neutrophilic, rather than granulomatous, inflammation.

https://t.me/USMLEWorldStep1

to pattern recognition receptors on innate immune cells, promoting the release of proinflammatory cytokines (eg, tumor necrosis factor-alpha, IL-1, IL-6) that recruit neutrophils to the alveoli. The **activated neutrophils** then release **proteases** and **reactive oxygen species** (ROS) that further damage the alveolar membrane.

The cascade of lung damage leads to failure of alveolar tight junctions and exudation of fibrinous proteinaceous fluid into the airspaces, resulting in **pulmonary edema**. Therefore, the origin of pulmonary edema in ARDS is **abnormal vascular permeability** rather than hydrostatic congestion due to left ventricular dysfunction (ie, noncardiogenic). Surfactant is depleted and dysfunctional, leading to alveolar collapse (increased surface tension causes alveolar walls to cling together), further impairing lung inflation. The flooding and collapse of alveoli produce diffuse crackles on lung auscultation and bilateral infiltrates on chest x-ray.

Several important clinical entities can **mimic ARDS**: diffuse alveolar hemorrhage (DAH), acute eosinophilic pneumonia (AEP), and acute hypersensitivity pneumonitis (HP). Like ARDS, these conditions present with acute severe hypoxemia, diffuse bilateral infiltrates, and fever. However, the pathophysiologic bases of these conditions are fundamentally different from that of ARDS.

(Choice A) DAH is characterized by widespread alveolar bleeding due typically to small-vessel vasculitis, which can be driven by autoantibodies (eg, against basement membrane collagen [anti-GBM disease]) causing pulmonary capillary necrosis with subsequent hemorrhage. ARDS is an innate immune response driven primarily by neutrophils rather than autoantibodies.

(Choice B) AEP is an idiopathic form of pneumonia caused by eosinophilic invasion of the lung tissue, often with hyaline membranes, a nonspecific finding of inflammatory fibrinous edema. ARDS also features prominent hyaline membranes, but the inflammation is driven by *neutrophils* rather than eosinophils.

(Choice C) HP is characterized by lymphocyte-driven granuloma formation in response to extrinsic antigens (eg, mold, bird dander). ARDS is characterized by neutrophilic, rather than granulomatous, inflammation.

Educational objective:
Acute respiratory distress syndrome involves acute neutrophilic lung inflammation with widespread alveolar damage due to proteases and reactive oxygen species, leading to failure of the vascular barrier and exudative pulmonary edema.

https://t.me/USMLEWorldStep1

A 21-year-old man is brought to the emergency department after being found unresponsive in a public restroom. He has a history of injection drug use. Temperature is 36.1 C (97 F), blood pressure is 110/70 mm Hg, pulse is 62/min, and respiratory rate is 8/min. On physical examination, the patient is unconscious with pinpoint pupils. Endotracheal intubation is performed, and mechanical ventilation is begun. The ventilator settings are adjusted to provide a minute ventilation of 6.0 L/min. Calculated alveolar ventilation is 4.2 L/min. Which of the following most likely accounts for the difference between these 2 parameters?

- A. Dead space volume
- B. Functional residual capacity
- C. Residual volume
- D. Respiratory rate
- E. Tidal volume

Submit

https://t.me/USMLEWorldStep1

A 21-year-old man is brought to the emergency department after being found unresponsive in a public restroom. He has a history of injection drug use. Temperature is 36.1 C (97 F), blood pressure is 110/70 mm Hg, pulse is 62/min, and respiratory rate is 8/min. On physical examination, the patient is unconscious with pinpoint pupils. Endotracheal intubation is performed, and mechanical ventilation is begun. The ventilator settings are adjusted to provide a minute ventilation of 6.0 L/min. Calculated alveolar ventilation is 4.2 L/min. Which of the following most likely accounts for the difference between these 2 parameters?

- ✓ A. Dead space volume (83%)
- B. Functional residual capacity (3%)
- C. Residual volume (6%)
- D. Respiratory rate (5%)
- E. Tidal volume (2%)

Correct

83%
Answered correctly

15 mins, 44 secs
Time Spent

2023
Version

Explanation

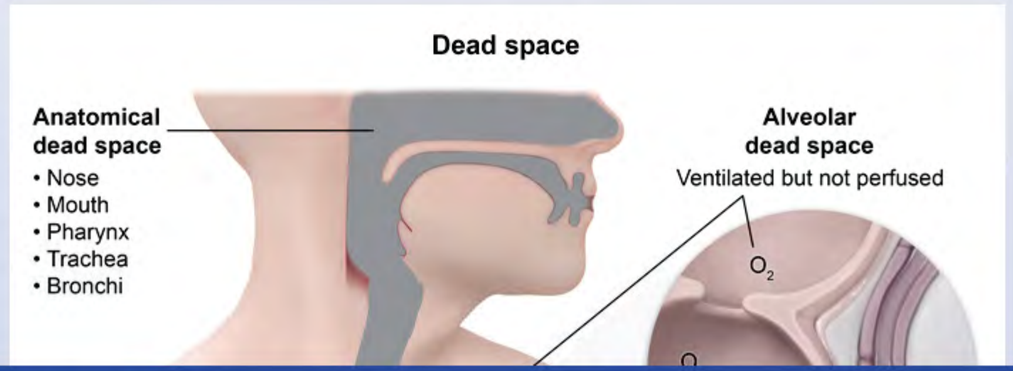

https://t.me/USMLEWorldStep1

A 21-year-old man is brought to the emergency department after being found unresponsive in a public restroom.
He has
62/min
Endotr
provid
likely a

Cor

Expl

Exhibit Display

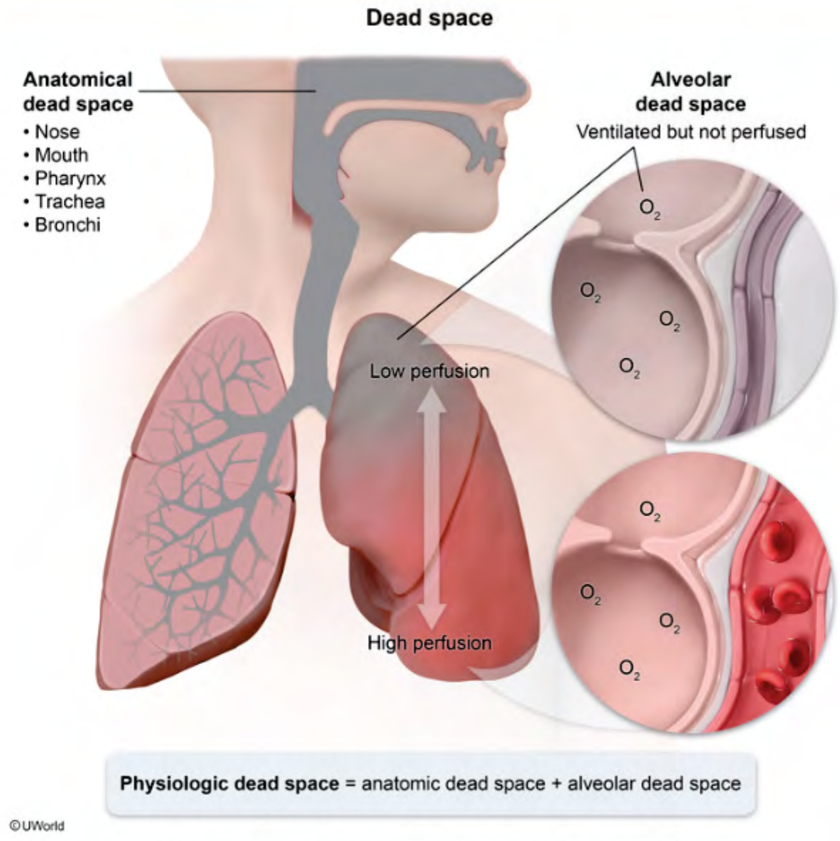

Zoom In | Zoom Out | Reset | New | Existing | My Notebook

https://t.me/USMLEWorldStep1

Minute ventilation is the **total volume of new air** that enters the respiratory pathways per minute. It can be calculated by multiplying the average tidal volume by the number of breaths per minute (minute ventilation [L/min] = tidal volume [L] x breaths/min).

Alveolar ventilation refers only to the **volume of new air reaching the gas exchange areas** (ie, alveoli and respiratory bronchioles) per minute. It can be calculated by **subtracting dead space volume** (which does not participate in gas exchange) **from the tidal volume**:

Alveolar ventilation (L/min) = (tidal volume − dead space volume) × breaths/min

The total volume of dead space in the lungs is known as physiologic dead space. It consists of both the **anatomic dead space** of the conducting airways (ie, nose, trachea, bronchi, bronchioles; normally ~150 mL) and alveolar dead space due to well-ventilated but poorly perfused alveoli. Because it is difficult to directly measure physiologic dead space, it is often estimated in mechanically ventilated patients by comparing arterial (a) and expiratory (E) pCO_2 levels:

Physiologic dead space = tidal volume × $([P_aCO_2 - P_ECO_2]/P_aCO_2)$

(Choices B and C) Functional residual capacity is the volume of air remaining in the lungs after a normal exhalation. It is the sum of residual volume (the volume of air remaining in the lungs after maximal exhalation) and expiratory reserve volume (the volume difference between normal end-expiration and maximal end-expiration).

(Choice D) Respiratory rate is the number of breaths taken per minute and is a factor in calculating both minute ventilation and alveolar ventilation.

(Choice E) Tidal volume is the volume of new air that enters the lungs with each normal, unforced breath. It is a factor in calculating both minute ventilation and alveolar ventilation.

Educational objective:
Minute ventilation is equal to the product of tidal volume and respiratory rate and includes dead space ventilation. Alveolar ventilation is equal to the product of respiratory rate and the difference between tidal volume and dead space volume.

Physiology Pulmonary & Critical Care Respiratory physiology

https://t.me/USMLEWorldStep1

Minute ventilation is the **total volume of new air** that enters the respiratory pathways per minute. It can be calcula
= tidal

Alveo
respira
partici

Alv

The to
dead s
dead s
dead s
pCO_2 l

Ph

(Choi
exhala
expira

(Choi
ventila

(Choi
factor

Educa
Minute
Alveol
space

Physiology Pulmonary & Critical Care Respiratory physiology

Exhibit Display

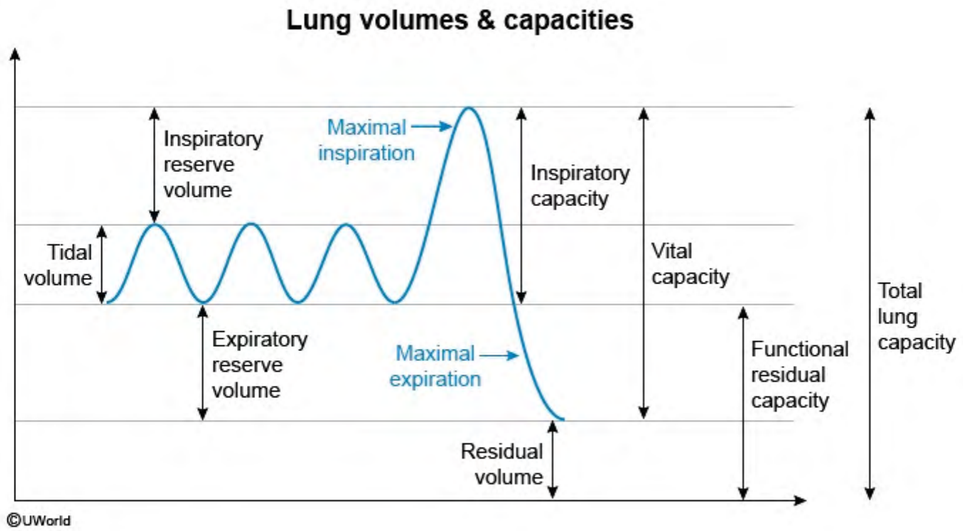

Zoom In Zoom Out Reset New | Existing My Notebook

https://t.me/USMLEWorldStep1

A 56-year-old man is brought to the emergency department due to burning substernal pain that began 6 hours ago. The patient has a history of type 2 diabetes mellitus and hypertension. He smokes 2 packs of cigarettes daily and consumes alcohol occasionally. An ECG performed in the emergency department shows ST segment elevation in leads I, aVL, and V3-V6. During the next several hours, the patient develops progressive shortness of breath that worsens when lying flat. Which of the following histologic features is most likely to be present in this patient's lung tissue?

- A. Fat globules and bone marrow cells in the pulmonary arterioles
- B. Focal necrosis of the alveolar walls with intraalveolar hemorrhage
- C. Neutrophil-rich fluid filling the bronchi, bronchioles, and alveoli
- D. Numerous hemosiderin-laden macrophages in the alveoli
- E. Engorged capillaries and alveoli filled with acellular pink material
- F. Prominent mononuclear cell infiltration in the interstitium

Submit

https://t.me/USMLEWorldStep1

A 56-year-old man is brought to the emergency department due to burning substernal pain that began 6 hours ago. The patient has a history of type 2 diabetes mellitus and hypertension. He smokes 2 packs of cigarettes daily and consumes alcohol occasionally. An ECG performed in the emergency department shows ST segment elevation in leads I, aVL, and V3-V6. During the next several hours, the patient develops progressive shortness of breath that worsens when lying flat. Which of the following histologic features is most likely to be present in this patient's lung tissue?

- A. Fat globules and bone marrow cells in the pulmonary arterioles (0%)
- ✗ B. Focal necrosis of the alveolar walls with intraalveolar hemorrhage (3%)
- C. Neutrophil-rich fluid filling the bronchi, bronchioles, and alveoli (7%)
- D. Numerous hemosiderin-laden macrophages in the alveoli (44%)
- ✓ E. Engorged capillaries and alveoli filled with acellular pink material (41%)
- F. Prominent mononuclear cell infiltration in the interstitium (2%)

Incorrect
Correct answer
E

41%
Answered correctly

03 secs
Time Spent

2023
Version

Explanation

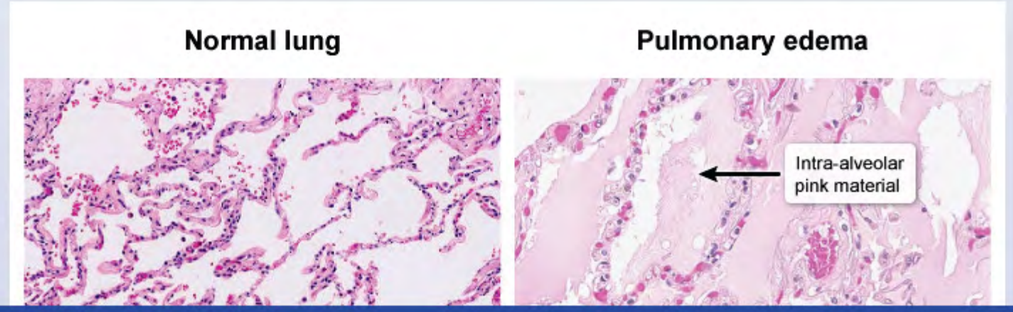

https://t.me/USMLEWorldStep1

A 56-year-old man is brought to the emergency department due to burning substernal pain that began 6 hours ago. T
and co
elevati
breath
patien

Inco
Corre
E

Expl

Exhibit Display

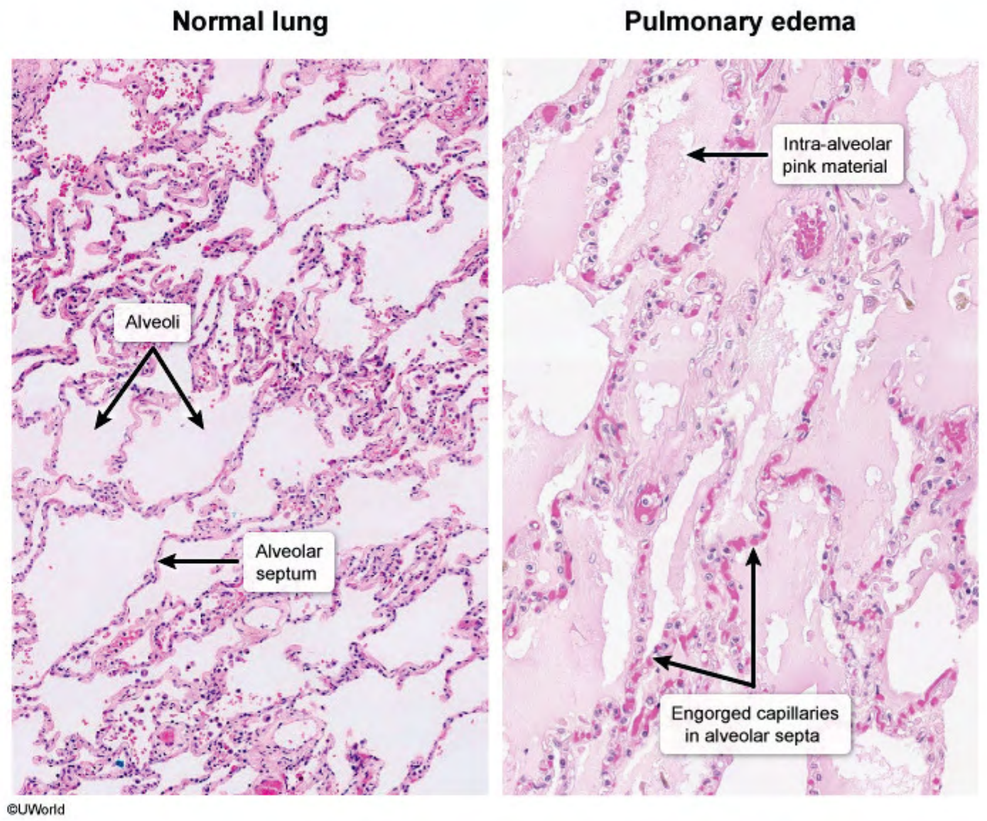

Zoom In | Zoom Out | Reset | New | Existing | My Notebook

https://t.me/USMLEWorldStep1

This patient has chest pain and ECG evidence of acute **myocardial infarction** (MI) involving the lateral wall of the left ventricle. His subsequent development of dyspnea and orthopnea is most likely due to MI-induced acute **left ventricular failure**, which can result in rapid onset of pulmonary venous hypertension and **acute pulmonary edema**.

Cardiogenic pulmonary edema represents increased filtration of fluid and electrolytes into the lung interstitium and alveoli. The fluid that accumulates is a **transudate** (an ultrafiltrate of plasma caused by changes in hydrostatic or oncotic pressure) rather than an exudate (an extravasation of not only fluid and electrolytes but also plasma proteins and circulating leukocytes due to inflammatory disruption of the vascular membrane). On light microscopy, engorged alveolar capillaries are evident and the intraalveolar transudate appears as **acellular pink material**.

(Choice A) Fat globules and bone marrow cells in the pulmonary arterioles occur with fat embolism syndrome, which is not a complication of MI but is typically associated with long bone (eg, femur) or pelvic fracture.

(Choice B) Focal necrosis of alveolar walls with intraalveolar hemorrhage is typical of pulmonary hemorrhage syndromes such as Goodpasture syndrome and other vasculitides (eg, hypersensitivity angiitis, granulomatosis with polyangiitis).

(Choice C) The presence of numerous neutrophils in the alveolar fluid is consistent with exudative alveolar filling, as occurs in bacterial pneumonia.

(Choice D) Hemosiderin-laden macrophages ("heart failure cells") form as macrophages digest red blood cells that leak from alveolar capillaries damaged by high intravascular pressure. They are a sign of chronic lung congestion and would not be present acutely.

(Choice F) Mononuclear interstitial pulmonary infiltrates are found in various interstitial lung diseases (eg, idiopathic pulmonary fibrosis).

Educational objective:
Acute pulmonary edema is a common consequence of acute myocardial infarction affecting the left ventricle. Elevated hydrostatic pressure in the pulmonary venous system leads to engorged alveolar capillaries with transudation of fluid into the alveoli, appearing as acellular pink material on microscopy. Hemosiderin-laden

https://t.me/USMLEWorldStep1

edema.

Cardiogenic pulmonary edema represents increased filtration of fluid and electrolytes into the lung interstitium and alveoli. The fluid that accumulates is a **transudate** (an ultrafiltrate of plasma caused by changes in hydrostatic or oncotic pressure) rather than an exudate (an extravasation of not only fluid and electrolytes but also plasma proteins and circulating leukocytes due to inflammatory disruption of the vascular membrane). On light microscopy, engorged alveolar capillaries are evident and the intraalveolar transudate appears as **acellular pink material**.

(Choice A) Fat globules and bone marrow cells in the pulmonary arterioles occur with fat embolism syndrome, which is not a complication of MI but is typically associated with long bone (eg, femur) or pelvic fracture.

(Choice B) Focal necrosis of alveolar walls with intraalveolar hemorrhage is typical of pulmonary hemorrhage syndromes such as Goodpasture syndrome and other vasculitides (eg, hypersensitivity angiitis, granulomatosis with polyangiitis).

(Choice C) The presence of numerous neutrophils in the alveolar fluid is consistent with exudative alveolar filling, as occurs in bacterial pneumonia.

(Choice D) Hemosiderin-laden macrophages ("heart failure cells") form as macrophages digest red blood cells that leak from alveolar capillaries damaged by high intravascular pressure. They are a sign of chronic lung congestion and would not be present acutely.

(Choice F) Mononuclear interstitial pulmonary infiltrates are found in various interstitial lung diseases (eg, idiopathic pulmonary fibrosis).

Educational objective:
Acute pulmonary edema is a common consequence of acute myocardial infarction affecting the left ventricle. Elevated hydrostatic pressure in the pulmonary venous system leads to engorged alveolar capillaries with transudation of fluid into the alveoli, appearing as acellular pink material on microscopy. Hemosiderin-laden macrophages are indicative of chronic lung congestion and are not present acutely.

Pathology	Pulmonary & Critical Care	Acute heart failure
Subject	System	Topic

https://t.me/USMLEWorldStep1

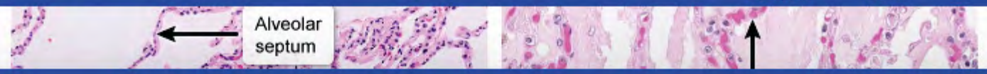

Exhibit Display

ECG leads & corresponding cardiac anatomy

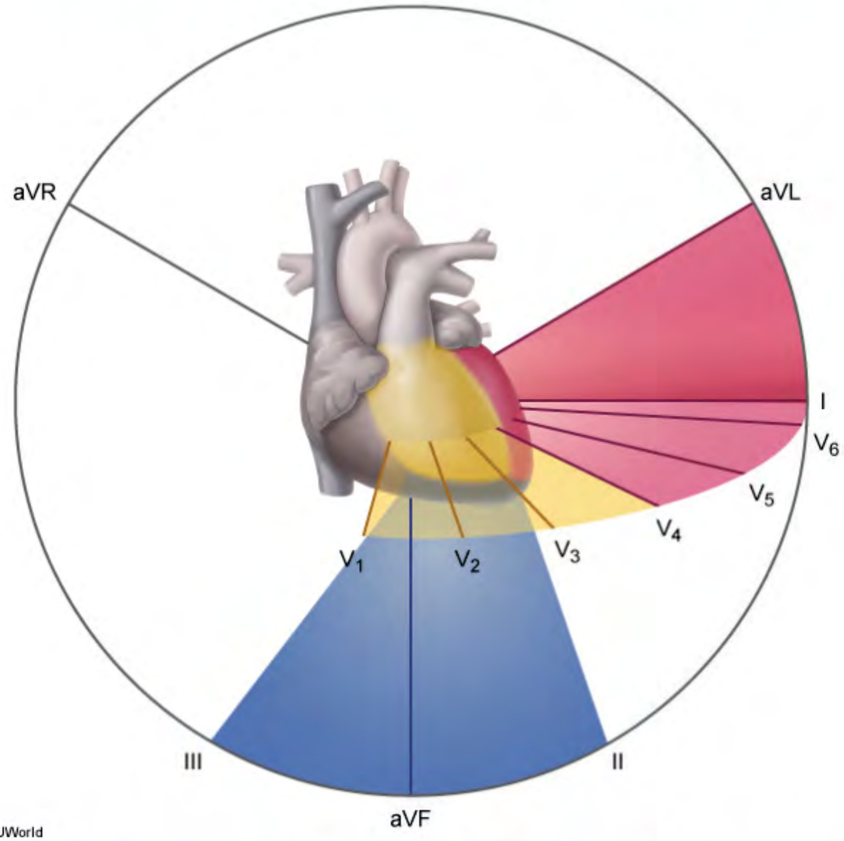

Zoom In | Zoom Out | Reset | New | Existing | My Notebook

This p
left ve
ventri
edema

Cardio
alveoli
oncoti
protein
micros
mater

(Choi
which

(Choi
syndro
with p

(Choi
as occ

(Choi
that leak from alveolar capillaries damaged by high intravascular pressure. They are a sign of chronic lung congestion and would not be present acutely.

https://t.me/USMLEWorldStep1

An autopsy is performed on a 6-month-old girl who was born at 25 weeks gestation and died of respiratory complications. A sample of the patient's lung tissue is obtained, and histopathologic examination shows few, dilated alveoli with decreased septation. Alveolar capillaries are dysmorphic, and pulmonary arterioles have narrow lumina with thick, muscular walls. These findings are most consistent with which of the following conditions?

- A. Bronchopulmonary dysplasia
- B. Congenital cystic adenomatoid malformation
- C. Neonatal infection
- D. Cystic fibrosis
- E. Pulmonary alveolar proteinosis

Submit

https://t.me/USMLEWorldStep1

An autopsy is performed on a 6-month-old girl who was born at 25 weeks gestation and died of respiratory complications. A sample of the patient's lung tissue is obtained, and histopathologic examination shows few, dilated alveoli with decreased septation. Alveolar capillaries are dysmorphic, and pulmonary arterioles have narrow lumina with thick, muscular walls. These findings are most consistent with which of the following conditions?

- ✓ A. Bronchopulmonary dysplasia (66%)
- B. Congenital cystic adenomatoid malformation (6%)
- C. Neonatal infection (2%)
- D. Cystic fibrosis (9%)
- E. Pulmonary alveolar proteinosis (15%)

Correct | 66% Answered correctly | 04 secs Time Spent | 2023 Version

Explanation

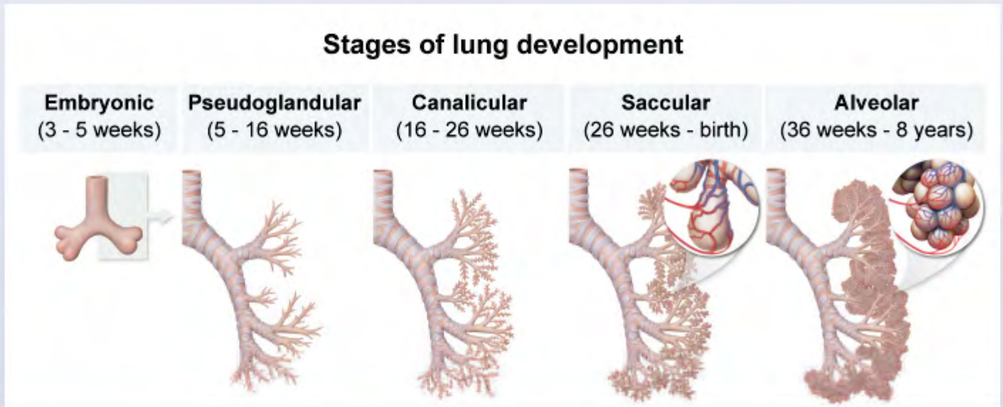

https://t.me/USMLEWorldStep1

An autopsy is performed on a 6-month-old girl who was born at 25 weeks gestation and died of respiratory
compli
dilatec
narrow
conditi

Cor

Expl

Exhibit Display

Stages of lung development

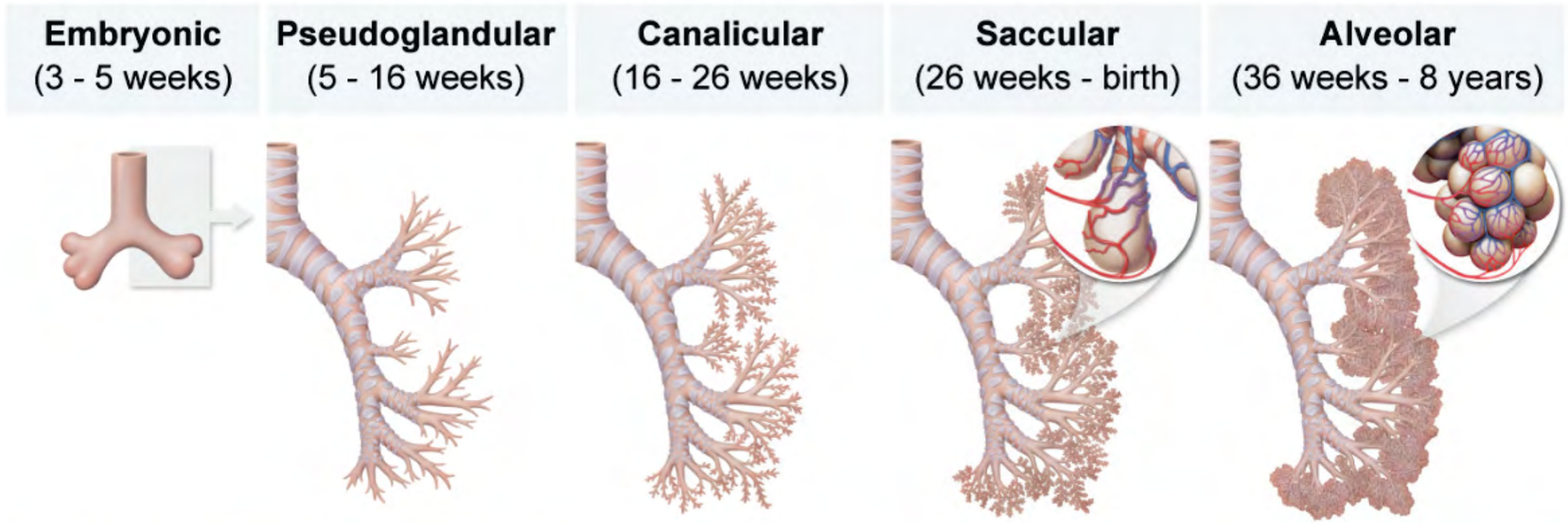

©UWorld

Zoom In Zoom Out Reset New | Existing My Notebook

https://t.me/USMLEWorldStep1

This infant's autopsy findings are consistent with **bronchopulmonary dysplasia** (BPD), or chronic lung disease of **prematurity**. The pathologic findings of BPD have evolved over time as advanced treatment modalities (eg, surfactant, noninvasive ventilation) have improved survival rates and reduced iatrogenic lung injury (eg, airway overdistension, oxygen toxicity).

Currently, BPD is primarily characterized by disrupted fetal lung development in the **early saccular stage**. During this stage, which begins at 26 weeks gestation and extends until birth, terminal sacs form and undergo septation, increasing the surface area for gas exchange. This period is also critical for the development and growth of a capillary network within the septa.

Characteristic histopathologic findings of BPD currently include:

- **Few, dilated alveoli** that have **poor septation** due to disrupted alveolarization. These malformed alveoli have decreased surface area for gas exchange, which manifests as respiratory distress in the neonatal period and a prolonged oxygen requirement.
- **Dysmorphic alveolar capillaries** due to impaired vasculogenesis, contributing to persistent hypoxia. Patients may also have thickening of the muscular layer of the pulmonary arterioles, which leads to increased pulmonary vascular resistance and pulmonary hypertension.

(Choice B) Congenital cystic adenomatoid malformation (ie, congenital pulmonary airway malformation) is an anomaly of the respiratory tract in which abnormal lung tissue forms a cystic mass. Histopathologic examination would likely show cystic areas (lined by ciliated columnar epithelium) surrounded by relatively normal alveoli.

(Choice C) Neonatal pneumonia is most commonly bacterial, and a predominance of inflammatory cells with neutrophils within the alveoli would be seen on histopathologic examination.

(Choice D) Cystic fibrosis is caused by a defective chloride channel that allows viscous secretions to accumulate in the airways, predisposing patients to chronic inflammation and bronchiectasis. Thickened, dilated bronchi with mucus plugging would be seen.

(Choice E) Pulmonary alveolar proteinosis is characterized by surfactant accumulation within the alveoli due to impaired clearance by alveolar macrophages. Histopathologic findings would include granular, proteinaceous material within the alveoli with normal alveolar architecture.

https://t.me/USMLEWorldStep1

this stage, which begins at 26 weeks gestation and extends until birth, terminal sacs form and undergo septation, increasing the surface area for gas exchange. This period is also critical for the development and growth of a capillary network within the septa.

Characteristic histopathologic findings of BPD currently include:

- **Few, dilated alveoli** that have **poor septation** due to disrupted alveolarization. These malformed alveoli have decreased surface area for gas exchange, which manifests as respiratory distress in the neonatal period and a prolonged oxygen requirement.
- **Dysmorphic alveolar capillaries** due to impaired vasculogenesis, contributing to persistent hypoxia. Patients may also have thickening of the muscular layer of the pulmonary arterioles, which leads to increased pulmonary vascular resistance and pulmonary hypertension.

(Choice B) Congenital cystic adenomatoid malformation (ie, congenital pulmonary airway malformation) is an anomaly of the respiratory tract in which abnormal lung tissue forms a cystic mass. Histopathologic examination would likely show cystic areas (lined by ciliated columnar epithelium) surrounded by relatively normal alveoli.

(Choice C) Neonatal pneumonia is most commonly bacterial, and a predominance of inflammatory cells with neutrophils within the alveoli would be seen on histopathologic examination.

(Choice D) Cystic fibrosis is caused by a defective chloride channel that allows viscous secretions to accumulate in the airways, predisposing patients to chronic inflammation and bronchiectasis. Thickened, dilated bronchi with mucus plugging would be seen.

(Choice E) Pulmonary alveolar proteinosis is characterized by surfactant accumulation within the alveoli due to impaired clearance by alveolar macrophages. Histopathologic findings would include granular, proteinaceous material within the alveoli with normal alveolar architecture.

Educational objective:
Bronchopulmonary dysplasia is common in premature infants due to arrest of fetal lung development in the saccular stage. Histopathologic examination of lung tissue shows impaired alveolarization (ie, dilated alveoli with decreased septation) and abnormal vasculogenesis (ie, dysmorphic alveolar capillaries).

https://t.me/USMLEWorldStep1

this stage, which begins at 26 weeks gestation and extends until birth, terminal sacs form and undergo septation,

increa

capilla

Chara

- **F**
  h
  a
- **D**
  P
  p

(Choi
anoma
would

(Choi
neutro

(Choi
in the
mucus

(Choi
impair
materi

Educa
Bronch
saccul
decreased septation) and abnormal vasculogenesis (ie, dysmorphic alveolar capillaries).

Exhibit Display

Congenital cystic adenomatoid malformation

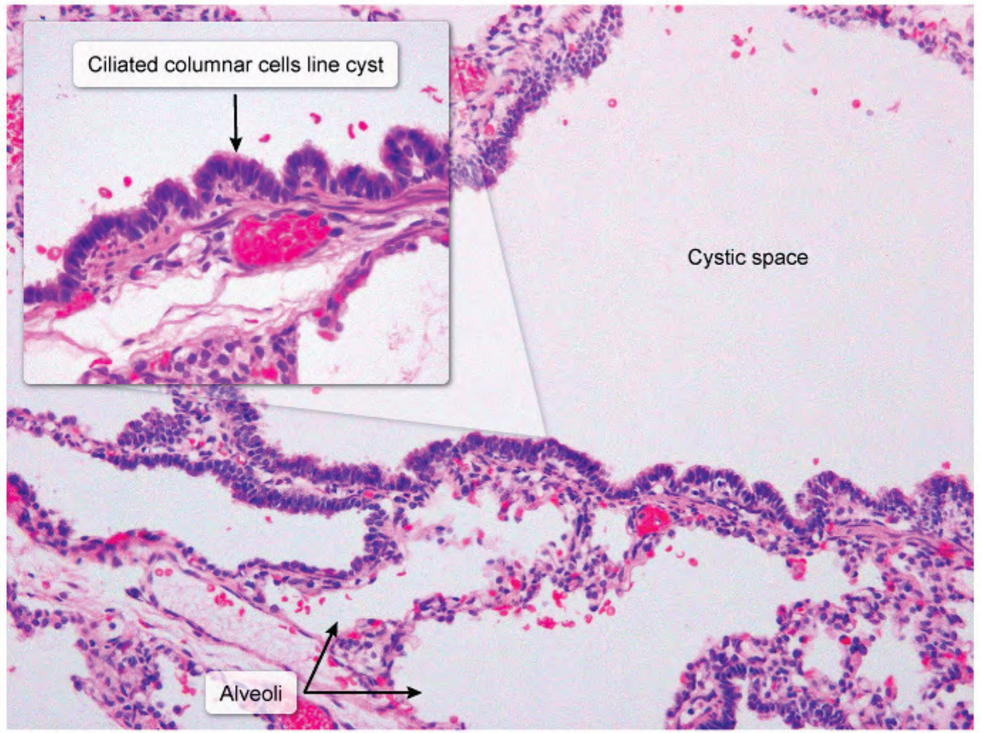

Congenital cystic adenomatoid malformation is also known as congenital pulmonary airway malformation. ©UWorld

Zoom In | Zoom Out | Reset | New | Existing | My Notebook

https://t.me/USMLEWorldStep1

this stage, which begins at 26 weeks gestation and extends until birth, terminal sacs form and undergo septation,

increa

capilla

Chara

- **F**
  h
  a
- **D**
  P
  p

(Choi
anoma
would

(Choi
neutro

(Choi
in the
mucus

(Choi
impair
materi

Educa
Bronch
saccul
decreased septation) and abnormal vasculogenesis (ie, dysmorphic alveolar capillaries).

Exhibit Display

Acute pneumonia

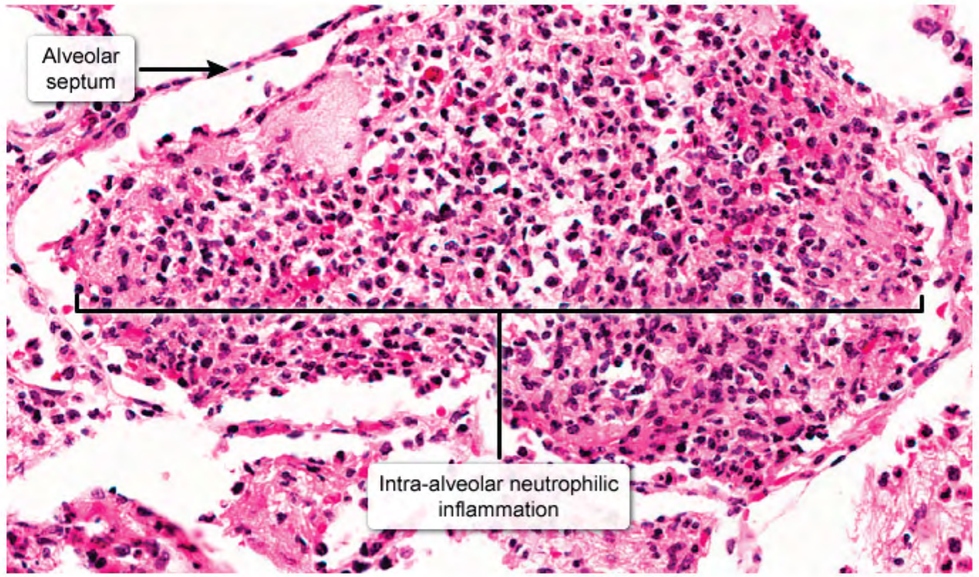

©UWorld

Zoom In | Zoom Out | Reset | New | Existing | My Notebook

https://t.me/USMLEWorldStep1

this stage, which begins at 26 weeks gestation and extends until birth, terminal sacs form and undergo septation,

increa

capilla

Chara

- **F**
  h
  a
- **D**
  P
  p

(Choi
anoma
would

(Choi
neutro

(Choi
in the
mucus

(Choi
impair
materi

Educa
Bronch
saccul
decreased septation) and abnormal vasculogenesis (ie, dysmorphic alveolar capillaries).

Exhibit Display

Cystic fibrosis

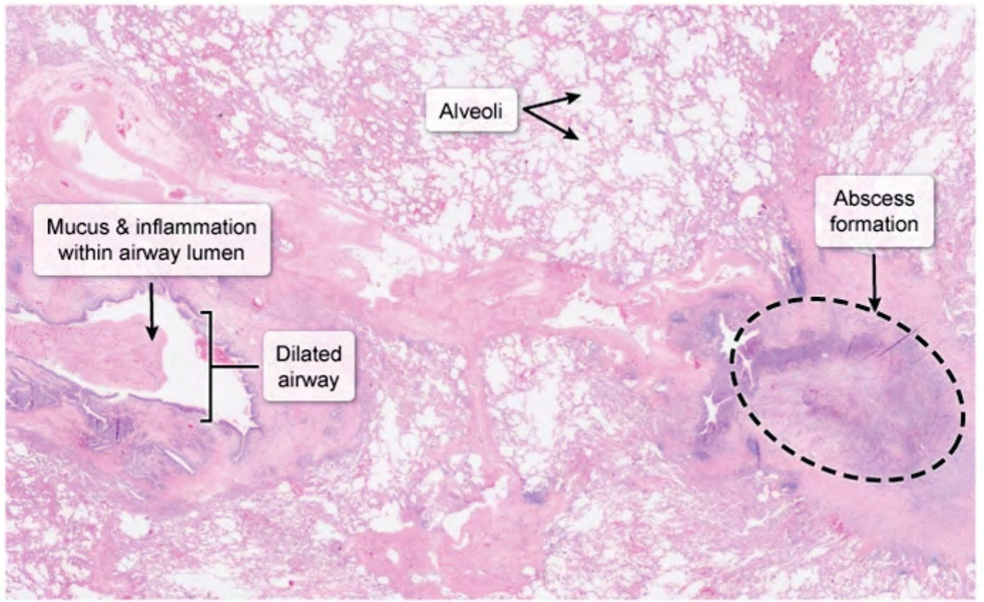

Zoom In | Zoom Out | Reset | New | Existing | My Notebook

https://t.me/USMLEWorldStep1

this stage, which begins at 26 weeks gestation and extends until birth, terminal sacs form and undergo septation,

increa

capilla

Chara

- **F**
  h
  a
- **D**
  P
  p

(Choi

anoma

would

(Choi

neutro

(Choi

in the

mucus

(Choi

impair

materi

Educa

Broncl

saccul

decreased septation) and abnormal vasculogenesis (ie, dysmorphic alveolar capillaries).

Exhibit Display

Pulmonary alveolar proteinosis

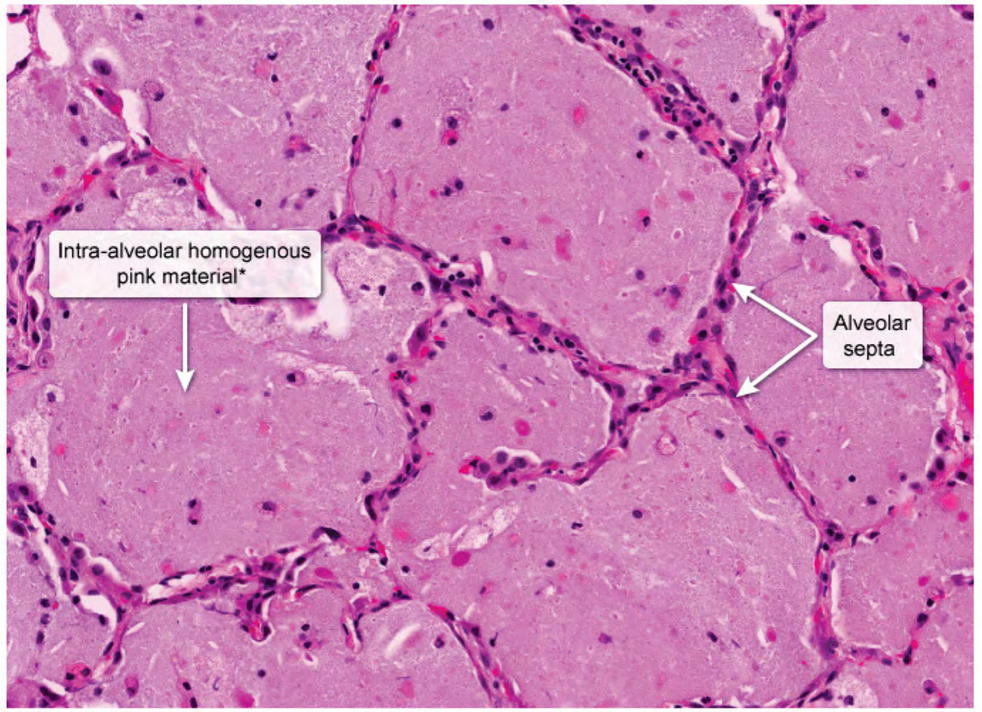

*Contains surfactant.

©UWorld

Zoom In | Zoom Out | Reset | New | Existing | My Notebook

https://t.me/USMLEWorldStep1

A 48-year-old man comes to the physician with a 6-month history of cough and fatigue. He also has experienced malaise and weight loss. He does not recall any sick contacts. The patient is a carpenter. He smokes 1 pack of cigarettes daily. Temperature is 37.1 C (98.8 F). Examination shows left lower lobe crackles. HIV testing is negative. Chest x-ray reveals a pulmonary infiltrate in the lower lobe of the left lung. Results from sputum potassium hydroxide preparation are shown below.

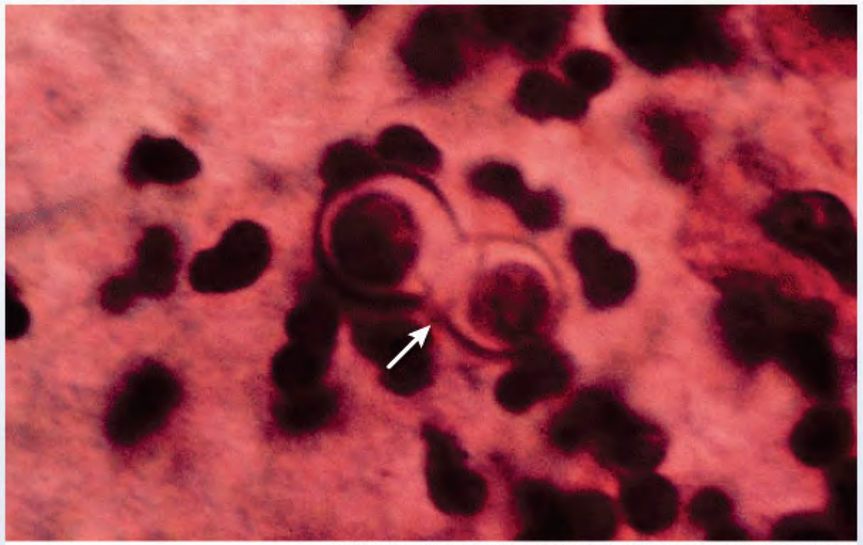

Displayed with permission from Current Medicine Group LLC © 2000.

Which of the following is the most likely cause of this patient's condition?

- A. *Aspergillus fumigatus*
- B. *Blastomyces dermatitidis*
- C. *Candida albicans*
- D. *Coccidioides immitis*
- E. *Cryptococcus neoformans*
- F. *Histoplasma capsulatum*

https://t.me/USMLEWorldStep1

A 48-year-old man comes to the physician with a 6-month history of cough and fatigue. He also has experienced
malais
cigare
negati
potass

Exhibit Display

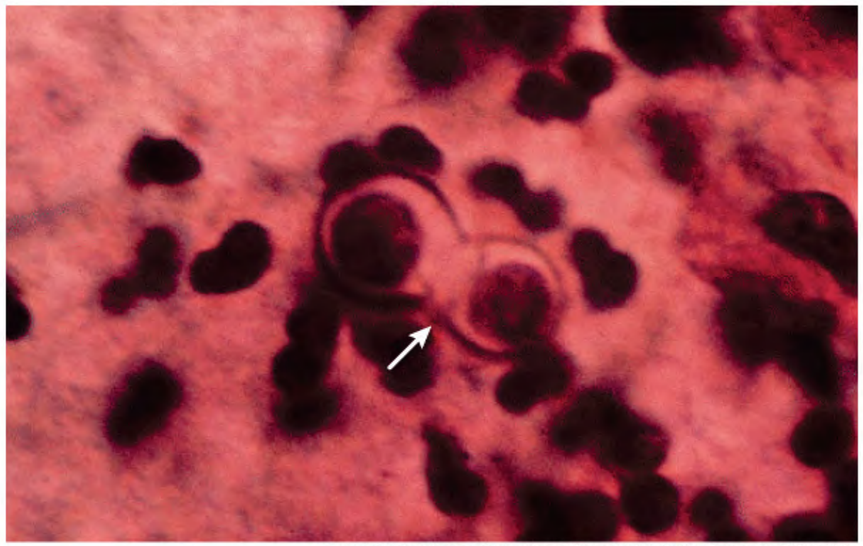

Displayed with permission from Current Medicine Group LLC © 2000.

Zoom In | Zoom Out | Reset | New | Existing | My Notebook

Which

F. *Histoplasma capsulatum*

https://t.me/USMLEWorldStep1

negative. Chest x-ray reveals a pulmonary infiltrate in the lower lobe of the left lung. Results from sputum potassium hydroxide preparation are shown below.

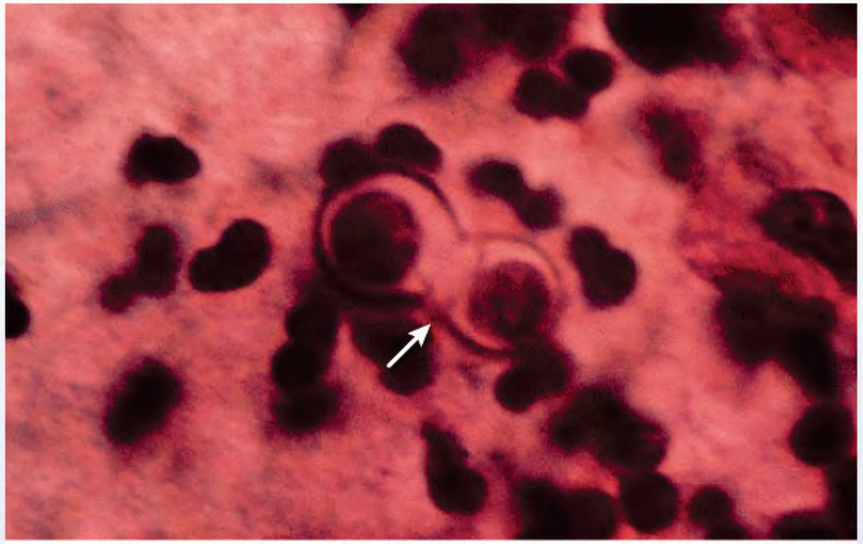

Displayed with permission from Current Medicine Group LLC © 2000.

Which of the following is the most likely cause of this patient's condition?

- A. *Aspergillus fumigatus*
- B. *Blastomyces dermatitidis*
- C. *Candida albicans*
- D. *Coccidioides immitis*
- E. *Cryptococcus neoformans*
- F. *Histoplasma capsulatum*
- G. *Rhizopus* species

Submit

https://t.me/USMLEWorldStep1

negative. Chest x-ray reveals a pulmonary infiltrate in the lower lobe of the left lung. Results from sputum potassium hydroxide preparation are shown below.

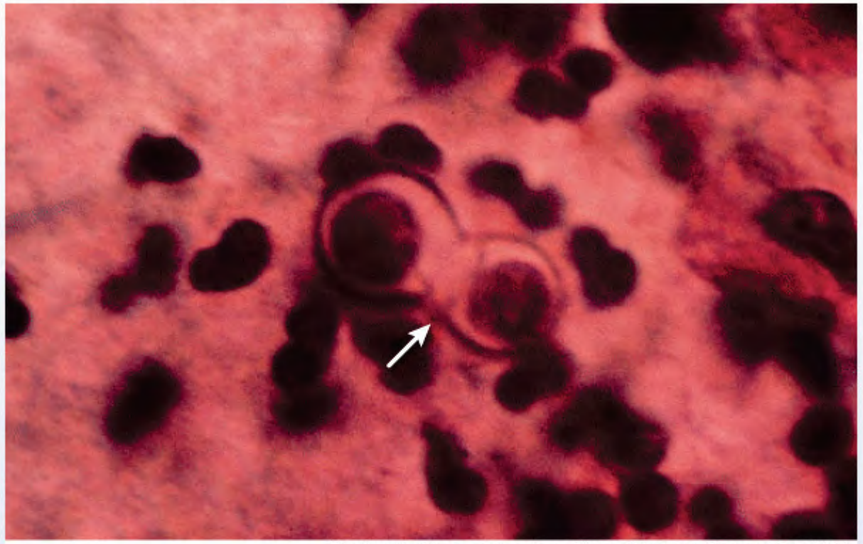

Displayed with permission from Current Medicine Group LLC © 2000.

Which of the following is the most likely cause of this patient's condition?

- A. *Aspergillus fumigatus* (3%)
- ✓ B. *Blastomyces dermatitidis* (77%)
- C. *Candida albicans* (1%)
- D. *Coccidioides immitis* (6%)
- ✗ E. *Cryptococcus neoformans* (7%)
- F. *Histoplasma capsulatum* (4%)
- G. *Rhizopus* species (0%)

Incorrect

https://t.me/USMLEWorldStep1

Blastomyces dermatitidis, a fungus endemic in the southeastern United States (states east of the Mississippi River), is present in soil and rotten organic matter. *Blastomyces* is a dimorphic fungus, meaning it assumes different forms at different temperatures. In the human body (37-40 C), it assumes the yeast form (single cells). The image shows a typical **large yeast** with a single, **broad-based bud**. The mold form (branching hyphae) predominates in the environment, at average temperatures of 25-30 C.

Infection occurs by inhalation of aerosolized fungus from the environment. In about half of **immunocompetent** individuals, blastomycosis may present as a lung infection or cause a flu-like illness (fever, chills, myalgia, headache, nonproductive cough) or pneumonia (fever, cough, pleuritic chest pain). **Pulmonary** blastomycosis is diagnosed by finding the typical yeast forms. In **immunocompromised** patients, blastomycosis can cause **disseminated** disease. Patients experience systemic symptoms (fever, weight loss, night sweats), lung involvement (cough, dyspnea), skin lesions (papules, pustules, ulcers, verrucous lesions), and **bone** pain (caused by lytic lesions).

(Choice A) *Aspergillus fumigatus* can cause lung disease in immunocompromised patients. It has only a mold form; in tissue samples it is seen as septate hyphae that branch at 45-degree angles.

(Choice C) *Candida albicans* is characterized by small oval yeast with narrow-based budding. Candida pneumonia is a very rare disease.

(Choice D) *Coccidioides immitis* is also a dimorphic fungus. It is seen as spherules (round encapsulated structures containing many endospores) in tissue samples.

(Choice E) *Cryptococcus neoformans* causes lung disease and meningitis in immunocompromised patients. In contrast to blastomycosis, it forms round yeast with variable sizes and narrow-based buds. *Cryptococcus* has a thick polysaccharide capsule that appears clear with India ink staining and stains red with mucicarmine.

(Choice F) *Histoplasma capsulatum* can cause lung disease. Like *Blastomyces*, it is a dimorphic fungus. Unlike *Blastomyces*, the yeast form of *Histoplasma* is smaller and is often found intracellularly within macrophages. *H capsulatum* is endemic in parts of the central and eastern United States along the Ohio and Mississippi river valleys.

(Choice G) *Rhizopus* species can cause lung disease in immunocompromised patients. *Rhizopus* is the most

https://t.me/USMLEWorldStep1

individuals, blastomycosis may present as a lung infection or cause a flu-like illness (fever, chills, myalgia, headache, nonproductive cough) or pneumonia (fever, cough, pleuritic chest pain). **Pulmonary** blastomycosis is diagnosed by finding the typical yeast forms. In **immunocompromised** patients, blastomycosis can cause **disseminated** disease. Patients experience systemic symptoms (fever, weight loss, night sweats), lung involvement (cough, dyspnea), skin lesions (papules, pustules, ulcers, verrucous lesions), and **bone** pain (caused by lytic lesions).

(Choice A) *Aspergillus fumigatus* can cause lung disease in immunocompromised patients. It has only a mold form; in tissue samples it is seen as septate hyphae that branch at 45-degree angles.

(Choice C) *Candida albicans* is characterized by small oval yeast with narrow-based budding. Candida pneumonia is a very rare disease.

(Choice D) *Coccidioides immitis* is also a dimorphic fungus. It is seen as spherules (round encapsulated structures containing many endospores) in tissue samples.

(Choice E) *Cryptococcus neoformans* causes lung disease and meningitis in immunocompromised patients. In contrast to blastomycosis, it forms round yeast with variable sizes and narrow-based buds. *Cryptococcus* has a thick polysaccharide capsule that appears clear with India ink staining and stains red with mucicarmine.

(Choice F) *Histoplasma capsulatum* can cause lung disease. Like *Blastomyces*, it is a dimorphic fungus. Unlike *Blastomyces*, the yeast form of *Histoplasma* is smaller and is often found intracellularly within macrophages. *H capsulatum* is endemic in parts of the central and eastern United States along the Ohio and Mississippi river valleys.

(Choice G) *Rhizopus* species can cause lung disease in immunocompromised patients. *Rhizopus* is the most common genus causing mucormycosis. It has only a mold form, with broad ribbon-like hyphae with rare septations.

Educational objective:
Blastomyces dermatitidis is a dimorphic fungus seen in tissue as round or oval yeasts with thick walls and broad-based budding. It is endemic in the southeastern United States (states east of the Mississippi River). The lungs are the primary site of involvement, and the skin and bone are the major sites of dissemination.

https://t.me/USMLEWorldStep1

Blastomyces dermatitidis, a fungus endemic in the southeastern United States (states east of the Mississippi River)
differe
The im
predor

Infecti
individ
headac
diagnc
disser
involve
by lytic

(Choic
form; i

(Choic
pneum

(Choic
structu

(Choic
contra
thick p

(Choic
Blasto
capsu
valleys

Exhibit Display

Blastomyces dermatitidis

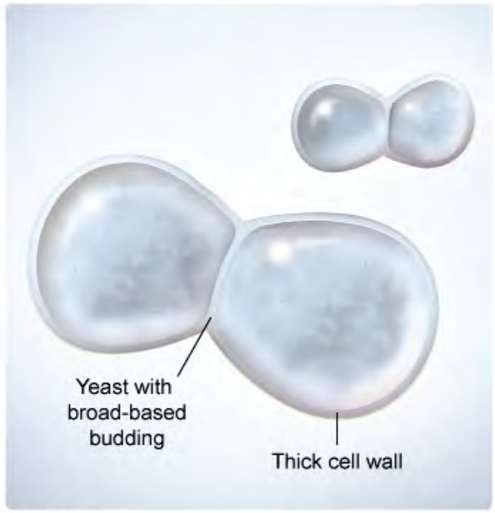

©UWorld

Zoom In | Zoom Out | Reset | New | Existing | My Notebook

(Choice G) *Rhizopus* species can cause lung disease in immunocompromised patients. *Rhizopus* is the most

https://t.me/USMLEWorldStep1

Blastomyces dermatitidis, a fungus endemic in the southeastern United States (states east of the Mississippi River)

differe

The im

predor

Infecti

individ

heada

diagnc

disser

involve

by lytic

(Choic

form; i

(Choic

pneum

(Choic

structu

(Choic

contra

thick p

(Choic

Blasto

capsu

valleys

Exhibit Display

Aspergillus

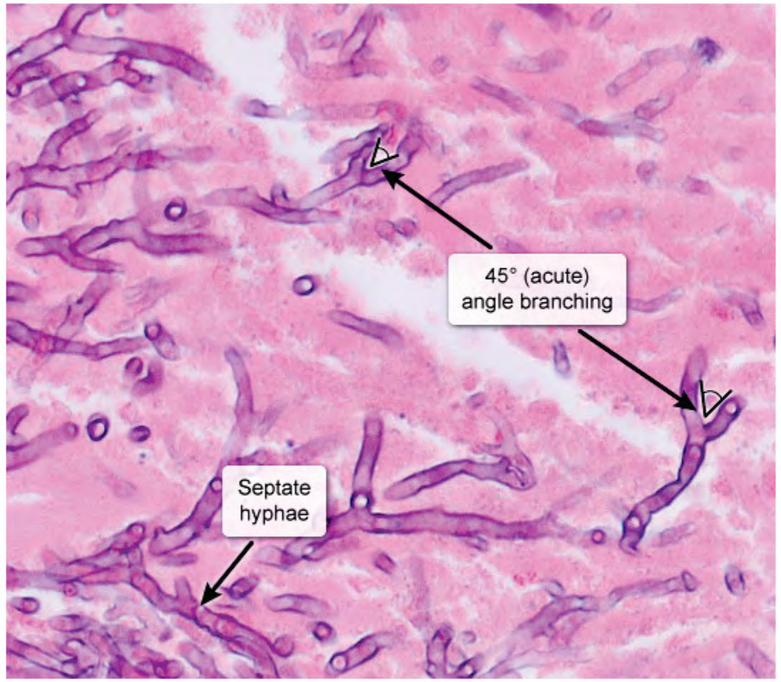

©UWorld

Zoom In | Zoom Out | Reset | New | Existing | My Notebook

(Choice G) *Rhizopus* species can cause lung disease in immunocompromised patients. *Rhizopus* is the most

https://t.me/USMLEWorldStep1

Blastomyces dermatitidis, a fungus endemic in the southeastern United States (states east of the Mississippi River) differe
The im
predor

Infecti
individ
heada
diagnc
disser
involve
by lytic

(Choic
form; i

(Choic
pneum

(Choic
structu

(Choic
contra
thick p

(Choic
Blasto
capsu
valleys

Exhibit Display

Candida albicans

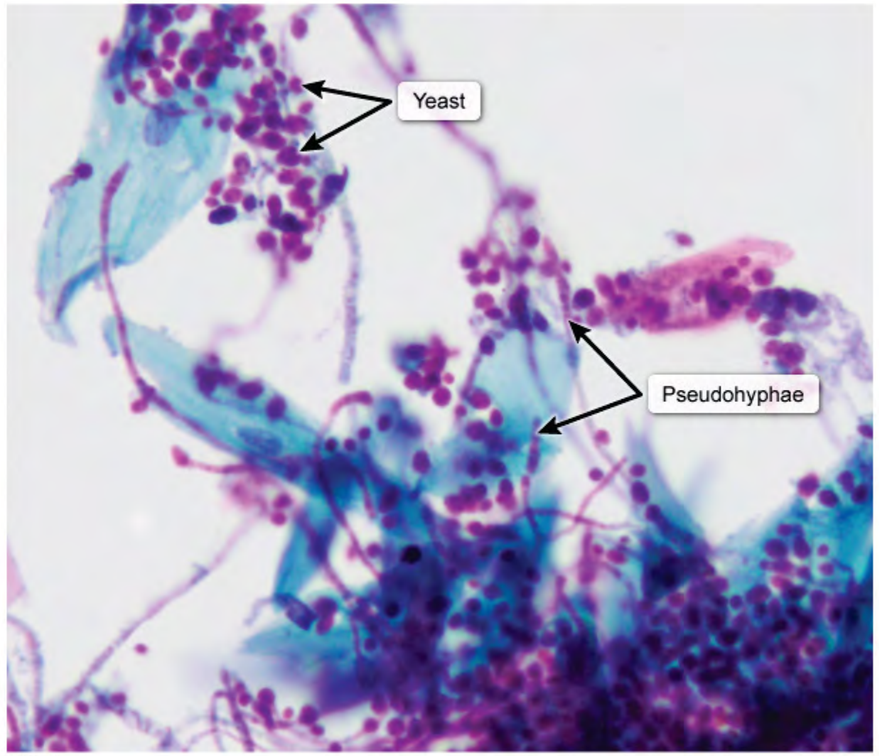

©UWorld

Zoom In | Zoom Out | Reset | New | Existing | My Notebook

(Choice G) *Rhizopus* species can cause lung disease in immunocompromised patients. *Rhizopus* is the most

https://t.me/USMLEWorldStep1

Blastomyces dermatitidis, a fungus endemic in the southeastern United States (states east of the Mississippi River)
differe
The im
predor

Infecti
individ
headac
diagnc
disser
involve
by lytic

(Choic
form; i

(Choic
pneum

(Choic
structu

(Choic
contra
thick p

(Choic
Blasto
capsu
valleys

Exhibit Display

Coccidioides

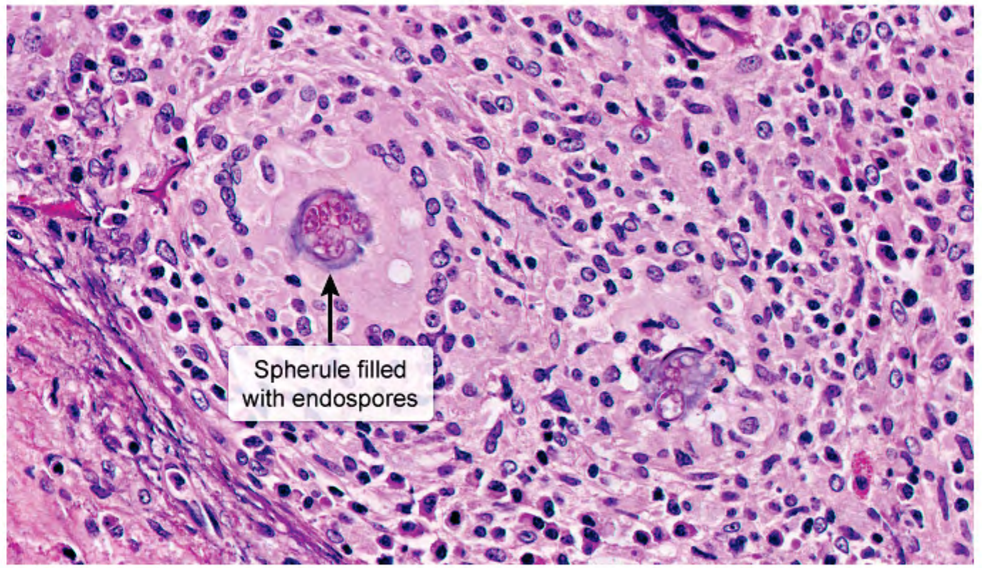

©UWorld

Zoom In | Zoom Out | Reset | New | Existing | My Notebook

(Choice G) *Rhizopus* species can cause lung disease in immunocompromised patients. *Rhizopus* is the most

https://t.me/USMLEWorldStep1

Blastomyces dermatitidis, a fungus endemic in the southeastern United States (states east of the Mississippi River) differe
The im
predor

Infecti
individ
heada
diagnc
disser
involve
by lytic

(Choic
form; i

(Choic
pneum

(Choic
structu

(Choic
contra
thick p

(Choic
Blasto
capsu
valleys

Exhibit Display

Cryptococcus

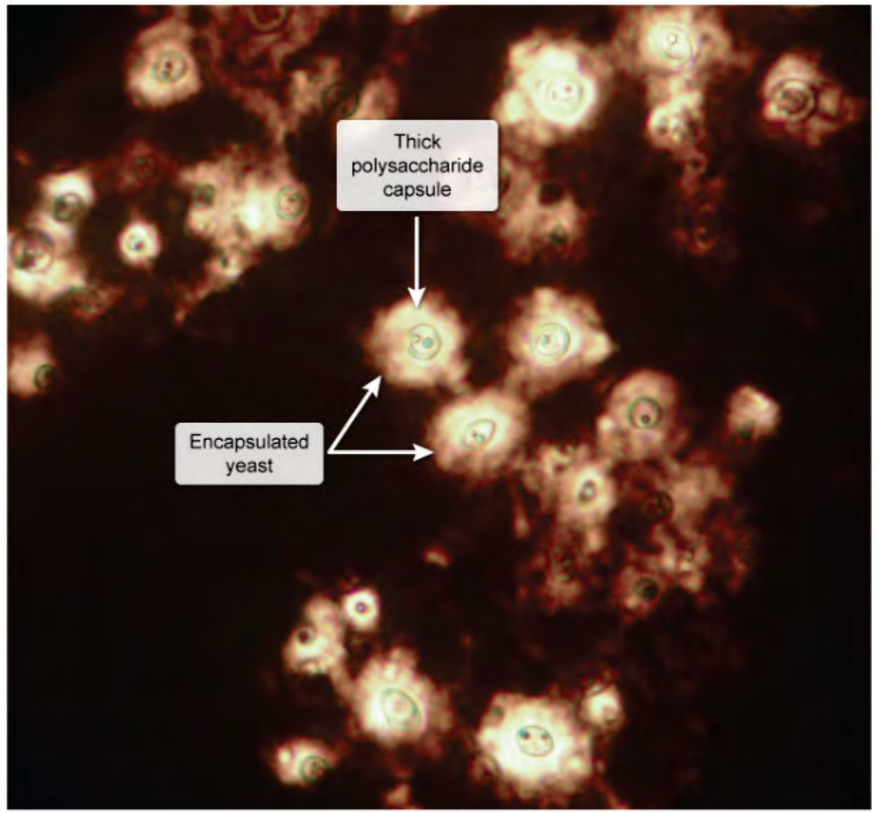

India ink stain ©UWorld

Zoom In Zoom Out Reset New | Existing My Notebook

(Choice G) *Rhizopus* species can cause lung disease in immunocompromised patients. *Rhizopus* is the most

https://t.me/USMLEWorldStep1

Blastomyces dermatitidis, a fungus endemic in the southeastern United States (states east of the Mississippi River) differe
The im
predor

Infecti
individ
heada
diagnc
disser
involve
by lytic

(Choic
form; i

(Choic
pneum

(Choic
structu

(Choic
contra
thick p

(Choic
Blasto
capsu
valleys

Exhibit Display

Histoplasma

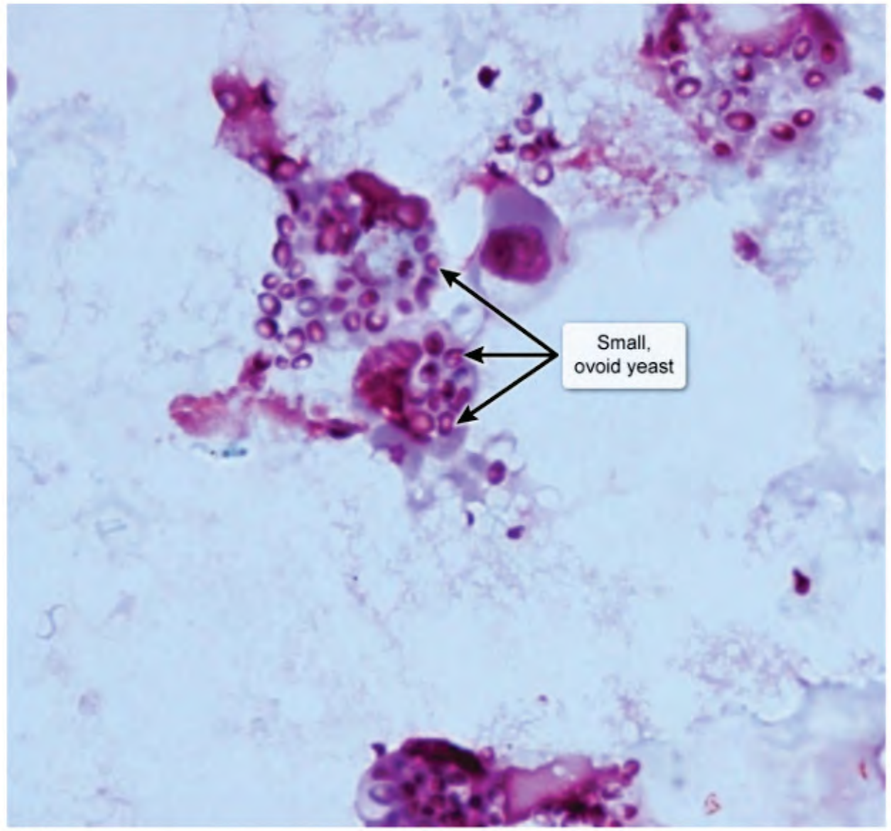

©UWorld

Zoom In Zoom Out Reset New | Existing My Notebook

(Choice G) *Rhizopus* species can cause lung disease in immunocompromised patients. *Rhizopus* is the most

https://t.me/USMLEWorldStep1

individuals, blastomycosis may present as a lung infection or cause a flu-like illness (fever, chills, myalgia,
headache, nonproductive cough) or pneumonia (fever, cough, pleuritic chest pain). **Pulmonary** blastomycosis is
diagnosed
disse
involve
by lytic

(Choi
form; i

(Choi
pneum

(Choi
structu

(Choi
contra
thick p

(Choi
Blasto
capsu
valleys

(Choi
comm
septat

Educa
Blasto
based
are the primary site of involvement, and the skin and bone are the major sites of dissemination.

Exhibit Display

Invasive fungal sinusitis due to mucormycosis (zygomycosis)

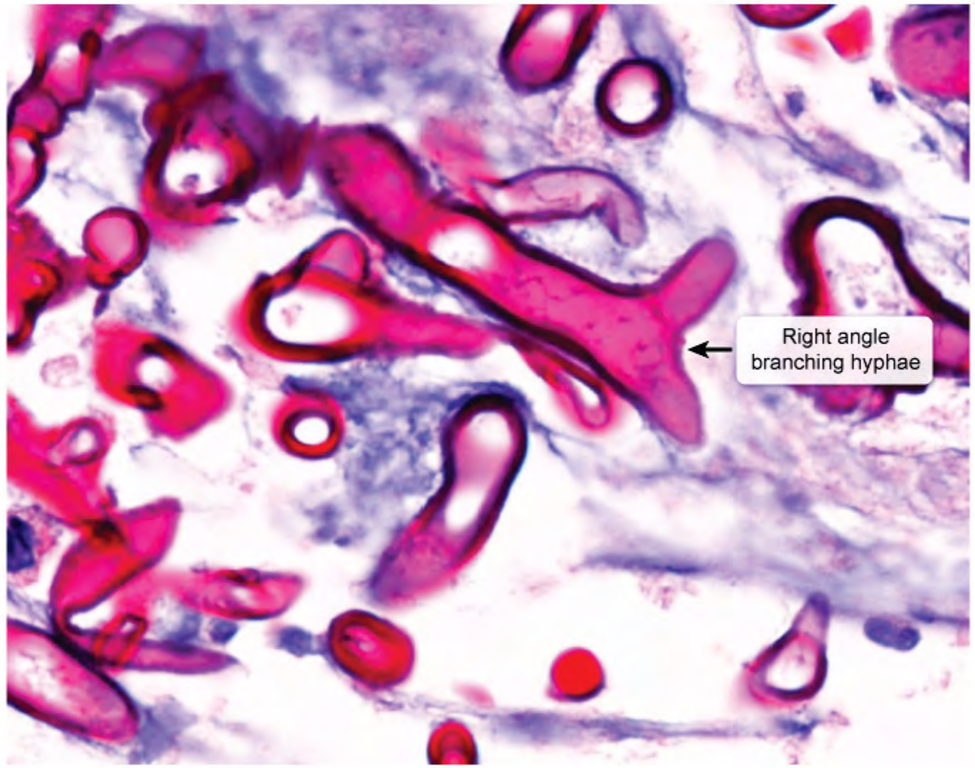

©UWorld

Zoom In | Zoom Out | Reset | New | Existing | My Notebook

https://t.me/USMLEWorldStep1

A 76-year-old man is brought to the emergency department after being involved in a motor vehicle collision. He is found to have a laceration of the spleen and is taken for emergent laparotomy. During surgery, the patient goes into cardiac arrest and dies, despite aggressive resuscitation efforts. Autopsy examination is performed and shows areas of thickening inside the chest wall as shown below.

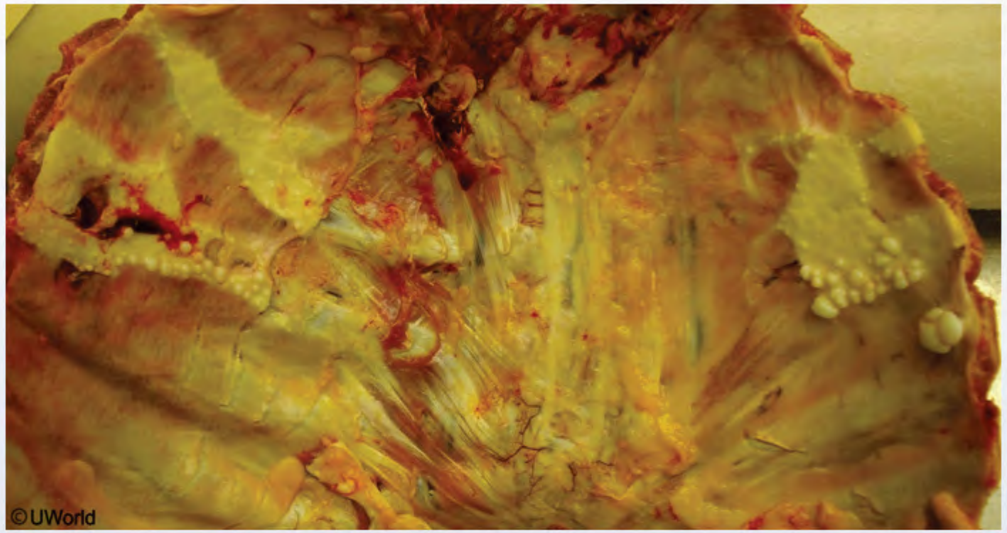

Lung examination shows fibrosis of the lower lobes. Pathologic examination of these fibrotic areas is most likely to reveal which of the following findings?

- A. Alveolar hyaline membranes
- B. Birefringent silicate particles
- C. Carbon-laden macrophages
- D. Cells with dense-core granules
- E. Coalescence of granulomas
- F. Ferruginous bodies

https://t.me/USMLEWorldStep1

A 76-year-old man is brought to the emergency department after being involved in a motor vehicle collision. He is found
into ca
areas

Exhibit Display

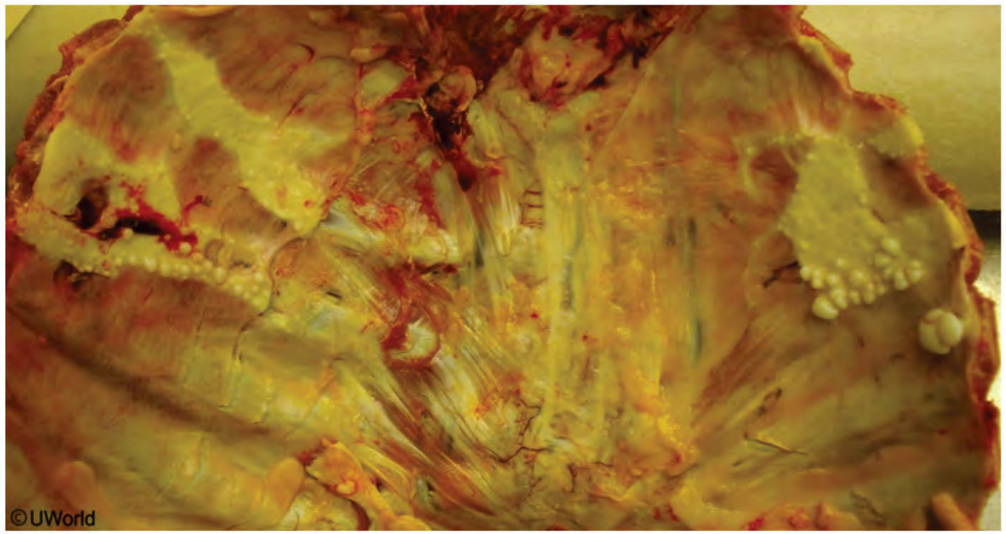

Zoom In | Zoom Out | Reset | New | Existing | My Notebook

Lung e
reveal

F. Ferruginous bodies

https://t.me/USMLEWorldStep1

into cardiac arrest and dies, despite aggressive resuscitation efforts. Autopsy examination is performed and shows areas of thickening inside the chest wall as shown below.

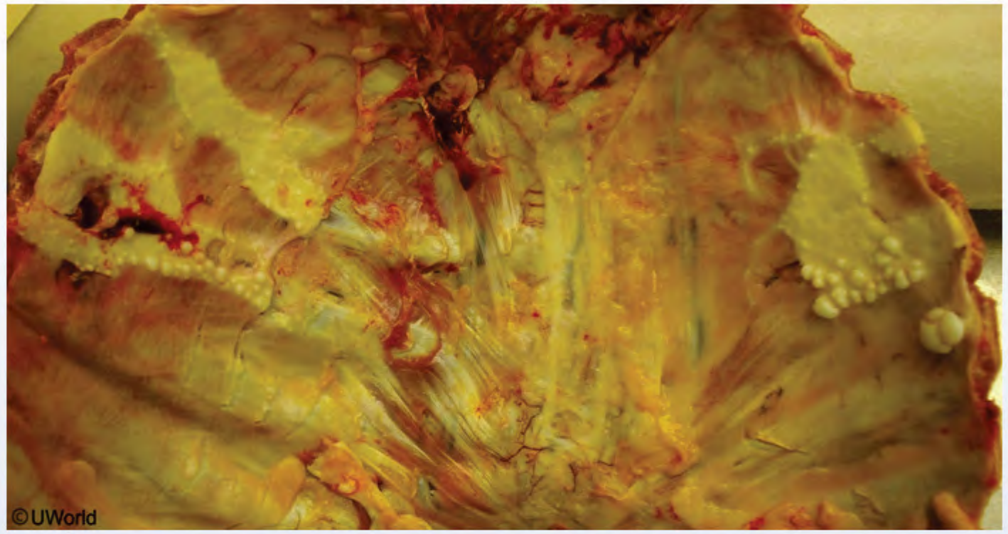

Lung examination shows fibrosis of the lower lobes. Pathologic examination of these fibrotic areas is most likely to reveal which of the following findings?

- A. Alveolar hyaline membranes
- B. Birefringent silicate particles
- C. Carbon-laden macrophages
- D. Cells with dense-core granules
- E. Coalescence of granulomas
- F. Ferruginous bodies

Submit

https://t.me/USMLEWorldStep1

into cardiac arrest and dies, despite aggressive resuscitation efforts. Autopsy examination is performed and shows areas of thickening inside the chest wall as shown below.

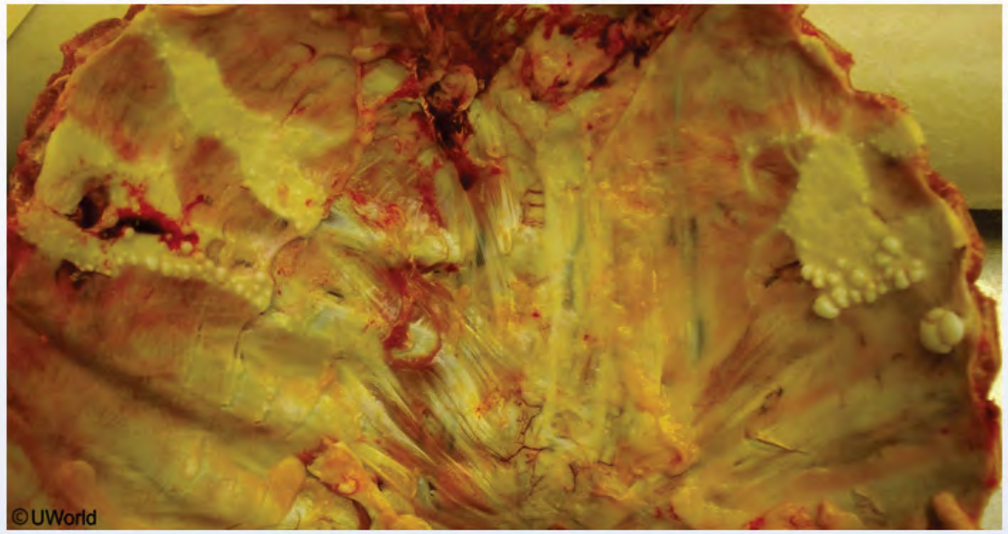

Lung examination shows fibrosis of the lower lobes. Pathologic examination of these fibrotic areas is most likely to reveal which of the following findings?

- A. Alveolar hyaline membranes (10%)
- ✗ B. Birefringent silicate particles (11%)
- C. Carbon-laden macrophages (5%)
- D. Cells with dense-core granules (7%)
- E. Coalescence of granulomas (7%)
- ✓ F. Ferruginous bodies (57%)

Incorrect
Correct answer
F

57%
Answered correctly

01 min, 11 secs
Time Spent

2023
Version

https://t.me/USMLEWorldStep1

Explanation

Exhibit Display

Asbestos exposure

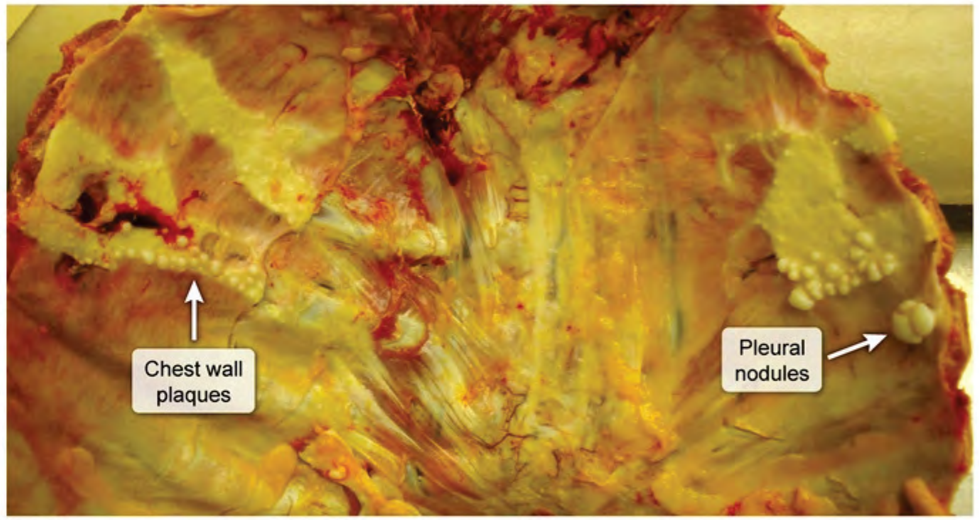

©UWorld

Zoom In | Zoom Out | Reset | New | Existing | My Notebook

This e
fibrosi
of asb
installa
dyspn

CT rad
honey
pleura
diffuse
coated
carbon, talc) by their **translucent** fiber core.

https://t.me/USMLEWorldStep1

This elderly patient had pleural plaques (focal thickening and calcification of the parietal pleura) and lower lung fibrosis, consistent with **pleuropulmonary asbestosis**. Asbestosis is a pneumoconiosis that occurs with inhalation of asbestos fibers (hydrated magnesium silicates), typically in patients with occupational exposure (eg, insulation installation, shipbuilding, pipe work). Patients are typically asymptomatic for 20-30 years after initial exposure; dyspnea, cough, and fatigue are common presenting symptoms.

CT radiography in asbestosis demonstrates bilateral parenchymal **fibrosis**, most predominant in the **lower lungs**; honeycombing and upper lung involvement occur in advanced disease. Pleural disease is common and includes **pleural plaques**, diffuse pleural thickening, or benign pleural effusions. Histopathology typically demonstrates diffuse **interstitial fibrosis** in association with ferruginous bodies (golden brown, rod- or fusiform-shaped fibers coated with iron-protein complexes). Asbestos fibers can be differentiated from other ferruginous bodies (eg, carbon, talc) by their **translucent** fiber core.

(Choice A) Hyaline membranes within the alveoli are seen in acute respiratory distress syndrome (ARDS) and can occur after severe trauma or sepsis. ARDS can lead to fibrosis, but this typically occurs weeks to months after the initial pulmonary insult and is not associated with pleural plaques.

(Choice B) Birefringent silicate particles are seen in silicosis, which typically presents with innumerable nodules that predominate in the upper lungs; egg-shell calcifications of the hilar lymph nodes may also be seen. Pleural plaques are unexpected.

(Choice C) Carbon-laden macrophages are seen in coal workers pneumoconiosis. Gross pathology demonstrates black coal nodules distributed throughout the upper lungs.

(Choice D) Carcinoid tumors are neuroendocrine malignancies that appear histologically as sheets of uniform cells with dense core granules noted on electron microscopy. They sometimes cause carcinoid syndrome (eg, flushing, diarrhea, wheezing), which is seen more commonly with gastrointestinal tumors. However, they tend to involve the large bronchi; fibrosis and pleural plaques are unexpected.

(Choice E) Chronic granulomatous disease is an immunodeficiency due to the inability of phagocytes to produce reactive oxygen species. Patients develop excessive granuloma formation and recurrent bacterial and fungal infections. Patients are typically diagnosed in childhood.

https://t.me/USMLEWorldStep1

CT radiography in asbestosis demonstrates bilateral parenchymal **fibrosis**, most predominant in the **lower lungs**; honeycombing and upper lung involvement occur in advanced disease. Pleural disease is common and includes **pleural plaques**, diffuse pleural thickening, or benign pleural effusions. Histopathology typically demonstrates diffuse **interstitial fibrosis** in association with ferruginous bodies (golden brown, rod- or fusiform-shaped fibers coated with iron-protein complexes). Asbestos fibers can be differentiated from other ferruginous bodies (eg, carbon, talc) by their **translucent** fiber core.

(Choice A) Hyaline membranes within the alveoli are seen in acute respiratory distress syndrome (ARDS) and can occur after severe trauma or sepsis. ARDS can lead to fibrosis, but this typically occurs weeks to months after the initial pulmonary insult and is not associated with pleural plaques.

(Choice B) Birefringent silicate particles are seen in silicosis, which typically presents with innumerable nodules that predominate in the upper lungs; egg-shell calcifications of the hilar lymph nodes may also be seen. Pleural plaques are unexpected.

(Choice C) Carbon-laden macrophages are seen in coal workers pneumoconiosis. Gross pathology demonstrates black coal nodules distributed throughout the upper lungs.

(Choice D) Carcinoid tumors are neuroendocrine malignancies that appear histologically as sheets of uniform cells with dense core granules noted on electron microscopy. They sometimes cause carcinoid syndrome (eg, flushing, diarrhea, wheezing), which is seen more commonly with gastrointestinal tumors. However, they tend to involve the large bronchi; fibrosis and pleural plaques are unexpected.

(Choice E) Chronic granulomatous disease is an immunodeficiency due to the inability of phagocytes to produce reactive oxygen species. Patients develop excessive granuloma formation and recurrent bacterial and fungal infections. Patients are typically diagnosed in childhood.

Educational objective:
Asbestosis is a pneumoconiosis that occurs with inhalation of asbestos fibers, most commonly in patients with occupational exposure (eg, insulation installation, shipbuilding, pipe work). Histopathology demonstrates diffuse interstitial fibrosis and ferruginous asbestos bodies (translucent fibers coated with a golden iron-containing material). Pleural disease (eg, plaques, benign effusions) is common.

https://t.me/USMLEWorldStep1

Exhibit Display

Ferruginous bodies

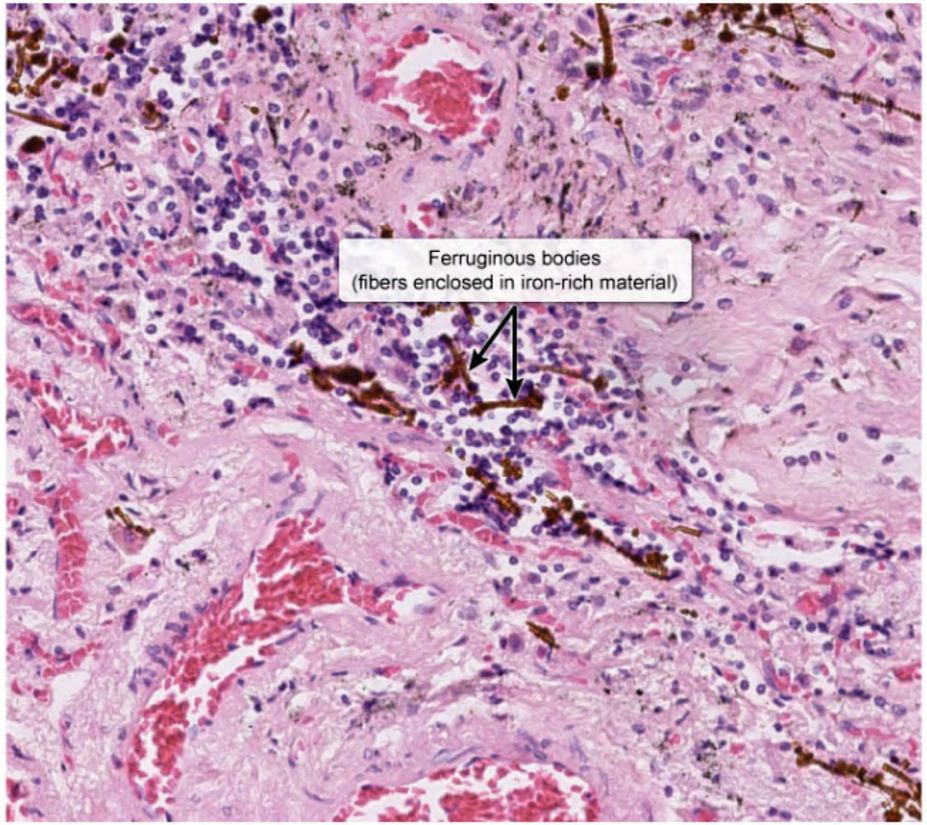

Zoom In | Zoom Out | Reset | New | Existing | My Notebook

This e
fibrosi
of asb
installa
dyspn

CT rad
honey
pleura
diffuse
coated
carbon

(Choi
can oc
the ini

(Choi
that pr
plaque

(Choice C) Carbon-laden macrophages are seen in coal workers pneumoconiosis. Gross pathology demonstrates black coal nodules distributed throughout the upper lungs.

https://t.me/USMLEWorldStep1

Exhibit Display

Diffuse alveolar damage

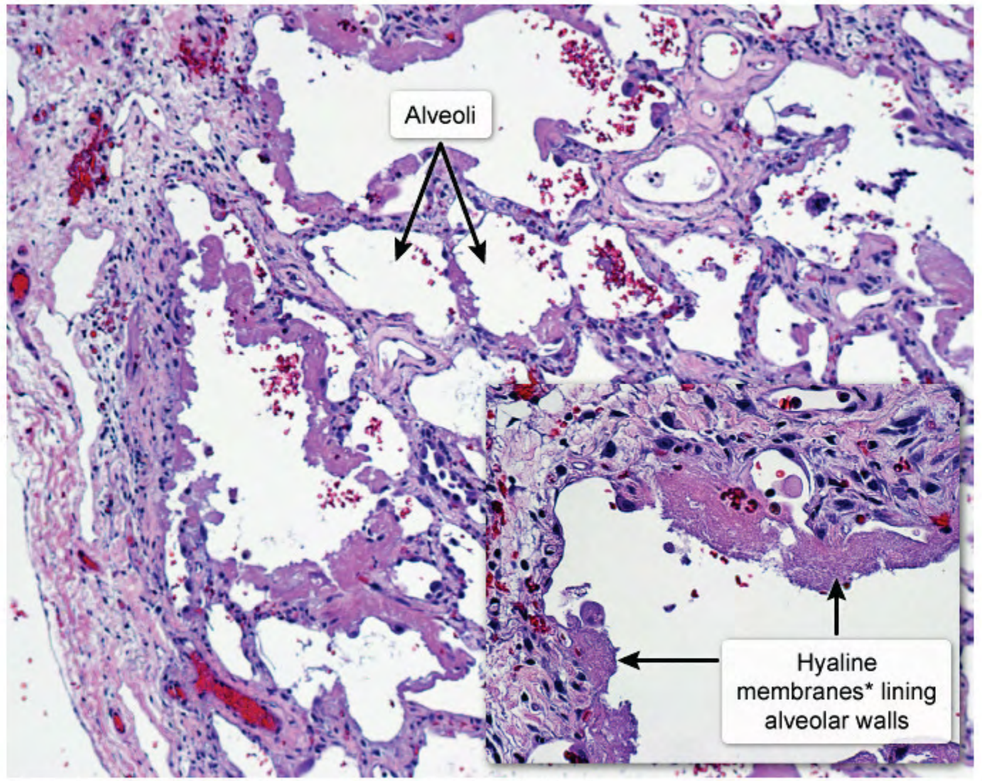

*Dense pink material composed of plasma proteins and necrotic epithelial cells

©UWorld

Zoom In | Zoom Out | Reset | New | Existing | My Notebook

This e
fibrosi
of asb
installa
dyspn

CT rad
honey
pleura
diffuse
coated
carbon

(Choi
can oc
the ini

(Choi
that pr
plaque

(Choice C) Carbon-laden macrophages are seen in coal workers pneumoconiosis. Gross pathology demonstrates black coal nodules distributed throughout the upper lungs.

https://t.me/USMLEWorldStep1

A 32-year-old woman is brought to the emergency department after being stuck in a malfunctioning elevator for 45 minutes. The patient says she felt extremely anxious in the closed space of the elevator and experienced dizziness, shortness of breath, generalized weakness, and blurred vision. She has no other medical conditions and takes no medications. She does not use tobacco, alcohol, or illicit drugs. Which of the following is the most likely cause of this patient's symptoms?

- A. Decreased arterial partial pressure of CO_2
- B. Decreased arterial partial pressure of O_2
- C. Decreased arterial pH
- D. Decreased arterial total O_2 content
- E. Increased alveolar-arterial O_2 gradient
- F. Increased arterial lactic acid content

Submit

https://t.me/USMLEWorldStep1

A 32-year-old woman is brought to the emergency department after being stuck in a malfunctioning elevator for 45 minutes. The patient says she felt extremely anxious in the closed space of the elevator and experienced dizziness, shortness of breath, generalized weakness, and blurred vision. She has no other medical conditions and takes no medications. She does not use tobacco, alcohol, or illicit drugs. Which of the following is the most likely cause of this patient's symptoms?

- ✓ A. Decreased arterial partial pressure of CO_2 (69%)
- B. Decreased arterial partial pressure of O_2 (11%)
- ✗ C. Decreased arterial pH (7%)
- D. Decreased arterial total O_2 content (6%)
- E. Increased alveolar-arterial O_2 gradient (2%)
- F. Increased arterial lactic acid content (1%)

Incorrect
Correct answer
A

69%
Answered correctly

05 secs
Time Spent

2023
Version

Explanation

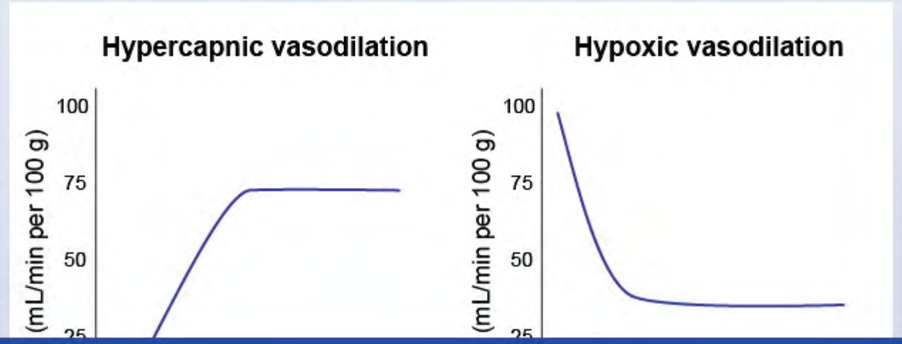

https://t.me/USMLEWorldStep1

A 32-year-old woman is brought to the emergency department after being stuck in a malfunctioning elevator for 45 minute
dizzine
and ta
likely c

Inco
Corre
A

Expl

Exhibit Display

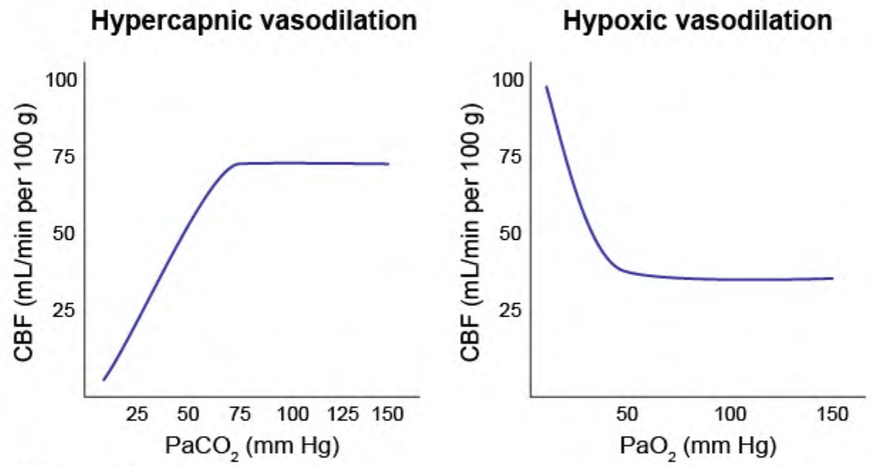

CBF = cerebral blood flow.
©UWorld

Zoom In | Zoom Out | Reset | New | Existing | My Notebook

https://t.me/USMLEWorldStep1

This patient most likely had a panic attack while trapped in the elevator. Panic attacks are typically accompanied by **hyperventilation** with a resulting **decrease in arterial partial pressure of CO_2** ($PaCO_2$). This hypocapnia can cause **decreased cerebral perfusion** with consequent neurologic sequelae, including generalized weakness, blurred vision, presyncope (ie, dizziness, lightheadedness), and syncope.

Cerebral blood flow (CBF) remains relatively constant over a wide range of perfusion pressures (cerebrovascular autoregulation) and is mainly influenced by arterial blood gas levels, particularly changes in $PaCO_2$. Hypercapnia triggers an increase in CBF (to aid in removal of toxins), and hypocapnia triggers a decrease in CBF. In fact, because hypocapnia decreases CBF, mechanically ventilated patients with cerebral edema are often hyperventilated to decrease intracranial pressure and help prevent brain herniation.

CBF is less sensitive to the arterial partial pressure of oxygen (PaO_2). PaO_2 has little influence on CBF until the level drops below 50 mm Hg, at which point a rapid increase in CBF is triggered.

(Choices B and D) The total blood O_2 content is predominantly made up of hemoglobin-bound O_2 (determined by the blood hemoglobin level and PaO_2) plus a small contribution of dissolved O_2. Hyperventilation increases the alveolar partial pressure of O_2 and should somewhat increase (rather than decrease) both PaO_2 and total blood O_2 content.

(Choice C) Hyperventilation produces respiratory alkalosis, marked by an increase in arterial pH.

(Choice E) Disturbances that increase the alveolar-arterial O_2 gradient include V/Q mismatch (eg, pulmonary embolism), diffusion limitation, and right-to-left shunting (eg, Eisenmenger syndrome). Changes in ventilation rate (ie, hypo- or hyperventilation) have no effect on the alveolar-arterial O_2 gradient.

(Choice F) Increased arterial lactic acid content is a sign of tissue hypoxia (eg, due to sepsis or ischemia), which is unlikely in the setting of hyperventilation from a panic attack.

Educational objective:
Panic attacks are typically accompanied by hyperventilation, leading to hypocapnia. Cerebral blood flow is directly related to the arterial partial pressure of CO_2; therefore, hypocapnia can lead to reduced cerebral blood flow and symptoms of cerebral hypoperfusion (eg, blurred vision, dizziness, lightheadedness).

https://t.me/USMLEWorldStep1

A 45-year-old previously healthy man is brought to the emergency department after being hit by a car while cycling. The patient is hypotensive and tachycardic on arrival and has comminuted fractures of the pelvis and lower extremities. Volume resuscitation is performed with intravenous fluids and multiple units of packed red blood cells and plasma. Several hours later, the patient develops worsening dyspnea and hypoxia. Chest imaging reveals new bilateral infiltrates. Endotracheal intubation is performed for respiratory support. Despite aggressive resuscitation, the patient dies 24 hours later. Autopsy examination of the lungs shows protein-rich fluid within the alveolar airspaces. Breakdown of the barrier formed by which of the following cells most likely contributed to this patient's pulmonary pathology?

- A. Alveolar macrophages
- B. Ciliated epithelial cells
- C. Club cells (previously Clara cells)
- D. Goblet cells
- E. Type I pneumocytes
- F. Type II pneumocytes

Submit

https://t.me/USMLEWorldStep1

A 45-year-old previously healthy man is brought to the emergency department after being hit by a car while cycling. The patient is hypotensive and tachycardic on arrival and has comminuted fractures of the pelvis and lower extremities. Volume resuscitation is performed with intravenous fluids and multiple units of packed red blood cells and plasma. Several hours later, the patient develops worsening dyspnea and hypoxia. Chest imaging reveals new bilateral infiltrates. Endotracheal intubation is performed for respiratory support. Despite aggressive resuscitation, the patient dies 24 hours later. Autopsy examination of the lungs shows protein-rich fluid within the alveolar airspaces. Breakdown of the barrier formed by which of the following cells most likely contributed to this patient's pulmonary pathology?

- ✗ A. Alveolar macrophages (8%)
- B. Ciliated epithelial cells (3%)
- C. Club cells (previously Clara cells) (2%)
- D. Goblet cells (0%)
- ✓ E. Type I pneumocytes (69%)
- F. Type II pneumocytes (15%)

Incorrect
Correct answer
E

69%
Answered correctly

03 secs
Time Spent

2023
Version

Explanation

https://t.me/USMLEWorldStep1

A 45-year-old previously healthy man is brought to the emergency department after being hit by a car while cycling
lower
cells a
reveal
resusc
alveol
patien

Exhibit Display

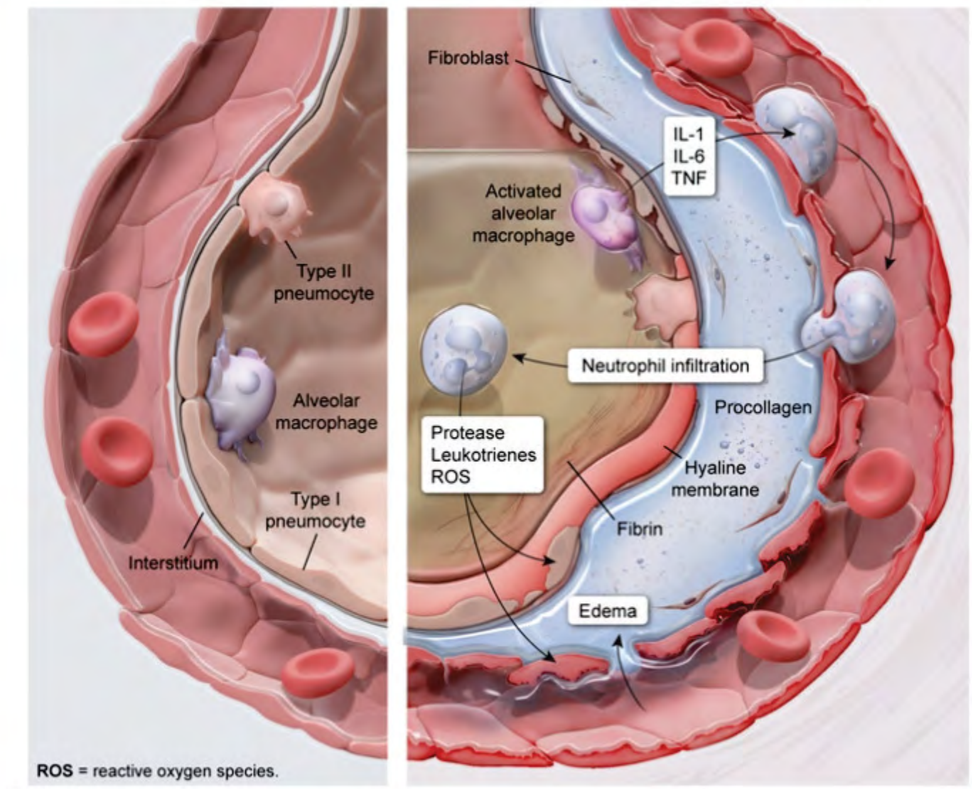

Zoom In | Zoom Out | Reset | New | Existing | My Notebook

https://t.me/USMLEWorldStep1

This patient who developed hypoxia, pulmonary edema (bilateral pulmonary infiltrates), and protein-rich fluid in the alveoli had **acute respiratory distress syndrome** (ARDS). ARDS is a severe inflammatory reaction that occurs in the lungs and results in respiratory failure with hypoxemia and **noncardiogenic pulmonary edema**. Risk factors include **sepsis**, severe **trauma** (eg, long-bone fractures with fat embolism, extensive tissue injury), and **transfusion** of blood products, all of which can initiate pulmonary injury and trigger a cascade of inflammation:

- In response to injury, alveolar macrophages release multiple proinflammatory cytokines that recruit neutrophils to the lungs **(Choice A)**.
- Upon arrival to pulmonary tissue, the neutrophils release inflammatory mediators (eg, proteases, free radicals). This increases inflammation and leads to damage to the pulmonary endothelium and alveolar pneumocytes.
- The **alveolar-capillary barrier**, which is formed by the endothelial cells and **type I pneumocytes**, is then destroyed, allowing fluid and red blood cells to escape the vascular and interstitial spaces and pour into the alveoli. There, they combine with material from necrotic cells and form a **thick proteinaceous fluid** and a hyaline membrane.
- Destruction of type II pneumocytes, which normally produce surfactant and proliferate in response to injury, leads to alveolar collapse (but does not cause destruction of the alveolar capillary barrier) **(Choice F)**.

The net effect is impaired alveolar gas exchange and respiratory failure, with affected patients having a high mortality rate.

(Choices B and D) Ciliated epithelium and goblet cells line the larger airways. Goblet cells secrete mucus that traps particulate matter (eg, dust, bacteria), while ciliated epithelial cells assist in its elimination by sweeping the mucus up the bronchi and trachea to the pharynx, where it is swallowed. These cells are not prominently involved in ARDS.

(Choice C) Club cells (formerly called Clara cells) are nonciliated, secretory constituents of the terminal respiratory epithelium. They secrete protein and surfactant components and help detoxify inhaled substances (eg, tobacco smoke). They are not prominently involved in ARDS.

https://t.me/USMLEWorldStep1

transfusion of blood products, all of which can initiate pulmonary injury and trigger a cascade of inflammation.

- In response to injury, alveolar macrophages release multiple proinflammatory cytokines that recruit neutrophils to the lungs **(Choice A)**.
- Upon arrival to pulmonary tissue, the neutrophils release inflammatory mediators (eg, proteases, free radicals). This increases inflammation and leads to damage to the pulmonary endothelium and alveolar pneumocytes.
- The **alveolar-capillary barrier**, which is formed by the endothelial cells and **type I pneumocytes**, is then destroyed, allowing fluid and red blood cells to escape the vascular and interstitial spaces and pour into the alveoli. There, they combine with material from necrotic cells and form a **thick proteinaceous fluid** and a hyaline membrane.
- Destruction of type II pneumocytes, which normally produce surfactant and proliferate in response to injury, leads to alveolar collapse (but does not cause destruction of the alveolar capillary barrier) **(Choice F)**.

The net effect is impaired alveolar gas exchange and respiratory failure, with affected patients having a high mortality rate.

(Choices B and D) Ciliated epithelium and goblet cells line the larger airways. Goblet cells secrete mucus that traps particulate matter (eg, dust, bacteria), while ciliated epithelial cells assist in its elimination by sweeping the mucus up the bronchi and trachea to the pharynx, where it is swallowed. These cells are not prominently involved in ARDS.

(Choice C) Club cells (formerly called Clara cells) are nonciliated, secretory constituents of the terminal respiratory epithelium. They secrete protein and surfactant components and help detoxify inhaled substances (eg, tobacco smoke). They are not prominently involved in ARDS.

Educational objective:
Acute respiratory distress syndrome is a severe inflammatory reaction that occurs in the lungs and results in hypoxemia and noncardiogenic pulmonary edema. Pulmonary injury leads to an inflammatory response resulting in breakdown of the capillary-alveolar barrier (created by type I pneumocytes and endothelial cells), increased capillary permeability, intraalveolar fluid accumulation, and hyaline membrane formation.

https://t.me/USMLEWorldStep1

A 42-year-old man comes to the emergency department due to several hours of dyspnea. He is a long-haul truck driver who became acutely short of breath during a 36-hour trip but previously had been healthy. The patient smokes a pack of cigarettes daily and drinks a 6-pack of beer on weekends. Pulmonary examination reveals vesicular breath sounds bilaterally with the overlying areas resonant to percussion. CT pulmonary angiogram shows a right lower lobe pulmonary artery occlusion consistent with pulmonary embolism but no evidence of pulmonary infarction. Which of the following is the most likely reason for the lack of lung tissue necrosis in this patient?

- A. Collateral circulation
- B. Decreased surfactant
- C. Endothelial tissue plasminogen activator
- D. Increased pulmonary venous pressure
- E. Intrapulmonary shunting

Submit

https://t.me/USMLEWorldStep1

A 42-year-old man comes to the emergency department due to several hours of dyspnea. He is a long-haul truck driver who became acutely short of breath during a 36-hour trip but previously had been healthy. The patient smokes a pack of cigarettes daily and drinks a 6-pack of beer on weekends. Pulmonary examination reveals vesicular breath sounds bilaterally with the overlying areas resonant to percussion. CT pulmonary angiogram shows a right lower lobe pulmonary artery occlusion consistent with pulmonary embolism but no evidence of pulmonary infarction. Which of the following is the most likely reason for the lack of lung tissue necrosis in this patient?

- ✓ A. Collateral circulation (77%)
- B. Decreased surfactant (0%)
- C. Endothelial tissue plasminogen activator (1%)
- D. Increased pulmonary venous pressure (1%)
- E. Intrapulmonary shunting (19%)

Correct | 77% Answered correctly | 04 secs Time Spent | 2023 Version

Explanation

Bronchopulmonary anastomosis

https://t.me/USMLEWorldStep1

Correct

Answered correctly

Time Spent

Version

Exhibit Display

Bronchopulmonary anastomosis

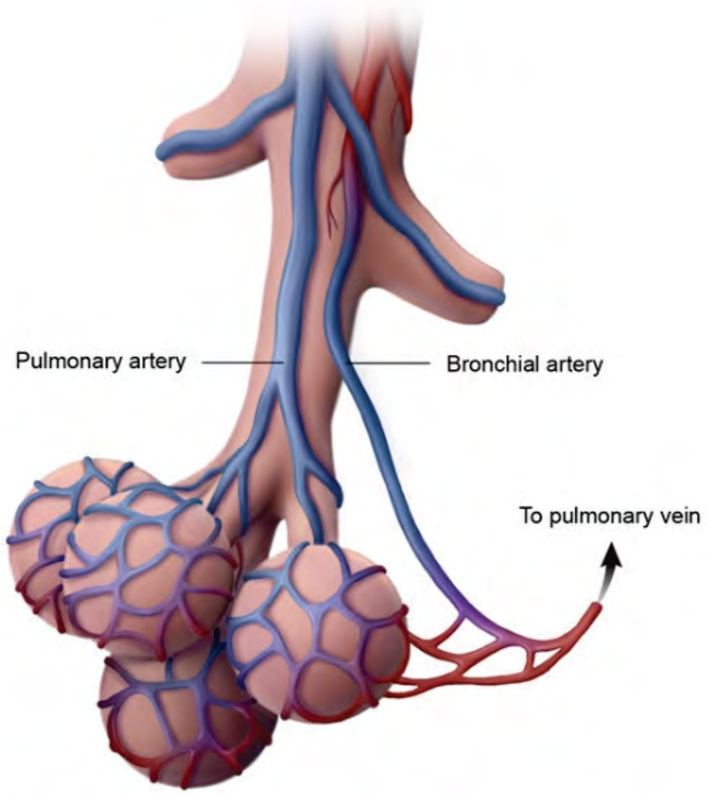

©UWorld

Zoom In | Zoom Out | Reset | New | Existing | My Notebook

©UWorld

The lung is supplied by **dual circulation** from both the pulmonary arteries and bronchial arteries. This collateral

https://t.me/USMLEWorldStep1

The lung is supplied by **dual circulation** from both the pulmonary arteries and bronchial arteries. This collateral circulation can help **protect against lung infarction** as a complication of **pulmonary embolism** (PE).

The pulmonary arteries are the major suppliers of blood to the lungs, providing deoxygenated blood for gas exchange; the bronchial arteries supply nutrients, remove waste from the bronchi, and provide collateral blood flow to the remainder of the lung parenchyma. When a clot occludes the pulmonary system, the bronchial system continues to supply nutrients to pulmonary tissue and can even backfill the pulmonary capillaries to partially maintain gas exchange in the area of the thromboembolism.

Distal PEs in small arteries (≤3 mm) are more likely to cause infarction as they may occlude areas distal to the pulmonary-bronchial anastomoses. When a pulmonary infarction does occur, it is typically **hemorrhagic** (red) rather than ischemic (white) due to the relatively low density of lung tissue and the dual blood supply.

(Choice B) Alveolar inflammation triggered by PE can eventually lead to decreased surfactant and some degree of atelectasis. This process can take up to 2 days to develop, and the resulting intrapulmonary shunting makes a small contribution to the hypoxemia that occurs with PE.

(Choice C) Recombinant tissue plasminogen activator (TPA) may be used to treat PE in patients who are hemodynamically unstable. However, endothelial-derived TPA is limited primarily to the bronchial circulation, and spontaneous recanalization of the pulmonary artery is a slow process.

(Choice D) PE leads to increased pulmonary arterial pressure; however, the pulmonary venous pressure is unchanged or decreased as blood flow through the proximal pulmonary circulation is obstructed. Patients with an underlying elevation in pulmonary venous pressure (eg, decompensated heart failure) may be more likely to experience lung infarction with PE due to the high pulmonary venous pressure impairing collateral flow from the bronchial circulation.

(Choice E) Intrapulmonary shunting occurs when an area of the lung is adequately perfused but poorly ventilated. PE causes intrapulmonary shunting due to redistribution of blood away from segments directly affected by the clot; the remaining accessible alveoli are unable to fully oxygenate all the blood passing through the pulmonary circulation, resulting in hypoxemia. In contrast, areas distal to the clot receive adequate ventilation but poor perfusion (ie, dead space ventilation).

https://t.me/USMLEWorldStep1

exchange, the bronchial arteries supply nutrients, remove waste from the bronchi, and provide collateral blood flow to the remainder of the lung parenchyma. When a clot occludes the pulmonary system, the bronchial system continues to supply nutrients to pulmonary tissue and can even backfill the pulmonary capillaries to partially maintain gas exchange in the area of the thromboembolism.

Distal PEs in small arteries (≤3 mm) are more likely to cause infarction as they may occlude areas distal to the pulmonary-bronchial anastomoses. When a pulmonary infarction does occur, it is typically **hemorrhagic** (red) rather than ischemic (white) due to the relatively low density of lung tissue and the dual blood supply.

(Choice B) Alveolar inflammation triggered by PE can eventually lead to decreased surfactant and some degree of atelectasis. This process can take up to 2 days to develop, and the resulting intrapulmonary shunting makes a small contribution to the hypoxemia that occurs with PE.

(Choice C) Recombinant tissue plasminogen activator (TPA) may be used to treat PE in patients who are hemodynamically unstable. However, endothelial-derived TPA is limited primarily to the bronchial circulation, and spontaneous recanalization of the pulmonary artery is a slow process.

(Choice D) PE leads to increased pulmonary arterial pressure; however, the pulmonary venous pressure is unchanged or decreased as blood flow through the proximal pulmonary circulation is obstructed. Patients with an underlying elevation in pulmonary venous pressure (eg, decompensated heart failure) may be more likely to experience lung infarction with PE due to the high pulmonary venous pressure impairing collateral flow from the bronchial circulation.

(Choice E) Intrapulmonary shunting occurs when an area of the lung is adequately perfused but poorly ventilated. PE causes intrapulmonary shunting due to redistribution of blood away from segments directly affected by the clot; the remaining accessible alveoli are unable to fully oxygenate all the blood passing through the pulmonary circulation, resulting in hypoxemia. In contrast, areas distal to the clot receive adequate ventilation but poor perfusion (ie, dead space ventilation).

Educational objective:
The lungs are supplied by dual circulation from both the pulmonary and bronchial arteries. This collateral circulation can help protect against lung infarction due to pulmonary artery occlusion (ie, pulmonary embolism), as the bronchial circulation can continue to provide blood to the lung parenchyma.

https://t.me/USMLEWorldStep1

Distal PEs in small arteries (≤3 mm) are more likely to cause infarction as they may occlude areas distal to the pulmo
rather

(Choi
of atel
small

(Choi
hemoc
sponta

(Choi
uncha
underl
experi
bronch

(Choi
PE ca
the re
circula
perfus

Educa
The lu
circula
the br

Refere

- Pul
- Lung infarction following pulmonary embolism: a comparative study on clinical conditions and CT findings to

Exhibit Display

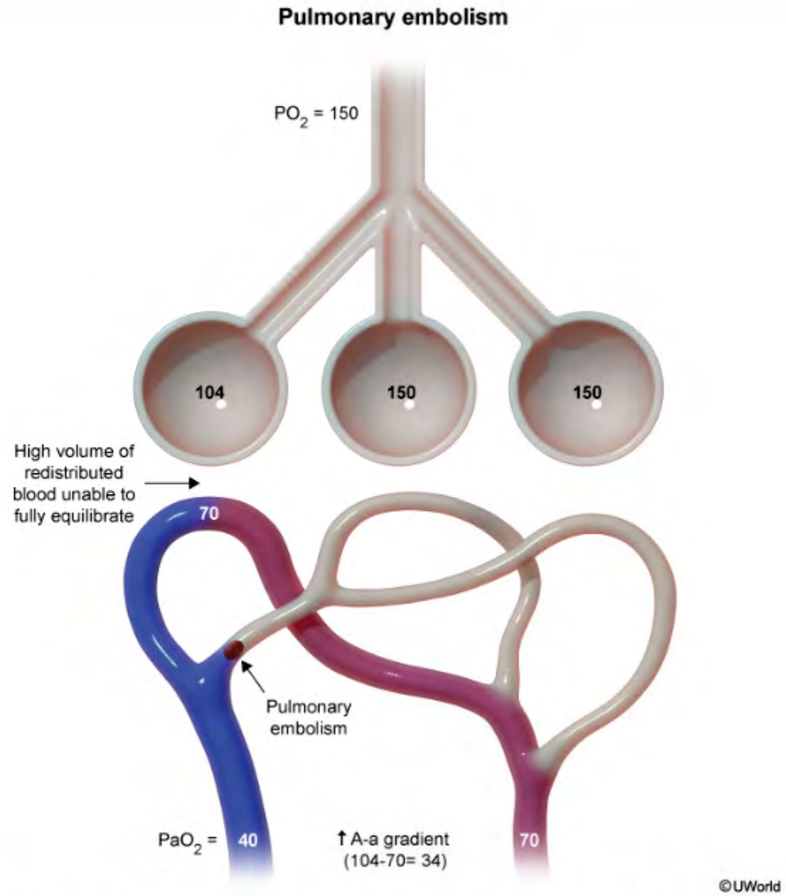

Zoom In | Zoom Out | Reset | New | Existing | My Notebook

https://t.me/USMLEWorldStep1

A 28-year-old professional athlete participates in a sports physiology study. She runs on a treadmill at an incrementally increasing speed. After 15-minutes, her pulse is 90% of the maximal heart rate based on her age, and several physiologic parameters are measured. Which of the following changes have most likely occurred compared to at rest?

	Minute ventilation	Ventilation/perfusion ratio	Mixed venous oxygen content
○ A.	Decreased	Increased	Unchanged
○ B.	Increased	Decreased	Decreased
○ C.	Increased	Increased	Decreased
○ D.	Increased	Unchanged	Increased
○ E.	Unchanged	Unchanged	Increased

Submit

https://t.me/USMLEWorldStep1

A 28-year-old professional athlete participates in a sports physiology study. She runs on a treadmill at an incrementally increasing speed. After 15-minutes, her pulse is 90% of the maximal heart rate based on her age, and several physiologic parameters are measured. Which of the following changes have most likely occurred compared to at rest?

		Minute ventilation	Ventilation/perfusion ratio	Mixed venous oxygen content	
	A.	Decreased	Increased	Unchanged	(2%)
✗	B.	Increased	Decreased	Decreased	(20%)
✓	C.	Increased	Increased	Decreased	(57%)
	D.	Increased	Unchanged	Increased	(19%)
	E.	Unchanged	Unchanged	Increased	(0%)

Incorrect
Correct answer
C

57%
Answered correctly

04 secs
Time Spent

2023
Version

Explanation

During **aerobic exercise**, respiratory activity changes to help meet the body's **increased metabolic demand**. The physiologic changes that occur are most pronounced in highly trained athletes:

- **Increased minute ventilation** occurs via an increase in respiratory rate and tidal volume and facilitates an increased rate of **oxygen uptake** and **carbon dioxide removal**. The increase in tidal volume can reach up to 50% of resting vital capacity.
- The increased minute ventilation **increases alveolar ventilation** throughout the lungs up to 20 times resting levels. Pulmonary vascular resistance is reduced and cardiac output is increased, which allows for more

https://t.me/USMLEWorldStep1

During **aerobic exercise**, respiratory activity changes to help meet the body's **increased metabolic demand**. The physiologic changes that occur are most pronounced in highly trained athletes:

- **Increased minute ventilation** occurs via an increase in respiratory rate and tidal volume and facilitates an increased rate of **oxygen uptake** and **carbon dioxide removal**. The increase in tidal volume can reach up to 50% of resting vital capacity.
- The increased minute ventilation **increases alveolar ventilation** throughout the lungs up to 20 times resting levels. Pulmonary vascular resistance is reduced and cardiac output is increased, which allows for more evenly distributed blood flow throughout the lungs and **reduced physiologic dead space** (ie, reduction in the proportion of air in the respiratory tract that does not participate in gas exchange). Although blood flow through the lungs is increased (the increase in cardiac output maxes out at approximately 8 times resting levels), alveolar ventilation is more increased (ie, ventilatory capacity exceeds cardiac output capacity), resulting in an **increased ventilation-perfusion ratio**.

In addition, an accumulation of lactic acid decreases blood pH and stimulates a **rightward shift** in the hemoglobin dissociation curve, facilitating **increased unloading of oxygen** in skeletal muscle. Although increased cardiac output increases the rate of blood flow through the skeletal muscle capillaries and reduces the time allowed for oxygen unloading, the rate of arterial oxygen extraction by skeletal muscle markedly increases during exercise, outpacing cardiac output. This results in increased fractional extraction of arterial oxygen and **decreased mixed venous oxygen content**.

It follows that cardiac output, and not alveolar ventilation or the rate of oxygen uptake by skeletal muscle, is the primary limitation to aerobic exercise.

Educational objective:
Physiologic changes in the respiratory system that occur with exercise include increased minute ventilation (via both an increase in respiratory rate and tidal volume), reduced physiologic dead space, increased ventilation-perfusion ratio, and increased extraction of oxygen by skeletal muscle (resulting in decreased mixed venous oxygen content).

https://t.me/USMLEWorldStep1

During **aerobic exercise**, respiratory activity changes to help meet the body's **increased metabolic demand**. The physic

- **In** in 5
- T le e p th le re

In add dissoc output oxyge outpac **venou**

It follo primar

Educa

Physic both a perfus oxygen content).

Exhibit Display

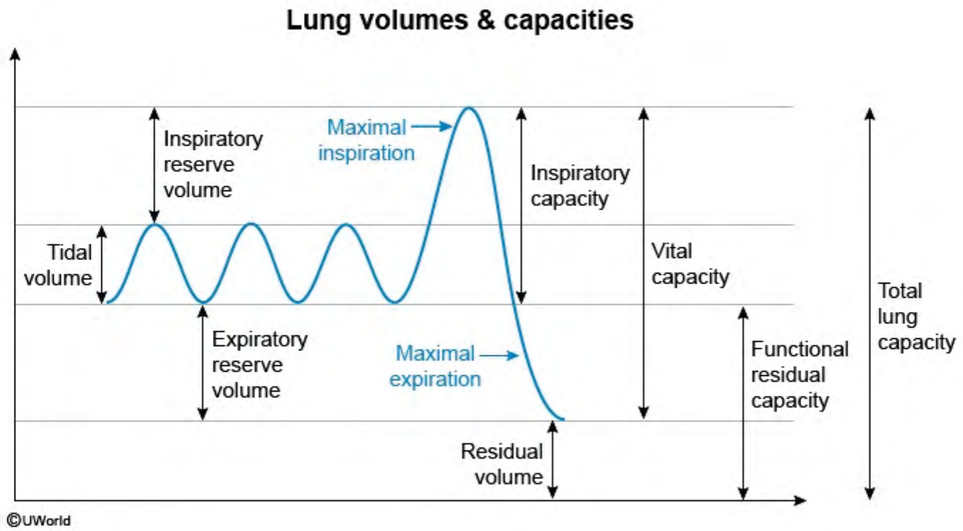

Zoom In Zoom Out Reset New | Existing My Notebook

https://t.me/USMLEWorldStep1

During **aerobic exercise**, respiratory activity changes to help meet the body's **increased metabolic demand**. The physic

- **In** in 5
- T le e p th le re

In add dissoc output oxyge outpac **venou**

It follo primar

Educa

Physic both a perfus oxygen content).

Exhibit Display

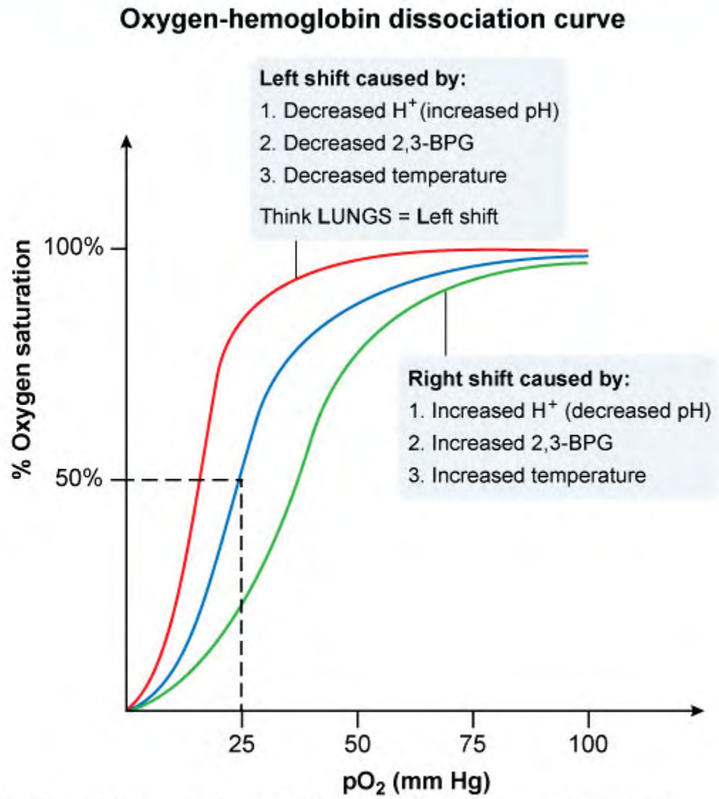

2,3-BPG = 2,3-bisphosphoglycerate; **pO_2** = partial pressure of oxygen in the blood.

©UWorld

Zoom In Zoom Out Reset New | Existing My Notebook

https://t.me/USMLEWorldStep1

A 21-year-old man with asthma comes to the office for follow-up. His asthma symptoms are not adequately controlled with albuterol as needed, and a daily inhaled therapy was added at the previous visit. The patient says he feels much better and has been using his rescue inhaler less frequently. He has no other medical conditions. The patient does not use tobacco or illicit drugs and drinks one or two 12-oz cans of beer daily. He received childhood vaccinations but has refused the flu and pneumococcal vaccines. Vital signs are within normal limits, and lungs are clear to auscultation. White mucosal plaques that can be easily scraped off using a tongue depressor are present in the oropharynx. The remainder of the physical examination shows no abnormalities. Which of the following measures would have been most effective in preventing this patient's abnormal oropharyngeal findings?

- A. Avoiding alcohol intake
- B. Obtaining recommended vaccines
- C. Oral rinsing after inhaler use
- D. Periodic glucose monitoring
- E. Taking prophylactic antibiotics
- F. Using vitamin supplements

Submit

https://t.me/USMLEWorldStep1

A 21-year-old man with asthma comes to the office for follow-up. His asthma symptoms are not adequately controlled with albuterol as needed, and a daily inhaled therapy was added at the previous visit. The patient says he feels much better and has been using his rescue inhaler less frequently. He has no other medical conditions. The patient does not use tobacco or illicit drugs and drinks one or two 12-oz cans of beer daily. He received childhood vaccinations but has refused the flu and pneumococcal vaccines. Vital signs are within normal limits, and lungs are clear to auscultation. White mucosal plaques that can be easily scraped off using a tongue depressor are present in the oropharynx. The remainder of the physical examination shows no abnormalities. Which of the following measures would have been most effective in preventing this patient's abnormal oropharyngeal findings?

- ✗ A. Avoiding alcohol intake (0%)
- B. Obtaining recommended vaccines (0%)
- ✓ C. Oral rinsing after inhaler use (98%)
- D. Periodic glucose monitoring (0%)
- E. Taking prophylactic antibiotics (0%)
- F. Using vitamin supplements (0%)

Incorrect
Correct answer
C

98%
Answered correctly

04 secs
Time Spent

2023
Version

Explanation

Patients with intermittent **asthma** may be managed with an as-needed, short-acting beta-agonist alone; however, persistent symptoms or severe disease necessitates the addition of long-term controller medications. **Inhaled glucocorticoids** are recommended for all such patients and have been shown to improve symptoms, reduce the need for short-acting bronchodilators, and lower the risk of serious exacerbations and associated hospitalization.

https://t.me/USMLEWorldStep1

Patients with intermittent **asthma** may be managed with an as-needed, short-acting beta-agonist alone; however, persistent symptoms or severe disease necessitates the addition of long-term controller medications. **Inhaled glucocorticoids** are recommended for all such patients and have been shown to improve symptoms, reduce the need for short-acting bronchodilators, and lower the risk of serious exacerbations and associated hospitalization.

Low-dose inhaled glucocorticoids are well tolerated and rarely cause systemic adverse effects. However, poor inhalation technique can cause much of the medication to deposit on the oral mucous membranes, where it is ineffective and can lead to **oropharyngeal candidiasis** (OPC) (evidenced by white plaques that are easily scraped off). Patients can avoid this complication by using a spacer and **rinsing the mouth** after inhalation. Dysphonia unrelated to OPC can also occur with inhaled glucocorticoids due to myopathy of laryngeal muscles and mucosal irritation.

(Choice A) Excessive alcohol intake may increase the risk of developing OPC; however, this patient's intake of 1 or 2 beers per day is within acceptable limits and is an unlikely contributing factor.

(Choice B) Diphtheria (due to *Corynebacterium diphtheriae*) is a serious infection that typically presents with pharyngitis and gray oropharyngeal pseudomembranes; it can be prevented with vaccination. However, there is no vaccine to prevent OPC.

(Choice D) Patients with chronically elevated blood glucose levels have increased risk of developing OPC; however, there is no evidence that this patient has poorly controlled diabetes mellitus.

(Choice E) Prophylactic antibiotics are not indicated for OPC and, in fact, are likely to increase the risk of developing OPC by altering the normal oropharyngeal bacterial flora. Prophylactic antifungals are also not indicated for OPC.

(Choice F) Vitamin A deficiency can impair cell-mediated immunity and create higher susceptibility to OPC. However, patients with vitamin A deficiency typically have drying and thickening of the skin and ocular conjunctivae. Improper administration of inhaled glucocorticoids is far more likely in this patient.

Educational objective:
Improper administration of inhaled glucocorticoids for the treatment of asthma can lead to adverse effects, including oropharyngeal candidiasis and dysphonia. Using a spacer during administration and rinsing the mouth

https://t.me/USMLEWorldStep1

need for short-acting bronchodilators, and lower the risk of serious exacerbations and associated hospitalization.

Low-dose inhaled glucocorticoids are well tolerated and rarely cause systemic adverse effects. However, poor inhalation technique can cause much of the medication to deposit on the oral mucous membranes, where it is ineffective and can lead to **oropharyngeal candidiasis** (OPC) (evidenced by white plaques that are easily scraped off). Patients can avoid this complication by using a spacer and **rinsing the mouth** after inhalation. Dysphonia unrelated to OPC can also occur with inhaled glucocorticoids due to myopathy of laryngeal muscles and mucosal irritation.

(Choice A) Excessive alcohol intake may increase the risk of developing OPC; however, this patient's intake of 1 or 2 beers per day is within acceptable limits and is an unlikely contributing factor.

(Choice B) Diphtheria (due to *Corynebacterium diphtheriae*) is a serious infection that typically presents with pharyngitis and gray oropharyngeal pseudomembranes; it can be prevented with vaccination. However, there is no vaccine to prevent OPC.

(Choice D) Patients with chronically elevated blood glucose levels have increased risk of developing OPC; however, there is no evidence that this patient has poorly controlled diabetes mellitus.

(Choice E) Prophylactic antibiotics are not indicated for OPC and, in fact, are likely to increase the risk of developing OPC by altering the normal oropharyngeal bacterial flora. Prophylactic antifungals are also not indicated for OPC.

(Choice F) Vitamin A deficiency can impair cell-mediated immunity and create higher susceptibility to OPC. However, patients with vitamin A deficiency typically have drying and thickening of the skin and ocular conjunctivae. Improper administration of inhaled glucocorticoids is far more likely in this patient.

Educational objective:
Improper administration of inhaled glucocorticoids for the treatment of asthma can lead to adverse effects, including oropharyngeal candidiasis and dysphonia. Using a spacer during administration and rinsing the mouth after each use can help prevent these adverse effects.

Pharmacology	Pulmonary & Critical Care	Asthma
Subject	System	Topic

https://t.me/USMLEWorldStep1

F. Using vitamin supplements (0%)

Inco
Corre
C

Expl

Patien
persis
gluco
need f

Low-d
inhala
ineffec
off). P
unrela
irritatio

(Choi
or 2 be

(Choi
pharyn
vaccin

(Choi
howev

(Choi
developing OPC by altering the normal oropharyngeal bacterial flora. Prophylactic antifungals are also not indicated for OPC.

Exhibit Display

Candidiasis

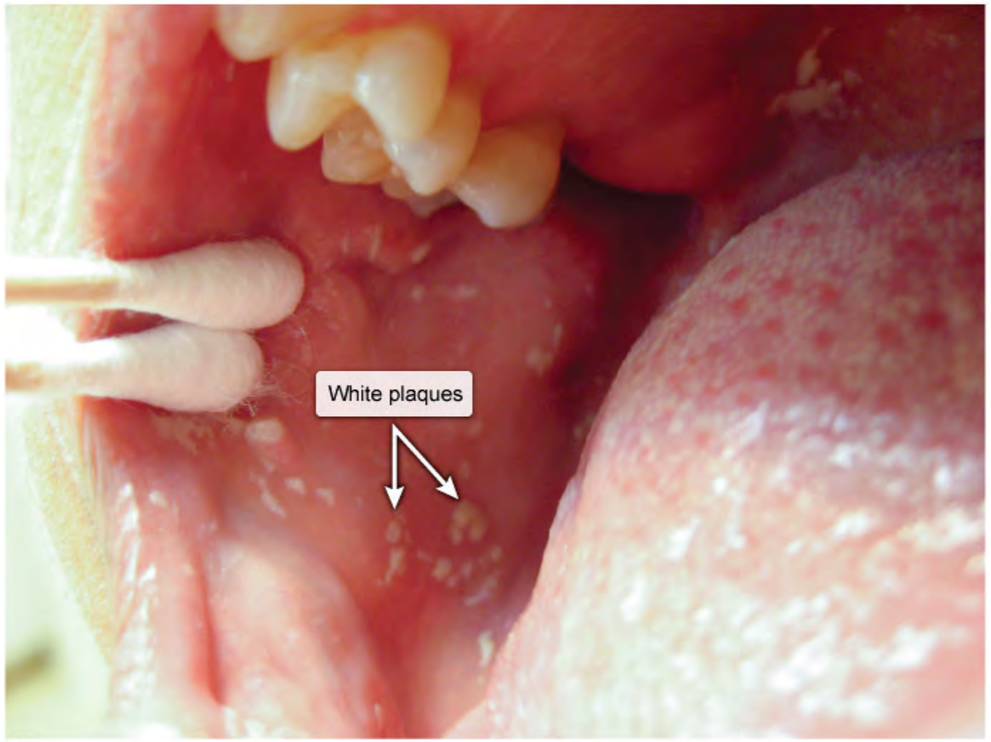

©UWorld

Zoom In | Zoom Out | Reset | New | Existing | My Notebook

https://t.me/USMLEWorldStep1

F. Using vitamin supplements (0%)

Exhibit Display

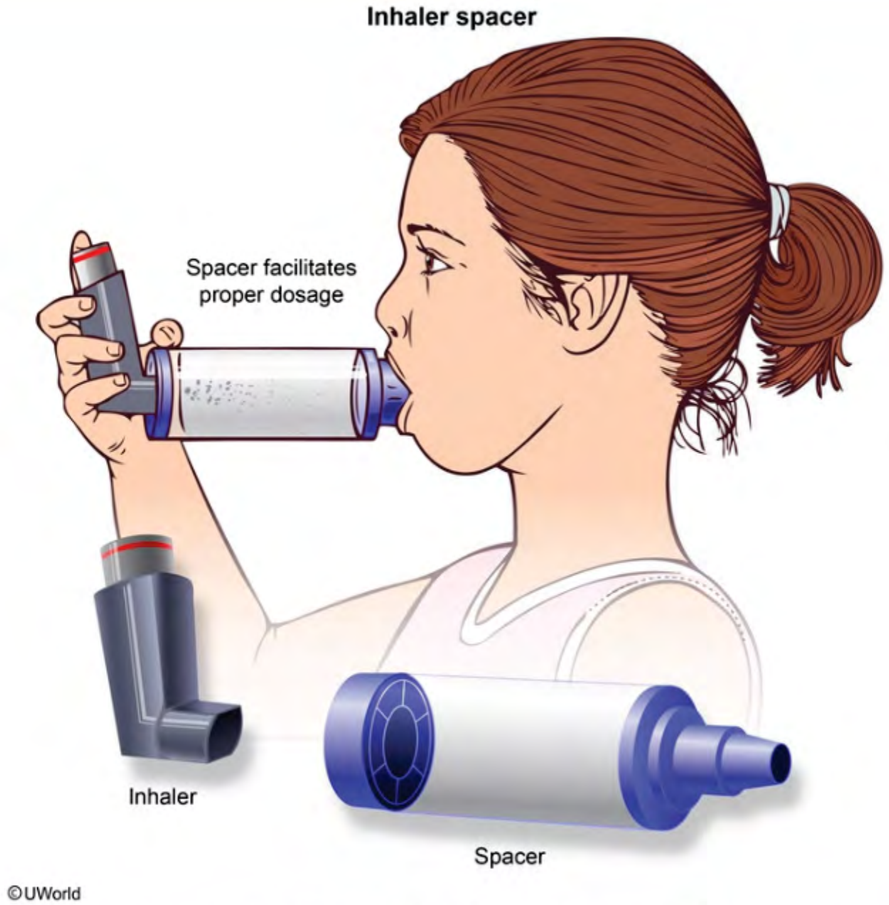

Zoom In | Zoom Out | Reset | New | Existing | My Notebook

developing OPC by altering the normal oropharyngeal bacterial flora. Prophylactic antifungals are also not indicated for OPC.

https://t.me/USMLEWorldStep1

A 24-year-old man comes to the office due to paroxysmal episodes of breathlessness and wheezing for the past 6 months. He does not recognize any triggers for these episodes and reports they are not associated with exercise or stress. The patient has no history of recent illness. He had eczema as a child. The patient has no other medical conditions and takes no medications. Vital signs are within normal limits. Lung examination shows good air movement and no wheezing. Sputum microscopy reveals many granule-containing cells and crystalloid masses. The sputum findings in this patient are a direct result of which of the following cytokines?

- A. IL-1
- B. IL-5
- C. IL-12
- D. Interferon-gamma
- E. TGF-β

Submit

https://t.me/USMLEWorldStep1

A 24-year-old man comes to the office due to paroxysmal episodes of breathlessness and wheezing for the past 6 months. He does not recognize any triggers for these episodes and reports they are not associated with exercise or stress. The patient has no history of recent illness. He had eczema as a child. The patient has no other medical conditions and takes no medications. Vital signs are within normal limits. Lung examination shows good air movement and no wheezing. Sputum microscopy reveals many granule-containing cells and crystalloid masses. The sputum findings in this patient are a direct result of which of the following cytokines?

- A. IL-1 (3%)
- ✓ B. IL-5 (76%)
- C. IL-12 (6%)
- D. Interferon-gamma (9%)
- ✗ E. TGF-β (3%)

Incorrect
Correct answer
B

76%
Answered correctly

07 secs
Time Spent

2023
Version

Explanation

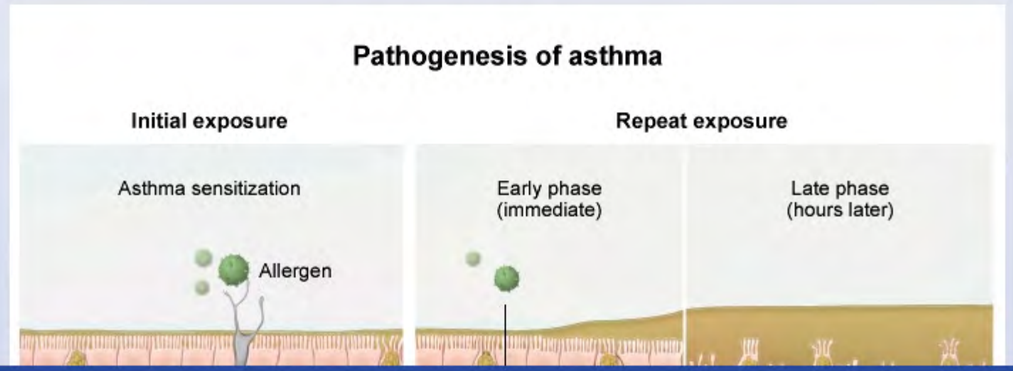

https://t.me/USMLEWorldStep1

A 24-year-old man comes to the office due to paroxysmal episodes of breathlessness and wheezing for the past 6 month
or stre
medic
air mo
masse

Exhibit Display

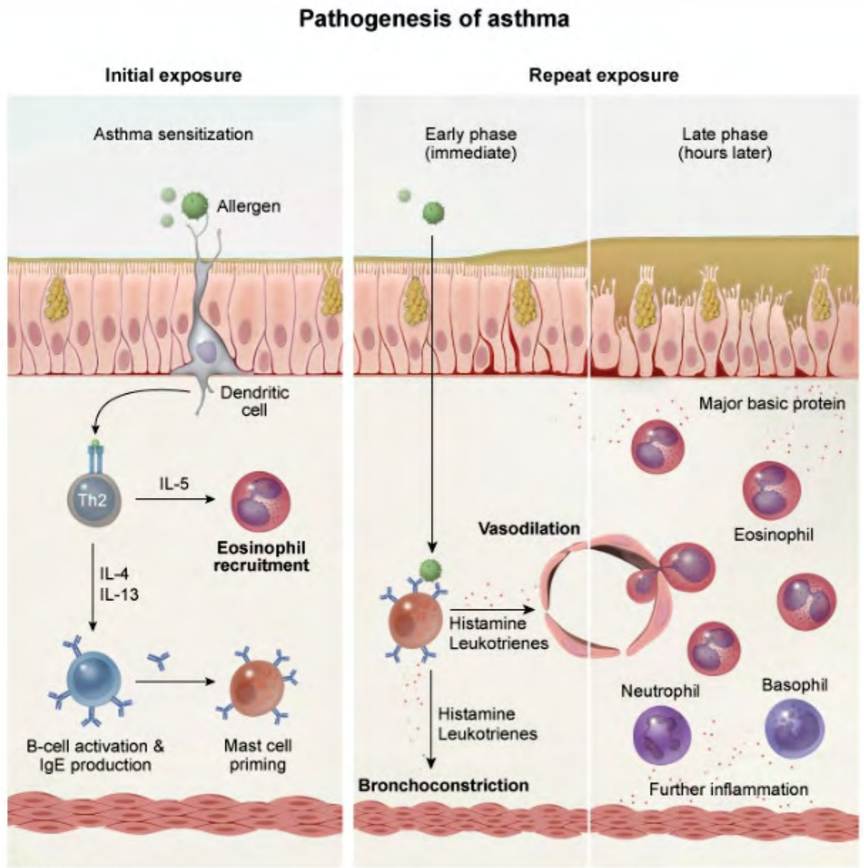

Zoom In | Zoom Out | Reset | New | Existing | My Notebook

https://t.me/USMLEWorldStep1

This young patient with paroxysmal dyspnea and wheezing likely has **asthma**, a disease characterized by airway inflammation, bronchial hyperreactivity, and a variable airflow obstruction. Symptoms that cannot be related to pulmonary infection, inhalation of irritants, stress, exercise, or aspirin ingestion should raise suspicion for **atopic (extrinsic) asthma**. Atopic asthma occurs in genetically predisposed individuals; patients often have a family history of asthma, allergies, or eczema. Sputum microscopy classically demonstrates elevated levels of eosinophils (granule-containing cells) with Charcot-Leyden crystals (bipyramidal-shaped accumulations of eosinophil membrane protein).

Atopic asthma occurs due to an excessive **T_H2-mediated** reaction to environmental aero-antigens (eg, pollen, pet dander). In response to allergic stimuli, these cells secrete **IL-5**, a critical cytokine for **eosinophilic activation**, **recruitment**, and **prolonged survival** in the bronchial mucosa. T_H2 cells also synthesize IL-4, which stimulates IgE formation by plasma cells. As with other type I hypersensitivity reactions, these antigen-specific antibodies bind to receptors on mast cells, and repeated exposure induces mast cell degranulation. This leads to bronchoconstriction, increased vascular permeability, and increased mucus production associated with acute asthma exacerbations. Eosinophils also release inflammatory mediators (ie, major basic protein, eosinophil cationic protein) that damage the bronchial epithelium later in the immune response.

(Choice A) Although IL-1 release from macrophages is involved in asthma pathogenesis, it is not a specific cytokine. IL-1 release is a component of almost all inflammatory processes and does not necessarily cause eosinophil infiltration.

(Choice C) IL-12 functions to promote the differentiation of T_H1 cells; it is not directly involved in eosinophil recruitment.

(Choice D) Interferon-gamma is secreted by helper T cells and functions to activate macrophages, thereby promoting adaptive immunity against intracellular pathogens. It is not directly chemotactic for eosinophils.

(Choice E) Transforming growth factor beta (TGF-β) is a growth factor involved in tissue regeneration and repair; high levels are associated with subepithelial fibrosis and airway remodeling seen in chronic asthma. However, it is not chemotactic for eosinophils.

Educational objective:

https://t.me/USMLEWorldStep1

history of asthma, allergies, or eczema. Sputum microscopy classically demonstrates elevated levels of eosinophils (granule-containing cells) with Charcot-Leyden crystals (bipyramidal-shaped accumulations of eosinophil membrane protein).

Atopic asthma occurs due to an excessive **T_H2-mediated** reaction to environmental aero-antigens (eg, pollen, pet dander). In response to allergic stimuli, these cells secrete **IL-5**, a critical cytokine for **eosinophilic activation**, **recruitment**, and **prolonged survival** in the bronchial mucosa. T_H2 cells also synthesize IL-4, which stimulates IgE formation by plasma cells. As with other type I hypersensitivity reactions, these antigen-specific antibodies bind to receptors on mast cells, and repeated exposure induces mast cell degranulation. This leads to bronchoconstriction, increased vascular permeability, and increased mucus production associated with acute asthma exacerbations. Eosinophils also release inflammatory mediators (ie, major basic protein, eosinophil cationic protein) that damage the bronchial epithelium later in the immune response.

(Choice A) Although IL-1 release from macrophages is involved in asthma pathogenesis, it is not a specific cytokine. IL-1 release is a component of almost all inflammatory processes and does not necessarily cause eosinophil infiltration.

(Choice C) IL-12 functions to promote the differentiation of T_H1 cells; it is not directly involved in eosinophil recruitment.

(Choice D) Interferon-gamma is secreted by helper T cells and functions to activate macrophages, thereby promoting adaptive immunity against intracellular pathogens. It is not directly chemotactic for eosinophils.

(Choice E) Transforming growth factor beta (TGF-β) is a growth factor involved in tissue regeneration and repair; high levels are associated with subepithelial fibrosis and airway remodeling seen in chronic asthma. However, it is not chemotactic for eosinophils.

Educational objective:
Paroxysmal breathlessness and wheezing in a young patient that are unrelated to ingestion of aspirin, pulmonary infection, inhalation of irritants, and/or exercise should raise a strong suspicion for atopic (extrinsic) asthma. Classic sputum findings include eosinophils and Charcot-Leyden crystals. Eosinophils are recruited and activated by IL-5 secreted by T_H2 type T cells.

https://t.me/USMLEWorldStep1

Exhibit Display

Eosinophils

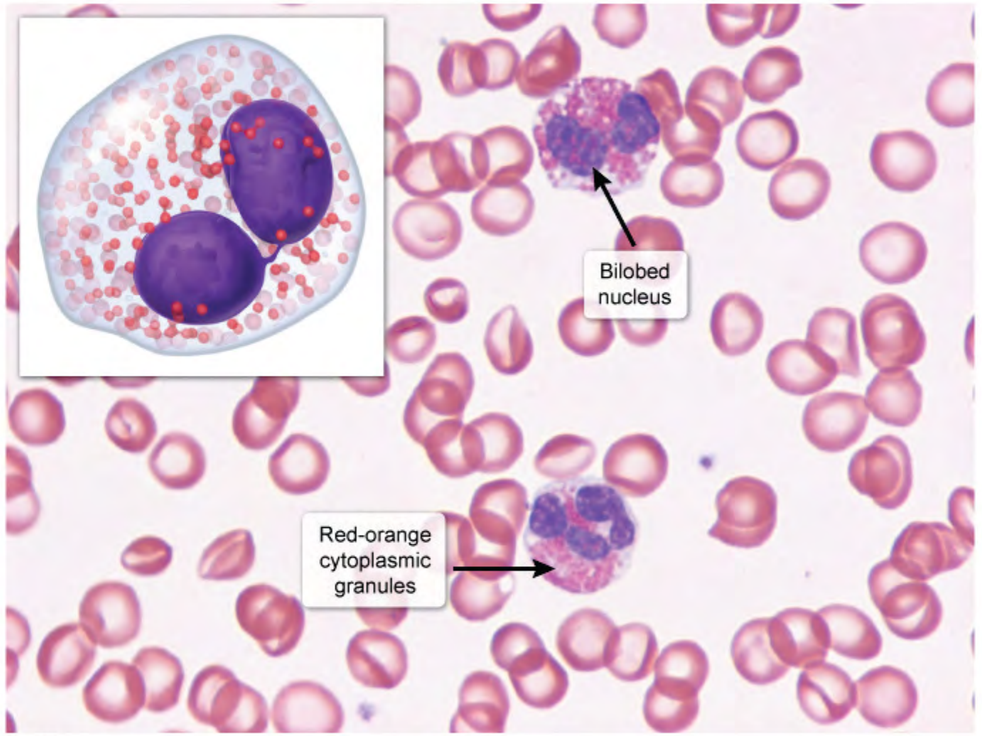

Zoom In | Zoom Out | Reset | New | Existing | My Notebook

This y
inflam
pulmo
(extri
histor
eosin
eosin

Atopic
dande
recrui
IgE fo
bind t
bronch
asthm
cationi

(Choi
cytoki
eosin

(Choi
recruit

(Choi
promo

(Choice E) Transforming growth factor beta (TGF-β) is a growth factor involved in tissue regeneration and repair; high levels are associated with subepithelial fibrosis and airway remodeling seen in chronic asthma. However, it is

https://t.me/USMLEWorldStep1

Exhibit Display

This y
inflam
pulmo
(extri
histor
eosino
eosino

Atopic
dande
recrui
IgE fo
bind t
bronch
asthm
cationi

(Choi
cytoki
eosino

(Choi
recruit

(Choi
promo

(Choice E) Transforming growth factor beta (TGF-β) is a growth factor involved in tissue regeneration and repair; high levels are associated with subepithelial fibrosis and airway remodeling seen in chronic asthma. However, it is

Charcot-Leyden crystals

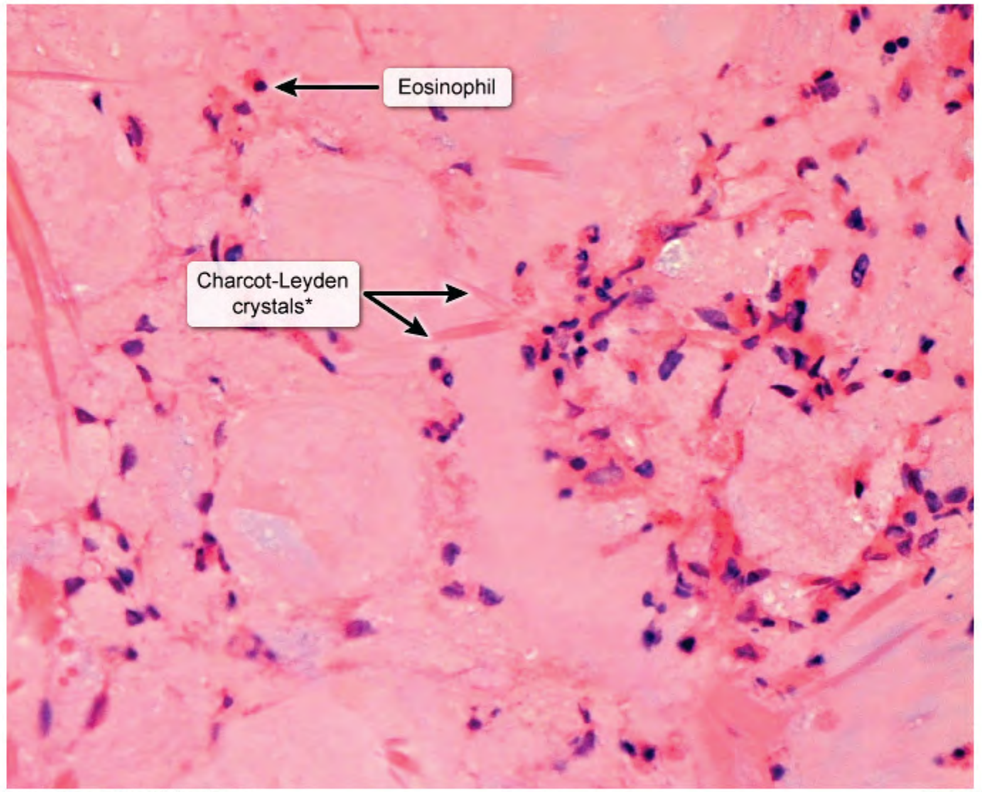

*Formed by eosinophil breakdown

©UWorld

Zoom In | Zoom Out | Reset | New | Existing | My Notebook

https://t.me/USMLEWorldStep1

A 52-year-old man comes to the office for a routine health maintenance visit. The patient feels well. He is a former cigarette smoker of 15 pack-years but quit 10 years ago. The patient no longer has cravings or an interest in smoking. He enjoys restoring and preserving antique paintings, spending considerable time in his basement studio. The patient has an African gray parrot and lives with his wife in a home built in the 1950s. Cardiovascular and pulmonary examinations are normal. He expresses concern about his risk for lung cancer. Protection against which of the following is most likely to lower this patient's risk for lung cancer?

- A. Benzene solvent
- B. Bird antigens
- C. Bisphenol A
- D. Mold spores
- E. Radon gas

Submit

https://t.me/USMLEWorldStep1

A 52-year-old man comes to the office for a routine health maintenance visit. The patient feels well. He is a former cigarette smoker of 15 pack-years but quit 10 years ago. The patient no longer has cravings or an interest in smoking. He enjoys restoring and preserving antique paintings, spending considerable time in his basement studio. The patient has an African gray parrot and lives with his wife in a home built in the 1950s. Cardiovascular and pulmonary examinations are normal. He expresses concern about his risk for lung cancer. Protection against which of the following is most likely to lower this patient's risk for lung cancer?

- ✗ A. Benzene solvent (31%)
- B. Bird antigens (4%)
- C. Bisphenol A (7%)
- D. Mold spores (9%)
- ✓ E. Radon gas (48%)

Incorrect
Correct answer
E

48%
Answered correctly

03 secs
Time Spent

2023
Version

Explanation

This former smoker has an elevated lifetime risk for lung cancer. He quit smoking, which is the single most important intervention for decreasing his risk. In addition to combustible tobacco, several **environmental carcinogens** have been definitively linked to lung cancer. The most significant of these is **radon** (^{222}Rn), a colorless, odorless, **radioactive** gas produced from the decay of uranium, found throughout the earth.

Radon enters structures through subterranean cracks and contaminated groundwater and accumulates in the lower levels of the home (eg, **basements**). Radon is unstable and undergoes nuclear decay, emitting radiation in the form of alpha particles. Although they have minimal penetration in human tissue (< 50 microns), alpha particles are the most potent form of DNA-damaging ionizing radiation. Because radon gas is **inhaled**, the respiratory tract

https://t.me/USMLEWorldStep1

This former smoker has an elevated lifetime risk for lung cancer. He quit smoking, which is the single most important intervention for decreasing his risk. In addition to combustible tobacco, several **environmental carcinogens** have been definitively linked to lung cancer. The most significant of these is **radon** (^{222}Rn), a colorless, odorless, **radioactive** gas produced from the decay of uranium, found throughout the earth.

Radon enters structures through subterranean cracks and contaminated groundwater and accumulates in the lower levels of the home (eg, **basements**). Radon is unstable and undergoes nuclear decay, emitting radiation in the form of alpha particles. Although they have minimal penetration in human tissue (< 50 microns), alpha particles are the most potent form of DNA-damaging ionizing radiation. Because radon gas is **inhaled**, the respiratory tract epithelium is most susceptible to mutagenesis.

Radon is the second-leading cause of lung cancer in the US and the leading environmental risk factor for **lung cancer in nonsmokers**. The risk is multiplied in current or previous smokers. Radon testing and mitigation (eg, negative soil depressurization to prevent upward gas seepage) are recommended by multiple federal agencies and medical societies.

(Choice A) Reactive metabolites of benzene (benzoquinones) cause oxidative DNA damage; benzene is a carcinogen implicated in hematologic neoplasms (eg, acute leukemias). The main domestic source of benzene exposure is cigarette smoke. Organic solvents (eg, paint thinners, lacquers) contain low levels of benzene and can irritate the mucosae (eg, conjunctivitis, nonspecific respiratory tract inflammation) but are not clearly linked to lung cancer.

(Choices B and D) Bird ownership (eg, parrots) and mold spores (eg, *Penicillium* spp., *Aspergillus* spp.) can predispose to hypersensitivity pneumonitis, a type IV inflammatory lung disease (granulomatous, T-lymphocyte–driven) that can transition into pulmonary fibrosis if untreated. However, it does not cause oncogenic DNA damage.

(Choice C) Bisphenol A is a polycarbonate compound that is ubiquitous in consumer goods (eg, plastic containers). It is classified as an endocrine-disrupting chemical, functioning as mixed estrogen agonist-antagonist and has been linked to an array of reproductive (eg, decreased spermatogenesis, decreased ovarian follicle mass) and cardiometabolic (eg, insulin resistance) disorders.

Educational objective:

https://t.me/USMLEWorldStep1

Radon enters structures through subterranean cracks and contaminated groundwater and accumulates in the lower levels of the home (eg, **basements**). Radon is unstable and undergoes nuclear decay, emitting radiation in the form of alpha particles. Although they have minimal penetration in human tissue (< 50 microns), alpha particles are the most potent form of DNA-damaging ionizing radiation. Because radon gas is **inhaled**, the respiratory tract epithelium is most susceptible to mutagenesis.

Radon is the second-leading cause of lung cancer in the US and the leading environmental risk factor for **lung cancer in nonsmokers**. The risk is multiplied in current or previous smokers. Radon testing and mitigation (eg, negative soil depressurization to prevent upward gas seepage) are recommended by multiple federal agencies and medical societies.

(Choice A) Reactive metabolites of benzene (benzoquinones) cause oxidative DNA damage; benzene is a carcinogen implicated in hematologic neoplasms (eg, acute leukemias). The main domestic source of benzene exposure is cigarette smoke. Organic solvents (eg, paint thinners, lacquers) contain low levels of benzene and can irritate the mucosae (eg, conjunctivitis, nonspecific respiratory tract inflammation) but are not clearly linked to lung cancer.

(Choices B and D) Bird ownership (eg, parrots) and mold spores (eg, *Penicillium* spp., *Aspergillus* spp.) can predispose to hypersensitivity pneumonitis, a type IV inflammatory lung disease (granulomatous, T-lymphocyte–driven) that can transition into pulmonary fibrosis if untreated. However, it does not cause oncogenic DNA damage.

(Choice C) Bisphenol A is a polycarbonate compound that is ubiquitous in consumer goods (eg, plastic containers). It is classified as an endocrine-disrupting chemical, functioning as mixed estrogen agonist-antagonist and has been linked to an array of reproductive (eg, decreased spermatogenesis, decreased ovarian follicle mass) and cardiometabolic (eg, insulin resistance) disorders.

Educational objective:
Radon is a radioactive gas found throughout the earth that enters homes through contaminated soil and groundwater. It emits highly ionizing alpha radiation, causing DNA damage in the respiratory tract epithelium when inhaled. Aside from cigarette smoke, radon is the most important environmental risk factor for lung cancer.

https://t.me/USMLEWorldStep1

This former smoker has an elevated lifetime risk for lung cancer. He quit smoking, which is the single most important intervention for decreasing his risk. In addition to combustible tobacco, several **environmental carcin**

colorle

Radon

lower

the for

are the

epithe

Radon

cance

negati

medic

(Choi

carcin

expos

irritate

cancer

(Choi

predis

driven

damag

(Choi

contai

and ha

and ca

Educational objective:

Exhibit Display

Zoom In | Zoom Out | Reset | New | Existing | My Notebook

https://t.me/USMLEWorldStep1

A 72-year-old man is brought to the hospital due to a 1-week history of progressive confusion and lethargy. He has also had a persistent cough for the past several weeks with 2 episodes of blood in the sputum. The patient has hyperlipidemia, well-controlled hypertension, and a 48-pack-year smoking history. On examination, mucous membranes are moist. Lung auscultation reveals wheezing in the left lung. Serum sodium is 123 mEq/dL. Chest x-ray reveals a mass in the upper lobe of the left lung. A bronchoscopic biopsy of the mass is performed, and light microscopy of the tissue confirms an aggressive lung cancer. Which of the following is most likely to be present on further analysis of the patient's biopsy sample?

- A. Epidermal growth factor receptor gene mutation
- B. Glial fibrillary acidic protein
- C. *KRAS* mutation
- D. Mucin
- E. Neural cell adhesion molecule
- F. Vimentin

Submit

https://t.me/USMLEWorldStep1

A 72-year-old man is brought to the hospital due to a 1-week history of progressive confusion and lethargy. He has also had a persistent cough for the past several weeks with 2 episodes of blood in the sputum. The patient has hyperlipidemia, well-controlled hypertension, and a 48-pack-year smoking history. On examination, mucous membranes are moist. Lung auscultation reveals wheezing in the left lung. Serum sodium is 123 mEq/dL. Chest x-ray reveals a mass in the upper lobe of the left lung. A bronchoscopic biopsy of the mass is performed, and light microscopy of the tissue confirms an aggressive lung cancer. Which of the following is most likely to be present on further analysis of the patient's biopsy sample?

- A. Epidermal growth factor receptor gene mutation (16%)
- ✗ B. Glial fibrillary acidic protein (5%)
- C. *KRAS* mutation (16%)
- D. Mucin (6%)
- ✓ E. Neural cell adhesion molecule (48%)
- F. Vimentin (6%)

Incorrect
Correct answer
E

48%
Answered correctly

03 secs
Time Spent

2023
Version

Explanation

Small cell carcinoma of the lung	
Clinical features	• Risks: smoking, male > female • Highly aggressive • Central location
	• Sheets of small blue cells with scant cytoplasm

https://t.me/USMLEWorldStep1

Small cell carcinoma of the lung	
Clinical features	• Risks: smoking, male > female • Highly aggressive • Central location
Histology	• Sheets of small blue cells with scant cytoplasm • Neuroendocrine markers: NCAM, neuron-specific enolase, chromogranin, synaptophysin
Associated paraneoplastic syndromes	• SIADH • Cushing syndrome • Lambert-Eaton syndrome
NCAM = neural cell adhesion molecule; **SIADH** = syndrome of inappropriate antidiuretic hormone.	

This patient with an aggressive lung cancer has symptomatic hyponatremia (eg, confusion, lethargy) despite appearing euvolemic (moist mucous membranes). This presentation suggests **small cell carcinoma of the lung** complicated by paraneoplastic syndrome of inappropriate antidiuretic hormone secretion (**SIADH**).

Small cell carcinoma, the **most aggressive** type of lung cancer, typically occurs in patients with a history of **heavy smoking**. It is characterized by a rapid doubling time and early distant spread; most patients have metastatic disease at the time of diagnosis. Although small cell carcinoma is sensitive to chemotherapy and radiation, most patients relapse within months, and the 5-year survival rate is very low. This malignancy frequently synthesizes hormones or hormone-like substances, resulting in paraneoplastic syndromes (eg, vasopressin resulting in SIADH, adrenocorticotropic hormone resulting in Cushing syndrome).

Small cell carcinomas show evidence of neuroendocrine differentiation. These tumors stain for **neuroendocrine markers**, such as **neural cell adhesion molecule** (**CD56**), neuron-specific enolase, **chromogranin**, and synaptophysin. Neurosecretory granules can be identified in the cytoplasm of the tumor cells on electron microscopy.

(Choice A) Epidermal growth factor receptor gene mutations are present in some non-small cell lung cancers

https://t.me/USMLEWorldStep1

Small cell carcinoma, the **most aggressive** type of lung cancer, typically occurs in patients with a history of **heavy smoking**. It is characterized by a rapid doubling time and early distant spread; most patients have metastatic disease at the time of diagnosis. Although small cell carcinoma is sensitive to chemotherapy and radiation, most patients relapse within months, and the 5-year survival rate is very low. This malignancy frequently synthesizes hormones or hormone-like substances, resulting in paraneoplastic syndromes (eg, vasopressin resulting in SIADH, adrenocorticotropic hormone resulting in Cushing syndrome).

Small cell carcinomas show evidence of neuroendocrine differentiation. These tumors stain for **neuroendocrine markers**, such as **neural cell adhesion molecule** (**CD56**), neuron-specific enolase, **chromogranin**, and synaptophysin. Neurosecretory granules can be identified in the cytoplasm of the tumor cells on electron microscopy.

(Choice A) Epidermal growth factor receptor gene mutations are present in some non-small cell lung cancers (NSCLCs), most commonly in adenocarcinoma in nonsmokers. This mutation can predict responsiveness to tyrosine kinase inhibitor drugs (eg, erlotinib, afatinib). It is not present in small cell lung cancer.

(Choice B) Glial fibrillary acidic protein-positive fibrils are seen with some astrocytomas.

(Choice C) *KRAS* is an activating mutation that is present in up to 25% of lung adenocarcinomas and is associated with smoking. It is also frequently seen in colorectal and pancreatic cancer.

(Choice D) Mucin is a glycoprotein that frequently provides a protective barrier to epithelial cells. However, the *MUC* gene is overexpressed in a variety of malignancies (eg, breast, NSCLC, pancreatic) and is a marker for poor prognosis.

(Choice F) Vimentin is an intermediate filament found within cells of mesenchymal origin and is used in diagnosing sarcomas.

Educational objective:
Small cell carcinoma of the lung is the most aggressive type of lung cancer and is commonly associated with paraneoplastic syndromes (eg, SIADH, Cushing syndrome). It is thought to have a neuroendocrine origin; tumor cells express neuroendocrine markers (eg, neural cell adhesion molecule, chromogranin, synaptophysin) and contain neurosecretory granules in the cytoplasm.

https://t.me/USMLEWorldStep1

A 60-year-old man is brought to the emergency department following a motor vehicle collision. He is comatose and unable to provide any information. Multiple blunt injuries of the torso and abdomen are present. Review of the patient's medical record reveals a history of right upper lobe cavitary tuberculosis that was effectively treated several years ago. Recent notes from the primary care physician indicate the patient is otherwise healthy, with no fevers, night sweats, or weight loss. He is a never smoker. After initial stabilization, CT of the head, neck, chest, abdomen, and pelvis is obtained. A representative slice of the chest CT, shown in the image below, redemonstrates his known right upper lobe cavity. Compared to prior imaging, the cavity now appears to be filled with a round mass as shown in the exhibit. Which of the following best describes this patient's condition?

- A. Allergic inflammation
- B. Chronic colonization
- C. Contagious infection
- D. Heterotopic calcification
- E. Invasive malignancy

Submit

https://t.me/USMLEWorldStep1

A 60-year-old man is brought to the emergency department following a motor vehicle collision. He is comatose and ur
patien
severa
fevers
abdom
redem
with a

Sub

Exhibit Display

Zoom In Zoom Out Reset New | Existing My Notebook

https://t.me/USMLEWorldStep1

A 60-year-old man is brought to the emergency department following a motor vehicle collision. He is comatose and unable to provide any information. Multiple blunt injuries of the torso and abdomen are present. Review of the patient's medical record reveals a history of right upper lobe cavitary tuberculosis that was effectively treated several years ago. Recent notes from the primary care physician indicate the patient is otherwise healthy, with no fevers, night sweats, or weight loss. He is a never smoker. After initial stabilization, CT of the head, neck, chest, abdomen, and pelvis is obtained. A representative slice of the chest CT, shown in the image below, redemonstrates his known right upper lobe cavity. Compared to prior imaging, the cavity now appears to be filled with a round mass as shown in the exhibit. Which of the following best describes this patient's condition?

- A. Allergic inflammation (3%)
- ✓ B. Chronic colonization (40%)
- C. Contagious infection (10%)
- D. Heterotopic calcification (40%)
- E. Invasive malignancy (4%)

Correct

40% Answered correctly

11 secs Time Spent

2023 Version

Explanation

Spectrum of pulmonary aspergillosis

***Aspergillus* spore inhalation**
(ubiquitous in environment)

https://t.me/USMLEWorldStep1

A 60-year-old man is brought to the emergency department following a motor vehicle collision. He is comatose and ur
patien
severa
fevers
abdom
redem
with a

Cor

Expl

Exhibit Display

Spectrum of pulmonary aspergillosis

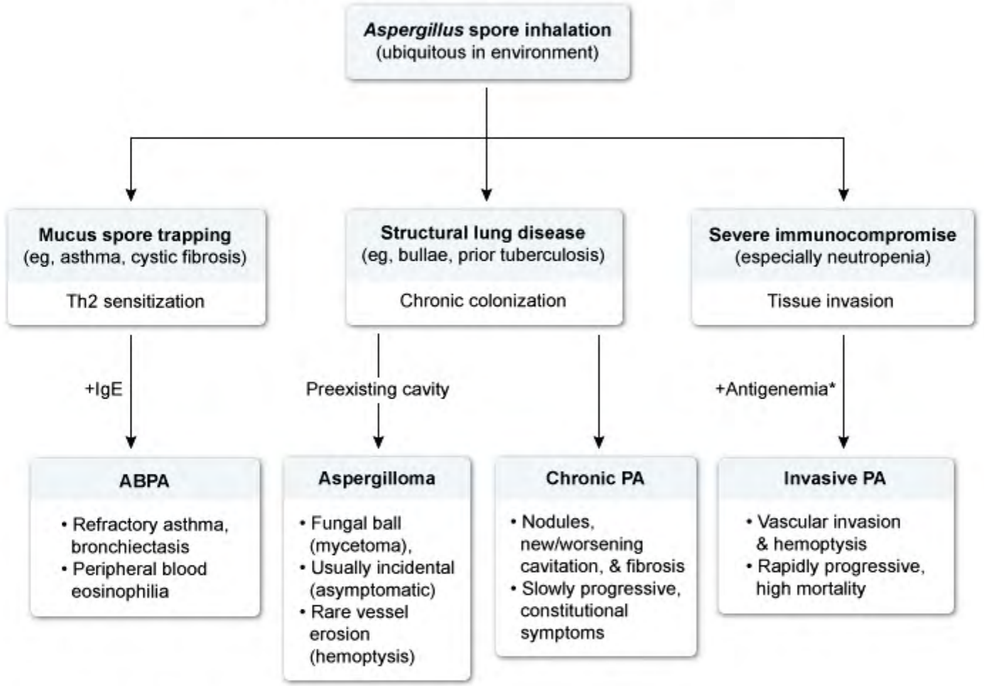

*Circulating fungal antigens (eg, galactomannan, beta-D-glucan)
ABPA = allergic bronchopulmonary aspergillosis; **PA** = pulmonary aspergillosis.

©UWorld

Zoom In | Zoom Out | Reset | New | Existing | My Notebook

https://t.me/USMLEWorldStep1

*Circulating fungal antigens (eg, galactomannan, beta-D-glucan)
ABPA = allergic bronchopulmonary aspergillosis; **PA** = pulmonary aspergillosis.

©UWorld

This asymptomatic patient with previously eradicated tuberculosis now has a spherical mass occupying a preexisting lung cavity, findings consistent with an aspergilloma. ***Aspergillus fumigatus*** is a mold that is ubiquitous in the environment and widely present in soil and organic matter. Spores are constantly inhaled and typically cleared by the respiratory tract's innate defenses (eg, mucociliary escalator, macrophages). However, **chronic colonization** can occur in patients with underlying abnormal lung structure, such as those with bullae (eg, emphysema) or **old cavities** (eg, prior tuberculosis, postsurgical status).

Over months to years, *Aspergillus* proliferates in the cavity, forming a conglomeration of hyphae and cellular debris known as an **aspergilloma**. The fungus ball (mycetoma) appears as a round intracavity mass surrounded by a crescent of air (surrounding empty space). The aspergilloma shifts with gravity, helping distinguish it from other lung masses (eg, neoplasm) fixed to the parenchyma.

Aspergillomas typically grow uneventfully and do not elicit a significant host immunologic reaction. Therefore, they usually remain asymptomatic for years and are only **detected incidentally** (as in this trauma patient). Occasionally, aspergillomas can erode into adjacent blood vessels, producing **hemoptysis**.

(Choice A) Allergic bronchopulmonary aspergillosis is a T_H2–induced, IgE-mediated hypersensitivity to *Aspergillus* spores that become trapped in dysfunctional airways (eg, asthma, cystic fibrosis). It presents with difficult-to-control asthma and bronchiectasis (copious, thick sputum; thickened dilated airways with mucus impaction).

(Choice C) *Aspergillus* is not contagious (ie, transmissible from person to person); it is acquired passively from inhalation of fungal spores in the environment. Reactivation tuberculosis can cause new areas of cavitation or consolidation (not a cavity-filling mass) and is typically accompanied by profound constitutional symptoms (eg, weight loss, night sweats, fever).

(Choice D) Dystrophic calcification is a frequent sequela of granulomatous inflammation (eg, old/healed histoplasmosis or tuberculosis). However, such granuloma-related calcification would have radiodensity equal to that of bone (eg, similar to adjacent vertebrae), would not affect a preexisting cavity, and typically also involves the hilar lymph nodes.

(Choice E) Squamous cell lung cancer can cavitate (representing central tumor necrosis). However, invasive

https://t.me/USMLEWorldStep1

known as an **aspergilloma**. The fungus ball (mycetoma) appears as a round intracavity mass surrounded by a crescent of air (surrounding empty space). The aspergilloma shifts with gravity, helping distinguish it from other lung masses (eg, neoplasm) fixed to the parenchyma.

Aspergillomas typically grow uneventfully and do not elicit a significant host immunologic reaction. Therefore, they usually remain asymptomatic for years and are only **detected incidentally** (as in this trauma patient). Occasionally, aspergillomas can erode into adjacent blood vessels, producing **hemoptysis**.

(Choice A) Allergic bronchopulmonary aspergillosis is a T_H2–induced, IgE-mediated hypersensitivity to *Aspergillus* spores that become trapped in dysfunctional airways (eg, asthma, cystic fibrosis). It presents with difficult-to-control asthma and bronchiectasis (copious, thick sputum; thickened dilated airways with mucus impaction).

(Choice C) *Aspergillus* is not contagious (ie, transmissible from person to person); it is acquired passively from inhalation of fungal spores in the environment. Reactivation tuberculosis can cause new areas of cavitation or consolidation (not a cavity-filling mass) and is typically accompanied by profound constitutional symptoms (eg, weight loss, night sweats, fever).

(Choice D) Dystrophic calcification is a frequent sequela of granulomatous inflammation (eg, old/healed histoplasmosis or tuberculosis). However, such granuloma-related calcification would have radiodensity equal to that of bone (eg, similar to adjacent vertebrae), would not affect a preexisting cavity, and typically also involves the hilar lymph nodes.

(Choice E) Squamous cell lung cancer can cavitate (representing central tumor necrosis). However, invasive malignancies violate anatomic planes, appearing irregular and spiculated, and are typically symptomatic (eg, chest pain, hemoptysis, weight loss). A well-circumscribed, round mass forming within a preexisting, thin-walled cavity is more consistent with aspergilloma.

Educational objective:
Aspergillus fumigatus, a ubiquitous environmental mold, can chronically colonize old pulmonary cavities (eg, prior tuberculosis), forming a fungus ball (aspergilloma) that does not elicit a significant host immune response and is typically discovered incidentally.

Microbiology	Pulmonary & Critical Care	Aspergillosis
Subject	System	Topic

https://t.me/USMLEWorldStep1

- Peripheral blood eosinophilia
- Usually incidental (asymptomatic)
- cavitation, & fibrosis
- Slowly progressive,
- Rapidly progressive, high mortality

Exhibit Display

Pulmonary aspergilloma

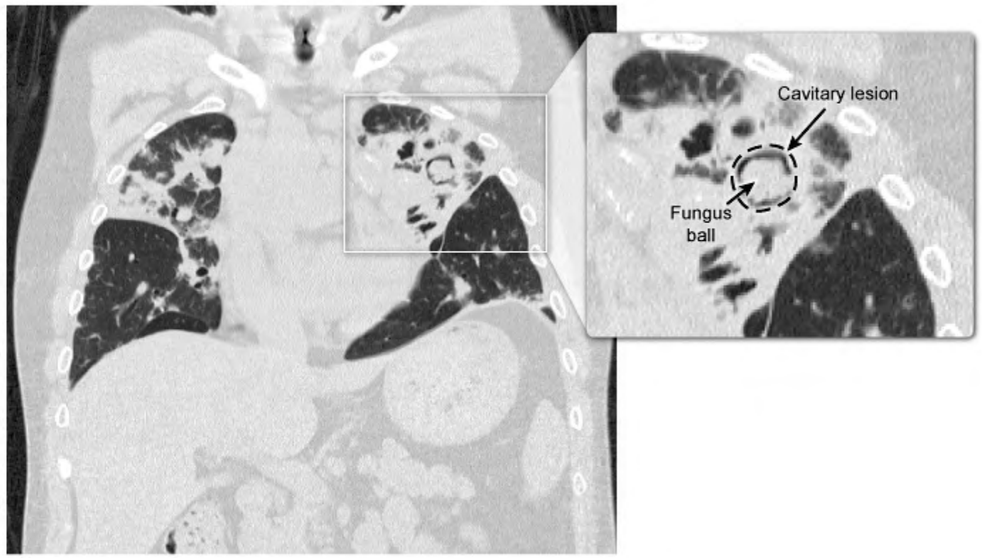

©UWorld

Zoom In | Zoom Out | Reset | New | Existing | My Notebook

This a
preexi
ubiqui
typical
chron
emphy

Over r
known
cresce
lung m

Asperg
usually
Occas

(Choi
spores
contro

(Choi
inhalat
consol
weight

(Choice D) Dystrophic calcification is a frequent sequela of granulomatous inflammation (eg, old/healed histoplasmosis or tuberculosis). However, such granuloma-related calcification would have radiodensity equal to

https://t.me/USMLEWorldStep1

- Peripheral blood eosinophilia
- Usually incidental (asymptomatic)
- cavitation, & fibrosis
- Slowly progressive,
- Rapidly progressive, high mortality

Exhibit Display

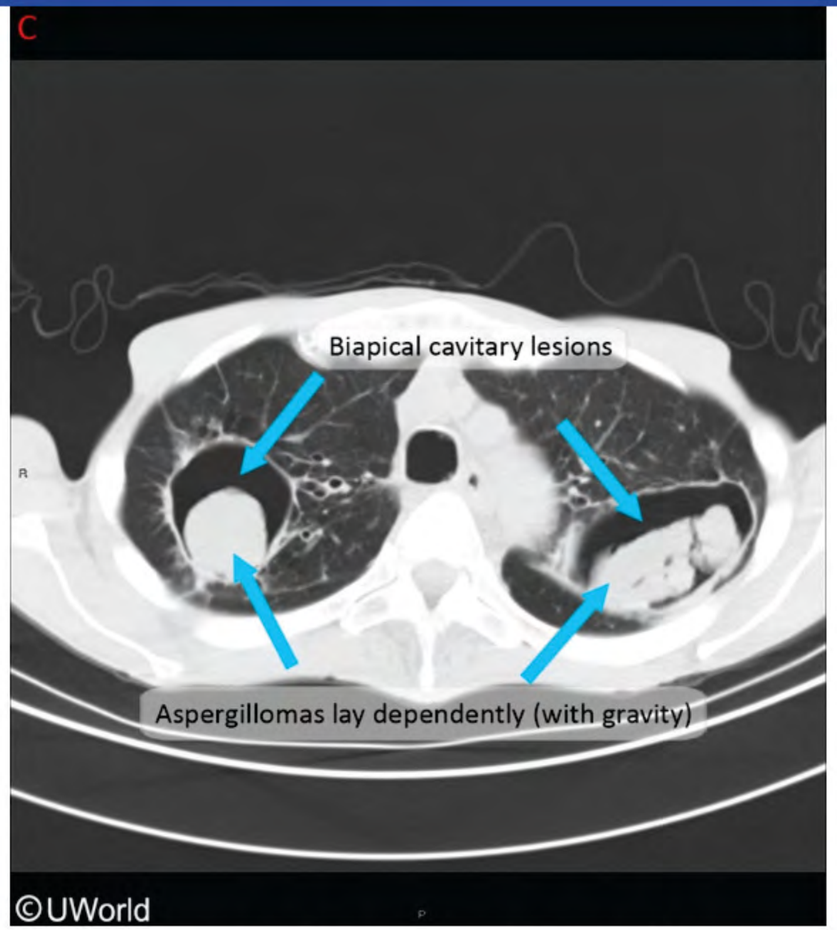

Zoom In | Zoom Out | Reset | New | Existing | My Notebook

This a
preexi
ubiqui
typical
chron
emphy

Over r
known
cresce
lung m

Asperg
usually
Occas

(Choi
spores
contro

(Choi
inhalat
consol
weight

(Choice D) Dystrophic calcification is a frequent sequela of granulomatous inflammation (eg, old/healed histoplasmosis or tuberculosis). However, such granuloma-related calcification would have radiodensity equal to

https://t.me/USMLEWorldStep1

- Peripheral blood eosinophilia
- Usually incidental (asymptomatic)
- cavitation, & fibrosis
- Slowly progressive,
- Rapidly progressive, high mortality

Exhibit Display

Bronchiectasis

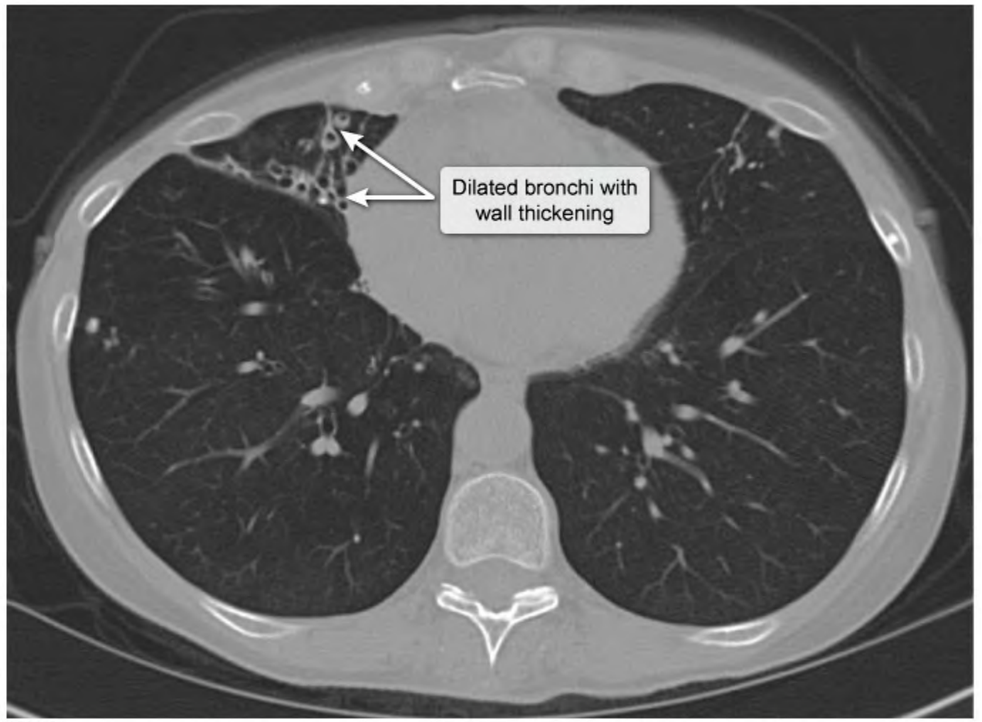

©UWorld

Zoom In | Zoom Out | Reset | New | Existing | My Notebook

This a
preexi
ubiqui
typical
chron
emphy

Over r
known
cresce
lung m

Asperg
usually
Occas

(Choi
spores
contro

(Choi
inhalat
consol
weight

(Choice D) Dystrophic calcification is a frequent sequela of granulomatous inflammation (eg, old/healed histoplasmosis or tuberculosis). However, such granuloma-related calcification would have radiodensity equal to

https://t.me/USMLEWorldStep1

*Circulating fungal antigens (eg, galactomannan, beta-D-glucan)
ABPA = allergic bronchopulmonary aspergillosis; **PA** = pulmonary aspergillosis.

Exhibit Display

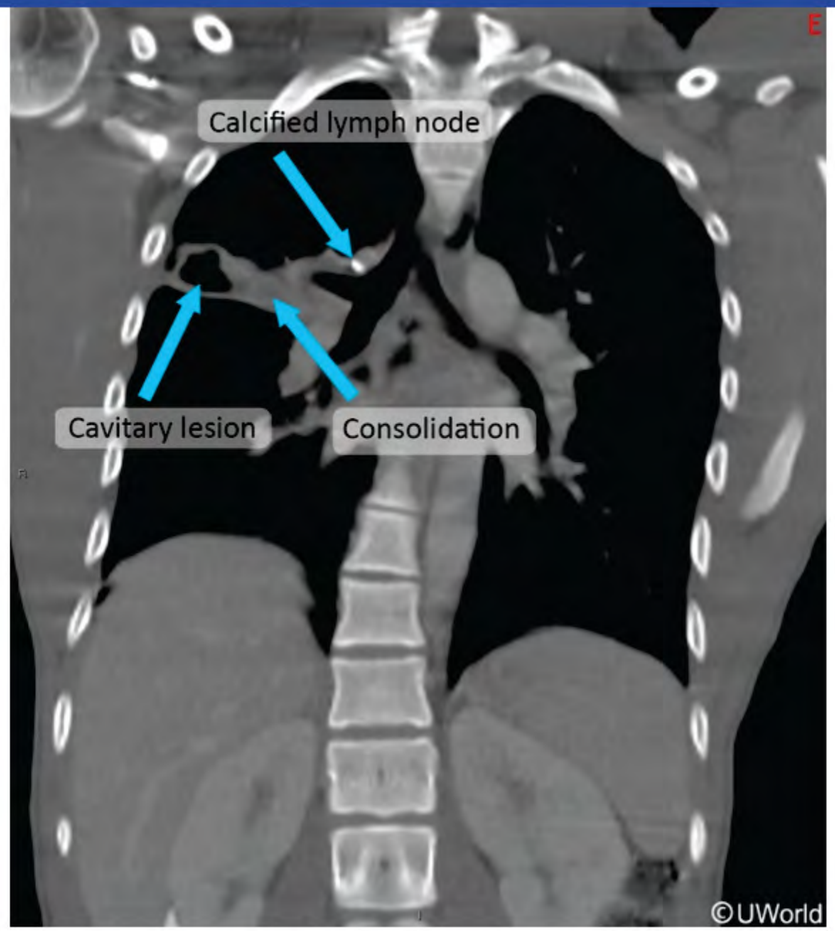

Zoom In | Zoom Out | Reset | New | Existing | My Notebook

This a
preexi
ubiqui
typical
chron
emphy

Over r
known
cresce
lung m

Asperg
usuall
Occas

(Choi
spores
contro

(Choi
inhala
consol
weight

(Choi
histopl
that of
hilar lymph nodes.

(Choice E) Squamous cell lung cancer can cavitate (representing central tumor necrosis). However, invasive

https://t.me/USMLEWorldStep1

A 56-year-old man is evaluated for dyspnea, wheezing, and cough productive of yellow sputum. The patient reports that he has been treated with antibiotics when the dyspnea is severe. He has smoked 2 packs of cigarettes daily for the past 25 years. The schematic diagram below is a representation of a bronchial wall. Which of the following ratios is the best pathological index to determine the severity of this patient's disease?

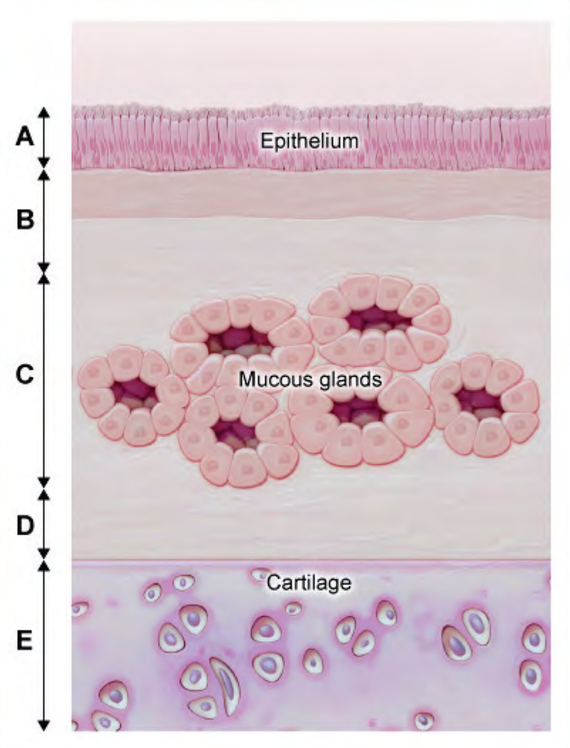

- A. A / (A+B+C+D)
- B. A / (A+B+C+D+E)
- C. C / (B+C+D)
- D. C / (A+B+C+D+E)

https://t.me/USMLEWorldStep1

A 56-year-old man is evaluated for dyspnea, wheezing, and cough productive of yellow sputum. The patient reports
cigare
of the

Exhibit Display

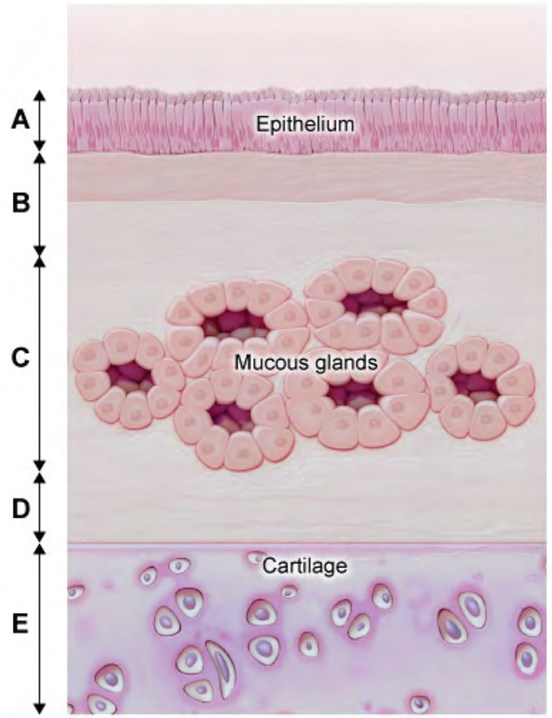

Zoom In Zoom Out Reset New | Existing My Notebook

D. C / (A+B+C+D+E)

https://t.me/USMLEWorldStep1

of the following ratios is the best pathological index to determine the severity of this patient's disease?

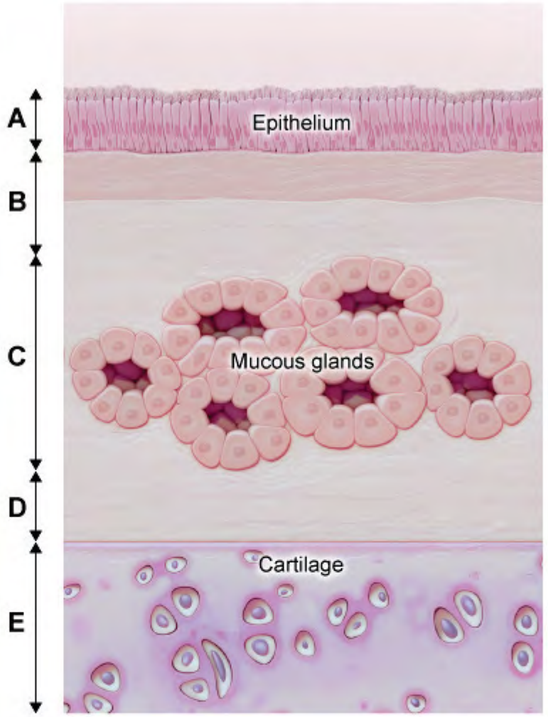

- A. A / (A+B+C+D)
- B. A / (A+B+C+D+E)
- C. C / (B+C+D)
- D. C / (A+B+C+D+E)
- E. (B+C+D) / (A+B+C+D+E)

Submit

https://t.me/USMLEWorldStep1

of the following ratios is the best pathological index to determine the severity of this patient's disease?

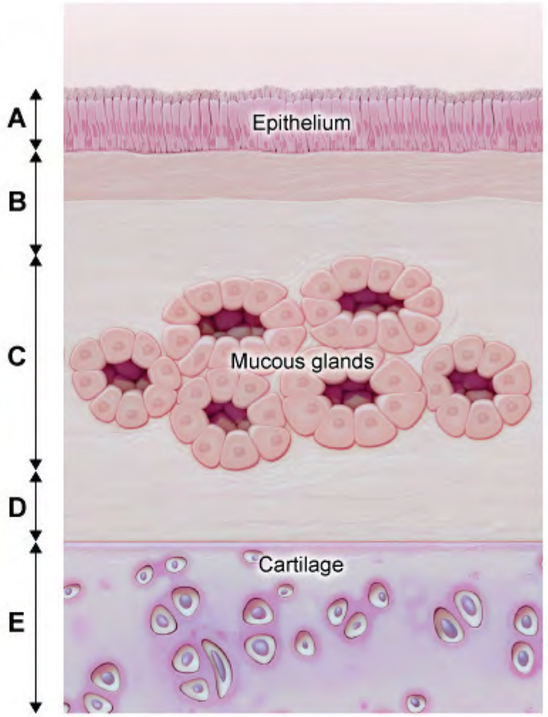

- A. A / (A+B+C+D) (12%)
- ✗ B. A / (A+B+C+D+E) (3%)
- ✓ C. C / (B+C+D) (42%)
- D. C / (A+B+C+D+E) (29%)
- E. (B+C+D) / (A+B+C+D+E) (10%)

Incorrect
Correct answer
C

42%
Answered correctly

16 secs
Time Spent

2023
Version

https://t.me/USMLEWorldStep1

Explanation

Exhibit Display

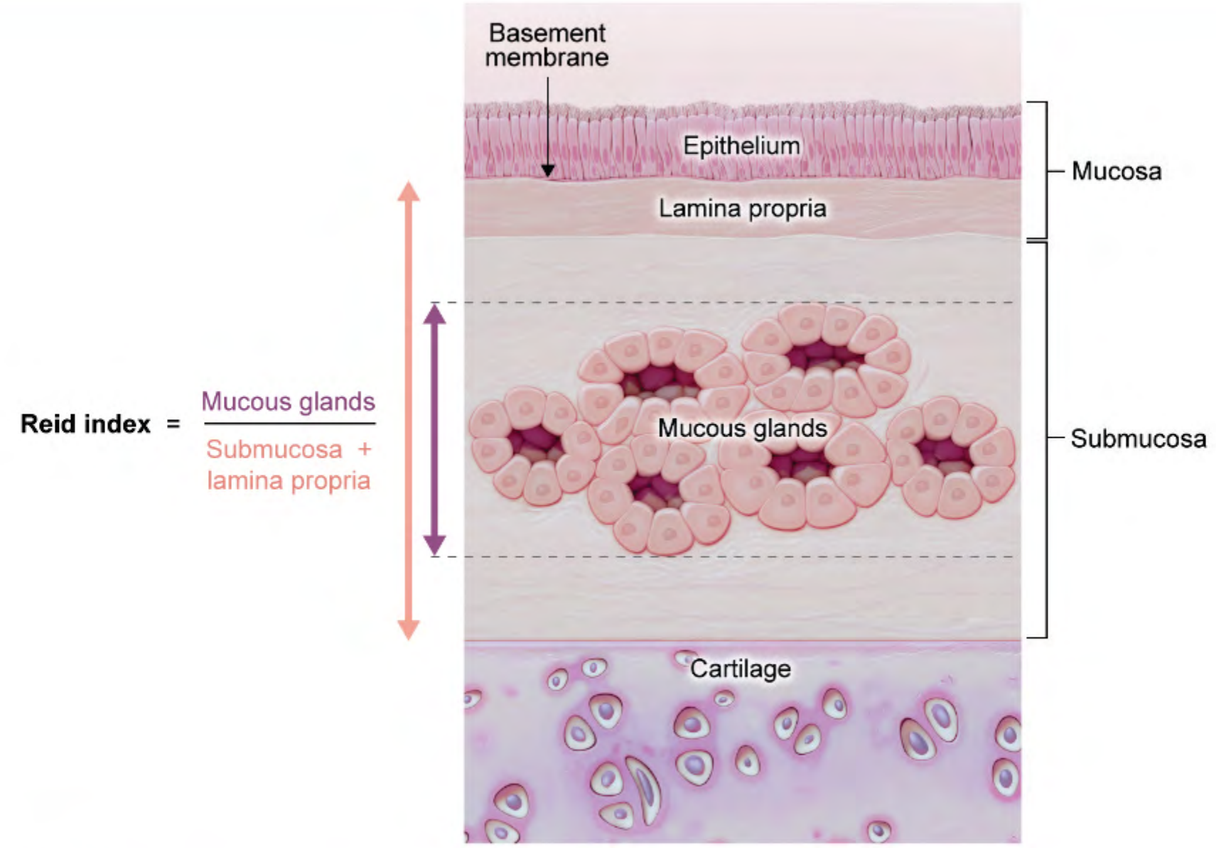

Zoom In Zoom Out Reset New | Existing My Notebook

This p
chron
bronch
thicker
the ma

The R
thickne
values correlate with increased duration and severity of chronic bronchitis.

https://t.me/USMLEWorldStep1

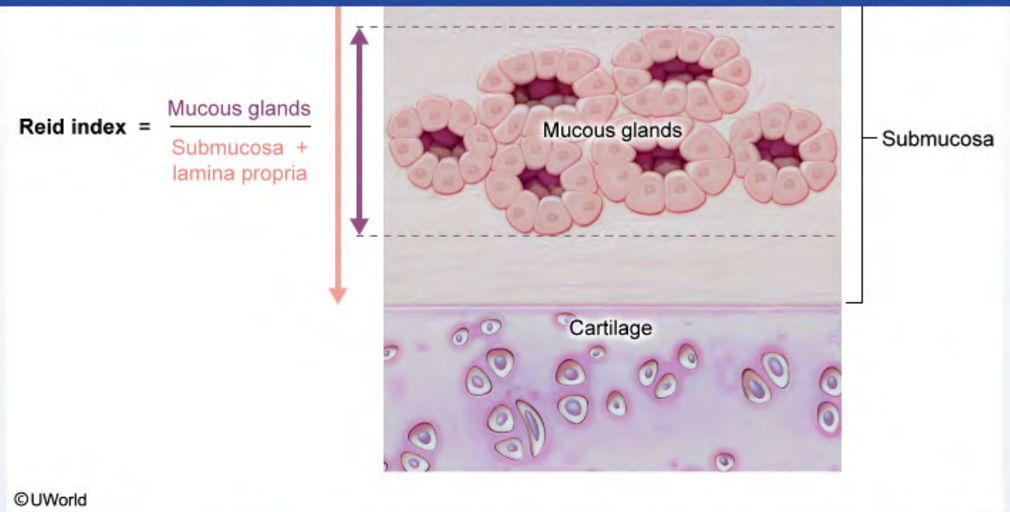

This patient's dyspnea, wheezing, and productive cough in the setting of heavy smoking are consistent with **chronic obstructive pulmonary disease** (COPD). Patients with COPD often have components of both chronic bronchitis and emphysema. Chronic bronchitis is characterized by increased mucus secretion and bronchial wall thickening with consequent narrowing of the bronchial lumen. **Bronchial gland hyperplasia** in the submucosa is the major contributor to bronchial wall thickening. The severity of this change can be measured by the **Reid index**.

The Reid index is a pathologic tool that measures the ratio of the **thickness of the submucosal glands** to the thickness of the bronchial wall between the epithelial basement membrane and the bronchial cartilage. Higher values correlate with increased duration and severity of chronic bronchitis.

Educational objective:
Hyperplasia of the submucosal bronchial glands is the major contributor to bronchial wall thickening in chronic bronchitis. The Reid index is the ratio of the thickness of the submucosal bronchial glands to the thickness of the bronchial wall between the epithelial basement membrane and the bronchial cartilage.

Pathology	Pulmonary & Critical Care	COPD
Subject	System	Topic

Copyright © UWorld. All rights reserved.

https://t.me/USMLEWorldStep1

A 35-year-old man comes to the office due to worsening shortness of breath. The patient is an avid hiker; he began to have shortness of breath 18 months ago on challenging hikes, but it now occurs even while he is walking. He has also had mild wheezing and sputum production recently. He has no other medical problems. The patient has smoked half a pack of cigarettes daily for the past 5 years. His father died from lung and liver disease at a young age. Spirometry shows decreased forced expiratory volume in 1 second (FEV1), decreased forced vital capacity (FVC), and a decreased FEV1/FVC ratio. This patient's lower lung lobes are most likely to demonstrate which of the following findings?

- A. Centriacinar emphysema
- B. Colonization with pathogenic bacteria
- C. Compensatory hyperinflation
- D. Panacinar emphysema
- E. Subpleural blebs

Submit

https://t.me/USMLEWorldStep1

A 35-year-old man comes to the office due to worsening shortness of breath. The patient is an avid hiker; he began to have shortness of breath 18 months ago on challenging hikes, but it now occurs even while he is walking. He has also had mild wheezing and sputum production recently. He has no other medical problems. The patient has smoked half a pack of cigarettes daily for the past 5 years. His father died from lung and liver disease at a young age. Spirometry shows decreased forced expiratory volume in 1 second (FEV1), decreased forced vital capacity (FVC), and a decreased FEV1/FVC ratio. This patient's lower lung lobes are most likely to demonstrate which of the following findings?

- A. Centriacinar emphysema (20%)
- ✗ B. Colonization with pathogenic bacteria (1%)
- C. Compensatory hyperinflation (7%)
- ✓ D. Panacinar emphysema (66%)
- E. Subpleural blebs (2%)

Incorrect
Correct answer
D

66%
Answered correctly

03 secs
Time Spent

2023
Version

Explanation

Centriacinar vs. panacinar emphysema

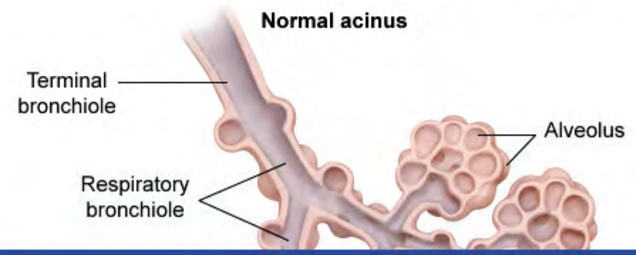

https://t.me/USMLEWorldStep1

Correct answer
D

Answered correctly

Time Spent

Version

Exhibit Display

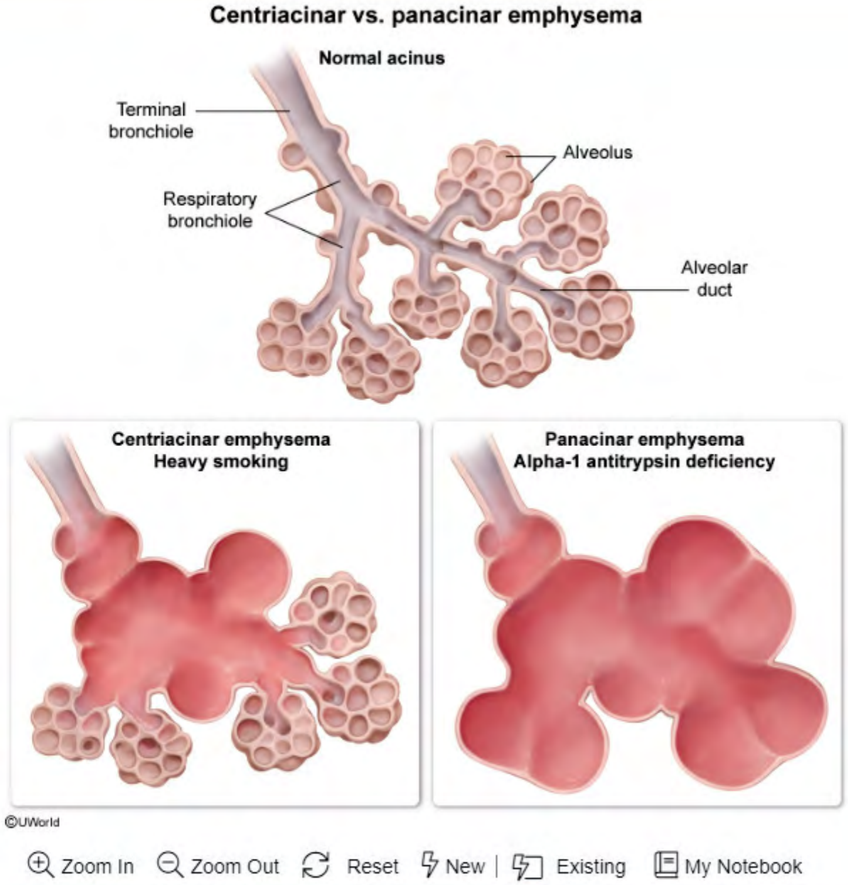

Zoom In | Zoom Out | Reset | New | Existing | My Notebook

This patient with chronic progressive dyspnea has spirometry findings consistent with **obstructive lung disease**.

https://t.me/USMLEWorldStep1

©UWorld

This patient with chronic progressive dyspnea has spirometry findings consistent with **obstructive lung disease**. His **young age** and family history of lung and **liver disease** suggest emphysema due to **alpha-1 antitrypsin deficiency**. The diagnosis is further suggested by his minimal smoking history; chronic obstructive pulmonary disease due to tobacco exposure alone is most commonly seen in those with a >30-pack-year smoking history.

Alpha-1 antitrypsin is the major inhibitor of **neutrophil elastase**, and deficiency leads to unchecked elastase-mediated tissue damage in the lungs. Because alpha-1 antitrypsin is deficient throughout the acinus, the entirety of the acinus is affected, resulting in **panacinar emphysema**. The lower lung lobes are predominantly affected, likely due to relatively greater perfusion compared to the upper lung lobes, allowing for an increased rate of neutrophil infiltration.

(Choice A) Centriacinar emphysema is characteristic of tobacco-related emphysema, as only the portion of the acinus most exposed to smoke particles is affected. Tobacco-related centriacinar emphysema predominantly affects the upper lung lobes, possibly due to a higher ventilation-perfusion ratio in those regions.

(Choice B) Colonization of the lung with pathogenic bacteria most commonly occurs in patients with cystic fibrosis and is not a common feature of alpha-1 antitrypsin deficiency.

(Choice C) Compensatory hyperinflation refers to the expansion of normal lung parenchyma that occurs when adjacent lung segments or lobes collapse or are surgically removed.

(Choice E) Subpleural blebs can develop in severe emphysema but typically occur in the apices, rather than the bases, of the lung. Their rupture is a cause of spontaneous pneumothorax.

Educational objective:
Alpha-1 antitrypsin is the major serum inhibitor of neutrophil elastase. Alpha-1 antitrypsin deficiency typically causes early-onset panacinar emphysema, predominantly affecting the lower lung lobes.

References

- Alpha-1 antitrypsin deficiency: a commonly overlooked cause of lung disease.
- Alpha-1 antitrypsin deficiency.

https://t.me/USMLEWorldStep1

©UWorld

This p
His yo
defici
diseas

Alpha-
media
of the
likely c
neutro

(Choi
acinus
affects

(Choi
and is

(Choi
adjace

(Choi
bases

Educa
Alpha-
cause

Refere

- Alp
- Alpha-1 antitrypsin deficiency.

Exhibit Display

Pulmonary function tests

Type	Normal	Obstructive lung disease			Restrictive lung disease	
		Emphysema	*Chronic bronchitis*	*Asthma*	*Intrinsic*	*Extrinsic*
DLCO*	Normal	Normal to decreased	Normal	Normal to high	Decreased	Normal
FEV_1	> 80% (of predicted)	Decreased			Decreased	
FEV_1/FVC	> 70%	Decreased			Normal to increased	
FVC	> 80% (of predicted)	Normal to decreased			Decreased	

*DLCO is directly proportional to alveolar surface area and solubility of the gas (eg, more blood volume). DLCO is inversely proportional to membrane thickness.
FEV_1 = forced expiratory volume in 1 second; **FVC** = forced vital capacity; **DLCO** = Diffusing capacity of lung for carbon monoxide.

New | Existing | My Notebook

https://t.me/USMLEWorldStep1

©UWorld

This p
His yo
defici
diseas

Alpha-
media
of the
likely c
neutro

(Choi
acinus
affects

(Choi
and is

(Choi
adjace

(Choi
bases

Educa
Alpha-
cause

Refere
- Alp
- Alpha-1 antitrypsin deficiency.

Exhibit Display

Alpha-1 antitrypsin deficiency	
Etiology	• Autosomal codominant inheritance • ↓ Alpha-1 antitrypsin leads to unchecked elastase activity
Clinical presentation	• Early-onset (age ≤45) panacinar emphysema • Basilar lung areas predominantly affected • Smoking accelerates disease • Associated liver dysfunction or cirrhosis
Diagnosis	• Obstructive pattern on PFT: ↓ FEV1/FVC ratio, ↓ DLCO • ↓ Serum alpha-1 antitrypsin level & genetic testing
DLCO = diffusing capacity of the lung for carbon monoxide; **PFT** = pulmonary function testing.	

New | Existing | My Notebook

https://t.me/USMLEWorldStep1

A 32-year-old woman comes to the office for a preemployment examination. The patient has had mild shortness of breath on exertion over the past year, which she attributes to deconditioning. Three months ago, an ophthalmologist treated her for anterior uveitis. The patient has no other medical conditions and takes no medications. She does not use tobacco, alcohol, or recreational drugs. Blood pressure is 110/70, pulse is 72/min, and respirations are 14/min. On physical examination, visual acuity is within normal limits. There is swelling of the parotid glands and the lungs are clear to auscultation. Chest x-ray reveals enlarged hilar lymph nodes and nodular pulmonary infiltrates. Which of the following histopathological findings are most likely to be seen on lymph node biopsy in this patient?

- A. Caseating epithelioid granulomas and acid-fast bacilli
- B. Eosinophilic, perivascular, inflammatory infiltrate
- C. Granulomatous inflammation with no central necrosis
- D. Reed-Sternberg cells surrounded by inflammatory cells
- E. Small basophilic cells with granular nuclear chromatin

Submit

https://t.me/USMLEWorldStep1

A 32-year-old woman comes to the office for a preemployment examination. The patient has had mild shortness of breath on exertion over the past year, which she attributes to deconditioning. Three months ago, an ophthalmologist treated her for anterior uveitis. The patient has no other medical conditions and takes no medications. She does not use tobacco, alcohol, or recreational drugs. Blood pressure is 110/70, pulse is 72/min, and respirations are 14/min. On physical examination, visual acuity is within normal limits. There is swelling of the parotid glands and the lungs are clear to auscultation. Chest x-ray reveals enlarged hilar lymph nodes and nodular pulmonary infiltrates. Which of the following histopathological findings are most likely to be seen on lymph node biopsy in this patient?

- ✗ A. Caseating epithelioid granulomas and acid-fast bacilli (5%)
- B. Eosinophilic, perivascular, inflammatory infiltrate (6%)
- ✓ C. Granulomatous inflammation with no central necrosis (76%)
- D. Reed-Sternberg cells surrounded by inflammatory cells (7%)
- E. Small basophilic cells with granular nuclear chromatin (3%)

Incorrect
Correct answer
C

76%
Answered correctly

03 secs
Time Spent

2023
Version

Explanation

This patient with hilar lymphadenopathy, nodular pulmonary infiltrates, and a history of anterior uveitis likely has **sarcoidosis**, an inflammatory disorder of unknown etiology that occurs most commonly in younger, African American patients. It is characterized on histology by the presence of **noncaseating granulomas** (collections of tightly clustered, epithelioid macrophages with abundant pink cytoplasm surrounded by a rim of mononuclear cells without central necrosis). Multinucleated giant cells, formed by macrophage fusion, are frequently seen.

Sarcoidosis primarily involves the lungs, causing nodular or **interstitial infiltrates**. However, extrapulmonary

https://t.me/USMLEWorldStep1

This patient with hilar lymphadenopathy, nodular pulmonary infiltrates, and a history of anterior uveitis likely has **sarcoidosis**, an inflammatory disorder of unknown etiology that occurs most commonly in younger, African American patients. It is characterized on histology by the presence of **noncaseating granulomas** (collections of tightly clustered, epithelioid macrophages with abundant pink cytoplasm surrounded by a rim of mononuclear cells without central necrosis). Multinucleated giant cells, formed by macrophage fusion, are frequently seen.

Sarcoidosis primarily involves the lungs, causing nodular or **interstitial infiltrates**. However, extrapulmonary manifestations are common and can involve the lymph nodes (eg, **hilar adenopathy**), eyes (eg, **anterior uveitis**), skin (eg, erythematous nodular rashes), CNS (eg, neurosarcoidosis), and internal organs (eg, heart, liver). Salivary glands (eg, parotid, as in this patient) are involved in up to 5% of patients. Constitutional symptoms, including fatigue, weight loss, and night sweats, can also occur.

(Choice A) Tuberculosis can cause pulmonary infection associated with fatigue, dyspnea, and adenopathy but is characterized by caseating granulomas (central necrosis is present) and acid-fast bacilli. Tuberculosis occurs more frequently in those with risk factors (eg, incarceration, homeless, high-risk health care workers), whereas this patient's history of anterior uveitis and parotid enlargement is more suggestive of sarcoidosis.

(Choice B) Churg-Strauss syndrome (eosinophilic granulomatosis with polyangiitis) is characterized by perivascular eosinophilic inflammatory infiltrates and presents with asthmatic symptoms and pulmonary infiltrates. However, it is also typically accompanied by allergic rhinitis, sinusitis, nasal polyps, and skin lesions.

(Choice D) Reed-Sternberg cells are seen in Hodgkin lymphoma, which causes lymphadenopathy but would not be expected to cause pulmonary infiltrates or anterior uveitis.

(Choice E) Small cell lung carcinoma is characterized by small basophilic cells with granular chromatin and causes bulky adenopathy and pulmonary masses. However, it is much more common in older patients and heavy smokers.

Educational objective:
Sarcoidosis is characterized by noncaseating granulomas. Multinucleated giant cells, formed by macrophage fusion, are frequently seen. Sarcoidosis commonly involves the lungs with interstitial or nodular infiltrates; extrapulmonary manifestations can affect lymph nodes, eyes (eg, uveitis), skin, internal organs, and salivary

https://t.me/USMLEWorldStep1

tightly clustered, epithelioid macrophages with abundant pink cytoplasm surrounded by a rim of mononuclear cells without central necrosis). Multinucleated giant cells, formed by macrophage fusion, are frequently seen.

Sarcoidosis primarily involves the lungs, causing nodular or **interstitial infiltrates**. However, extrapulmonary manifestations are common and can involve the lymph nodes (eg, **hilar adenopathy**), eyes (eg, **anterior uveitis**), skin (eg, erythematous nodular rashes), CNS (eg, neurosarcoidosis), and internal organs (eg, heart, liver). Salivary glands (eg, parotid, as in this patient) are involved in up to 5% of patients. Constitutional symptoms, including fatigue, weight loss, and night sweats, can also occur.

(Choice A) Tuberculosis can cause pulmonary infection associated with fatigue, dyspnea, and adenopathy but is characterized by caseating granulomas (central necrosis is present) and acid-fast bacilli. Tuberculosis occurs more frequently in those with risk factors (eg, incarceration, homeless, high-risk health care workers), whereas this patient's history of anterior uveitis and parotid enlargement is more suggestive of sarcoidosis.

(Choice B) Churg-Strauss syndrome (eosinophilic granulomatosis with polyangiitis) is characterized by perivascular eosinophilic inflammatory infiltrates and presents with asthmatic symptoms and pulmonary infiltrates. However, it is also typically accompanied by allergic rhinitis, sinusitis, nasal polyps, and skin lesions.

(Choice D) Reed-Sternberg cells are seen in Hodgkin lymphoma, which causes lymphadenopathy but would not be expected to cause pulmonary infiltrates or anterior uveitis.

(Choice E) Small cell lung carcinoma is characterized by small basophilic cells with granular chromatin and causes bulky adenopathy and pulmonary masses. However, it is much more common in older patients and heavy smokers.

Educational objective:
Sarcoidosis is characterized by noncaseating granulomas. Multinucleated giant cells, formed by macrophage fusion, are frequently seen. Sarcoidosis commonly involves the lungs with interstitial or nodular infiltrates; extrapulmonary manifestations can affect lymph nodes, eyes (eg, uveitis), skin, internal organs, and salivary glands.

Pathophysiology	Pulmonary & Critical Care	Sarcoidosis
Subject	System	Topic

https://t.me/USMLEWorldStep1

Exhibit Display

Pulmonary sarcoidosis

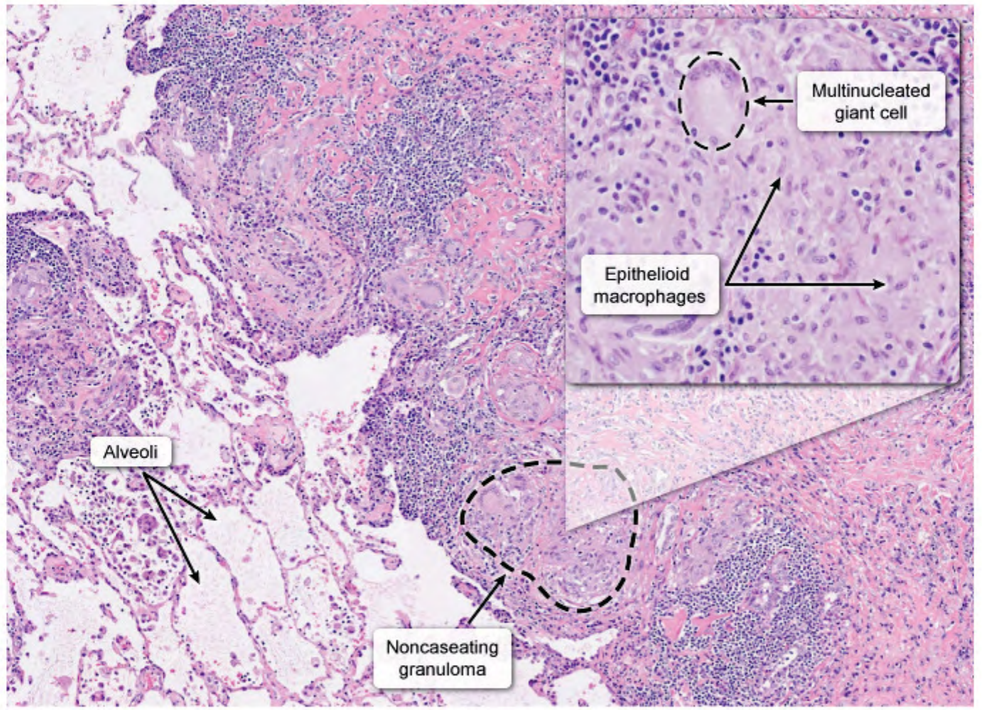

©UWorld

Zoom In | Zoom Out | Reset | New | Existing | My Notebook

Expl

This p
sarcoi
Ameri
tightly
withou

Sarcoi
manife
skin (e
Saliva
includi

(Choi
charac
more f
patien

(Choi
periva
Howev

(Choi
be exp

(Choi
cause
smoke

Educational objective:

https://t.me/USMLEWorldStep1

Expl

This p
sarcoi
Ameri
tightly
withou

Sarcoi
manife
skin (e
Saliva
includi

(Choi
charac
more f
patien

(Choi
periva
Howev

(Choi
be exp

(Choi
cause
smoke

Educational objective:

Exhibit Display

Pulmonary tuberculosis

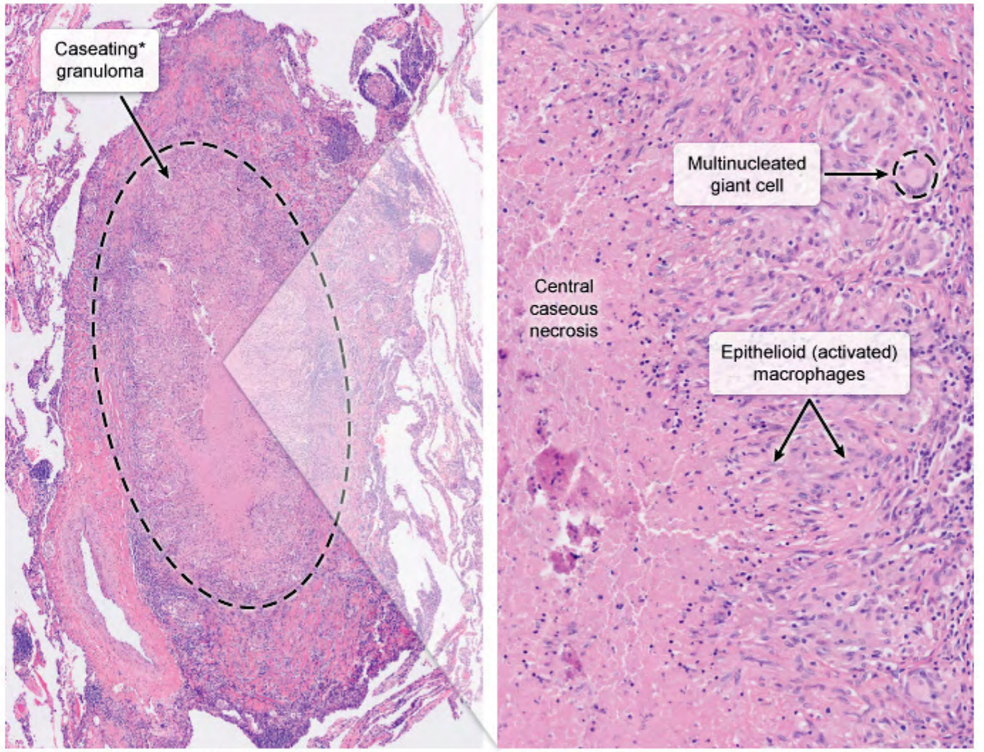

*Cheesy appearance on gross examination.

©UWorld

Zoom In | Zoom Out | Reset | New | Existing | My Notebook

https://t.me/USMLEWorldStep1

Expl

This p
sarcoi
Ameri
tightly
withou

Sarcoi
manife
skin (e
Saliva
includi

(Choi
charac
more f
patien

(Choi
periva
Howev

(Choi
be exp

(Choi
cause
smoke

Educational objective:

Exhibit Display

Hodgkin lymphoma

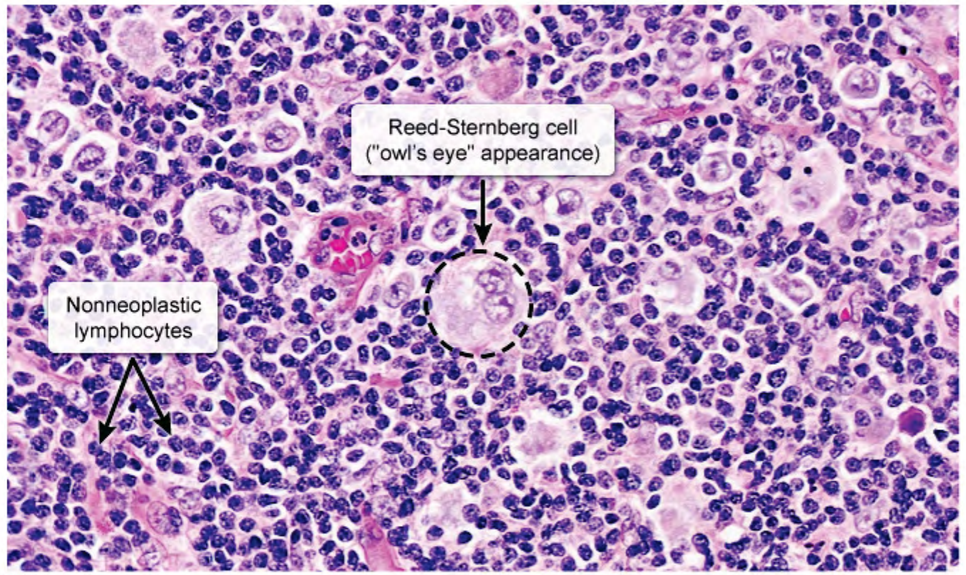

©UWorld

Zoom In | Zoom Out | Reset | New | Existing | My Notebook

https://t.me/USMLEWorldStep1

Expl

This p
sarcoi
Ameri
tightly
withou

Sarcoi
manife
skin (e
Saliva
includi

(Choi
charac
more f
patien

(Choi
periva
Howev

(Choi
be exp

(Choi
cause
smoke

Educational objective:

Exhibit Display

Small cell lung carcinoma

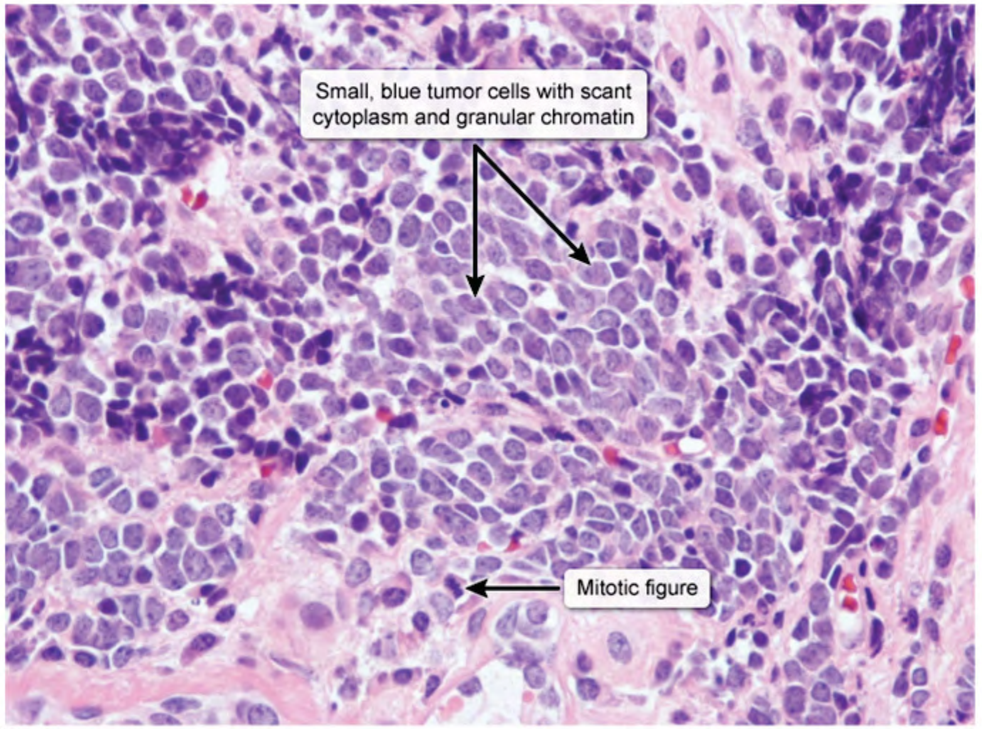

©UWorld

Zoom In | Zoom Out | Reset | New | Existing | My Notebook

https://t.me/USMLEWorldStep1

Investigators study the prevalence of respiratory pathogens in patients with cystic fibrosis across the age spectrum. It is found that age is a strong predictor of colonization by a specific microbe, as shown below.

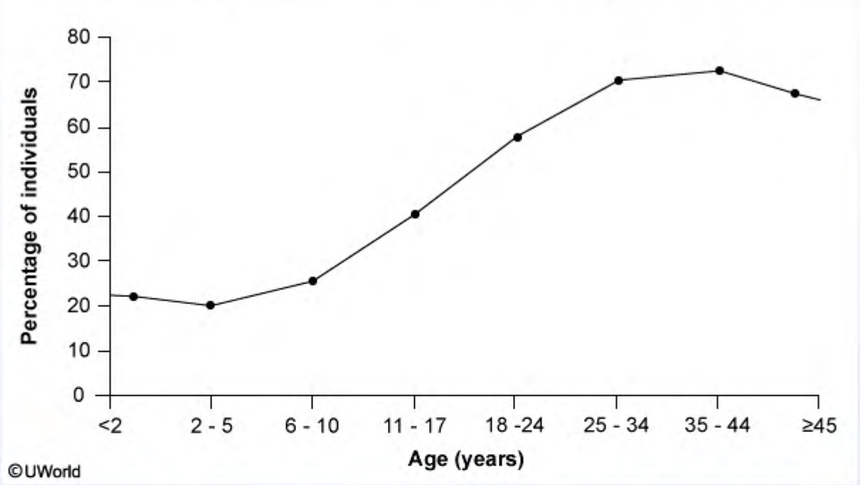

The pathogen, once acquired, often switches into mucoid phenotype, which is able to produce an alginate-containing biofilm matrix that helps to establish chronic infection. Which of the following bacteria was most likely found in this study?

- A. *Haemophilus influenzae*
- B. *Klebsiella pneumoniae*
- C. *Pseudomonas aeruginosa*
- D. *Staphylococcus aureus*
- E. *Streptococcus pneumoniae*

Submit

https://t.me/USMLEWorldStep1

Investigators study the prevalence of respiratory pathogens in patients with cystic fibrosis across the age spectr

Exhibit Display

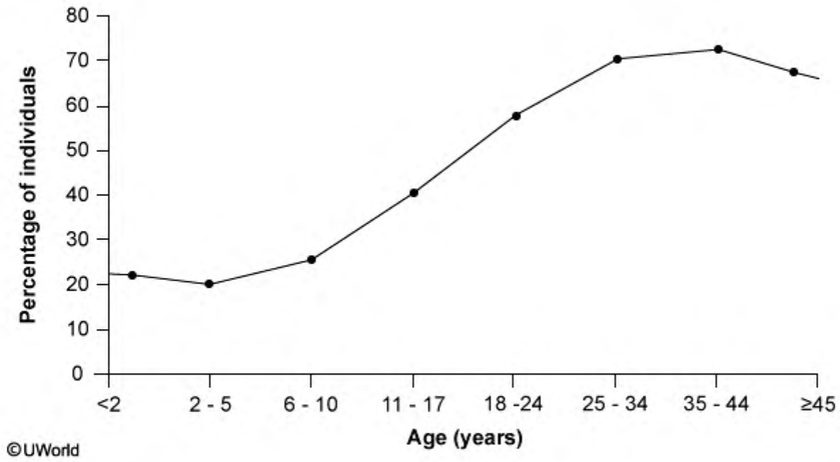

Zoom In Zoom Out Reset New | Existing My Notebook

The pa
contai
found

Sub

https://t.me/USMLEWorldStep1

Investigators study the prevalence of respiratory pathogens in patients with cystic fibrosis across the age spectrum. It is found that age is a strong predictor of colonization by a specific microbe, as shown below.

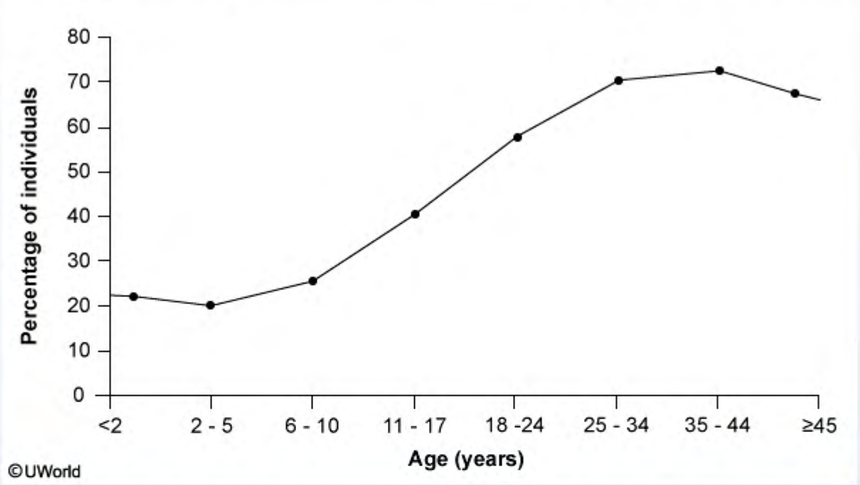

The pathogen, once acquired, often switches into mucoid phenotype, which is able to produce an alginate-containing biofilm matrix that helps to establish chronic infection. Which of the following bacteria was most likely found in this study?

- A. *Haemophilus influenzae* (3%)
- ✗ B. *Klebsiella pneumoniae* (11%)
- ✓ C. *Pseudomonas aeruginosa* (76%)
- D. *Staphylococcus aureus* (3%)
- E. *Streptococcus pneumoniae* (5%)

Incorrect
Correct answer
C

76%
Answered correctly

10 secs
Time Spent

2023
Version

https://t.me/USMLEWorldStep1

Correct answer
C

76%
Answered correctly

10 secs
Time Spent

2023
Version

Exhibit Display

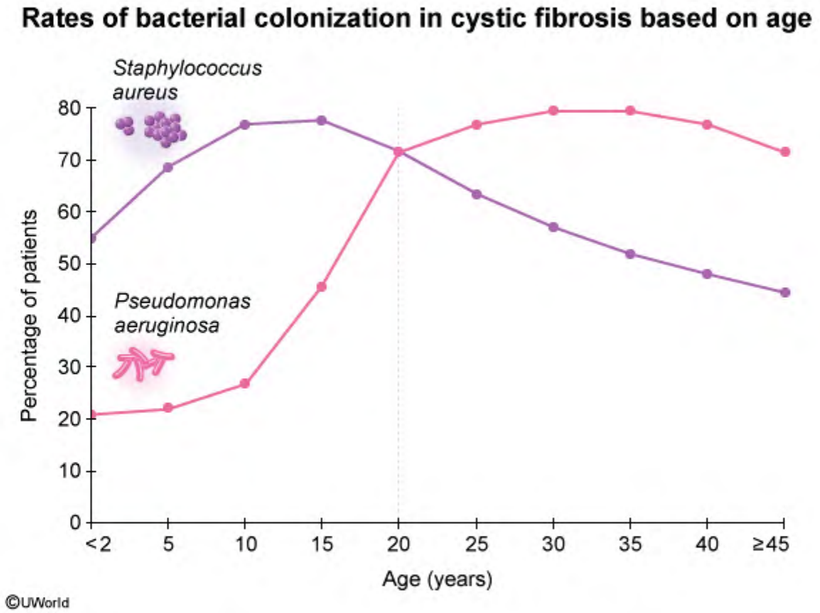

Zoom In | Zoom Out | Reset | New | Existing | My Notebook

Cystic
the lur
bacter
isolate
respira

P aeru
includi
colonization/infection is then primarily mediated by the following:

https://t.me/USMLEWorldStep1

Cystic fibrosis (CF) is associated with the accumulation of thick, viscous secretions in multiple organ systems. In the lungs, secretions clog the airways, leading to the colonization of the lower respiratory tract with pathogenic bacteria early in the course of disease. *Staphylococcus aureus* and *Haemophilus influenzae* are most commonly isolated in children, but ***Pseudomonas aeruginosa***, a ubiquitous gram-negative bacillus, is the leading cause of respiratory tract colonization and infection in adults with CF.

P aeruginosa has several adaptations that make it well suited to the pulmonic environment of patients with CF including the ability to directly bind mucous, which shields the organism from phagocytosis. Persistent colonization/infection is then primarily mediated by the following:

- **Biofilm formation** – The bacteria clump together within an extracellular matrix of polysaccharides, proteins, and DNA, which prevents phagocytosis and antibiotic-mediated destruction
- Conversion to a **mucoid phenotype** that produces an **alginate polysaccharide**, which strengthens biofilm structure and aids in the inhibition of opsonization and phagocytosis
- Downregulation of virulence factors (eg, flagella, pili, lipopolysaccharide components) reduces antigenic targets, which promotes persistent colonization

Neutrophils respond to the chronic infection by releasing elastase, myeloperoxidase, and other digestive enzymes. However, these compounds fail to eliminate *P aeruginosa* and ultimately cause progressive destruction of the airway wall (ie, bronchiectasis) and a steady decline in pulmonary function.

(Choices A and D) Pathogenic strains of *H influenzae* are able to form biofilms but do not convert to mucoid phenotype. *S aureus* can generate a biofilm and convert to mucoid growth. Although *H influenzae* and *S aureus* are the leading respiratory pathogens in children with CF, neither is as common as *Pseudomonas* in adult patients with CF.

(Choice B) *Klebsiella pneumoniae* can generate a thick biofilm and grows in mucoid colonies on blood agar. Although colonization with *K pneumoniae* can occur in patients with CF, this pathogen is far less common than *Pseudomonas*.

(Choice E) *Streptococus pneumoniae* can form a biofilm and grow in mucoid colonies but is not a common

https://t.me/USMLEWorldStep1

including the ability to directly bind mucous, which shields the organism from phagocytosis. Persistent colonization/infection is then primarily mediated by the following:

- **Biofilm formation** – The bacteria clump together within an extracellular matrix of polysaccharides, proteins, and DNA, which prevents phagocytosis and antibiotic-mediated destruction
- Conversion to a **mucoid phenotype** that produces an **alginate polysaccharide**, which strengthens biofilm structure and aids in the inhibition of opsonization and phagocytosis
- Downregulation of virulence factors (eg, flagella, pili, lipopolysaccharide components) reduces antigenic targets, which promotes persistent colonization

Neutrophils respond to the chronic infection by releasing elastase, myeloperoxidase, and other digestive enzymes. However, these compounds fail to eliminate *P aeruginosa* and ultimately cause progressive destruction of the airway wall (ie, bronchiectasis) and a steady decline in pulmonary function.

(Choices A and D) Pathogenic strains of *H influenzae* are able to form biofilms but do not convert to mucoid phenotype. *S aureus* can generate a biofilm and convert to mucoid growth. Although *H influenzae* and *S aureus* are the leading respiratory pathogens in children with CF, neither is as common as *Pseudomonas* in adult patients with CF.

(Choice B) *Klebsiella pneumoniae* can generate a thick biofilm and grows in mucoid colonies on blood agar. Although colonization with *K pneumoniae* can occur in patients with CF, this pathogen is far less common than *Pseudomonas*.

(Choice E) *Streptococcus pneumoniae* can form a biofilm and grow in mucoid colonies but is not a common colonizing pathogen in the airways of patients with CF.

Educational objective:
Pseudomonas aeruginosa is the leading respiratory pathogen in adult patients with cystic fibrosis. Persistent colonization is promoted by biofilm formation, conversion to a mucoid phenotype with alginate production, and downregulation of virulence factors.

References

https://t.me/USMLEWorldStep1

Exhibit Display

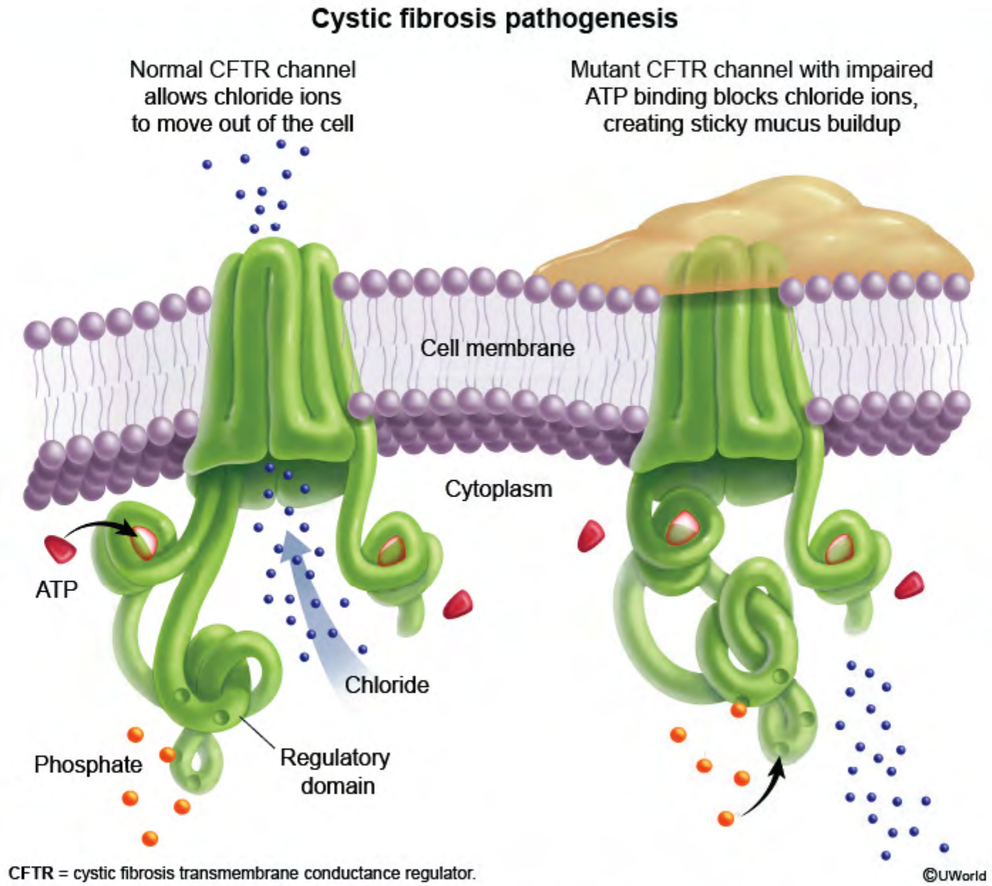

Zoom In | Zoom Out | Reset | New | Existing | My Notebook

(Choice B) *Klebsiella pneumoniae* can generate a thick biofilm and grows in mucoid colonies on blood agar.

https://t.me/USMLEWorldStep1

colonization/infection is then primarily mediated by the following:

- **B**
  a
- C
  st
- D
  ta

Neutro
Howev
airway

(Choi
pheno
are the
with C

(Choi
Althou
Pseud

(Choi
coloniz

Educa
Pseud
coloniz
downr

Refere

- Alginate overproduction affects Pseudomonas aeruginosa biofilm structure and function.

Exhibit Display

Klebsiella pneumoniae

*Mucus-like due to polysaccharide capsule

©UWorld

Zoom In | Zoom Out | Reset | New | Existing | My Notebook

https://t.me/USMLEWorldStep1

A 53-year-old woman is admitted to the hospital due to a 3-day history of worsening dyspnea. On examination, the patient is tachypneic; diffuse, wet, inspiratory crackles are present on pulmonary auscultation. Chest x-ray reveals bilateral patchy opacities. Arterial blood gas analysis shows that the patient's alveolar-arterial gradient (P_AO_2 – P_aO_2) is markedly increased. Although the patient receives 100% oxygen via a face mask, she has persistent hypoxemia and respiratory distress. Consequently, she is intubated and placed on mechanical ventilation with 100% oxygen and positive end-expiratory pressure (PEEP). Results of arterial oxygen measurements are as follows:

	Arterial partial pressure of oxygen (mm Hg)	O_2 saturation
Room air	40	75%
100% oxygen via face mask	43	78%
100% oxygen & PEEP	80	96%

The patient's improved oxygenation following PEEP application is most likely due to a decrease in which of the following?

- A. Anatomical dead space
- B. Intrapulmonary shunt effect
- C. Lung compliance
- D. Pulmonary vascular resistance
- E. Right-to-left intracardiac shunt

Submit

https://t.me/USMLEWorldStep1

A 53-year-old woman is admitted to the hospital due to a 3-day history of worsening dyspnea. On examination, the patient is tachypneic; diffuse, wet, inspiratory crackles are present on pulmonary auscultation. Chest x-ray reveals bilateral patchy opacities. Arterial blood gas analysis shows that the patient's alveolar-arterial gradient (P_AO_2 – P_aO_2) is markedly increased. Although the patient receives 100% oxygen via a face mask, she has persistent hypoxemia and respiratory distress. Consequently, she is intubated and placed on mechanical ventilation with 100% oxygen and positive end-expiratory pressure (PEEP). Results of arterial oxygen measurements are as follows:

	Arterial partial pressure of oxygen (mm Hg)	O_2 saturation
Room air	40	75%
100% oxygen via face mask	43	78%
100% oxygen & PEEP	80	96%

The patient's improved oxygenation following PEEP application is most likely due to a decrease in which of the following?

- ✗ A. Anatomical dead space (21%)
- ✓ B. Intrapulmonary shunt effect (48%)
- C. Lung compliance (12%)
- D. Pulmonary vascular resistance (14%)
- E. Right-to-left intracardiac shunt (2%)

Incorrect
Correct answer
B

48%
Answered correctly

04 secs
Time Spent

2023
Version

Explanation

https://t.me/USMLEWorldStep1

Expl

Exhibit Display

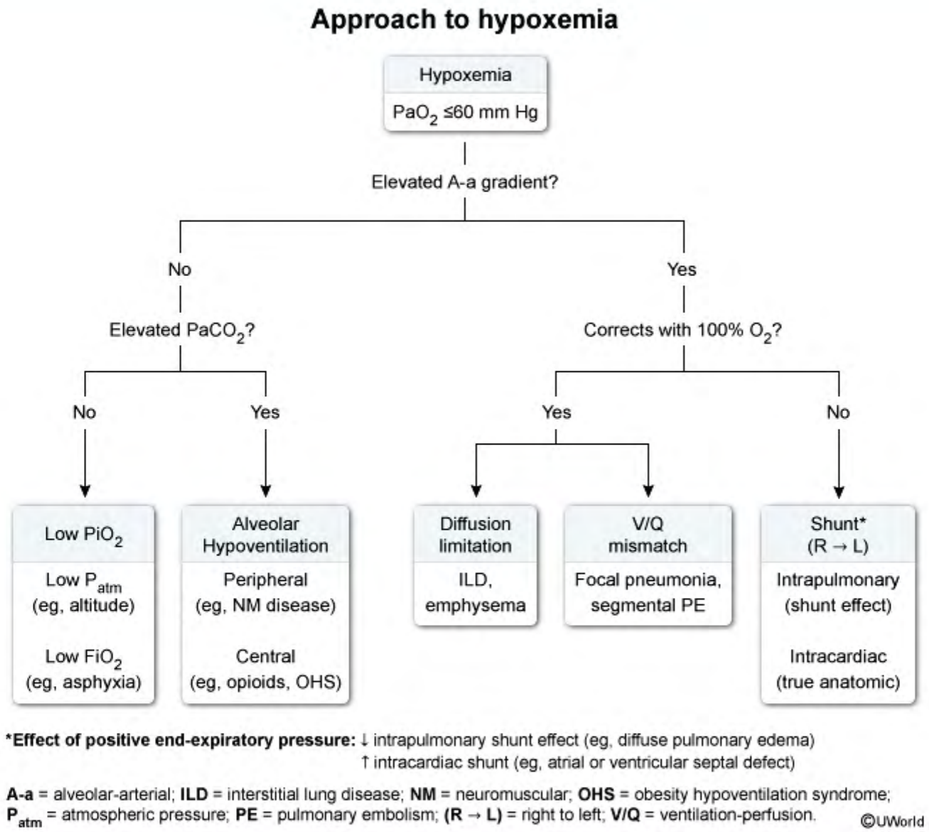

Zoom In | Zoom Out | Reset | New | Existing | My Notebook

This p
cardio
syndro
However, they are still being perfused (Q), resulting in many alveoli with ventilation-perfusion (V/Q) ratios approaching zero.

https://t.me/USMLEWorldStep1

This patient has **diffuse pulmonary edema** (inspiratory wet crackles, bilateral patchy infiltrates) that can be cardiogenic (eg, decompensated left ventricular failure) or noncardiogenic (eg, acute respiratory distress syndrome). With pulmonary edema, the **alveoli become flooded** and unable to fill with gas (ventilation: $V \approx 0$). However, they are still being perfused (Q), resulting in many alveoli with ventilation-perfusion (V/Q) ratios approaching zero.

Because blood passing through the lungs returns to the left atrium without being oxygenated, this situation is analogous to a true right-to-left anatomic shunt (eg, atrial septal defect with flow from the right to the left atrium) and is termed **intrapulmonary shunt effect**. Increasing the fraction of inspired oxygen (FiO_2) to 100% does not improve oxygenation because the shunted blood never "sees" the alveolar gas. Therefore, this patient's low arterial partial pressure of oxygen (PaO_2) has **not corrected with** 100% supplemental **oxygen**.

Because pure oxygen alone cannot improve hypoxemia, treatment depends on reducing the shunt effect. This can be done by **pressurizing** the inspired gas in a closed circuit (eg, mechanical ventilator). Positive end-expiratory pressure (PEEP) **reduces the shunt** by propping the collapsed alveoli open, displacing extracellular lung fluid and exposing more alveolar surface area for gas exchange/oxygen uptake.

(Choice A) Anatomical dead space refers to the volume of air in the conducting airways (eg, trachea, bronchi) that never reaches alveoli. It is increased, not decreased, in an intubated patient due to the extra volume of the ventilator tubing. At any given tidal volume, increased anatomic dead space causes less air to reach alveoli with each breath, contributing to hypoventilation and worsening hypoxemia.

(Choice C) When fluid enters the alveolar airspace (ie, pulmonary edema), the surface tension increases (due to dilution of surfactant) causing the alveolar walls to cling together and collapse (ie, atelectasis), which decreases lung compliance. PEEP props open ("recruits") the partially flooded alveoli, improving lung compliance.

(Choices D and E) PEEP raises intrathoracic pressure, which compresses pulmonary capillaries and raises pulmonary vascular resistance. This increases pressure within the right heart chambers and can increase right-to-left shunting through an existing intracardiac shunt (eg, atrial or ventricular septal defect), worsening hypoxemia. Therefore, PEEP is generally avoided in patients with intracardiac shunts.

Educational objective:

https://t.me/USMLEWorldStep1

However, they are still being perfused (Q), resulting in many alveoli with ventilation-perfusion (V/Q) ratios approaching zero.

Because blood passing through the lungs returns to the left atrium without being oxygenated, this situation is analogous to a true right-to-left anatomic shunt (eg, atrial septal defect with flow from the right to the left atrium) and is termed **intrapulmonary shunt effect**. Increasing the fraction of inspired oxygen (FiO_2) to 100% does not improve oxygenation because the shunted blood never "sees" the alveolar gas. Therefore, this patient's low arterial partial pressure of oxygen (PaO_2) has **not corrected with** 100% supplemental **oxygen**.

Because pure oxygen alone cannot improve hypoxemia, treatment depends on reducing the shunt effect. This can be done by **pressurizing** the inspired gas in a closed circuit (eg, mechanical ventilator). Positive end-expiratory pressure (PEEP) **reduces the shunt** by propping the collapsed alveoli open, displacing extracellular lung fluid and exposing more alveolar surface area for gas exchange/oxygen uptake.

(Choice A) Anatomical dead space refers to the volume of air in the conducting airways (eg, trachea, bronchi) that never reaches alveoli. It is increased, not decreased, in an intubated patient due to the extra volume of the ventilator tubing. At any given tidal volume, increased anatomic dead space causes less air to reach alveoli with each breath, contributing to hypoventilation and worsening hypoxemia.

(Choice C) When fluid enters the alveolar airspace (ie, pulmonary edema), the surface tension increases (due to dilution of surfactant) causing the alveolar walls to cling together and collapse (ie, atelectasis), which decreases lung compliance. PEEP props open ("recruits") the partially flooded alveoli, improving lung compliance.

(Choices D and E) PEEP raises intrathoracic pressure, which compresses pulmonary capillaries and raises pulmonary vascular resistance. This increases pressure within the right heart chambers and can increase right-to-left shunting through an existing intracardiac shunt (eg, atrial or ventricular septal defect), worsening hypoxemia. Therefore, PEEP is generally avoided in patients with intracardiac shunts.

Educational objective:
Severe hypoxemia that does not correct with 100% supplemental oxygen is consistent with a right-to-left shunt. Intrapulmonary shunt effect occurs when an alveolar filling process (eg, diffuse pulmonary edema) causes poor alveolar ventilation despite continued perfusion; this improves with positive end-expiratory pressure.

https://t.me/USMLEWorldStep1

Low P_{atm}	Hypoventilation	limitation	mismatch	(R → L)
	Peripheral	ILD,	Focal pneumonia,	Intrapulmonary

Exhibit Display

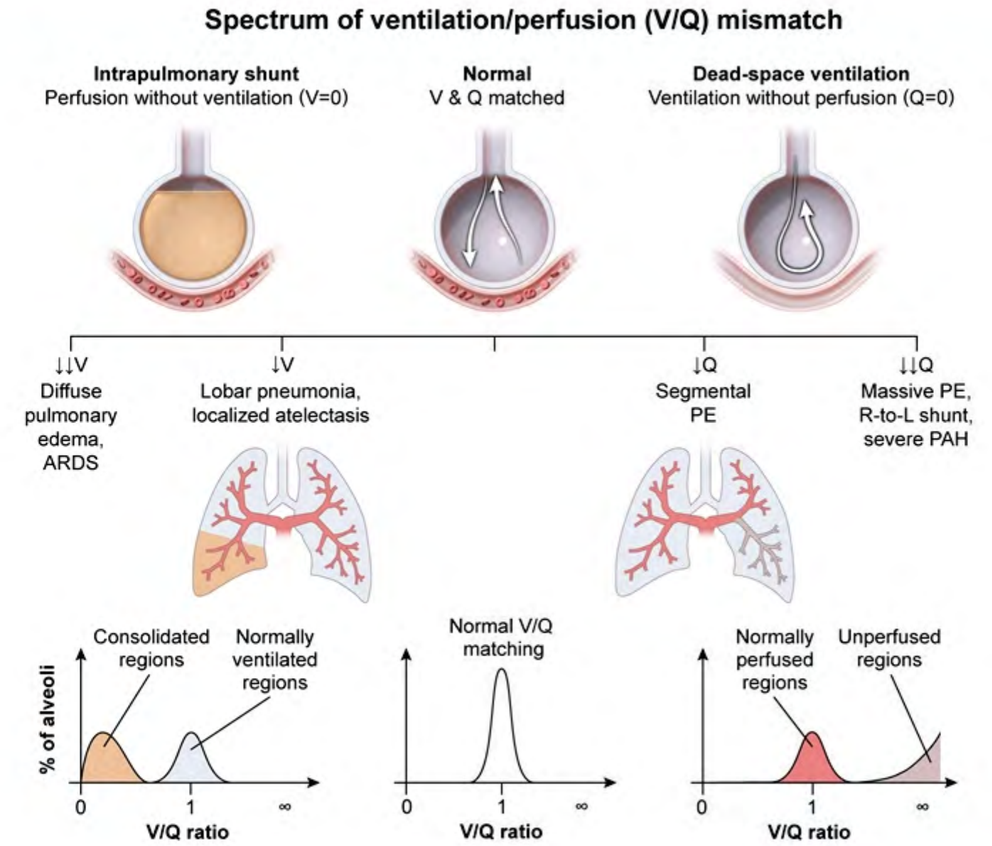

Zoom In | Zoom Out | Reset | New | Existing | My Notebook

This p
cardio
syndro
Howev
approa

Becau
analog
and is
improv
arteria

Becau
be dor
pressu
exposi

(Choi
never
ventila
each b

(Choice C) When fluid enters the alveolar airspace (ie, pulmonary edema), the surface tension increases (due to dilution of surfactant) causing the alveolar walls to cling together and collapse (ie, atelectasis), which decreases

https://t.me/USMLEWorldStep1

A 14-year-old boy is brought to the emergency department by his mother after he develops a sudden rash. He was trying to retrieve a baseball that had rolled under a log when he got stung by something. By the time he told his mom, his body was covered in welts. Within minutes, the patient's face started to swell and he was having a hard time swallowing. The patient's blood pressure is 70/50 mm Hg and heart rate is 120/min. Physical examination shows erythematous, raised plaques over the trunk, extremities, and face. Lung auscultation reveals bilateral expiratory wheezes. The mother is not aware of the child having any similar reaction in the past. Which of the following most likely triggered this patient's condition?

- A. Antibody-antigen complex deposition in the endothelium
- B. Antibody-dependent cell-mediated cytotoxicity
- C. CD8+ T lymphocyte-mediated hypersensitivity
- D. Cell surface-bound antibody linking by antigen
- E. Complement-mediated cytotoxicity

Submit

https://t.me/USMLEWorldStep1

A 14-year-old boy is brought to the emergency department by his mother after he develops a sudden rash. He was trying to retrieve a baseball that had rolled under a log when he got stung by something. By the time he told his mom, his body was covered in welts. Within minutes, the patient's face started to swell and he was having a hard time swallowing. The patient's blood pressure is 70/50 mm Hg and heart rate is 120/min. Physical examination shows erythematous, raised plaques over the trunk, extremities, and face. Lung auscultation reveals bilateral expiratory wheezes. The mother is not aware of the child having any similar reaction in the past. Which of the following most likely triggered this patient's condition?

- A. Antibody-antigen complex deposition in the endothelium (3%)
- ✗ B. Antibody-dependent cell-mediated cytotoxicity (11%)
- C. CD8+ T lymphocyte-mediated hypersensitivity (14%)
- ✓ D. Cell surface-bound antibody linking by antigen (64%)
- E. Complement-mediated cytotoxicity (6%)

Incorrect
Correct answer
D

64%
Answered correctly

04 secs
Time Spent

2023
Version

Explanation

Hypersensitivity reactions			
	Humoral components	**Cellular components**	**Examples**
Type I (immediate)	• **IgE**	• Basophils • Mast cells	• Anaphylaxis • Allergies
			• Autoimmune

https://t.me/USMLEWorldStep1

Hypersensitivity reactions			
	Humoral components	**Cellular components**	**Examples**
Type I (immediate)	• **IgE**	• Basophils • Mast cells	• Anaphylaxis • Allergies
Type II (cytotoxic)	• **IgG & IgM** autoantibodies • Complement activation	• NK cells • Eosinophils • Neutrophils • Macrophages	• Autoimmune hemolytic anemia • Goodpasture syndrome
Type III (immune complex)	• Deposition of **antibody-antigen complexes** • Complement activation	• Neutrophils	• Serum sickness • PSGN • Lupus nephritis
Type IV (delayed type)	• None	• **T cells** • **Macrophages**	• Contact dermatitis • Tuberculin skin test
NK = natural killer; **PSGN** = poststreptococcal glomerulonephritis.			

This patient is experiencing **anaphylaxis**, a type I (immediate) hypersensitivity reaction that occurs in response to allergen (eg, venom from insect sting) exposure. An allergen is an antigen that promotes a robust immune response only in a subset of the population.

https://t.me/USMLEWorldStep1

This patient is experiencing **anaphylaxis**, a type I (immediate) hypersensitivity reaction that occurs in response to allergen (eg, venom from insect sting) exposure. An allergen is an antigen that promotes a robust immune response only in a subset of the population.

On initial exposure to allergen, a patient who will eventually develop an allergic response will undergo antibody class switching to **IgE** in B lymphocytes specific for these allergens. Antigen-specific IgE produced by plasma cells binds to IgE receptors on basophils in the blood and mast cells in the tissues. When the relevant antigen (allergen) interacts with cell bound-specific IgE, these antibodies will cross-link, causing degranulation and release of chemical mediators (histamine, prostaglandin, leukotrienes) responsible for systemic vasodilation, increased vascular permeability, bronchoconstriction, and hemodynamic instability.

(Choice A) Antibody-antigen complex deposition in the vasculature occurs with Type III hypersensitivity reactions (eg, serum sickness, Arthus reaction).

(Choice B) Antibody-dependent cell-mediated cytotoxicity occurs in type II hypersensitivity reactions wherein IgM or IgG binds to antigens expressed on the cell surface. These antibodies are then recognized by Fc receptors on immune cells, triggering the release of perforin and granzymes that ultimately leads to cell lysis and death.

(Choice C) CD8+ T lymphocyte-mediated hypersensitivity is a delayed rather than immediate type of immune response. Type IV hypersensitivity is unique in that it is not cell- versus antibody-mediated (seen in types I-III).

(Choice E) Complement-mediated cytotoxicity is a function of circulating IgM and IgG, not IgE. This pathway plays a role in the damage associated with Type II and III hypersensitivity reactions. IgM is the antibody most efficient at initiating the classical complement cascade because it circulates as a pentamer (allows for increased complement interaction).

Educational objective:
Type I hypersensitivity reactions are mediated by the interaction of allergen with preexisting IgE bound to basophils and mast cells. This facilitates cross-linking of the surface IgE molecules that signals the cell to degranulate releasing chemical mediators (eg, histamine, heparin). These agents are responsible for the immediate signs and symptoms of allergy, from a local wheal and flare to life-threatening anaphylaxis.

Immunology Pulmonary & Critical Care Anaphylaxis

https://t.me/USMLEWorldStep1

This patient is experiencing **anaphylaxis**, a type I (immediate) hypersensitivity reaction that occurs in response to allerge
respor

On init
class s
binds t
interac
chemi
vascul

(Choi
(eg, se

(Choi
or IgG
immur

(Choi
respor

(Choi
plays a
efficier
compl

Educa
Type I
and m
releasing chemical mediators (eg, histamine, heparin). These agents are responsible for the immediate signs and symptoms of allergy, from a local wheal and flare to life-threatening anaphylaxis.

Exhibit Display

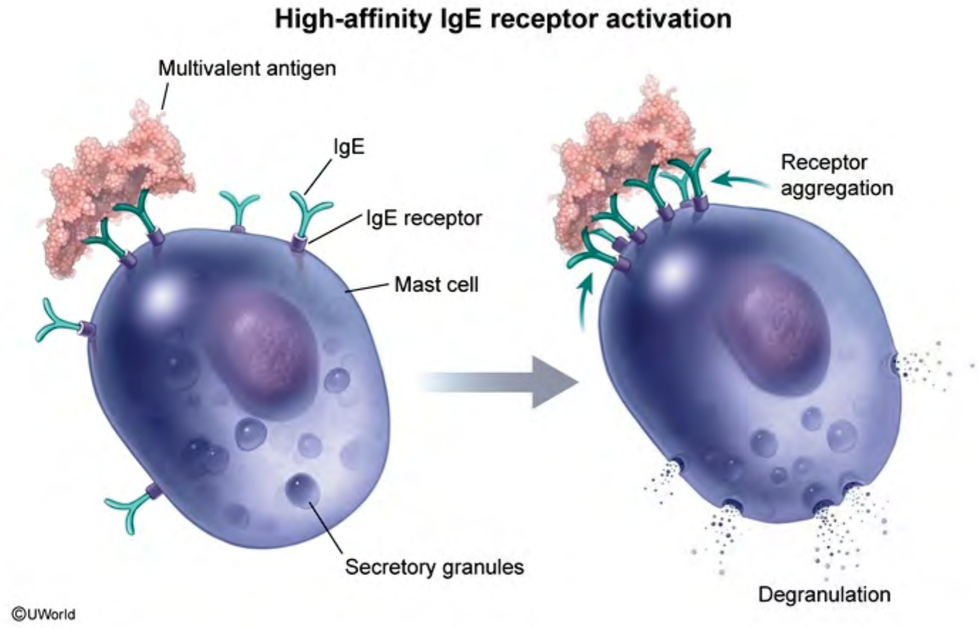

Zoom In Zoom Out Reset New | Existing My Notebook

https://t.me/USMLEWorldStep1
Show all

A 33-year-old man comes to the emergency department due to 3 days of shortness of breath, profound fatigue, and chills. The patient has a history of intravenous drug use. He was enrolled in a methadone program but admits to relapsing last week. Temperature is 40 C (104 F), blood pressure is 75/40 mm Hg, pulse is 122/min and regular, and respirations are 40/min. He is admitted to the intensive care unit but dies despite treatment efforts. Lung autopsy findings are shown in the image below.

mp4
73123 (1).mp4
73123.mp4
https://t.me/USMLEWorldStep1
Show all

A 33-year-old man comes to the emergency department due to 3 days of shortness of breath, profound fatigue
and ch
to rela
and re
autops

Exhibit Display

Zoom In | Zoom Out | Reset | New | Existing | My Notebook

mp4
73123 (1).mp4
73123.mp4
https://t.me/USMLEWorldStep1
Show all

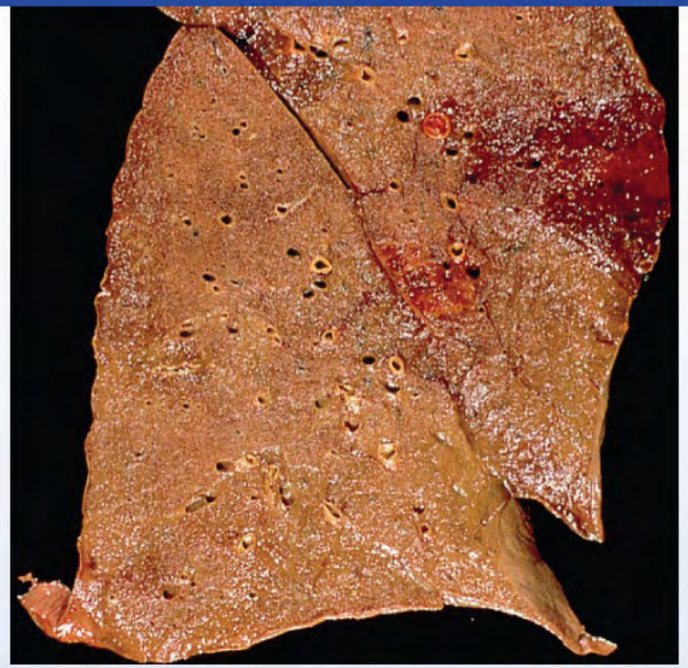

Which of the following is the most likely diagnosis in this patient?

- A. Miliary tuberculosis
- B. Mycotic aortic aneurysm
- C. Severe small airway obstruction
- D. Tricuspid valve endocarditis
- E. Venous thromboembolism

Submit

mp4
73123 (1).mp4
73123.mp4
https://t.me/USMLEWorldStep1
Show all

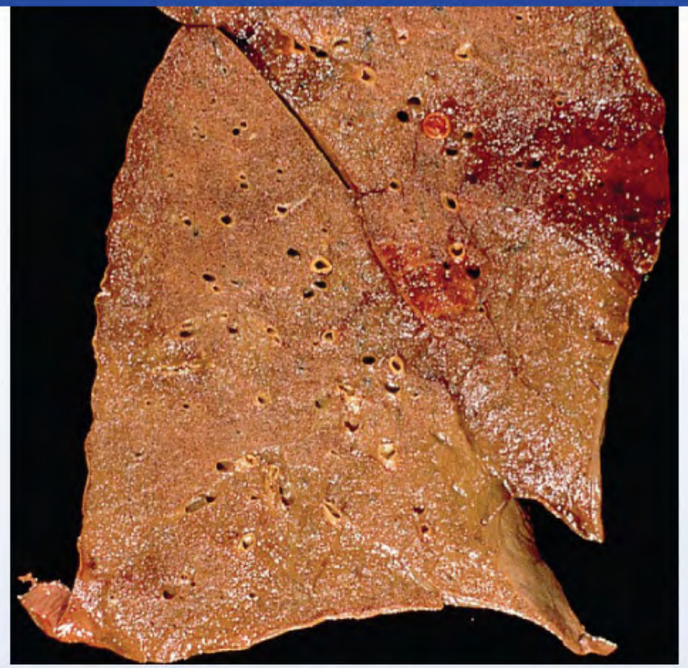

Which of the following is the most likely diagnosis in this patient?

- ✗ A. Miliary tuberculosis (10%)
- B. Mycotic aortic aneurysm (0%)
- C. Severe small airway obstruction (4%)
- ✓ D. Tricuspid valve endocarditis (55%)
- E. Venous thromboembolism (27%)

Incorrect
Correct answer
D

55%
Answered correctly

13 secs
Time Spent

2023
Version

mp4
73123 (1).mp4
73123.mp4
https://t.me/USMLEWorldStep1
Show all

C. Severe small airway obstruction (4%)

Exhibit Display

Hemorrhagic pulmonary infarcts

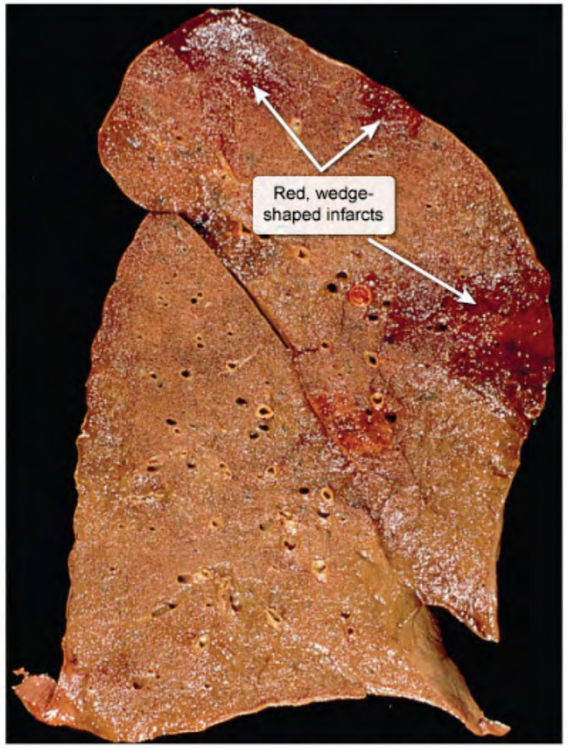

Displayed with permission from Springer Healthcare Ltd © Copyright 1996, 2004 by Current Medicine

Zoom In | Zoom Out | Reset | New | Existing | My Notebook

73123 (1).mp4
73123.mp4
https://t.me/USMLEWorldStep1
Show all

The lung specimen above shows multiple wedge-shaped hemorrhagic infarcts in the periphery of the lung, which, given this patient's presentation, are most likely due to **septic pulmonary emboli**.

Patients with **intravenous drug use** are at increased risk of developing **tricuspid valve endocarditis**, most commonly due to *Staphylococcus aureus*. The clinical presentation is typically acute with high-grade fever, and tachycardia and hypotension due to septic shock. The majority of patients with tricuspid valve endocarditis experience embolization of tricuspid valve vegetation fragments; these fragments lodge in distal portions of the pulmonary arterial tree and cause septic pulmonary infarcts. The infarcts are typically **wedge-shaped** due to the triangular perfusion field of small arteries at the lung periphery. Due to the relatively low density of lung tissue (which allows blood seepage into tissue during infarction) and a dual blood supply (ie, pulmonary and bronchial arteries), pulmonary infarcts are typically **hemorrhagic (red)** rather than ischemic (white).

(Choice A) Miliary tuberculosis typically has a subacute or chronic presentation and is accompanied by night sweats, weight loss, and anorexia. Innumerable, small, white nodules resembling millet seeds are typically seen; peripherally located wedge-shaped hemorrhages in the lung are not characteristic.

(Choice B) Mycotic aneurysms may occur as a complication of endocarditis; however, they refer to the local destruction and dilation of an arterial wall due to infection. Despite their name, mycotic aneurysms are very rarely associated with fungal infections.

(Choice C) Small airway obstruction is characteristic of asthma, which typically presents with dyspnea, cough, wheezing, and chest tightness. Lung autopsy usually reveals the occlusion of bronchi and bronchioles by thick mucous plugs containing shed epithelium.

(Choice E) Venous thromboembolism in the pulmonary vasculature (ie, thrombotic pulmonary embolism) can also cause wedge-shaped hemorrhagic infarct in the periphery of the lung. However, this patient's high-grade fever and recent intravenous drug use are more suggestive of septic emboli from tricuspid valve endocarditis. In addition, multiple pulmonary infarcts are more consistent with septic embolization than venous thromboembolism.

Educational objective:

Pulmonary infarcts are typically hemorrhagic (red) and wedge-shaped in the periphery of the lung. Intravenous

mp4
73123 (1).mp4
73123.mp4
https://t.me/USMLEWorldStep1
Show all

Patients with **intravenous drug use** are at increased risk of developing **tricuspid valve endocarditis**, most commonly due to *Staphylococcus aureus*. The clinical presentation is typically acute with high-grade fever, and tachycardia and hypotension due to septic shock. The majority of patients with tricuspid valve endocarditis experience embolization of tricuspid valve vegetation fragments; these fragments lodge in distal portions of the pulmonary arterial tree and cause septic pulmonary infarcts. The infarcts are typically **wedge-shaped** due to the triangular perfusion field of small arteries at the lung periphery. Due to the relatively low density of lung tissue (which allows blood seepage into tissue during infarction) and a dual blood supply (ie, pulmonary and bronchial arteries), pulmonary infarcts are typically **hemorrhagic (red)** rather than ischemic (white).

(Choice A) Miliary tuberculosis typically has a subacute or chronic presentation and is accompanied by night sweats, weight loss, and anorexia. Innumerable, small, white nodules resembling millet seeds are typically seen; peripherally located wedge-shaped hemorrhages in the lung are not characteristic.

(Choice B) Mycotic aneurysms may occur as a complication of endocarditis; however, they refer to the local destruction and dilation of an arterial wall due to infection. Despite their name, mycotic aneurysms are very rarely associated with fungal infections.

(Choice C) Small airway obstruction is characteristic of asthma, which typically presents with dyspnea, cough, wheezing, and chest tightness. Lung autopsy usually reveals the occlusion of bronchi and bronchioles by thick mucous plugs containing shed epithelium.

(Choice E) Venous thromboembolism in the pulmonary vasculature (ie, thrombotic pulmonary embolism) can also cause wedge-shaped hemorrhagic infarct in the periphery of the lung. However, this patient's high-grade fever and recent intravenous drug use are more suggestive of septic emboli from tricuspid valve endocarditis. In addition, multiple pulmonary infarcts are more consistent with septic embolization than venous thromboembolism.

Educational objective:
Pulmonary infarcts are typically hemorrhagic (red) and wedge-shaped in the periphery of the lung. Intravenous drug users are at increased risk of tricuspid valve endocarditis, which can cause multiple septic pulmonary infarcts due to embolization of tricuspid valve vegetation fragments.

mp4
73123 (1).mp4
73123.mp4
https://t.me/USMLEWorldStep1
Show all

A 45-year-old man comes to the emergency department due to severe dyspnea and chest discomfort that began earlier in the day. The dyspnea has been worsening throughout the day and has been present at rest. He reports no inciting trauma. The patient has no other medical conditions and takes no medications. He has a 20-pack-year smoking history and does not use alcohol or illicit drugs. Temperature is 36.7 C (98 F), blood pressure is 110/60 mm Hg, and pulse is 96/min. Arterial blood gas drawn on room air shows an arterial partial pressure of oxygen (PaO_2) of 54 mm Hg and an arterial partial pressure of carbon dioxide ($PaCO_2$) of 26 mm Hg. Which of the following processes is most likely occurring in this patient?

- A. Alveolar hyperventilation
- B. Decreased chest wall compliance
- C. Expiratory air trapping
- D. Poor respiratory drive
- E. Respiratory muscle fatigue

Submit

https://t.me/USMLEWorldStep1

A 45-year-old man comes to the emergency department due to severe dyspnea and chest discomfort that began earlier in the day. The dyspnea has been worsening throughout the day and has been present at rest. He reports no inciting trauma. The patient has no other medical conditions and takes no medications. He has a 20-pack-year smoking history and does not use alcohol or illicit drugs. Temperature is 36.7 C (98 F), blood pressure is 110/60 mm Hg, and pulse is 96/min. Arterial blood gas drawn on room air shows an arterial partial pressure of oxygen (PaO_2) of 54 mm Hg and an arterial partial pressure of carbon dioxide ($PaCO_2$) of 26 mm Hg. Which of the following processes is most likely occurring in this patient?

- ✓ A. Alveolar hyperventilation (52%)
- B. Decreased chest wall compliance (10%)
- C. Expiratory air trapping (19%)
- D. Poor respiratory drive (10%)
- E. Respiratory muscle fatigue (7%)

Correct

52%
Answered correctly

05 mins, 41 secs
Time Spent

2023
Version

Explanation

Effect of hyperventilation on O_2 & CO_2 exchange

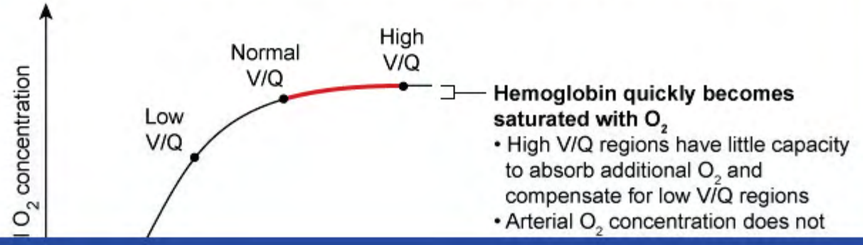

Hemoglobin quickly becomes saturated with O_2

- High V/Q regions have little capacity to absorb additional O_2 and compensate for low V/Q regions
- Arterial O_2 concentration does not

https://t.me/USMLEWorldStep1

E. Respiratory muscle fatigue (7%)

Exhibit Display

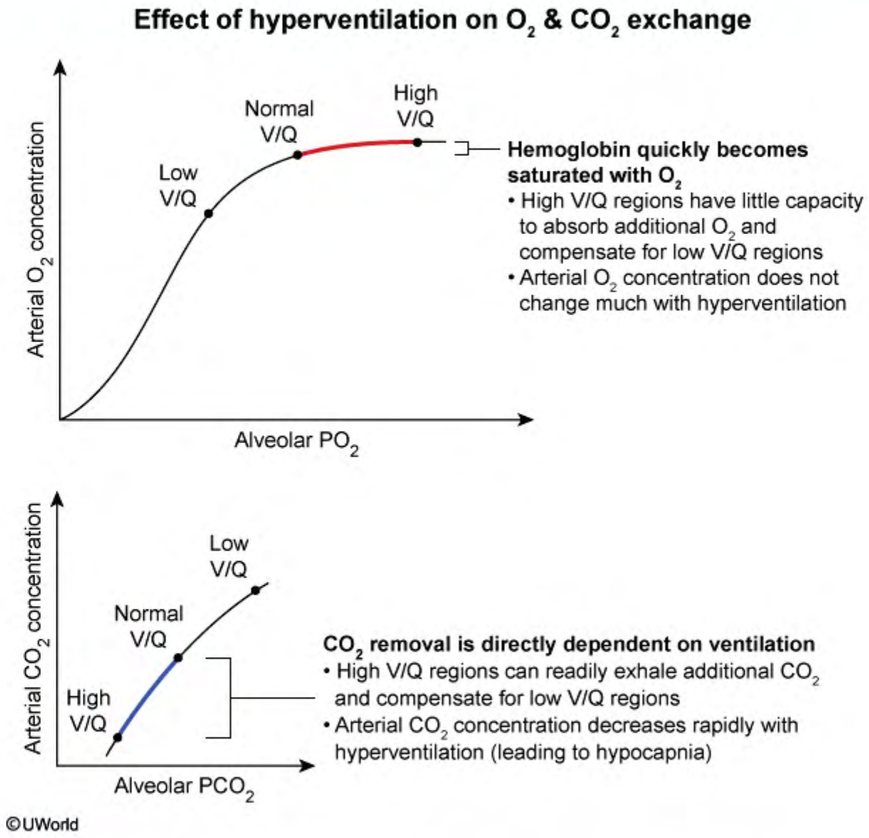

Zoom In | Zoom Out | Reset | New | Existing | My Notebook

©UWorld

https://t.me/USMLEWorldStep1

This patient with acute-onset dyspnea and chest discomfort likely has an **acute pulmonary embolism** (PE). PE leads to increased dead-space ventilation with a consequent ventilation/perfusion (V/Q) mismatch that causes **hypoxemia**. The acute hypoxemia along with pulmonary parenchymal inflammation triggers an increase in respiratory drive and **hyperventilation**.

Because the rate of CO_2 removal is closely tied to ventilation rate, alveolar hyperventilation leads to **increased expiration of CO_2** with resulting **hypocapnia** (low arterial partial pressure of carbon dioxide [$PaCO_2$]) and **respiratory alkalosis**. In contrast, the rate of O_2 absorption becomes capped once hemoglobin is saturated, which occurs at relatively low arterial partial pressure of oxygen (PaO_2) levels (eg, hemoglobin is 85% saturated at PaO_2 50 mm Hg). Therefore, the blood in highly ventilated lung regions cannot absorb extra O_2 to compensate for poorly ventilated regions, and hyperventilation does not significantly increase PaO_2.

It follows that patients with an acute V/Q mismatch (eg, due to PE or pneumonia) typically have hypocapnia with respiratory alkalosis and persistent hypoxemia. Without treatment, prolonged hyperventilation can lead to respiratory muscle fatigue **(Choice E)** with consequent respiratory failure; these patients will have hypoventilation with hypercapnia and respiratory acidosis.

(Choices B and D) Both decreased chest wall compliance, as occurs in obesity hypoventilation syndrome, and poor respiratory drive, as occurs in opioid overdose and some types of stroke, lead to hypoventilation with hypoxemia and increased $PaCO_2$ levels.

(Choice C) Expiratory air trapping occurs in chronic obstructive lung disease. These patients often have chronic respiratory acidosis (high $PaCO_2$) that may worsen (acute on chronic respiratory acidosis) during exacerbation.

Educational objective:
An acute ventilation/perfusion mismatch (eg, due to pulmonary embolism or pneumonia) causes hypoxemia and triggers hyperventilation. Because the removal of CO_2 is directly dependent on ventilation but the absorption of O_2 is capped by the high baseline saturation of hemoglobin, the hyperventilation response typically leads to respiratory alkalosis (low arterial partial pressure of carbon dioxide) with persistent hypoxemia.

References

- Mechanisms of hypoxemia and hypocapnia in pulmonary embolism

https://t.me/USMLEWorldStep1

This patient with acute-onset dyspnea and chest discomfort likely has an **acute pulmonary embolism** (PE). PE leads
hypox
respira

Becau
expira
respir
which
PaO_2 5
poorly

It follo
respira
respira
with hy

(Choi
poor re
hypox

(Choi
respira

Educa
An acu
trigger
is capp
respira

References

- Mechanisms of hypoxemia and hypocapnia in pulmonary embolism

Exhibit Display

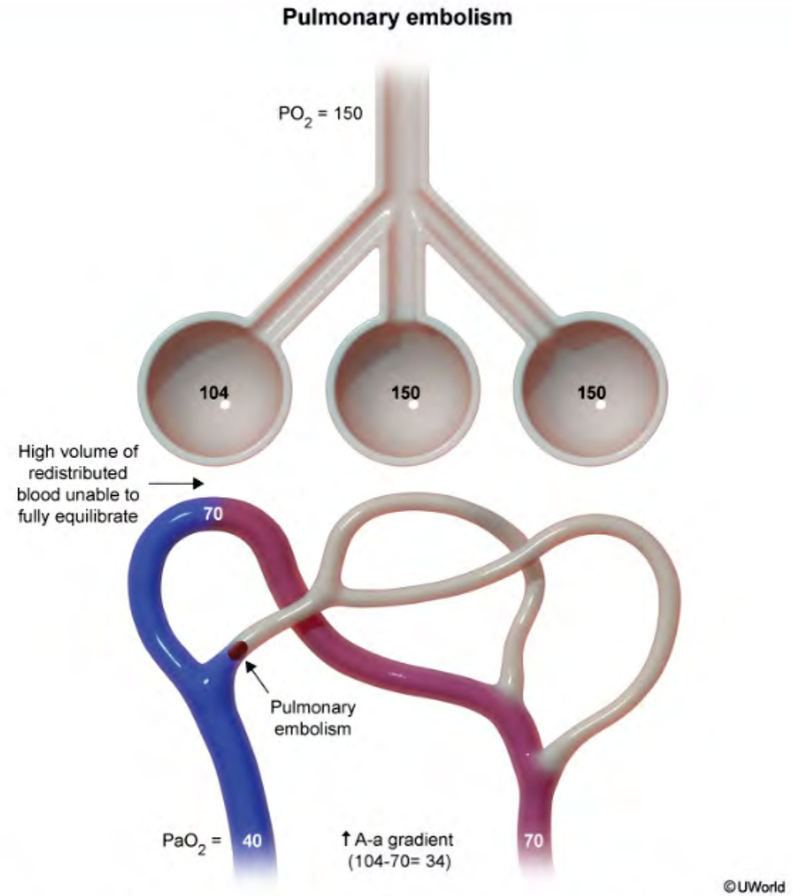

Zoom In | Zoom Out | Reset | New | Existing | My Notebook

https://t.me/USMLEWorldStep1

A 44-year-old man with a chronic cough and progressive weight loss comes to the emergency department. He has lost 5 kg (11 lb) over the past 3 months. The patient recently emigrated from Southeast Asia. Temperature is 37.4 C (99.3 F), blood pressure is 113/70 mm Hg, pulse is 78/min, and respirations are 18/min. Chest x-ray reveals an apical left lung infiltrate. Sputum Gram stain and cultures are negative. However, culture of a lung biopsy specimen grows acid-fast bacilli. Microscopy of the lung specimen is shown below.

Which of the following processes is most likely to contribute to formation of the finding indicated by the arrow?

- A. Activation of CD8 T lymphocytes
- B. B-lymphocyte transformation
- C. Fibroblast proliferation
- D. Neutrophil infiltration
- E. Cytokine secretion by CD4 T lymphocytes

Submit

https://t.me/USMLEWorldStep1

A 44-year-old man with a chronic cough and progressive weight loss comes to the emergency department. He has lost 5
C (99.
apical
specin

Exhibit Display

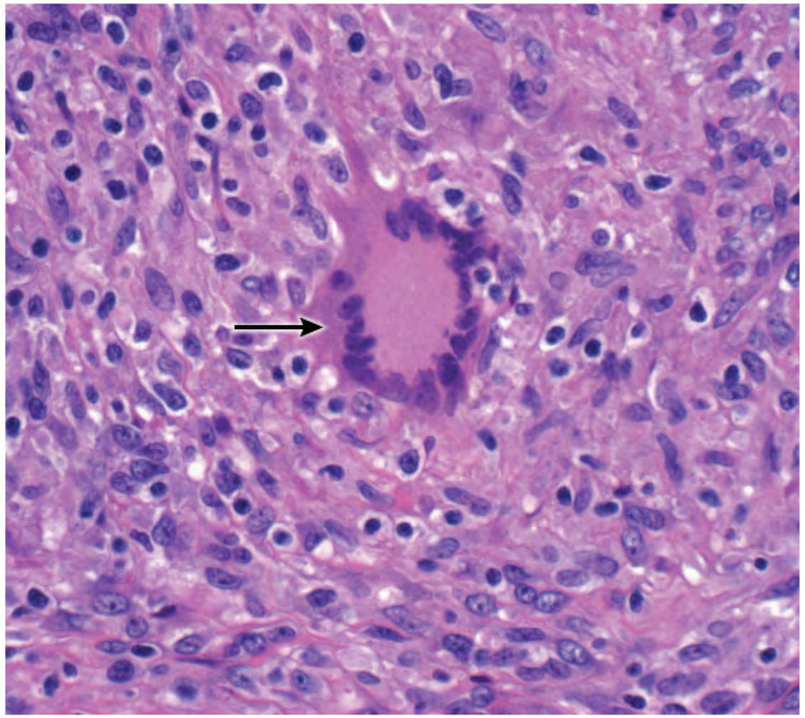

Zoom In Zoom Out Reset New | Existing My Notebook

Which

C. Fibroblast proliferation

https://t.me/USMLEWorldStep1

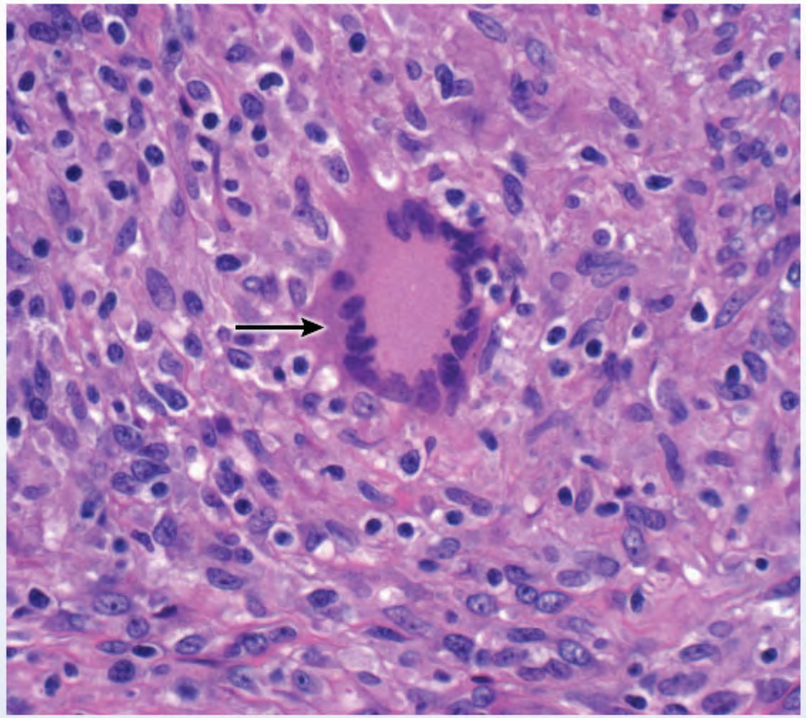

Which of the following processes is most likely to contribute to formation of the finding indicated by the arrow?

- A. Activation of CD8 T lymphocytes
- B. B-lymphocyte transformation
- C. Fibroblast proliferation
- D. Neutrophil infiltration
- E. Cytokine secretion by CD4 T lymphocytes

Submit

https://t.me/USMLEWorldStep1

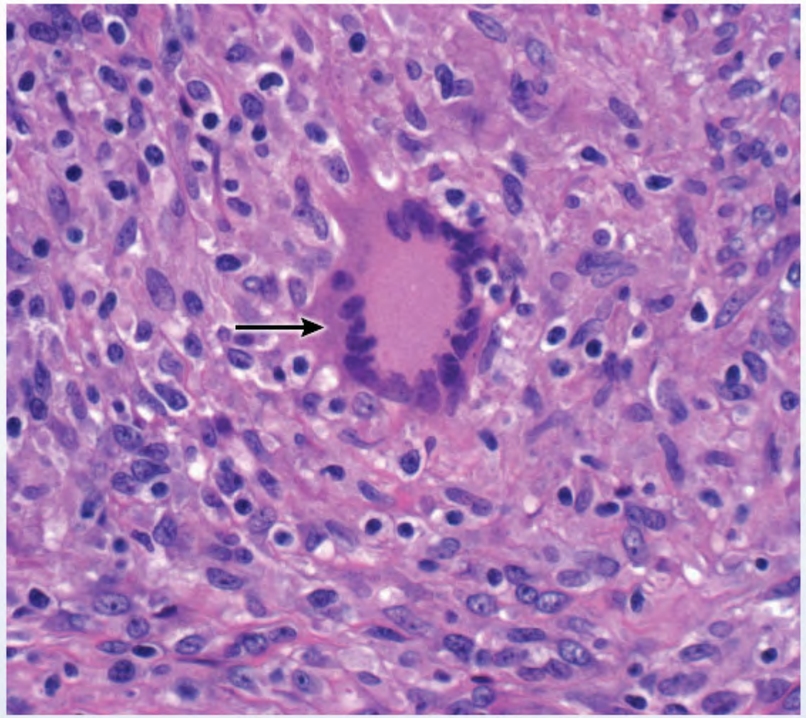

Which of the following processes is most likely to contribute to formation of the finding indicated by the arrow?

- A. Activation of CD8 T lymphocytes (15%)
- B. B-lymphocyte transformation (2%)
- ✗ C. Fibroblast proliferation (5%)
- D. Neutrophil infiltration (7%)
- ✓ E. Cytokine secretion by CD4 T lymphocytes (69%)

Incorrect
Correct answer
E

69%
Answered correctly

12 secs
Time Spent

2023
Version

https://t.me/USMLEWorldStep1

D. Neutrophil infiltration (7%)

Exhibit Display

Tuberculosis

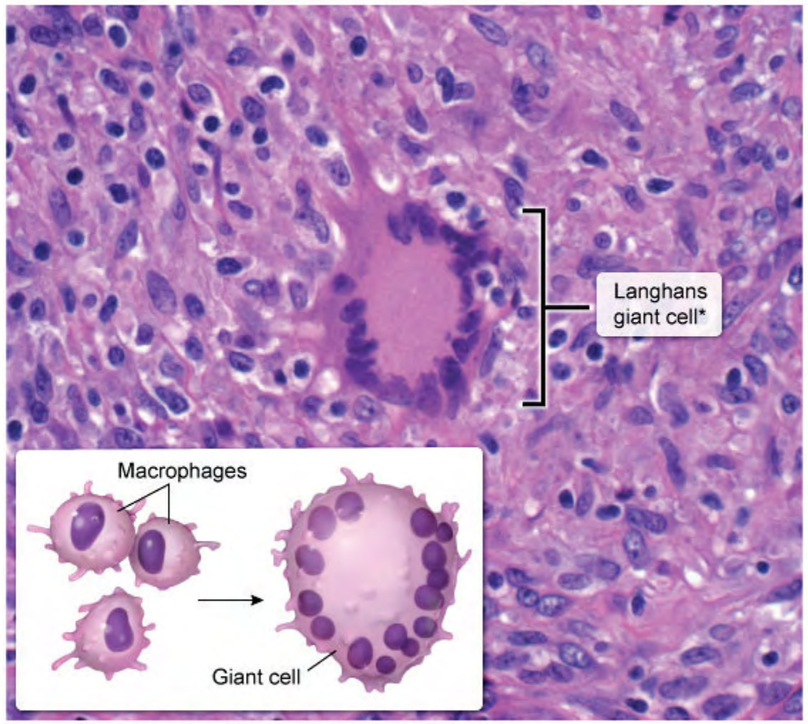

*Coalesced epithelioid macrophages with nuclei arranged at periphery ©UWorld

Zoom In | Zoom Out | Reset | New | Existing | My Notebook

*Coalesced epithelioid macrophages with nuclei arranged at periphery ©UWorld

https://t.me/USMLEWorldStep1

This patient from Southeast Asia has weight loss, cough, and an apical infiltrate with acid-fast bacilli, raising strong suspicion for **pulmonary tuberculosis**. *Mycobacterium tuberculosis* is transmitted to the lungs via aerosolized droplets. It initially replicates in an unchecked fashion within the alveoli and alveolar macrophages due to virulence factors (eg, cord factor) that prevent macrophage-mediated destruction. After a few weeks, infected macrophages in the draining lymphatic system display mycobacterial antigens on major histocompatibility complex (MHC) class II molecules, leading to the **stimulation of CD4 T lymphocytes**.

Stimulated CD4 cells **release interferon-gamma** that activates macrophages, greatly increasing their ability to kill phagocytized organisms. Activated macrophages can also differentiate into epithelioid histiocytes and coalesce into **multinucleated Langhans giant cells** that wall off mycobacteria within granulomas. The center of the granuloma is acidic and hypoxic, which causes it to appear acellular, necrotic, and "cheese-like" (**caseating**). Granulomas typically limit mycobacterial proliferation but do not fully eliminate the infection.

Although Langhans giant cells are an important component of the immunologic response to pulmonary tuberculosis, they are a nonspecific finding that may also be present in other chronic infectious or inflammatory conditions (eg, sarcoidosis, Crohn disease).

(Choice A) Some intracellular bacterial pathogens (eg, *Listeria*, *Rickettsia*) have virulence factors that allow them to escape the phagosome and replicate within the cytosol. These pathogens are primarily processed by the proteasome (rather than the lysosome), leading to the display of bacterial protein fragments on MHC class I molecules. MHC class I molecules stimulate cytotoxic T cells (CD8 lymphocytes). In contrast, phagocytosed bacteria that remain within the phagosome (eg, *M tuberculosis*) are broken down by the lysosome and displayed on MHC class II molecules, which activate CD4, not CD8, cells.

(Choice B) Epstein-Barr virus attacks B lymphocytes and leads to long-term, latent infection that is typically asymptomatic but can occasionally lead to B-lymphocyte malignant transformation. Although malignant transformation can cause large, atypical cells, acid-fast bacilli would not be seen on culture.

(Choice C) Fibroblast proliferation and collagen production contribute to caseating granuloma formation but do not cause macrophage activation, which is necessary for the formation of multinucleated Langhans giant cells.

(Choice D) Neutrophils (polymorphonuclear cells) have multilobed nuclei that would be visible at this magnification. Neutrophils play a major role in early inflammation and elimination of extracellular bacterial

https://t.me/USMLEWorldStep1

into **multinucleated Langhans giant cells** that wall off mycobacteria within granulomas. The center of the granuloma is acidic and hypoxic, which causes it to appear acellular, necrotic, and "cheese-like" (**caseating**). Granulomas typically limit mycobacterial proliferation but do not fully eliminate the infection.

Although Langhans giant cells are an important component of the immunologic response to pulmonary tuberculosis, they are a nonspecific finding that may also be present in other chronic infectious or inflammatory conditions (eg, sarcoidosis, Crohn disease).

(Choice A) Some intracellular bacterial pathogens (eg, *Listeria*, *Rickettsia*) have virulence factors that allow them to escape the phagosome and replicate within the cytosol. These pathogens are primarily processed by the proteasome (rather than the lysosome), leading to the display of bacterial protein fragments on MHC class I molecules. MHC class I molecules stimulate cytotoxic T cells (CD8 lymphocytes). In contrast, phagocytosed bacteria that remain within the phagosome (eg, *M tuberculosis*) are broken down by the lysosome and displayed on MHC class II molecules, which activate CD4, not CD8, cells.

(Choice B) Epstein-Barr virus attacks B lymphocytes and leads to long-term, latent infection that is typically asymptomatic but can occasionally lead to B-lymphocyte malignant transformation. Although malignant transformation can cause large, atypical cells, acid-fast bacilli would not be seen on culture.

(Choice C) Fibroblast proliferation and collagen production contribute to caseating granuloma formation but do not cause macrophage activation, which is necessary for the formation of multinucleated Langhans giant cells.

(Choice D) Neutrophils (polymorphonuclear cells) have multilobed nuclei that would be visible at this magnification. Neutrophils play a major role in early inflammation and elimination of extracellular bacterial pathogens (eg, *Staphylococcus aureus*). However, they are not the primary effector cell in the elimination of facultative intracellular pathogens such as *M tuberculosis*.

Educational objective:
Mycobacterium tuberculosis triggers CD4 T lymphocytes to release interferon-gamma, which leads to macrophage activation (improves intracellular killing ability) and differentiation into epithelioid histiocytes. These cells, along with horseshoe-shaped, multinucleated Langhans giant cells (fused, activated macrophages) are a key component of granuloma formation.

https://t.me/USMLEWorldStep1

Exhibit Display

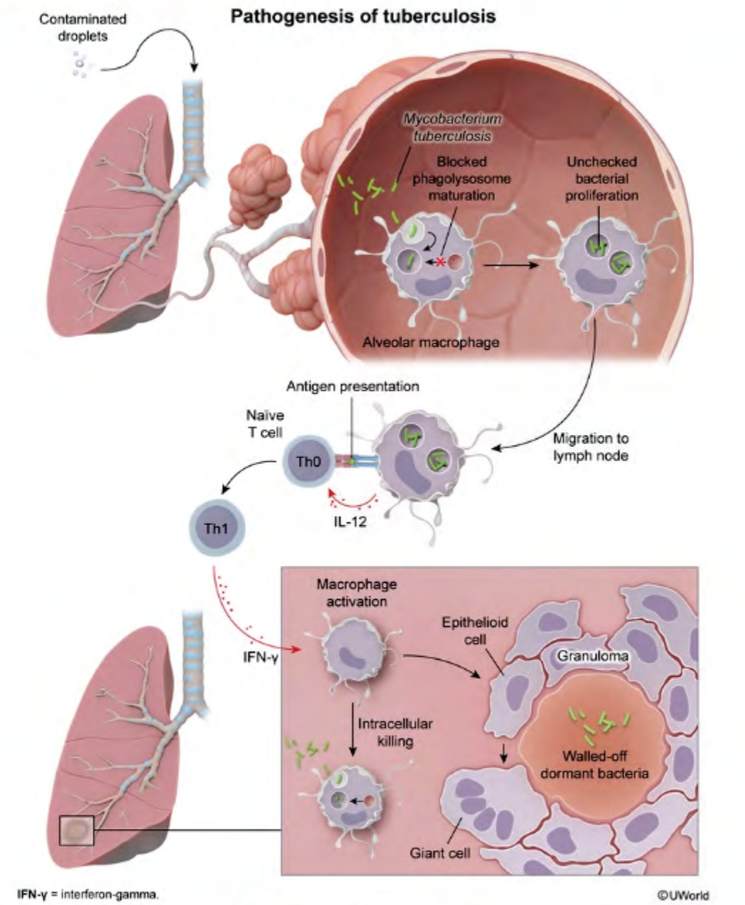

Zoom In | Zoom Out | Reset | New | Existing | My Notebook

This p
suspic
drople
factors
in the
molecu

Stimul
phago
into **m**
granul
Granu

Althou
tuberc
conditi

(Choi
to esc
protea
molec
bacter
on MH

(Choice B) Epstein-Barr virus attacks B-lymphocytes and leads to long-term, latent infection that is typically asymptomatic but can occasionally lead to B-lymphocyte malignant transformation. Although malignant

https://t.me/USMLEWorldStep1

suspicion for **pulmonary tuberculosis**. *Mycobacterium tuberculosis* is transmitted to the lungs via aerosolized droplets. It initially replicates in an unchecked fashion within the alveoli and alveolar macrophages due to virulence factors

in the

molecu

Stimul

phago

into **m**

granul

Granu

Althou

tuberc

conditi

(Choi

to esc

protea

molec

bacter

on MH

(Choi

asymp

transfo

(Choi

cause

(Choi

Exhibit Display

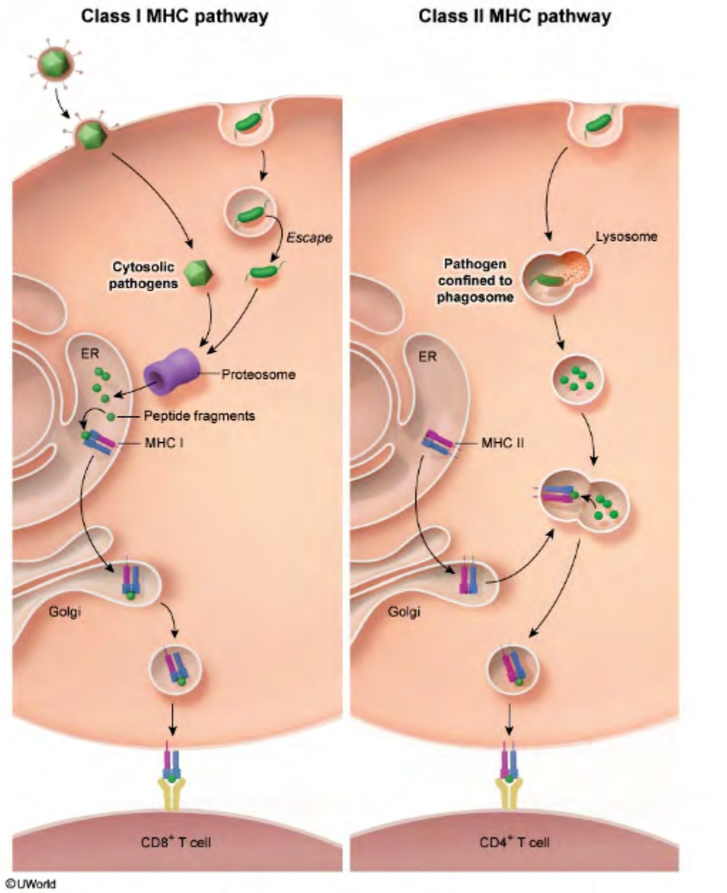

Zoom In | Zoom Out | Reset | New | Existing | My Notebook

https://t.me/USMLEWorldStep1
Show all

A 64-year-old patient with frequent wheezing and shortness of breath is started on a new inhaled medication, with significant relief of symptoms. The medication has a long lipophilic side chain that allows attachment to the plasma membrane. The side chain also binds to an auxiliary, deeper site different from the one that binds epinephrine, helping to tether the molecule near the beta-2 adrenergic receptor. Which of the following medications did this patient most likely receive?

- A. Albuterol
- B. Isoproterenol
- C. Levalbuterol
- D. Salmeterol
- E. Terbutaline

Submit

https://t.me/USMLEWorldStep1
Show all

A 64-year-old patient with frequent wheezing and shortness of breath is started on a new inhaled medication, with significant relief of symptoms. The medication has a long lipophilic side chain that allows attachment to the plasma membrane. The side chain also binds to an auxiliary, deeper site different from the one that binds epinephrine, helping to tether the molecule near the beta-2 adrenergic receptor. Which of the following medications did this patient most likely receive?

- A. Albuterol (24%)
- ✗ B. Isoproterenol (10%)
- C. Levalbuterol (8%)
- ✓ D. Salmeterol (39%)
- E. Terbutaline (17%)

Incorrect
Correct answer
D

39%
Answered correctly

03 secs
Time Spent

2023
Version

Explanation

Beta-2 agonists are bronchodilators frequently used in the treatment of asthma and chronic obstructive pulmonary disease (COPD). They can be categorized by their duration of action, which is largely due to drug lipophilicity.

- **Long-acting beta-2 agonists** (eg, salmeterol, formoterol) are typically used for maintenance therapy in COPD or with inhaled corticosteroids in asthma. These drugs have a **lipophilic side chain**, which allows them to attach to the plasma membrane and diffuse laterally across to the beta-2 receptor. As a result, they have an extended duration of action (≥12 hours) but slow onset of action. **Salmeterol** has a slightly longer duration of action than formoterol due to its ability to bind a **secondary exosite** within the beta-2 receptor,

https://t.me/USMLEWorldStep1
Show all

Beta-2 agonists are bronchodilators frequently used in the treatment of asthma and chronic obstructive pulmonary disease (COPD). They can be categorized by their duration of action, which is largely due to drug lipophilicity.

- **Long-acting beta-2 agonists** (eg, salmeterol, formoterol) are typically used for maintenance therapy in COPD or with inhaled corticosteroids in asthma. These drugs have a **lipophilic side chain**, which allows them to attach to the plasma membrane and diffuse laterally across to the beta-2 receptor. As a result, they have an extended duration of action (≥12 hours) but slow onset of action. **Salmeterol** has a slightly longer duration of action than formoterol due to its ability to bind a **secondary exosite** within the beta-2 receptor, which serves as an anchor to prevent active site dissociation.
- **Short-acting beta-2 agonists** (eg, albuterol, levalbuterol) are typically used for acute symptom relief. These drugs are relatively hydrophilic, interact minimally with the plasma membrane, and are rapidly metabolized, explaining their rapid onset (minutes) and short duration of action (4-6 hours) **(Choices A and C)**.

(Choice B) Isoproterenol is a nonselective beta agonist used primarily for its chronotropic effects in patients with bradycardia or heart block.

(Choice E) Terbutaline is a short-acting beta-2 agonist administered via intravenous or subcutaneous injection for very severe asthma exacerbations (ie, those requiring intubation). It does not have a long lipophilic side chain.

Educational objective:
Short-acting beta-2 agonists (eg, albuterol, levalbuterol) are hydrophilic and are rapidly metabolized, explaining their rapid onset and short duration of action. Long-acting beta-2 agonists (eg, salmeterol, formoterol) have a prolonged duration of action due to their lipophilic side chain, which allows them to attach to the cell plasma membrane. Salmeterol also binds to a secondary exosite within the beta-2 receptor, anchoring the molecule and further prolonging its action.

Pharmacology	Pulmonary & Critical Care	Beta 2 agonists
Subject	System	Topic

https://t.me/USMLEWorldStep1
Show all

Beta-2 agonists are bronchodilators frequently used in the treatment of asthma and chronic obstructive pulmonary disease (COPD). They can be categorized by their duration of action, which is largely due to drug lipophilicity.

- **Long-acting beta-2 agonists** (eg, salmeterol, formoterol) are typically used for maintenance therapy in COPD or with inhaled corticosteroids in asthma. These drugs have a **lipophilic side chain**, which allows them to attach to the plasma membrane and diffuse laterally across to the beta-2 receptor. As a result, they have an extended duration of action (≥12 hours) but slow onset of action. **Salmeterol** has a slightly longer duration of action than formoterol due to its ability to bind a **secondary exosite** within the beta-2 receptor, which serves as an anchor to prevent active site dissociation.
- **Short-acting beta-2 agonists** (eg, albuterol, levalbuterol) are typically used for acute symptom relief. These drugs are relatively hydrophilic, interact minimally with the plasma membrane, and are rapidly metabolized, explaining their rapid onset (minutes) and short duration of action (4-6 hours) **(Choices A and C)**.

(Choice B) Isoproterenol is a nonselective beta agonist used primarily for its chronotropic effects in patients with bradycardia or heart block.

(Choice E) Terbutaline is a short-acting beta-2 agonist administered via intravenous or subcutaneous injection for very severe asthma exacerbations (ie, those requiring intubation). It does not have a long lipophilic side chain.

Educational objective:
Short-acting beta-2 agonists (eg, albuterol, levalbuterol) are hydrophilic and are rapidly metabolized, explaining their rapid onset and short duration of action. Long-acting beta-2 agonists (eg, salmeterol, formoterol) have a prolonged duration of action due to their lipophilic side chain, which allows them to attach to the cell plasma membrane. Salmeterol also binds to a secondary exosite within the beta-2 receptor, anchoring the molecule and further prolonging its action.

Pharmacology	Pulmonary & Critical Care	Beta 2 agonists
Subject	System	Topic

https://t.me/USMLEWorldStep1
Show all

A 3-year-old boy is brought to the office with 5 days of productive cough and fever. Examination shows a tachypneic, ill-appearing child with rales over the right lower lung. Chest x-ray reveals right lower lobe pneumonia. The boy is admitted to the hospital for intravenous antibiotics. Review of his medical history shows 4 prior pneumonias, and his weight is at the third percentile. Further testing demonstrates high sweat chloride content, and genetic sequencing shows a mutation in a transmembrane protein. Which of the following best describes the dysfunctional transmembrane protein causing this patient's disease?

- A. ATP-gated
- B. Cyclic nucleotide-gated
- C. Mechanically gated
- D. Temperature-gated
- E. Voltage-gated

Submit

https://t.me/USMLEWorldStep1
Show all

A 3-year-old boy is brought to the office with 5 days of productive cough and fever. Examination shows a tachypneic, ill-appearing child with rales over the right lower lung. Chest x-ray reveals right lower lobe pneumonia. The boy is admitted to the hospital for intravenous antibiotics. Review of his medical history shows 4 prior pneumonias, and his weight is at the third percentile. Further testing demonstrates high sweat chloride content, and genetic sequencing shows a mutation in a transmembrane protein. Which of the following best describes the dysfunctional transmembrane protein causing this patient's disease?

- ✓ A. ATP-gated (51%)
- B. Cyclic nucleotide-gated (8%)
- C. Mechanically gated (8%)
- D. Temperature-gated (0%)
- E. Voltage-gated (30%)

Correct

51% Answered correctly

04 secs Time Spent

2023 Version

Explanation

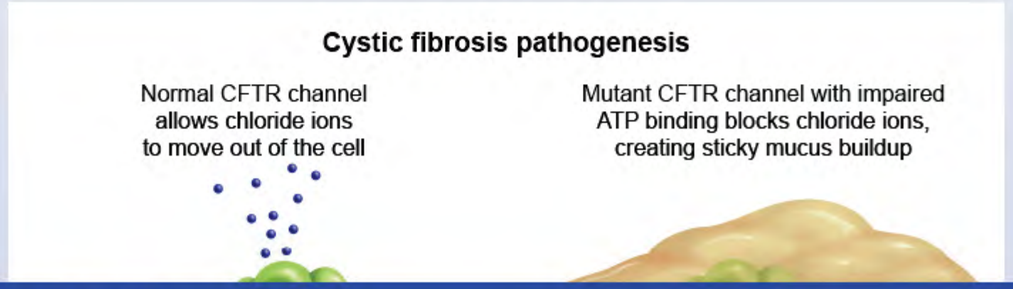

https://t.me/USMLEWorldStep1
Show all

Exhibit Display

Cystic fibrosis pathogenesis

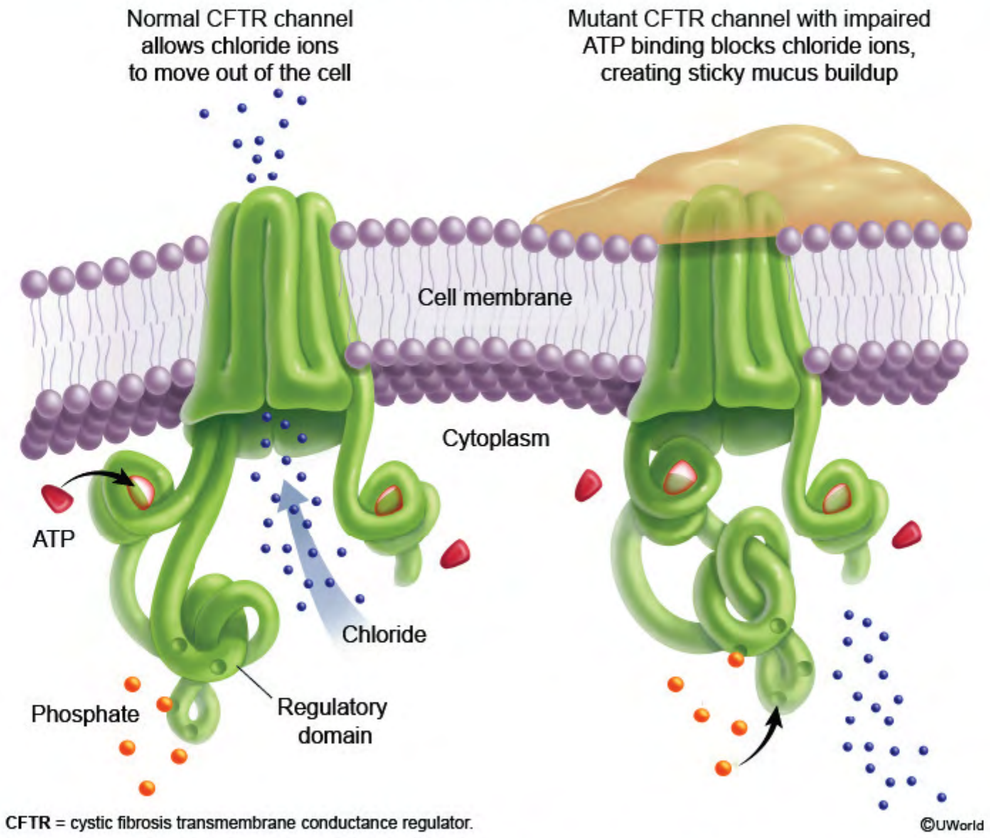

CFTR = cystic fibrosis transmembrane conductance regulator.

Zoom In | Zoom Out | Reset | New | Existing | My Notebook

https://t.me/USMLEWorldStep1
Show all

Cystic fibrosis (CF) is an autosomal recessive disorder due to mutations (eg, ΔF508) in the **CF transmembrane conductance regulator (CFTR)** protein. The channel pore **opens** after binding of **2 ATP molecules**, allowing transport of chloride ions down the electrochemical gradient. The movement of chloride establishes a membrane potential that draws sodium and water across the membrane as well. By encouraging sodium chloride and water transport across epithelial membranes, the CFTR **hydrates mucosal surfaces** in the airways and bowel. Mutations in the *CFTR* gene lead to intracellular protein degradation and decreased activity of the proteins that do reach the membrane. This leads to **thick mucus** on the lining of epithelial cells, which results in clinical manifestations of chronic cough, recurrent pneumonias, and pancreatic damage.

The normal CFTR protein also plays a role in the production of hypotonic sweat. In the eccrine gland, sweat is initially isotonic with the plasma, and normally sodium chloride is removed from the ductal lumen by CFTR. In the absence of functional CFTR, patients with CF cannot remove salt from their sweat and therefore have **elevated sweat chloride** and sodium levels. As early as the 17th century, increased mortality was recognized for children whose foreheads tasted salty. Today, the sweat chloride test is frequently used to screen for CF.

(Choice B) Cyclic nucleotide-gated ion channels are important for photoreceptor and olfactory receptor neurons. These nonselective channels are directly activated by cyclic nucleotides (eg, cyclic adenosine monophosphate [cAMP]). In contrast, CFTR channels are modulated by cAMP-dependent phosphorylation, but they are not directly gated by cAMP binding.

(Choice C) Mechanically gated (or stretch-activated) channels are ion channels that open in response to mechanical deformation of a cell membrane. Touch and hearing depend on mechanically activated channel transduction of mechanical force into electrochemical signals.

(Choice D) Temperature-gated ion channels open in response to heat and are responsible for human sensation of external temperature.

(Choice E) Voltage-gated ion channels open and close in response to changes in electrical membrane potential and are permeable to various ions. Congenital long QT syndrome is caused by a mutation in a voltage-gated potassium channel.

https://t.me/USMLEWorldStep1
Show all

reach the membrane. This leads to **thick mucus** on the lining of epithelial cells, which results in clinical manifestations of chronic cough, recurrent pneumonias, and pancreatic damage.

The normal CFTR protein also plays a role in the production of hypotonic sweat. In the eccrine gland, sweat is initially isotonic with the plasma, and normally sodium chloride is removed from the ductal lumen by CFTR. In the absence of functional CFTR, patients with CF cannot remove salt from their sweat and therefore have **elevated sweat chloride** and sodium levels. As early as the 17th century, increased mortality was recognized for children whose foreheads tasted salty. Today, the sweat chloride test is frequently used to screen for CF.

(Choice B) Cyclic nucleotide-gated ion channels are important for photoreceptor and olfactory receptor neurons. These nonselective channels are directly activated by cyclic nucleotides (eg, cyclic adenosine monophosphate [cAMP]). In contrast, CFTR channels are modulated by cAMP-dependent phosphorylation, but they are not directly gated by cAMP binding.

(Choice C) Mechanically gated (or stretch-activated) channels are ion channels that open in response to mechanical deformation of a cell membrane. Touch and hearing depend on mechanically activated channel transduction of mechanical force into electrochemical signals.

(Choice D) Temperature-gated ion channels open in response to heat and are responsible for human sensation of external temperature.

(Choice E) Voltage-gated ion channels open and close in response to changes in electrical membrane potential and are permeable to various ions. Congenital long QT syndrome is caused by a mutation in a voltage-gated potassium channel.

Educational objective:
Cystic fibrosis is an autosomal recessive disease caused by mutations in the CF transmembrane conductance regulator (*CFTR*) gene. The CFTR protein is a transmembrane ATP-gated chloride channel. Defects in CFTR result in thick, plugging mucous and elevated sodium and chloride levels in sweat.

References

- Targeting ion channels in cystic fibrosis

https://t.me/USMLEWorldStep1
Show all

Several residents of a long-term care facility develop febrile illness within a short period of time. Symptoms include fever, nonproductive cough, myalgia, rigors, dyspnea, and diarrhea. Organisms found in induced sputum samples stain poorly with Gram stain but are visualized easily using silver stain. Urine testing for bacterial antigens is positive in most of the affected individuals. Which of the following is the most likely source of this outbreak?

- A. Anterior nares of colonized staff
- B. Building water-distribution system
- C. Contaminated ready-to-eat food
- D. Nasopharynx of infected resident
- E. Skin flora of affected residents

Submit

https://t.me/USMLEWorldStep1
Show all

Several residents of a long-term care facility develop febrile illness within a short period of time. Symptoms include fever, nonproductive cough, myalgia, rigors, dyspnea, and diarrhea. Organisms found in induced sputum samples stain poorly with Gram stain but are visualized easily using silver stain. Urine testing for bacterial antigens is positive in most of the affected individuals. Which of the following is the most likely source of this outbreak?

- ✗ A. Anterior nares of colonized staff (2%)
- ✓ B. Building water-distribution system (85%)
- C. Contaminated ready-to-eat food (4%)
- D. Nasopharynx of infected resident (6%)
- E. Skin flora of affected residents (0%)

Incorrect
Correct answer
B

85%
Answered correctly

04 secs
Time Spent

2023
Version

Explanation

Characteristics of *Legionella* pneumonia	
Exposure to contaminated water	• Recent travel (especially cruise/hotel visit) • Hospital/nursing home stay
Clinical findings	• Fever >39 C (102.2 F) • Bradycardia relative to high fever • Headache & confusion • Watery diarrhea

https://t.me/USMLEWorldStep1
Show all

Characteristics of *Legionella* pneumonia	
Exposure to contaminated water	• Recent travel (especially cruise/hotel visit) • Hospital/nursing home stay
Clinical findings	• Fever >39 C (102.2 F) • Bradycardia relative to high fever • Headache & confusion • Watery diarrhea
Laboratory findings	• Hyponatremia • Sputum Gram stain shows many neutrophils but few or no organisms
Diagnosis	• Culture of organism on BCYE • *Legionella* urine antigen test
BCYE = buffered charcoal yeast extract.	

Legionella pneumophila is a thin, pleomorphic, gram-negative rod that stains poorly with Gram stain and does not grow in traditional agar. Detection of the pathogen is typically made with **urine antigen testing**, but the organism can also be visualized with silver stain and grown on buffered charcoal yeast extract agar supplemented with L-cysteine and iron (ground-glass colonies). *L pneumophila* has a strong affinity for the lung (hence the name *pneumophila*) and typically causes a **multifocal pneumonia** that is preceded by nonspecific symptoms (eg, high fever, myalgia, headache) and diarrhea.

L pneumophila is a frequent contaminant of natural bodies of water, municipal **water supplies**, and water-based **cooling systems** found in commercial and hospital settings. **Aerosolization** and subsequent inhalation of contaminated water can lead to **outbreaks** of *Legionella* pneumonia. Common nosocomial sources of infection include showers/baths, cooling towers, nasogastric tubes, ventilators, nebulizers, and other respiratory therapy

https://t.me/USMLEWorldStep1
Show all

Diagnosis	• *Legionella* urine antigen test

BCYE = buffered charcoal yeast extract.

Legionella pneumophila is a thin, pleomorphic, gram-negative rod that stains poorly with Gram stain and does not grow in traditional agar. Detection of the pathogen is typically made with **urine antigen testing**, but the organism can also be visualized with silver stain and grown on buffered charcoal yeast extract agar supplemented with L-cysteine and iron (ground-glass colonies). *L pneumophila* has a strong affinity for the lung (hence the name *pneumophila*) and typically causes a **multifocal pneumonia** that is preceded by nonspecific symptoms (eg, high fever, myalgia, headache) and diarrhea.

L pneumophila is a frequent contaminant of natural bodies of water, municipal **water supplies**, and water-based **cooling systems** found in commercial and hospital settings. **Aerosolization** and subsequent inhalation of contaminated water can lead to **outbreaks** of *Legionella* pneumonia. Common nosocomial sources of infection include showers/baths, cooling towers, nasogastric tubes, ventilators, nebulizers, and other respiratory therapy equipment. Cigarette smoking and chronic lung disease increase the risk for infection.

(Choice A) *Staphylococcus aureus* colonizes the anterior nares and can spread from asymptomatic carriers to hospitalized patients or other individuals. Although methicillin-resistant *S aureus* can cause severe, rapidly progressive pneumonia, the organism appears as gram-positive cocci in clusters.

(Choice C) *Listeria* can be transmitted by contaminated ready-to-eat food. It is associated with febrile diarrhea and is poorly visualized by Gram stain. However, the diagnosis is usually made by visualizing the organism on light microscopy (tumbling motility) or identifying it on blood or cerebrospinal fluid culture. It is not typically identified by sputum sample silver stain or urine antigen testing.

(Choice D) Influenza colonizes the nasopharynx, and outbreaks are common in long-term care facilities and other cohabitated settings. Although influenza often causes nonspecific symptoms (eg, myalgia, malaise, fever) and cough, the virus is typically diagnosed by antigen testing from a nasopharyngeal swab.

(Choice E) Widespread use of long-term intravascular devices increases the risk of catheter-related bacteremia

https://t.me/USMLEWorldStep1
Show all

pneumophila) and typically causes a **multifocal pneumonia** that is preceded by nonspecific symptoms (eg, high fever, myalgia, headache) and diarrhea.

L pneumophila is a frequent contaminant of natural bodies of water, municipal **water supplies**, and water-based **cooling systems** found in commercial and hospital settings. **Aerosolization** and subsequent inhalation of contaminated water can lead to **outbreaks** of *Legionella* pneumonia. Common nosocomial sources of infection include showers/baths, cooling towers, nasogastric tubes, ventilators, nebulizers, and other respiratory therapy equipment. Cigarette smoking and chronic lung disease increase the risk for infection.

(Choice A) *Staphylococcus aureus* colonizes the anterior nares and can spread from asymptomatic carriers to hospitalized patients or other individuals. Although methicillin-resistant *S aureus* can cause severe, rapidly progressive pneumonia, the organism appears as gram-positive cocci in clusters.

(Choice C) *Listeria* can be transmitted by contaminated ready-to-eat food. It is associated with febrile diarrhea and is poorly visualized by Gram stain. However, the diagnosis is usually made by visualizing the organism on light microscopy (tumbling motility) or identifying it on blood or cerebrospinal fluid culture. It is not typically identified by sputum sample silver stain or urine antigen testing.

(Choice D) Influenza colonizes the nasopharynx, and outbreaks are common in long-term care facilities and other cohabitated settings. Although influenza often causes nonspecific symptoms (eg, myalgia, malaise, fever) and cough, the virus is typically diagnosed by antigen testing from a nasopharyngeal swab.

(Choice E) Widespread use of long-term intravascular devices increases the risk of catheter-related bacteremia and sepsis with skin flora such as coagulase-negative staphylococci and *S aureus*. Bacteremia is typically identified by Gram stain and culture of peripheral blood.

Educational objective:
Legionella pneumophila commonly contaminates natural bodies of water, municipal water supplies, and water-based cooling systems. The organism is inhaled in aerosolized water and establishes infection via the pulmonary route. Diagnosis is generally made by urine antigen testing, silver stain, or culture on buffered charcoal yeast extract agar supplemented with L-cysteine and iron.

https://t.me/USMLEWorldStep1
Show all

A 32-year-old man is hospitalized due to nausea, vomiting, and severe abdominal pain. He has a history of heavy alcohol use and was admitted to the hospital for acute pancreatitis a year ago. He has continued to drink alcohol since his last hospitalization and had a party last weekend, during which he consumed an entire 750-mL bottle of liquor. Temperature is 38.3 C (100.9 F), blood pressure is 110/80 mm Hg, pulse is 104/min, and respirations are 20/min. Abdominal examination is notable for marked tenderness in the epigastric region. Serum lipase is 2,392 U/L. The patient is admitted and started on intravenous fluids, analgesics, and antiemetics with subsequent improvement in his symptoms. His vital signs remain stable with adequate urine output. However, on the second day of hospitalization, the patient develops progressive shortness of breath and hypoxemia. Chest x-ray reveals new bilateral opacities. Which of the following parameters is most likely to be normal in this patient?

- A. Capillary permeability
- B. Lung compliance
- C. Pulmonary capillary wedge pressure
- D. Ventilation/perfusion matching
- E. Work of breathing

Submit

https://t.me/USMLEWorldStep1
Show all

A 32-year-old man is hospitalized due to nausea, vomiting, and severe abdominal pain. He has a history of heavy alcohol use and was admitted to the hospital for acute pancreatitis a year ago. He has continued to drink alcohol since his last hospitalization and had a party last weekend, during which he consumed an entire 750-mL bottle of liquor. Temperature is 38.3 C (100.9 F), blood pressure is 110/80 mm Hg, pulse is 104/min, and respirations are 20/min. Abdominal examination is notable for marked tenderness in the epigastric region. Serum lipase is 2,392 U/L. The patient is admitted and started on intravenous fluids, analgesics, and antiemetics with subsequent improvement in his symptoms. His vital signs remain stable with adequate urine output. However, on the second day of hospitalization, the patient develops progressive shortness of breath and hypoxemia. Chest x-ray reveals new bilateral opacities. Which of the following parameters is most likely to be normal in this patient?

- A. Capillary permeability (10%)
- ✗ B. Lung compliance (24%)
- ✓ C. Pulmonary capillary wedge pressure (53%)
- D. Ventilation/perfusion matching (8%)
- E. Work of breathing (3%)

Incorrect
Correct answer
C

53%
Answered correctly

03 secs
Time Spent

2023
Version

Explanation

Acute respiratory distress syndrome	
Risk factors	• Sepsis, pneumonia • Trauma

https://t.me/USMLEWorldStep1
Show all

Acute respiratory distress syndrome	
Risk factors	• Sepsis, pneumonia • Trauma • Pancreatitis
Pathophysiology	• Cytokine release, endothelial activation • Neutrophil recruitment & degranulation in lung • ↑ Capillary permeability, alveolar fluid accumulation • Formation of hyaline membrane
Clinical features	• Hypoxia • Bilateral pulmonary infiltrates • Normal pulmonary capillary wedge pressure (6-12 mm Hg)

This patient with **pancreatitis** (abdominal pain, elevated lipase, recent heavy alcohol intake) has developed hypoxic respiratory failure with bilateral pulmonary infiltrates. In a young patient without a history of cardiac disease, this is highly suggestive of **acute respiratory distress syndrome** (ARDS). Direct (eg, irritant chemicals, trauma, gastric aspiration) or indirect (eg, pancreatitis, sepsis) pulmonary insults cause excessive cytokine release, leading to endothelial activation, neutrophilic migration to the lungs, and degranulation with release of toxic mediators. This process worsens the pulmonary alveolar and endothelial injury, leading to **increased pulmonary capillary permeability**, leakage of fluid into the alveoli, and pulmonary edema **(Choice A)**.

ARDS-associated interstitial edema and hyaline membrane formation along with fluid-filled alveoli collapse and atelectasis result in **decreased lung compliance** and increased work of breathing **(Choices B and E)**. The fluid-filled, collapsed alveoli are unable to deliver oxygen despite continuing to receive adequate blood flow, resulting in **ventilation/perfusion mismatch** (ie, physiologic shunting) and hypoxia **(Choice D)**.

Noncardiogenic pulmonary edema (eg, ARDS, high-altitude pulmonary edema) can be distinguished from

https://t.me/USMLEWorldStep1
Show all

Clinical features	• Hypoxia • Bilateral pulmonary infiltrates • Normal pulmonary capillary wedge pressure (6-12 mm Hg)

This patient with **pancreatitis** (abdominal pain, elevated lipase, recent heavy alcohol intake) has developed hypoxic respiratory failure with bilateral pulmonary infiltrates. In a young patient without a history of cardiac disease, this is highly suggestive of **acute respiratory distress syndrome** (ARDS). Direct (eg, irritant chemicals, trauma, gastric aspiration) or indirect (eg, pancreatitis, sepsis) pulmonary insults cause excessive cytokine release, leading to endothelial activation, neutrophilic migration to the lungs, and degranulation with release of toxic mediators. This process worsens the pulmonary alveolar and endothelial injury, leading to **increased pulmonary capillary permeability**, leakage of fluid into the alveoli, and pulmonary edema **(Choice A)**.

ARDS-associated interstitial edema and hyaline membrane formation along with fluid-filled alveoli collapse and atelectasis result in **decreased lung compliance** and increased work of breathing **(Choices B and E)**. The fluid-filled, collapsed alveoli are unable to deliver oxygen despite continuing to receive adequate blood flow, resulting in **ventilation/perfusion mismatch** (ie, physiologic shunting) and hypoxia **(Choice D)**.

Noncardiogenic pulmonary edema (eg, ARDS, high-altitude pulmonary edema) can be distinguished from cardiogenic pulmonary edema (eg, decompensated left ventricular failure, volume overload) by a **normal pulmonary capillary wedge pressure** (6-12 mm Hg). Other distinguishing features include the clinical history (pneumonia/sepsis or pancreatitis suggests ARDS) and physical exam (peripheral edema and jugular venous distension suggest a cardiogenic source).

Educational objective:
Acute respiratory distress syndrome is characterized by hypoxia and bilateral pulmonary infiltrates and is associated with pneumonia, sepsis, trauma, and pancreatitis. The associated pulmonary edema is noncardiogenic in nature, so the pulmonary capillary wedge pressure will be within the normal range (6-12 mm Hg).

Pathology | Pulmonary & Critical Care | ARDS

https://t.me/USMLEWorldStep1
Show all

- Hypoxia

This p
hypoxi
diseas
trauma
leadin
media
capill

ARDS
atelec
filled,
ventil

Nonca
cardio
pulmo
(pneur
distens

Educa
Acute
associ
in natu

Pathol

Exhibit Display

Acute respiratory distress syndrome

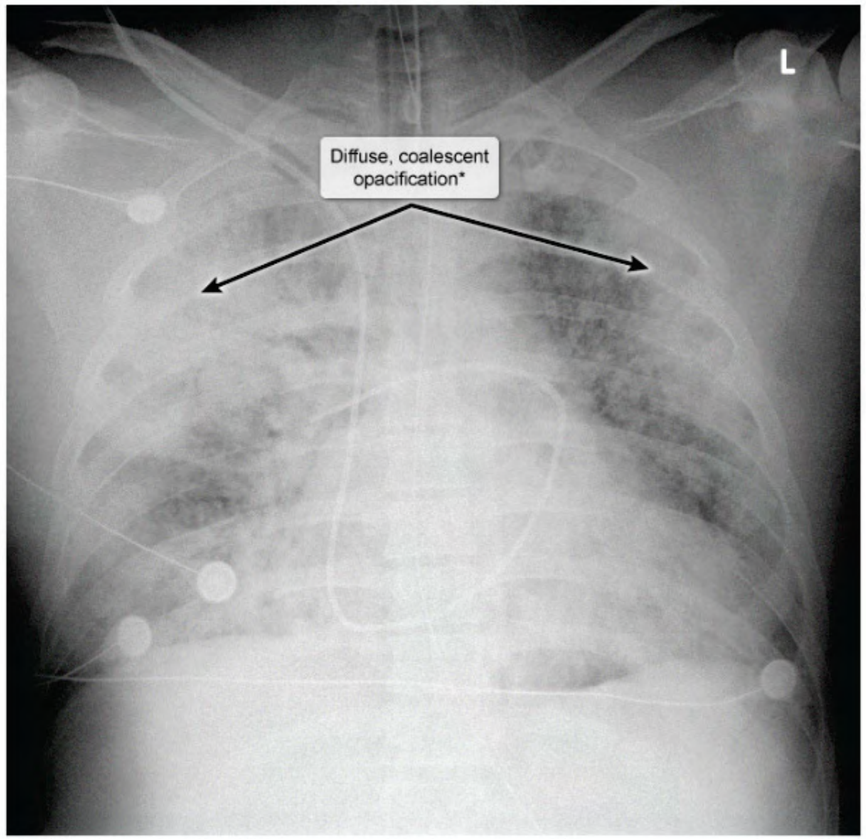

*Exudate due to diffuse alveolar endothelial damage (eg, sepsis, pneumonia, trauma)

©UWorld

Zoom In | Zoom Out | Reset | New | Existing | My Notebook

https://t.me/USMLEWorldStep1

An outbreak of infection with a seasonal influenza A strain is reported in a small community. The strain is similar to the one that circulated in the preceding year. Approximately 70% of the adult population in that community remains uninfected, despite prolonged and repeated exposure to ill contacts. Which of the following is the most important host factor in preventing influenza infection in these subjects?

- A. Antibodies against hemagglutinin
- B. Antibodies against neuraminidase
- C. Antibodies against RNA polymerase
- D. Antigen-nonspecific macrophage response
- E. T-cell response against nucleocapsid proteins

Submit

https://t.me/USMLEWorldStep1
Show all

An outbreak of infection with a seasonal influenza A strain is reported in a small community. The strain is similar to the one that circulated in the preceding year. Approximately 70% of the adult population in that community remains uninfected, despite prolonged and repeated exposure to ill contacts. Which of the following is the most important host factor in preventing influenza infection in these subjects?

- ✓ A. Antibodies against hemagglutinin (54%)
- ✗ B. Antibodies against neuraminidase (23%)
- C. Antibodies against RNA polymerase (3%)
- D. Antigen-nonspecific macrophage response (2%)
- E. T-cell response against nucleocapsid proteins (15%)

Incorrect
Correct answer
A

54%
Answered correctly

01 min, 58 secs
Time Spent

2023
Version

Explanation

In this question, 70% of the adult population in a small community with an influenza A outbreak are uninfected, because they are protected either through vaccination or from prior influenza A infection (with a similar strain). A **humoral** response with antibodies directed against **hemagglutinin** is generally the most important source of protection. These antibodies can neutralize the virus and primarily block its binding to the host cells. Antibodies to neuraminidase are not the main source of protection against reinfection although they have some protective effect (decrease extent of viral invasion and shedding) **(Choice B)**.

(Choices C and D) Circulating antibodies to internal influenza virus proteins (including the viral RNA-dependent RNA polymerase) do not confer immunity. Innate immunity (eg, antigen-nonspecific macrophage responses) does

https://t.me/USMLEWorldStep1
Show all

Explanation

In this question, 70% of the adult population in a small community with an influenza A outbreak are uninfected, because they are protected either through vaccination or from prior influenza A infection (with a similar strain). A **humoral** response with antibodies directed against **hemagglutinin** is generally the most important source of protection. These antibodies can neutralize the virus and primarily block its binding to the host cells. Antibodies to neuraminidase are not the main source of protection against reinfection although they have some protective effect (decrease extent of viral invasion and shedding) **(Choice B)**.

(Choices C and D) Circulating antibodies to internal influenza virus proteins (including the viral RNA-dependent RNA polymerase) do not confer immunity. Innate immunity (eg, antigen-nonspecific macrophage responses) does not appear to prevent primary influenza infection or reinfection. Reinfection is best prevented by adaptive immune mechanisms, which are by definition antigen-specific.

(Choice E) Cytotoxic CD8+ T cells specific for the major histocompatibility complex (MHC) class I-associated peptides derived from nucleocapsid proteins can kill infected cells and limit disease severity but are not thought to prevent infection. Expression of nucleocapsid proteins on MHC class II stimulates a CD4+ Th1-type T cell response (which stimulates CD8+ cell production through cytokines) and a CD4+ Th2-type T cell response. The Th2-type T cell response generates anti-nucleocapsid antibodies that do not appear to play a role in protective immunity.

Educational objective:
Major adaptive immune mechanisms that prevent reinfection with the influenza virus include anti-hemagglutinin antibodies.

Microbiology	Pulmonary & Critical Care	Influenza
Subject	System	Topic

Copyright © UWorld. All rights reserved.

https://t.me/USMLEWorldStep1
Show all

A 64-year-old man is brought to the emergency department after a motor vehicle collision in which his chest hit the steering wheel. The patient has no prior medical conditions and takes no medications. Temperature is 36.7 C (98 F), blood pressure is 132/78 mm Hg, pulse is 76/min, and respirations are 14/min. Physical examination shows mild tenderness over the lower right chest. Imaging of the neck and chest reveals no fractures or dislocations. However, the chest CT scan reveals pleural opacities as shown below.

These abnormal findings are most likely to occur in a patient with which of the following occupational histories?

- A. Aerospace manufacturing
- B. Coal mining
- C. Insulation manufacturing
- D. Hay farming
- E. Petroleum processing/refining
- F. Sandblasting

Submit

https://t.me/USMLEWorldStep1

A 64-year-old man is brought to the emergency department after a motor vehicle collision in which his chest hit the steerin
F), blo
mild te
Howev

Exhibit Display

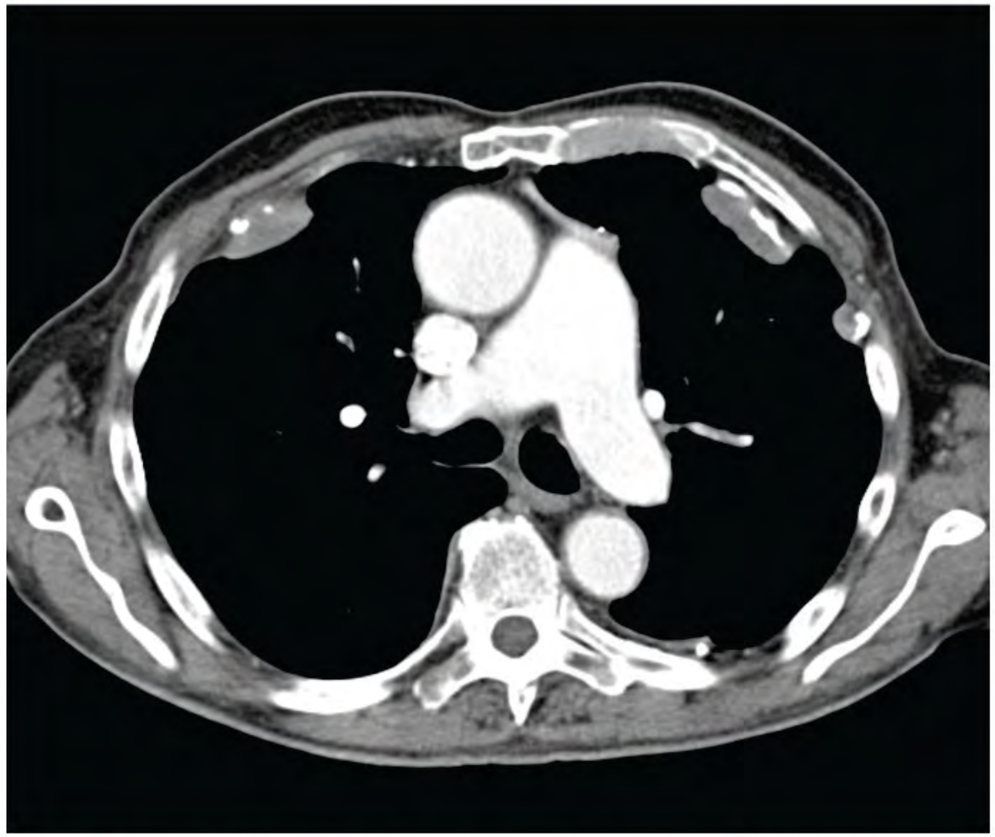

Zoom In Zoom Out Reset New | Existing My Notebook

These abnormal findings are most likely to occur in a patient with which of the following occupational histories?

https://t.me/USMLEWorldStep1
Show all

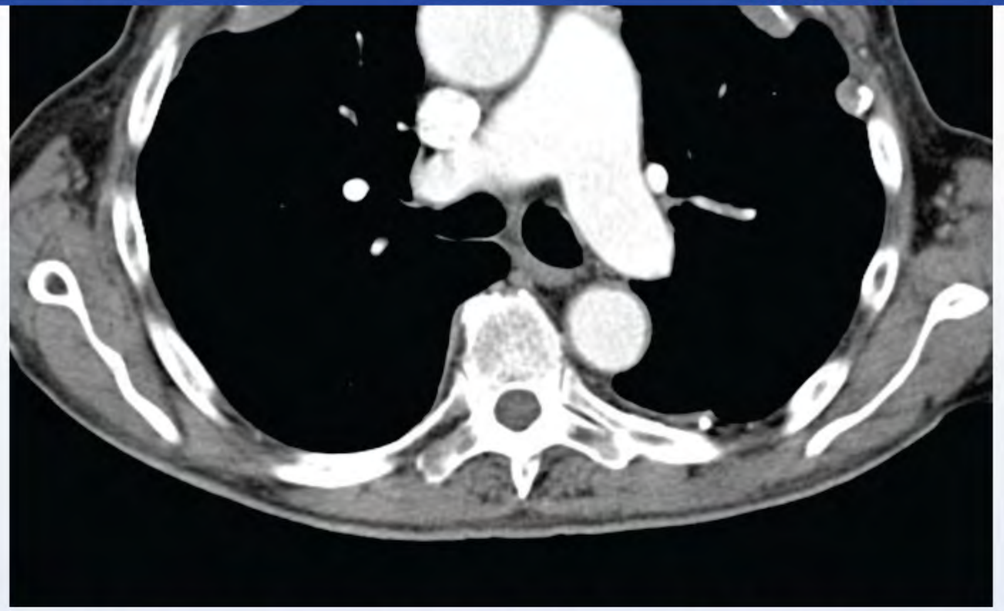

These abnormal findings are most likely to occur in a patient with which of the following occupational histories?

- A. Aerospace manufacturing
- B. Coal mining
- C. Insulation manufacturing
- D. Hay farming
- E. Petroleum processing/refining
- F. Sandblasting

Submit

https://t.me/USMLEWorldStep1
Show all

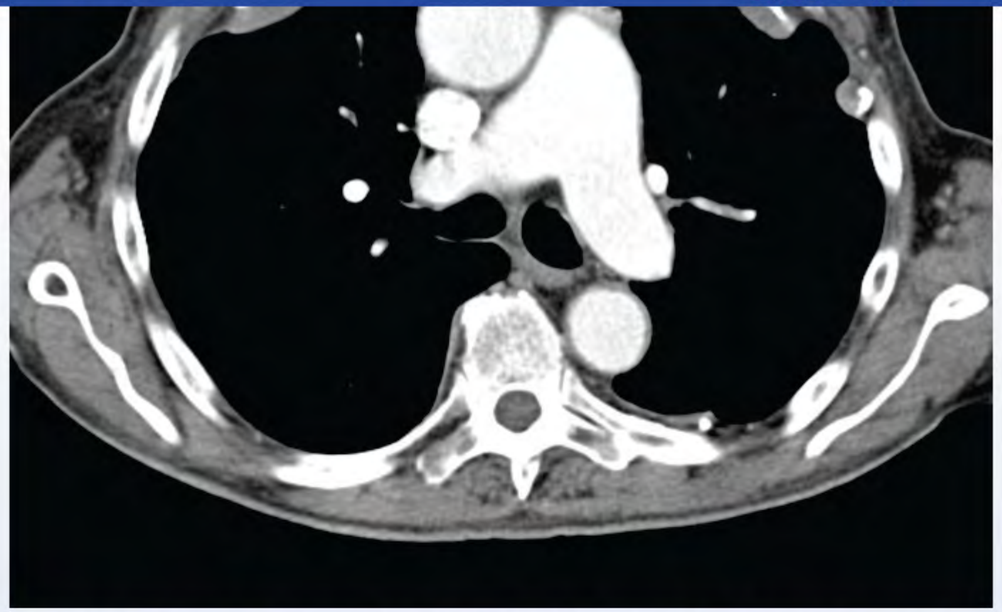

These abnormal findings are most likely to occur in a patient with which of the following occupational histories?

- A. Aerospace manufacturing (7%)
- ✗ B. Coal mining (7%)
- ✓ C. Insulation manufacturing (64%)
- D. Hay farming (2%)
- E. Petroleum processing/refining (1%)
- F. Sandblasting (16%)

Incorrect
Correct answer
C

64%
Answered correctly

11 secs
Time Spent

2023
Version

https://t.me/USMLEWorldStep1

Expl

Exhibit Display

Asbestosis

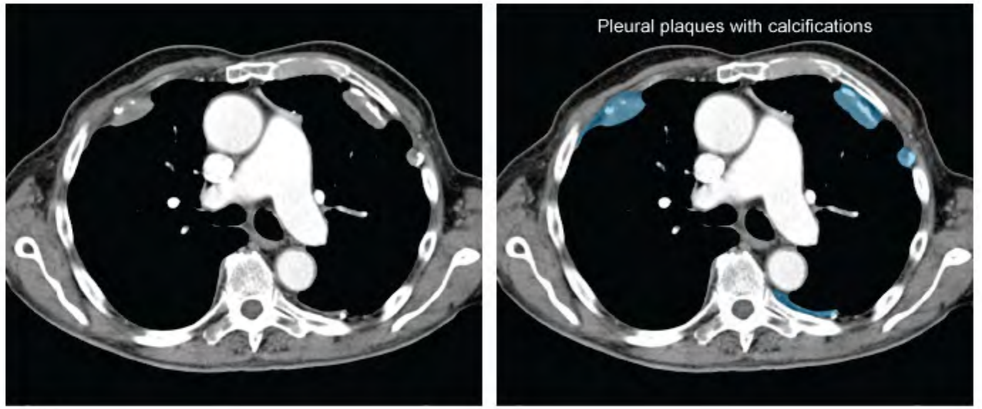

©UWorld

Zoom In Zoom Out Reset New | Existing My Notebook

This C
with **ca**
inflam
coveri
occur.

Some
fibros
manife

Asbes
shipbuilding, drywall workers). There is usually a **20-30 year latent period** between asbestos exposure and onset

https://t.me/USMLEWorldStep1

©UWorld

This CT scan demonstrates an incidental finding of **pleural plaques** (focal or band-like pleural thickening, often with **calcifications**). Pleural plaques are a hallmark of **asbestos** exposure; inhaled fibers result in chronic inflammation and collagen deposition within the pleura. They occur most commonly along the parietal pleura covering the ribs and diaphragm. Diffuse pleural thickening, benign pleural effusions, and mesothelioma can also occur.

Some patients eventually develop asbestosis, which presents with slowly progressive, diffuse **pulmonary fibrosis**. Interstitial lung injury due to fiber inhalation predominantly affects the lower pulmonary zones and manifests radiographically as interstitial densities that predominate in the lung bases.

Asbestos exposure typically occurs during occupational exposure (eg, **insulation manufacturing** and application, shipbuilding, drywall workers). There is usually a **20-30 year latent period** between asbestos exposure and onset of symptoms.

(Choice A) Beryllium is used in the aerospace manufacturing and nuclear weapon industries. Pulmonary berylliosis closely resembles sarcoidosis (nodular infiltrates, enlarged lymph nodes, noncaseating granulomas) but is not strongly associated with pleural plaques.

(Choice B) Coal worker's pneumoconiosis presents radiologically as multiple small, discrete nodules that are most prominent in the upper lung zones. Pleural plaques are not typical.

(Choice D) Hypersensitivity pneumonitis due to inhalation of agricultural dusts or bacteria (eg, farmer's lung) tends to result in diffuse, nodular interstitial infiltrates; pleural plaques are unexpected.

(Choice E) Petroleum processing can result in exposure to sulfur oxides and aromatic hydrocarbons; these can cause occupational asthma and (rarely) bronchiolitis obliterans, which result in air trapping and bronchial wall thickening (as opposed to the pleural thickening seen in asbestos exposure).

(Choice F) Silicosis is most common in patients with a history of sandblasting or mining. Numerous upper lobe

https://t.me/USMLEWorldStep1
Show all

covering the ribs and diaphragm. Diffuse pleural thickening, benign pleural effusions, and mesothelioma can also occur.

Some patients eventually develop asbestosis, which presents with slowly progressive, diffuse **pulmonary fibrosis**. Interstitial lung injury due to fiber inhalation predominantly affects the lower pulmonary zones and manifests radiographically as interstitial densities that predominate in the lung bases.

Asbestos exposure typically occurs during occupational exposure (eg, **insulation manufacturing** and application, shipbuilding, drywall workers). There is usually a **20-30 year latent period** between asbestos exposure and onset of symptoms.

(Choice A) Beryllium is used in the aerospace manufacturing and nuclear weapon industries. Pulmonary berylliosis closely resembles sarcoidosis (nodular infiltrates, enlarged lymph nodes, noncaseating granulomas) but is not strongly associated with pleural plaques.

(Choice B) Coal worker's pneumoconiosis presents radiologically as multiple small, discrete nodules that are most prominent in the upper lung zones. Pleural plaques are not typical.

(Choice D) Hypersensitivity pneumonitis due to inhalation of agricultural dusts or bacteria (eg, farmer's lung) tends to result in diffuse, nodular interstitial infiltrates; pleural plaques are unexpected.

(Choice E) Petroleum processing can result in exposure to sulfur oxides and aromatic hydrocarbons; these can cause occupational asthma and (rarely) bronchiolitis obliterans, which result in air trapping and bronchial wall thickening (as opposed to the pleural thickening seen in asbestos exposure).

(Choice F) Silicosis is most common in patients with a history of sandblasting or mining. Numerous upper lobe nodular densities and eggshell calcifications of the hilar nodes are seen; pleural plaques are unexpected.

Educational objective:
Asbestos-related pleural disease is characterized by pleural plaques (focal pleural thickening, typically with calcifications). Common occupational exposures include shipbuilding, insulation manufacturing and application, and drywall application. Most affected patients remain asymptomatic for 20-30 years following initial exposure.

https://t.me/USMLEWorldStep1
Show all

Exhibit Display

Asbestosis

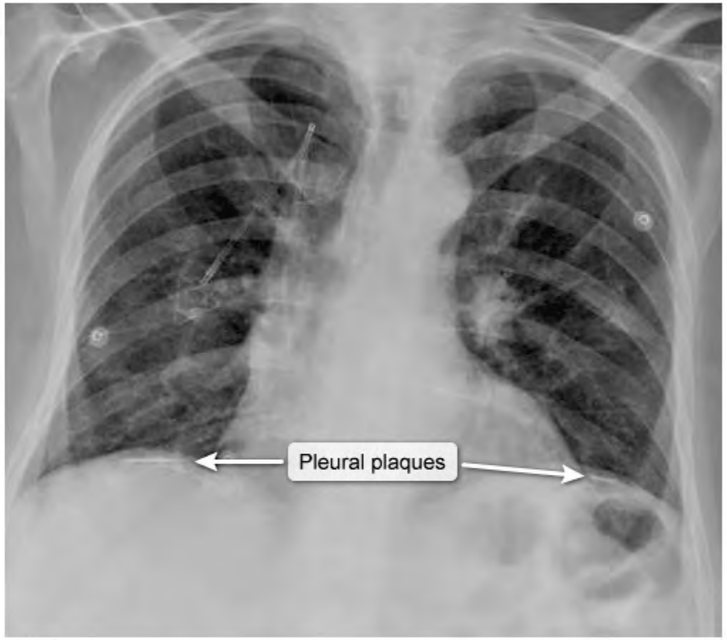

©UWorld

Zoom In | Zoom Out | Reset | New | Existing | My Notebook

This C
with **ca**
inflam
coveri
occur.

Some
fibros
manife

Asbes
shipbu
of sym

(Choic
berylli
is not

(Choice B) Coal worker's pneumoconiosis presents radiologically as multiple small, discrete nodules that are most

https://t.me/USMLEWorldStep1

Pleural plaques with calcifications

Exhibit Display

Zoom In | Zoom Out | Reset | New | Existing | My Notebook

This C
with **ca**
inflam
coveri
occur.

Some
fibros
manife

Asbes
shipbu
of sym

(Choic
berylli
is not

(Choice B) Coal worker's pneumoconiosis presents radiologically as multiple small, discrete nodules that are most

https://t.me/USMLEWorldStep1

The combined compliance of the lung and chest wall of a healthy individual is measured and plotted as shown below. It is noted that the intrapleural pressure at the end of maximal inspiration is -8 cm H_20 (marked x).

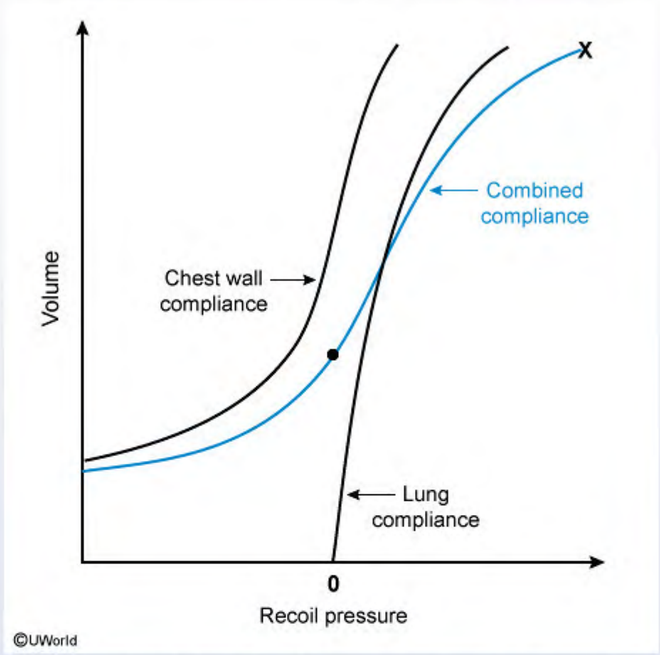

Which of the following is the best estimate of the intrapleural pressure at the point marked by the black dot?

- A. + 10 cm H_2O
- B. + 5 cm H_2O
- C. 0 cm H_2O
- D. - 5 cm H_2O
- E. -10 cm H_2O

https://t.me/USMLEWorldStep1
Show all

The combined compliance of the lung and chest wall of a healthy individual is measured and plotted as shown below.

Exhibit Display

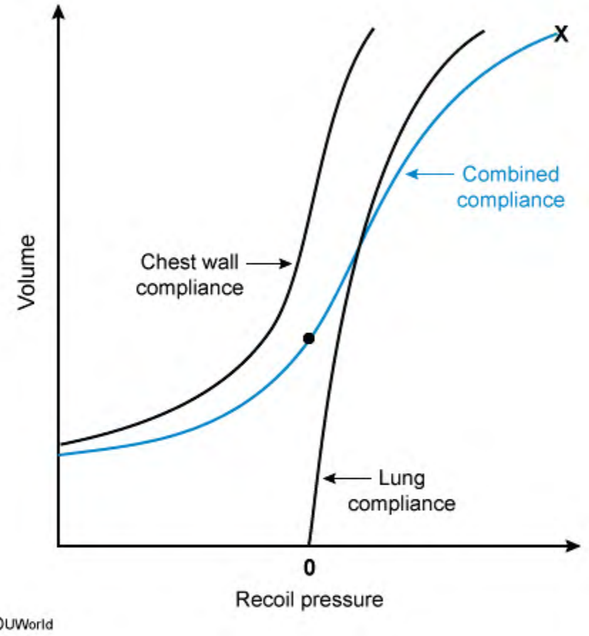

Zoom In | Zoom Out | Reset | New | Existing | My Notebook

Which

E. -10 cm H_2O

https://t.me/USMLEWorldStep1

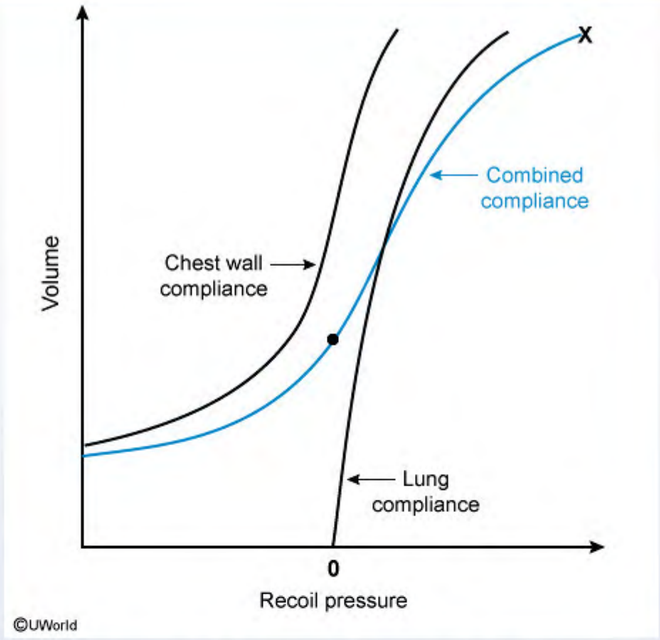

Which of the following is the best estimate of the intrapleural pressure at the point marked by the black dot?

- A. + 10 cm H_2O
- B. + 5 cm H_2O
- C. 0 cm H_2O
- D. - 5 cm H_2O
- E. -10 cm H_2O

Submit

https://t.me/USMLEWorldStep1
Show all

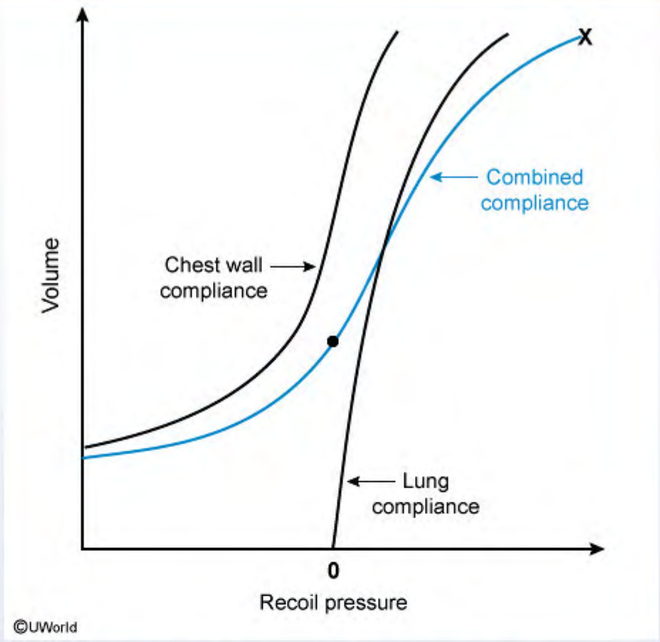

Which of the following is the best estimate of the intrapleural pressure at the point marked by the black dot?

- A. + 10 cm H_2O (1%)
- ✗ B. + 5 cm H_2O (18%)
- C. 0 cm H_2O (28%)
- ✓ D. - 5 cm H_2O (45%)
- E. -10 cm H_2O (5%)

Incorrect
Correct answer
D

45%
Answered correctly

12 secs
Time Spent

2023
Version

https://t.me/USMLEWorldStep1
Show all

Inco
Corre
D

Expl

Exhibit Display

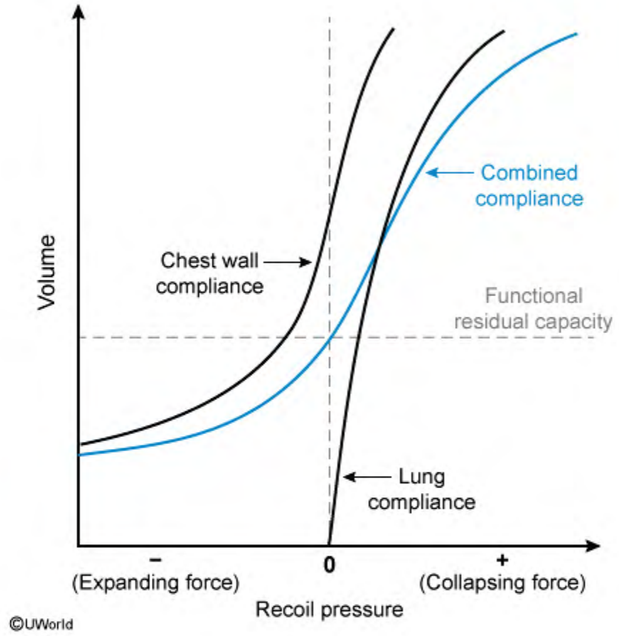

Zoom In Zoom Out Reset New | Existing My Notebook

On the
lungs
region
most of the chest wall curve is located in the negative region. The point where the collapsing force of the lungs is

https://t.me/USMLEWorldStep1
Show all

On the above pressure-volume curve, collapsing pressure is positive and expanding pressure is negative. The **lungs** have a **tendency to collapse** at all lung volumes; therefore, the entire lung curve is located in the positive region. In contrast, the resting **chest wall** has a **tendency to expand** at all but very high lung volumes; therefore, most of the chest wall curve is located in the negative region. The point where the collapsing force of the lungs is equivalent to the expanding force of the chest wall is the **resting equilibrium** of the respiratory system (ie, end-tidal expiration), represented by the black dot); the alveolar pressure at this point is equivalent to atmospheric pressure (ie, 0 cm H_2O) and the lung volume is the **functional residual capacity** (FRC).

Compliance is defined as change in volume per change in pressure and is represented by the slope of the pressure-volume curve. A highly compliant container is able to stretch to accommodate large increases in volume with little change in pressure, demonstrating a steep compliance curve. Generally, lung compliance is greatest around the FRC and decreases at very high and very low lung volumes (note that surface tension causes compliance to differ during inspiration and expiration). The chest wall has low compliance at low lung volumes and becomes more compliant as lung volume increases with inspiration. The compliance of the respiratory system as a whole is the combined compliance of the lungs and chest wall (represented by the blue curve).

Intrapleural pressures are not represented on the lung pressure-volume curve. The expanding force of the chest wall working in opposition to the collapsing force of the lungs creates **negative intrapleural pressure** throughout the respiratory cycle. Inspiration is driven by active expansion of the chest wall, which generates even greater intrapleural negative pressure and pulls the lungs outward. Intrapleural negative pressure peaks at maximal inspiration at a value of approximately -8 cm H_2O. During passive expiration the chest wall relaxes and the respiratory system returns to its equilibrium position, in which intrapleural pressure is approximately **-5 cm H_2O**.

Educational objective:
The lungs generate a collapsing force and the chest wall generates an expanding force; the point at which these opposing forces are equivalent is the resting equilibrium of the respiratory system, where alveolar pressure is equal to atmospheric pressure (ie, 0 cm H_2O) and lung volume is the functional residual capacity. The opposing forces create negative intrapleural pressure throughout the respiratory cycle; intrapleural pressure at resting equilibrium

https://t.me/USMLEWorldStep1
Show all

most of the chest wall curve is located in the negative region. The point where the collapsing force of the lungs is equivalent to the expanding force of the chest wall is the **resting equilibrium** of the respiratory system (ie, end-tidal expiration), represented by the black dot); the alveolar pressure at this point is equivalent to atmospheric pressure (ie, 0 cm H_2O) and the lung volume is the **functional residual capacity** (FRC).

Compliance is defined as change in volume per change in pressure and is represented by the slope of the pressure-volume curve. A highly compliant container is able to stretch to accommodate large increases in volume with little change in pressure, demonstrating a steep compliance curve. Generally, lung compliance is greatest around the FRC and decreases at very high and very low lung volumes (note that surface tension causes compliance to differ during inspiration and expiration). The chest wall has low compliance at low lung volumes and becomes more compliant as lung volume increases with inspiration. The compliance of the respiratory system as a whole is the combined compliance of the lungs and chest wall (represented by the blue curve).

Intrapleural pressures are not represented on the lung pressure-volume curve. The expanding force of the chest wall working in opposition to the collapsing force of the lungs creates **negative intrapleural pressure** throughout the respiratory cycle. Inspiration is driven by active expansion of the chest wall, which generates even greater intrapleural negative pressure and pulls the lungs outward. Intrapleural negative pressure peaks at maximal inspiration at a value of approximately -8 cm H_2O. During passive expiration the chest wall relaxes and the respiratory system returns to its equilibrium position, in which intrapleural pressure is approximately **-5 cm H_2O**.

Educational objective:

The lungs generate a collapsing force and the chest wall generates an expanding force; the point at which these opposing forces are equivalent is the resting equilibrium of the respiratory system, where alveolar pressure is equal to atmospheric pressure (ie, 0 cm H_2O) and lung volume is the functional residual capacity. The opposing forces create negative intrapleural pressure throughout the respiratory cycle; intrapleural pressure at resting equilibrium (ie, end-tidal expiration) is approximately -5 cm H_2O.

References

- Physiology, lung compliance.

https://t.me/USMLEWorldStep1
Show all

compliance

Exhibit Display

On the
lungs
region
most c
equiva
tidal e
pressu

Compl
pressu
with lit
around
compli
becom
whole

Intrap
wall w
the res
intrapl
inspira
respira

Educa
The lu

Lung volumes & capacities

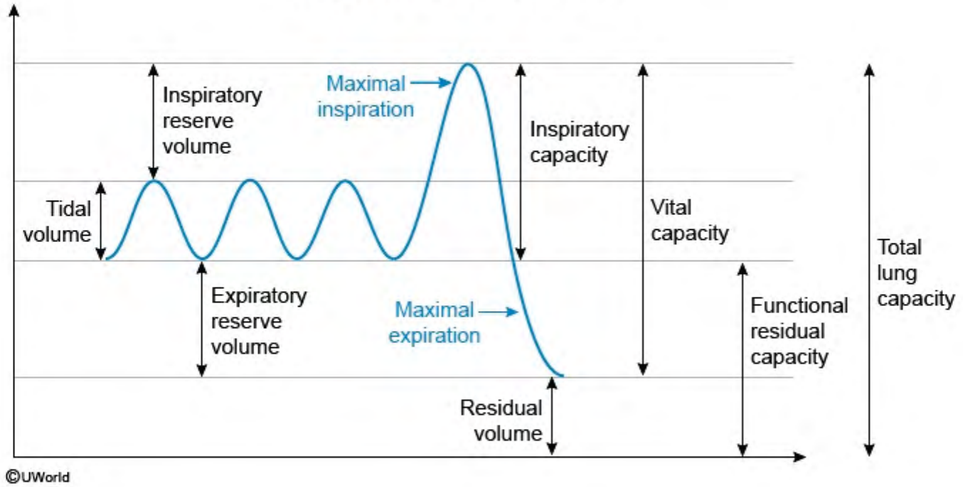

Zoom In | Zoom Out | Reset | New | Existing | My Notebook

https://t.me/USMLEWorldStep1

Show all

compliance

Exhibit Display

On the
lungs
region
most c
equiva
tidal e
pressu

Compl
pressu
with lit
around
compli
becom
whole

Intrap
wall w
the res
intrapl
inspira
respira

Educational objective:
The lungs generate a collapsing force and the chest wall generates an expanding force; the point at which these

Lung compliance hysteresis

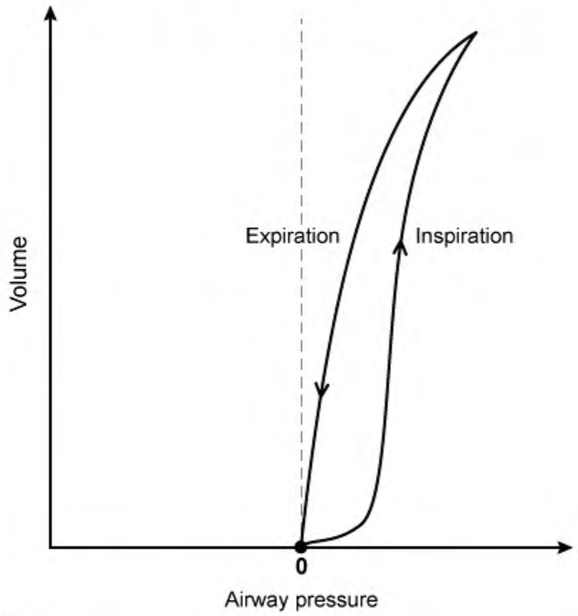

©UWorld

Zoom In | Zoom Out | Reset | New | Existing | My Notebook

https://t.me/USMLEWorldStep1
Show all

compliance

Exhibit Display

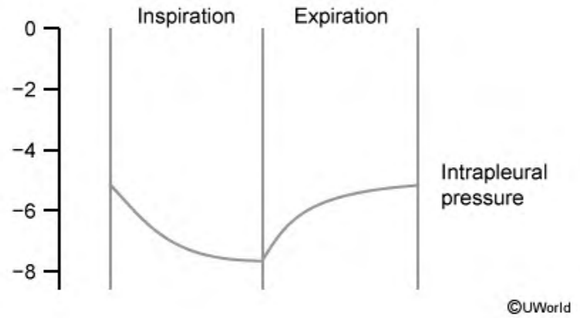

Zoom In | Zoom Out | Reset | New | Existing | My Notebook

On the
lungs
region
most c
equiva
tidal e
pressu

Compl
pressu
with lit
around
compli
becom
whole

Intrap
wall w
the res
intrapl
inspira
respira

Educational objective:
The lungs generate a collapsing force and the chest wall generates an expanding force; the point at which these

https://t.me/USMLEWorldStep1
Show all

A 43-year-old man comes to the office due to malaise, night sweats, and cough for the past several weeks. He has also lost 4.5 kg (10 lb) over the past 4 months. The patient has no appreciable medical history and has not traveled recently. He has spent the last 10 years working as a respiratory therapist at an urban hospital. Chest x-ray is shown below.

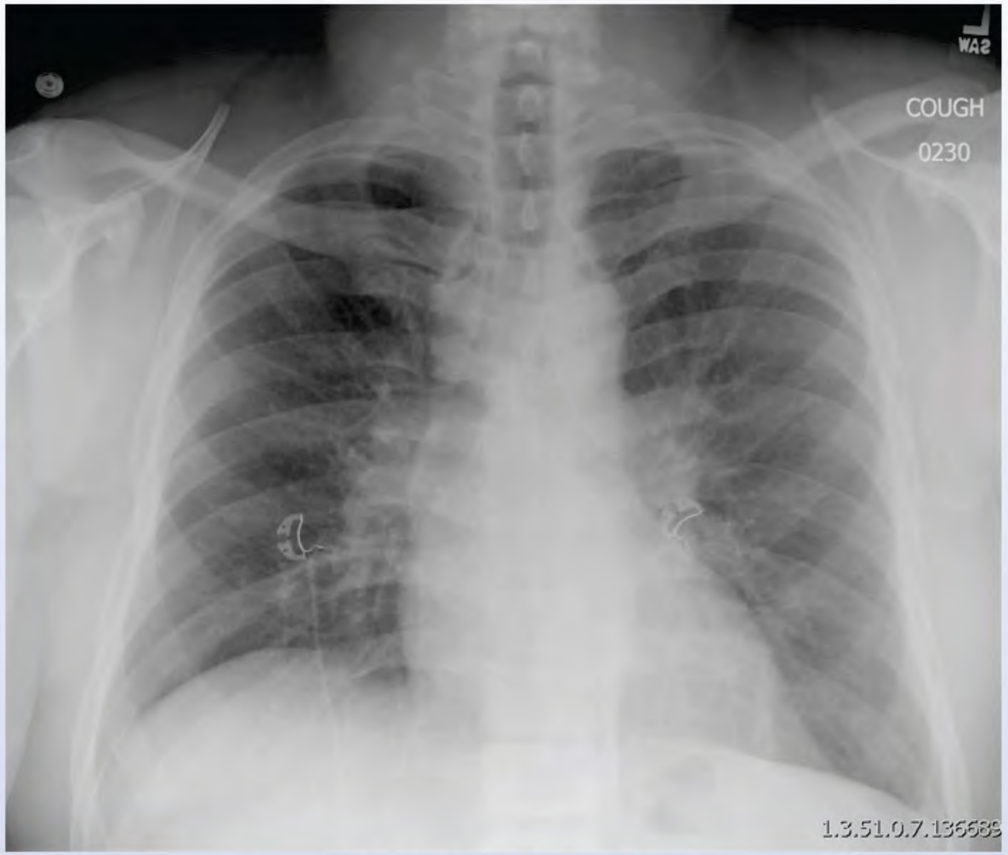

A palpable lymph node in the supraclavicular bed is biopsied and pathology reveals well-formed, noncaseating granulomas. Which of the following is the most likely diagnosis?

https://t.me/USMLEWorldStep1
Show all

A 43-year-old man comes to the office due to malaise, night sweats, and cough for the past several weeks. He has also lo
travele
ray is

Exhibit Display

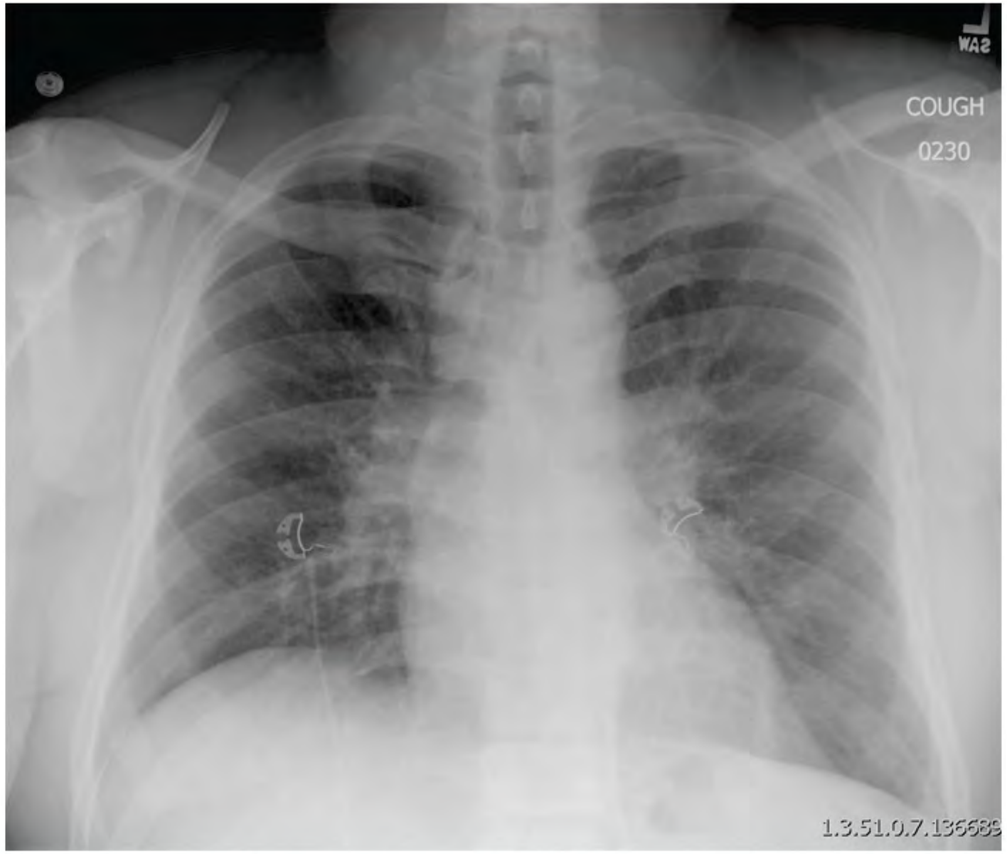

Zoom In | Zoom Out | Reset | New | Existing | My Notebook

A palpable lymph node in the supraclavicular bed is biopsied and pathology reveals well-formed, noncaseating granulomas. Which of the following is the most likely diagnosis?

https://t.me/USMLEWorldStep1
Show all

A palpable lymph node in the supraclavicular bed is biopsied and pathology reveals well-formed, noncaseating granulomas. Which of the following is the most likely diagnosis?

- A. HIV infection
- B. Hodgkin lymphoma
- C. Metastatic adenocarcinoma of the lung
- D. Metastatic squamous cell carcinoma of the lung
- E. *Mycobacterium avium* complex
- F. *Mycobacterium tuberculosis*
- G. Sarcoidosis

Submit

https://t.me/USMLEWorldStep1
Show all

A palpable lymph node in the supraclavicular bed is biopsied and pathology reveals well-formed, noncaseating granulomas. Which of the following is the most likely diagnosis?

- A. HIV infection (1%)
- B. Hodgkin lymphoma (7%)
- ✗ C. Metastatic adenocarcinoma of the lung (3%)
- D. Metastatic squamous cell carcinoma of the lung (1%)
- E. *Mycobacterium avium* complex (3%)
- F. *Mycobacterium tuberculosis* (13%)
- ✓ G. Sarcoidosis (69%)

Incorrect
Correct answer
G

69%
Answered correctly

12 secs
Time Spent

2023
Version

https://t.me/USMLEWorldStep1
Show all

Inco
Corre
G

Expl

Exhibit Display

Sarcoidosis

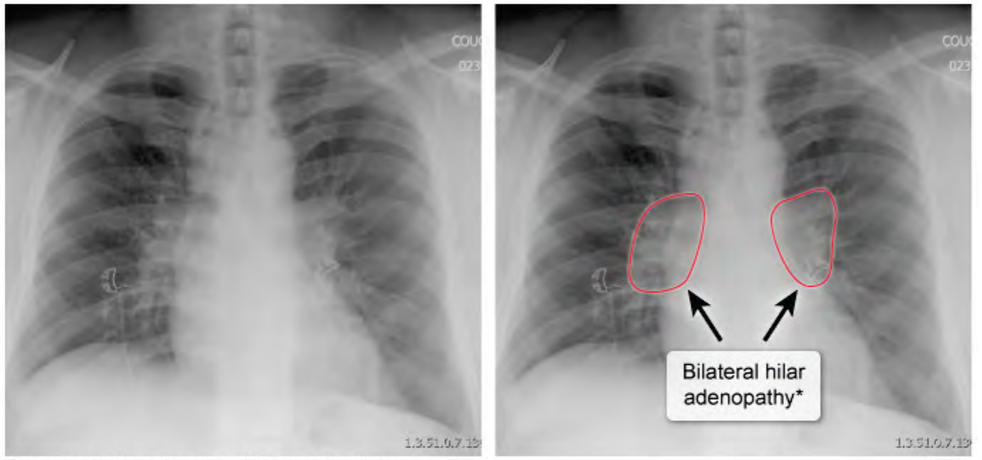

*Noncaseating granuloma and inflammatory cell accumulation

©UWorld

Zoom In | Zoom Out | Reset | New | Existing | My Notebook

This p
inflam
macro
occurs

Any or
hilar adenopathy), skin (erythematous rash), and eyes (eg, anterior uveitis) are often involved. In addition to

https://t.me/USMLEWorldStep1
Show all

This patient with cough, night sweats, and **bilateral hilar adenopathy** likely has **sarcoidosis**, a systemic inflammatory disease characterized by noncaseating granulomas (non-necrotic aggregates of epithelioid macrophages frequently with multinucleated giant cells). It typically presents in young adults (women > men) and occurs more commonly in African Americans.

Any organ can be affected by sarcoidosis; however, the lungs (eg, reticular/nodular infiltrates), lymph nodes (eg, hilar adenopathy), skin (erythematous rash), and eyes (eg, anterior uveitis) are often involved. In addition to pulmonary symptoms (eg, cough, chest pain, dyspnea), **constitutional symptoms** (including fever, **weight loss**, fatigue, night sweats, and arthralgias) are common.

(Choice A) Acute HIV infection can present with constitutional symptoms and weight loss; however, noncaseating granulomas are not consistent with isolated HIV infection and suggest sarcoidosis.

(Choice B) Hodgkin lymphoma can cause supraclavicular adenopathy and B symptoms (eg, weight loss, fever, night sweats); however, biopsy would demonstrate Reed-Sternberg cells surrounded by an inflammatory infiltrate.

(Choices C and D) Adenocarcinoma and squamous cell carcinoma of the lung can cause constitutional symptoms and cough; however, a mass would be expected on imaging. In addition, biopsy of squamous cell carcinoma would show sheets or nests of malignant cells with squamous differentiation (eg, keratinization), whereas adenocarcinoma would show glandular differentiation with atypia.

(Choice E) *Mycobacterium avium* complex can cause similar symptoms with noncaseating (and caseating) granulomas but typically occurs in severely immunocompromised patients. In addition, *Mycobacterium avium* pulmonary disease typically causes cavitations and pulmonary infiltrates on imaging.

(Choice F) Tuberculosis can cause weight loss, cough, and night sweats, particularly in those with risk factors (eg, immunosuppression, imprisonment, immigrants, HIV positive). However, biopsy would typically show caseating granulomas and acid-fast bacilli.

Educational objective:
Sarcoidosis is an inflammatory disorder characterized histologically by noncaseating granulomas consisting of

https://t.me/USMLEWorldStep1
Show all

occurs more commonly in African Americans.

Any organ can be affected by sarcoidosis; however, the lungs (eg, reticular/nodular infiltrates), lymph nodes (eg, hilar adenopathy), skin (erythematous rash), and eyes (eg, anterior uveitis) are often involved. In addition to pulmonary symptoms (eg, cough, chest pain, dyspnea), **constitutional symptoms** (including fever, **weight loss**, fatigue, night sweats, and arthralgias) are common.

(Choice A) Acute HIV infection can present with constitutional symptoms and weight loss; however, noncaseating granulomas are not consistent with isolated HIV infection and suggest sarcoidosis.

(Choice B) Hodgkin lymphoma can cause supraclavicular adenopathy and B symptoms (eg, weight loss, fever, night sweats); however, biopsy would demonstrate Reed-Sternberg cells surrounded by an inflammatory infiltrate.

(Choices C and D) Adenocarcinoma and squamous cell carcinoma of the lung can cause constitutional symptoms and cough; however, a mass would be expected on imaging. In addition, biopsy of squamous cell carcinoma would show sheets or nests of malignant cells with squamous differentiation (eg, keratinization), whereas adenocarcinoma would show glandular differentiation with atypia.

(Choice E) *Mycobacterium avium* complex can cause similar symptoms with noncaseating (and caseating) granulomas but typically occurs in severely immunocompromised patients. In addition, *Mycobacterium avium* pulmonary disease typically causes cavitations and pulmonary infiltrates on imaging.

(Choice F) Tuberculosis can cause weight loss, cough, and night sweats, particularly in those with risk factors (eg, immunosuppression, imprisonment, immigrants, HIV positive). However, biopsy would typically show caseating granulomas and acid-fast bacilli.

Educational objective:
Sarcoidosis is an inflammatory disorder characterized histologically by noncaseating granulomas consisting of aggregates of epithelioid macrophages and multinucleated giant cells. Common manifestations include hilar adenopathy, pulmonary infiltrates, skin rash, ophthalmic findings, and constitutional symptoms.

Pathology Pulmonary & Critical Care Sarcoidosis

https://t.me/USMLEWorldStep1
Show all

Exhibit Display

Sarcoidosis

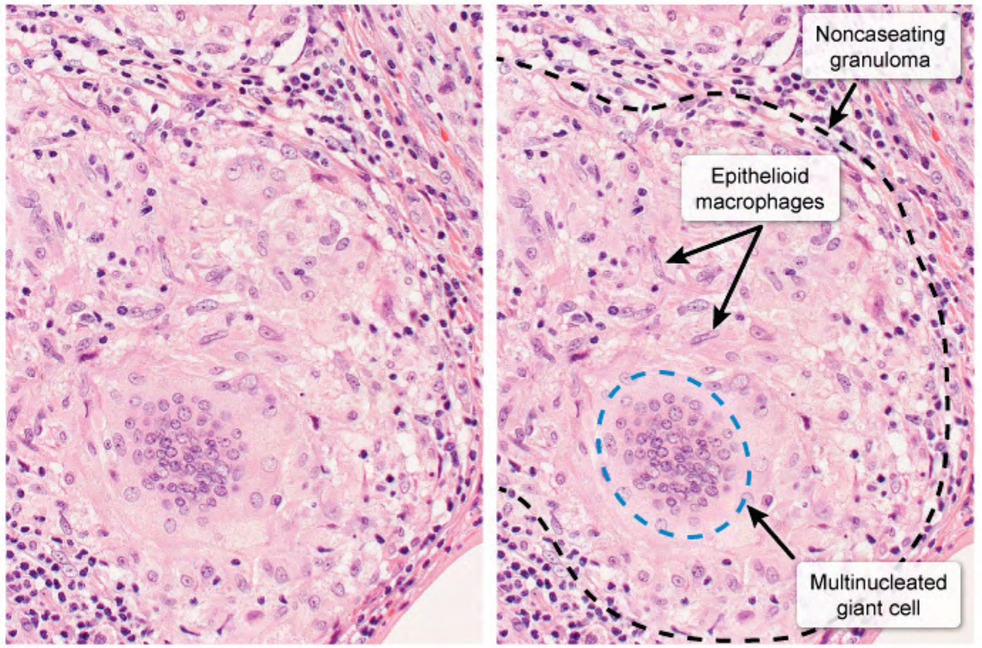

©UWorld

Zoom In | Zoom Out | Reset | New | Existing | My Notebook

This p
inflam
macro
occurs

Any or
hilar a
pulmo
fatigue

(Choi
granul

(Choi
night s

(Choi
sympt
carcin
where

(Choi
granulomas but typically occurs in severely immunocompromised patients. In addition, *Mycobacterium avium*

https://t.me/USMLEWorldStep1

Exhibit Display

Hodgkin lymphoma

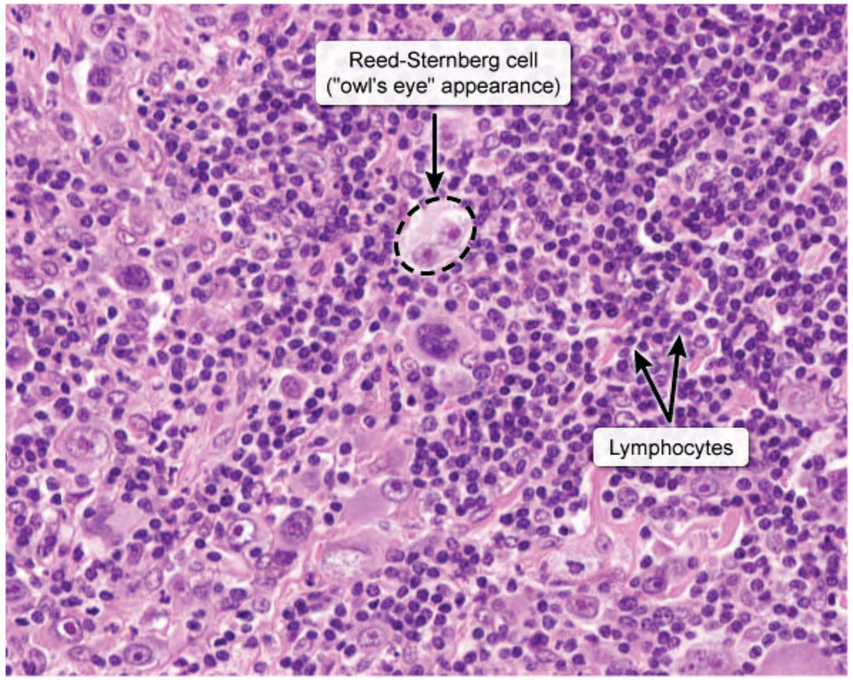

Zoom In | Zoom Out | Reset | New | Existing | My Notebook

This p
inflam
macro
occurs

Any or
hilar a
pulmo
fatigue

(Choi
granul

(Choi
night s

(Choi
sympt
carcin
where

(Choi
granulomas but typically occurs in severely immunocompromised patients. In addition, *Mycobacterium avium*

https://t.me/USMLEWorldStep1
Show all

This patient with cough, night sweats, and **bilateral hilar adenopathy** likely has **sarcoidosis**, a systemic
inflam
macro
occurs

Any or
hilar a
pulmo
fatigue

(Choi
granul

(Choi
night s

(Choi
sympt
carcin
where

(Choi
granul
pulmo

(Choi
immur
granul

Educa

Sarcoidosis is an inflammatory disorder characterized histologically by noncaseating granulomas consisting of

Exhibit Display

Squamous cell carcinoma of the lung

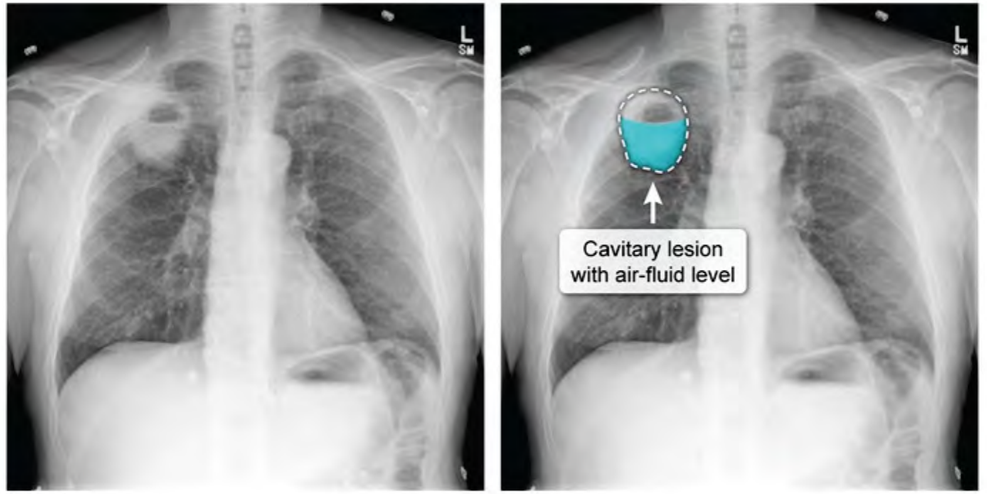

©UWorld

Zoom In Zoom Out Reset New | Existing My Notebook

https://t.me/USMLEWorldStep1
Show all

This patient with cough, night sweats, and **bilateral hilar adenopathy** likely has **sarcoidosis**, a systemic
inflam
macro
occurs

Any or
hilar a
pulmo
fatigue

(Choi
granul

(Choi
night s

(Choi
sympt
carcin
where

(Choi
granul
pulmo

(Choi
immur
granul

Educa
Sarcoi

Exhibit Display

Squamous cell carcinoma

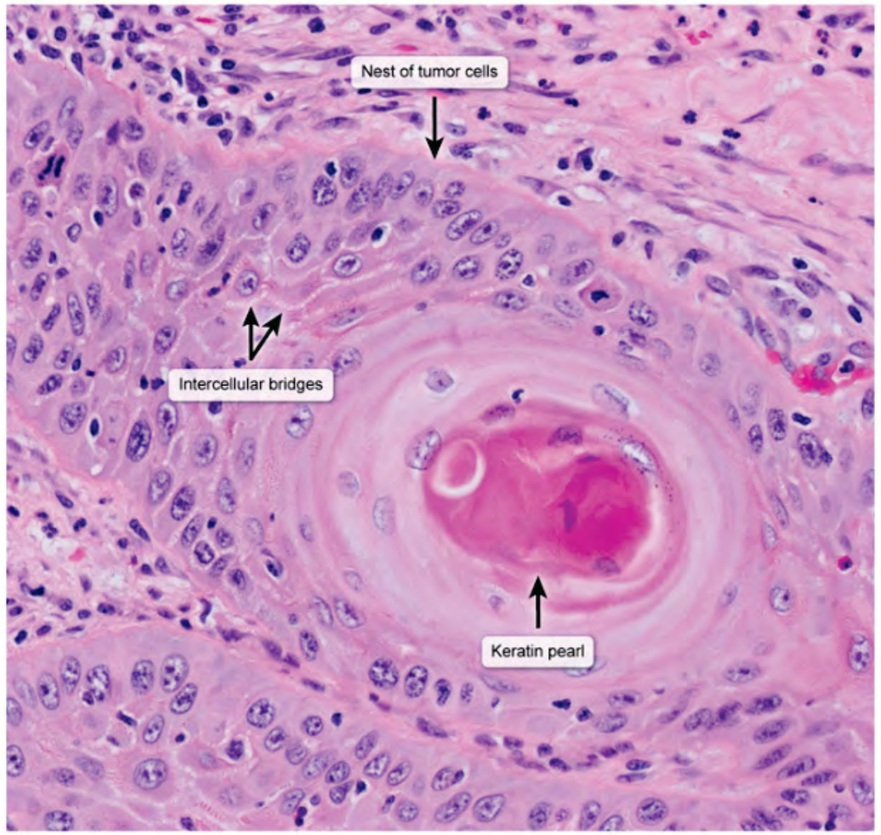

Zoom In | Zoom Out | Reset | New | Existing | My Notebook

https://t.me/USMLEWorldStep1

This patient with cough, night sweats, and **bilateral hilar adenopathy** likely has **sarcoidosis**, a systemic
inflam
macro
occurs

Any or
hilar a
pulmo
fatigue

(Choi
granul

(Choi
night s

(Choi
sympt
carcin
where

(Choi
granul
pulmo

(Choi
immur
granul

Educa

Sarcoidosis is an inflammatory disorder characterized histologically by noncaseating granulomas consisting of

Exhibit Display

Lung adenocarcinoma

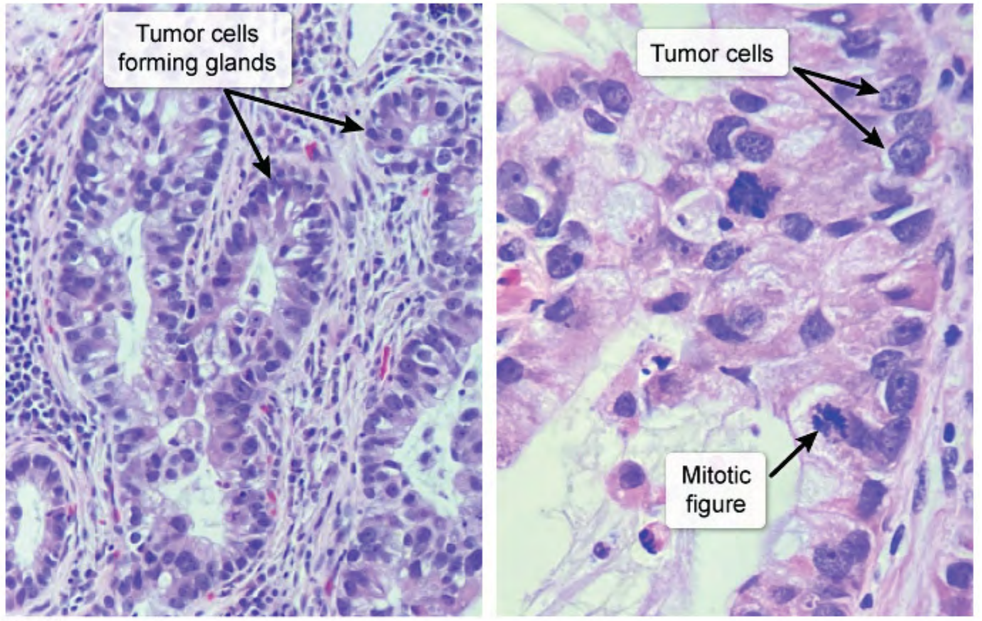

©UWorld

Zoom In Zoom Out Reset New | Existing My Notebook

https://t.me/USMLEWorldStep1
Show all

This patient with cough, night sweats, and **bilateral hilar adenopathy** likely has **sarcoidosis**, a systemic
inflam
macro
occurs

Any or
hilar a
pulmo
fatigue

(Choi
granul

(Choi
night s

(Choi
sympt
carcin
where

(Choi
granul
pulmo

(Choi
immur
granul

Educa

Sarcoidosis is an inflammatory disorder characterized histologically by noncaseating granulomas consisting of

Exhibit Display

Chronic pulmonary *Mycobacterium avium*

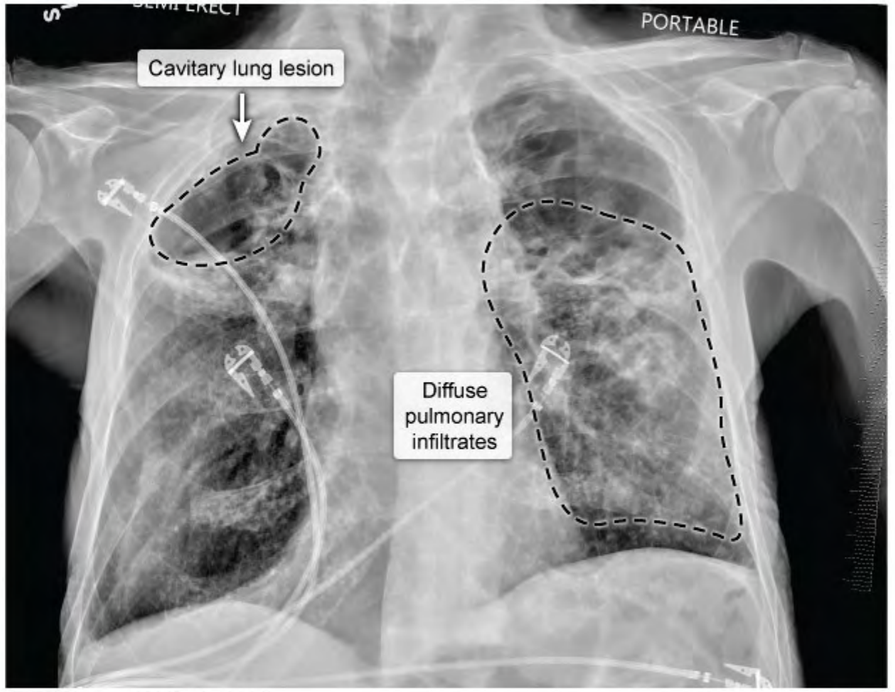

*Necrotizing (caseating) granulomas

©UWorld

Zoom In Zoom Out Reset New | Existing My Notebook

https://t.me/USMLEWorldStep1
Show all

This patient with cough, night sweats, and **bilateral hilar adenopathy** likely has **sarcoidosis**, a systemic
inflam
macro
occurs

Any or
hilar a
pulmo
fatigue

(Choi
granul

(Choi
night s

(Choi
sympt
carcin
where

(Choi
granul
pulmo

(Choi
immur
granul

Educa

Sarcoidosis is an inflammatory disorder characterized histologically by noncaseating granulomas consisting of

Exhibit Display

Caseating granuloma

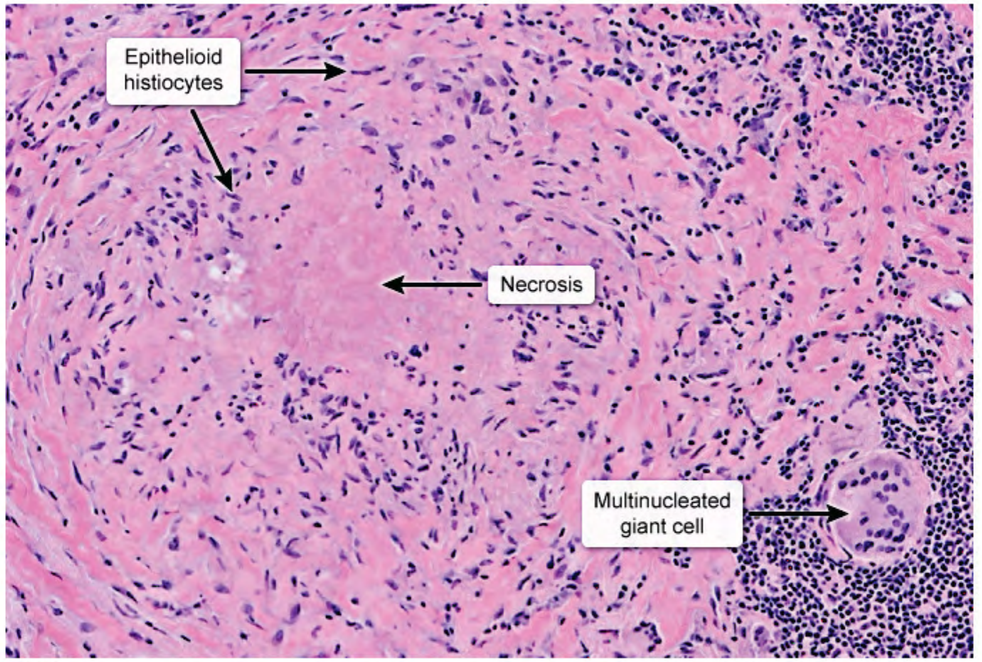

©UWorld

Zoom In | Zoom Out | Reset | New | Existing | My Notebook

https://t.me/USMLEWorldStep1

A 62-year-old man comes to the office for evaluation of progressive exertional dyspnea. His medical history is significant for pneumonia and hypertension. He has a 45-pack-year smoking history. On physical examination, breath sounds are decreased bilaterally and wheezes are heard. A CT scan of the chest is shown below.

Increased activity of which of the following cells is most likely responsible for the development of this patient's lung condition?

- A. Club cells
- B. Eosinophils
- C. Mast cells
- D. Neutrophils
- E. Type I pneumocytes
- F. Type II pneumocytes

Submit

https://t.me/USMLEWorldStep1
Show all

A 62-year-old man comes to the office for evaluation of progressive exertional dyspnea. His medical history is significant for pneumonia and hypertension. He has a 45-pack-year smoking history. On physical examination, breath sounds are decreased bilaterally and wheezes are heard. A CT scan of the chest is shown below.

Increased activity of which of the following cells is most likely responsible for the development of this patient's lung condition?

- A. Club cells
- B. Eosinophils
- C. Mast cells
- D. Neutrophils
- E. Type I pneumocytes
- F. Type II pneumocytes

https://t.me/USMLEWorldStep1
Show all

A 62-year-old man comes to the office for evaluation of progressive exertional dyspnea. His medical history is signifi
breath

Exhibit Display

Zoom In Zoom Out Reset New | Existing My Notebook

Increa
conditi

E. Type II pneumocytes

https://t.me/USMLEWorldStep1

breath sounds are decreased bilaterally and wheezes are heard. A CT scan of the chest is shown below:

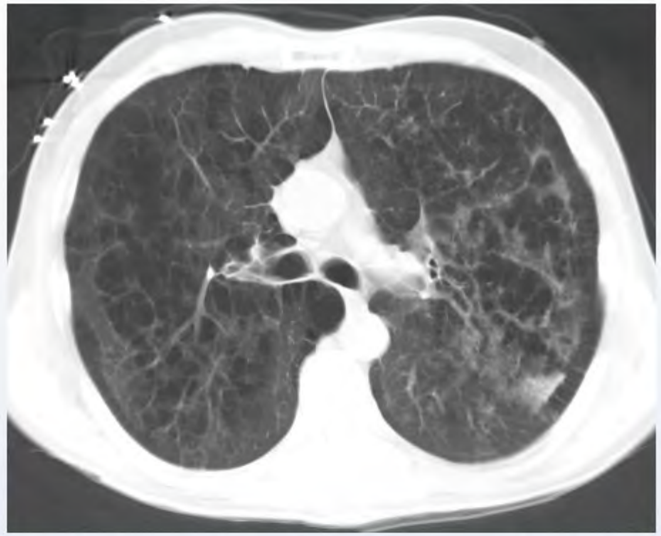

Increased activity of which of the following cells is most likely responsible for the development of this patient's lung condition?

- A. Club cells
- B. Eosinophils
- C. Mast cells
- D. Neutrophils
- E. Type I pneumocytes
- F. Type II pneumocytes

Submit

https://t.me/USMLEWorldStep1

breath sounds are decreased bilaterally and wheezes are heard. A CT scan of the chest is shown below:

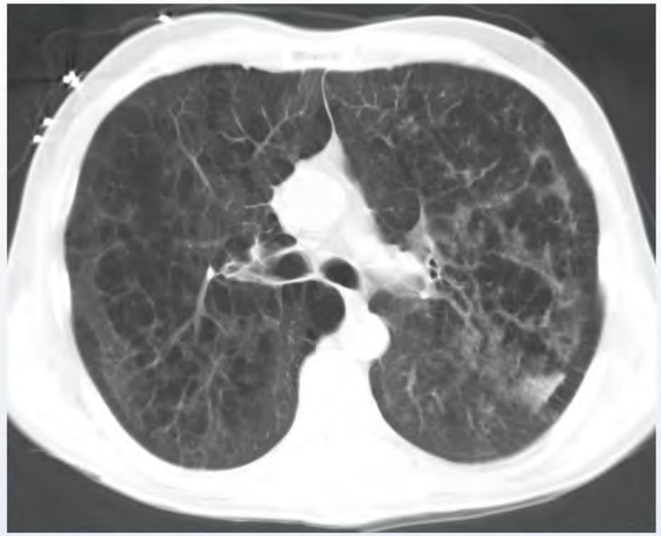

Increased activity of which of the following cells is most likely responsible for the development of this patient's lung condition?

- A. Club cells (8%)
- B. Eosinophils (4%)
- ✗ C. Mast cells (5%)
- ✓ D. Neutrophils (53%)
- E. Type I pneumocytes (7%)
- F. Type II pneumocytes (19%)

Incorrect
Correct answer
D

53%
Answered correctly

14 secs
Time Spent

2023
Version

https://t.me/USMLEWorldStep1
Show all

Type II pneumocytes (10%)

Inco
Corre
D

Expl

Exhibit Display

Normal chest CT scan

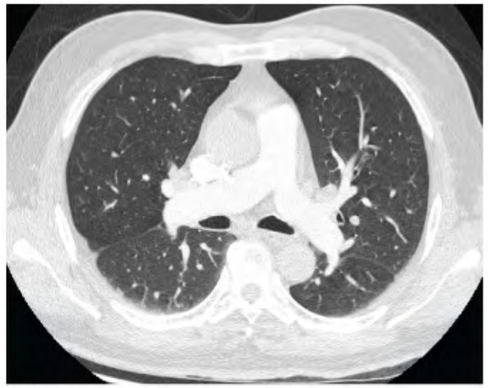

Emphysema

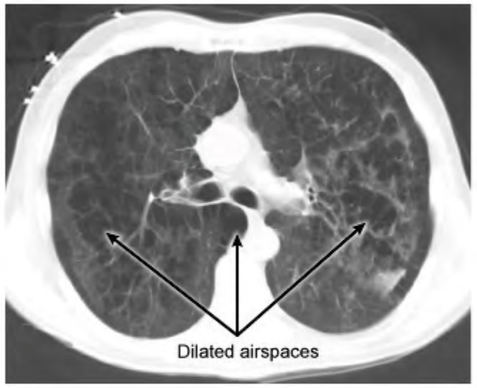

©UWorld

Zoom In | Zoom Out | Reset | New | Existing | My Notebook

This p
centria

The pa
activat
recruit
protea
matrix, they also generate oxygen free radicals that impair the function of protease inhibitors (eg, alpha-1 antitrypsin).

https://t.me/USMLEWorldStep1
Show all

©UWorld

This patient's heavy smoking history, exertional dyspnea, and **dilated airspaces** on CT scan are consistent with centriacinar emphysema.

The pathogenesis of **smoking-induced emphysema** involves oxidative injury to the respiratory bronchioles and activation of resident alveolar macrophages by components of cigarette smoke. This is followed by inflammatory recruitment of neutrophils into the affected airspaces. Activated **macrophages** and **neutrophils** release proteases, including elastase and others (eg, cathepsins, matrix metalloproteinases), that degrade the extracellular matrix; they also generate oxygen free radicals that impair the function of protease inhibitors (eg, alpha-1 antitrypsin).

The resultant **protease-antiprotease imbalance** leads to acinar wall destruction and irreversible airspace dilation distal to the terminal bronchioles. Excess protease activity is also involved in panacinar emphysema, such as occurs with alpha-1 antitrypsin deficiency.

(Choice A) Club cells are nonciliated, secretory constituents of the terminal respiratory epithelium. They secrete club cell secretory protein and surfactant components and also help detoxify inhaled substances (eg, tobacco smoke) by a cytochrome P450 mechanism.

(Choice B) Eosinophils play an important role in the late-phase component of Type I immediate hypersensitivity reactions. In the lung, they are recruited to help sustain the localized inflammatory response that follows exposure to allergens.

(Choice C) Interstitial pulmonary mast cells play a central role in the pathogenesis of allergic asthma by releasing histamine and leukotrienes that induce bronchospasm.

(Choice E) Type I pneumocytes constitute >95% of the inner epithelial lining of the alveoli. In emphysema, these cells are destroyed by the acinar wall damage inflicted by neutrophils and other inflammatory cells.

(Choice F) Type II pneumocytes are the source of pulmonary surfactant and the main cell type responsible for repair of alveolar epithelium after destruction of Type I pneumocytes.

https://t.me/USMLEWorldStep1
Show all

The pathogenesis of **smoking-induced emphysema** involves oxidative injury to the respiratory bronchioles and activation of resident alveolar macrophages by components of cigarette smoke. This is followed by inflammatory recruitment of neutrophils into the affected airspaces. Activated **macrophages** and **neutrophils** release proteases, including elastase and others (eg, cathepsins, matrix metalloproteinases), that degrade the extracellular matrix; they also generate oxygen free radicals that impair the function of protease inhibitors (eg, alpha-1 antitrypsin).

The resultant **protease-antiprotease imbalance** leads to acinar wall destruction and irreversible airspace dilation distal to the terminal bronchioles. Excess protease activity is also involved in panacinar emphysema, such as occurs with alpha-1 antitrypsin deficiency.

(Choice A) Club cells are nonciliated, secretory constituents of the terminal respiratory epithelium. They secrete club cell secretory protein and surfactant components and also help detoxify inhaled substances (eg, tobacco smoke) by a cytochrome P450 mechanism.

(Choice B) Eosinophils play an important role in the late-phase component of Type I immediate hypersensitivity reactions. In the lung, they are recruited to help sustain the localized inflammatory response that follows exposure to allergens.

(Choice C) Interstitial pulmonary mast cells play a central role in the pathogenesis of allergic asthma by releasing histamine and leukotrienes that induce bronchospasm.

(Choice E) Type I pneumocytes constitute >95% of the inner epithelial lining of the alveoli. In emphysema, these cells are destroyed by the acinar wall damage inflicted by neutrophils and other inflammatory cells.

(Choice F) Type II pneumocytes are the source of pulmonary surfactant and the main cell type responsible for repair of alveolar epithelium after destruction of Type I pneumocytes.

Educational objective:
The pathogenesis of centriacinar emphysema associated with chronic, heavy smoking predominantly involves the release of proteases, especially elastase, from infiltrating neutrophils and alveolar macrophages.

https://t.me/USMLEWorldStep1
Show all

Exhibit Display

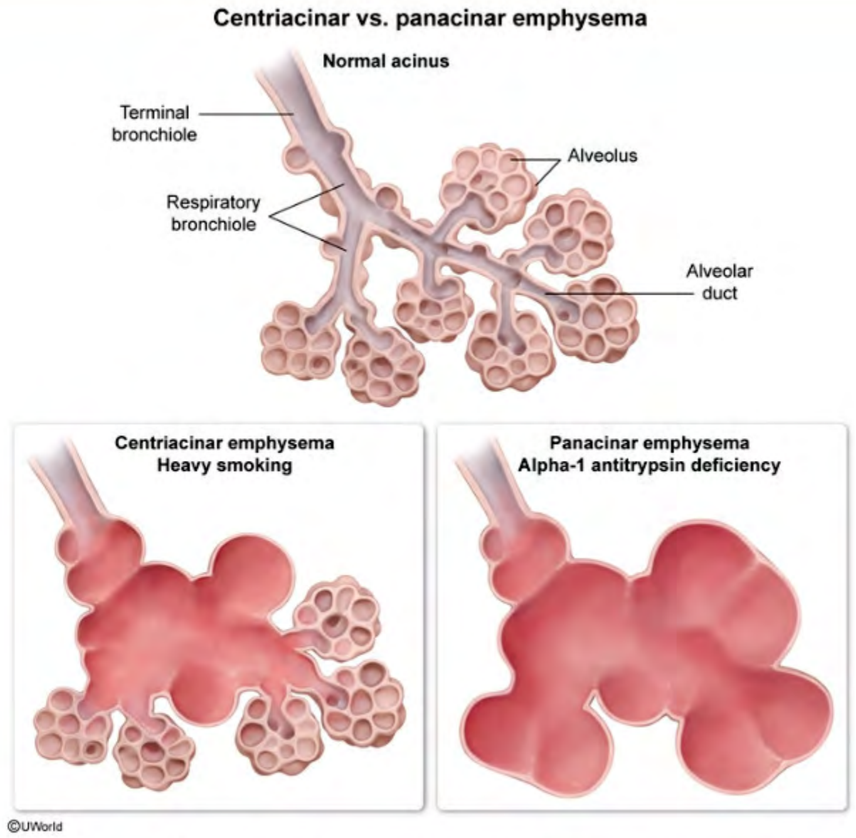

Zoom In | Zoom Out | Reset | New | Existing | My Notebook

This p
centria

The pa
activat
recruit
protea
matrix
antitry

The re
distal t
occurs

(Choi
club c
smoke

(Choi
reactio
to alle

(Choice C) Interstitial pulmonary mast cells play a central role in the pathogenesis of allergic asthma by releasing

https://t.me/USMLEWorldStep1
Show all

Exhibit Display

Histology of bronchial mucosa

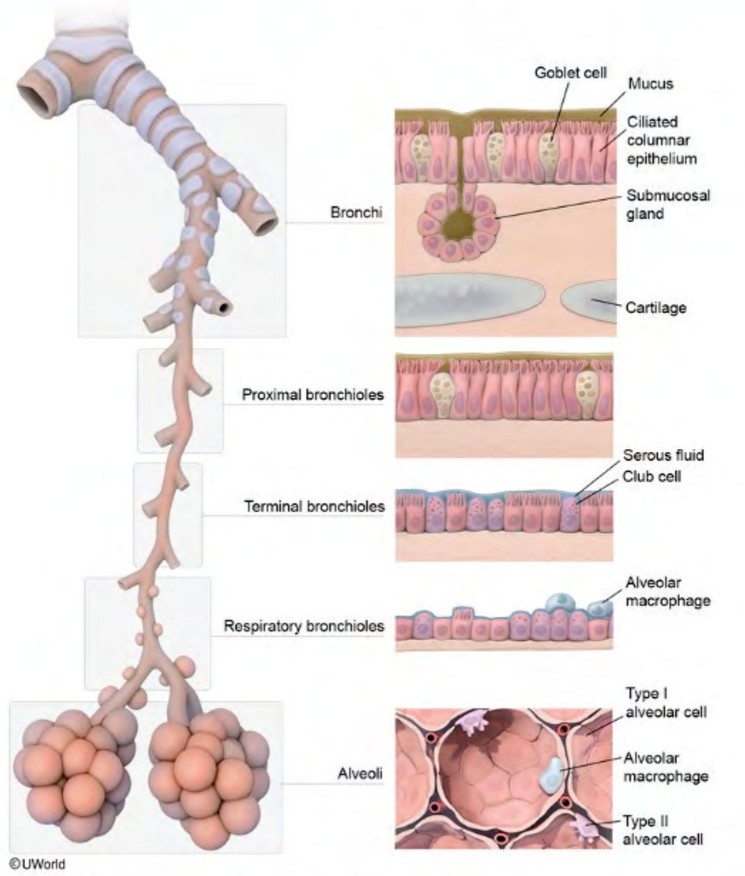

Zoom In | Zoom Out | Reset | New | Existing | My Notebook

This p
centria
The pa
activat
recruit
protea
matrix
antitry
The re
distal t
occurs
(Choi
club ce
smoke
(Choi
reactio
to aller
(Choi

https://t.me/USMLEWorldStep1

The pathogenesis of **smoking-induced emphysema** involves oxidative injury to the respiratory bronchioles and activation of resident alveolar macrophages by components of cigarette smoke. This is followed by inflammatory recruit
protea
matrix
antitry

The re
distal t
occurs

(Choi
club c
smoke

(Choi
reactio
to alle

(Choi
histam

(Choi
cells a

(Choi
repair

Educa
The pa
releas

Exhibit Display

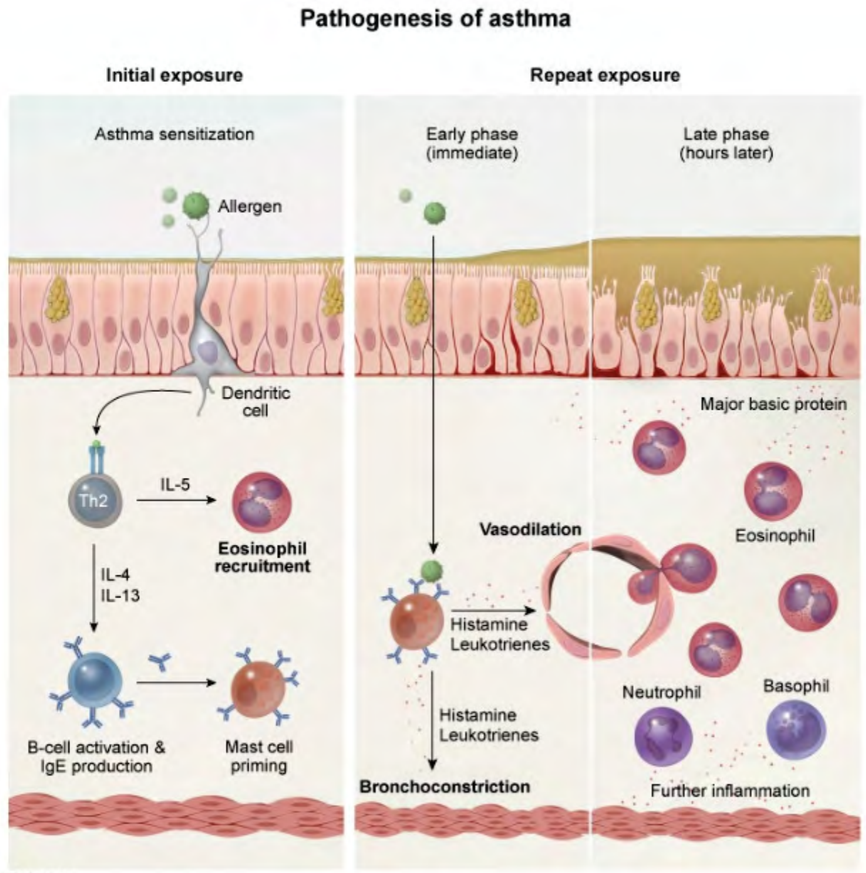

Zoom In Zoom Out Reset New | Existing My Notebook

https://t.me/USMLEWorldStep1
Show all

The pathogenesis of **smoking-induced emphysema** involves oxidative injury to the respiratory bronchioles and activation of resident alveolar macrophages by components of cigarette smoke. This is followed by inflammatory recruit
protea
matrix
antitry

The re
distal t
occurs

(Choi
club c
smoke

(Choi
reactio
to alle

(Choi
histam

(Choi
cells a

(Choi
repair

Educa
The pa
release of proteases, especially elastase, from infiltrating neutrophils and alveolar macrophages.

Exhibit Display

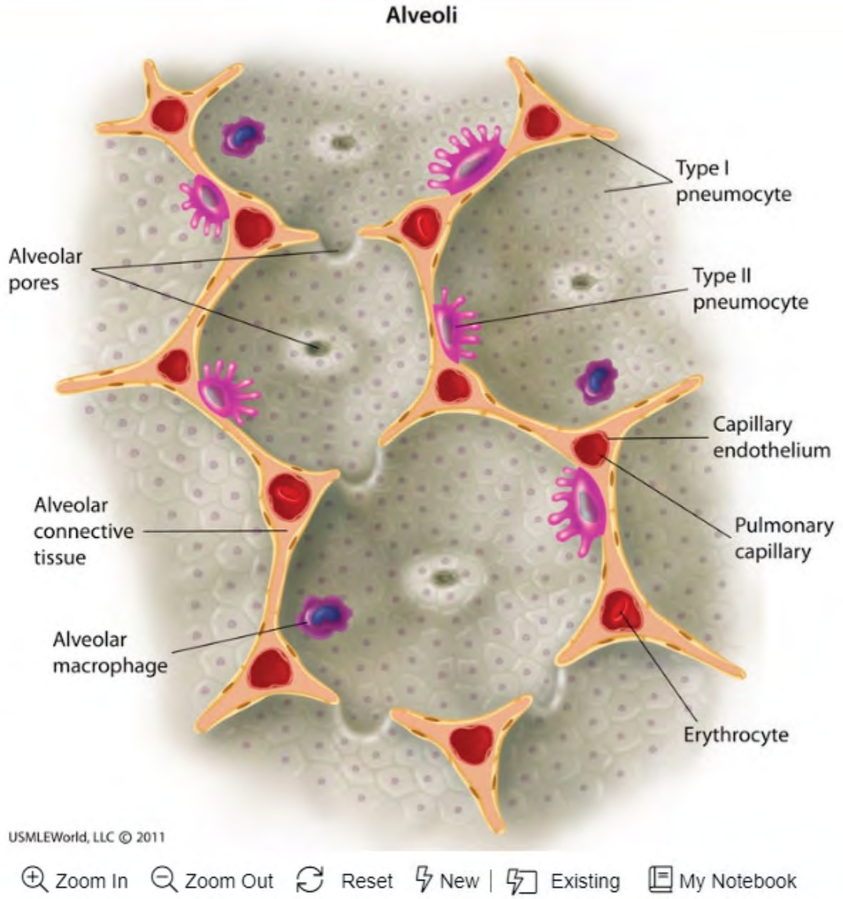

Zoom In Zoom Out Reset New | Existing My Notebook

https://t.me/USMLEWorldStep1

A 34-year-old man comes to the office due to episodic dyspnea, wheezing, and chest tightness for the past 4 months. He has no prior medical conditions and takes no medications. The patient smoked marijuana as a teenager but does not currently use tobacco, alcohol, or recreational drugs. He started working at an automotive body painting shop 7 months ago and has had no sick contacts. The patient's symptoms abated about a month ago during a 2-week vacation to Arizona but reappeared within a few days of his return. Temperature is 36.7 C (98.1 F), blood pressure is 120/80 mm Hg, pulse is 76/min, and respirations are 18/min. Cardiovascular examination is unremarkable. Lungs are clear to auscultation with normal air movement. Office spirometry, performed when the patient is asymptomatic, shows a normal FEV_1/FVC of 81%. Chest radiography reveals no abnormalities. Which of the following is most likely involved in the pathogenesis of this patient's condition?

- A. Exposure to inhaled allergens
- B. Infection with endemic dimorphic fungi
- C. Inherited deficiency of protease inhibitor
- D. Mutation in the *BMPR2* gene
- E. Necrotizing vasculitis of the small vessels

Submit

https://t.me/USMLEWorldStep1
Show all

A 34-year-old man comes to the office due to episodic dyspnea, wheezing, and chest tightness for the past 4 months. He has no prior medical conditions and takes no medications. The patient smoked marijuana as a teenager but does not currently use tobacco, alcohol, or recreational drugs. He started working at an automotive body painting shop 7 months ago and has had no sick contacts. The patient's symptoms abated about a month ago during a 2-week vacation to Arizona but reappeared within a few days of his return. Temperature is 36.7 C (98.1 F), blood pressure is 120/80 mm Hg, pulse is 76/min, and respirations are 18/min. Cardiovascular examination is unremarkable. Lungs are clear to auscultation with normal air movement. Office spirometry, performed when the patient is asymptomatic, shows a normal FEV_1/FVC of 81%. Chest radiography reveals no abnormalities. Which of the following is most likely involved in the pathogenesis of this patient's condition?

- ✓ A. Exposure to inhaled allergens
- B. Infection with endemic dimorphic fungi
- C. Inherited deficiency of protease inhibitor
- D. Mutation in the *BMPR2* gene
- E. Necrotizing vasculitis of the small vessels

Correct | Collecting Statistics | 03 secs Time Spent | 2023 Version

Explanation

This patient has intermittent vague **respiratory symptoms**, including dyspnea, wheezing, and chest tightness. His symptoms developed a few months after he started a new industrial painting job and **regressed after sustained absence** from the workplace (eg, vacation). This correlation is suspicious for **occupational asthma** (OA), a common form of adult-onset asthma

https://t.me/USMLEWorldStep1
Show all

Explanation

This patient has intermittent vague **respiratory symptoms**, including dyspnea, wheezing, and chest tightness. His symptoms developed a few months after he started a new industrial painting job and **regressed after sustained absence** from the workplace (eg, vacation). This correlation is suspicious for **occupational asthma** (OA), a common form of adult-onset asthma.

Like other forms of asthma, OA involves airway inflammation with leukocyte-induced bronchoconstriction. The underlying trigger may be immunologic or nonimmunologic:

- Immunologic OA (IgE-dependent, T-helper 2–mediated) involves exposure to **workplace aeroallergens** (eg, isocyanates in painters, grain proteins in bakers). It often has a **latent period** of several months as the patient becomes sensitized to the allergen.
- Nonimmunologic OA (IgE-independent, irritant-induced) involves inhalation of noxious compounds (eg, chlorine, ammonia) that induce airway irritation and mast cell degranulation. This typically occurs after large accidental exposures (eg, chemical spill); symptom onset is sudden.

Normal spirometry without obstruction (ie, normal FEV_1/FVC ratio >0.7) **does not exclude** asthma, as asthmatic bronchoconstriction may be intermittent. Outside of an attack, patients may be relatively asymptomatic with normal pulmonary function tests.

(Choice B) Coccidioidomycosis is endemic to the southwestern United States. It presents as fungal pneumonia (eg, fever, chest pain) often with extrapulmonary manifestations (eg, arthralgia, erythema nodosum). In addition, chest imaging typically reveals pulmonary infiltrates and hilar adenopathy, and this patient's symptoms emerged before his trip to Arizona.

(Choice C) Alpha-1 antitrypsin deficiency, an inherited disorder, causes premature-onset emphysema out of proportion to smoking history. Patients have dyspnea, cough, and wheezing. However, imaging typically reveals

https://t.me/USMLEWorldStep1
Show all

accidental exposures (eg, chemical spill); symptom onset is sudden.

Normal spirometry without obstruction (ie, normal FEV_1/FVC ratio >0.7) **does not exclude** asthma, as asthmatic bronchoconstriction may be intermittent. Outside of an attack, patients may be relatively asymptomatic with normal pulmonary function tests.

(Choice B) Coccidioidomycosis is endemic to the southwestern United States. It presents as fungal pneumonia (eg, fever, chest pain) often with extrapulmonary manifestations (eg, arthralgia, erythema nodosum). In addition, chest imaging typically reveals pulmonary infiltrates and hilar adenopathy, and this patient's symptoms emerged before his trip to Arizona.

(Choice C) Alpha-1 antitrypsin deficiency, an inherited disorder, causes premature-onset emphysema out of proportion to smoking history. Patients have dyspnea, cough, and wheezing. However, imaging typically reveals basilar-predominant bullae, spirometry consistently shows an obstructive pattern, and symptoms would not resolve with travel.

(Choice D) *BMPR2* gene mutations cause hereditary pulmonary arterial hypertension (PAH); symptoms include progressive dyspnea and signs of right ventricular pressure overload (eg, peripheral edema, jugulovenous distension). Because PAH affects the pulmonary vascular system instead of the airways or parenchyma, spirometry would be normal; resolution while traveling would be unexpected.

(Choice E) Eosinophilic granulomatosis with polyangiitis is a vasculitis of small- or medium-sized arteries characterized by asthma and chronic rhinosinusitis. Chest imaging typically demonstrates patchy infiltrates; symptoms would not resolve while traveling.

Educational objective:
Occupational asthma involves airway inflammation and bronchoconstriction triggered by sensitization to a workplace aeroallergen (eg, isocyanates, grain proteins). Improvement on sustained absence from work (eg, vacation) is an important clinical clue. Normal spirometry does not exclude asthma because bronchospasm may occur intermittently.

https://t.me/USMLEWorldStep1
Show all

patient becomes sensitized to the allergen.

- N
  cl
  a

Norma
bronch
pulmo

(Choi
(eg, fe
chest i
before

(Choi
propor
basilar
with tr

(Choi
progre
distens
spirom

(Choi
charac
sympt

Educa
Occup

Exhibit Display

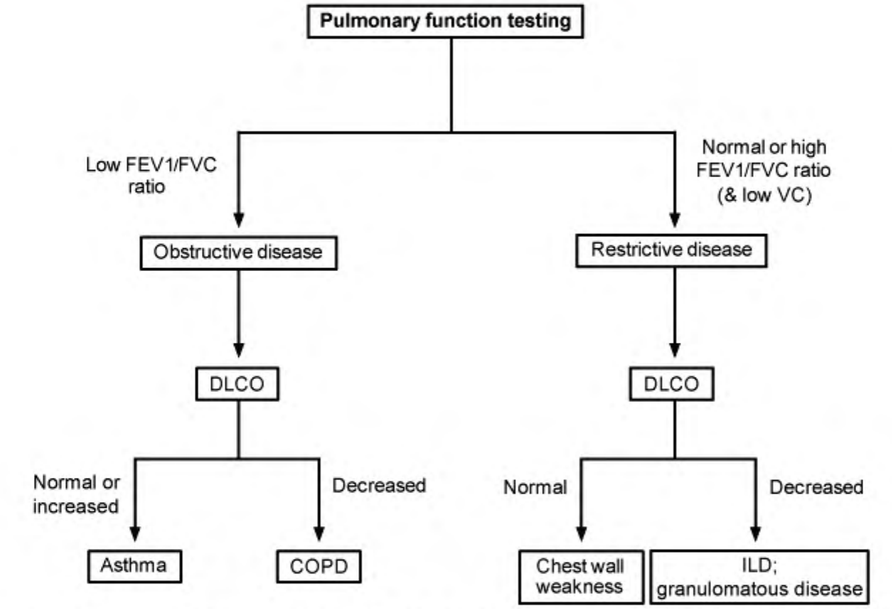

COPD = chronic obstructive pulmonary disease; **DLCO** = diffusion capacity of the lung for carbon monoxide; **FEV1** = forced expiratory volume in 1 second; **FVC** = forced vital capacity; **ILD** = interstitial lung disease; **VC** = vital capacity.
©UWorld

Zoom In | Zoom Out | Reset | New | Existing | My Notebook

https://t.me/USMLEWorldStep1
Show all

A 39-year-old woman comes to the office due to a nagging cough. Two weeks ago, the patient had a mild upper respiratory illness which resolved spontaneously after several days. Since then, she has had cough that is productive of minimal clear sputum. The patient has had no shortness of breath or chest pain. She took unexpired, leftover dextromethorphan for 2 days. The patient's only other medical condition is major depression, for which she takes sertraline. She does not use tobacco, alcohol, or illicit drugs. Vital signs and physical examination show no abnormalities. Use of dextromethorphan is most concerning for which of the following in this patient?

- A. Potential for recreational use
- B. Drug-drug interaction
- C. Liver injury
- D. Hypoventilation
- E. Rebound symptoms after discontinuation

Submit

https://t.me/USMLEWorldStep1
Show all

A 39-year-old woman comes to the office due to a nagging cough. Two weeks ago, the patient had a mild upper respiratory illness which resolved spontaneously after several days. Since then, she has had cough that is productive of minimal clear sputum. The patient has had no shortness of breath or chest pain. She took unexpired, leftover dextromethorphan for 2 days. The patient's only other medical condition is major depression, for which she takes sertraline. She does not use tobacco, alcohol, or illicit drugs. Vital signs and physical examination show no abnormalities. Use of dextromethorphan is most concerning for which of the following in this patient?

- ✗ A. Potential for recreational use (26%)
- ✓ B. Drug-drug interaction (49%)
- C. Liver injury (2%)
- D. Hypoventilation (6%)
- E. Rebound symptoms after discontinuation (15%)

Incorrect
Correct answer
B

49%
Answered correctly

03 secs
Time Spent

2023
Version

Explanation

Dextromethorphan	

Mechanism of action	• Activates medullary sigma receptors → cough suppressant
	• Trivial mu/delta opioid receptor agonism at therapeutic dose:
	  ◦ No constipation
	  ◦ Minimal respiratory depression

https://t.me/USMLEWorldStep1
Show all

Dextromethorphan	

Mechanism of action	• Activates medullary sigma receptors → cough suppressant
	• Trivial mu/delta opioid receptor agonism at therapeutic dose:
	  ◦ No constipation
	  ◦ Minimal respiratory depression
	  ◦ No analgesic effect
	  ◦ Low abuse potential

Overdose	• Serotonin syndrome: hypertonia, autonomic instability, encephalopathy • NMDA receptor inhibition: hallucinations, dissociation • Respiratory depression and coma at very high doses

Dextromethorphan (DXM) is a popular **cough suppressant** (antitussive agent) that is readily available over the counter. Its primary mechanism of action is inhibition of the medullary cough center through **sigma (σ) receptor activation**. Although structurally very closely related to other opioid morphinans (eg, codeine, morphine), DXM has trivial mu (μ) and delta (δ) opioid receptor affinity. Therefore, **classic opioid adverse effects** (eg, constipation, respiratory depression, analgesia, sedation) are **not seen** at therapeutic doses. This favorable pharmacologic profile makes DXM a first-choice agent for cough suppression.

However, DXM also increases serotonin activity in the CNS by decreasing the rate of presynaptic serotonin reuptake and directly stimulating serotonin receptors. For this reason, DXM abuse can cause **serotonin syndrome**, manifesting as muscular hypertonia, spasticity (eg, clonus, hyperreflexia), autonomic instability (eg, hyperthermia, hypertension), and encephalopathy. This potentially fatal condition most often occurs in settings of overdose or accidental drug interaction with other serotonergic drugs (eg, selective serotonin reuptake inhibitors, triptans, monoamine oxidase inhibitors).

(Choice A) Although DXM has the potential for abuse, addiction is less likely than with opioid cough suppressants (eg, codeine). Recreational drug use typically begins in peer settings, and adolescents and young adults are at

https://t.me/USMLEWorldStep1
Show all

Dextromethorphan (DXM) is a popular **cough suppressant** (antitussive agent) that is readily available over the counter. Its primary mechanism of action is inhibition of the medullary cough center through **sigma (σ) receptor activation**. Although structurally very closely related to other opioid morphinans (eg, codeine, morphine), DXM has trivial mu (μ) and delta (δ) opioid receptor affinity. Therefore, **classic opioid adverse effects** (eg, constipation, respiratory depression, analgesia, sedation) are **not seen** at therapeutic doses. This favorable pharmacologic profile makes DXM a first-choice agent for cough suppression.

However, DXM also increases serotonin activity in the CNS by decreasing the rate of presynaptic serotonin reuptake and directly stimulating serotonin receptors. For this reason, DXM abuse can cause **serotonin syndrome**, manifesting as muscular hypertonia, spasticity (eg, clonus, hyperreflexia), autonomic instability (eg, hyperthermia, hypertension), and encephalopathy. This potentially fatal condition most often occurs in settings of overdose or accidental drug interaction with other serotonergic drugs (eg, selective serotonin reuptake inhibitors, triptans, monoamine oxidase inhibitors).

(Choice A) Although DXM has the potential for abuse, addiction is less likely than with opioid cough suppressants (eg, codeine). Recreational drug use typically begins in peer settings, and adolescents and young adults are at greatest risk; this 39-year-old woman has no history of recreational drug use and is likely at low risk.

(Choice C) DXM has no intrinsic hepatotoxicity. However, acute liver injury can occur in overdose scenarios involving combination dextromethorphan-acetaminophen preparations (eg, multi-symptom cold remedies).

(Choice D) Although it has negligible μ receptor agonism at therapeutic doses, DXM at high doses may cause intoxication that can occasionally elicit enough μ receptor agonism to produce hypoventilation and stupor. These symptoms can be reversed with naloxone.

(Choice E) Patients who use over-the-counter decongestants (eg, oxymetazoline or phenylephrine sprays, oral pseudoephedrine) for prolonged periods can develop rhinitis medicamentosa, characterized by rebound nasal congestion, rhinorrhea, and turbinate hypertrophy. However, rebound cough is not observed on DXM withdrawal.

Educational objective:
Dextromethorphan (DXM) is a popular over-the-counter antitussive agent that acts on sigma receptors to suppress

https://t.me/USMLEWorldStep1
Show all

has trivial mu (μ) and delta (δ) opioid receptor affinity. Therefore, **classic opioid adverse effects** (eg, constipation, respiratory depression, analgesia, sedation) are **not seen** at therapeutic doses. This favorable pharmacologic profile makes DXM a first-choice agent for cough suppression.

However, DXM also increases serotonin activity in the CNS by decreasing the rate of presynaptic serotonin reuptake and directly stimulating serotonin receptors. For this reason, DXM abuse can cause **serotonin syndrome**, manifesting as muscular hypertonia, spasticity (eg, clonus, hyperreflexia), autonomic instability (eg, hyperthermia, hypertension), and encephalopathy. This potentially fatal condition most often occurs in settings of overdose or accidental drug interaction with other serotonergic drugs (eg, selective serotonin reuptake inhibitors, triptans, monoamine oxidase inhibitors).

(Choice A) Although DXM has the potential for abuse, addiction is less likely than with opioid cough suppressants (eg, codeine). Recreational drug use typically begins in peer settings, and adolescents and young adults are at greatest risk; this 39-year-old woman has no history of recreational drug use and is likely at low risk.

(Choice C) DXM has no intrinsic hepatotoxicity. However, acute liver injury can occur in overdose scenarios involving combination dextromethorphan-acetaminophen preparations (eg, multi-symptom cold remedies).

(Choice D) Although it has negligible μ receptor agonism at therapeutic doses, DXM at high doses may cause intoxication that can occasionally elicit enough μ receptor agonism to produce hypoventilation and stupor. These symptoms can be reversed with naloxone.

(Choice E) Patients who use over-the-counter decongestants (eg, oxymetazoline or phenylephrine sprays, oral pseudoephedrine) for prolonged periods can develop rhinitis medicamentosa, characterized by rebound nasal congestion, rhinorrhea, and turbinate hypertrophy. However, rebound cough is not observed on DXM withdrawal.

Educational objective:
Dextromethorphan (DXM) is a popular over-the-counter antitussive agent that acts on sigma receptors to suppress the medullary cough center. DXM also has an off-target action on serotonin transports and receptors in the CNS. Overdose or accidental interaction with other serotonergic medications (eg, selective serotonin reuptake inhibitors, antidepressants) can precipitate serotonin syndrome.

https://t.me/USMLEWorldStep1
Show all

- Low abuse potential

Exhibit Display

Common drug interactions implicated in serotonin syndrome

Antibiotics	• Linezolid
Antidepressants	• SSRIs, SNRIs • Monoamine oxidase inhibitors • Tricyclics
Analgesics	• Tramadol • Meperidine • Fentanyl
Anti-emetics	• 5-HT_3 receptor antagonists (eg, ondansetron)
Antitussive	• Dextromethorphan
Drugs of abuse	• MDMA • Amphetamine
Herbs	• St. John's Wort
Neuropsychiatric	• Triptans • Lithium

5-HT_3 = serotonin-gated ion channel; **MDMA** = 3,4-methylenedioxymethamphetamine ("ecstasy"); **SNRI** = serotonin-norepinephrine reuptake inhibitors; **SSRI** = selective serotonin reuptake inhibitors.

New | Existing | My Notebook

Dextr
counte
activa
has tri
consti
pharm

Howev
reupta
syndr
hypert
overdo
triptan

(Choi
(eg, co
greate

(Choice C) DXM has no intrinsic hepatotoxicity. However, acute liver injury can occur in overdose scenarios involving combination dextromethorphan-acetaminophen preparations (eg, multi-symptom cold remedies)

https://t.me/USMLEWorldStep1
Show all

A 68-year-old man comes to the emergency department due to cough, breathlessness, and chest pain. The patient has a medical history of hypertension and type 2 diabetes mellitus. He is a former smoker with a 20-pack-year history. Temperature is 38 C (100.4 F), blood pressure is 130/80 mm Hg, respirations are 22/min, and oxygen saturation is 95% while breathing ambient air. The trachea is central in position. There is dullness to percussion over the lower right lung area compared to the resonancy on the left. Auscultation of the right lower lobe reveals breath sounds that are loud, hollow, and high-pitched. When the patient recites the word "ninety-nine" in a normal voice, the sound has higher clarity and intensity over the right base compared to other lung areas. Which of the following is the most likely cause of these findings?

- A. Accumulation of interstitial fluid within the pleural space
- B. Embolic occlusion of a pulmonary segmental artery
- C. Exudation of neutrophil-rich fluid in the lung parenchyma
- D. Leakage of air from spontaneous rupture of visceral pleura
- E. Lung collapse due to a mass causing bronchial obstruction
- F. Transudation of interstitial fluid within the alveolar spaces

Submit

https://t.me/USMLEWorldStep1
Show all

A 68-year-old man comes to the emergency department due to cough, breathlessness, and chest pain. The patient has a medical history of hypertension and type 2 diabetes mellitus. He is a former smoker with a 20-pack-year history. Temperature is 38 C (100.4 F), blood pressure is 130/80 mm Hg, respirations are 22/min, and oxygen saturation is 95% while breathing ambient air. The trachea is central in position. There is dullness to percussion over the lower right lung area compared to the resonancy on the left. Auscultation of the right lower lobe reveals breath sounds that are loud, hollow, and high-pitched. When the patient recites the word "ninety-nine" in a normal voice, the sound has higher clarity and intensity over the right base compared to other lung areas. Which of the following is the most likely cause of these findings?

- A. Accumulation of interstitial fluid within the pleural space
- B. Embolic occlusion of a pulmonary segmental artery
- C. Exudation of neutrophil-rich fluid in the lung parenchyma
- D. Leakage of air from spontaneous rupture of visceral pleura
- E. Lung collapse due to a mass causing bronchial obstruction
- F. Transudation of interstitial fluid within the alveolar spaces

Submit

https://t.me/USMLEWorldStep1
Show all

A 68-year-old man comes to the emergency department due to cough, breathlessness, and chest pain. The patient has a medical history of hypertension and type 2 diabetes mellitus. He is a former smoker with a 20-pack-year history. Temperature is 38 C (100.4 F), blood pressure is 130/80 mm Hg, respirations are 22/min, and oxygen saturation is 95% while breathing ambient air. The trachea is central in position. There is dullness to percussion over the lower right lung area compared to the resonancy on the left. Auscultation of the right lower lobe reveals breath sounds that are loud, hollow, and high-pitched. When the patient recites the word "ninety-nine" in a normal voice, the sound has higher clarity and intensity over the right base compared to other lung areas. Which of the following is the most likely cause of these findings?

- A. Accumulation of interstitial fluid within the pleural space (12%)
- ✗ B. Embolic occlusion of a pulmonary segmental artery (2%)
- ✓ C. Exudation of neutrophil-rich fluid in the lung parenchyma (58%)
- D. Leakage of air from spontaneous rupture of visceral pleura (7%)
- E. Lung collapse due to a mass causing bronchial obstruction (5%)
- F. Transudation of interstitial fluid within the alveolar spaces (14%)

Incorrect
Correct answer
C

58%
Answered correctly

01 min, 17 secs
Time Spent

2023
Version

Explanation

Pulmonary auscultation examination findings			
Condition	**Breath sounds**	**Tactile fremitus**	**Percussion**

https://t.me/USMLEWorldStep1
Show all

Explanation

Pulmonary auscultation examination findings			
Condition	**Breath sounds**	**Tactile fremitus**	**Percussion**
Normal lung	Normal	Normal	Resonance
Consolidation	Increased	Increased	Dullness
Pleural effusion	Decreased or absent	Decreased	Dullness
Pneumothorax	Decreased or absent	Decreased	Hyperresonance
Atelectasis	Decreased or absent	Decreased	Dullness

This patient's presentation is consistent with **bacterial pneumonia**. The infection causes the alveoli to fill with inflammatory, neutrophil-rich exudate (pus); alveolar filling with any kind of fluid (eg, pus, edema, blood) creates **alveolar consolidation**.

Alveolar consolidation leads to a number of characteristic physical examination findings. Sound travels faster and more efficiently through liquids than gases; therefore, fluid-filled alveoli transmit higher intensity sound than those filled with air. As a result, **breath sounds** and **tactile fremitus** (vibration) are **more prominent** over areas of alveolar consolidation. **Bronchophony**, a phenomenon in which a patient's spoken words (eg, "ninety-nine," "toy boat") are **heard more loudly and clearly** when auscultated over an area of consolidation compared to normal lung, is also present. The higher density of fluid-filled alveoli also creates relative **dullness to percussion** compared to the resonant sound created on percussion of air-filled alveoli.

(Choice A) Accumulation of interstitial fluid within the pleural space (pleural effusion) insulates breath sounds and vibrations that originate in the airways of the lungs. Consequently, tactile fremitus and breath sound intensity are decreased. The fluid in the chest cavity creates dullness to percussion over the affected area.

(Choice B) Pulmonary embolism typically has minimal effect on physical examination findings for the lungs.

https://t.me/USMLEWorldStep1
Show all

This patient's presentation is consistent with **bacterial pneumonia**. The infection causes the alveoli to fill with inflammatory, neutrophil-rich exudate (pus); alveolar filling with any kind of fluid (eg, pus, edema, blood) creates **alveolar consolidation**.

Alveolar consolidation leads to a number of characteristic physical examination findings. Sound travels faster and more efficiently through liquids than gases; therefore, fluid-filled alveoli transmit higher intensity sound than those filled with air. As a result, **breath sounds** and **tactile fremitus** (vibration) are **more prominent** over areas of alveolar consolidation. **Bronchophony**, a phenomenon in which a patient's spoken words (eg, "ninety-nine," "toy boat") are **heard more loudly and clearly** when auscultated over an area of consolidation compared to normal lung, is also present. The higher density of fluid-filled alveoli also creates relative **dullness to percussion** compared to the resonant sound created on percussion of air-filled alveoli.

(Choice A) Accumulation of interstitial fluid within the pleural space (pleural effusion) insulates breath sounds and vibrations that originate in the airways of the lungs. Consequently, tactile fremitus and breath sound intensity are decreased. The fluid in the chest cavity creates dullness to percussion over the affected area.

(Choice B) Pulmonary embolism typically has minimal effect on physical examination findings for the lungs.

(Choice D) As in pleural effusion, accumulation of air in the pleural space (pneumothorax) insulates sounds and vibrations that originate in the lungs, and breath sound intensity and tactile fremitus are decreased. In contrast to pleural effusion, the relatively low density of the air in the pleural space creates hyperresonance to percussion.

(Choice E) A mass in a proximal bronchial airway (eg, malignancy, mucus plug) can cause airway obstruction and consequent collapse (atelectasis) of distal alveoli. Breath sounds and tactile fremitus are decreased, and dullness to percussion is created due to the absence of air.

(Choice F) Transudation of interstitial fluid into the alveoli occurs in heart failure and can create alveolar consolidation with physical examination findings similar to bacterial pneumonia. However, in heart failure the findings are typically similar bilaterally. Pneumonia, with accumulation of inflammatory exudate, is more likely in this patient with low-grade fever and evidence of unilateral alveolar consolidation.

https://t.me/USMLEWorldStep1
Show all

filled with air. As a result, **breath sounds** and **tactile fremitus** (vibration) are **more prominent** over areas of alveolar consolidation. **Bronchophony**, a phenomenon in which a patient's spoken words (eg, "ninety-nine," "toy boat") are **heard more loudly and clearly** when auscultated over an area of consolidation compared to normal lung, is also present. The higher density of fluid-filled alveoli also creates relative **dullness to percussion** compared to the resonant sound created on percussion of air-filled alveoli.

(Choice A) Accumulation of interstitial fluid within the pleural space (pleural effusion) insulates breath sounds and vibrations that originate in the airways of the lungs. Consequently, tactile fremitus and breath sound intensity are decreased. The fluid in the chest cavity creates dullness to percussion over the affected area.

(Choice B) Pulmonary embolism typically has minimal effect on physical examination findings for the lungs.

(Choice D) As in pleural effusion, accumulation of air in the pleural space (pneumothorax) insulates sounds and vibrations that originate in the lungs, and breath sound intensity and tactile fremitus are decreased. In contrast to pleural effusion, the relatively low density of the air in the pleural space creates hyperresonance to percussion.

(Choice E) A mass in a proximal bronchial airway (eg, malignancy, mucus plug) can cause airway obstruction and consequent collapse (atelectasis) of distal alveoli. Breath sounds and tactile fremitus are decreased, and dullness to percussion is created due to the absence of air.

(Choice F) Transudation of interstitial fluid into the alveoli occurs in heart failure and can create alveolar consolidation with physical examination findings similar to bacterial pneumonia. However, in heart failure the findings are typically similar bilaterally. Pneumonia, with accumulation of inflammatory exudate, is more likely in this patient with low-grade fever and evidence of unilateral alveolar consolidation.

Educational objective:
Alveolar consolidation occurs when the alveoli become filled with fluid (eg, inflammatory exudate in bacterial pneumonia). The increased compactness of the alveolar fluid (compared to air) causes sound to travel faster and more efficiently, resulting in bronchophony, increased tactile fremitus (vibration), and increased intensity of breath sounds over the affected area. Dullness to percussion is also present.

https://t.me/USMLEWorldStep1
Show all

A 34-year-old man with HIV comes to the emergency department due to fever, chills, productive cough, and left-sided chest pain that worsens with deep breathing. His symptoms began 3 days ago and have progressively worsened. The patient was diagnosed with HIV 4 years ago during routine screening, and he takes antiretroviral therapy. His CD4 count was 480 cells/mm^3 a month ago. Temperature is 38.8 C (102 F), blood pressure is 110/66 mm Hg, pulse is 110/min, and respirations are 22/min. Physical examination shows dullness to percussion, bronchial breath sounds, and crackles over the left lower lung. The right lung and cardiac auscultation findings are normal. Laboratory testing reveals an elevated leukocyte count with left shift. Which of the following organisms is most likely responsible for this patient's current symptoms?

- A. *Aspergillus fumigatus*
- B. Influenza virus
- C. *Legionella pneumophila*
- D. *Mycobacterium tuberculosis*
- E. *Mycoplasma pneumoniae*
- F. *Pneumocystis jiroveci*
- G. *Streptococcus pneumoniae*

Submit

https://t.me/USMLEWorldStep1
Show all

A 34-year-old man with HIV comes to the emergency department due to fever, chills, productive cough, and left-sided chest pain that worsens with deep breathing. His symptoms began 3 days ago and have progressively worsened. The patient was diagnosed with HIV 4 years ago during routine screening, and he takes antiretroviral therapy. His CD4 count was 480 cells/mm^3 a month ago. Temperature is 38.8 C (102 F), blood pressure is 110/66 mm Hg, pulse is 110/min, and respirations are 22/min. Physical examination shows dullness to percussion, bronchial breath sounds, and crackles over the left lower lung. The right lung and cardiac auscultation findings are normal. Laboratory testing reveals an elevated leukocyte count with left shift. Which of the following organisms is most likely responsible for this patient's current symptoms?

- A. *Aspergillus fumigatus* (6%)
- ✗ B. Influenza virus (1%)
- C. *Legionella pneumophila* (3%)
- D. *Mycobacterium tuberculosis* (4%)
- E. *Mycoplasma pneumoniae* (2%)
- F. *Pneumocystis jiroveci* (24%)
- ✓ G. *Streptococcus pneumoniae* (56%)

Incorrect
Correct answer
G

56%
Answered correctly

04 secs
Time Spent

2023
Version

Explanation

Although **HIV** is classically associated with impairment to the cell-mediated immune response, the virus also dramatically hampers the production of opsonizing antibodies and the recruitment of phagocytes to areas of

https://t.me/USMLEWorldStep1
Show all

Although **HIV** is classically associated with impairment to the cell-mediated immune response, the virus also dramatically hampers the production of opsonizing antibodies and the recruitment of phagocytes to areas of infection. Therefore, patients with HIV are at much greater risk for **invasive bacterial infections**, particularly with encapsulated organisms such as ***Streptococcus pneumoniae***.

S pneumoniae is the most common cause of **community-acquired pneumonia** in both HIV-infected and HIV-uninfected individuals, and usually presents with acute-onset fever, productive cough, leukocytosis, and signs of **lobar consolidation** (eg, dullness to percussion, crackles). *S pneumoniae* is also a frequent cause of sepsis and bacterial meningitis. To reduce the risk of invasive pneumococcal disease, all patients with HIV should be immunized with the pneumococcal vaccination, which provides immunity to the most common strains.

(Choice A) Although invasive *Aspergillus* is much more common in patients with HIV, it primarily affects those with extremely low CD4 counts (<50/mm^3). Fever, cough, shortness of breath, and nodular or cavitary pulmonary infiltrate often occurs.

(Choice B) Influenza usually causes acute-onset fever, malaise, myalgias, and headache. Manifestations of lobar consolidation would be atypical and would likely indicate an influenza complication (eg, secondary pneumonia). Patients with HIV should receive yearly influenza vaccination.

(Choice C) *Legionella* is a common cause of atypical pneumonia and is far more common in patients with HIV than the general population. Although *Legionella* often causes lobar consolidation, most cases are marked by several days of gastrointestinal symptoms (eg, vomiting, diarrhea) prior to developing pulmonary symptoms.

(Choice D) Patients with HIV are at much greater risk of *Mycobacterium tuberculosis* infection, which usually presents over several weeks (not days) with cough, low-grade fever, weight loss, and fatigue. Active pulmonary tuberculosis is usually characterized by cavitary disease in the upper lobes of the lung; signs of lower lobe consolidation would be atypical.

(Choice E) *Mycoplasma pneumoniae* is a leading cause of "walking pneumonia," a form of atypical pneumonia.

https://t.me/USMLEWorldStep1
Show all

(Choice A) Although invasive *Aspergillus* is much more common in patients with HIV, it primarily affects those with extremely low CD4 counts (<50/mm^3). Fever, cough, shortness of breath, and nodular or cavitary pulmonary infiltrate often occurs.

(Choice B) Influenza usually causes acute-onset fever, malaise, myalgias, and headache. Manifestations of lobar consolidation would be atypical and would likely indicate an influenza complication (eg, secondary pneumonia). Patients with HIV should receive yearly influenza vaccination.

(Choice C) *Legionella* is a common cause of atypical pneumonia and is far more common in patients with HIV than the general population. Although *Legionella* often causes lobar consolidation, most cases are marked by several days of gastrointestinal symptoms (eg, vomiting, diarrhea) prior to developing pulmonary symptoms.

(Choice D) Patients with HIV are at much greater risk of *Mycobacterium tuberculosis* infection, which usually presents over several weeks (not days) with cough, low-grade fever, weight loss, and fatigue. Active pulmonary tuberculosis is usually characterized by cavitary disease in the upper lobes of the lung; signs of lower lobe consolidation would be atypical.

(Choice E) *Mycoplasma pneumoniae* is a leading cause of "walking pneumonia," a form of atypical pneumonia. "Walking pneumonia" usually presents with several weeks (not days) of nonproductive cough and malaise. The infection usually affects multiple lobes of lung and causes a bilateral patchy infiltrate on chest x-ray.

(Choice F) *Pneumocystis* pneumonia (PCP) is common in patients with HIV, but occurs primarily in those with CD4 counts <200/mm^3 (unlike this patient). It usually presents with several weeks (not days) of slowly worsening dyspnea and fever. In addition, PCP usually affects both lungs and appears as bilateral reticulonodular pulmonary infiltrates on chest x-ray.

Educational objective:
The most common cause of community-acquired pneumonia in both HIV-infected and HIV-uninfected individuals is *Streptococcus pneumoniae*. Risk of invasive pneumococcal disease is significantly increased in patients with HIV regardless of CD4 count.

https://t.me/USMLEWorldStep1
Show all

(Choice B) Influenza usually causes acute-onset fever, malaise, myalgias, and headache. Manifestations of lobar

consol

Patien

(Choi

than th

severa

(Choi

preser

tuberc

consol

(Choi

"Walki

infecti

(Choi

CD4 c

dyspn

infiltrat

Educa

The m

Strept

regard

Microbi

Subject

Exhibit Display

Zoom In | Zoom Out | Reset | New | Existing | My Notebook

Copyright © UWorld. All rights reserved.

https://t.me/USMLEWorldStep1

The following vignette applies to the next **2** items. The items in the set must be answered in sequential order. Once you click **Proceed to Next Item**, you will not be able to add or change an answer.

An 87-year-old nursing home resident is brought to the emergency department with a 2-day history of fever, vomiting, and progressive lethargy. The patient's past medical history is significant for advanced dementia and stroke. Temperature is 38.3 C (101 F), blood pressure is 88/62 mm Hg, and pulse is 120/min and regular. On examination, he is lethargic but arousable. Coarse rhonchi are heard over the right midlung. Laboratory results are as follows:

Leukocytes	23,000/mm^3
Platelets	210,000/mm^3
Sodium	140 mEq/L
Potassium	4.2 mEq/L
Chloride	101 mEq/L
Bicarbonate	18 mEq/L
Creatinine	0.9 mg/dL
Glucose	121 mg/dL
Lactic acid	4.0 mmol/L (normal: <2 mmol/L)

Item 1 of 2

Which of the following is the most likely cause of this patient's increased anion gap?

A. Decreased oxidative phosphorylation

B. Impaired hepatic gluconeogenesis

https://t.me/USMLEWorldStep1
Show all

are as follows:

Leukocytes	23,000/mm^3
Platelets	210,000/mm^3
Sodium	140 mEq/L
Potassium	4.2 mEq/L
Chloride	101 mEq/L
Bicarbonate	18 mEq/L
Creatinine	0.9 mg/dL
Glucose	121 mg/dL
Lactic acid	4.0 mmol/L (normal: <2 mmol/L)

Item 1 of 2

Which of the following is the most likely cause of this patient's increased anion gap?

- A. Decreased oxidative phosphorylation
- B. Impaired hepatic gluconeogenesis
- C. Impaired renal tubular bicarbonate reabsorption
- D. Increased lipolysis and ketogenesis
- E. Increased protein breakdown

Submit

https://t.me/USMLEWorldStep1
Show all

Item 2 of 2

The patient is treated with intravenous fluids and antibiotics, with improvement in fever, leukocytosis, and hypotension. On the third day of hospitalization, temperature is 36.7 C (98 F), blood pressure is 122/78 mm Hg, and pulse is 86/min. On physical examination, he is mildly lethargic and his voice is soft and breathy. Rhonchi are still heard over the lower right lung. There is left-sided facial droop and hemiparesis from a previous stroke. Chest x-ray demonstrates dense air space opacities in the superior region of the right lower lobe. Which of the following underlying factors most likely predisposed this patient to his current hospitalization?

- A. Decreased enteral feeding
- B. Extended immobility
- C. Impaired cellular immunity
- D. Reduced intercostal muscle strength
- E. Swallowing muscle dysfunction

Submit

https://t.me/USMLEWorldStep1
Show all

are as follows:

Leukocytes	23,000/mm^3
Platelets	210,000/mm^3
Sodium	140 mEq/L
Potassium	4.2 mEq/L
Chloride	101 mEq/L
Bicarbonate	18 mEq/L
Creatinine	0.9 mg/dL
Glucose	121 mg/dL
Lactic acid	4.0 mmol/L (normal: <2 mmol/L)

Item 1 of 2

Which of the following is the most likely cause of this patient's increased anion gap?

- ✓ A. Decreased oxidative phosphorylation (52%)
- B. Impaired hepatic gluconeogenesis (3%)
- C. Impaired renal tubular bicarbonate reabsorption (19%)
- D. Increased lipolysis and ketogenesis (15%)
- E. Increased protein breakdown (9%)

Correct

52% Answered correctly

10 secs Time Spent

2023 Version

https://t.me/USMLEWorldStep1
Show all

Causes of lactic acidosis	
Underlying mechanism	**Etiology**
Enhanced metabolic rate	• Seizures • Exercise
Reduced oxygen delivery	• Cardiac or pulmonary failure • Tissue ischemia/infarction
Diminished lactate catabolism	• Hepatic failure or hypoperfusion
Decreased oxygen utilization	• Cyanide poisoning
Enzymatic defects	• Glycogen storage diseases (von Gierke) • Mitochondrial myopathies

This patient's clinical presentation (eg, fever, leukocytosis, hypotension, tachycardia) is indicative of **septic shock**; laboratory studies also show a corresponding anion gap metabolic acidosis secondary to an **elevated lactic acid** level.

Lactic acidosis may result from overproduction and/or impaired clearance of lactic acid. **End-organ hypoperfusion** in septic shock impairs tissue oxygenation and **decreases oxidative phosphorylation**, leading to a buildup of NADH during glycolysis and **shunting of pyruvate to lactate**. Hepatic hypoperfusion during sepsis also contributes to the accumulation of lactic acid as the liver is the primary site of lactate clearance (via gluconeogenesis).

(Choice B) Lactic acidosis due to primary impairment of hepatic gluconeogenesis can occur with certain inborn errors of metabolism (eg, pyruvate carboxylase or glucose-6-phosphatase deficiency). However, these diseases usually present in infancy (not elderly adults) and affected patients have fasting hypoglycemia.

(Choice C) Impaired renal tubular bicarbonate reabsorption is seen in type 2 (proximal) renal tubular acidosis

https://t.me/USMLEWorldStep1
Show all

This patient's clinical presentation (eg, fever, leukocytosis, hypotension, tachycardia) is indicative of **septic shock**; laboratory studies also show a corresponding anion gap metabolic acidosis secondary to an **elevated lactic acid** level.

Lactic acidosis may result from overproduction and/or impaired clearance of lactic acid. **End-organ hypoperfusion** in septic shock impairs tissue oxygenation and **decreases oxidative phosphorylation**, leading to a buildup of NADH during glycolysis and **shunting of pyruvate to lactate**. Hepatic hypoperfusion during sepsis also contributes to the accumulation of lactic acid as the liver is the primary site of lactate clearance (via gluconeogenesis).

(Choice B) Lactic acidosis due to primary impairment of hepatic gluconeogenesis can occur with certain inborn errors of metabolism (eg, pyruvate carboxylase or glucose-6-phosphatase deficiency). However, these diseases usually present in infancy (not elderly adults) and affected patients have fasting hypoglycemia.

(Choice C) Impaired renal tubular bicarbonate reabsorption is seen in type 2 (proximal) renal tubular acidosis. Poor bicarbonate reabsorption can occur in a variety of inherited or acquired conditions, including multiple myeloma and drug toxicity (eg, acetazolamide). Affected patients have a non-anion gap metabolic acidosis.

(Choice D) Increased lipolysis and ketogenesis occur in patients with diabetic ketoacidosis (DKA), which also presents with anion gap metabolic acidosis. However, serum glucose is much higher in DKA (on average >350 mg/dL), and ketones can be detected in blood and urine.

(Choice E) Increased protein breakdown can occur in the setting of chronic metabolic acidosis. However, it is not a direct cause of acidosis.

Educational objective:
Lactic acidosis in septic shock results from tissue hypoxia, which impairs oxidative phosphorylation and causes shunting of pyruvate to lactate following glycolysis. Hepatic hypoperfusion also contributes to the buildup of lactic acid as the liver is the primary site of lactate clearance.

https://t.me/USMLEWorldStep1
Show all

Reduced oxygen delivery	• Cardiac or pulmonary failure • [illegible]

Exhibit Display

Anion gap metabolic acidosis	
Calculation	Anion gap = sodium – (chloride + bicarbonate) (normal: 10-14 mEq/L)
Common causes Mnemonic: MUDPILES	• Methanol • Uremia • Diabetic ketoacidosis • Propylene glycol/paraldehyde • Isoniazid/iron • Lactic acidosis • Ethylene glycol (antifreeze) • Salicylate (aspirin)

New | Existing My Notebook

This p
labora
level.

Lactic
hypop
a build
also c
glucon

(Choi
errors
usuall

(Choi
Poor b
myelo

(Choi
preser
mg/dL), and ketones can be detected in blood and urine.

(Choice E) Increased protein breakdown can occur in the setting of chronic metabolic acidosis. However, it is not

https://t.me/USMLEWorldStep1

Item 2 of 2

The patient is treated with intravenous fluids and antibiotics, with improvement in fever, leukocytosis, and hypotension. On the third day of hospitalization, temperature is 36.7 C (98 F), blood pressure is 122/78 mm Hg, and pulse is 86/min. On physical examination, he is mildly lethargic and his voice is soft and breathy. Rhonchi are still heard over the lower right lung. There is left-sided facial droop and hemiparesis from a previous stroke. Chest x-ray demonstrates dense air space opacities in the superior region of the right lower lobe. Which of the following underlying factors most likely predisposed this patient to his current hospitalization?

- A. Decreased enteral feeding (1%)
- ✗ B. Extended immobility (13%)
- C. Impaired cellular immunity (14%)
- D. Reduced intercostal muscle strength (13%)
- ✓ E. Swallowing muscle dysfunction (57%)

Incorrect
Correct answer
E

57%
Answered correctly

05 secs
Time Spent

2023
Version

Explanation

Predisposing conditions for aspiration pneumonia
• Altered consciousness impairing cough reflex/glottic closure (eg, dementia, drug

https://t.me/USMLEWorldStep1
Show all

Predisposing conditions for aspiration pneumonia
• Altered consciousness impairing cough reflex/glottic closure (eg, dementia, drug intoxication) • Dysphagia due to neurologic deficits (eg, stroke, neurodegenerative disease) • Upper gastrointestinal tract disorders (eg, GERD) • Mechanical compromise of aspiration defenses (eg, nasogastric & endotracheal tubes) • Protracted vomiting • Large volume tube feedings in recumbent position
GERD = gastroesophageal reflux disease.

This patient developed septic shock secondary to pneumonia (rhonchi on lung examination and radiographic lung opacities). His **history of dementia and stroke** with residual hemiparesis and evidence of vocal cord paralysis (soft, breathy voice) is highly suggestive of **aspiration pneumonia** due to inhalation of oral secretions. The superior regions of the lower lobes and posterior regions of the upper lobes are the most dependent locations in the lungs of supine individuals; infiltrates in these locations are further evidence of aspiration pneumonia.

Although early studies indicated that anaerobic organisms were largely responsible for aspiration pneumonia, newer data indicate that **aerobic upper respiratory organisms** are primarily involved. Therefore, first-line empiric

https://t.me/USMLEWorldStep1
Show all

position
GERD = gastroesophageal reflux disease.

This patient developed septic shock secondary to pneumonia (rhonchi on lung examination and radiographic lung opacities). His **history of dementia and stroke** with residual hemiparesis and evidence of vocal cord paralysis (soft, breathy voice) is highly suggestive of **aspiration pneumonia** due to inhalation of oral secretions. The superior regions of the lower lobes and posterior regions of the upper lobes are the most dependent locations in the lungs of supine individuals; infiltrates in these locations are further evidence of aspiration pneumonia.

Although early studies indicated that anaerobic organisms were largely responsible for aspiration pneumonia, newer data indicate that **aerobic upper respiratory organisms** are primarily involved. Therefore, first-line empiric treatment targets typical community-acquired pneumonia pathogens. Anaerobic coverage is only required when lung abscess or empyema are present.

(Choice A) Enteral feeding, specifically oral intake, increases the risk of aspiration in patients with dysphagia.

(Choices B and D) Reduced intercostal muscle strength can result in atelectasis and hypoxia. Extended immobility can produce atelectasis in the posterior lungs if the patient remains in a supine position. These conditions can also predispose to the development of pneumonia if pulmonary hygiene is inadequate. However, aspiration pneumonia is less likely in such patients as long as swallow and cough reflexes are intact.

(Choice C) Impaired cellular immunity can increase the risk of pneumonia. However, affected patients usually have a history of recurrent viral and fungal infections.

Educational objective:
Patients with dementia or hemiparesis may have dysphagia, which is a risk factor for aspiration pneumonia. Dependent lung consolidation is commonly seen in aspiration pneumonia.

Pathology	Pulmonary & Critical Care	Aspiration pneumonia
Subject	System	Topic

Copyright © UWorld. All rights reserved.

https://t.me/USMLEWorldStep1
Show all

position

GERD = gastroesophageal reflux disease

Exhibit Display

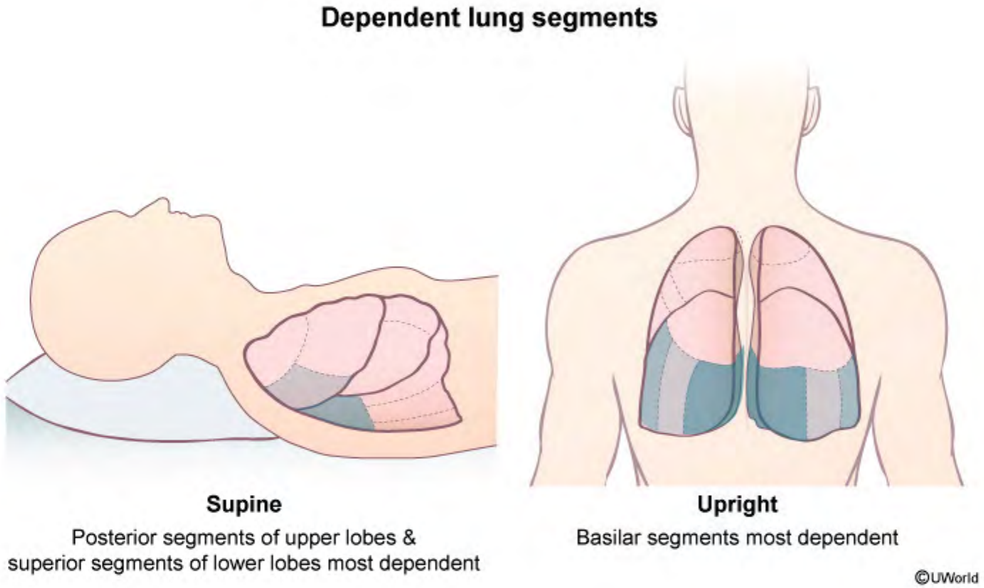

Zoom In | Zoom Out | Reset | New | Existing | My Notebook

This p
opaciti
(soft, b
superi
the lur

Althou
newer
treatm
lung a

(Choi

(Choi
immob
conditi
aspira

(Choi
have a

Educa
Patien
Deper

Pathol
Subject

Copyright © UWorld. All rights reserved.

https://t.me/USMLEWorldStep1

An 18-year-old man is evaluated for recurrent episodes of shortness of breath, wheezing, runny nose, and watery eyes. The patient reports that his symptoms have recently worsened since he started training outdoors for an upcoming marathon. He does not use tobacco, alcohol, or illicit drugs. Skin testing is performed to determine symptom triggers. A pricking device is used to apply allergen extract underneath the skin. After 15 minutes, the patient develops raised, erythematous plaques with surrounding erythema at the application site. Which of the following mediators is the first to be released during the pathogenesis of this patient's skin findings?

- A. Histamine
- B. Leukotriene D4
- C. Major basic proteins
- D. Platelet-activating factor
- E. Prostaglandin D2

Submit

https://t.me/USMLEWorldStep1
Show all

An 18-year-old man is evaluated for recurrent episodes of shortness of breath, wheezing, runny nose, and watery eyes. The patient reports that his symptoms have recently worsened since he started training outdoors for an upcoming marathon. He does not use tobacco, alcohol, or illicit drugs. Skin testing is performed to determine symptom triggers. A pricking device is used to apply allergen extract underneath the skin. After 15 minutes, the patient develops raised, erythematous plaques with surrounding erythema at the application site. Which of the following mediators is the first to be released during the pathogenesis of this patient's skin findings?

- ✓ A. Histamine (86%)
- ✗ B. Leukotriene D4 (5%)
- C. Major basic proteins (4%)
- D. Platelet-activating factor (0%)
- E. Prostaglandin D2 (1%)

Incorrect
Correct answer
A

86%
Answered correctly

03 secs
Time Spent

2023
Version

Explanation

https://t.me/USMLEWorldStep1
Show all

Exhibit Display

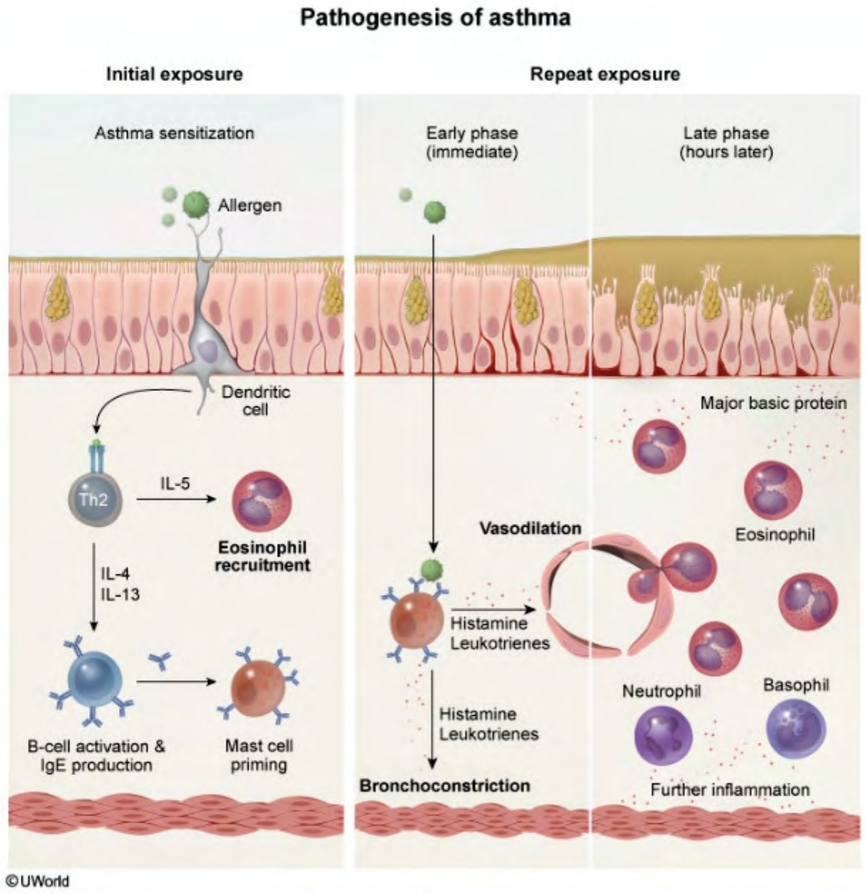

Zoom In | Zoom Out | Reset | New | Existing | My Notebook

https://t.me/USMLEWorldStep1

Show all

This patient's shortness of breath and wheezing are suggestive of **asthma**, and his rhinorrhea and watery eyes are suggestive of **allergic rhinitis**. Both of these conditions are examples of **type I hypersensitivity**, which involves the triggering of an allergic response via the binding of previously recognized antigen to IgE antibodies on **mast cells**. Many type I hypersensitivity reactions are composed of both an early and late phase.

Histamine is housed in **preformed granules** of unactivated mast cells and plays an important role in the early phase of type I hypersensitivity. Upon activation, mast cells rapidly release histamine via degranulation, making histamine the first chemical mediator to take effect. Once released, histamine triggers smooth muscle contraction leading to bronchoconstriction, increases vascular permeability leading to edema, and increases mucus secretion from glandular tissue.

(Choice B) Leukotriene D4, along with the other cysteinyl leukotrienes (C4 and E4), are not preformed but require synthesis via the 5-lipoxygenase pathway of arachidonic acid metabolism. Therefore, these mediators are released by mast cells later than histamine. Once released, the cysteinyl leukotrienes are potent mediators of vasoconstriction, bronchoconstriction, and increased vascular permeability.

(Choice C) Major basic protein is released from eosinophils in the late stage of a type I hypersensitivity reaction and causes localized tissue damage.

(Choice D) Platelet-activating factor is a secondary inflammatory mediator that must be synthesized from phospholipid prior to being released from activated mast cells and basophils. Once released, it stimulates bronchospasm and increased vascular permeability.

(Choice E) Prostaglandin D2 is synthesized via the cyclooxygenase pathway of arachidonic acid metabolism prior to being released from mast cells. Once released, it causes bronchospasm and vasodilation.

Educational objective:
Type I hypersensitivity reactions are an allergic response triggered by the binding of previously recognized antigen to IgE antibodies on mast cells. In the early phase of the response, histamine, already stored in preformed granules in mast cells, is the first chemical mediator released. Once released, histamine stimulates smooth muscle

https://t.me/USMLEWorldStep1
Show all

cells. Many type I hypersensitivity reactions are composed of both an early and late phase.

Histamine is housed in **preformed granules** of unactivated mast cells and plays an important role in the early phase of type I hypersensitivity. Upon activation, mast cells rapidly release histamine via degranulation, making histamine the first chemical mediator to take effect. Once released, histamine triggers smooth muscle contraction leading to bronchoconstriction, increases vascular permeability leading to edema, and increases mucus secretion from glandular tissue.

(Choice B) Leukotriene D4, along with the other cysteinyl leukotrienes (C4 and E4), are not preformed but require synthesis via the 5-lipoxygenase pathway of arachidonic acid metabolism. Therefore, these mediators are released by mast cells later than histamine. Once released, the cysteinyl leukotrienes are potent mediators of vasoconstriction, bronchoconstriction, and increased vascular permeability.

(Choice C) Major basic protein is released from eosinophils in the late stage of a type I hypersensitivity reaction and causes localized tissue damage.

(Choice D) Platelet-activating factor is a secondary inflammatory mediator that must be synthesized from phospholipid prior to being released from activated mast cells and basophils. Once released, it stimulates bronchospasm and increased vascular permeability.

(Choice E) Prostaglandin D2 is synthesized via the cyclooxygenase pathway of arachidonic acid metabolism prior to being released from mast cells. Once released, it causes bronchospasm and vasodilation.

Educational objective:
Type I hypersensitivity reactions are an allergic response triggered by the binding of previously recognized antigen to IgE antibodies on mast cells. In the early phase of the response, histamine, already stored in preformed granules in mast cells, is the first chemical mediator released. Once released, histamine stimulates smooth muscle contraction (bronchoconstriction), increases vascular permeability (edema), and increases mucus secretion.

References

- The development of allergic inflammation.

https://t.me/USMLEWorldStep1
Show all

IgE production
priming
Bronchoconstriction
Further inflammation

Exhibit Display

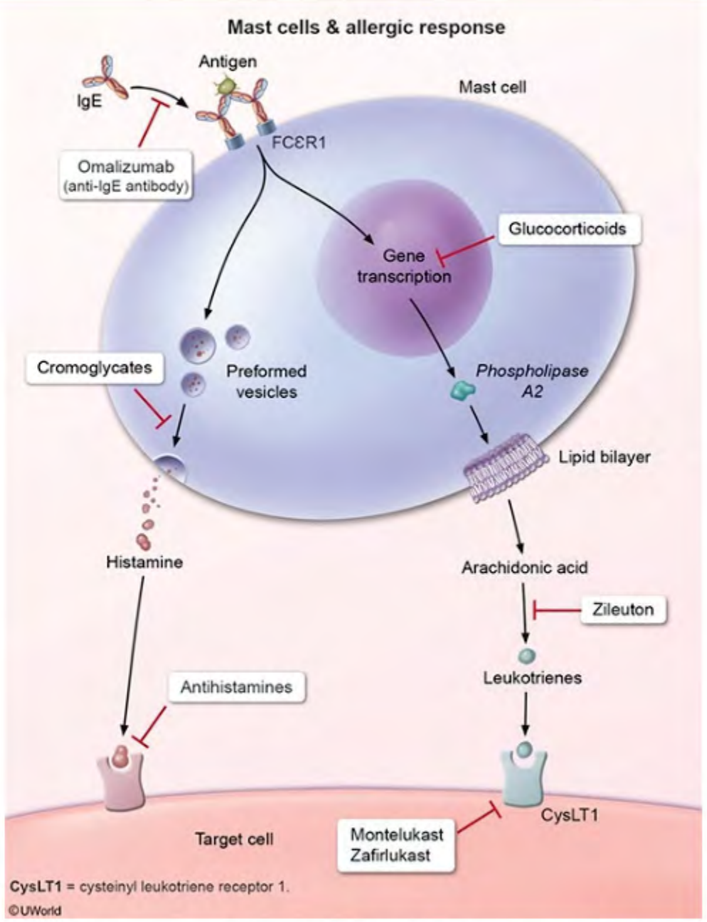

Zoom In | Zoom Out | Reset | New | Existing | My Notebook

This p
sugge
the trig
cells.

Histar
phase
histam
leadin
from g

(Choi
synthe
releas
vasoc

(Choi
and ca

(Choi
phosp
bronch

(Choi
to beir

Educa

https://t.me/USMLEWorldStep1

Show all

IgE production
priming
Bronchoconstriction
Further inflammation

Exhibit Display

This p
sugge
the trig
cells.

Histar
phase
histam
leadin
from g

(Choi
synthe
releas
vasoc

(Choi
and ca

(Choi
phosp
bronch

(Choi
to bein

Educational objective:

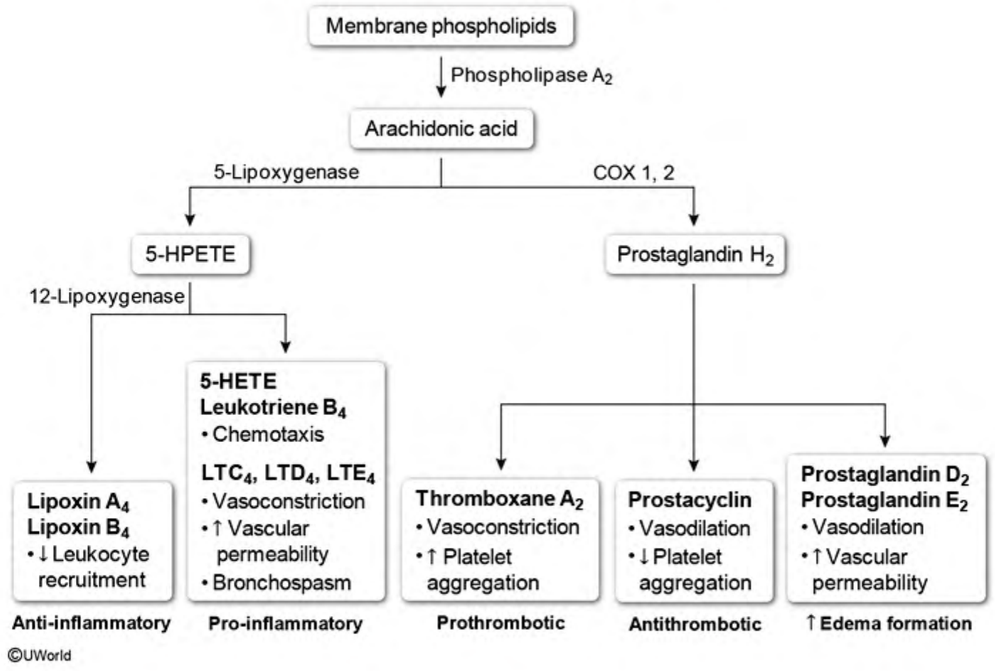

Zoom In | Zoom Out | Reset | New | Existing | My Notebook

https://t.me/USMLEWorldStep1

Show all

A 48-year-old, previously healthy woman is seen in the clinic for community-onset bacterial pneumonia. Chest x-ray reveals dense consolidation of the right middle lobe. Her pulse oximetry is 90% on room air. The patient is treated with appropriate antibiotics. Two days later, the patient feels well overall and her pulse oximetry is improved to 98% on room air. Examination reveals unchanged crackles and egophony from her previous visit. Which of the following processes best explains this patient's improved oxygenation?

- A. Decreased alveolar consolidation
- B. Decreased hemoglobin oxygen-binding affinity
- C. Increased erythrocyte production
- D. Restored hypoxic pulmonary vasoconstriction

Submit

https://t.me/USMLEWorldStep1
Show all

A 48-year-old, previously healthy woman is seen in the clinic for community-onset bacterial pneumonia. Chest x-ray reveals dense consolidation of the right middle lobe. Her pulse oximetry is 90% on room air. The patient is treated with appropriate antibiotics. Two days later, the patient feels well overall and her pulse oximetry is improved to 98% on room air. Examination reveals unchanged crackles and egophony from her previous visit. Which of the following processes best explains this patient's improved oxygenation?

- A. Decreased alveolar consolidation (34%)
- ✗ B. Decreased hemoglobin oxygen-binding affinity (9%)
- C. Increased erythrocyte production (15%)
- ✓ D. Restored hypoxic pulmonary vasoconstriction (40%)

Incorrect
Correct answer
D

40%
Answered correctly

04 secs
Time Spent

2023
Version

Explanation

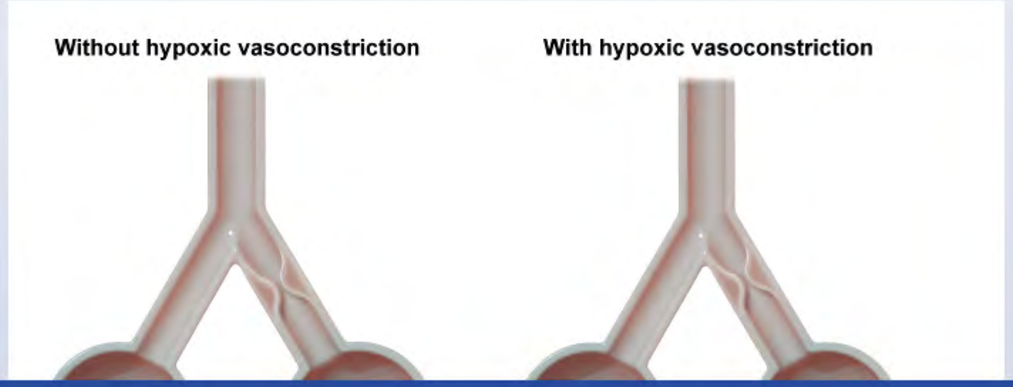

https://t.me/USMLEWorldStep1
Show all

Correct answer
D

Answered correctly
Time Spent
Version

Exhibit Display

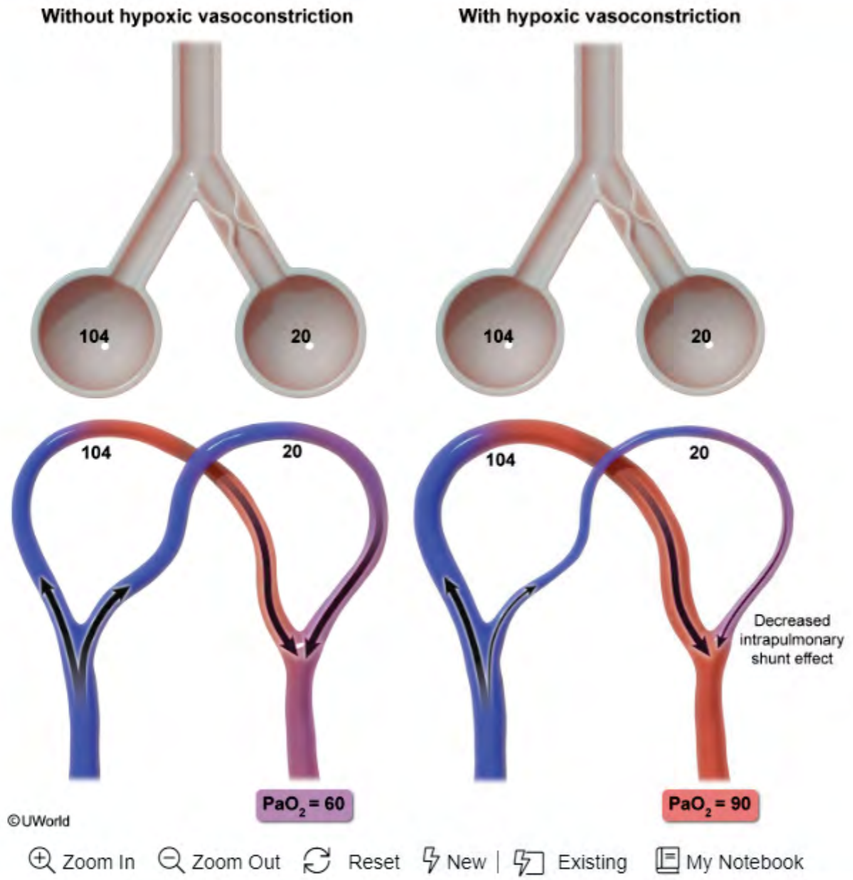

Zoom In | Zoom Out | Reset | New | Existing | My Notebook

https://t.me/USMLEWorldStep1
Show all

This patient has bacterial pneumonia with **lobar consolidation** (ie, alveoli filled with pus). Continued blood flow (perfusion) through these gasless (nonventilated) alveoli results in severe **ventilation-perfusion (V/Q) mismatch**, the primary mechanism by which pneumonia causes hypoxemia.

The normal response to local alveolar hypoxia is **hypoxic pulmonary vasoconstriction** (HPVC). Pulmonary arterioles detect hypoxia, vasoconstricting in response. This limits blood flow to the hypoxic nonventilated alveoli, redirecting it toward better-ventilated ones. Therefore, HPVC mitigates V/Q mismatch, optimizing oxygenation.

However, HPVC is impaired by **inflammatory states** such as acute pneumonia or sepsis. Proinflammatory cytokines cause **regional vasodilation**, resulting in hyperemia (↑ perfusion) to affected lung areas, further lowering the V/Q ratio and **worsening the hypoxemia**.

Once treatment is initiated (eg, antibiotic therapy), vasoactive inflammatory mediators are downregulated over the ensuing hours to days, and **HPVC is restored**. This occurs *prior* to resorption of alveolar debris and fibrinous edema, a slower process carried out by alveolar macrophages. Therefore, oxygenation typically improves days to weeks before resolution of the pneumonic infiltrates (eg, clear x-ray), which is consistent with this patient's improved oxygenation despite unchanged crackles and egophony **(Choice A)**.

(Choices B and C) Chronic hypoxemia (eg, obstructive sleep apnea, living at high altitude) causes increased erythropoietin levels to stimulate red cell production, augmenting the oxygen carrying capacity of blood. At the same time, the oxygen affinity of hemoglobin decreases, partially due to allosteric effects of glycolytic intermediates, promoting greater oxygen release to the tissues. These chronic adaptations merely compensate for hypoxemia but do not actually correct it, and they are unlikely to occur acutely (eg, initial days following bacterial pneumonia).

Educational objective:
Hypoxic pulmonary vasoconstriction (HPVC) limits perfusion to nonventilated alveoli, shunting blood toward better-ventilated ones, preserving ventilation-perfusion matching to maintain oxygenation. HPVC can be impaired by inflammatory vasodilation (eg, pneumonia or sepsis), and restoration of HPVC optimizes oxygenation despite minimal improvement in ventilation of consolidated alveoli.

https://t.me/USMLEWorldStep1
Show all

Decreased intrapulmonary

Exhibit Display

Spectrum of ventilation/perfusion (V/Q) mismatch

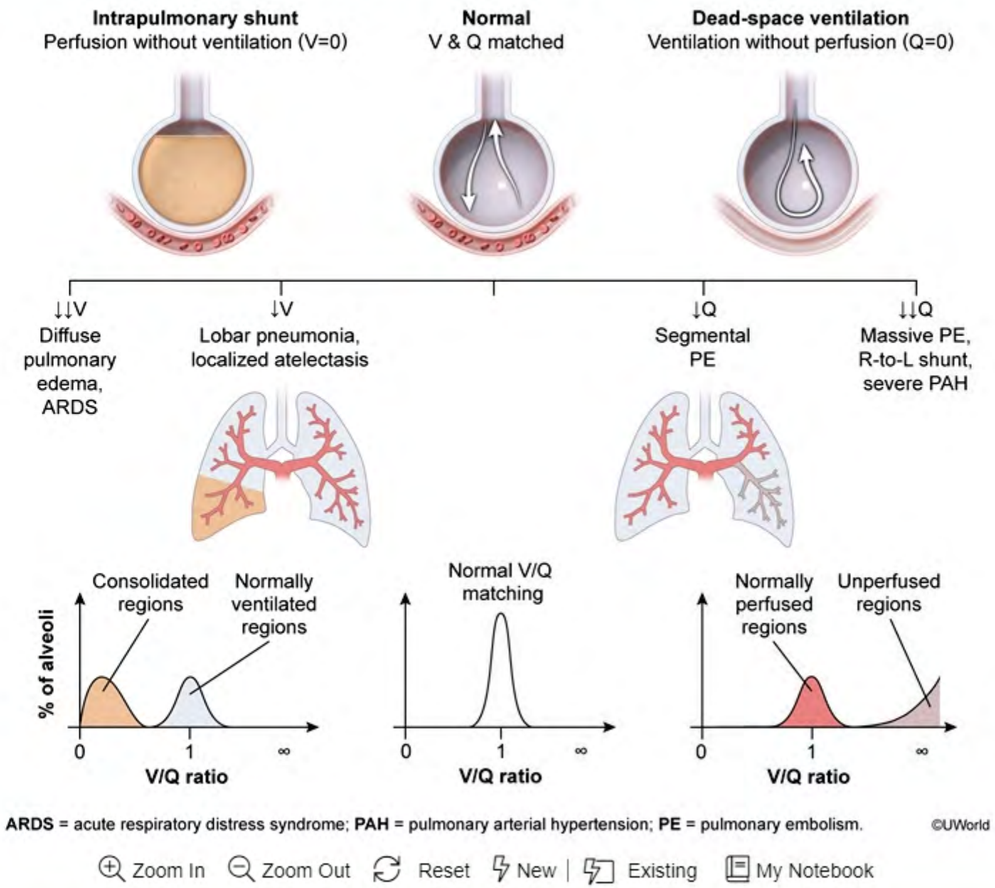

ARDS = acute respiratory distress syndrome; **PAH** = pulmonary arterial hypertension; **PE** = pulmonary embolism. ©UWorld

Zoom In | Zoom Out | Reset | New | Existing | My Notebook

https://t.me/USMLEWorldStep1

A 21-year-old previously healthy man comes to the office due to fever, malaise, myalgia, and nonproductive cough. His symptoms began 2 weeks after returning from exploring caves in Missouri. The patient does not use tobacco, alcohol, or illicit drugs. Temperature is 38.3 C (100.9 F), blood pressure is 120/70 mm Hg, pulse is 96/min, and respirations are 16/min. Physical examination reveals lung crackles. Chest x-ray shows patchy parenchymal infiltrates with enlarged mediastinal and hilar lymph nodes. Which of the following is most likely to be present in this patient's pulmonary lesions?

- A. Budding yeasts with a thick capsule
- B. Macrophages with intracellular small yeasts
- C. Round spherules with multiple endospores
- D. Septate hyphae with dichotomous branching
- E. Yeasts with pseudohyphae and blastoconidia

Submit

https://t.me/USMLEWorldStep1
Show all

A 21-year-old previously healthy man comes to the office due to fever, malaise, myalgia, and nonproductive cough. His symptoms began 2 weeks after returning from exploring caves in Missouri. The patient does not use tobacco, alcohol, or illicit drugs. Temperature is 38.3 C (100.9 F), blood pressure is 120/70 mm Hg, pulse is 96/min, and respirations are 16/min. Physical examination reveals lung crackles. Chest x-ray shows patchy parenchymal infiltrates with enlarged mediastinal and hilar lymph nodes. Which of the following is most likely to be present in this patient's pulmonary lesions?

- A. Budding yeasts with a thick capsule (9%)
- ✓ B. Macrophages with intracellular small yeasts (71%)
- C. Round spherules with multiple endospores (9%)
- D. Septate hyphae with dichotomous branching (4%)
- E. Yeasts with pseudohyphae and blastoconidia (4%)

Correct | 71% Answered correctly | 03 secs Time Spent | 2023 Version

Explanation

Histoplasma capsulatum	
Epidemiology	• Dimorphic fungus – mold in environment, yeast at body temperature • Endemic to Ohio & Mississippi River Valleys • Soil contaminated by bird or bat droppings
	• Inhaled → phagocytosed by alveolar macrophages → escapes lysosome destruction

https://t.me/USMLEWorldStep1
Show all

Histoplasma capsulatum	
Epidemiology	• Dimorphic fungus – mold in environment, yeast at body temperature • Endemic to Ohio & Mississippi River Valleys • Soil contaminated by bird or bat droppings
Pathophysiology	• Inhaled → phagocytosed by alveolar macrophages → escapes lysosome destruction → spreads to hilar/mediastinal lymph nodes • Controlled by cell-mediated immune response (**granulomas**)
Disease course	• Immunocompetent: Asymptomatic (primarily) or self-limited pneumonia with mediastinal/hilar lymphadenopathy • **Immunocompromised**: Disseminated disease through liver, spleen, or bone marrow
Diagnosis	• Urine antigen testing • Biopsy with histopathology – granulomas & macrophages with **intracellular ovoid/round yeast**

Histoplasma capsulatum is a dimorphic fungus that is endemic to the Ohio and Mississippi River valleys. It exists as a filamentous mold in the environment and is found primarily in soil contaminated with **bird or bat droppings**. Therefore, infected patients often report a history of exploring caves (exposure to bats) or cleaning bird cages or coops.

H capsulatum is transmitted when fungal spores from contaminated soil are inhaled into the alveoli. At body temperature, the spores germinate into yeasts and are subsequently phagocytosed by alveolar macrophages. The pathogen eludes macrophage-mediated destruction by preventing acidification of the phagolysosome and initially replicates in an unchecked fashion. Therefore, light microscopy of the affected areas reveals macrophages with intracellular ovoid or round yeasts.

Spread to the draining mediastinal and hilar lymph nodes prompts a cell-mediated immune response that helps

https://t.me/USMLEWorldStep1
Show all

Histoplasma capsulatum is a dimorphic fungus that is endemic to the Ohio and Mississippi River valleys. It exists as a filamentous mold in the environment and is found primarily in soil contaminated with **bird or bat droppings**. Therefore, infected patients often report a history of exploring caves (exposure to bats) or cleaning bird cages or coops.

H capsulatum is transmitted when fungal spores from contaminated soil are inhaled into the alveoli. At body temperature, the spores germinate into yeasts and are subsequently phagocytosed by alveolar macrophages. The pathogen eludes macrophage-mediated destruction by preventing acidification of the phagolysosome and initially replicates in an unchecked fashion. Therefore, light microscopy of the affected areas reveals macrophages with intracellular ovoid or round yeasts.

Spread to the draining mediastinal and hilar lymph nodes prompts a cell-mediated immune response that helps contain the infection within caseating granulomas (similar to the immune response to *Mycobacterium tuberculosis*). Patients with intact immune systems usually remain **asymptomatic**, but a minority develop **subacute pneumonia** (ie, cough, fever, pleuritic chest pain, pulmonary infiltrates) with hilar and mediastinal lymphadenopathy. In immunocompromised patients (eg, AIDS), infected macrophages can spread the organism throughout the reticuloendothelial system, resulting in widespread disseminated disease.

(Choice A) *Cryptococcus neoformans* appears as a budding yeast with a thick polysaccharide capsule. Although *C neoformans* is often transmitted from soil contaminated with bird (pigeon) droppings, this pathogen primarily causes central nervous system disease (meningoencephalitis) in patients with severe immunocompromise (eg, advanced AIDS).

(Choice C) *Coccidioides immitis* appears as spherules packed with endospores. *Coccidioides* can cause pulmonary disease in healthy individuals, but this pathogen is endemic to the southwestern United States deserts (not Missouri) and is not associated with cave exploration.

(Choice D) *Aspergillus fumigatus* appears as septate hyphae with V-shaped branching. Invasive pulmonary aspergillosis is seen primarily in patients with severe immunocompromise (eg, AIDS).

(Choice E) *Candida* species are yeasts that form pseudohyphae and blastoconidia (budded cells off of the

https://t.me/USMLEWorldStep1
Show all

pathogen eludes macrophage-mediated destruction by preventing acidification of the phagolysosome and initially replicates in an unchecked fashion. Therefore, light microscopy of the affected areas reveals macrophages with intracellular ovoid or round yeasts.

Spread to the draining mediastinal and hilar lymph nodes prompts a cell-mediated immune response that helps contain the infection within caseating granulomas (similar to the immune response to *Mycobacterium tuberculosis*). Patients with intact immune systems usually remain **asymptomatic**, but a minority develop **subacute pneumonia** (ie, cough, fever, pleuritic chest pain, pulmonary infiltrates) with hilar and mediastinal lymphadenopathy. In immunocompromised patients (eg, AIDS), infected macrophages can spread the organism throughout the reticuloendothelial system, resulting in widespread disseminated disease.

(Choice A) *Cryptococcus neoformans* appears as a budding yeast with a thick polysaccharide capsule. Although *C neoformans* is often transmitted from soil contaminated with bird (pigeon) droppings, this pathogen primarily causes central nervous system disease (meningoencephalitis) in patients with severe immunocompromise (eg, advanced AIDS).

(Choice C) *Coccidioides immitis* appears as spherules packed with endospores. *Coccidioides* can cause pulmonary disease in healthy individuals, but this pathogen is endemic to the southwestern United States deserts (not Missouri) and is not associated with cave exploration.

(Choice D) *Aspergillus fumigatus* appears as septate hyphae with V-shaped branching. Invasive pulmonary aspergillosis is seen primarily in patients with severe immunocompromise (eg, AIDS).

(Choice E) *Candida* species are yeasts that form pseudohyphae and blastoconidia (budded cells off of the pseudohyphae). Patients with intact immune systems rarely develop invasive *Candida* infections.

Educational objective:
Histoplasma capsulatum is endemic to the Ohio and Mississippi River valleys and is found primarily in soil contaminated with bird or bat droppings. It exists in tissues as an ovoid/round yeast predominantly within the intracellular space of macrophages. Immunocompetent patients are often asymptomatic but can infrequently develop subacute pneumonia with hilar and mediastinal lymphadenopathy.

https://t.me/USMLEWorldStep1
Show all

Histoplasma capsulatum is a dimorphic fungus that is endemic to the Ohio and Mississippi River valleys. It exists as a fi… Theref… coops… *H cap*… tempe… pathog… replica… intrace… Sprea… contai… *tuberc*… **subac**… lymph… throug… **(Choi**… *C neo*… cause… advan… **(Choi**… pulmo… (not M… **(Choi**… asperg…

Exhibit Display

Histoplasma

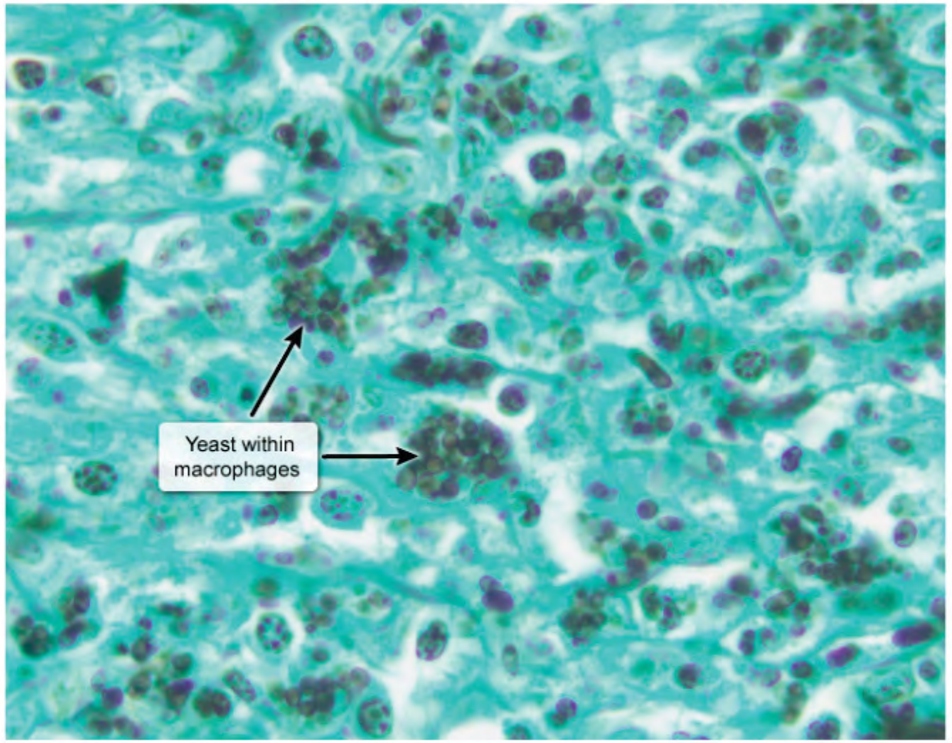

Silver stain

©UWorld

Zoom In Zoom Out Reset New | Existing My Notebook

(Choice E) *Candida* species are yeasts that form pseudohyphae and blastoconidia (budded cells off of the

https://t.me/USMLEWorldStep1
Show all

Histoplasma capsulatum is a dimorphic fungus that is endemic to the Ohio and Mississippi River valleys. It exists as a filamentous mold in the environment and is found primarily in soil contaminated with **bird or bat droppings**.

Theref
coops

H cap
tempe
pathog
replica
intrace

Sprea
contai
tuberc
subac
lymph
throug

(Choi
C neo
cause
advan

(Choi
pulmo
(not M

(Choi
asperg

(Choi

Exhibit Display

Cryptococcus

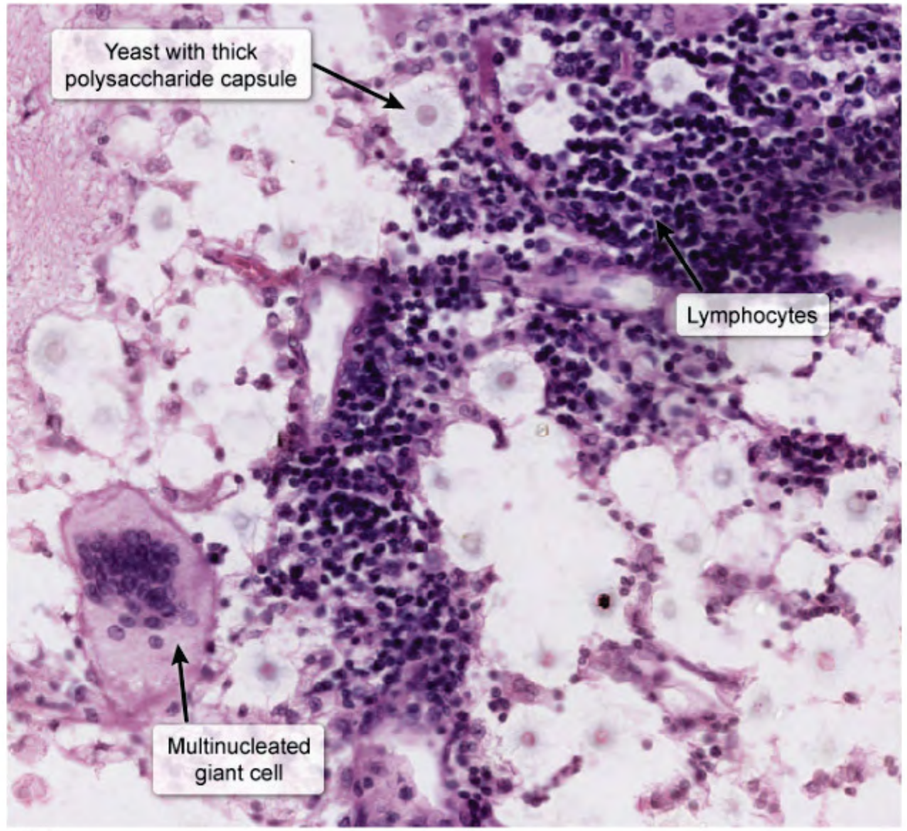

©UWorld

Zoom In | Zoom Out | Reset | New | Existing | My Notebook

https://t.me/USMLEWorldStep1
Show all

Histoplasma capsulatum is a dimorphic fungus that is endemic to the Ohio and Mississippi River valleys. It exists as a fil… Theref… coops… *H cap*… tempe… pathog… replica… intrace… Sprea… contai… *tuberc*… **subac**… lymph… throug… **(Choi**… *C neo*… cause… advan… **(Choi**… pulmo… (not M… **(Choi**… asperg…

Exhibit Display

Coccidioidomycosis

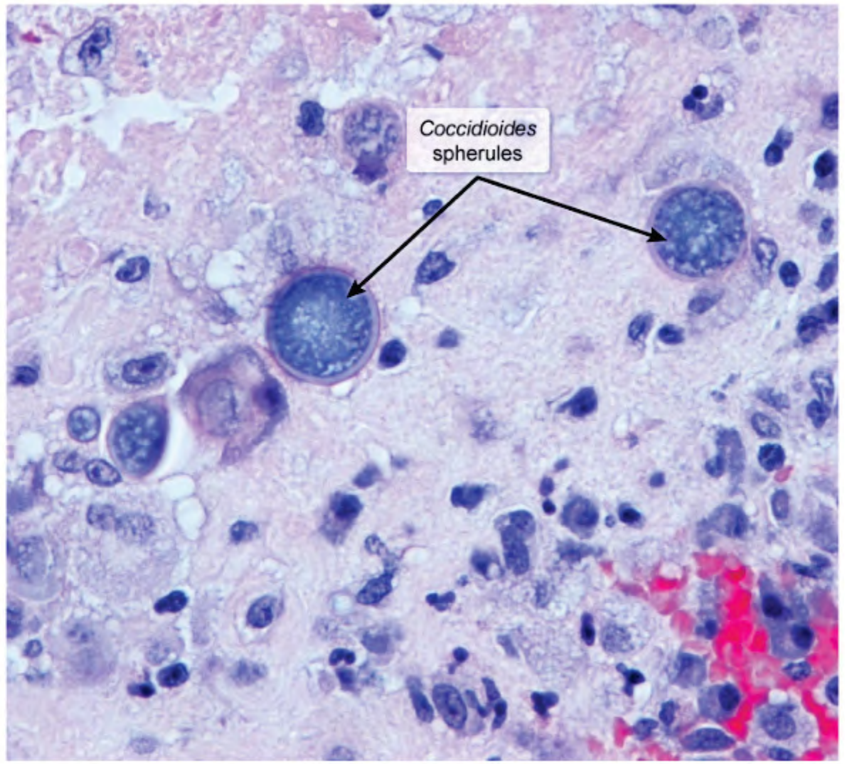

©UWorld

Zoom In | Zoom Out | Reset | New | Existing | My Notebook

(Choice E) *Candida* species are yeasts that form pseudohyphae and blastoconidia (budded cells off of the

https://t.me/USMLEWorldStep1
Show all

Histoplasma capsulatum is a dimorphic fungus that is endemic to the Ohio and Mississippi River valleys. It exists as a filamentous mold in the environment and is found primarily in soil contaminated with **bird or bat droppings**.

Theref
coops

H cap
tempe
pathog
replica
intrace

Sprea
contai
tuberc
subac
lymph
throug

(Choi
C neo
cause
advan

(Choi
pulmo
(not M

(Choi
asperg

(Choi

Exhibit Display

Aspergillus

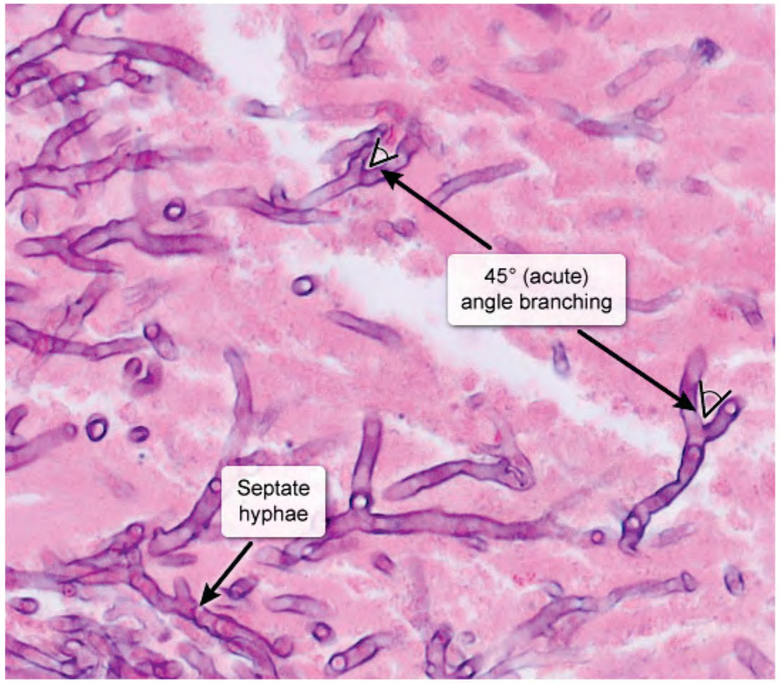

©UWorld

Zoom In | Zoom Out | Reset | New | Existing | My Notebook

https://t.me/USMLEWorldStep1
Show all

pathogen eludes macrophage-mediated destruction by preventing acidification of the phagolysosome and initially replicates in an unchecked fashion. Therefore, light microscopy of the affected areas reveals macrophages with intrace

Sprea
contai
tuberc
subac
lymph
throug

(Choi
C neo
cause
advan

(Choi
pulmo
(not M

(Choi
asperg

(Choi
pseud

Educa
Histop
contar
intrace

develop subacute pneumonia with hilar and mediastinal lymphadenopathy.

Exhibit Display

Candida

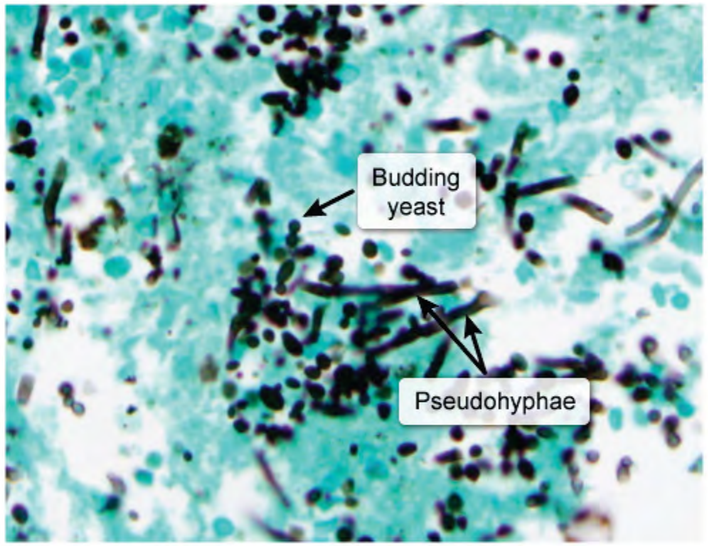

©UWorld

Zoom In | Zoom Out | Reset | New | Existing | My Notebook

https://t.me/USMLEWorldStep1
Show all

A 32-year-old man presents with low grade fever, cough and generalized malaise. The patient has otherwise been healthy and has no significant medical history. His past surgical history includes tonsillectomy and tympanostomy tube placement at the age of 8. Careful questioning reveals that the patient recently came back from an "outdoor adventure" trip in the Great Lakes, and began feeling sick only after returning. Microscopic examination of a KOH preparation of an exudate specimen reveals a large yeast cell with a single bud. When incubated in a specific medium at 75.2°F (24°C), a multicellular structure with branching, tubular cells grows. The patient is most likely infected with which of the following:

- A. *Aspergillus fumigatus*
- B. *Blastomyces dermatitidis*
- C. *Candida albicans*
- D. *Cryptococcus neoformans*
- E. *Malassezia furfur*
- F. *Rhizopus species*

Submit

https://t.me/USMLEWorldStep1
Show all

A 32-year-old man presents with low grade fever, cough and generalized malaise. The patient has otherwise been healthy and has no significant medical history. His past surgical history includes tonsillectomy and tympanostomy tube placement at the age of 8. Careful questioning reveals that the patient recently came back from an "outdoor adventure" trip in the Great Lakes, and began feeling sick only after returning. Microscopic examination of a KOH preparation of an exudate specimen reveals a large yeast cell with a single bud. When incubated in a specific medium at 75.2ºF (24ºC), a multicellular structure with branching, tubular cells grows. The patient is most likely infected with which of the following:

- A. *Aspergillus fumigatus* (12%)
- ✓ B. *Blastomyces dermatitidis* (61%)
- C. *Candida albicans* (14%)
- D. *Cryptococcus neoformans* (4%)
- E. *Malassezia furfur* (3%)
- F. *Rhizopus species* (3%)

Correct

61%
Answered correctly

04 secs
Time Spent

2023
Version

Explanation

Certain fungal species display different morphologic characteristics in different environments. These fungi are "**dimorphic**," forming molds (with hyphae) in ambient temperatures (25-30ºC) and yeasts (single cells) at body temperature (37ºC). Five species of thermally dimorphic fungi are medically important and tested on the USMLE Step1. A comparison table is provided below for study purposes:

https://t.me/USMLEWorldStep1
Show all

Explanation

Certain fungal species display different morphologic characteristics in different environments. These fungi are "**dimorphic**," forming molds (with hyphae) in ambient temperatures (25-30ºC) and yeasts (single cells) at body temperature (37ºC). Five species of thermally dimorphic fungi are medically important and tested on the USMLE Step1. A comparison table is provided below for study purposes:

Fungal species	**Epidemiology**	**Clinical presentation**	**Laboratory diagnosis**
Sporothrix schenckii	Associated with gardening; often transmitted via a thorn prick.	Pustules, ulcers, and subcutaneous nodules along the lymphatics.	Culture (25ºC): branching hyphae. Biopsy: round or cigar-shaped budding yeasts.
Coccidioides immitis	Southwestern states (desert areas). Mold form is present in soil.	Pulmonary form: flu-like illness, cough, erythema nodosum. Disseminated form: affects skin, bones, and lungs.	Culture (25ºC): forms hyphae. Biopsy: at 37º forms **thick-walled spherules** filled with endospores.
Histoplasma	Ohio and Mississippi River valleys.	Pulmonary: similar to tuberculosis (lung granulomas with	Culture (25ºC): branching hyphae. Biopsy:

https://t.me/USMLEWorldStep1
Show all

Certain fungal species display different morphologic characteristics in different environments. These fungi are "**dimorphic**," forming molds (with hyphae) in ambient temperatures (25-30ºC) and yeasts (single cells) at body temperature (37ºC). Five species of thermally dimorphic fungi are medically important and tested on the USMLE Step1. A comparison table is provided below for study purposes:

Fungal species	**Epidemiology**	**Clinical presentation**	**Laboratory diagnosis**
Sporothrix schenckii	Associated with gardening; often transmitted via a thorn prick.	Pustules, ulcers, and subcutaneous nodules along the lymphatics.	Culture (25ºC): branching hyphae. Biopsy: round or cigar-shaped budding yeasts.
Coccidioides immitis	Southwestern states (desert areas). Mold form is present in soil.	Pulmonary form: flu-like illness, cough, erythema nodosum. Disseminated form: affects skin, bones, and lungs.	Culture (25ºC): forms hyphae. Biopsy: at 37º forms **thick-walled spherules** filled with endospores.
Histoplasma capsulatum	Ohio and Mississippi River valleys. Soil, bird and bat droppings	Pulmonary: similar to tuberculosis (lung granulomas with calcifications). Disseminated:	Culture (25ºC): branching hyphae. Biopsy: oval yeast cells **within**

https://t.me/USMLEWorldStep1
Show all

Histoplasma capsulatum	Ohio and Mississippi River valleys. Soil, bird and bat droppings (chicken coops, caves).	Pulmonary: similar to tuberculosis (lung granulomas with calcifications). Disseminated: lungs, spleen, liver	Culture (25ºC): branching hyphae. Biopsy: oval yeast cells **within macrophages.**
Blastomyces dermatitidis	Ohio and Mississippi River valleys, Great Lakes region. Found in soil.	Pulmonary: pneumonia. Disseminated form is common and severe.	Culture (25ºC): branching hyphae. Biopsy: large, round yeasts with **doubly refractile wall** and **single broad-based bud**.
Paracoccidioides brasiliensis	Central and South America	Mucocutaneous: chronic mucocutaneous or cutaneous ulcers, can progress to lymph nodes and lungs	Culture (25ºC): multiple blastoconidia. Biopsy: cells covered in budding blastoconidia

https://t.me/USMLEWorldStep1
Show all

Paracoccidioides brasiliensis	Central and South America	mucocutaneous or cutaneous ulcers, can progress to lymph nodes and lungs	blastoconidia. Biopsy: cells covered in budding blastoconidia

(Choice A) *Aspergillus fumigatus* has a mold form only and is not dimorphic. It is seen in biopsy specimens as septate hyphae that form acute angle V-shaped branches. *Aspergillus* mainly affects immunocompromised patients.

(Choice C) *Candida albicans* is a component of normal human flora. It causes disseminated infections in immunocompromised patients. It is polymorphic, and it is commonly seen as a budding yeast or forming pseudohyphae. True hyphae also occur, usually only when *Candida* becomes invasive (in early stages, these hyphae can be identified as germ tubes).

(Choice D) *Cryptococcus neoformans* causes meningitis in AIDS patients. This fungus exists in yeast form only. India ink stain of CSF reveals encapsulated yeast.

(Choice E) *Malassezia furfur* causes a cutaneous mycosis (hypopigmented skin patches). KOH preparation of skin scrapings shows short hyphae and spores ("spaghetti and meatballs").

(Choice F) *Rhizopus*, *Mucor*, and *Absidia* are the saprophytic fungi that cause mucormycosis in immunosuppressed patients. Mold forms of Rhizopus and Mucor are found with nonseptate hyphae and wide angle branching (90°). The typical presentation is a paranasal infection in diabetic ketoacidosis patients. Broad non-septate hyphae are seen in tissue specimens.

Educational Objective:
Dimorphic fungi grow as molds at 25-30°C and as yeast at body temperature (35-37°C). Medically important dimorphic fungi include *Sporothrix*, *Coccidioides*, *Histoplasma*, *Blastomyces* and *Paracoccidioides* species.

References

Coccidioidomycosis and other endemic mycoses in Mexico

https://t.me/USMLEWorldStep1
Show all

A 24-year-old man comes to the office due to nonproductive cough, subjective fevers, right-sided pleuritic chest pain, and increasing dyspnea for the past 4 weeks. He was empirically treated for pneumonia with levofloxacin at an urgent care center 2 weeks ago but has had no improvement. The patient is an exchange student from the Philippines. Temperature is 37.3 C (99.1 F), blood pressure is 118/66 mm Hg, pulse is 90/min, and respirations are 20/min. Physical examination is remarkable for decreased right-sided breath sounds. Chest x-ray shows a large, right-sided pleural effusion. Pleural fluid is drained, and a subsequent chest CT scan reveals right upper lobe infiltrate and calcified hilar adenopathy. This patient's pleural fluid analysis is most likely to demonstrate which of the following findings?

- A. Cytology positive for atypical cells
- B. Elevated fluid triglyceride level
- C. Fluid protein concentration >4.0 g/dL
- D. Normal lactate dehydrogenase level
- E. Predominant neutrophilic leukocytosis

Submit

https://t.me/USMLEWorldStep1
Show all

A 24-year-old man comes to the office due to nonproductive cough, subjective fevers, right-sided pleuritic chest pain, and increasing dyspnea for the past 4 weeks. He was empirically treated for pneumonia with levofloxacin at an urgent care center 2 weeks ago but has had no improvement. The patient is an exchange student from the Philippines. Temperature is 37.3 C (99.1 F), blood pressure is 118/66 mm Hg, pulse is 90/min, and respirations are 20/min. Physical examination is remarkable for decreased right-sided breath sounds. Chest x-ray shows a large, right-sided pleural effusion. Pleural fluid is drained, and a subsequent chest CT scan reveals right upper lobe infiltrate and calcified hilar adenopathy. This patient's pleural fluid analysis is most likely to demonstrate which of the following findings?

- A. Cytology positive for atypical cells (8%)
- ✗ B. Elevated fluid triglyceride level (2%)
- ✓ C. Fluid protein concentration >4.0 g/dL (60%)
- D. Normal lactate dehydrogenase level (7%)
- E. Predominant neutrophilic leukocytosis (19%)

Incorrect
Correct answer
C

60%
Answered correctly

04 secs
Time Spent

2023
Version

Explanation

Exudative & transudative pleural effusions		
	Exudate	**Transudate**
	Pleural protein/serum protein	

https://t.me/USMLEWorldStep1
Show all

Exudative & transudative pleural effusions		
	Exudate	**Transudate**
Light criteria	Pleural protein/serum protein >0.5 **OR** Pleural LDH/serum LDH >0.6 **OR** Pleural LDH greater than two-thirds upper limit of normal of serum LDH	Exudate criteria not met
Pathophysiology	Inflammatory increase in membrane permeability	Change in hydrostatic or oncotic pressure
Common causes	• Infection (eg, pneumonia, TB) • Malignancy • Rheumatologic disease	• Heart failure • Cirrhosis (hepatic hydrothorax) • Nephrotic syndrome
LDH = lactate dehydrogenase; **TB** = tuberculosis.		

This patient's clinical findings are consistent with **reactivation tuberculosis**, given his nonresponse to routine pneumonia treatment, prior residence in an endemic region (ie, Southeast Asia), and CT scan showing calcified hilar adenopathy (representing granulomatous lymph node involvement). Reactivation tuberculosis typically affects the upper lobes of the lungs and is often associated with **pleural effusion**.

Pulmonary infection causes pleural effusion primarily via an **inflammatory** increase in vascular and pleural

https://t.me/USMLEWorldStep1
Show all

This patient's clinical findings are consistent with **reactivation tuberculosis**, given his nonresponse to routine pneumonia treatment, prior residence in an endemic region (ie, Southeast Asia), and CT scan showing calcified hilar adenopathy (representing granulomatous lymph node involvement). Reactivation tuberculosis typically affects the upper lobes of the lungs and is often associated with **pleural effusion**.

Pulmonary infection causes pleural effusion primarily via an **inflammatory** increase in vascular and pleural membrane permeability, leading to relatively **high pleural fluid protein and lactate dehydrogenase (LDH)** concentration **(Choice D)**. Such effusions are **exudative** by Light criteria, with pleural fluid/serum protein ratio >0.5, pleural fluid/serum LDH ratio >0.6, and/or pleural fluid LDH >⅔ the upper limit of normal serum LDH. Normal serum total protein ranges from 6.0 g/dL to 7.8 g/dL; therefore, **pleural fluid protein >4 g/dL** (ratio >0.5) is most likely in this patient.

(Choice A) Pleural fluid cytology showing atypical cells can be seen with a malignant pleural effusion, but is not expected with tuberculous effusion. Malignant effusions are also typically exudative by Light criteria.

(Choice B) An elevated pleural fluid triglyceride level is diagnostic of a chylothorax, which results from disruption (eg, trauma, malignant invasion) of the thoracic duct leading to leakage of chylomicron-rich lymphatic fluid into the pleural space.

(Choice E) Tuberculosis pleural effusions are typically lymphocyte predominant. Neutrophil predominance is expected with a typical parapneumonic effusion (eg, due to community-acquired bacterial pneumonia).

Educational objective:
Pulmonary infection (eg, community-acquired pneumonia, tuberculosis) causes pleural effusion primarily via an inflammatory increase in vascular and pleural membrane permeability. Such effusions are exudative by Light criteria, typically with relatively high pleural fluid protein and lactate dehydrogenase concentrations. Tuberculosis pleural effusions typically demonstrate a lymphocyte-predominant leukocyte pattern.

References

- Diagnostic approach to pleural effusion in adults.

https://t.me/USMLEWorldStep1

This patient's clinical findings are consistent with **reactivation tuberculosis**, given his nonresponse to routine

pneum
hilar a
the up

Pulmo
memb
concer
>0.5, p
serum
likely i

(Choi
expect

(Choi
(eg, tra
pleura

(Choi
expect

Educa
Pulmo
inflam
criteria
pleura

Refere
- Dia

Exhibit Display

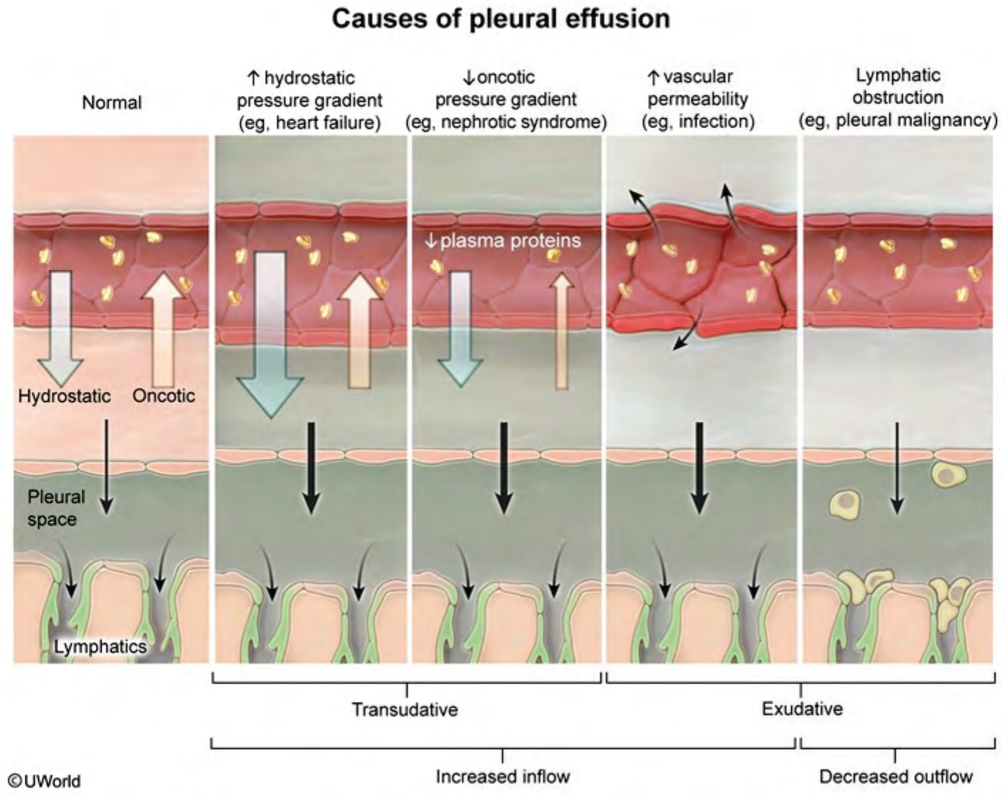

Zoom In | Zoom Out | Reset | New | Existing | My Notebook

https://t.me/USMLEWorldStep1

A 22-year-old man is brought to the emergency department after being involved in a fight at a nearby bar. The patient's respiratory rate is 28/min, blood pressure is 88/60 mm Hg, and heart rate is 114/min. Physical examination shows a penetrating right-sided stab wound along the upper surface of the clavicle between the lateral border of the sternum and the midclavicular line. Which of the following structures was most likely injured?

- A. Accessory nerve
- B. Ansa cervicalis
- C. Carotid body
- D. Inferior thyroid artery
- E. Lung pleura

Submit

https://t.me/USMLEWorldStep1
Show all

A 22-year-old man is brought to the emergency department after being involved in a fight at a nearby bar. The patient's respiratory rate is 28/min, blood pressure is 88/60 mm Hg, and heart rate is 114/min. Physical examination shows a penetrating right-sided stab wound along the upper surface of the clavicle between the lateral border of the sternum and the midclavicular line. Which of the following structures was most likely injured?

- ✗ A. Accessory nerve (5%)
- B. Ansa cervicalis (6%)
- C. Carotid body (12%)
- D. Inferior thyroid artery (6%)
- ✓ E. Lung pleura (68%)

Incorrect
Correct answer
E

68%
Answered correctly

04 secs
Time Spent

2023
Version

Explanation

Normal chest x-ray

https://t.me/USMLEWorldStep1
Show all

A 22-year-old man is brought to the emergency department after being involved in a fight at a nearby bar. The patien
exami
border

Inco
Corre
E

Expl

Exhibit Display

Normal chest x-ray

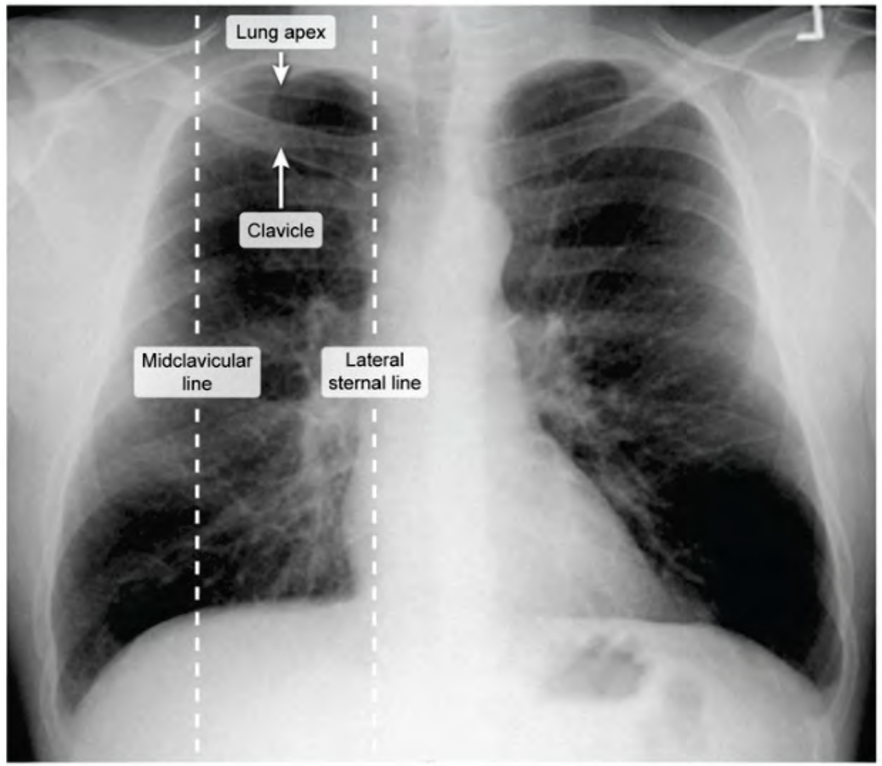

©UWorld

Zoom In Zoom Out Reset New | Existing My Notebook

Clavicle

https://t.me/USMLEWorldStep1

©UWorld

In patients with neck injuries, it is important to remember that the **lung apices** and cervical pleura extend **above the clavicle and first rib** through the superior thoracic aperture. Stab wounds immediately above the clavicle and lateral to the manubrium can puncture the pleura and cause pneumothorax, tension pneumothorax, or hemothorax.

This patient most likely has a **tension pneumothorax** as a result of his pleural injury. As an increasing volume of air accumulates within the pleural space, the lungs and mediastinum deviate to the opposite side of the chest. Increased pressure within the chest cavity decreases systemic venous return to the heart, **lowering cardiac output**. Signs and symptoms of tension pneumothorax include tachycardia, **hypotension**, tachypnea, hypoxemia, and hyperresonance to percussion and absence of breath sounds on the affected side. Treatment is with emergency needle thoracostomy or chest tube.

(Choice A) The accessory nerve (cranial nerve XI) innervates the sternocleidomastoid and trapezius muscles. This nerve may be injured during surgery involving the posterior triangle of the neck (a region bounded by the sternocleidomastoid muscle, trapezius muscle, and clavicle).

(Choice B) The ansa cervicalis arises from the C1, C2, and C3 nerve roots and innervates the sternohyoid, sternothyroid, and omohyoid muscles of the anterior neck. Penetrating trauma to the neck above the cricoid cartilage can injure this nerve.

(Choice C) The carotid body, which contains O_2, CO_2, and H^+ chemoreceptors, lies at the bifurcation of the common carotid artery (just inferior to the hyoid bone).

(Choice D) The inferior thyroid artery arises from the thyrocervical trunk and courses posterior to the carotid artery and jugular vein to supply the inferior pole of the thyroid gland. Injury to the inferior thyroid artery is commonly associated with hoarseness because it runs adjacent to the recurrent laryngeal nerve.

Educational objective:
The lung apices extend above the level of the clavicle and first rib through the superior thoracic aperture. Penetrating injury in this area may lead to pneumothorax, tension pneumothorax, or hemothorax.

https://t.me/USMLEWorldStep1
Show all

©UWorld

In patients with neck injuries, it is important to remember that the **lung apices** and cervical pleura extend **above**
the cl
lateral

This p
air acc
Increa
outpu
and hy
emerg

(Choi
This n
sterno

(Choi
sterno
cartila

(Choi
comm

(Choi
and ju
associ

Educa
The lu
Penetr

Exhibit Display

Pneumothorax

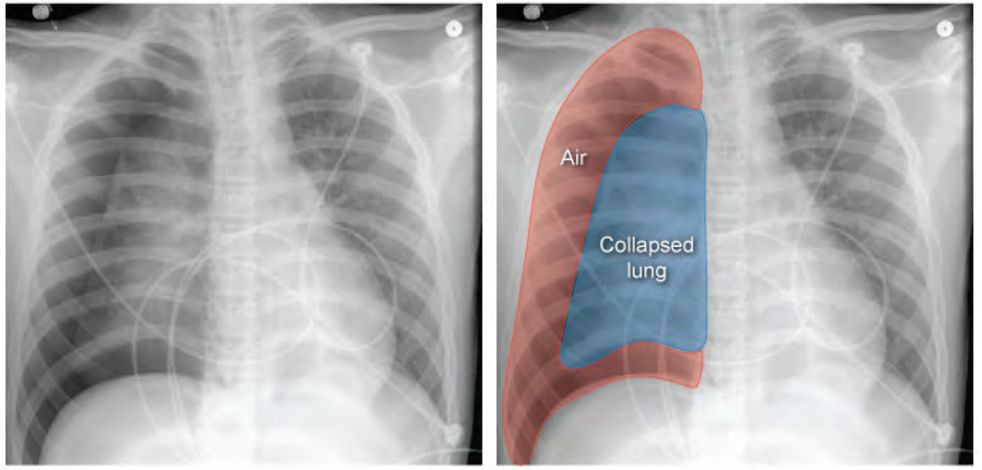

©UWorld

Zoom In | Zoom Out | Reset | New | Existing | My Notebook

https://t.me/USMLEWorldStep1

A 34-year-old man is hospitalized due to trauma sustained during a motor vehicle collision. He subsequently develops worsening shortness of breath and confusion and dies despite appropriate management. Autopsy examination shows scattered petechiae on the anterior thorax. Microscopic evaluation of his pulmonary vessels reveals the findings shown below.

Which of the following most likely predisposed this patient to developing the observed histopathologic abnormality?

- A. Aspiration of gastric contents
- B. Left ventricular dysfunction
- C. Long-bone fracture
- D. Severe systemic infection
- E. Thrombosis in the deep veins

Submit

https://t.me/USMLEWorldStep1
Show all

A 34-year-old man is hospitalized due to trauma sustained during a motor vehicle collision. He subsequently develo
exami
reveal

Exhibit Display

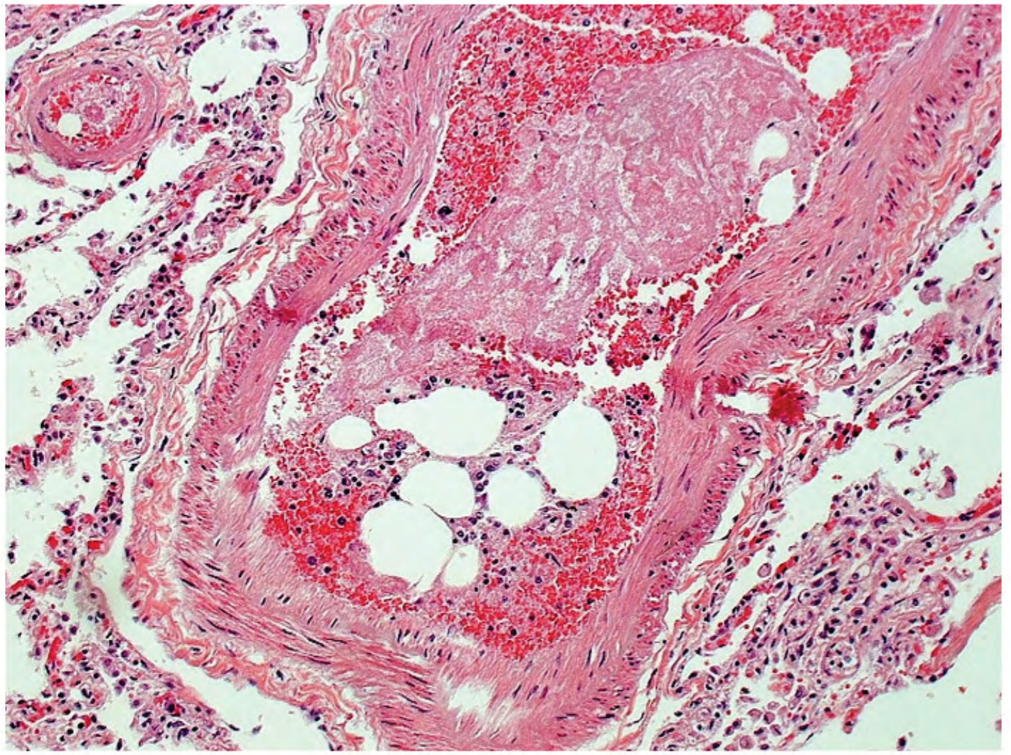

Zoom In | Zoom Out | Reset | New | Existing | My Notebook

Which

B. Left ventricular dysfunction

https://t.me/USMLEWorldStep1
Show all

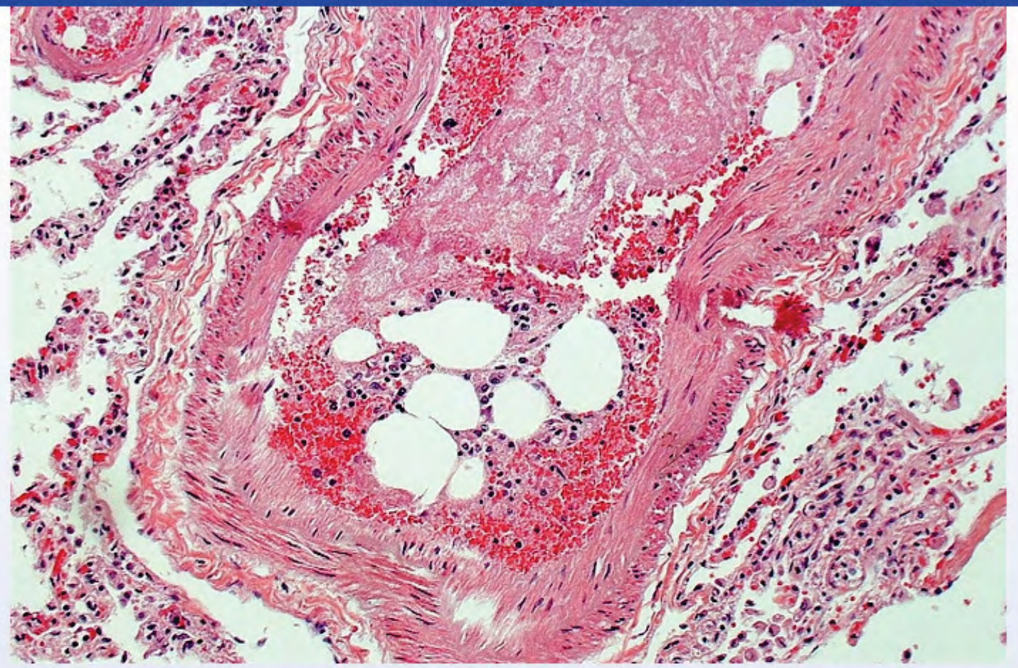

Which of the following most likely predisposed this patient to developing the observed histopathologic abnormality?

- A. Aspiration of gastric contents
- B. Left ventricular dysfunction
- C. Long-bone fracture
- D. Severe systemic infection
- E. Thrombosis in the deep veins

Submit

https://t.me/USMLEWorldStep1
Show all

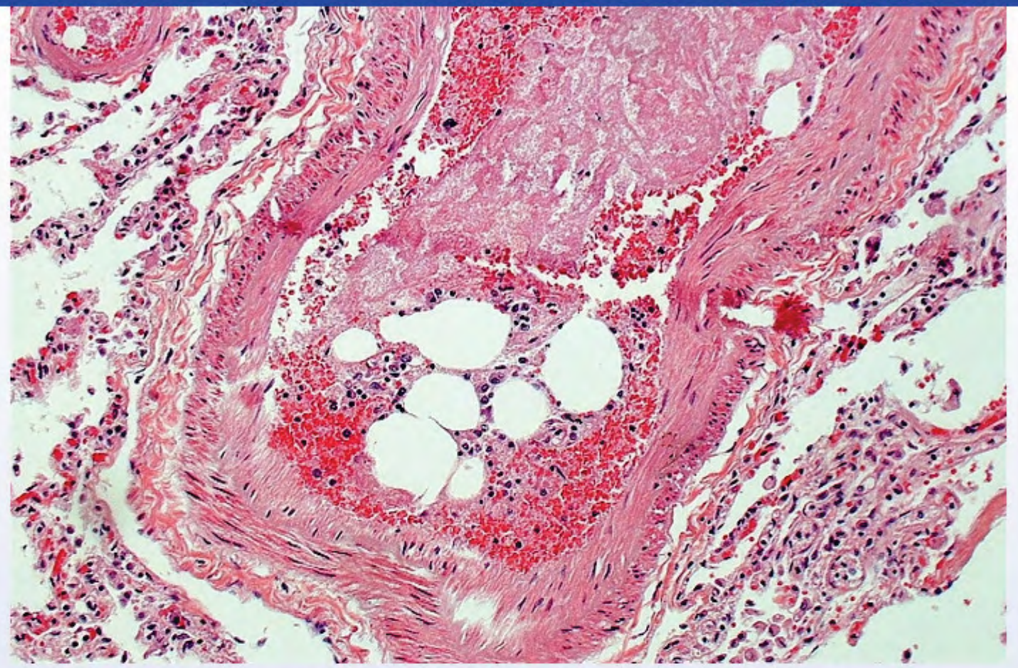

Which of the following most likely predisposed this patient to developing the observed histopathologic abnormality?

- A. Aspiration of gastric contents (1%)
- ✗ B. Left ventricular dysfunction (2%)
- ✓ C. Long-bone fracture (87%)
- D. Severe systemic infection (2%)
- E. Thrombosis in the deep veins (6%)

Incorrect
Correct answer
C

87%
Answered correctly

11 secs
Time Spent

2023
Version

https://t.me/USMLEWorldStep1
Show all

Expl

Exhibit Display

Bone marrow embolus

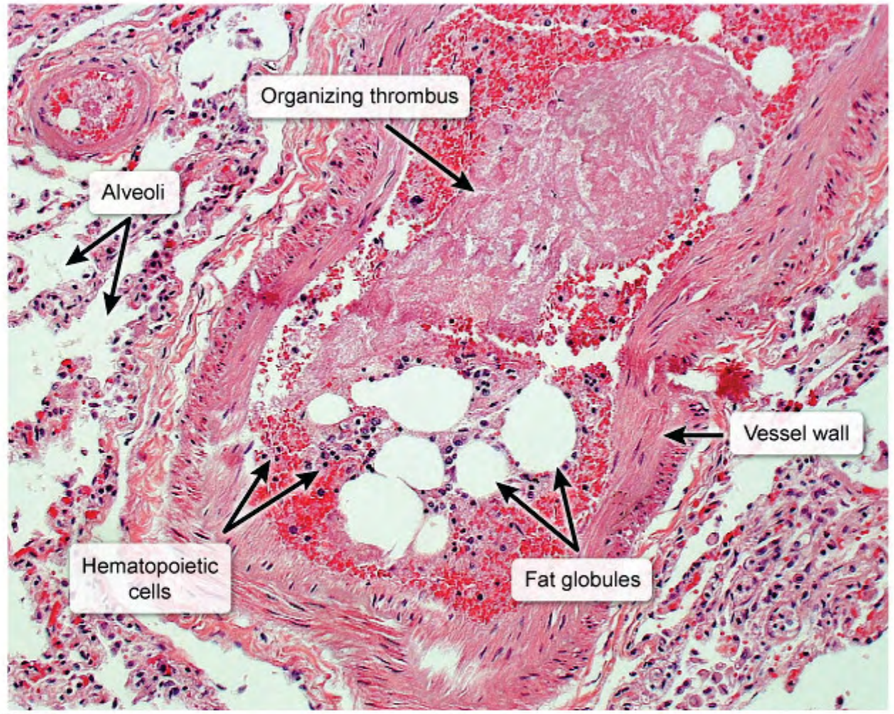

©UWorld

Zoom In | Zoom Out | Reset | New | Existing | My Notebook

The hi
thromb
in **fat embolism syndrome** (FES).

FES classically presents with the triad of **respiratory distress**, **neurologic impairment**, and **petechial rash** within

https://t.me/USMLEWorldStep1

The histologic section of this patient's lung shows an aggregate of fat globules, hematopoietic cells, and organizing thrombus lodged inside the pulmonary vasculature. This is consistent with bone marrow embolism, which occurs in **fat embolism syndrome** (FES).

FES classically presents with the triad of **respiratory distress**, **neurologic impairment**, and **petechial rash** within **24-72 hours** following a **long-bone or pelvic fracture**. Severe skeletal injuries can cause fat globules to be dislodged from bone marrow into the bloodstream, where they form aggregates with platelets and red blood cells. These aggregates occlude pulmonary microvessels and impair gas exchange. Some fat emboli may be small enough to pass through the pulmonary circulation and cause microvascular occlusion in the systemic circulation, leading to the neurologic manifestations (eg, confusion) and petechial rash characterizing the condition. Release of toxic inflammatory mediators (eg, cytokines, free fatty acids) may also contribute to the neurologic manifestations and rash. Thrombocytopenia can occur due to platelet adherence and aggregation to circulating fat globules.

(Choice A) Aspiration of gastric contents can lead to aspiration pneumonitis or aspiration pneumonia. The lung parenchyma would demonstrate polymorphonuclear leukocyte infiltration and multinucleated foreign body giant cells.

(Choice B) Left ventricular dysfunction can lead to heart failure and pulmonary edema. Over time, alveolar fibrosis develops and there is accumulation of hemosiderin-laden macrophages, also known as heart failure cells.

(Choice D) Severe systemic infection, or sepsis, can lead to acute respiratory distress syndrome, in which parenchymal inflammation leads to accumulation of interstitial fluid and fluid leakage in the alveoli. Histopathology often shows diffuse alveolar damage.

(Choice E) Thrombosis in the deep veins can lead to acute pulmonary embolism. Due to localized ischemia, the adjacent lung parenchyma can demonstrate coagulative necrosis and hemorrhage.

Educational objective:
Fat embolism syndrome most commonly results from the release of fat globules from bone marrow following a

https://t.me/USMLEWorldStep1
Show all

FES classically presents with the triad of **respiratory distress**, **neurologic impairment**, and **petechial rash** within **24-72 hours** following a **long-bone or pelvic fracture**. Severe skeletal injuries can cause fat globules to be dislodged from bone marrow into the bloodstream, where they form aggregates with platelets and red blood cells. These aggregates occlude pulmonary microvessels and impair gas exchange. Some fat emboli may be small enough to pass through the pulmonary circulation and cause microvascular occlusion in the systemic circulation, leading to the neurologic manifestations (eg, confusion) and petechial rash characterizing the condition. Release of toxic inflammatory mediators (eg, cytokines, free fatty acids) may also contribute to the neurologic manifestations and rash. Thrombocytopenia can occur due to platelet adherence and aggregation to circulating fat globules.

(Choice A) Aspiration of gastric contents can lead to aspiration pneumonitis or aspiration pneumonia. The lung parenchyma would demonstrate polymorphonuclear leukocyte infiltration and multinucleated foreign body giant cells.

(Choice B) Left ventricular dysfunction can lead to heart failure and pulmonary edema. Over time, alveolar fibrosis develops and there is accumulation of hemosiderin-laden macrophages, also known as heart failure cells.

(Choice D) Severe systemic infection, or sepsis, can lead to acute respiratory distress syndrome, in which parenchymal inflammation leads to accumulation of interstitial fluid and fluid leakage in the alveoli. Histopathology often shows diffuse alveolar damage.

(Choice E) Thrombosis in the deep veins can lead to acute pulmonary embolism. Due to localized ischemia, the adjacent lung parenchyma can demonstrate coagulative necrosis and hemorrhage.

Educational objective:
Fat embolism syndrome most commonly results from the release of fat globules from bone marrow following a long-bone or pelvic fracture. The fat globules form inflammatory aggregates that cause microvessel obstruction and systemic inflammation leading to the triad of respiratory distress, neurologic dysfunction, and petechial rash.

Pathology Pulmonary & Critical Care Fat embolism

https://t.me/USMLEWorldStep1
Show all

dislodged from bone marrow into the bloodstream, where they form aggregates with platelets and red blood cells.

These
enoug
leadin
of toxi
manife
globul

(Choi
paren
cells.

(Choi
fibrosi

(Choi
paren
often s

(Choi
adjace

Educa
Fat em
long-b
and sy

Pathol
Subject

Exhibit Display

Chronic pulmonary congestion

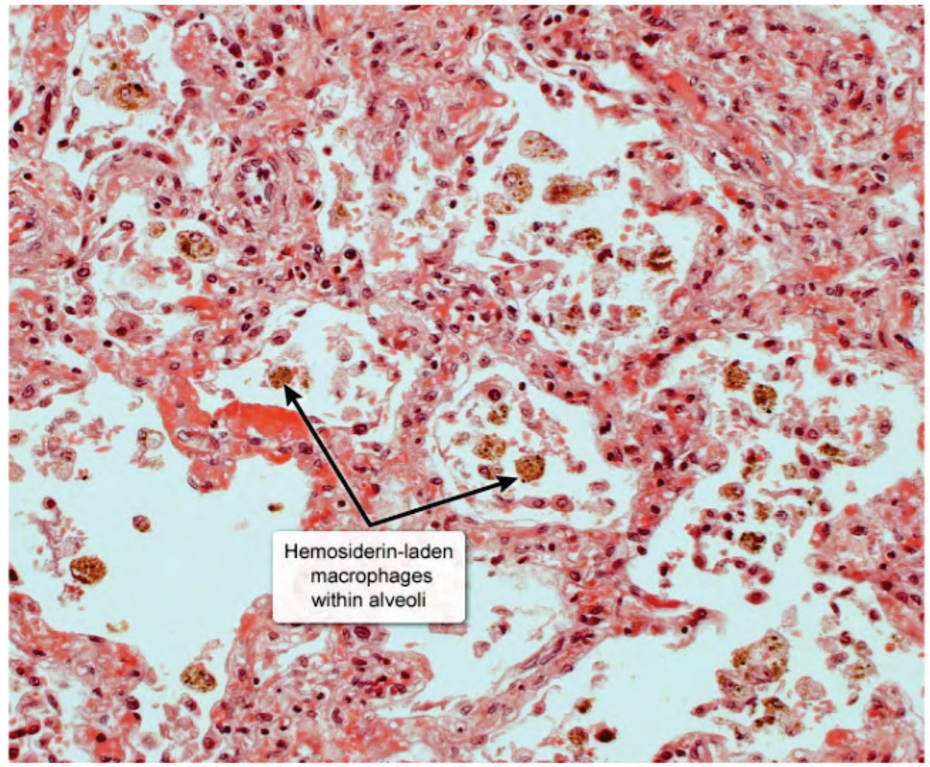

©UWorld

Zoom In | Zoom Out | Reset | New | Existing | My Notebook

Copyright © UWorld. All rights reserved.

https://t.me/USMLEWorldStep1

dislodged from bone marrow into the bloodstream, where they form aggregates with platelets and red blood cells.

These
enoug
leadin
of toxi
manife
globul

(Choi
paren
cells.

(Choi
fibrosi

(Choi
paren
often s

(Choi
adjace

Educa
Fat em
long-b
and sy

Pathol
Subject

Exhibit Display

Diffuse alveolar damage

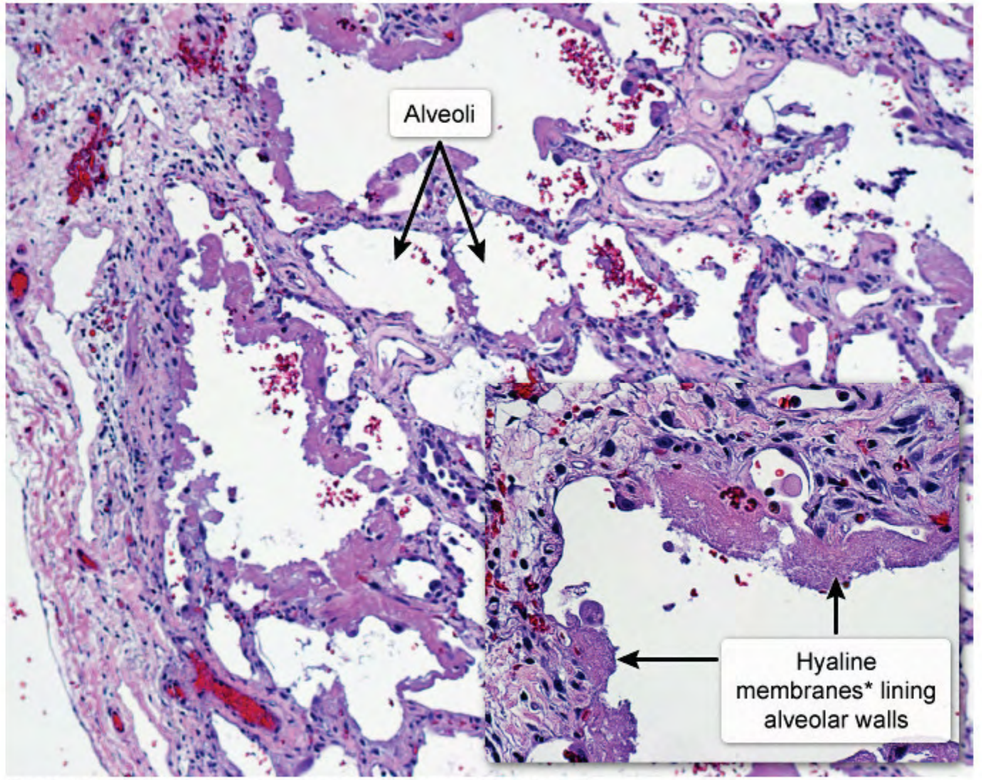

*Dense pink material composed of plasma proteins and necrotic epithelial cells

©UWorld

Zoom In | Zoom Out | Reset | New | Existing | My Notebook

https://t.me/USMLEWorldStep1

dislodged from bone marrow into the bloodstream, where they form aggregates with platelets and red blood cells.

These
enoug
leadin
of toxi
manife
globul

(Choi
paren
cells.

(Choi
fibrosi

(Choi
paren
often s

(Choi
adjace

Educa
Fat em
long-b
and sy

Pathol
Subject

Exhibit Display

Pulmonary embolus

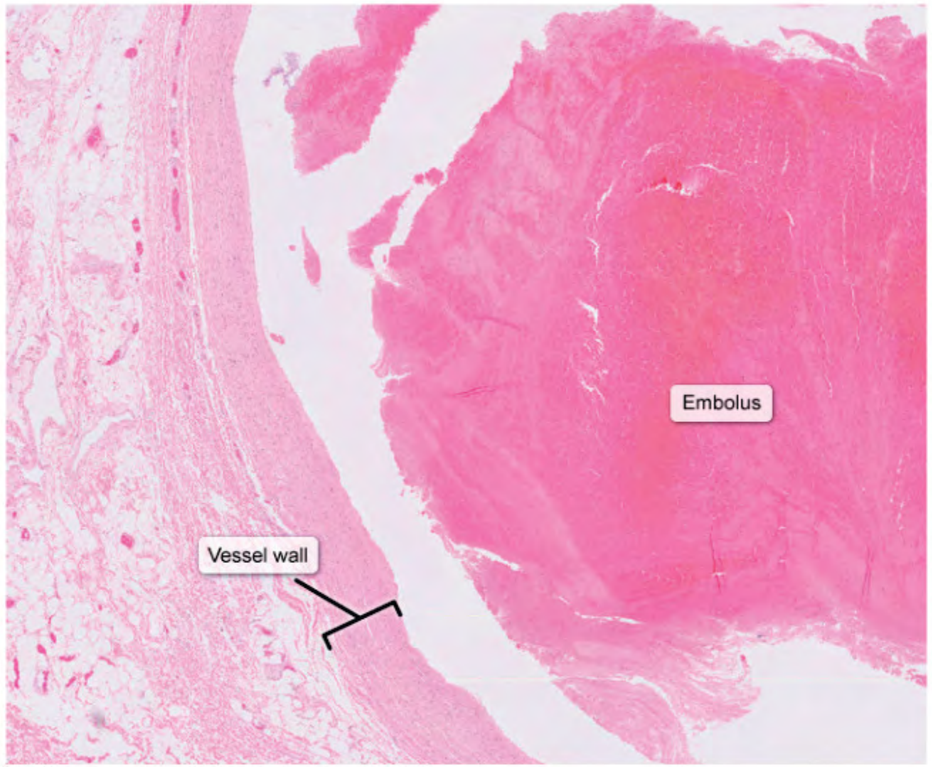

©UWorld

Zoom In | Zoom Out | Reset | New | Existing | My Notebook

Copyright © UWorld. All rights reserved.

https://t.me/USMLEWorldStep1

A 62-year-old man is evaluated for persistent dry cough and exertional dyspnea that has progressed over the past year. He has had difficulty accomplishing normal daily activities. The patient has no significant medical history and takes no medications. He smoked cigarettes for 10 years and quit 25 years ago. The patient works as an investment banker and does not use alcohol or illicit drugs. Vital signs are normal. Physical examination shows bilateral inspiratory crackles and digital clubbing. CT scan of the chest is shown in the exhibit. Which of the following changes are most likely present in this patient's lung tissue?

	Type 1 pneumocytes	Type 2 pneumocytes	Basement membrane	Fibroblasts
○ A.	Decreased	Decreased	Intact	Increased
○ B.	Decreased	Increased	Abnormal	Increased
○ C.	Decreased	Increased	Intact	Decreased
○ D.	Increased	Decreased	Abnormal	Decreased
○ E.	Increased	Decreased	Abnormal	Increased

Submit

https://t.me/USMLEWorldStep1
Show all

Item 25 of 40
Question Id: 666
Mark
Previous
Next
Full Screen
Tutorial
Lab Values
Notes
Calculator
Reverse Color
Text Zoom
Settings

A 62-year-old man is evaluated for persistent dry cough and exertional dyspnea that has progressed over the past year.
takes
investi
bilater
followi

Sub

Exhibit Display

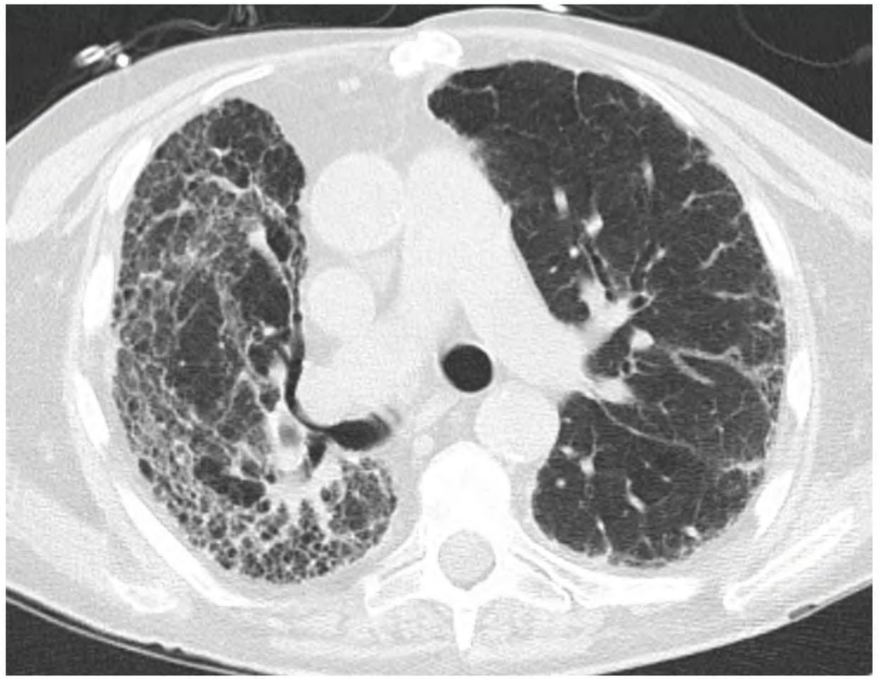

Zoom In Zoom Out Reset New | Existing My Notebook

https://t.me/USMLEWorldStep1

A 62-year-old man is evaluated for persistent dry cough and exertional dyspnea that has progressed over the past year. He has had difficulty accomplishing normal daily activities. The patient has no significant medical history and takes no medications. He smoked cigarettes for 10 years and quit 25 years ago. The patient works as an investment banker and does not use alcohol or illicit drugs. Vital signs are normal. Physical examination shows bilateral inspiratory crackles and digital clubbing. CT scan of the chest is shown in the exhibit. Which of the following changes are most likely present in this patient's lung tissue?

	Type 1 pneumocytes	Type 2 pneumocytes	Basement membrane	Fibroblasts	
A.	Decreased	Decreased	Intact	Increased	(32%)
✓ B.	Decreased	Increased	Abnormal	Increased	(52%)
C.	Decreased	Increased	Intact	Decreased	(1%)
D.	Increased	Decreased	Abnormal	Decreased	(0%)
E.	Increased	Decreased	Abnormal	Increased	(13%)

Correct

52% Answered correctly

15 secs Time Spent

2023 Version

Explanation

Idiopathic pulmonary fibrosis

https://t.me/USMLEWorldStep1

Exhibit Display

Idiopathic pulmonary fibrosis

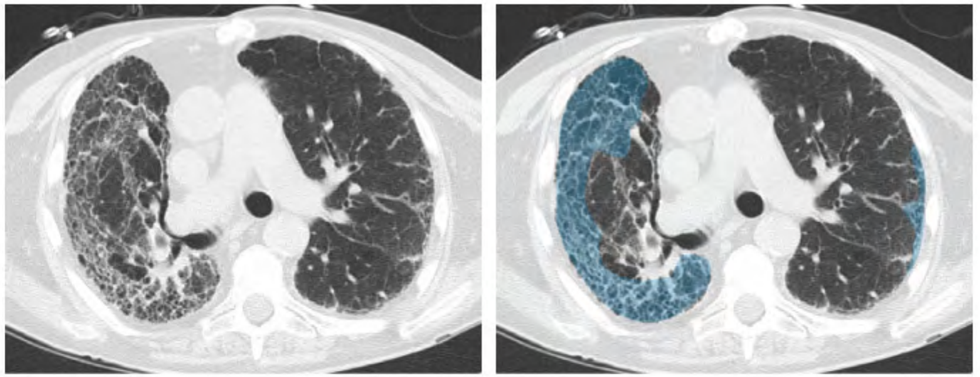

Peripheral honeycombing

©UWorld

Zoom In | Zoom Out | Reset | New | Existing | My Notebook

histologically defined by foci of fibroblast proliferation and dense collagen deposition intermixed with unaffected

https://t.me/USMLEWorldStep1

This patient's chronic progressive dyspnea, nonproductive cough, digital clubbing, and inspiratory crackles are concerning for interstitial lung disease. CT reveals peripheral reticular infiltrates (ie, thickened, linear interstitial markings) with **subpleural honeycombing** (ie, multiple cystic spaces with irregularly thickened walls), which strongly suggests **idiopathic pulmonary fibrosis** (IPF). IPF is a chronic, fibrosing interstitial pneumonia that is histologically defined by foci of fibroblast proliferation and dense collagen deposition intermixed with unaffected lung (ie, usual interstitial pneumonia pattern).

The pathogenesis of IPF is thought to be driven by **repetitive epithelial injury** (eg, smoking, acid reflux) followed by **disordered repair**:

1. Repetitive lung microinjuries result in the **loss of type 1 pneumocytes**, which compose 95% of the gas-exchanging alveolar surface area **(Choice E)**.
2. Type 1 pneumocytes are incapable of replication. Therefore, normal repair requires the proliferation of type 2 pneumocytes, with subsequent differentiation into type 1 pneumocytes to reestablish the alveolar epithelial lining.
3. In IPF, **type 2 pneumocytes** undergo **reactive hyperplasia** but fail to differentiate into type 1 cells because of dysfunctional cell fate pathways (eg, Wnt/transforming growth factor-beta) and abnormalities of the underlying basement membrane **(Choices A and C)**.
4. Impaired re-epithelialization causes lung **fibroblasts** to undergo **focal proliferation** and begin secreting excessive amounts of collagen, leading to interstitial fibrosis **(Choice D)**.
5. The fibrosis exerts radial traction on the distal airways, leading to dilation of the terminal bronchioles and producing the honeycomb appearance characteristic of IPF.

Educational objective:
Idiopathic pulmonary fibrosis is an interstitial lung disease characterized by chronic progressive dyspnea, nonproductive cough, inspiratory crackles, and subpleural (peripheral) lung honeycombing. In IPF, repetitive microinjury to the alveolar epithelium (eg, smoking, acid reflux) is focally repaired by fibroblast

https://t.me/USMLEWorldStep1
Show all

strongly suggests **idiopathic pulmonary fibrosis** (IPF). IPF is a chronic, fibrosing interstitial pneumonia that is histologically defined by foci of fibroblast proliferation and dense collagen deposition intermixed with unaffected lung (ie, usual interstitial pneumonia pattern).

The pathogenesis of IPF is thought to be driven by **repetitive epithelial injury** (eg, smoking, acid reflux) followed by **disordered repair**:

1. Repetitive lung microinjuries result in the **loss of type 1 pneumocytes**, which compose 95% of the gas-exchanging alveolar surface area **(Choice E)**.
2. Type 1 pneumocytes are incapable of replication. Therefore, normal repair requires the proliferation of type 2 pneumocytes, with subsequent differentiation into type 1 pneumocytes to reestablish the alveolar epithelial lining.
3. In IPF, **type 2 pneumocytes** undergo **reactive hyperplasia** but fail to differentiate into type 1 cells because of dysfunctional cell fate pathways (eg, Wnt/transforming growth factor-beta) and abnormalities of the underlying basement membrane **(Choices A and C)**.
4. Impaired re-epithelialization causes lung **fibroblasts** to undergo **focal proliferation** and begin secreting excessive amounts of collagen, leading to interstitial fibrosis **(Choice D)**.
5. The fibrosis exerts radial traction on the distal airways, leading to dilation of the terminal bronchioles and producing the honeycomb appearance characteristic of IPF.

Educational objective:
Idiopathic pulmonary fibrosis is an interstitial lung disease characterized by chronic progressive dyspnea, nonproductive cough, inspiratory crackles, and subpleural (peripheral) lung honeycombing. In IPF, repetitive microinjury to the alveolar epithelium (eg, smoking, acid reflux) is focally repaired by fibroblast proliferation/collagen deposition instead of normal restoration via type 2 pneumocyte differentiation.

Subject	System	Topic
Pathology	Pulmonary & Critical Care	Interstitial lung disease

https://t.me/USMLEWorldStep1
Show all

strongly suggests **idiopathic pulmonary fibrosis** (IPF). IPF is a chronic, fibrosing interstitial pneumonia that is

histolo

lung (i

The pa

by **dis**

1. R e
2. T p li
3. In d b
4. In e
5. T p

Educa

Idiopa

nonpr

microi

prolife

Pathol

Subject

Exhibit Display

Alveoli

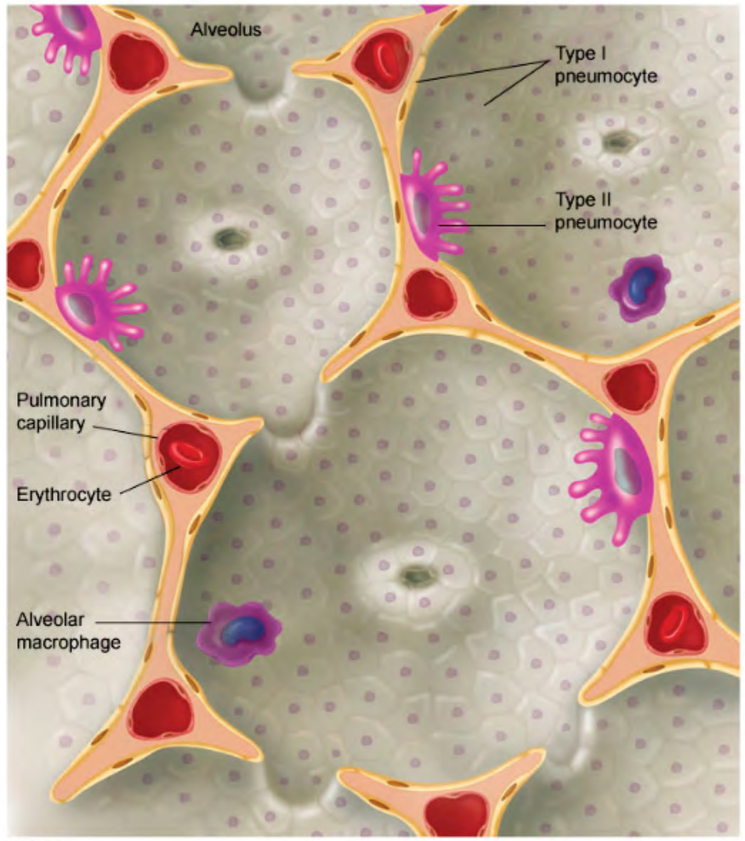

Zoom In | Zoom Out | Reset | New | Existing | My Notebook

https://t.me/USMLEWorldStep1

A 38-year-old man comes to the office with reports of dyspnea on exertion and decreased exercise tolerance. His medical history is unremarkable, and he has no history of childhood asthma or cough. He has never smoked and has no known occupational exposures. The patient has gained almost 100 lb over the past 4 years since leaving the military due to a sedentary lifestyle. He currently weighs 135 kg (297.6 lb) and has a BMI of 41 kg/m^2. His respiratory rate is 22/min and pulse oximetry is 93% on room air at rest. Physical examination is notable for central obesity. Lungs are clear on auscultation bilaterally. Which of the following changes (forced expiratory volume in 1 second [FEV_1], forced vital capacity [FVC], expiratory reserve volume [ERV], residual volume [RV], and total lung capacity [TLC]) are most likely to be seen on pulmonary function testing in this patient?

	FEV_1	FVC	ERV	RV	TLC
○ A.	↓	↓	↓	Normal	↓
○ B.	↓	↓	Normal	↑	↑
○ C.	↓	Normal	Normal	↑	↑
○ D.	↑	↑	↓	Normal	Normal
○ E.	↑	Normal	↑	↑	↑

Submit

https://t.me/USMLEWorldStep1
Show all

A 38-year-old man comes to the office with reports of dyspnea on exertion and decreased exercise tolerance. His medical history is unremarkable, and he has no history of childhood asthma or cough. He has never smoked and has no known occupational exposures. The patient has gained almost 100 lb over the past 4 years since leaving the military due to a sedentary lifestyle. He currently weighs 135 kg (297.6 lb) and has a BMI of 41 kg/m^2. His respiratory rate is 22/min and pulse oximetry is 93% on room air at rest. Physical examination is notable for central obesity. Lungs are clear on auscultation bilaterally. Which of the following changes (forced expiratory volume in 1 second [FEV_1], forced vital capacity [FVC], expiratory reserve volume [ERV], residual volume [RV], and total lung capacity [TLC]) are most likely to be seen on pulmonary function testing in this patient?

	FEV_1	FVC	ERV	RV	TLC	
✓ A.	↓	↓	↓	Normal	↓	(63%)
✗ B.	↓	↓	Normal	↑	↑	(15%)
C.	↓	Normal	Normal	↑	↑	(6%)
D.	↑	↑	↓	Normal	Normal	(12%)
E.	↑	Normal	↑	↑	↑	(3%)

Incorrect
Correct answer
A

63%
Answered correctly

04 secs
Time Spent

2023
Version

Explanation

Lung volumes & capacities

https://t.me/USMLEWorldStep1
Show all

E. ↑ Normal ↑ ↑ ↑ (3%)

Inco
Corre
A

Expl

This y
diseas
ability
diminis
compli
increa

Exhibit Display

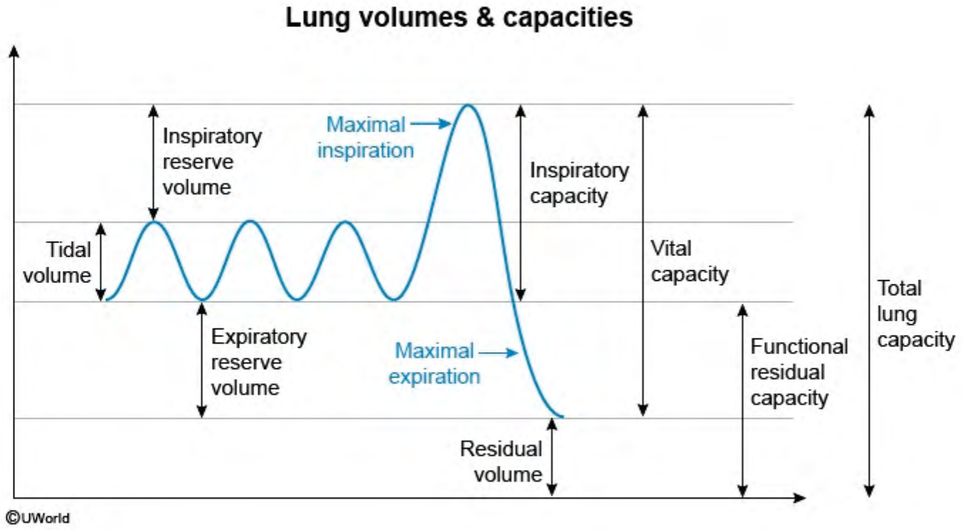

Zoom In Zoom Out Reset New | Existing My Notebook

https://t.me/USMLEWorldStep1

Show all

This young patient presenting with respiratory symptoms and **central obesity** without a history of pulmonary disease likely has obesity-related **restrictive lung disease**. Obesity alters respiratory compliance, which is the ability of the lung and chest wall to stretch in response to increased lung pressures. Respiratory compliance is diminished both by a reduction in chest wall compliance from increased weight and by a reduction in lung compliance due to microatelectasis. To compensate for the reduced compliance, obese patients typically have increased respiratory rates with reduced tidal volumes (rapid-shallow breathing).

The most common indicator of obesity-related disease is a **reduction** in **expiratory reserve volume** (ERV), which is the maximum volume of air that can be expired after a normal tidal expiration. Obesity has minimal effect on residual volume (RV), but **functional residual capacity**, which is the sum of RV and ERV, is reduced due to the marked reduction in ERV. Obesity can also cause reductions of forced vital capacity (FVC), forced expiratory volume in 1 second (FEV_1), and total lung capacity (TLC), depending on the severity of obesity and body fat distribution (abdominal obesity causes greater impairment). However, these reductions are generally modest, especially relative to decrements in ERV.

(Choices B and C) These are patterns that may be seen in a patient with chronic obstructive pulmonary disease, with FEV_1 reduced and FVC normal or only mildly diminished in comparison to FEV_1. TLC and RV are increased with emphysema.

(Choices D and E) FEV_1, FVC, and TLC may be increased in trained athletes.

Educational objective:
Obesity, particularly morbid, central obesity, can cause a pattern of extrinsic restrictive pulmonary function tests. The most common indicator of obesity-related disease is a reduction in expiratory reserve volume and functional residual capacity, but forced expiratory volume in 1 second, forced vital capacity, and total lung capacity are also typically decreased.

References

- Altered resting and exercise respiratory physiology in obesity.

https://t.me/USMLEWorldStep1
Show all

A 45-year-old man comes to the emergency department due to several days of cough and fever. His temperature is 38.4 C (101.2 F), blood pressure is 117/76 mm Hg, pulse is 92/min, and respirations are 18/min. Physical examination of the right lung reveals occasional rales and decreased breath sounds at the base. A chest x-ray demonstrates a lung infiltrate, hilar adenopathy, and a right-sided pleural effusion. Lung tissue obtained from the patient reveals the findings in the image below:

Which of the following is the most likely cause of this patient's condition?

- A. *Aspergillus fumigatus*
- B. *Blastomyces dermatitidis*
- C. *Coccidioides immitis*
- D. *Cryptococcus neoformans*
- E. *Cytomegalovirus*
- F. *Histoplasma capsulatum*
- G. *Rhizopus* species
- H. *Sporothrix schenckii*

Submit

https://t.me/USMLEWorldStep1
Show all

A 45-year-old man comes to the emergency department due to several days of cough and fever. His temperature is 38.4
exami
demor
patien

Exhibit Display

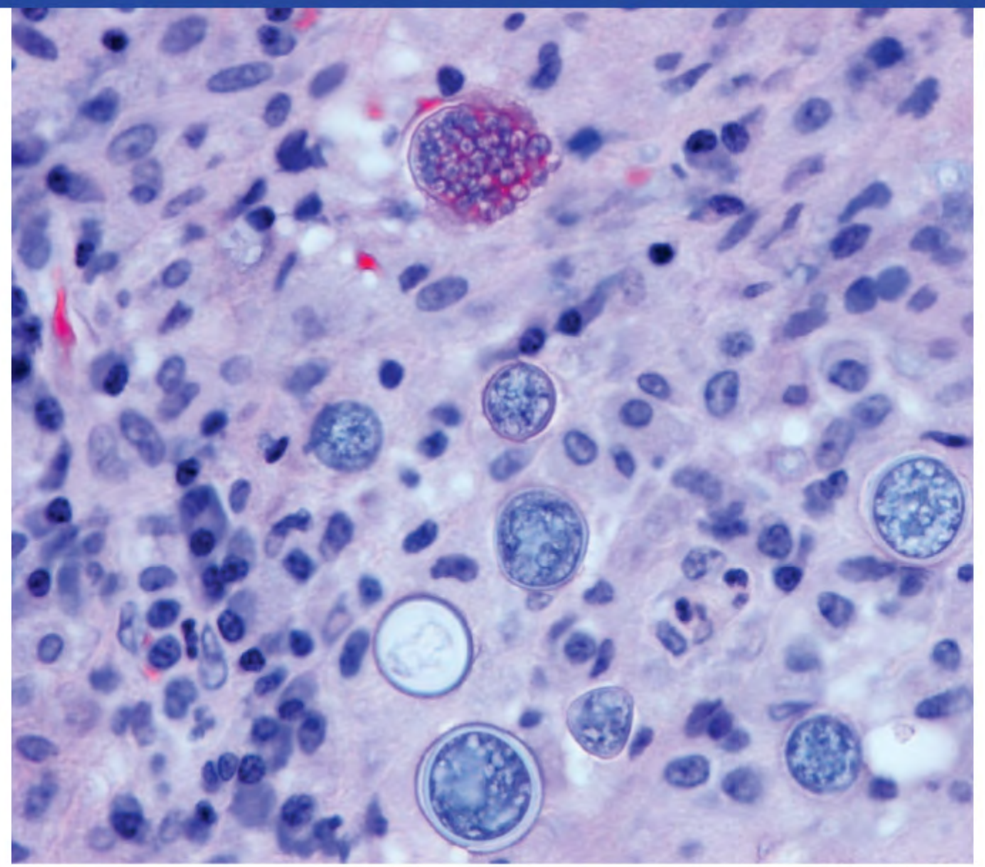

Zoom In Zoom Out Reset New | Existing My Notebook

https://t.me/USMLEWorldStep1

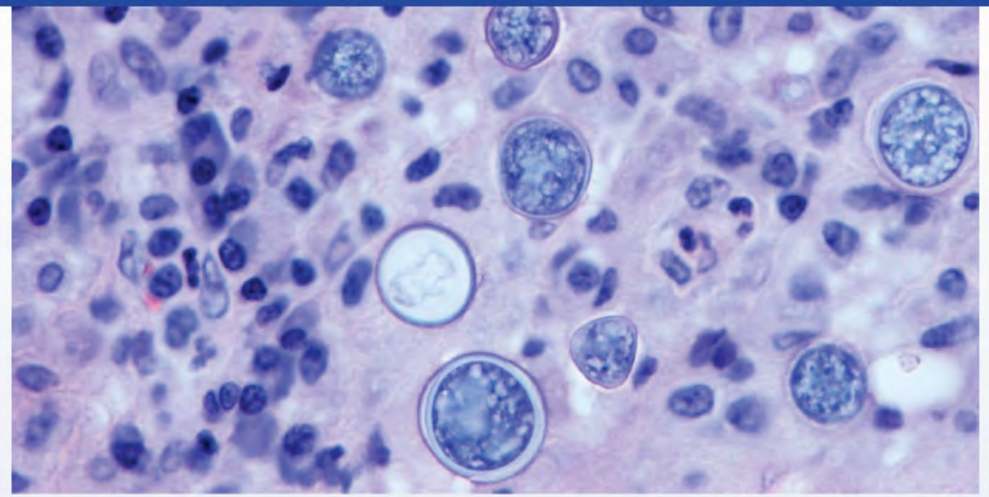

Which of the following is the most likely cause of this patient's condition?

- A. *Aspergillus fumigatus*
- B. *Blastomyces dermatitidis*
- C. *Coccidioides immitis*
- D. *Cryptococcus neoformans*
- E. *Cytomegalovirus*
- F. *Histoplasma capsulatum*
- G. *Rhizopus* species
- H. *Sporothrix schenckii*

Submit

https://t.me/USMLEWorldStep1
Show all

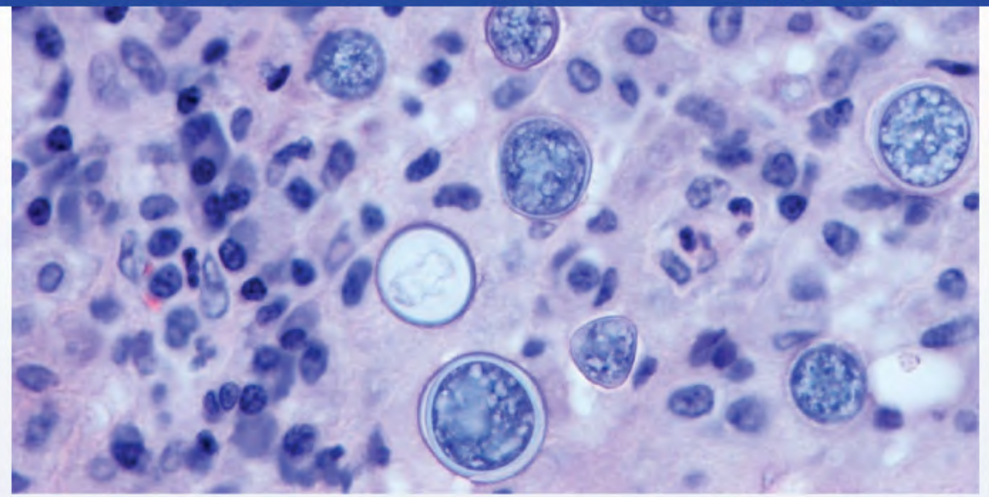

Which of the following is the most likely cause of this patient's condition?

- A. *Aspergillus fumigatus* (3%)
- ✗ B. *Blastomyces dermatitidis* (4%)
- ✓ C. *Coccidioides immitis* (59%)
- D. *Cryptococcus neoformans* (9%)
- E. *Cytomegalovirus* (0%)
- F. *Histoplasma capsulatum* (22%)
- G. *Rhizopus* species (0%)
- H. *Sporothrix schenckii* (0%)

Incorrect
Correct answer
C

59%
Answered correctly

11 secs
Time Spent

2023
Version

https://t.me/USMLEWorldStep1
Show all

F. *Histoplasma capsulatum* (22%)

Exhibit Display

Coccidioides immitis

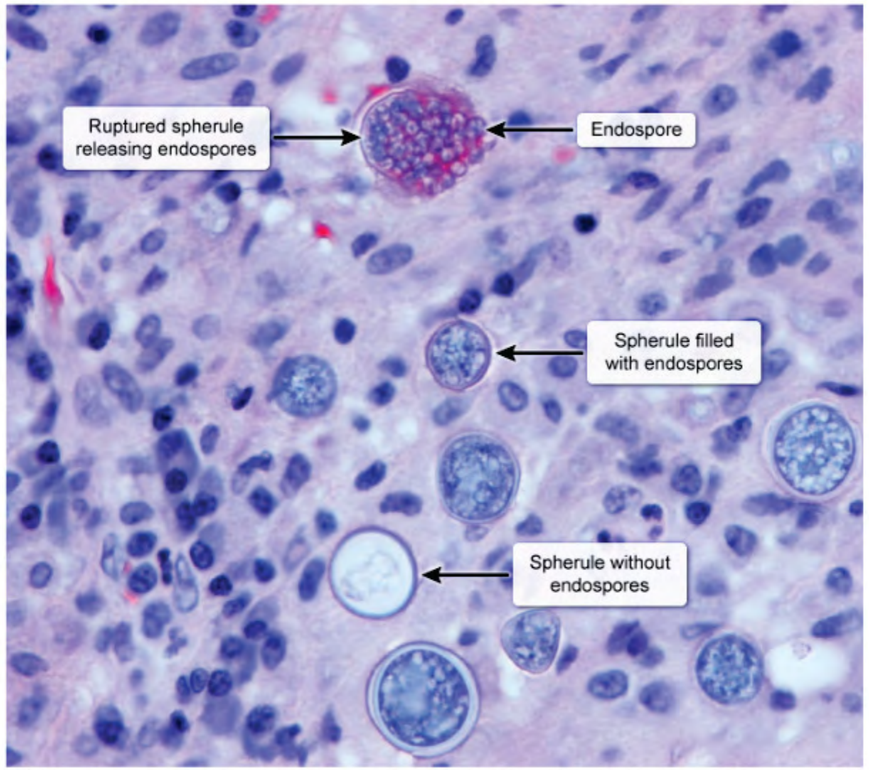

©UWorld

Zoom In Zoom Out Reset New | Existing My Notebook

https://t.me/USMLEWorldStep1

Coccidioides immitis is a dimorphic fungus that is endemic to the desert areas of the United States and Mexico. It can cause lung disease in immunocompetent patients and disseminated disease in the immunocompromised. *Coccidioides* exists in the environment in the form of mold (hyphae); in humans, microscopic examination of affected tissues shows **thick-walled spherules** packed with **endospores**. As seen in the image above, some spherules may be rupturing and others may be empty. The spherules are larger than surrounding red blood cells (RBCs). Culture on Sabouraud agar and serology are also important in making the diagnosis.

(Choice A) *Aspergillus fumigatus* commonly causes pulmonary disease in immunocompromised patients. It has a mold form only. *Aspergillus* have septate hyphae that branch at 45-degree angles.

(Choice B) The characteristic appearance of *Blastomyces dermatitidis* is that of a round yeast with broad-based budding. These yeasts have thick, doubly refractive walls.

(Choice D) *Cryptococcus neoformans* is a yeast with a thick capsule. When tissue specimens infected with *C neoformans* are stained with India ink, the capsule does not absorb the ink, resulting in a clear halo. The most common manifestation of *C neoformans* infection is meningitis, particularly among immunocompromised patients.

(Choice E) *Cytomegalovirus* can cause pneumonia in transplant patients. Prominent intranuclear inclusions surrounded by a clear halo are virtually pathognomonic for pulmonary cytomegalovirus.

(Choice F) *Histoplasma capsulatum* would appear histopathologically as small oval yeast forms within macrophages; unlike the spherules of *Coccidioides, Histoplasma* yeast forms are smaller than surrounding RBCs.

(Choice G) *Rhizopus* species typically cause rhino-orbito-cerebral mucormycosis but can cause lung disease in immunocompromised patients. The species has only a mold form, with broad ribbonlike hyphae with rare septations.

(Choice H) The pustular and ulcerated lesions of sporotrichosis (caused by the fungus *Sporothrix schenckii* and typically acquired by direct skin inoculation [eg, scrapes from rose bushes]) are localized to the site of the wound or associated lymphatic channels. On histologic examination, cigar-shaped yeast may be seen.

Educational objective:

https://t.me/USMLEWorldStep1
Show all

affected tissues shows **thick-walled spherules** packed with **endospores**. As seen in the image above, some spherules may be rupturing and others may be empty. The spherules are larger than surrounding red blood cells (RBCs). Culture on Sabouraud agar and serology are also important in making the diagnosis.

(Choice A) *Aspergillus fumigatus* commonly causes pulmonary disease in immunocompromised patients. It has a mold form only. *Aspergillus* have septate hyphae that branch at 45-degree angles.

(Choice B) The characteristic appearance of *Blastomyces dermatitidis* is that of a round yeast with broad-based budding. These yeasts have thick, doubly refractive walls.

(Choice D) *Cryptococcus neoformans* is a yeast with a thick capsule. When tissue specimens infected with *C neoformans* are stained with India ink, the capsule does not absorb the ink, resulting in a clear halo. The most common manifestation of *C neoformans* infection is meningitis, particularly among immunocompromised patients.

(Choice E) *Cytomegalovirus* can cause pneumonia in transplant patients. Prominent intranuclear inclusions surrounded by a clear halo are virtually pathognomonic for pulmonary cytomegalovirus.

(Choice F) *Histoplasma capsulatum* would appear histopathologically as small oval yeast forms within macrophages; unlike the spherules of *Coccidioides*, *Histoplasma* yeast forms are smaller than surrounding RBCs.

(Choice G) *Rhizopus* species typically cause rhino-orbito-cerebral mucormycosis but can cause lung disease in immunocompromised patients. The species has only a mold form, with broad ribbonlike hyphae with rare septations.

(Choice H) The pustular and ulcerated lesions of sporotrichosis (caused by the fungus *Sporothrix schenckii* and typically acquired by direct skin inoculation [eg, scrapes from rose bushes]) are localized to the site of the wound or associated lymphatic channels. On histologic examination, cigar-shaped yeast may be seen.

Educational objective:
Coccidioides immitis infection can be asymptomatic or it can cause pulmonary disease ranging from a flulike illness to chronic pneumonia. It causes disseminated disease in immunocompromised patients. Spherules containing endospores are found in tissue samples.

https://t.me/USMLEWorldStep1
Show all

Coccidioides immitis is a dimorphic fungus that is endemic to the desert areas of the United States and Mexico.

It can cause lung disease in immunocompetent patients and disseminated disease in the immunocompromised.

Coccid

affecte

spheru

(RBCs

(Choi

mold f

(Choi

buddin

(Choi

neofor

comm

(Choi

surrou

(Choi

macro

(Choi

immun

septat

(Choi

typical

associ

Educational objective:

Exhibit Display

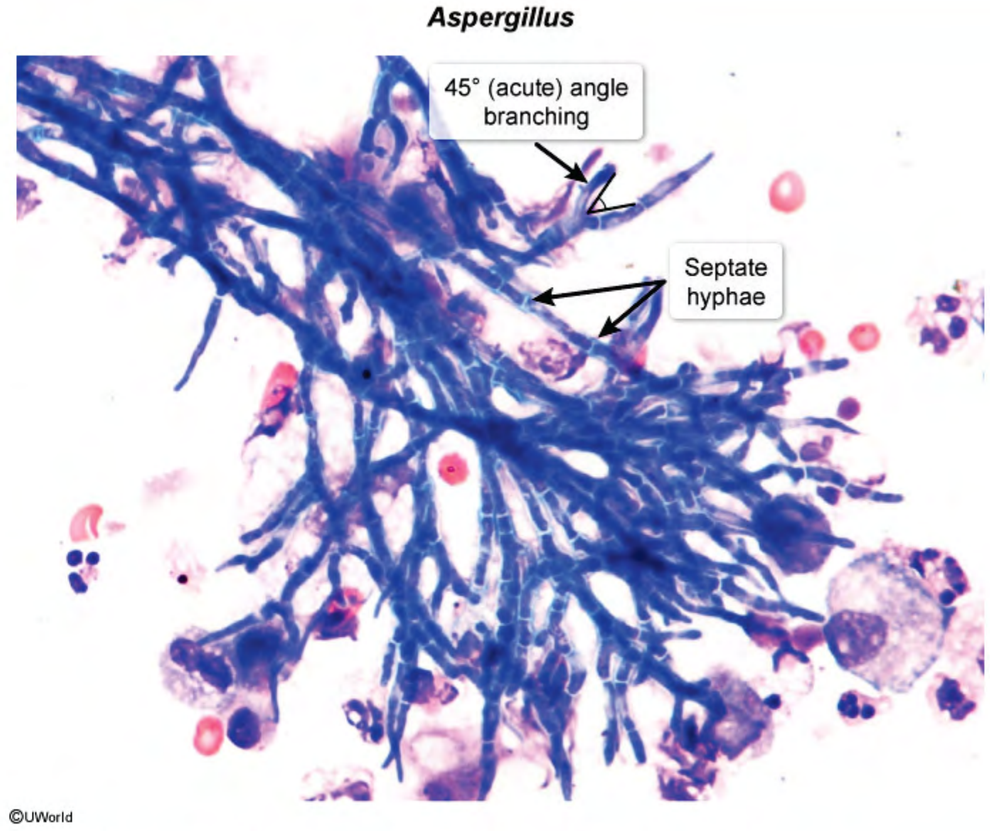

Zoom In | Zoom Out | Reset | New | Existing | My Notebook

https://t.me/USMLEWorldStep1
Show all

Coccidioides immitis is a dimorphic fungus that is endemic to the desert areas of the United States and Mexico.

It can cause lung disease in immunocompetent patients and disseminated disease in the immunocompromised.

Coccid

affecte

spheru

(RBCs

(Choi

mold f

(Choi

buddin

(Choi

neofor

comm

(Choi

surrou

(Choi

macro

(Choi

immun

septat

(Choi

typical

associ

Educational objective:

Exhibit Display

Blastomyces dermatitidis

©UWorld

Zoom In | Zoom Out | Reset | New | Existing | My Notebook

https://t.me/USMLEWorldStep1
Show all

Coccidioides immitis is a dimorphic fungus that is endemic to the desert areas of the United States and Mexico.

It can cause lung disease in immunocompetent patients and disseminated disease in the immunocompromised.

Coccid

affecte

spheru

(RBCs

(Choi

mold f

(Choi

buddin

(Choi

neofor

comm

(Choi

surrou

(Choi

macro

(Choi

immur

septat

(Choi

typical

associ

Educa

Exhibit Display

Cryptococcus

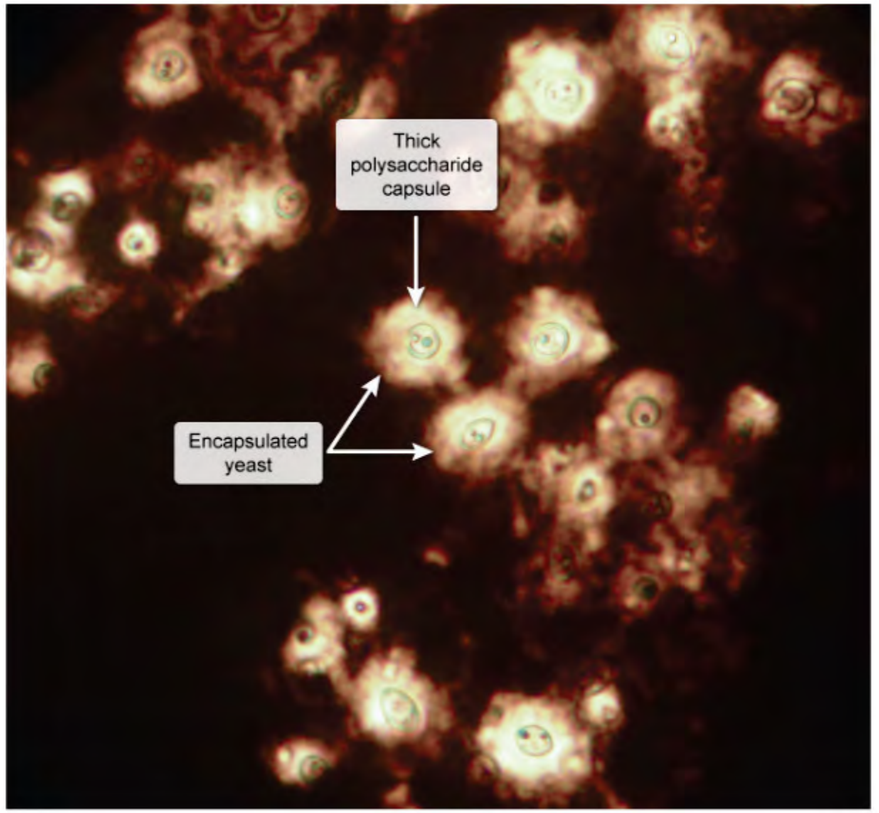

India ink stain

©UWorld

Zoom In | Zoom Out | Reset | New | Existing | My Notebook

https://t.me/USMLEWorldStep1

Coccidioides immitis is a dimorphic fungus that is endemic to the desert areas of the United States and Mexico.

It can cause lung disease in immunocompetent patients and disseminated disease in the immunocompromised.

Coccid

affecte

spheru

(RBCs

(Choi

mold f

(Choi

buddin

(Choi

neofor

comm

(Choi

surrou

(Choi

macro

(Choi

immun

septat

(Choi

typical

associ

Educa

Exhibit Display

Cytomegalovirus

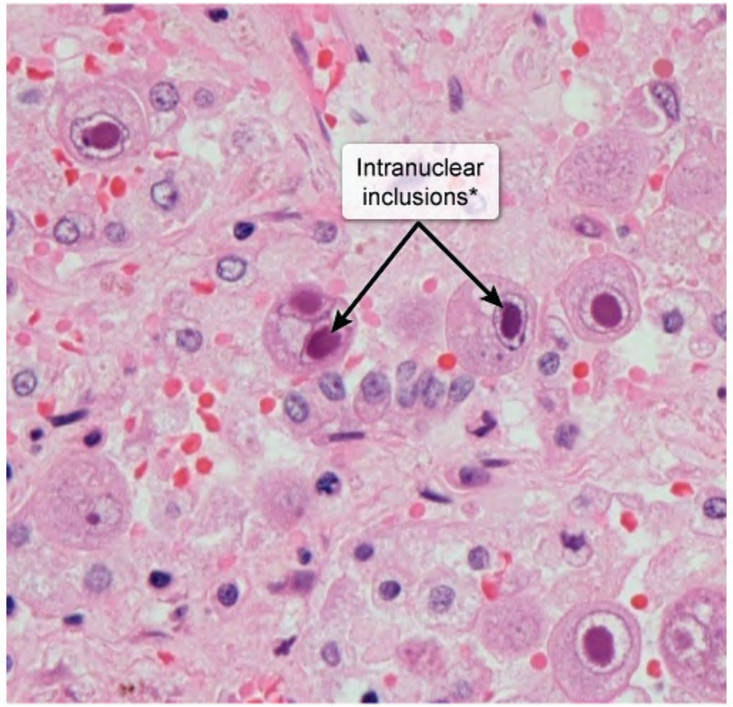

*"Owl's eye" appearance

©UWorld

Zoom In | Zoom Out | Reset | New | Existing | My Notebook

https://t.me/USMLEWorldStep1

Coccidioides immitis is a dimorphic fungus that is endemic to the desert areas of the United States and Mexico.

It can cause lung disease in immunocompetent patients and disseminated disease in the immunocompromised.

Cocci

affecte

spheru

(RBCs

(Choi

mold f

(Choi

buddir

(Choi

neofor

comm

(Choi

surrou

(Choi

macro

(Choi

immur

septat

(Choi

typical

associ

Educa

Exhibit Display

Histoplasma

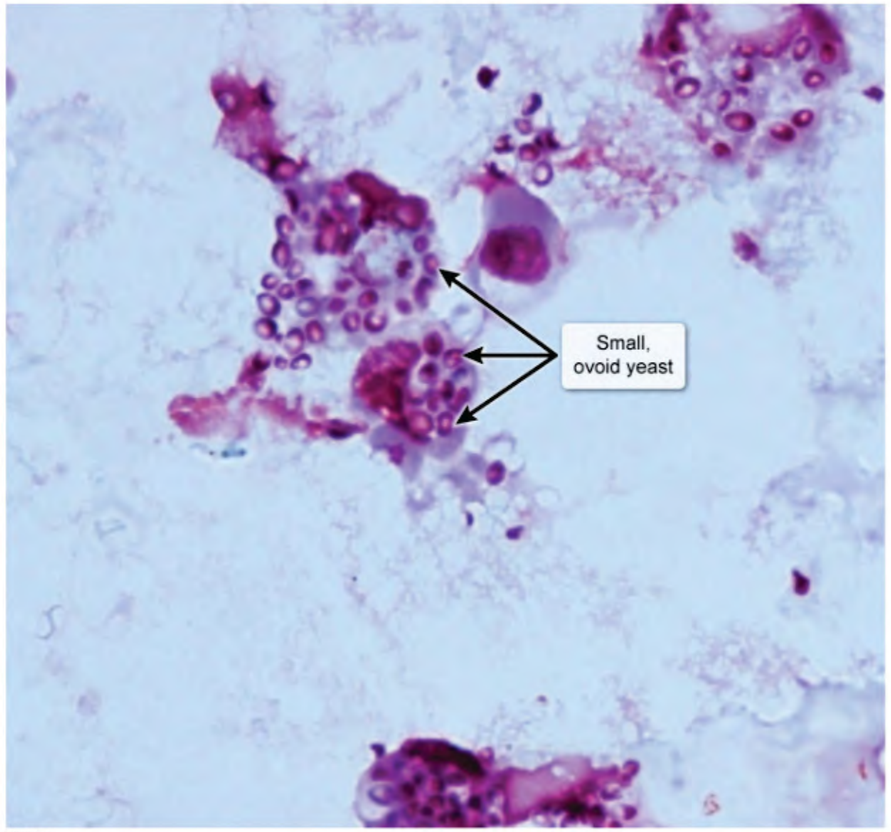

©UWorld

Zoom In | Zoom Out | Reset | New | Existing | My Notebook

https://t.me/USMLEWorldStep1

Coccidioides immitis is a dimorphic fungus that is endemic to the desert areas of the United States and Mexico.

It can cause lung disease in immunocompetent patients and disseminated disease in the immunocompromised.

Coccid

affecte

spheru

(RBCs

(Choi

mold f

(Choi

buddin

(Choi

neofor

comm

(Choi

surrou

(Choi

macro

(Choi

immur

septat

(Choi

typical

associ

Educa

Exhibit Display

Invasive fungal sinusitis due to mucormycosis (zygomycosis)

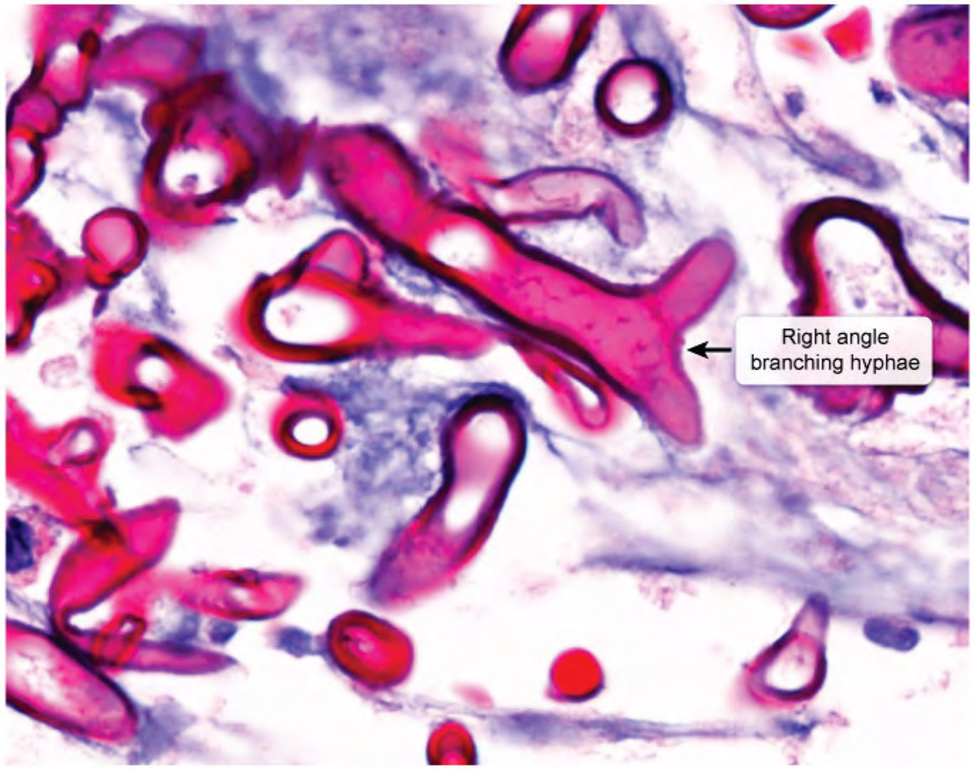

©UWorld

Zoom In | Zoom Out | Reset | New | Existing | My Notebook

https://t.me/USMLEWorldStep1

A 62-year-old man is found dead in his hotel room. He was traveling for work and had checked into the hotel the night prior. No other history is available. Autopsy examination is performed; the lung findings shown below are determined to be the cause of death.

Which of the following is the most likely inciting event that led to this patient's death?

https://t.me/USMLEWorldStep1
Show all

A 62-year-old man is found dead in his hotel room. He was traveling for work and had checked into the hotel the night p
determ

Exhibit Display

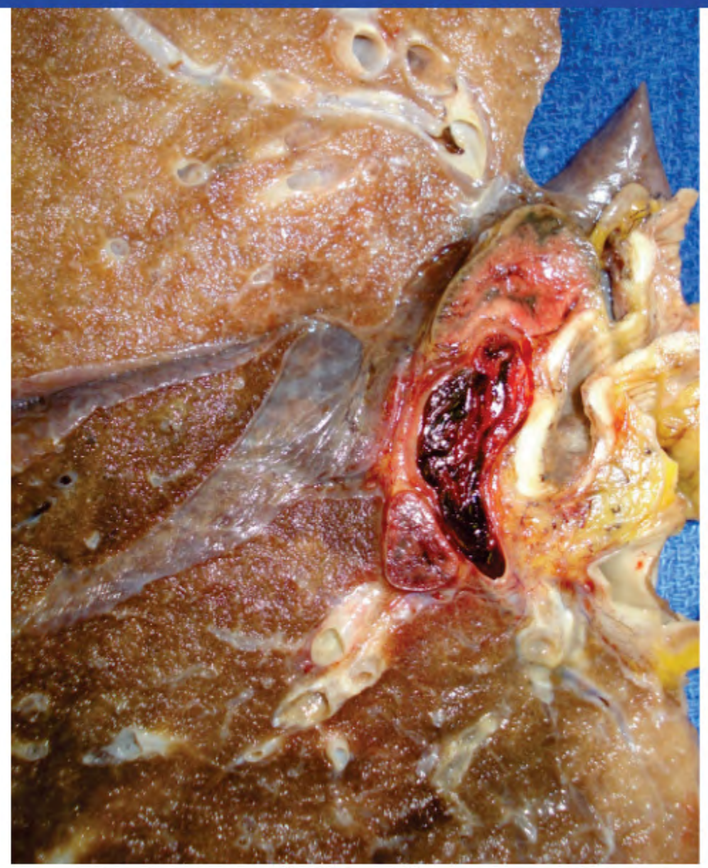

Zoom In Zoom Out Reset New | Existing My Notebook

Which of the following is the most likely inciting event that led to this patient's death?

https://t.me/USMLEWorldStep1

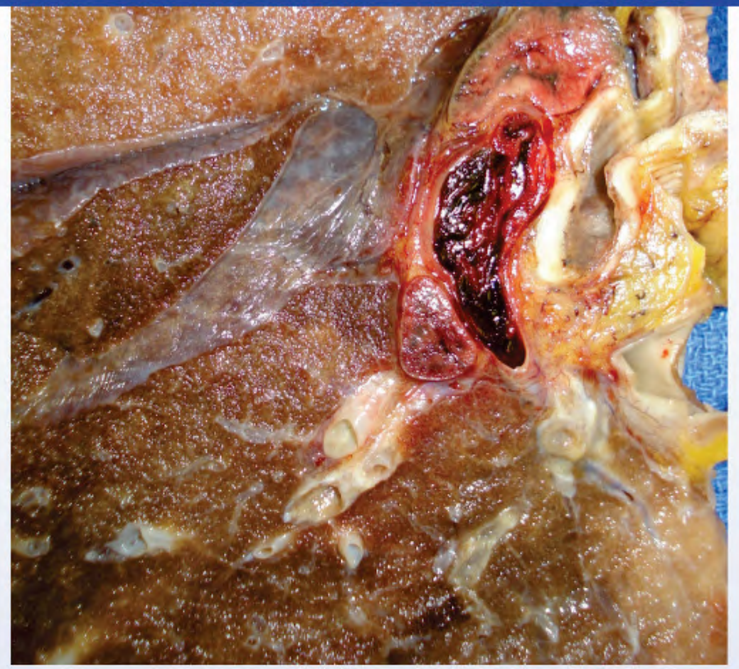

Which of the following is the most likely inciting event that led to this patient's death?

- A. Coronary atheromatous plaque rupture
- B. Deep femoral vein thrombus formation
- C. Malignancy-induced bronchial bleeding
- D. Malignancy-induced bronchial obstruction
- E. Sleep-related upper airway obstruction

Submit

https://t.me/USMLEWorldStep1
Show all

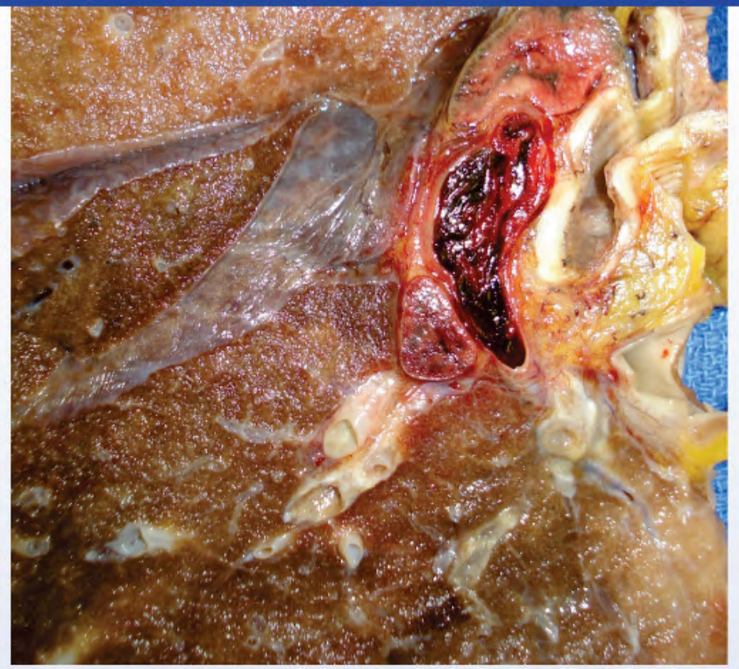

Which of the following is the most likely inciting event that led to this patient's death?

- ✗ A. Coronary atheromatous plaque rupture (2%)
- ✓ B. Deep femoral vein thrombus formation (93%)
- C. Malignancy-induced bronchial bleeding (2%)
- D. Malignancy-induced bronchial obstruction (2%)
- E. Sleep-related upper airway obstruction (0%)

Incorrect
Correct answer
B

93%
Answered correctly

18 secs
Time Spent

2023
Version

https://t.me/USMLEWorldStep1
Show all

Exhibit Display

Pulmonary embolism

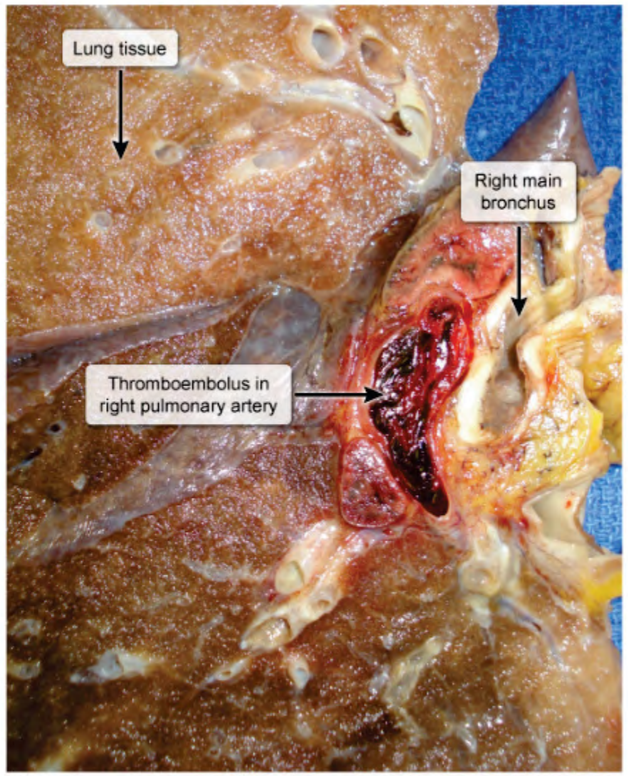

©UWorld

Zoom In | Zoom Out | Reset | New | Existing | My Notebook

©UWorld

https://t.me/USMLEWorldStep1

©UWorld

This patient's autopsy shows a large **thromboembolism** lodged in the **right pulmonary artery**; he most likely died from a massive **pulmonary embolism** (PE) that originated as a lower extremity **deep vein thrombosis**. Massive PE can lead to sudden occlusion of >50% of the pulmonary arterial circulation, causing a rapid increase in pulmonary vascular resistance and right ventricular (RV) pressure load. This can result in acute **RV dysfunction** and inability to pump blood through the pulmonary circulation to the left side of the heart. With a marked decrease in left ventricular preload (left ventricular end-diastolic volume) there is a sudden **loss of cardiac output**.

Depending on the degree of compensation for the loss of cardiac output, patients can experience lightheadedness, syncope, or **sudden cardiac death** (SCD). Less commonly, acute PE may also cause SCD due to **cardiac arrhythmia** induced by RV strain and ischemia.

(Choice A) Coronary atheromatous plaque rupture leads to acute myocardial infarction; SCD can result due to ventricular arrhythmia (ie, ventricular tachycardia, ventricular fibrillation) triggered by myocardial ischemia/infarction. There would not be evidence of thromboembolism in the pulmonary arteries.

(Choices C and D) Malignant tumor may erode into a bronchial artery, resulting in acute hemorrhage, or it may erode into a bronchus resulting in airway obstruction. Neither of these scenarios is likely to cause SCD. Bronchial artery hemorrhage would likely present with hemoptysis and, if fatal, would be evidenced by blood or thrombus in the airways on gross pathology. Bronchial airway obstruction is likely to present with respiratory difficulty or distress.

(Choice E) Sleep-related upper airway obstruction occurs in obstructive sleep apnea, which may cause SCD due to hypoxemia-related cardiac arrhythmia. However, there would not be evidence of thromboembolic disease on autopsy.

Educational objective:
Massive pulmonary embolism can lead to sudden cardiac death (SCD) due to a sudden loss of cardiac output. Less commonly, SCD may result from cardiac arrhythmia triggered by right ventricular strain and ischemia.

References

https://t.me/USMLEWorldStep1
Show all

©UWorld

This patient's autopsy shows a large **thromboembolism** lodged in the **right pulmonary artery**; he most likely died from a PE ca pulmo and in in left

Deper syncop **arrhyt**

(Choi ventric ischen

(Choi erode artery the air distres

(Choi to hyp autops

Educa Massiv Less c

References

Exhibit Display

Acute myocardial infarction

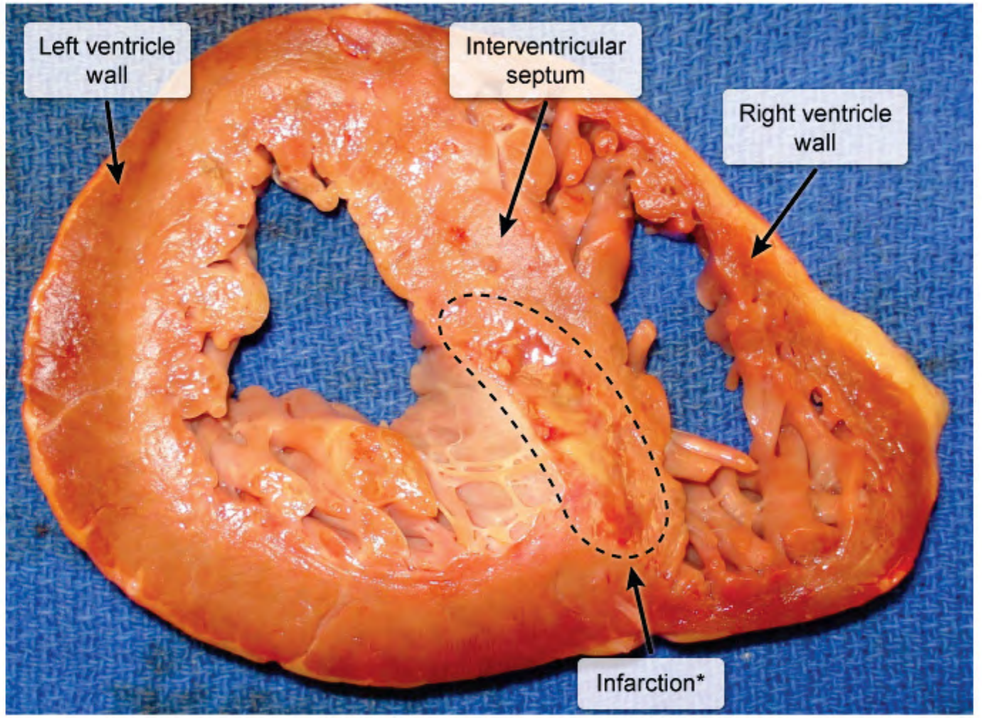

*Tan-yellow area with surrounding hyperemia

©UWorld

Zoom In | Zoom Out | Reset | New | Existing | My Notebook

https://t.me/USMLEWorldStep1
Show all

An 8-year-old girl is brought to the emergency department due to worsening shortness of breath and chest tightness for the past 2 hours. On physical examination, the patient speaks in short sentences. Lung auscultation reveals diffuse wheezing. During the evaluation, the patient is instructed to take a deep breath and blow as hard as possible into the mouthpiece of a hand-held device. The measured airflow rate is significantly lower than expected. Treatment with an inhaled medication is begun. A repeat evaluation several minutes later shows an increase in the airflow rate. The administered medication most likely affected which of the following to produce the observed finding in this patient?

- A. Airway inflammatory response
- B. Alveolar surfactant production
- C. Bronchiolar smooth muscle tone
- D. Lower-airway bacterial load
- E. Pulmonary vascular resistance

Submit

https://t.me/USMLEWorldStep1

An 8-year-old girl is brought to the emergency department due to worsening shortness of breath and chest tightness for the past 2 hours. On physical examination, the patient speaks in short sentences. Lung auscultation reveals diffuse wheezing. During the evaluation, the patient is instructed to take a deep breath and blow as hard as possible into the mouthpiece of a hand-held device. The measured airflow rate is significantly lower than expected. Treatment with an inhaled medication is begun. A repeat evaluation several minutes later shows an increase in the airflow rate. The administered medication most likely affected which of the following to produce the observed finding in this patient?

- A. Airway inflammatory response (4%)
- ✗ B. Alveolar surfactant production (0%)
- ✓ C. Bronchiolar smooth muscle tone (94%)
- D. Lower-airway bacterial load (0%)
- E. Pulmonary vascular resistance (0%)

Incorrect
Correct answer
C

94%
Answered correctly

04 secs
Time Spent

2023
Version

Explanation

This patient's acute-onset shortness of breath and chest tightness are consistent with the **airway spasm** and **bronchoconstriction** that occurs in **asthma**. She received a **bronchodilator** to reduce airway resistance and increase airway flow. In asthma, bronchodilation is typically accomplished with a **beta-2 receptor agonist** (eg, albuterol); these drugs work by stimulating beta-2 adrenergic receptors on **bronchial smooth muscle cells**, leading to an increase in cyclic AMP and consequent **smooth muscle relaxation** (decrease in smooth muscle tone)

https://t.me/USMLEWorldStep1
Show all

Correct answer
C

Answered correctly

Time Spent

Version

Explanation

This patient's acute-onset shortness of breath and chest tightness are consistent with the **airway spasm** and **bronchoconstriction** that occurs in **asthma**. She received a **bronchodilator** to reduce airway resistance and increase airway flow. In asthma, bronchodilation is typically accomplished with a **beta-2 receptor agonist** (eg, albuterol); these drugs work by stimulating beta-2 adrenergic receptors on **bronchial smooth muscle cells**, leading to an increase in cyclic AMP and consequent **smooth muscle relaxation** (decrease in smooth muscle tone).

(Choices A and B) Corticosteroids, both inhaled (eg, budesonide, fluticasone) and systemic (eg, prednisone), modify gene transcription to reduce the airway inflammatory response in patients with asthma. Corticosteroids are also used to stimulate alveolar surfactant production and reduce the risk of neonatal respiratory distress syndrome in premature infants.

(Choice D) Inhaled antibiotics (eg, tobramycin) are used to reduce lower-airway bacterial load in patients with cystic fibrosis.

(Choice E) Several medications, including endothelin receptor antagonists (eg, bosentan), phosphodiesterase inhibitors (eg, sildenafil), and prostacyclin analogs, are used to lower pulmonary vascular resistance in patients with pulmonary arterial hypertension.

Educational objective:
Bronchodilators induce bronchial smooth muscle relaxation to relieve airway spasm and bronchoconstriction in patients with asthma. Bronchodilation is most commonly accomplished with beta-2 receptor agonists (eg, albuterol), which function by increasing cyclic AMP levels in bronchial smooth muscle.

Pathophysiology Pulmonary & Critical Care Asthma

https://t.me/USMLEWorldStep1
Show all

Correct answer
C

Answered correctly
Time Spent
Version

Exhibit Display

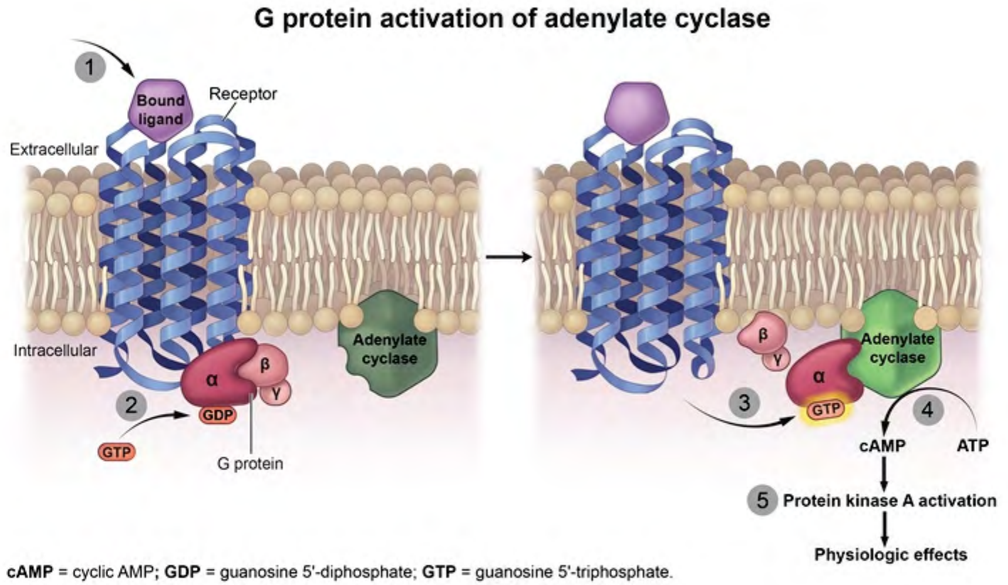

cAMP = cyclic AMP; **GDP** = guanosine 5'-diphosphate; **GTP** = guanosine 5'-triphosphate.

©UWorld

Zoom In Zoom Out Reset New | Existing My Notebook

https://t.me/USMLEWorldStep1

Show all

Correct answer
C

Answered correctly
Time Spent
Version

Exhibit Display

Expl

This p
bronc
increa
albute
leadin
tone).

(Choi
modify
also u
in pre

(Choi
cystic

(Choi
inhibit
with p

Educa
Bronc
patien
albute

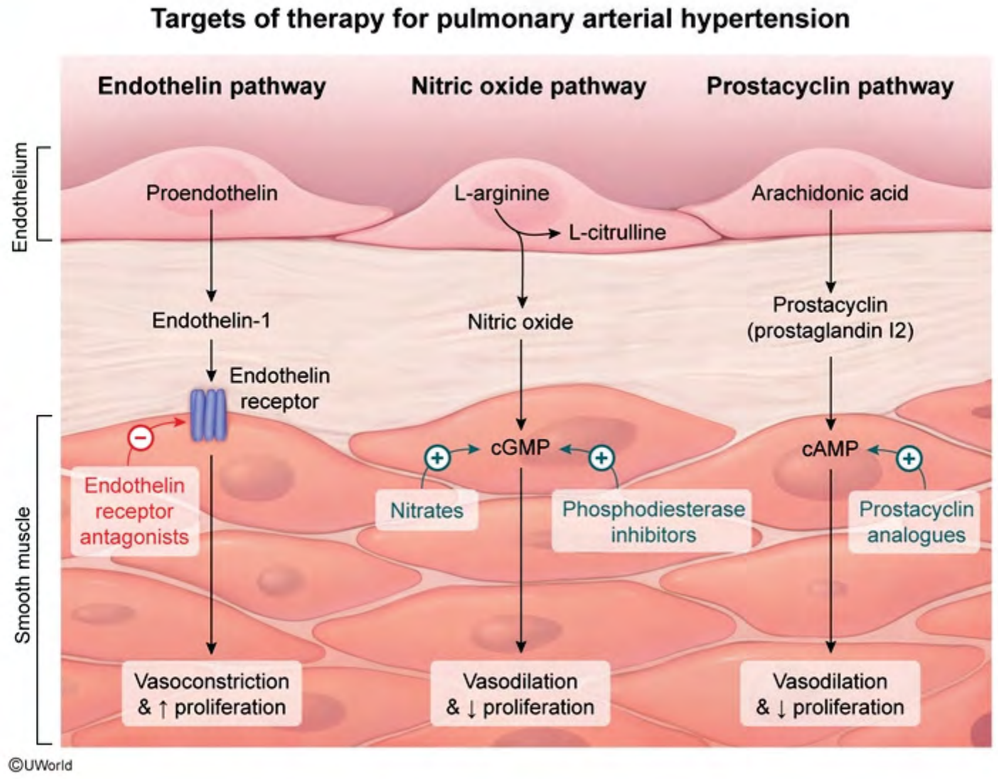

Zoom In | Zoom Out | Reset | New | Existing | My Notebook

Pathophysiology | Pulmonary & Critical Care | Asthma

https://t.me/USMLEWorldStep1
Show all

A 1-month-old boy is brought to the office on a hot summer day due to vomiting and excessive sleepiness. He had been exclusively breastfeeding with normal feeding patterns until this afternoon, when he had 2 episodes of emesis and appeared much sleepier than usual. The infant was born at 41 weeks gestation after an unremarkable pregnancy. Newborn screening was positive for a homozygous ΔF508 mutation affecting an epithelial transmembrane protein; further confirmatory testing is pending. Physical examination shows a somnolent boy with a sunken fontanelle and dry mucous membranes. Which of the following electrolyte disturbances is most likely responsible for this patient's current symptoms?

- A. Hyperchloremia
- B. Hyperkalemia
- C. Hypernatremia
- D. Hypomagnesemia
- E. Hyponatremia

Submit

https://t.me/USMLEWorldStep1
Show all

A 1-month-old boy is brought to the office on a hot summer day due to vomiting and excessive sleepiness. He had been exclusively breastfeeding with normal feeding patterns until this afternoon, when he had 2 episodes of emesis and appeared much sleepier than usual. The infant was born at 41 weeks gestation after an unremarkable pregnancy. Newborn screening was positive for a homozygous ΔF508 mutation affecting an epithelial transmembrane protein; further confirmatory testing is pending. Physical examination shows a somnolent boy with a sunken fontanelle and dry mucous membranes. Which of the following electrolyte disturbances is most likely responsible for this patient's current symptoms?

- A. Hyperchloremia (23%)
- ✕ B. Hyperkalemia (2%)
- C. Hypernatremia (19%)
- D. Hypomagnesemia (1%)
- ✓ E. Hyponatremia (52%)

Incorrect
Correct answer
E

52%
Answered correctly

04 secs
Time Spent

2023
Version

Explanation

https://t.me/USMLEWorldStep1
Show all

A 1-month-old boy is brought to the office on a hot summer day due to vomiting and excessive sleepiness. He had
been e
emesi
pregna
transm
a sunk
respor

Exhibit Display

Sweat ducts

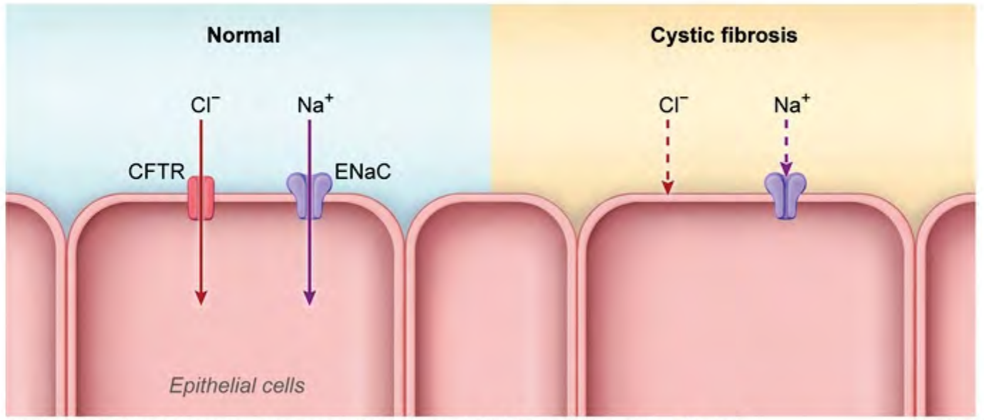

CFTR = cystic fibrosis transmembrane conductance regulator; **ENaC** = epithelial sodium channel. ©UWorld

Zoom In | Zoom Out | Reset | New | Existing | My Notebook

https://t.me/USMLEWorldStep1

The **ΔF508 mutation** in the cystic fibrosis transmembrane conductance regulator (**CFTR**) protein is the most common mutation in patients with **cystic fibrosis** (CF). In unaffected individuals, the CFTR protein serves as a chloride channel that regulates the flow of sodium, chloride, and water across the epithelial membranes of the airways, biliary tree, intestines, sweat ducts, and pancreatic ducts.

Newborn screening for CF is performed in the United States, but positive results should be confirmed by **sweat testing**. When eccrine sweat is first produced, it is isotonic with extracellular fluid. As sweat travels through the eccrine duct to the skin's surface, chloride is normally resorbed via CFTR, and sodium and water follow. CFTR facilitates production of hypotonic sweat in patients without CF. However, patients with CF are unable to reabsorb chloride and sodium in the eccrine ducts and therefore secrete **sweat with high sodium and chloride** levels.

The most likely cause of this patient's symptoms (lethargy, vomiting) is **hyponatremia due to excessive salt wasting** from his sweat. Risk factors for hyponatremia in patients with CF include exclusive breast or formula feeding prior to the introduction of sodium-rich, solid foods; exposure to high-temperature environments; and exercise. Therefore, **salt supplementation** is recommended for patients with CF.

(Choice A) Chloride ions are an important contributor to extracellular fluid volume, and hypochloremia is also very common in patients with CF due to sweat losses. In contrast, hyperchloremia is more likely to develop in normal patients with excessive sweating due to increased free water loss from hypotonic sweat.

(Choice B) Hyperkalemia typically occurs with cell lysis (eg, rhabdomyolysis, tumor lysis syndrome), metabolic acidosis (due to intracellular to extracellular K^+ shift), or abnormalities with renal excretion.

(Choice C) Hypernatremia classically occurs with excessive salt intake or free water loss (eg, diarrhea, diabetes insipidus, improperly prepared infant formula). Patients with CF typically do not experience hypernatremia as they lose excess sodium through their sweat glands.

(Choice D) Hypomagnesemia most commonly arises from urinary loss due to medications (eg, loop diuretics), alcohol use, or uncontrolled diabetes mellitus with polyuria.

Educational objective:

https://t.me/USMLEWorldStep1
Show all

airways, biliary tree, intestines, sweat ducts, and pancreatic ducts.

Newborn screening for CF is performed in the United States, but positive results should be confirmed by **sweat testing**. When eccrine sweat is first produced, it is isotonic with extracellular fluid. As sweat travels through the eccrine duct to the skin's surface, chloride is normally resorbed via CFTR, and sodium and water follow. CFTR facilitates production of hypotonic sweat in patients without CF. However, patients with CF are unable to reabsorb chloride and sodium in the eccrine ducts and therefore secrete **sweat with high sodium and chloride** levels.

The most likely cause of this patient's symptoms (lethargy, vomiting) is **hyponatremia due to excessive salt wasting** from his sweat. Risk factors for hyponatremia in patients with CF include exclusive breast or formula feeding prior to the introduction of sodium-rich, solid foods; exposure to high-temperature environments; and exercise. Therefore, **salt supplementation** is recommended for patients with CF.

(Choice A) Chloride ions are an important contributor to extracellular fluid volume, and hypochloremia is also very common in patients with CF due to sweat losses. In contrast, hyperchloremia is more likely to develop in normal patients with excessive sweating due to increased free water loss from hypotonic sweat.

(Choice B) Hyperkalemia typically occurs with cell lysis (eg, rhabdomyolysis, tumor lysis syndrome), metabolic acidosis (due to intracellular to extracellular K^+ shift), or abnormalities with renal excretion.

(Choice C) Hypernatremia classically occurs with excessive salt intake or free water loss (eg, diarrhea, diabetes insipidus, improperly prepared infant formula). Patients with CF typically do not experience hypernatremia as they lose excess sodium through their sweat glands.

(Choice D) Hypomagnesemia most commonly arises from urinary loss due to medications (eg, loop diuretics), alcohol use, or uncontrolled diabetes mellitus with polyuria.

Educational objective:
Patients with cystic fibrosis (CF) produce eccrine sweat with higher-than-normal concentrations of sodium and chloride. Exposure to high temperature or exercise can lead to hyponatremia and hypochloremia due to excessive sodium chloride loss through sweat; therefore, salt supplementation is recommended.

https://t.me/USMLEWorldStep1
Show all

A 54-year-old man comes to the office due to shortness of breath that has slowly worsened over the last 6 months. He also has a persistent, nonproductive cough. The patient does not use alcohol, tobacco, or illicit drugs. Temperature is 36.8 C (98 F), blood pressure is 132/78 mm Hg, pulse is 74/min, and respirations are 16/min. Physical examination reveals fine crackles bilaterally on pulmonary auscultation and drumstick-shaped fingers. Chest x-ray reveals diffuse reticular opacities. Pulmonary function testing shows decreased FVC, increased FEV1/FVC ratio, and expiratory flow rates that are higher than normal when corrected for lung volume. This patient's supernormal expiratory flow rates are best explained by an increase in which of the following parameters?

- A. Lung compliance
- B. Outward recoil of the chest wall
- C. Physiological dead space
- D. Radial traction on airway walls
- E. Wall thickness of bronchioles

Submit

https://t.me/USMLEWorldStep1
Show all

A 54-year-old man comes to the office due to shortness of breath that has slowly worsened over the last 6 months. He also has a persistent, nonproductive cough. The patient does not use alcohol, tobacco, or illicit drugs. Temperature is 36.8 C (98 F), blood pressure is 132/78 mm Hg, pulse is 74/min, and respirations are 16/min. Physical examination reveals fine crackles bilaterally on pulmonary auscultation and drumstick-shaped fingers. Chest x-ray reveals diffuse reticular opacities. Pulmonary function testing shows decreased FVC, increased FEV1/FVC ratio, and expiratory flow rates that are higher than normal when corrected for lung volume. This patient's supernormal expiratory flow rates are best explained by an increase in which of the following parameters?

- A. Lung compliance (14%)
- ✗ B. Outward recoil of the chest wall (10%)
- C. Physiological dead space (7%)
- ✓ D. Radial traction on airway walls (51%)
- E. Wall thickness of bronchioles (15%)

Incorrect
Correct answer
D

51%
Answered correctly

04 secs
Time Spent

2023
Version

Explanation

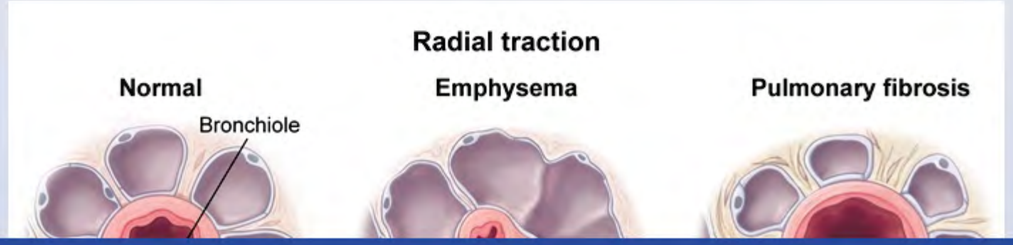

https://t.me/USMLEWorldStep1
Show all

A 54-year-old man comes to the office due to shortness of breath that has slowly worsened over the last 6 months.
He als
Tempe
Physic
Chest
FEV1/
patien

Exhibit Display

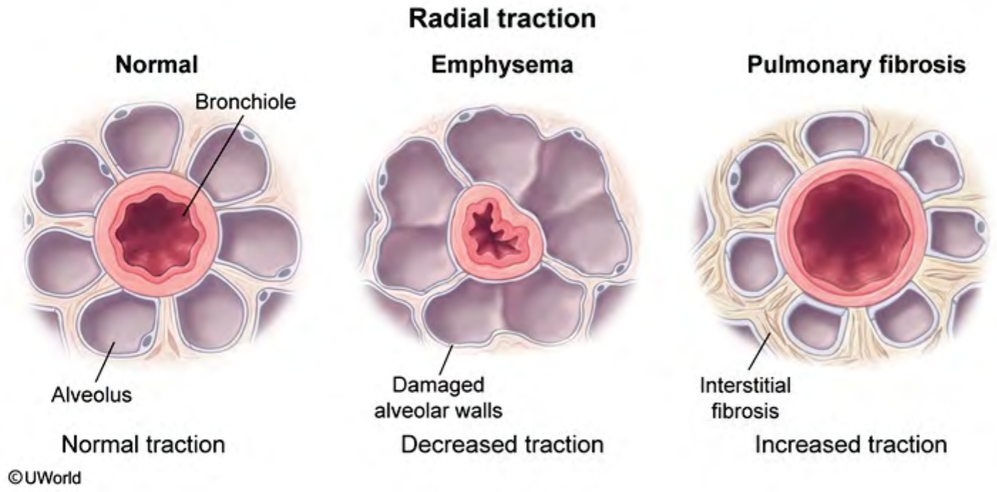

Zoom In Zoom Out Reset New | Existing My Notebook

Inco
Corre
D

Expl

https://t.me/USMLEWorldStep1

Show all

This patient's clinical presentation (progressive dyspnea, fine crackles, clubbing, diffuse reticular opacities) is consistent with **interstitial lung disease** (ILD). Most ILDs cause progressive **pulmonary fibrosis** with thickening and stiffening of the pulmonary interstitium. This causes increased lung elastic recoil, as well as **airway widening** due to increased outward pulling (**radial traction**) by the surrounding fibrotic tissue. The resulting decrease in airflow resistance leads to supernormal expiratory flow rates (higher than normal when corrected for lung volume).

Additional pulmonary function test findings in restrictive lung diseases include reduced total lung capacity, vital capacity, inspiratory capacity, functional residual capacity, and residual volume. The FVC and FEV1 are decreased as well. However, the FEV1/FVC ratio is typically normal or increased as FEV1 decreases less than FVC (due to airway widening relative to the low lung volumes). In addition, fibrosis causes a reduction in the diffusion capacity of carbon monoxide.

(Choice A) Lung compliance is defined as the change in lung volume for a given change in pressure. Increased compliance means that the lung tissue stretches and expands more in response to increased pressure. Restrictive lung diseases cause decreased lung compliance and lower lung volumes due to interstitial fibrosis.

(Choice B) The outward recoil of the chest wall limits the volume of air that can be expired during maximal exhalation. An increase in outward chest wall recoil would decrease expiratory flow rates, as the respiratory muscles must work harder during expiration to oppose the increased outward force.

(Choice C) Physiological dead space refers to the volume of inspired air that does not participate in gas exchange. Changes in the amount of physiological dead space can affect alveolar ventilation but do not affect expiratory flow rates.

(Choice E) Thickening of the bronchioles, which occurs in some obstructive lung diseases (eg, asthma), leads to narrowing of the airways. Although reduced airway radius leads to local increase in airflow velocity, overall the increased resistance causes a decrease in expiratory flow rates. In fibrotic lung disease, the interstitium, not the bronchiolar walls, is thickened.

Educational objective:
Interstitial lung disease is associated with decreased lung volumes and increased lung elastic recoil caused by

https://t.me/USMLEWorldStep1
Show all

due to increased outward pulling (**radial traction**) by the surrounding fibrotic tissue. The resulting decrease in airflow resistance leads to supernormal expiratory flow rates (higher than normal when corrected for lung volume).

Additional pulmonary function test findings in restrictive lung diseases include reduced total lung capacity, vital capacity, inspiratory capacity, functional residual capacity, and residual volume. The FVC and FEV1 are decreased as well. However, the FEV1/FVC ratio is typically normal or increased as FEV1 decreases less than FVC (due to airway widening relative to the low lung volumes). In addition, fibrosis causes a reduction in the diffusion capacity of carbon monoxide.

(Choice A) Lung compliance is defined as the change in lung volume for a given change in pressure. Increased compliance means that the lung tissue stretches and expands more in response to increased pressure. Restrictive lung diseases cause decreased lung compliance and lower lung volumes due to interstitial fibrosis.

(Choice B) The outward recoil of the chest wall limits the volume of air that can be expired during maximal exhalation. An increase in outward chest wall recoil would decrease expiratory flow rates, as the respiratory muscles must work harder during expiration to oppose the increased outward force.

(Choice C) Physiological dead space refers to the volume of inspired air that does not participate in gas exchange. Changes in the amount of physiological dead space can affect alveolar ventilation but do not affect expiratory flow rates.

(Choice E) Thickening of the bronchioles, which occurs in some obstructive lung diseases (eg, asthma), leads to narrowing of the airways. Although reduced airway radius leads to local increase in airflow velocity, overall the increased resistance causes a decrease in expiratory flow rates. In fibrotic lung disease, the interstitium, not the bronchiolar walls, is thickened.

Educational objective:
Interstitial lung disease is associated with decreased lung volumes and increased lung elastic recoil caused by fibrotic interstitial tissue. The increased elastic recoil results in increased radial traction (outward pulling) on the airways, leading to increased expiratory flow rates when corrected for the low lung volume.

https://t.me/USMLEWorldStep1
Show all

Alveolus

Damaged alveolar walls

Interstitial fibrosis

Exhibit Display

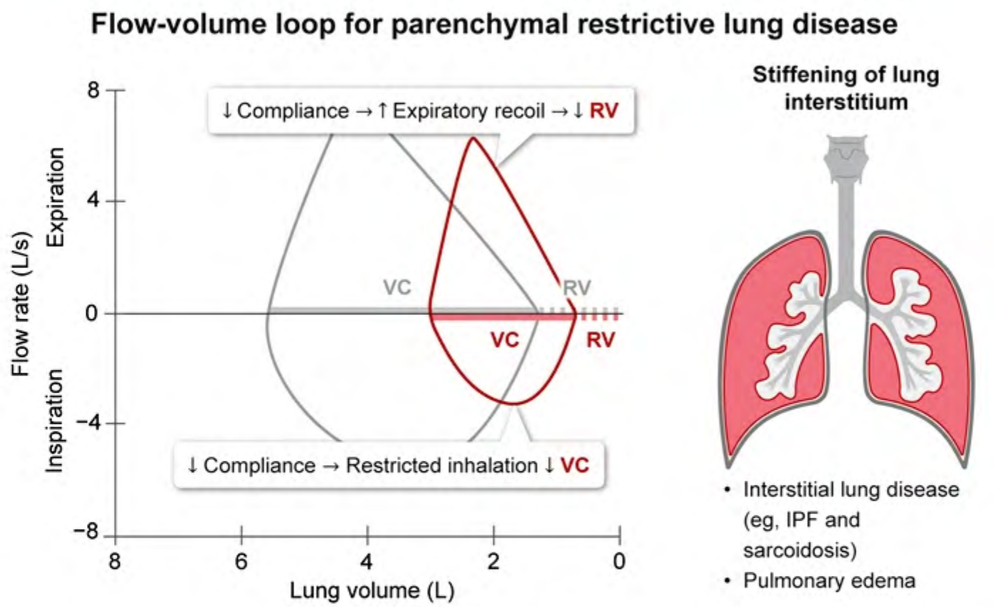

Zoom In Zoom Out Reset New | Existing My Notebook

This p
consis
and st
due to
airflow

Additio
capaci
as wel
airway
of carb

(Choi
compli
lung d

(Choi
exhala
muscle

(Choi
excha
expira

(Choi
narrowing of the airways. Although reduced airway radius leads to local increase in airflow velocity, overall the increased resistance causes a decrease in expiratory flow rates. In fibrotic lung disease, the interstitium, not the

https://t.me/USMLEWorldStep1

Alveolus

Damaged alveolar walls

Interstitial fibrosis

Exhibit Display

This p
consis
and st
due to
airflow

Additio
capaci
as wel
airway
of carb

(Choi
compli
lung d

(Choi
exhala
muscl

(Choi
excha
expira

(Choi
narrow
increa

Lung volumes & capacities

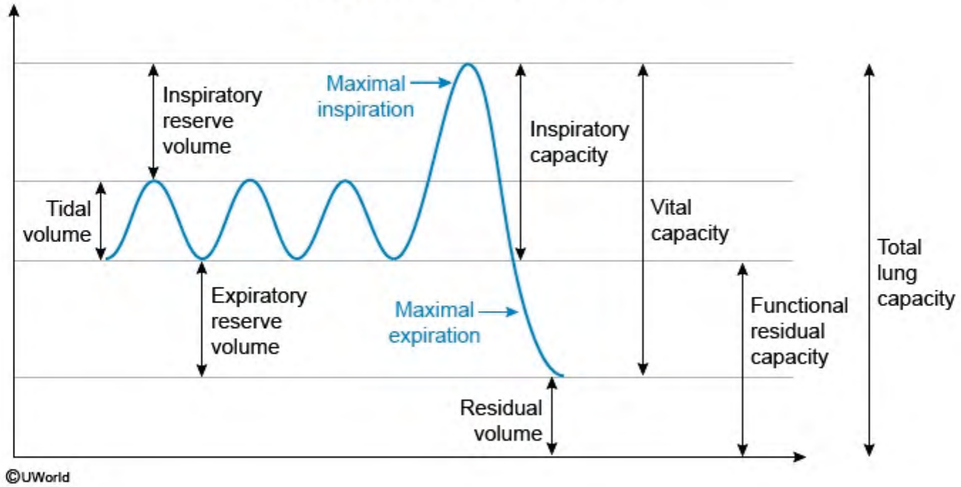

Zoom In | Zoom Out | Reset | New | Existing | My Notebook

https://t.me/USMLEWorldStep1

Show all

due to increased outward pulling (**radial traction**) by the surrounding fibrotic tissue. The resulting decrease in airflow resistance leads to supernormal expiratory flow rates (higher than normal when corrected for lung volume).

Additio
capaci
as wel
airway
of carb

(Choi
compli
lung d

(Choi
exhala
muscle

(Choi
excha
expira

(Choi
narrow
increa
bronch

Educa
Interst
fibrotic
airway

Exhibit Display

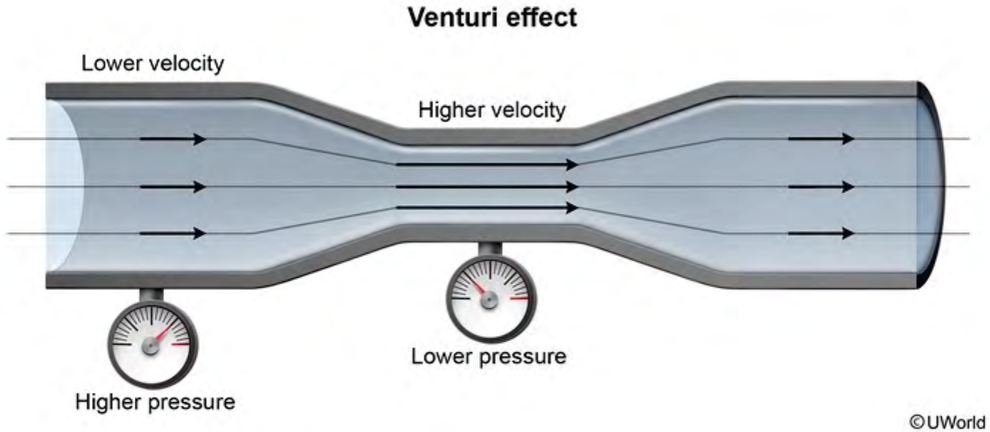

Zoom In Zoom Out Reset New | Existing My Notebook

https://t.me/USMLEWorldStep1
Show all

A 20-year-old woman is brought to the emergency department by her boyfriend after being found unresponsive in her apartment. She has a medical history of major depression and generalized anxiety disorder. There is no evidence of trauma. On examination, the patient is obtunded and responds only to painful stimuli. There are no indications of recent vomiting. Lungs are clear to auscultation. Toxicology screen is positive for benzodiazepines. Which of the following sets of arterial blood gas findings (in mm Hg) are most likely present in this patient?

	PaO_2	$PaCO_2$	Alveolar-arterial O_2 gradient
○ A.	45	30	10
○ B.	45	30	30
○ C.	55	60	25
○ D.	55	60	10
○ E.	65	70	35

Submit

https://t.me/USMLEWorldStep1
Show all

A 20-year-old woman is brought to the emergency department by her boyfriend after being found unresponsive in her apartment. She has a medical history of major depression and generalized anxiety disorder. There is no evidence of trauma. On examination, the patient is obtunded and responds only to painful stimuli. There are no indications of recent vomiting. Lungs are clear to auscultation. Toxicology screen is positive for benzodiazepines. Which of the following sets of arterial blood gas findings (in mm Hg) are most likely present in this patient?

	PaO_2	$PaCO_2$	Alveolar-arterial O_2 gradient	
✗ A.	45	30	10	(2%)
B.	45	30	30	(1%)
C.	55	60	25	(13%)
✓ D.	55	60	10	(76%)
E.	65	70	35	(5%)

Incorrect
Correct answer
D

76%
Answered correctly

03 secs
Time Spent

2023
Version

Explanation

Causes of hypoxemia		
	Examples	A-a gradient
Reduced PiO_2	High altitude	Normal

https://t.me/USMLEWorldStep1
Show all

Explanation

Causes of hypoxemia		
	Examples	**A-a gradient**
Reduced PiO_2	High altitude	Normal
Hypoventilation	CNS depression, morbid obesity	Normal
Diffusion limitation	Emphysema, ILD	Increased
V/Q mismatch*	Pulmonary embolism, pneumonia	Increased

*Caused by regional dead-space ventilation and/or intrapulmonary shunting.
A-a gradient = alveolar to arterial oxygen gradient; **ILD** = interstitial lung disease; **PiO_2** = partial pressure of inspired oxygen; **V/Q** = ventilation/perfusion ratio.

This patient has an **acute benzodiazepine overdose**. Benzodiazepines (eg, alprazolam, lorazepam) cause sedation and central respiratory depression with **hypoventilation** and **CO_2 retention**; therefore, affected patients have acute respiratory acidosis (low pH and $PaCO_2$ >40 mm Hg). Because full metabolic compensation by the kidneys (ie, HCO_3^- retention) requires approximately 72 hours, there is minimal compensation in the acute setting, and the expected serum HCO_3^- is near normal (24 mEq/L).

The alveolar-arterial **(A-a) O_2 gradient** is the difference between the partial pressure of alveolar oxygen (PAO_2) and the partial pressure of arterial oxygen (PaO_2); it represents the efficiency of gas transfer between the lungs and the circulation. A **small gradient** (eg, 4-15 mm Hg) is **normal** in part because there is physiologic shunting of unoxygenated bronchial blood, which decreases PaO_2. In addition to CO_2 retention, hypoventilation also causes **low PAO_2** that leads directly to hypoxemia (PaO_2 <75 mm Hg). The efficiency of gas transfer is intact and a **normal A-a O_2 gradient** is expected.

https://t.me/USMLEWorldStep1
Show all

oxygen; **V/Q** = ventilation/perfusion ratio.

This patient has an **acute benzodiazepine overdose**. Benzodiazepines (eg, alprazolam, lorazepam) cause sedation and central respiratory depression with **hypoventilation** and **CO_2 retention**; therefore, affected patients have acute respiratory acidosis (low pH and $PaCO_2$ >40 mm Hg). Because full metabolic compensation by the kidneys (ie, HCO_3^- retention) requires approximately 72 hours, there is minimal compensation in the acute setting, and the expected serum HCO_3^- is near normal (24 mEq/L).

The alveolar-arterial **(A-a) O_2 gradient** is the difference between the partial pressure of alveolar oxygen (PAO_2) and the partial pressure of arterial oxygen (PaO_2); it represents the efficiency of gas transfer between the lungs and the circulation. A **small gradient** (eg, 4-15 mm Hg) is **normal** in part because there is physiologic shunting of unoxygenated bronchial blood, which decreases PaO_2. In addition to CO_2 retention, hypoventilation also causes **low PAO_2** that leads directly to hypoxemia (PaO_2 <75 mm Hg). The efficiency of gas transfer is intact and a **normal A-a O_2 gradient** is expected.

(Choice A) $PaCO_2$ <40 mm Hg indicates respiratory alkalosis. Respiratory alkalosis (ie, hyperventilation) with hypoxemia and a normal A-a O_2 gradient is expected at high altitude. The efficiency of gas transfer is intact, but low partial pressure of inspired oxygen (PiO_2) causes low PAO_2.

(Choice B) Respiratory alkalosis with hypoxemia and an elevated A-a O_2 gradient is expected with lung pathology that causes acute V/Q mismatch (eg, pulmonary embolism and pneumonia).

(Choices C and E) Respiratory acidosis with hypoxemia and an elevated A-a O_2 gradient is expected with chronic obstructive pulmonary disease. These patients have chronic CO_2 retention, and O_2 exchange is impaired by emphysematous disruption of gas diffusion across the alveolar-capillary membrane.

Educational objective:
Acute benzodiazepine (eg, alprazolam, lorazepam) overdose causes central respiratory depression with hypoventilation. The hypoventilation leads to CO_2 retention and acute respiratory acidosis. It also decreases the

https://t.me/USMLEWorldStep1
Show all

sedation and central respiratory depression with **hypoventilation** and **CO_2 retention**, therefore, affected patients have acute respiratory acidosis (low pH and $PaCO_2$ >40 mm Hg). Because full metabolic compensation by the kidneys (ie, HCO_3^- retention) requires approximately 72 hours, there is minimal compensation in the acute setting, and the expected serum HCO_3^- is near normal (24 mEq/L).

The alveolar-arterial **(A-a) O_2 gradient** is the difference between the partial pressure of alveolar oxygen (PAO_2) and the partial pressure of arterial oxygen (PaO_2); it represents the efficiency of gas transfer between the lungs and the circulation. A **small gradient** (eg, 4-15 mm Hg) is **normal** in part because there is physiologic shunting of unoxygenated bronchial blood, which decreases PaO_2. In addition to CO_2 retention, hypoventilation also causes **low PAO_2** that leads directly to hypoxemia (PaO_2 <75 mm Hg). The efficiency of gas transfer is intact and a **normal A-a O_2 gradient** is expected.

(Choice A) $PaCO_2$ <40 mm Hg indicates respiratory alkalosis. Respiratory alkalosis (ie, hyperventilation) with hypoxemia and a normal A-a O_2 gradient is expected at high altitude. The efficiency of gas transfer is intact, but low partial pressure of inspired oxygen (PiO_2) causes low PAO_2.

(Choice B) Respiratory alkalosis with hypoxemia and an elevated A-a O_2 gradient is expected with lung pathology that causes acute V/Q mismatch (eg, pulmonary embolism and pneumonia).

(Choices C and E) Respiratory acidosis with hypoxemia and an elevated A-a O_2 gradient is expected with chronic obstructive pulmonary disease. These patients have chronic CO_2 retention, and O_2 exchange is impaired by emphysematous disruption of gas diffusion across the alveolar-capillary membrane.

Educational objective:
Acute benzodiazepine (eg, alprazolam, lorazepam) overdose causes central respiratory depression with hypoventilation. The hypoventilation leads to CO_2 retention and acute respiratory acidosis. It also decreases the PAO_2, leading directly to hypoxemia (PaO_2 <75 mm Hg). The efficiency of gas transfer between the lungs and the circulation is intact; therefore, a normal alveolar-arterial O_2 gradient (eg, <15 mm Hg) is expected.

Physiology Pulmonary & Critical Care Respiratory acidosis

https://t.me/USMLEWorldStep1
Show all

V/Q mismatch*	Pulmonary embolism, pneumonia	Increased

Exhibit Display

Arterial blood gas interpretation of acid-base disorders

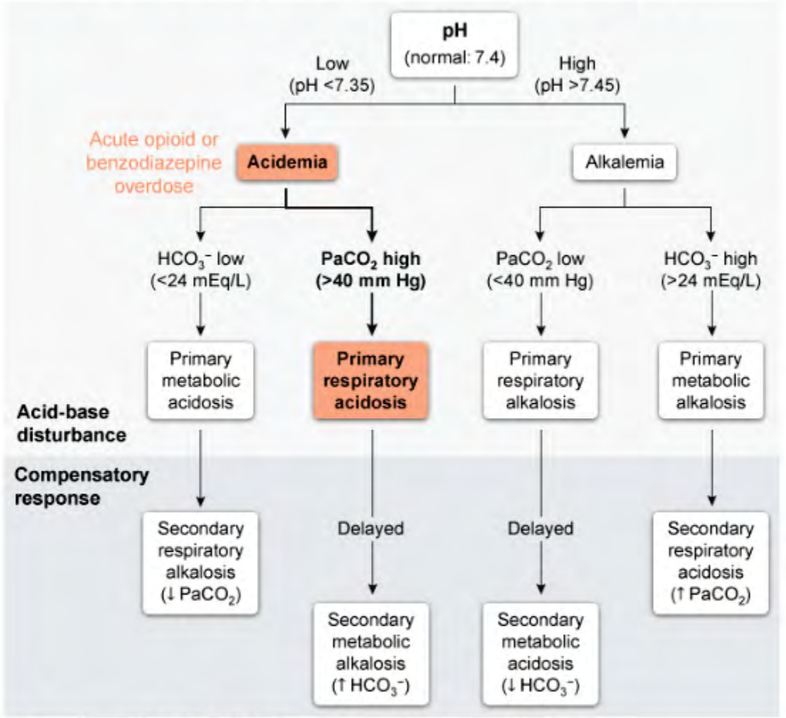

* The normal ranges for $PaCO_2$ and HCO_3^- vary slightly around 40 mm Hg and 24 mEq/L.
For simplicity, these numbers should be used as a normal baseline for acid-base calculations.

HCO_3^- = bicarbonate; $PaCO_2$ = partial pressure of carbon dioxide in arterial blood.

©UWorld

Zoom In | Zoom Out | Reset | New | Existing | My Notebook

This p
sedati
have a
kidney
and th

The al
the pa
circula
unoxy
low P
A-a O

(Choi
hypox
low pa

(Choi
that ca

(Choi
obstru

emphysematous disruption of gas diffusion across the alveolar-capillary membrane.

https://t.me/USMLEWorldStep1

V/Q mismatch*	Pulmonary embolism, pneumonia	Increased

*C
A-
oxy

This p
sedati
have a
kidney
and th

The al
the pa
circula
unoxy
low P
A-a O

(Choi
hypox
low pa

(Choi
that ca

(Choi
obstru
emphy

Exhibit Display

Normal bronchopulmonary shunting

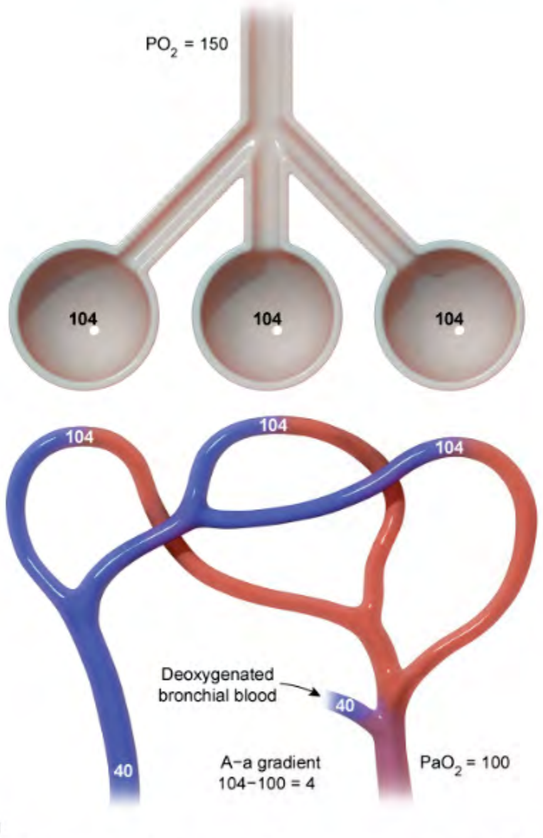

©UWorld

Zoom In | Zoom Out | Reset | New | Existing | My Notebook

https://t.me/USMLEWorldStep1

V/Q mismatch*	Pulmonary embolism, pneumonia	Increased

*C
A-
oxy

Exhibit Display

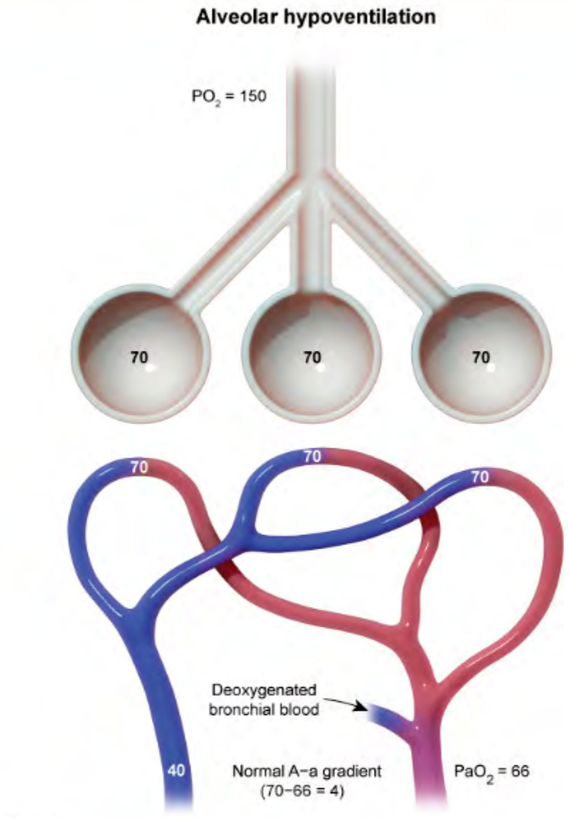

Zoom In | Zoom Out | Reset | New | Existing | My Notebook

This p
sedati
have a
kidney
and th

The al
the pa
circula
unoxy
low P
A-a O

(Choi
hypox
low pa

(Choi
that ca

(Choi
obstru

emphysematous disruption of gas diffusion across the alveolar-capillary membrane.

https://t.me/USMLEWorldStep1
Show all

oxygen; **V/Q** = ventilation/perfusion ratio.

This p
sedati
have a
kidney
and th

The al
the pa
circula
unoxy

low P

A-a O

(Choi
hypox
low pa

(Choi
that ca

(Choi
obstru
emphy

Educa
Acute
hypoventilation. The hypoventilation leads to CO_2 retention and acute respiratory acidosis. It also decreases the

Exhibit Display

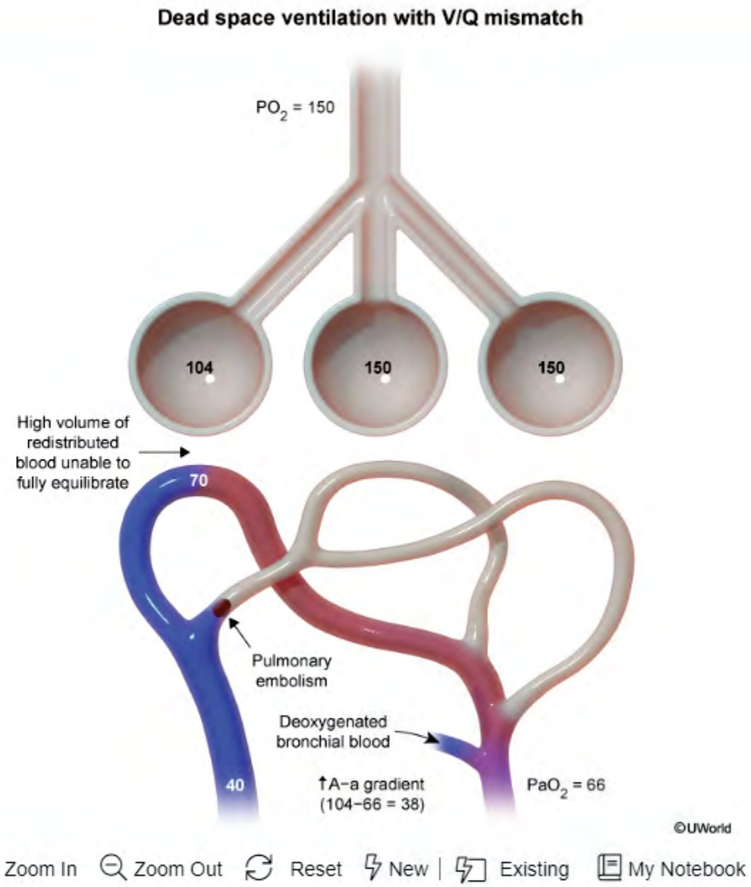

Zoom In Zoom Out Reset New | Existing My Notebook

https://t.me/USMLEWorldStep1
Show all

oxygen; **V/Q** = ventilation/perfusion ratio.

Exhibit Display

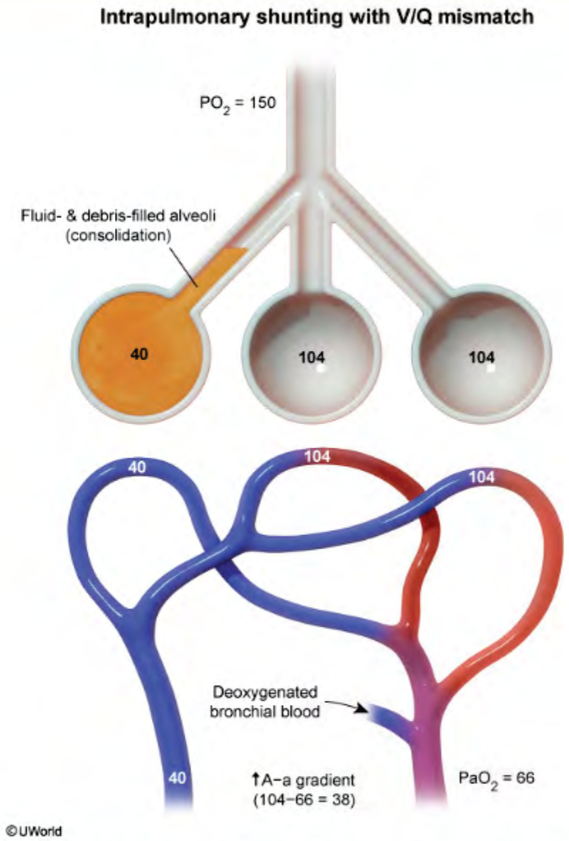

Zoom In | Zoom Out | Reset | New | Existing | My Notebook

This p
sedati
have a
kidney
and th

The al
the pa
circula
unoxy

low P

A-a O

(Choi
hypox
low pa

(Choi
that ca

(Choi
obstru
emphy

Educa
Acute
hypoventilation. The hypoventilation leads to CO_2 retention and acute respiratory acidosis. It also decreases the

https://t.me/USMLEWorldStep1

oxygen; **V/Q** = ventilation/perfusion ratio.

This p
sedati
have a
kidney
and th

The al
the pa
circula
unoxy

low P

A-a O

(Choi
hypox
low pa

(Choi
that ca

(Choi
obstru
emphy

Educa
Acute
hypoventilation. The hypoventilation leads to CO_2 retention and acute respiratory acidosis. It also decreases the

Exhibit Display

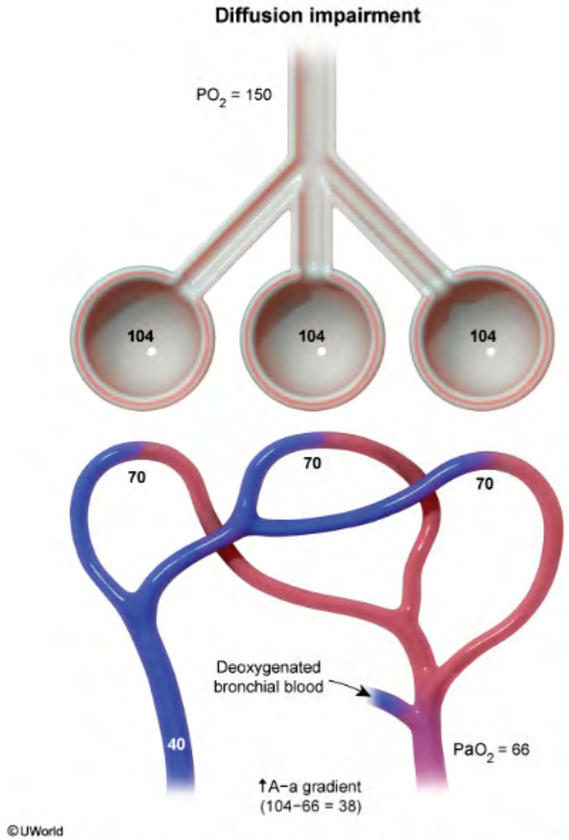

Zoom In Zoom Out Reset New | Existing My Notebook

https://t.me/USMLEWorldStep1
Show all

sedation and central respiratory depression with **hypoventilation** and **CO_2 retention**, therefore, affected patients have acute respiratory acidosis (low pH and $PaCO_2$ >40 mm Hg). Because full metabolic compensation by the kidney

and th

The al

the pa

circula

unoxy

low P

A-a O

(Choi

hypox

low pa

(Choi

that ca

(Choi

obstru

emphy

Educa

Acute

hypov

PAO_2,

circula

Exhibit Display

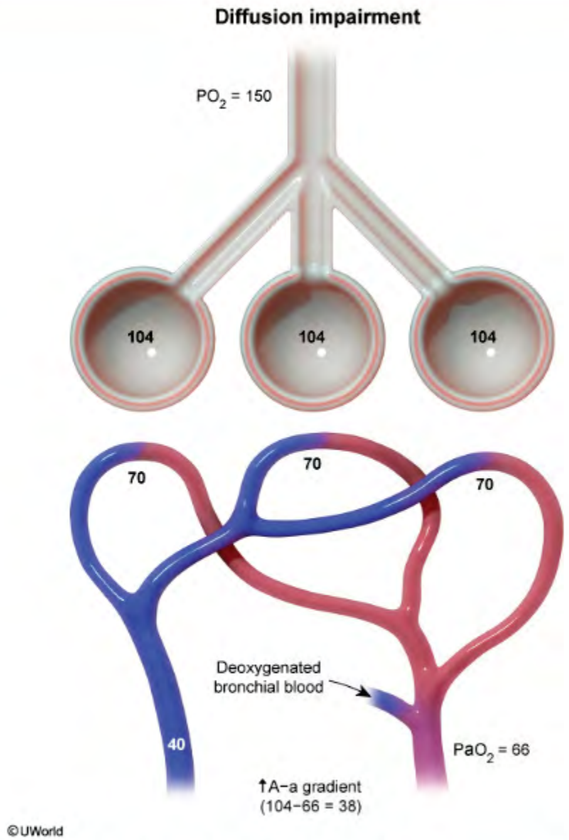

Zoom In Zoom Out Reset New | Existing My Notebook

Physiology Pulmonary & Critical Care Respiratory acidosis

https://t.me/USMLEWorldStep1
Show all

A 37-year-old woman is evaluated for exertional shortness of breath. The patient has had progressive dyspnea for the last year and for the last 2 months has been unable to walk half a block without stopping to rest. She also describes lightheadedness during exertion. Medical history is insignificant, and vital signs are within normal limits. BMI is 23 kg/m^2. Physical examination reveals a 2/6 holosystolic murmur at the lower sternal border, which increases with inspiration. Further evaluation indicates no evidence of obstructive or interstitial lung disease or venous thromboembolism. Cardiac catheterization results are as follows:

Mean pulmonary artery pressure	43 mm Hg (normal: 8-20)
Pulmonary capillary wedge pressure	9 mm Hg (normal: 6-12)

Pharmacotherapy blocking the effects of which of the following substances is most likely to benefit this patient?

- A. Aldosterone
- B. Angiotensin II
- C. Endothelin
- D. Norepinephrine
- E. Serotonin

Submit

https://t.me/USMLEWorldStep1
Show all

A 37-year-old woman is evaluated for exertional shortness of breath. The patient has had progressive dyspnea for the last year and for the last 2 months has been unable to walk half a block without stopping to rest. She also describes lightheadedness during exertion. Medical history is insignificant, and vital signs are within normal limits. BMI is 23 kg/m^2. Physical examination reveals a 2/6 holosystolic murmur at the lower sternal border, which increases with inspiration. Further evaluation indicates no evidence of obstructive or interstitial lung disease or venous thromboembolism. Cardiac catheterization results are as follows:

Mean pulmonary artery pressure	43 mm Hg (normal: 8-20)
Pulmonary capillary wedge pressure	9 mm Hg (normal: 6-12)

Pharmacotherapy blocking the effects of which of the following substances is most likely to benefit this patient?

- A. Aldosterone (5%)
- ✗ B. Angiotensin II (18%)
- ✓ C. Endothelin (69%)
- D. Norepinephrine (4%)
- E. Serotonin (1%)

Incorrect
Correct answer
C

69%
Answered correctly

04 secs
Time Spent

2023
Version

Explanation

Targets of therapy for pulmonary arterial hypertension

https://t.me/USMLEWorldStep1
Show all

E. Serotonin (1%)

Exhibit Display

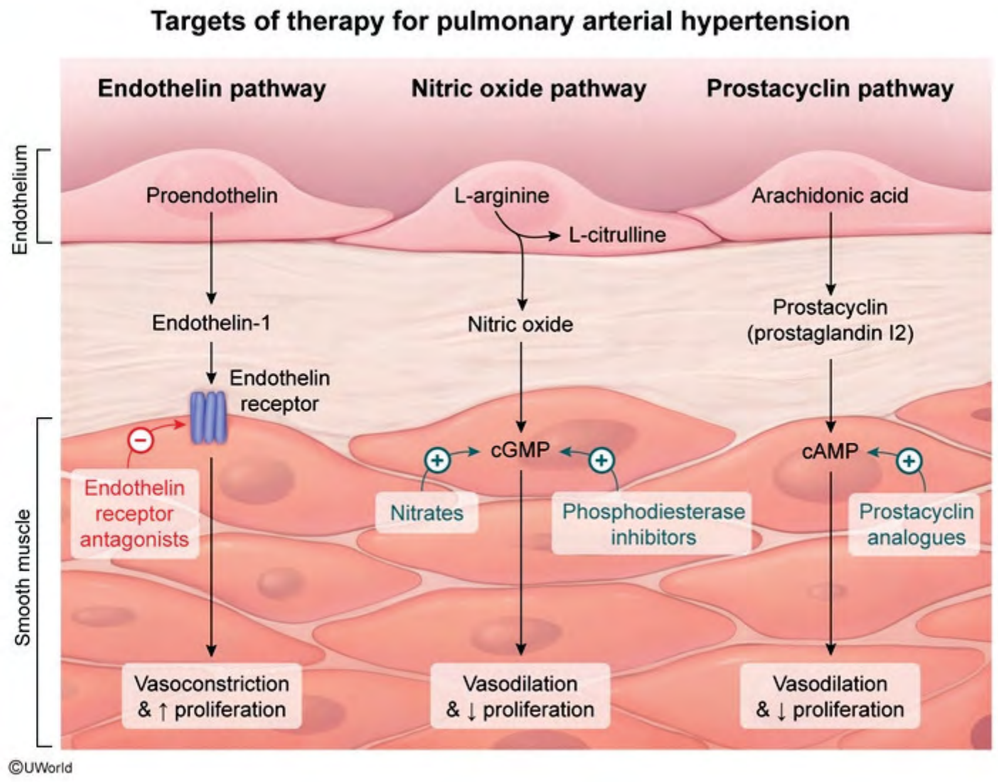

Zoom In | Zoom Out | Reset | New | Existing | My Notebook

https://t.me/USMLEWorldStep1

Show all

This patient has **pulmonary hypertension**, which typically presents with progressive dyspnea and fatigue, sometimes with associated chest pain and exertional lightheadedness or syncope. Due to right ventricular enlargement, a holosystolic murmur of functional **tricuspid regurgitation** is often present.

Pulmonary hypertension can occur due to a primary change in the pulmonary arteries or it can be secondary to a separate disease process; secondary causes include left-sided heart failure (ruled out by pulmonary capillary wedge pressure ≤12 mm Hg), chronic lung hypoxia (eg, interstitial lung disease), and chronic pulmonary thromboembolic disease. Pulmonary hypertension due to a primary change in the pulmonary arteries, termed **pulmonary arterial hypertension** (PAH), results from **proliferative vasculopathy** of the pulmonary arteriolar smooth muscle, which may occur in the setting of hereditary genetic mutation (**BMPR2 mutation** is most common), connective tissue disease, or HIV infection.

Endothelin is a potent **vasoconstrictor** that also promotes **smooth muscle cell proliferation**; it is typically found in high concentrations in patients with PAH and it is an important target of therapy for the disease. **Endothelin receptor antagonists** (eg, bosentan, ambrisentan) inhibit pulmonary arteriolar smooth muscle proliferation and alleviate vasoconstriction to lower pulmonary arterial pressure and improve dyspnea in patients with PAH.

(Choices A, B, and D) Aldosterone (mineralocorticoid) receptor antagonists (eg, spironolactone), angiotensin II receptor blockers (eg, losartan), and beta blockers (antagonists of the beta-1 adrenergic receptors that norepinephrine stimulates, eg, metoprolol) help prevent cardiac remodeling in patients with left ventricular systolic dysfunction. These drugs can be used to treat pulmonary hypertension that develops secondary to left-sided heart failure; however, they are not used for PAH as a direct effect on pulmonary vascular remodeling has not been established.

(Choice E) In carcinoid syndrome, high circulating levels of serotonin may cause deposition of fibrous tissue on the right-sided heart valves, typically leading to tricuspid regurgitation and/or pulmonic stenosis. Agents that block the effects of serotonin (eg, octreotide) can be helpful in treating carcinoid syndrome; however, carcinoid syndrome would not explain the elevated pulmonary arterial pressure in this patient. The role of serotonin in PAH has not been well-defined.

https://t.me/USMLEWorldStep1
Show all

thromboembolic disease. Pulmonary hypertension due to a primary change in the pulmonary arteries, termed **pulmonary arterial hypertension** (PAH), results from **proliferative vasculopathy** of the pulmonary arteriolar smooth muscle, which may occur in the setting of hereditary genetic mutation (**BMPR2 mutation** is most common), connective tissue disease, or HIV infection.

Endothelin is a potent **vasoconstrictor** that also promotes **smooth muscle cell proliferation**; it is typically found in high concentrations in patients with PAH and it is an important target of therapy for the disease. **Endothelin receptor antagonists** (eg, bosentan, ambrisentan) inhibit pulmonary arteriolar smooth muscle proliferation and alleviate vasoconstriction to lower pulmonary arterial pressure and improve dyspnea in patients with PAH.

(Choices A, B, and D) Aldosterone (mineralocorticoid) receptor antagonists (eg, spironolactone), angiotensin II receptor blockers (eg, losartan), and beta blockers (antagonists of the beta-1 adrenergic receptors that norepinephrine stimulates, eg, metoprolol) help prevent cardiac remodeling in patients with left ventricular systolic dysfunction. These drugs can be used to treat pulmonary hypertension that develops secondary to left-sided heart failure; however, they are not used for PAH as a direct effect on pulmonary vascular remodeling has not been established.

(Choice E) In carcinoid syndrome, high circulating levels of serotonin may cause deposition of fibrous tissue on the right-sided heart valves, typically leading to tricuspid regurgitation and/or pulmonic stenosis. Agents that block the effects of serotonin (eg, octreotide) can be helpful in treating carcinoid syndrome; however, carcinoid syndrome would not explain the elevated pulmonary arterial pressure in this patient. The role of serotonin in PAH has not been well-defined.

Educational objective:
Pulmonary hypertension can occur due to a primary change in the pulmonary arteries (ie, pulmonary arterial hypertension) or it can be secondary to a separate disease process such as left-sided heart failure (ruled out by normal pulmonary capillary wedge pressure). Endothelin receptor antagonists (eg, bosentan, ambrisentan) lower pulmonary arterial pressure and improve dyspnea in patients with pulmonary arterial hypertension.

References

https://t.me/USMLEWorldStep1
Show all

Exhibit Display

Classification of pulmonary hypertension	
Pulmonary arterial hypertension (group 1)	• Primary change in pulmonary arteries ◦ Hereditary (eg, *BMPR2* mutation) ◦ Connective tissue disease (eg, RA, SS) ◦ HIV infection • Treatment targeted at endothelial dysfunction
Pulmonary hypertension (groups 2-5)	• Secondary to another disease process ◦ Left-sided heart failure (group 2) ◦ Chronic lung disease/hypoxia (group 3) ◦ Chronic pulmonary thromboembolism (group 4) ◦ Other (eg, sarcoidosis) (group 5) • Treatment aimed at underlying disease
RA = rheumatoid arthritis; **SS** = systemic sclerosis.	

New | Existing | My Notebook

This p
somet
enlarg
Pulmo
separa
wedge
thromb
pulmo
smoot
conne
Endot
in high
recep
allevia
(Choi
recept
norepi
dysfun
failure

https://t.me/USMLEWorldStep1
Show all

A 72-year-old woman is brought to the emergency department due to exertional chest pain. The patient is on vacation with her family and her symptoms began after arriving in the Colorado mountains. She has a history of coronary artery disease but has had no ischemic symptoms over the past several years. The patient is a lifetime nonsmoker and has no history of lung disease. Physical examination shows mild hypoxemia, clear lungs, an S4, and no extremity edema. ECG shows T-wave inversion in the lateral leads. Serum troponin and D-dimer levels are within normal limits. It is determined that decreased oxygen levels at high altitude in combination with an age-related decline in pulmonary function resulted in exacerbation of this patient's preexisting heart disease. Which of the following most likely contributed to this patient's current condition?

- A. Decreased chest wall mobility
- B. Decreased dead space ventilation
- C. Increased chemoreceptor responsiveness
- D. Increased forced vital capacity
- E. Increased lung elastic recoil

Submit

https://t.me/USMLEWorldStep1
Show all

A 72-year-old woman is brought to the emergency department due to exertional chest pain. The patient is on vacation with her family and her symptoms began after arriving in the Colorado mountains. She has a history of coronary artery disease but has had no ischemic symptoms over the past several years. The patient is a lifetime nonsmoker and has no history of lung disease. Physical examination shows mild hypoxemia, clear lungs, an S4, and no extremity edema. ECG shows T-wave inversion in the lateral leads. Serum troponin and D-dimer levels are within normal limits. It is determined that decreased oxygen levels at high altitude in combination with an age-related decline in pulmonary function resulted in exacerbation of this patient's preexisting heart disease. Which of the following most likely contributed to this patient's current condition?

- ✓ A. Decreased chest wall mobility (61%)
- B. Decreased dead space ventilation (6%)
- C. Increased chemoreceptor responsiveness (16%)
- D. Increased forced vital capacity (4%)
- E. Increased lung elastic recoil (10%)

Correct | 61% Answered correctly | 05 secs Time Spent | 2023 Version

Explanation

The reduced partial pressure of inspired oxygen at high altitude leads to **hypoxemia** (ie, reduced partial pressure of arterial oxygen [PaO_2]). **Hyperventilation** is the most immediate and important physiologic adjustment to high altitude; peripheral chemoreceptors stimulate increased minute ventilation (via both increased tidal volume and respiratory rate) to help increase PaO_2 and minimize the symptoms of hypoxemia (eg, headache, dyspnea).

https://t.me/USMLEWorldStep1
Show all

Explanation

The reduced partial pressure of inspired oxygen at high altitude leads to **hypoxemia** (ie, reduced partial pressure of arterial oxygen [PaO_2]). **Hyperventilation** is the most immediate and important physiologic adjustment to high altitude; peripheral chemoreceptors stimulate increased minute ventilation (via both increased tidal volume and respiratory rate) to help increase PaO_2 and minimize the symptoms of hypoxemia (eg, headache, dyspnea).

In older individuals (eg, **age >65**), the body is less able to compensate for the hypoxemia at high altitude due to a number of age-related changes to the respiratory system. These changes include the following:

- **Decreased chest wall compliance:** Calcification of the intercostal joints and tendon insertion sites, as well as degeneration of the spine (eg, kyphosis), reduces chest wall expansion and limits the potential increase in tidal volume.
- **Decreased alveolar elastic recoil**: Degeneration of elastin causes increased alveolar compliance with alveolar enlargement and increased air trapping. This increases residual volume and decreases forced vital capacity, further limiting the achievable increase in tidal volume **(Choices D and E)**.
- Increased alveolar-arterial O_2 gradient: The alveolar enlargement increases ventilation-perfusion mismatch and decreases the efficiency of O_2 exchange in 2 ways. First, it decreases the percentage of alveolar surface area in contact with alveolar capillaries, effectively increasing dead space **(Choice B)**. Second, the increased air trapping decreases ventilation of highly perfused alveoli at the base of the lungs.

In this elderly patient, the body's ability to maintain PaO_2 at **high altitude** has likely been reduced, and, given her underlying coronary artery disease, she is likely experiencing **angina** (eg, exertional chest pain) due to inadequate O_2 supply to the myocardium.

(Choice C) Aging appears to have minimal effect on chemoreceptor responsiveness; therefore, respiratory drive is appropriately increased at high altitude. Age-related changes that reduce the mechanical efficiency of the respiratory system (ie, ability to respond to increased respiratory drive) are primarily responsible for reduced

https://t.me/USMLEWorldStep1
Show all

In older individuals (eg, **age >65**), the body is less able to compensate for the hypoxemia at high altitude due to a number of age-related changes to the respiratory system. These changes include the following:

- **Decreased chest wall compliance:** Calcification of the intercostal joints and tendon insertion sites, as well as degeneration of the spine (eg, kyphosis), reduces chest wall expansion and limits the potential increase in tidal volume.
- **Decreased alveolar elastic recoil**: Degeneration of elastin causes increased alveolar compliance with alveolar enlargement and increased air trapping. This increases residual volume and decreases forced vital capacity, further limiting the achievable increase in tidal volume **(Choices D and E)**.
- Increased alveolar-arterial O_2 gradient: The alveolar enlargement increases ventilation-perfusion mismatch and decreases the efficiency of O_2 exchange in 2 ways. First, it decreases the percentage of alveolar surface area in contact with alveolar capillaries, effectively increasing dead space **(Choice B)**. Second, the increased air trapping decreases ventilation of highly perfused alveoli at the base of the lungs.

In this elderly patient, the body's ability to maintain PaO_2 at **high altitude** has likely been reduced, and, given her underlying coronary artery disease, she is likely experiencing **angina** (eg, exertional chest pain) due to inadequate O_2 supply to the myocardium.

(Choice C) Aging appears to have minimal effect on chemoreceptor responsiveness; therefore, respiratory drive is appropriately increased at high altitude. Age-related changes that reduce the mechanical efficiency of the respiratory system (ie, ability to respond to increased respiratory drive) are primarily responsible for reduced compensation for hypoxemia at high altitude.

Educational objective:
Age-related changes to the respiratory system include decreased chest wall compliance and decreased alveolar elastic recoil with resulting alveolar enlargement and air trapping. These changes limit the potential increase in tidal volume and also increase the alveolar-arterial O_2 gradient (ie, decrease the efficiency of alveolar-capillary gas exchange), reducing the ability to compensate for hypoxemia.

https://t.me/USMLEWorldStep1
Show all

of arterial oxygen [PaO_2]). **Hyperventilation** is the most immediate and important physiologic adjustment to high altitude; peripheral chemoreceptors stimulate increased minute ventilation (via both increased tidal volume and respira

In olde
numbe

- **D**
- **D**
- **I**

In this
underl
O_2 sup

(Choi
approp
respira
compe

Educa
Age-re

Exhibit Display

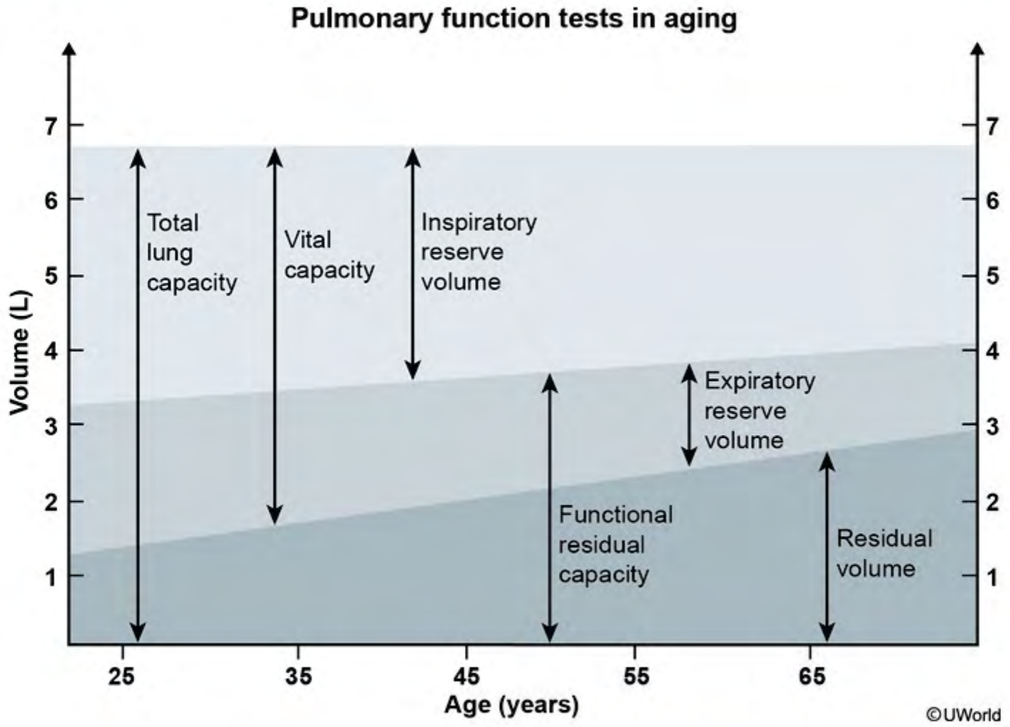

Zoom In | Zoom Out | Reset | New | Existing | My Notebook

https://t.me/USMLEWorldStep1
Show all

of arterial oxygen [PaO_2]). **Hyperventilation** is the most immediate and important physiologic adjustment to high altitude; peripheral chemoreceptors stimulate increased minute ventilation (via both increased tidal volume and respira

In olde
numbe

- **D**
- **D**
- **I**

In this
underl
O_2 sup

(Choi
approp
respira
compe

Educa
Age-related changes to the respiratory system include decreased chest wall compliance and decreased alveolar

Exhibit Display

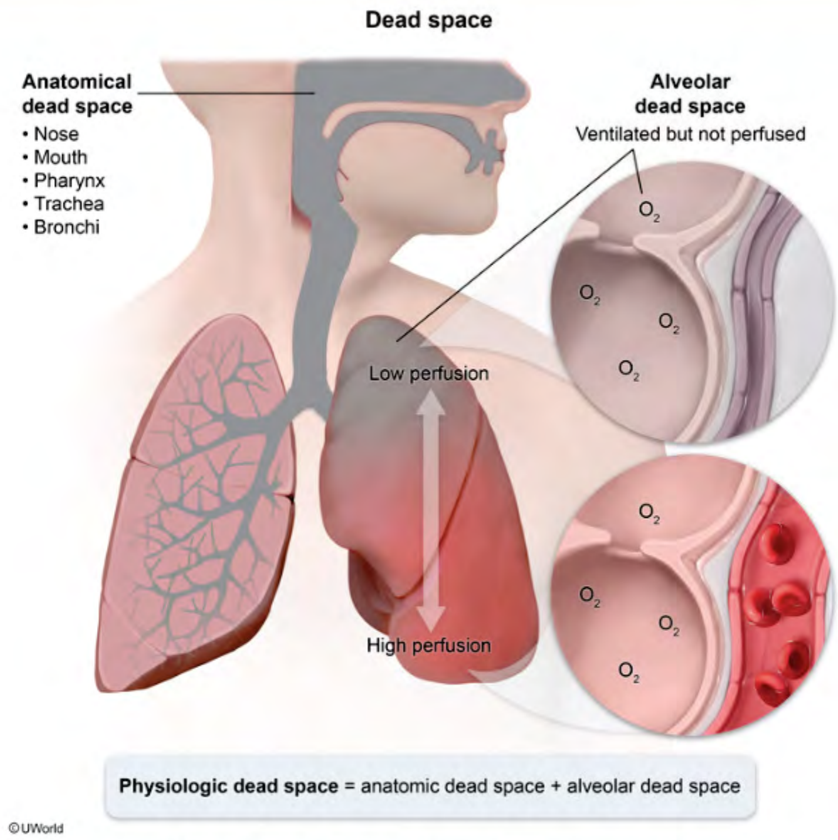

Zoom In | Zoom Out | Reset | New | Existing | My Notebook

https://t.me/USMLEWorldStep1
Show all

A 14-year-old girl is brought to the office due to intermittent shortness of breath over the past 4 months. She is unable to link the episodes to specific events or exposures. The patient has no prior medical conditions and takes no medications. She does not smoke and has no second-hand tobacco exposure. Her family has a cat that remains indoors. There is no significant family history. Blood pressure is 110/65 mm Hg, pulse is 80/min, and respirations are 16/min. On physical examination, heart sounds are normal and the lungs are clear to auscultation. Lung function tests reveal a FEV1/FVC ratio of 83%. Which of the following would be most helpful in excluding a diagnosis of asthma in this patient?

- A. Absence of peripheral blood eosinophilia
- B. Negative allergy skin tests
- C. Negative methacholine challenge
- D. Normal chest radiography
- E. Normal total serum IgE level

Submit

https://t.me/USMLEWorldStep1
Show all

A 14-year-old girl is brought to the office due to intermittent shortness of breath over the past 4 months. She is unable to link the episodes to specific events or exposures. The patient has no prior medical conditions and takes no medications. She does not smoke and has no second-hand tobacco exposure. Her family has a cat that remains indoors. There is no significant family history. Blood pressure is 110/65 mm Hg, pulse is 80/min, and respirations are 16/min. On physical examination, heart sounds are normal and the lungs are clear to auscultation. Lung function tests reveal a FEV1/FVC ratio of 83%. Which of the following would be most helpful in excluding a diagnosis of asthma in this patient?

- A. Absence of peripheral blood eosinophilia (1%)
- ✗ B. Negative allergy skin tests (1%)
- ✓ C. Negative methacholine challenge (93%)
- D. Normal chest radiography (0%)
- E. Normal total serum IgE level (2%)

Incorrect
Correct answer
C

93%
Answered correctly

04 secs
Time Spent

2023
Version

Explanation

Asthma is a disease of airway inflammation and bronchial hyperreactivity, with **variable airflow obstruction** that improves with bronchodilator medications. Classic symptoms include cough, shortness of breath, and wheeze, although these are nonspecific. Most patients with asthma have a chronic reduction in the FEV1/FVC ratio (≤70%; normal ~80%) due to increased expiratory airflow resistance. However, asymptomatic patients may have normal lung function tests, with alterations in lung function occurring only during exacerbations. This patient with intermittent shortness of breath has a normal FEV1/FVC ratio, therefore, further studies are required to exclude the

https://t.me/USMLEWorldStep1
Show all

Asthma is a disease of airway inflammation and bronchial hyperreactivity, with **variable airflow obstruction** that improves with bronchodilator medications. Classic symptoms include cough, shortness of breath, and wheeze, although these are nonspecific. Most patients with asthma have a chronic reduction in the FEV1/FVC ratio (≤70%; normal ~80%) due to increased expiratory airflow resistance. However, asymptomatic patients may have normal lung function tests, with alterations in lung function occurring only during exacerbations. This patient with intermittent shortness of breath has a normal FEV1/FVC ratio, therefore, further studies are required to exclude the diagnosis of asthma.

Bronchial challenge testing is a highly sensitive test with **high negative predictive value** used to assess **bronchial hyperreactivity** and exclude asthma. A provocative stimulus (typically aerosolized **methacholine**, a cholinergic muscarinic agonist) is administered at increasing concentrations to induce bronchoconstriction. Patients with asthma are hyperresponsive to this stimulus and experience a decline in FEV1 at lower doses than nonasthmatics. However, the test is nonspecific and positive results may also be seen with chronic obstructive pulmonary disease, cystic fibrosis, and allergic rhinitis.

(Choice A) Although peripheral eosinophil counts may be elevated in asthmatics, the presence of eosinophilia is not a sensitive or specific indicator of asthma and may be seen in other allergic diseases (eg, allergic rhinitis, drug reactions), parasitic infections (eg, strongyloides), and certain myeloid neoplasms.

(Choice B) Most patients with asthma are sensitive to a variety of inhaled allergens, and in such patients, skin tests to various allergens will provoke a localized, immediate, type I hypersensitivity reaction. However, patients may have allergic disease without asthma and patients with nonallergic (intrinsic) asthma may not have allergies; therefore this test is not useful for diagnosing asthma.

(Choice D) During an asthma attack, the lungs may appear hyperinflated on chest x-ray. However, chest x-rays are often normal between attacks; therefore, a chest x-ray cannot exclude asthma.

(Choice E) Although serum IgE levels are generally elevated in patients with allergic asthma, patients with nonimmune-mediated asthma have normal levels of serum IgE. Intrinsic asthma can be precipitated by pulmonary

https://t.me/USMLEWorldStep1
Show all

diagnosis of asthma.

Bronchial challenge testing is a highly sensitive test with **high negative predictive value** used to assess **bronchial hyperreactivity** and exclude asthma. A provocative stimulus (typically aerosolized **methacholine**, a cholinergic muscarinic agonist) is administered at increasing concentrations to induce bronchoconstriction. Patients with asthma are hyperresponsive to this stimulus and experience a decline in FEV1 at lower doses than nonasthmatics. However, the test is nonspecific and positive results may also be seen with chronic obstructive pulmonary disease, cystic fibrosis, and allergic rhinitis.

(Choice A) Although peripheral eosinophil counts may be elevated in asthmatics, the presence of eosinophilia is not a sensitive or specific indicator of asthma and may be seen in other allergic diseases (eg, allergic rhinitis, drug reactions), parasitic infections (eg, strongyloides), and certain myeloid neoplasms.

(Choice B) Most patients with asthma are sensitive to a variety of inhaled allergens, and in such patients, skin tests to various allergens will provoke a localized, immediate, type I hypersensitivity reaction. However, patients may have allergic disease without asthma and patients with nonallergic (intrinsic) asthma may not have allergies; therefore this test is not useful for diagnosing asthma.

(Choice D) During an asthma attack, the lungs may appear hyperinflated on chest x-ray. However, chest x-rays are often normal between attacks; therefore, a chest x-ray cannot exclude asthma.

(Choice E) Although serum IgE levels are generally elevated in patients with allergic asthma, patients with nonimmune-mediated asthma have normal levels of serum IgE. Intrinsic asthma can be precipitated by pulmonary infections (especially viral), aspirin ingestion, cold air, inhaled irritants (eg, perfumes), stress, and exercise.

Educational objective:
Bronchial challenge testing is a highly sensitive but nonspecific measure that can help exclude a diagnosis of asthma. A provocative stimulus (typically aerosolized methacholine) is administered at increasing concentrations to induce bronchoconstriction. Patients with asthma are hyperresponsive to this stimulus and experience a decline in FEV1 at lower doses than nonasthmatics.

https://t.me/USMLEWorldStep1
Show all

A 63-year-old woman comes to the office due to slowly progressive dyspnea on exertion and cough productive of white-yellow sputum over the past several years. She has a history of rheumatoid arthritis and seasonal allergies. The patient has smoked a pack of cigarettes daily for 40 years. Blood pressure is 135/80 mm Hg and pulse is 76/min. Lung examination demonstrates bilateral expiratory wheezes, and chest x-ray reveals hyperinflated lungs. Pulmonary function test results are as follows:

Forced expiratory volume in 1 second (FEV1)	58% of predicted	(normal >80%)
FEV1/Forced vital capacity ratio	62%	(normal >75%)
Diffusion capacity	67% of predicted	(normal >80%)

Which of the following cell types likely contributed the most to this patient's decline in pulmonary function?

- A. B lymphocytes
- B. $CD4^+$ T lymphocytes
- C. Eosinophils
- D. Mast cells
- E. Neutrophils

Submit

https://t.me/USMLEWorldStep1
Show all

A 63-year-old woman comes to the office due to slowly progressive dyspnea on exertion and cough productive of white-yellow sputum over the past several years. She has a history of rheumatoid arthritis and seasonal allergies. The patient has smoked a pack of cigarettes daily for 40 years. Blood pressure is 135/80 mm Hg and pulse is 76/min. Lung examination demonstrates bilateral expiratory wheezes, and chest x-ray reveals hyperinflated lungs. Pulmonary function test results are as follows:

Forced expiratory volume in 1 second (FEV1)	58% of predicted	(normal >80%)
FEV1/Forced vital capacity ratio	62%	(normal >75%)
Diffusion capacity	67% of predicted	(normal >80%)

Which of the following cell types likely contributed the most to this patient's decline in pulmonary function?

- ✗ A. B lymphocytes (1%)
- B. $CD4^+$ T lymphocytes (17%)
- C. Eosinophils (11%)
- D. Mast cells (11%)
- ✓ E. Neutrophils (56%)

Incorrect
Correct answer
E

56%
Answered correctly

05 secs
Time Spent

2023
Version

Explanation

Inflammatory cells & COPD

Cigarette smoke & other irritants

https://t.me/USMLEWorldStep1
Show all

Correct answer
E

56%
Answered correctly

05 secs
Time Spent

2023
Version

Exhibit Display

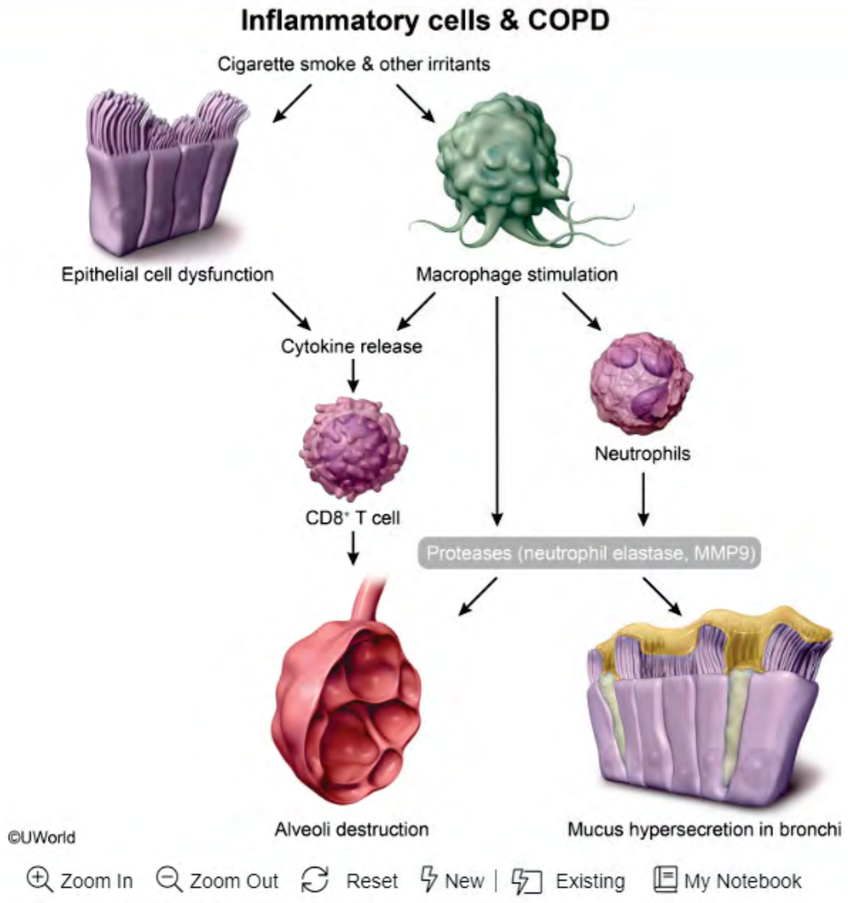

Zoom In Zoom Out Reset New | Existing My Notebook

https://t.me/USMLEWorldStep1

Show all

This patient with dyspnea, productive cough, and an obstructive pattern on pulmonary function testing—in the setting of a prolonged smoking history—likely has **chronic obstructive pulmonary disease** (COPD). COPD is characterized by chronic airway inflammation, which results in both parenchymal destruction (emphysema) and remodeling of the airways (chronic bronchitis).

The primary cell lines that are increased in the airways of patients with COPD are **neutrophils**, **macrophages**, and **$CD8^+$ T lymphocytes**. These cells release cytotoxic enzymes and proteases that cause alveolar damage, reduced ciliary motion, and increased mucus secretion by goblet cells. Although more abundant, the infiltrating inflammatory cells show impaired ability to phagocytize bacterial pathogens, contributing to increased risk of respiratory infections such as community-acquired pneumonia.

(Choice A) The involvement of B lymphocytes in COPD pathogenesis is controversial; however, they do not appear to have a major role, and their increased numbers may actually be protective against bacterial colonization.

(Choice B) Although $CD4^+$ T lymphocytes are slightly increased in COPD, their numbers and pathologic role are much less significant than those of $CD8^+$ T lymphocytes; $CD4^+$ T lymphocytes (in particular T_H2 cells) play a more important role in asthma pathogenesis.

(Choice C) Eosinophils play an important role in asthma but do not appear to have a major impact in COPD. Their increased presence in patients with COPD may indicate coexisting asthma.

(Choice D) Patients with mast cell disorders can have flushing, abdominal discomfort, and respiratory symptoms such as dyspnea and wheezing due to bronchoconstriction. However, mast cells do not play an important role in the pathogenesis of COPD.

Educational objective:
Neutrophils, macrophages, and $CD8^+$ T lymphocytes are the primary mediators of disease in chronic obstructive pulmonary disease. They secrete enzymes and proteases that cause and perpetuate both the alveolar destruction of emphysema and the mucus hypersecretion found in chronic bronchitis.

https://t.me/USMLEWorldStep1
Show all

setting of a prolonged smoking history likely has **chronic obstructive pulmonary disease** (COPD). COPD is characterized by chronic airway inflammation, which results in both parenchymal destruction (emphysema) and remodeling of the airways (chronic bronchitis).

The primary cell lines that are increased in the airways of patients with COPD are **neutrophils**, **macrophages**, and **$CD8^+$ T lymphocytes**. These cells release cytotoxic enzymes and proteases that cause alveolar damage, reduced ciliary motion, and increased mucus secretion by goblet cells. Although more abundant, the infiltrating inflammatory cells show impaired ability to phagocytize bacterial pathogens, contributing to increased risk of respiratory infections such as community-acquired pneumonia.

(Choice A) The involvement of B lymphocytes in COPD pathogenesis is controversial; however, they do not appear to have a major role, and their increased numbers may actually be protective against bacterial colonization.

(Choice B) Although $CD4^+$ T lymphocytes are slightly increased in COPD, their numbers and pathologic role are much less significant than those of $CD8^+$ T lymphocytes; $CD4^+$ T lymphocytes (in particular T_H2 cells) play a more important role in asthma pathogenesis.

(Choice C) Eosinophils play an important role in asthma but do not appear to have a major impact in COPD. Their increased presence in patients with COPD may indicate coexisting asthma.

(Choice D) Patients with mast cell disorders can have flushing, abdominal discomfort, and respiratory symptoms such as dyspnea and wheezing due to bronchoconstriction. However, mast cells do not play an important role in the pathogenesis of COPD.

Educational objective:
Neutrophils, macrophages, and $CD8^+$ T lymphocytes are the primary mediators of disease in chronic obstructive pulmonary disease. They secrete enzymes and proteases that cause and perpetuate both the alveolar destruction of emphysema and the mucus hypersecretion found in chronic bronchitis.

Pathophysiology	Pulmonary & Critical Care	COPD
Subject	System	Topic

https://t.me/USMLEWorldStep1
Show all

A 56-year-old man is evaluated for dyspnea and chest discomfort. Medical history includes hypertension, type 2 diabetes mellitus, and chronic kidney disease. Temperature is 37.8 C (100 F), blood pressure is 160/90 mm Hg, pulse is 98/min, and respirations are 24/min. BMI is 31 kg/m^2. The patient undergoes a 2-part nuclear medicine test. During the first part, he breathes in a radioactive tracer and a lung scan is performed. In the second part of the test, he is given an intravenous injection of a different radioactive material while breathing normal air, and the scan is repeated. When the images are compared, a large area of the lower right lung is not visualized in the second scan. Based on the observed findings, which of the following underlying disease processes is most likely present in this patient?

- A. Deep venous thrombosis
- B. Endobronchial neoplasm
- C. Left ventricular infarction
- D. Spontaneous pneumothorax
- E. Viral pleuritis with effusion

Submit

https://t.me/USMLEWorldStep1
Show all

A 56-year-old man is evaluated for dyspnea and chest discomfort. Medical history includes hypertension, type 2 diabetes mellitus, and chronic kidney disease. Temperature is 37.8 C (100 F), blood pressure is 160/90 mm Hg, pulse is 98/min, and respirations are 24/min. BMI is 31 kg/m^2. The patient undergoes a 2-part nuclear medicine test. During the first part, he breathes in a radioactive tracer and a lung scan is performed. In the second part of the test, he is given an intravenous injection of a different radioactive material while breathing normal air, and the scan is repeated. When the images are compared, a large area of the lower right lung is not visualized in the second scan. Based on the observed findings, which of the following underlying disease processes is most likely present in this patient?

- ✓ A. Deep venous thrombosis (83%)
- B. Endobronchial neoplasm (4%)
- C. Left ventricular infarction (1%)
- D. Spontaneous pneumothorax (4%)
- E. Viral pleuritis with effusion (6%)

Correct

83% Answered correctly

05 secs Time Spent

2023 Version

Explanation

https://t.me/USMLEWorldStep1
Show all

(homogeneous) (multiple defects)

Exhibit Display

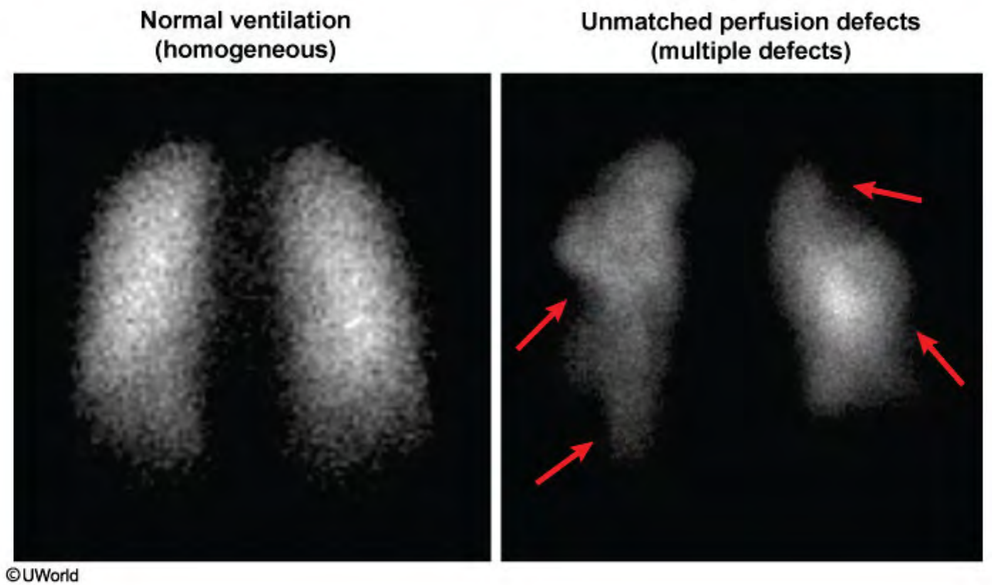

Zoom In Zoom Out Reset New | Existing My Notebook

This p
pulmo
that su
chest
modal
(eg, co

V/Q sc
aeroso
tracer
Norma
mism
can be
and malignancies that obstruct arterial blood flow.

https://t.me/USMLEWorldStep1
Show all

This patient, with dyspnea, chest discomfort, and a perfusion defect on ventilation-perfusion (V/Q) scan likely has a **pulmonary embolism** (PE). PEs are most commonly caused by **deep vein thrombosis** in the lower extremities that subsequently embolizes to the pulmonary vasculature. Signs and symptoms include acute-onset pleuritic chest pain, shortness of breath, tachycardia, and hypotension. CT pulmonary angiography is typically the imaging modality of choice; however, **V/Q scans** are helpful in evaluating patients in whom angiography is contraindicated (eg, contrast allergy, renal failure).

V/Q scans are 2-part studies that compare regional ventilation and perfusion. The initial phase uses a radiolabeled aerosol that is inhaled and delivered throughout the tracheobronchial tree. The second phase uses an intravenous tracer that is distributed throughout the pulmonary vasculature. The images are then overlaid for comparison. Normal results show even distribution of both radionucleotide tracers throughout the lung (ie, V/Q match). **V/Q mismatch** occurs when alveoli are ventilated but not perfused (ie, a defect in the perfusion phase). This pattern can be seen in diseases that increase physiologic dead space, including **pulmonary embolism** (as in this patient) and malignancies that obstruct arterial blood flow.

(Choices B, C, and E) Endobronchial neoplasms can cause obstruction of the airway. Left ventricular infarction can cause pulmonary edema. Exudative pleuritis causes a pleural effusion, often with compression and atelectasis of the adjacent lung. These diseases cause ventilation defects, typically with matched perfusion defects as the resulting alveolar hypoxia induces pulmonary vasoconstriction. However, this patient has isolated perfusion defects.

(Choice D) Spontaneous pneumothorax would cause compression of the ipsilateral lung; V/Q scan would show decreased lung volume on ventilation and perfusion images compared to the normal lung.

Educational objective:
Ventilation-perfusion (V/Q) scans use radiotracers to compare the ventilation and blood perfusion of each area of the lung. V/Q mismatch with perfusion defects are often indicative of a pulmonary embolism, which are most commonly caused by deep vein thrombosis in the lower extremities that embolizes to the pulmonary vasculature.

References

https://t.me/USMLEWorldStep1
Show all

A 30-year-old woman who normally resides in Florida (elevation near sea level) plans to travel to La Paz, Bolivia (elevation 3,600 m [11,900 ft]) for a week-long business trip. Medical history is unremarkable. Which of the following physiologic changes are expected during the patient's week in La Paz?

	Plasma volume	Pulmonary arterial resistance	Cardiac output
○ A.	↓	↓	↓
○ B.	↓	↓	↑
○ C.	↓	↑	↑
○ D.	↑	↓	↓
○ E.	↑	↑	↓

Submit

https://t.me/USMLEWorldStep1
Show all

A 30-year-old woman who normally resides in Florida (elevation near sea level) plans to travel to La Paz, Bolivia (elevation 3,600 m [11,900 ft]) for a week-long business trip. Medical history is unremarkable. Which of the following physiologic changes are expected during the patient's week in La Paz?

	Plasma volume	Pulmonary arterial resistance	Cardiac output	
✗ A.	↓	↓	↓	(1%)
B.	↓	↓	↑	(17%)
✓ C.	↓	↑	↑	(52%)
D.	↑	↓	↓	(5%)
E.	↑	↑	↓	(22%)

Incorrect
Correct answer
C

52%
Answered correctly

03 secs
Time Spent

2023
Version

Explanation

Physiologic responses to high altitude	
Lungs	• Hypoxic vasoconstriction → ↑ PVR & PAP • ↑ minute ventilation → ↑ PaO_2 & ↓ $PaCO_2$
Kidneys	• ↑ erythropoietin production • ↑ HCO_3^- excretion (compensatory metabolic acidosis)

https://t.me/USMLEWorldStep1

Physiologic responses to high altitude	
Lungs	• Hypoxic vasoconstriction → ↑ PVR & PAP • ↑ minute ventilation → ↑ PaO_2 & ↓ $PaCO_2$
Kidneys	• ↑ erythropoietin production • ↑ HCO_3^- excretion (compensatory metabolic acidosis) • Aldosterone suppression with diuresis & ↓ plasma volume
Blood	• ↑ 2,3-biphosphoglycerate → ↑ O_2 unloading in tissues • Upregulation of HIF → erythropoiesis & angiogenesis • ↑ hemoglobin concentration (O_2-carrying capacity)
Heart	• ↑ heart rate & slightly ↑ cardiac output
Brain	• Vasodilation with ↑ cerebral blood flow

HIF = hypoxia inducible factor; **PAP** = pulmonary arterial pressure; **PVR** = pulmonary vascular resistance.

The decreased atmospheric pressure at **high altitude** (eg, >2,500 m [~8,000 ft]) reduces the partial pressure of inspired oxygen (PiO_2). Such an environment stimulates an array of **physiologic responses** aimed at maintaining adequate O_2 delivery to the tissues. The initial responses to high altitude include:

- Peripheral chemoreceptors in the aorta and carotid body stimulate **hyperventilation** in an effort to increase arterial oxygenation (PaO_2). The hyperventilation also increases CO_2 removal to decrease $PaCO_2$ and cause respiratory alkalosis. The alkalosis initially shifts the hemoglobin dissociation curve to the left to increase O_2 uptake in the lungs.
- Hypoxic pulmonary vasoconstriction occurs to minimize ventilation-perfusion mismatching and optimize pulmonary O_2 uptake. This leads to **increased pulmonary vascular resistance**, which increases pulmonary arterial pressure.

https://t.me/USMLEWorldStep1
Show all

The decreased atmospheric pressure at **high altitude** (eg, >2,500 m [~8,000 ft]) reduces the partial pressure of inspired oxygen (PiO_2). Such an environment stimulates an array of **physiologic responses** aimed at maintaining adequate O_2 delivery to the tissues. The initial responses to high altitude include:

- Peripheral chemoreceptors in the aorta and carotid body stimulate **hyperventilation** in an effort to increase arterial oxygenation (PaO_2). The hyperventilation also increases CO_2 removal to decrease $PaCO_2$ and cause respiratory alkalosis. The alkalosis initially shifts the hemoglobin dissociation curve to the left to increase O_2 uptake in the lungs.
- Hypoxic pulmonary vasoconstriction occurs to minimize ventilation-perfusion mismatching and optimize pulmonary O_2 uptake. This leads to **increased pulmonary vascular resistance**, which increases pulmonary arterial pressure.
- Sympathetic activity is increased, leading to **increased heart rate and cardiac output**.
- Despite the drop in $PaCO_2$ (which encourages cerebral vasoconstriction), reduced PaO_2 and marked tissue hypoxia lead to overall cerebral vasodilation to increase cerebral blood flow.

Additional responses occur over the next 24-48 hours:

- The kidneys increase HCO_3^- excretion (compensatory metabolic acidosis), which decreases blood pH. Because central chemoreceptors inhibit ventilation when pH gets too high, the HCO_3^- excretion allows for additional hyperventilation.
- Hypoxemia suppresses aldosterone activity, which together with increased HCO_3^- excretion results in diuresis and total body volume loss. The **reduced plasma volume** increases hematocrit and also reduces cardiac preload to decrease myocardial O_2 demand. There is a resulting decrease in stroke volume, but cardiac output remains slightly increased from baseline due to increased heart rate.
- Red blood cells increase production of 2,3-biphosphoglycerate to shift the hemoglobin dissociation curve back to the right and facilitate O_2 unloading in the tissues. In addition, the kidneys increase secretion of

https://t.me/USMLEWorldStep1
Show all

hypoxia lead to overall cerebral vasodilation to increase cerebral blood flow.

Additional responses occur over the next 24-48 hours:

- The kidneys increase HCO_3^- excretion (compensatory metabolic acidosis), which decreases blood pH. Because central chemoreceptors inhibit ventilation when pH gets too high, the HCO_3^- excretion allows for additional hyperventilation.
- Hypoxemia suppresses aldosterone activity, which together with increased HCO_3^- excretion results in diuresis and total body volume loss. The **reduced plasma volume** increases hematocrit and also reduces cardiac preload to decrease myocardial O_2 demand. There is a resulting decrease in stroke volume, but cardiac output remains slightly increased from baseline due to increased heart rate.
- Red blood cells increase production of 2,3-biphosphoglycerate to shift the hemoglobin dissociation curve back to the right and facilitate O_2 unloading in the tissues. In addition, the kidneys increase secretion of erythropoietin. There is also upregulation of hypoxia inducible factor (HIF) in cells throughout the body. HIF stimulates erythropoiesis as well as increased angiogenesis in skeletal muscle and other tissues to improve O_2 delivery.

Individuals who remain at high altitude for an extended period will experience the full benefit of increased erythropoietin secretion and upregulation of HIF, as secondary polycythemia (increased O_2 carrying capacity) and angiogenesis are maximized after several weeks.

Educational objective:
An array of physiologic responses takes place to maintain adequate O_2 delivery to the tissues in the hypoxic environment at high altitude. These include hypoxic pulmonary vasoconstriction (increased pulmonary vascular resistance), increased sympathetic activity to increase cardiac output, and aldosterone suppression to reduce plasma volume.

References

https://t.me/USMLEWorldStep1
Show all

Brain	• Vasodilation with ↑ cerebral blood flow

Exhibit Display

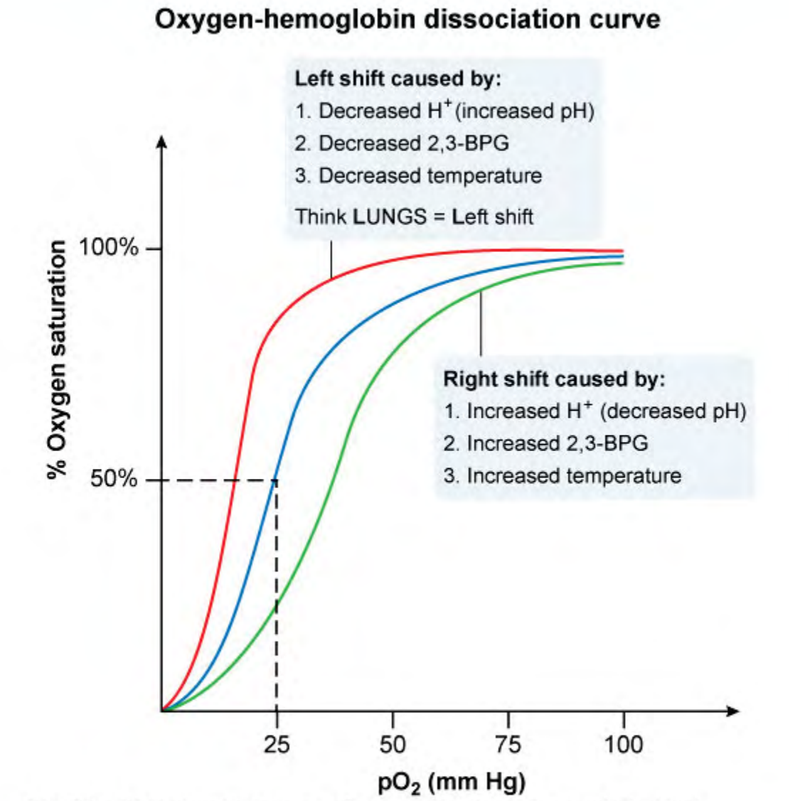

2,3-BPG = 2,3-bisphosphoglycerate; **pO_2** = partial pressure of oxygen in the blood.

©UWorld

Zoom In | Zoom Out | Reset | New | Existing | My Notebook

https://t.me/USMLEWorldStep1

A 35-year-old woman comes to the office due to 3 months of progressive dyspnea on exertion, nonproductive cough, and fatigue. She has a history of seasonal allergies for which she takes over-the-counter antihistamines. The patient ascribes her symptoms to smoking cigarettes and has cut down from a pack to 3 or 4 cigarettes daily. Her mother has rheumatoid arthritis. CT-guided lung biopsy is performed; findings are shown in the image below.

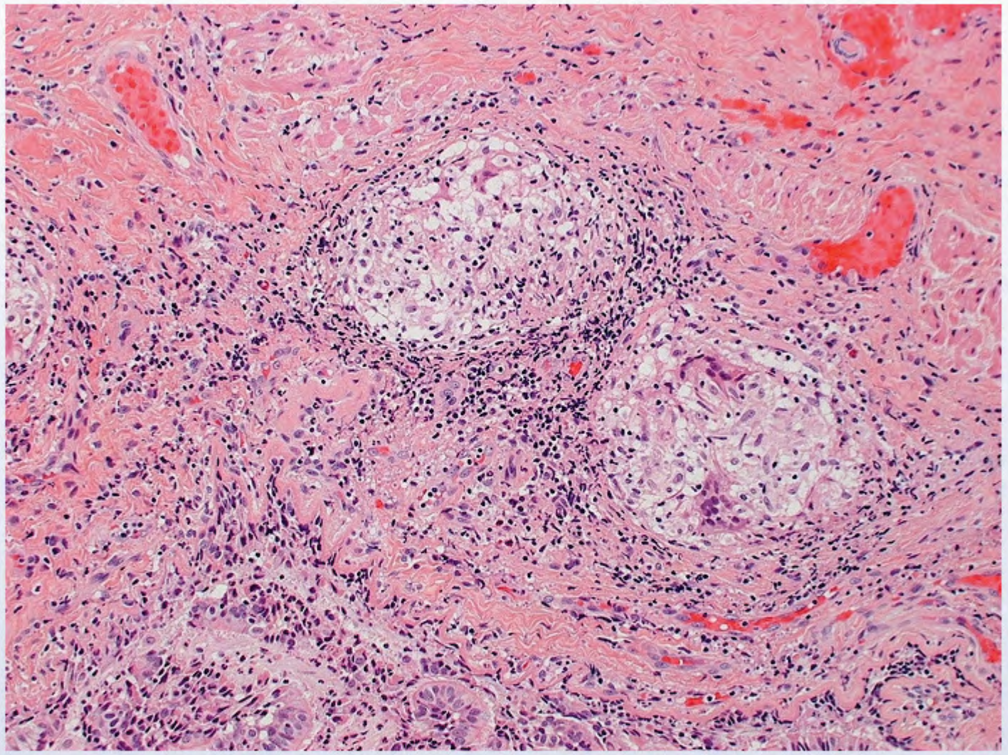

This patient most likely has which of the following conditions?

- A. Bronchopulmonary aspergillosis
- B. Churg-Strauss syndrome

https://t.me/USMLEWorldStep1
Show all

A 35-year-old woman comes to the office due to 3 months of progressive dyspnea on exertion, nonproductive cough
The pa
Her m

Exhibit Display

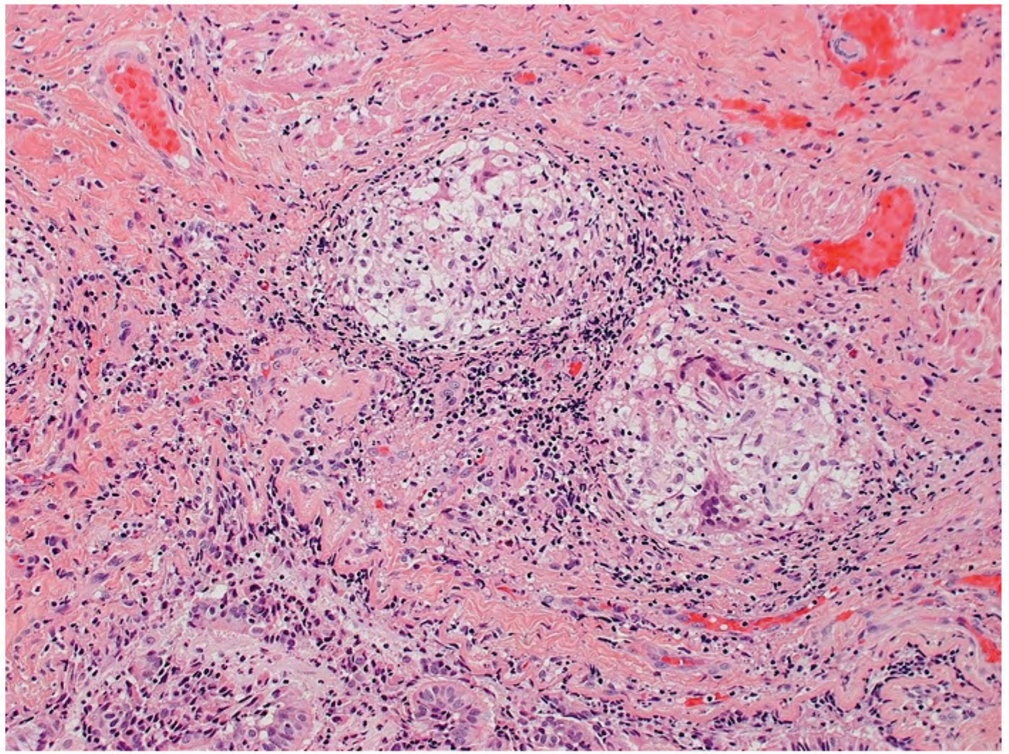

Zoom In Zoom Out Reset New | Existing My Notebook

This p

B. Churg-Strauss syndrome

https://t.me/USMLEWorldStep1

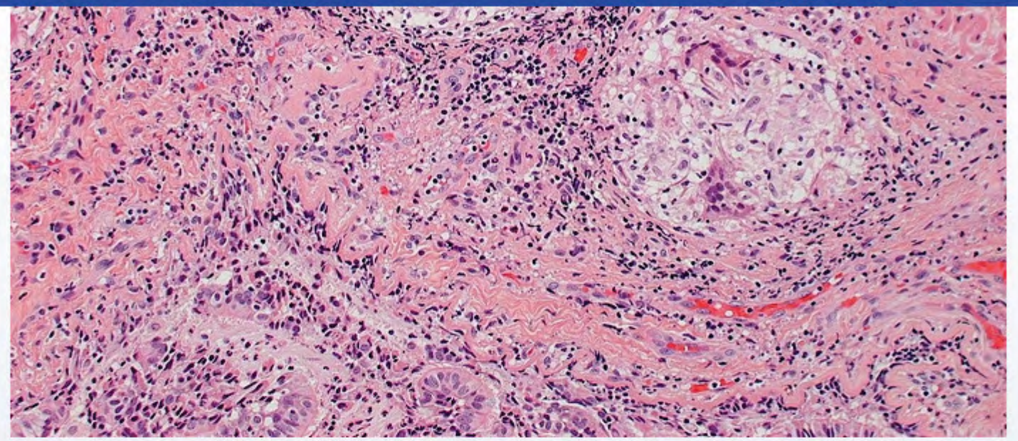

This patient most likely has which of the following conditions?

- A. Bronchopulmonary aspergillosis
- B. Churg-Strauss syndrome
- C. Desquamative interstitial pneumonia
- D. Hodgkin lymphoma
- E. Idiopathic pulmonary fibrosis
- F. Progressive systemic sclerosis
- G. Pulmonary alveolar proteinosis
- H. Sarcoidosis
- I. Small cell lung carcinoma

Submit

https://t.me/USMLEWorldStep1
Show all

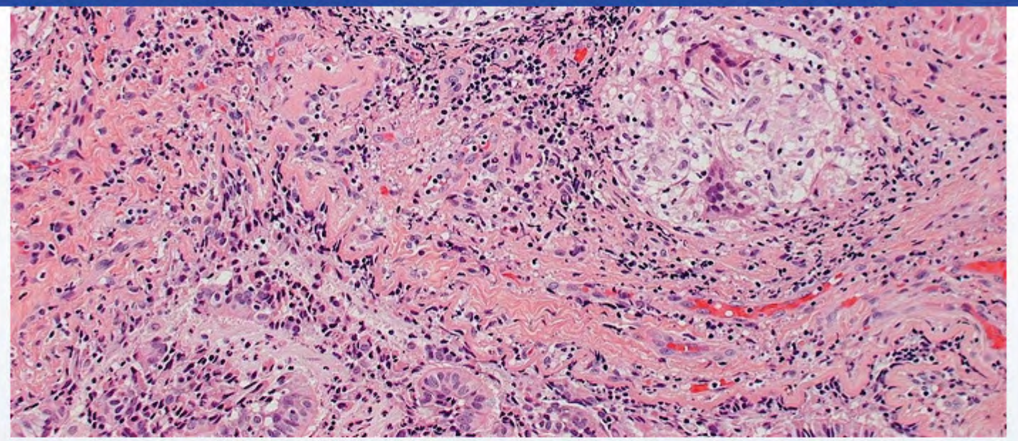

This patient most likely has which of the following conditions?

- A. Bronchopulmonary aspergillosis (2%)
- B. Churg-Strauss syndrome (9%)
- C. Desquamative interstitial pneumonia (1%)
- D. Hodgkin lymphoma (0%)
- E. Idiopathic pulmonary fibrosis (5%)
- ✗ F. Progressive systemic sclerosis (2%)
- G. Pulmonary alveolar proteinosis (1%)
- ✓ H. Sarcoidosis (74%)
- I. Small cell lung carcinoma (2%)

Incorrect
Correct answer
H

74%
Answered correctly

17 secs
Time Spent

2023
Version

https://t.me/USMLEWorldStep1
Show all

Exhibit Display

Sarcoidosis

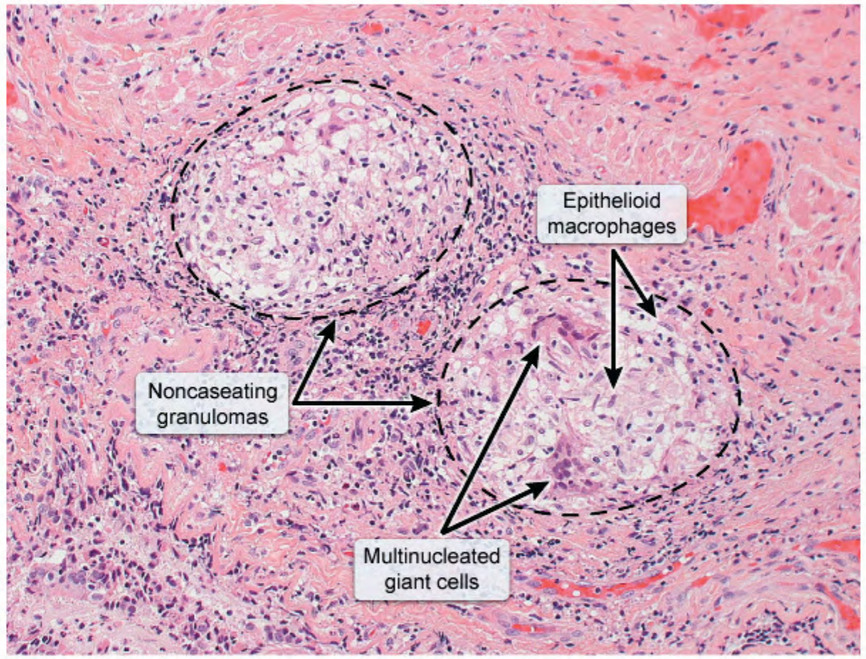

©UWorld

Zoom In | Zoom Out | Reset | New | Existing | My Notebook

This patient likely has **sarcoidosis**, a chronic multisystem disorder characterized by the formation of **noncaseating granulomas** (eg, epithelioid macrophages, multinucleated giant cells). It typically affects **young**

https://t.me/USMLEWorldStep1

©UWorld

This patient likely has **sarcoidosis**, a chronic multisystem disorder characterized by the formation of **noncaseating granulomas** (eg, epithelioid macrophages, multinucleated giant cells). It typically affects **young adults** and is more prevalent in African American individuals and in **women**.

Any organ can be affected, but the **lungs** are initially involved in most cases. Patients often have the insidious onset of respiratory symptoms (eg, cough, dyspnea, chest pain) accompanied by fatigue, fever, and weight loss. The disease may also be incidentally detected in asymptomatic patients with typical chest x-ray findings (eg, **bilateral hilar lymphadenopathy**, reticular opacities).

(Choice A) Allergic bronchopulmonary aspergillosis commonly occurs in patients with asthma or cystic fibrosis and presents with recurrent disease exacerbations. Microscopic examination would likely show mucin within the bronchial lumens with numerous eosinophils and rare *Aspergillus* hyphae.

(Choice B) Churg-Strauss syndrome (eosinophilic granulomatosis with polyangiitis) usually presents with chronic rhinosinusitis, asthma, and eosinophilia. The granulomas seen with Churg-Strauss syndrome typically have eosinophilic infiltration and extensive necrosis.

(Choices C, E, and G) Desquamative interstitial pneumonia (DIP), idiopathic pulmonary fibrosis (IPF), and pulmonary alveolar proteinosis (PAP) are associated with cigarette smoking and typically present with the insidious onset of progressive dyspnea and chronic cough. However, DIP is characterized by numerous intraalveolar macrophages, IPF is associated with patchy fibrosis and inflammation, and PAP demonstrates lipoproteinaceous material within the alveoli.

(Choice D) Hodgkin lymphoma typically presents with lymphadenopathy and B symptoms (eg, fever, night sweats, weight loss), and histopathology demonstrates Reed-Sternberg cells surrounded by inflammatory cells.

(Choice F) Systemic sclerosis results in progressive collagen deposition and fibrosis of the skin and visceral organs (eg, gastrointestinal tract, lungs, kidneys), which can lead to dyspnea and cough. However, biopsy would demonstrate excessive collagen deposition, not granulomas.

https://t.me/USMLEWorldStep1
Show all

and presents with recurrent disease exacerbations. Microscopic examination would likely show mucin within the bronchial lumens with numerous eosinophils and rare *Aspergillus* hyphae.

(Choice B) Churg-Strauss syndrome (eosinophilic granulomatosis with polyangiitis) usually presents with chronic rhinosinusitis, asthma, and eosinophilia. The granulomas seen with Churg-Strauss syndrome typically have eosinophilic infiltration and extensive necrosis.

(Choices C, E, and G) Desquamative interstitial pneumonia (DIP), idiopathic pulmonary fibrosis (IPF), and pulmonary alveolar proteinosis (PAP) are associated with cigarette smoking and typically present with the insidious onset of progressive dyspnea and chronic cough. However, DIP is characterized by numerous intraalveolar macrophages, IPF is associated with patchy fibrosis and inflammation, and PAP demonstrates lipoproteinaceous material within the alveoli.

(Choice D) Hodgkin lymphoma typically presents with lymphadenopathy and B symptoms (eg, fever, night sweats, weight loss), and histopathology demonstrates Reed-Sternberg cells surrounded by inflammatory cells.

(Choice F) Systemic sclerosis results in progressive collagen deposition and fibrosis of the skin and visceral organs (eg, gastrointestinal tract, lungs, kidneys), which can lead to dyspnea and cough. However, biopsy would demonstrate excessive collagen deposition, not granulomas.

(Choice I) Small cell carcinoma is a highly malignant lung cancer that is strongly associated with smoking. Histopathologic features include small cells with scant cytoplasm, granular nuclear chromatin (salt and pepper pattern), and indistinct nucleoli.

Educational objective:
Sarcoidosis often presents in young women with the insidious onset of respiratory symptoms (eg, cough, dyspnea, chest pain) accompanied by fatigue, fever, and weight loss. The characteristic histopathologic feature is noncaseating granulomas, which consist of aggregates of epithelioid macrophages, frequently with multinucleated giant cells.

Pathology Pulmonary & Critical Care Sarcoidosis

https://t.me/USMLEWorldStep1
Show all

The disease may also be incidentally detected in asymptomatic patients with typical chest x-ray findings (eg,

bilate

(Choi
and pr
bronch

(Choi
rhinos
eosinc

(Choi
pulmo
onset
macro
materi

(Choi
weight

(Choi
organs
demor

(Choi
Histop
pattern

Educa
Sarcoi
chest

Exhibit Display

Idiopathic pulmonary fibrosis

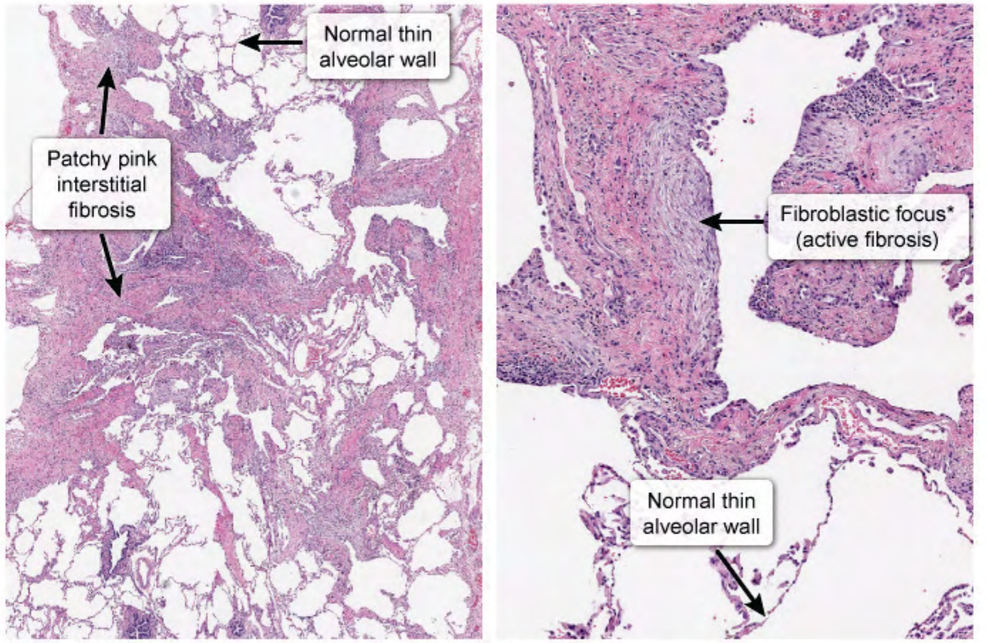

*Proliferation of fibroblasts and myofibroblasts with pale gray stroma

©UWorld

Zoom In | Zoom Out | Reset | New | Existing | My Notebook

https://t.me/USMLEWorldStep1
Show all

The disease may also be incidentally detected in asymptomatic patients with typical chest x-ray findings (eg,

bilate

(Choi
and pr
bronch

(Choi
rhinos
eosinc

(Choi
pulmo
onset
macro
materi

(Choi
weight

(Choi
organs
demor

(Choi
Histop
patterr

Educa
Sarcoi

chest pain) accompanied by fatigue, fever, and weight loss. The characteristic histopathologic feature is

Exhibit Display

Hodgkin lymphoma

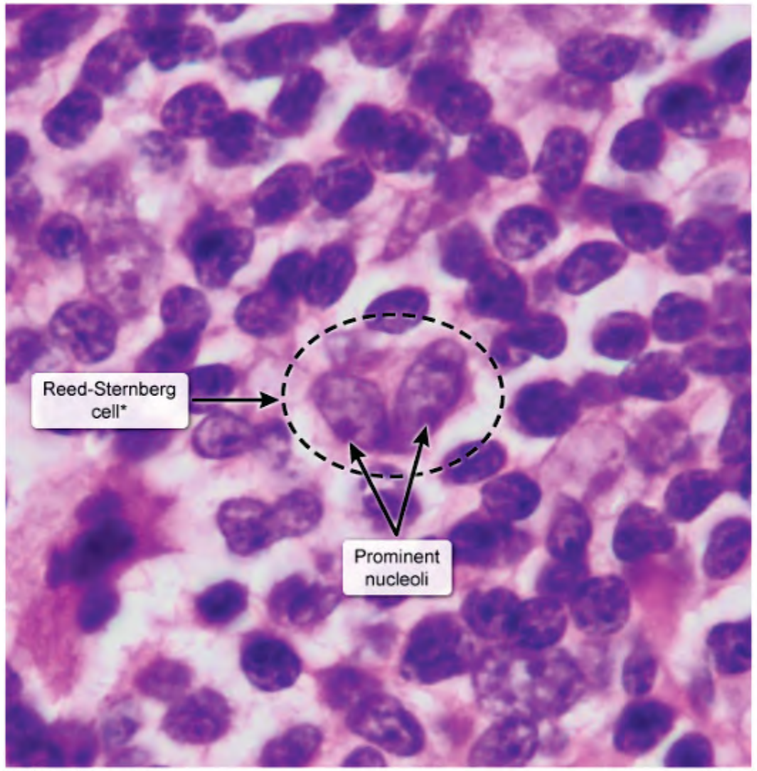

*"Owl's eye" appearance.

©UWorld

Zoom In | Zoom Out | Reset | New | Existing | My Notebook

https://t.me/USMLEWorldStep1
Show all

The disease may also be incidentally detected in asymptomatic patients with typical chest x-ray findings (eg,

bilate

(Choi
and pr
bronch

(Choi
rhinos
eosinc

(Choi
pulmo
onset
macro
materi

(Choi
weight

(Choi
organs
demor

(Choi
Histop
pattern

Educa
Sarcoi

chest pain) accompanied by fatigue, fever, and weight loss. The characteristic histopathologic feature is

Exhibit Display

Small cell carcinoma

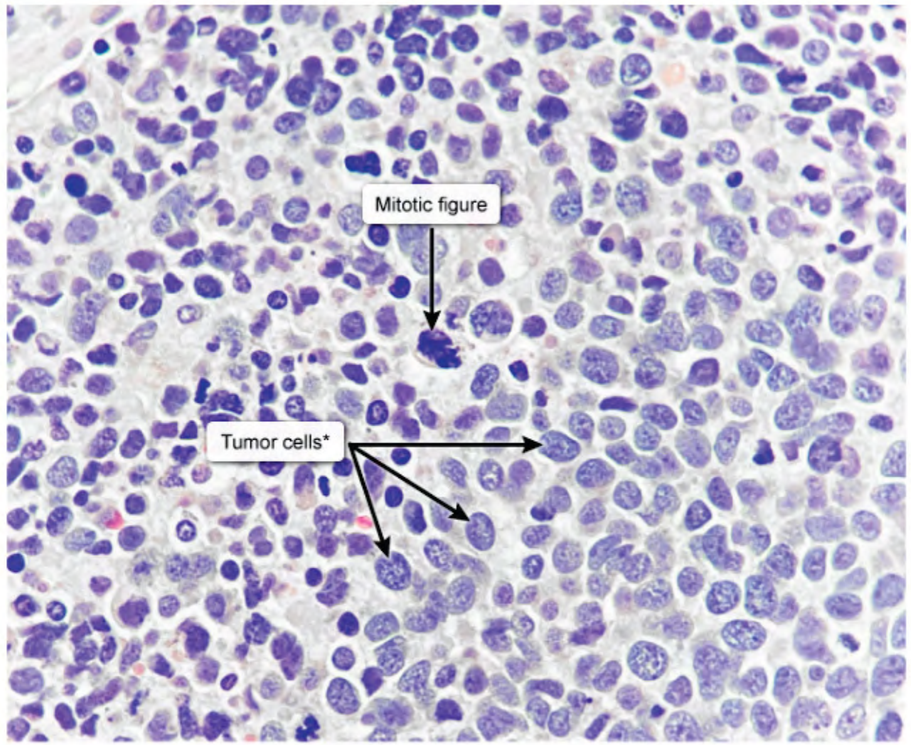

*Cells with granular chromatin, indistinct nucleoli, and scant cytoplasm

©UWorld

Zoom In Zoom Out Reset New | Existing My Notebook

https://t.me/USMLEWorldStep1

A 30-year-old previously healthy man experiences worsening dyspnea and hypoxia. During evaluation, he undergoes direct pulmonary angiography. Intravenous contrast dye is injected into one of his segmental pulmonary arteries under fluoroscopy, with the results shown below:

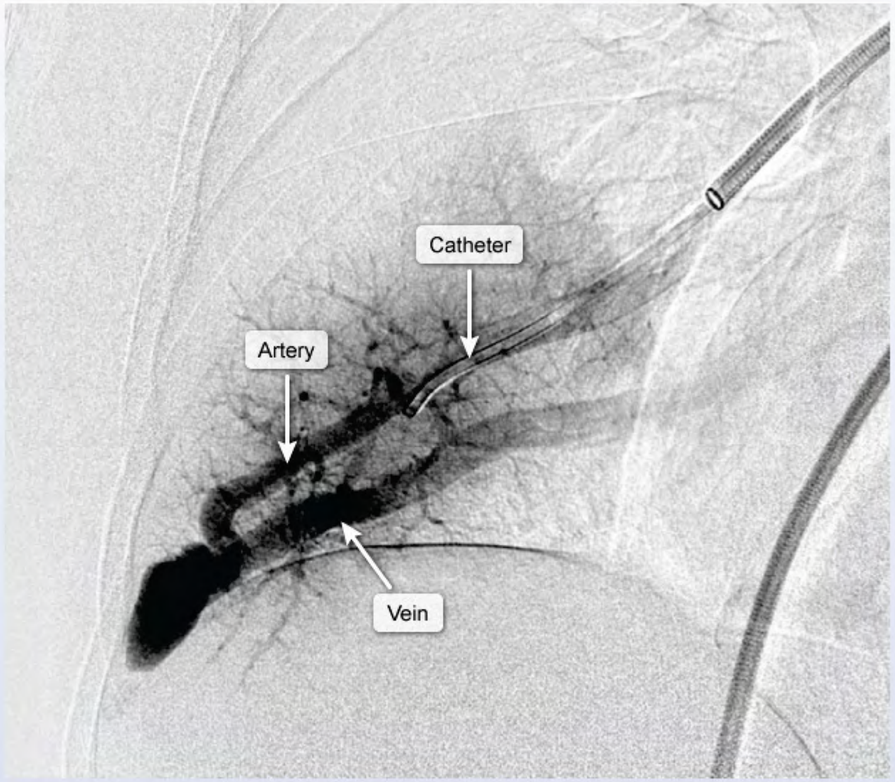

Which of the following is the most likely cause of this patient's hypoxia?

- A. Alveolar diffusion impairment
- B. Decreased alveolar ventilation

https://t.me/USMLEWorldStep1
Show all

A 30-year-old previously healthy man experiences worsening dyspnea and hypoxia. During evaluation, he
underg
pulmo

Exhibit Display

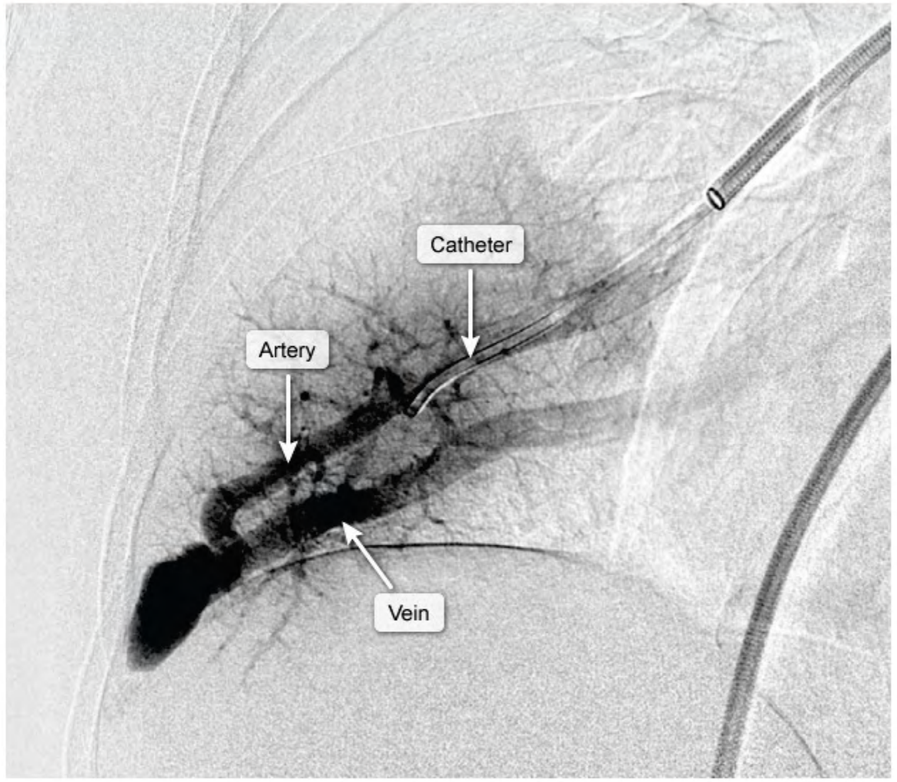

Zoom In | Zoom Out | Reset | New | Existing | My Notebook

Which

B. Decreased alveolar ventilation

https://t.me/USMLEWorldStep1

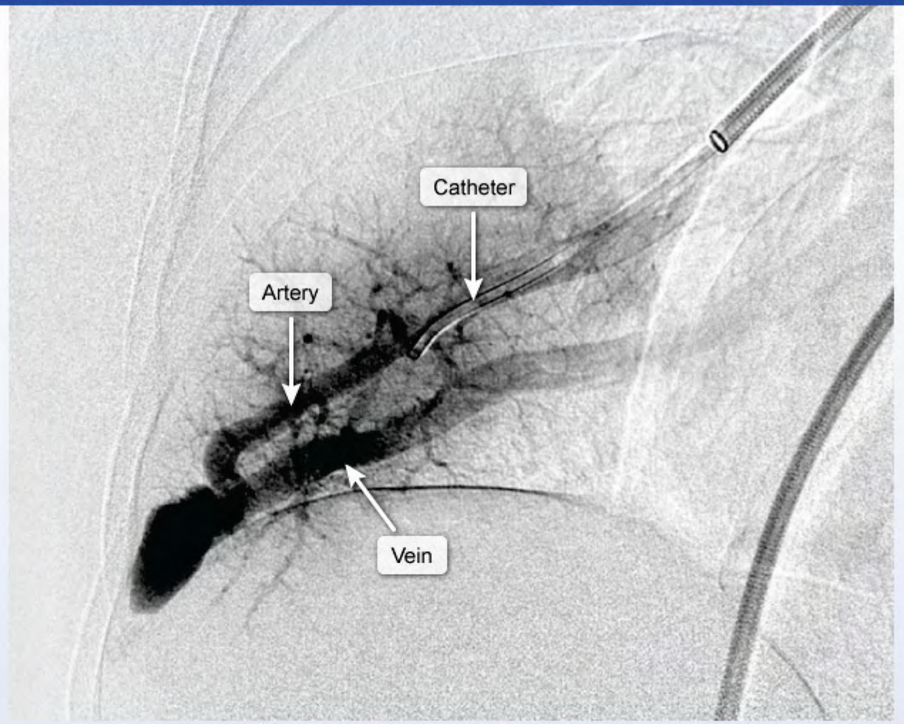

Which of the following is the most likely cause of this patient's hypoxia?

- A. Alveolar diffusion impairment
- B. Decreased alveolar ventilation
- C. Increased pulmonary vascular resistance
- D. Increased right-to-left shunting

Submit

https://t.me/USMLEWorldStep1
Show all

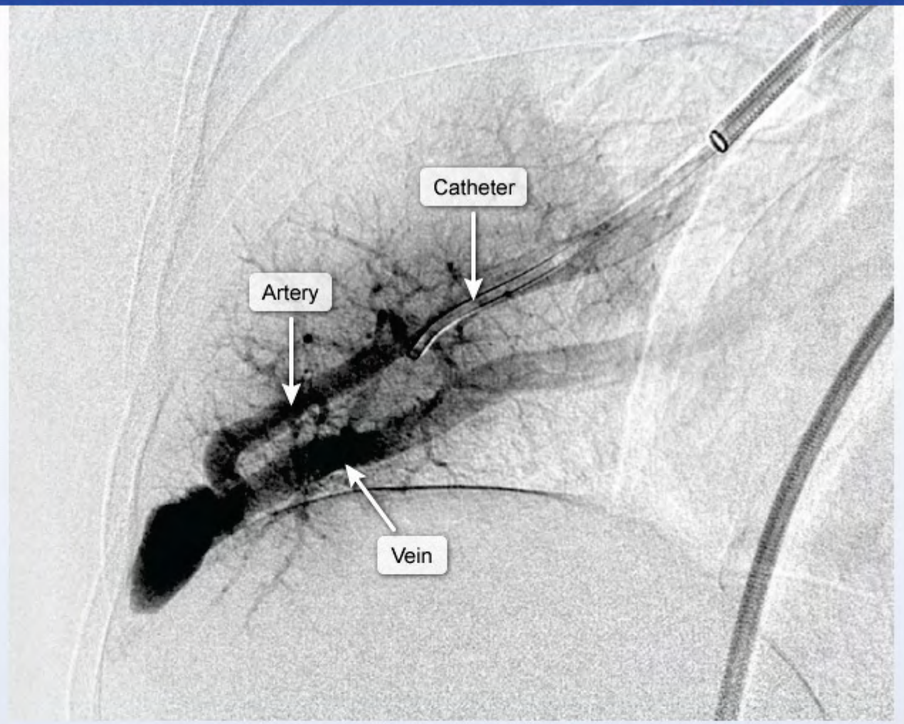

Which of the following is the most likely cause of this patient's hypoxia?

- A. Alveolar diffusion impairment (18%)
- ✕ B. Decreased alveolar ventilation (9%)
- C. Increased pulmonary vascular resistance (31%)
- ✓ D. Increased right-to-left shunting (39%)

Incorrect
Correct answer
D

39%
Answered correctly

14 secs
Time Spent

2023
Version

https://t.me/USMLEWorldStep1
Show all

B. Decreased alveolar ventilation (9%)

Exhibit Display

Pulmonary AVM

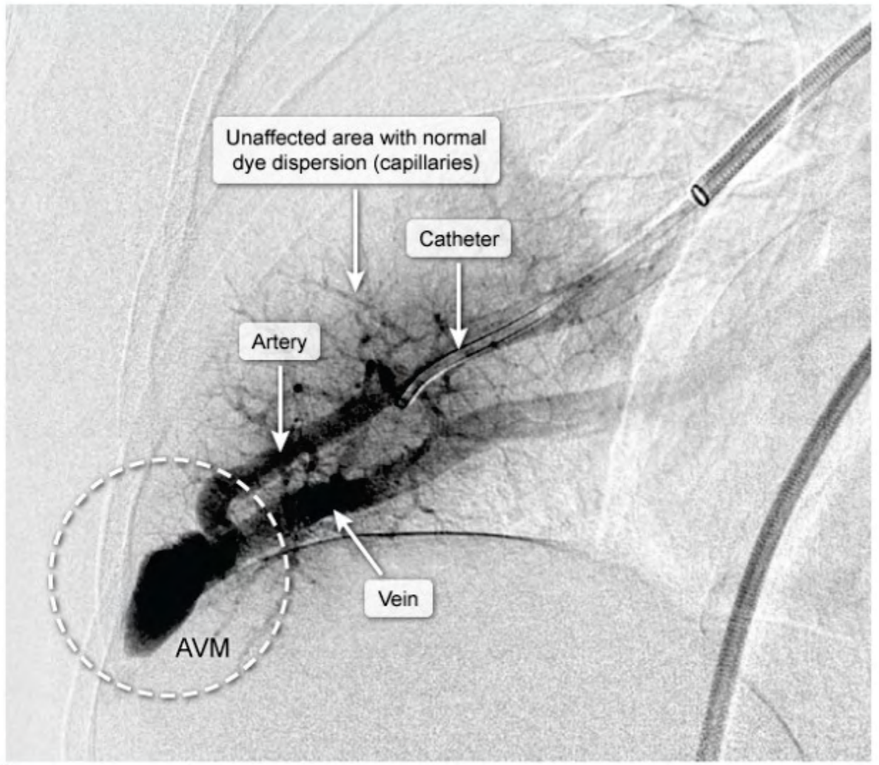

©UWorld

Zoom In | Zoom Out | Reset | New | Existing | My Notebook

Vein

https://t.me/USMLEWorldStep1

©UWorld

Direct pulmonary angiography visualizes the pulmonary vasculature in real time via fluoroscopy. The procedure involves injection of radiocontrast directly into a pulmonary artery segment with continuous x-ray imaging. Normally, the **dye dissipates** as blood is dispersed throughout the capillaries, so the **venous drainage is not seen**.

During this patient's procedure, the dye enters a **saccular structure** and immediately fills the pulmonary vein. This indicates a direct artery-to-vein anastomosis with no interposed capillary bed, a finding consistent with a large **arteriovenous malformation** (AVM).

Large pulmonary AVMs may induce significant hypoxemia, with the mechanism being a true anatomic **right-to-left shunt**. Deoxygenated blood is directly arterialized without participating in gas exchange. For this reason, hypoxemia due to true shunt is **poorly responsive to oxygen** supplementation.

(Choice A) Alveolar diffusion impairment most often occurs when the surface area for gas exchange is destroyed (eg, severe emphysema) or the basement membrane is thickened (eg, interstitial lung disease). Large AVMs (ie, detectable on angiography) cause hypoxemia primarily due to anatomic right-to-left shunting.

(Choice B) Alveolar hypoventilation (ie, insufficient ventilation leading to hypercapnia) occurs when minute ventilation is compromised by central (eg, opioids, brainstem lesions) or peripheral (eg, neuromuscular disease) causes.

(Choice C) Increased pulmonary vascular resistance occurs in pulmonary arterial hypertension and pulmonary embolism. Conversely, pulmonary AVMs *decrease* pulmonary vascular resistance.

Educational objective:
Pulmonary arteriovenous malformations cause hypoxemia through right-to-left shunting that is refractory to supplemental oxygenation. The shunt can be visualized during pulmonary angiography, which demonstrates direct communication between the inflow artery and outflow vein.

Pathophysiology Pulmonary & Critical Care Av malformation

https://t.me/USMLEWorldStep1
Show all

©UWorld

Direct pulmonary angiography visualizes the pulmonary vasculature in real time via fluoroscopy. The procedure involve
Norma
seen.

During
This in
arteri

Large
shunt
hypox

(Choi
(eg, se
detect

(Choi
ventila
cause

(Choi
embol

Educa
Pulmo
supple
comm

Pathoph

Exhibit Display

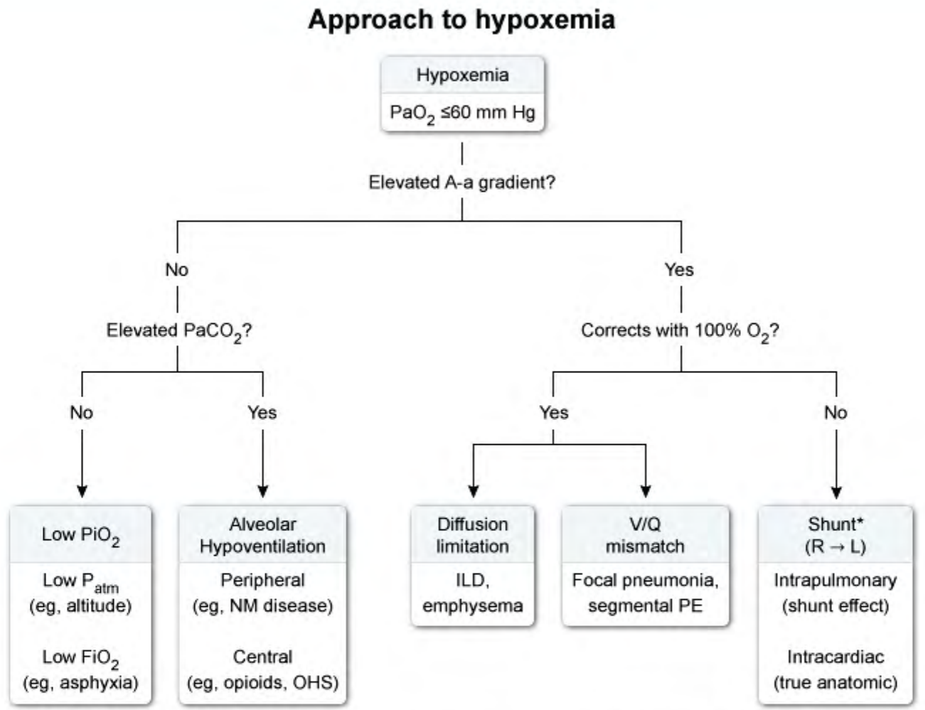

***Effect of positive end-expiratory pressure:** ↓ intrapulmonary shunt effect (eg, diffuse pulmonary edema)
↑ intracardiac shunt (eg, atrial or ventricular septal defect)

A-a = alveolar-arterial; **ILD** = interstitial lung disease; **NM** = neuromuscular; **OHS** = obesity hypoventilation syndrome; P_{atm} = atmospheric pressure; **PE** = pulmonary embolism; **(R → L)** = right to left; **V/Q** = ventilation-perfusion.

©UWorld

Zoom In | Zoom Out | Reset | New | Existing | My Notebook

https://t.me/USMLEWorldStep1

A 63-year-old man is admitted to the hospital after suffering a cerebral infarction. A swallow study performed during the acute recovery period shows oropharyngeal dysphagia. Despite being maintained on the appropriate dietary restrictions, the patient experiences an episode of vomiting while lying on his back and subsequently develops pneumonia. Which of the following lung regions is most likely to be affected?

- A. Anterior segment of the left upper lobe
- B. Basilar segments of the right lower lobe
- C. Lingular segments of the left lung
- D. Middle lobe segments of the right lung
- E. Posterior segment of the right upper lobe

Submit

https://t.me/USMLEWorldStep1

A 63-year-old man is admitted to the hospital after suffering a cerebral infarction. A swallow study performed during the acute recovery period shows oropharyngeal dysphagia. Despite being maintained on the appropriate dietary restrictions, the patient experiences an episode of vomiting while lying on his back and subsequently develops pneumonia. Which of the following lung regions is most likely to be affected?

- A. Anterior segment of the left upper lobe (0%)
- ✕ B. Basilar segments of the right lower lobe (19%)
- C. Lingular segments of the left lung (0%)
- D. Middle lobe segments of the right lung (18%)
- ✓ E. Posterior segment of the right upper lobe (60%)

Incorrect
Correct answer
E

60%
Answered correctly

13 secs
Time Spent

2023
Version

Explanation

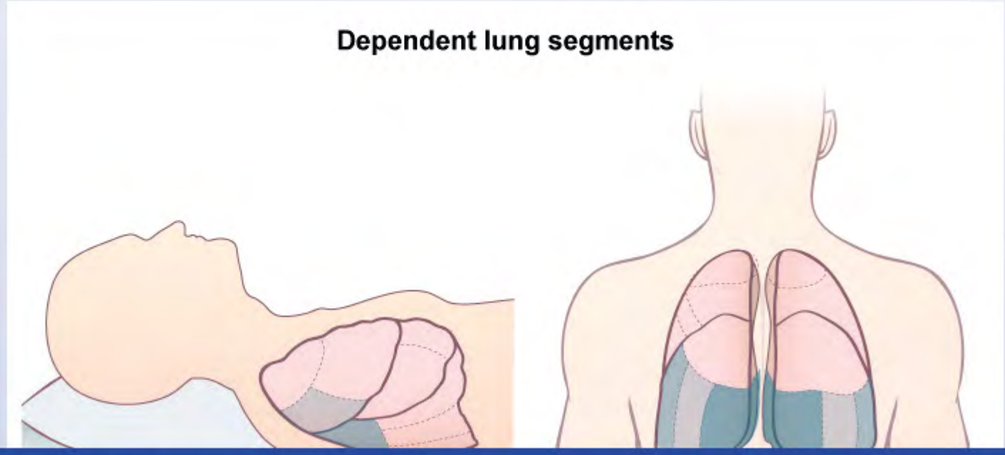

https://t.me/USMLEWorldStep1

A 63-year-old man is admitted to the hospital after suffering a cerebral infarction. A swallow study performed during
dietary
develc

Exhibit Display

Dependent lung segments

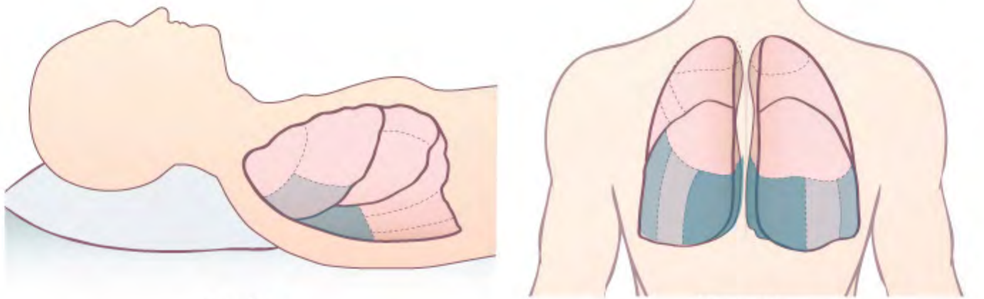

Supine
Posterior segments of upper lobes & superior segments of lower lobes most dependent

Upright
Basilar segments most dependent

©UWorld

Zoom In | Zoom Out | Reset | New | Existing | My Notebook

Inco
Corre
E

Expl

https://t.me/USMLEWorldStep1

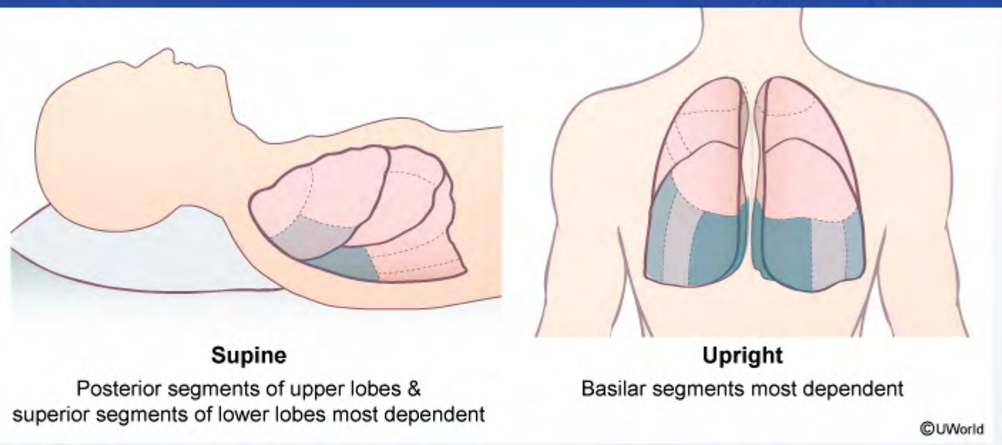

Supine
Posterior segments of upper lobes & superior segments of lower lobes most dependent

Upright
Basilar segments most dependent

©UWorld

Due to gravity, **aspiration pneumonia** typically develops in the most **dependent** portions of the lung. Patients who aspirate while **lying supine** typically have involvement of the **posterior segments of the upper lobes** and the **superior segments of the lower lobes**.

The **right lung** is more prone to aspiration than the left lung as the right main bronchus has a larger diameter, is shorter, and is more vertically oriented than the left main bronchus (mnemonic: "Inhale a bite, goes down the right").

(Choice B) Aspiration in an upright position tends to involve the basilar segments of the lower lobes.

(Choices C and D) Recumbent patients in the *prone position* (ie, lying on the abdomen) are more likely to aspirate into the middle lobe and lingula, as these are the most dependent portions of the lung in this position.

Educational objective:
Due to gravity, supine patients typically aspirate into the posterior segments of the upper lobes and superior segments of the lower lobes. Patients who are upright tend to aspirate into the basilar segments of the lower lobes. Aspirated material is more likely to travel down the right main bronchus.

Anatomy	Pulmonary & Critical Care	Aspiration pneumonia
Subject	System	Topic

Copyright © UWorld. All rights reserved.

https://t.me/USMLEWorldStep1

Physiologists conduct a study to identify the protein constituents present in normal pulmonary secretions. They recruit 20 healthy men and women who do not take any medications and have no history of tobacco use. Bronchoalveolar lavage is performed, and the proteins in the fluids are isolated. A specific protein is identified that can degrade elastin present in the extracellular matrix. Which of the following cells are most likely responsible for producing the protein found in this study?

- A. Alveolar macrophages
- B. Ciliated epithelium
- C. Club cells
- D. Goblet cells
- E. Type I pneumocytes
- F. Type II pneumocytes

Submit

https://t.me/USMLEWorldStep1

Physiologists conduct a study to identify the protein constituents present in normal pulmonary secretions. They recruit 20 healthy men and women who do not take any medications and have no history of tobacco use. Bronchoalveolar lavage is performed, and the proteins in the fluids are isolated. A specific protein is identified that can degrade elastin present in the extracellular matrix. Which of the following cells are most likely responsible for producing the protein found in this study?

- ✓ A. Alveolar macrophages (64%)
- ✗ B. Ciliated epithelium (1%)
- C. Club cells (10%)
- D. Goblet cells (3%)
- E. Type I pneumocytes (5%)
- F. Type II pneumocytes (15%)

Incorrect
Correct answer
A

64%
Answered correctly

06 secs
Time Spent

2023
Version

Explanation

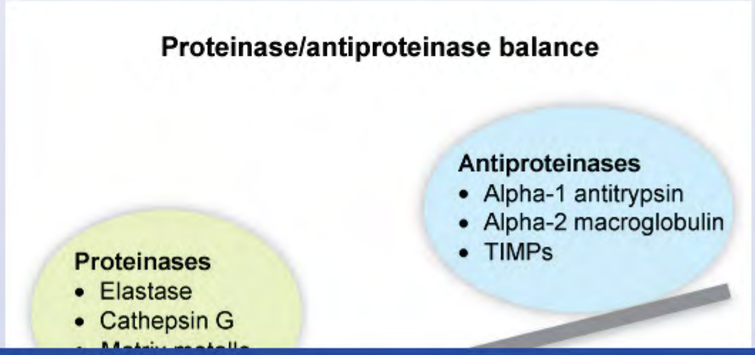

https://t.me/USMLEWorldStep1

Physiologists conduct a study to identify the protein constituents present in normal pulmonary secretions. They recruit
Bronch
can de
produc

Exhibit Display

Proteinase/antiproteinase balance

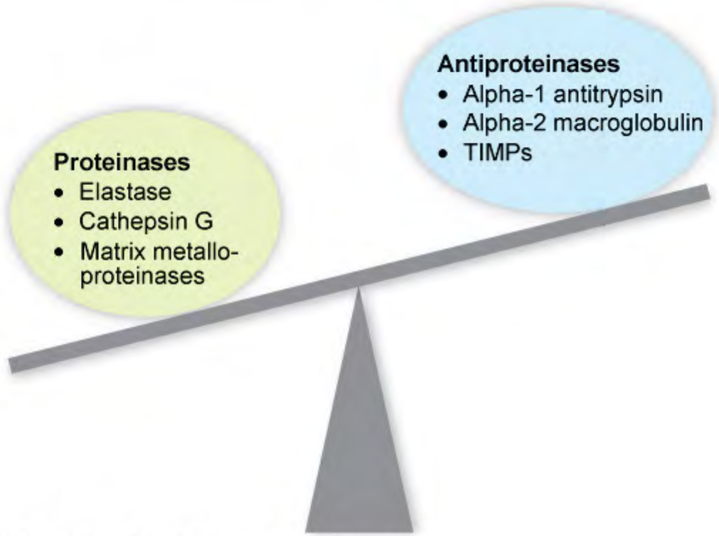

TIMPs = tissue inhibitors of metalloproteinase.
©UWorld

Zoom In | Zoom Out | Reset | New | Existing | My Notebook

Inco
Corre
A

Expl

• Alpha-2 macroglobulin
• TIMPs
Proteinases
• Elastase
• Cathepsin G

https://t.me/USMLEWorldStep1

Elastase is a neutral protease contained in **macrophage** lysosomes and in the azurophilic (primary) granules of **neutrophils**. Normally, elastase released from alveolar macrophages and infiltrating neutrophils is balanced by the presence of serum and tissue protease inhibitors. Neutrophil elastase is inhibited by serum alpha-1 antitrypsin, and macrophage elastase is inhibited by tissue inhibitors of metalloproteinases. Neutrophil and macrophage elastases can also degrade each other's inhibitors, augmenting their destructive capacity when both proteases are present.

Excess protease activity is a major contributor to the development of both centriacinar and panacinar **emphysema**.

(Choice B) The ciliated epithelium of the lower respiratory tract sweeps foreign particles and mucus toward the pharynx to promote mucociliary clearance.

(Choice C) Club cells are nonciliated cells found predominantly in the terminal portions of the bronchioles. They secrete club cell secretory protein (which protects against airway inflammation and oxidative stress) and surfactant components (which prevent bronchiolar collapse).

(Choice D) Goblet cells secrete mucin to help with mucociliary clearance. They are present in the epithelial lining of the trachea and bronchi but are not present in the more distal airways (ie, terminal bronchioles, respiratory bronchioles, alveoli).

(Choice E) Type I pneumocytes constitute over 95% of the surface area of the alveoli. These end-differentiated squamous cells are not a major source of alveolar fluid secretory products.

(Choice F) Type II pneumocytes secrete the major components of pulmonary surfactant, including phospholipids such as dipalmitoyl phosphatidylcholine and surfactant-associated proteins.

Educational objective:
Alveolar fluid contains proteases (eg, elastases) that are derived from alveolar macrophages and infiltrating neutrophils. These proteases can cause destruction of terminal lung parenchyma (eg, emphysema) when secreted in excess (or if left unchecked by deficient antiprotease activity).

Pathology	Pulmonary & Critical Care	Alpha1 antitrypsin deficiency
Subject	System	Topic

https://t.me/USMLEWorldStep1

Elastase is a neutral protease contained in **macrophage** lysosomes and in the azurophilic (primary) granules of **neutr**
the pr
and m
elastas
preser

Exces
emphy

(Choi
pharyn

(Choi
secret
compo

(Choi
of the
bronch

(Choi
squam

(Choi
such a

Educa
Alveol
neutro
in excess (or if left unchecked by deficient antiprotease activity).

Exhibit Display

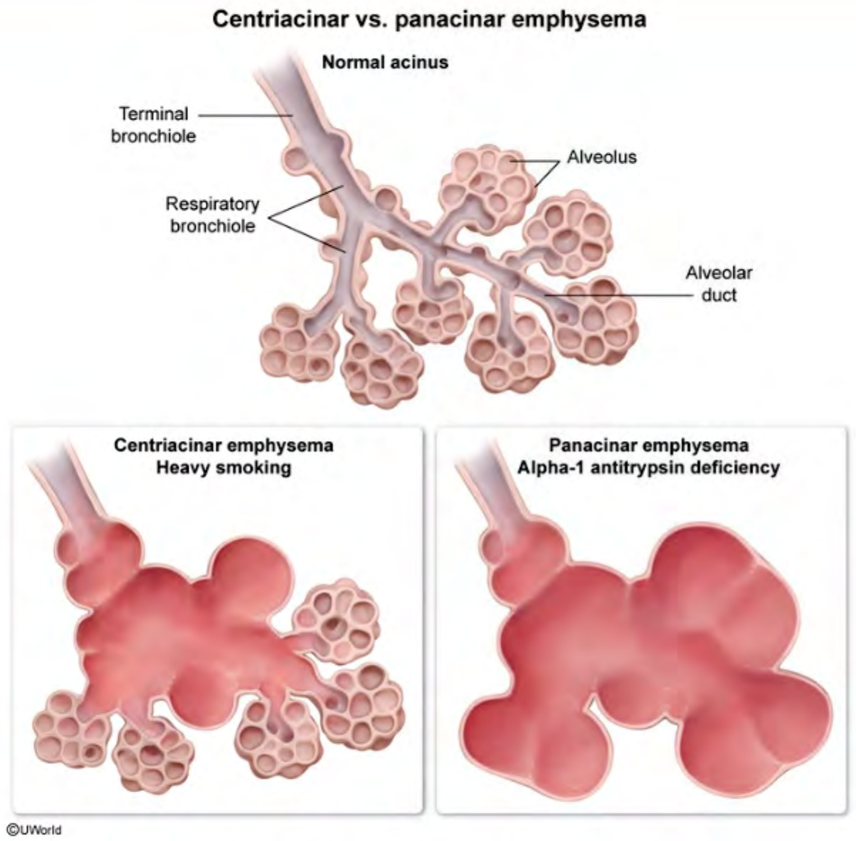

Zoom In Zoom Out Reset New | Existing My Notebook

Pathology (Subject) Pulmonary & Critical Care (System) Alpha1 antitrypsin deficiency (Topic)

https://t.me/USMLEWorldStep1

Elastase is a neutral protease contained in **macrophage** lysosomes and in the azurophilic (primary) granules of **neutr**

the pr
and m
elasta
preser

Exces
emphy

(Choi
pharyn

(Choi
secret
compo

(Choi
of the
bronch

(Choi
squam

(Choi
such a

Educa
Alveol
neutro
in exc

Exhibit Display

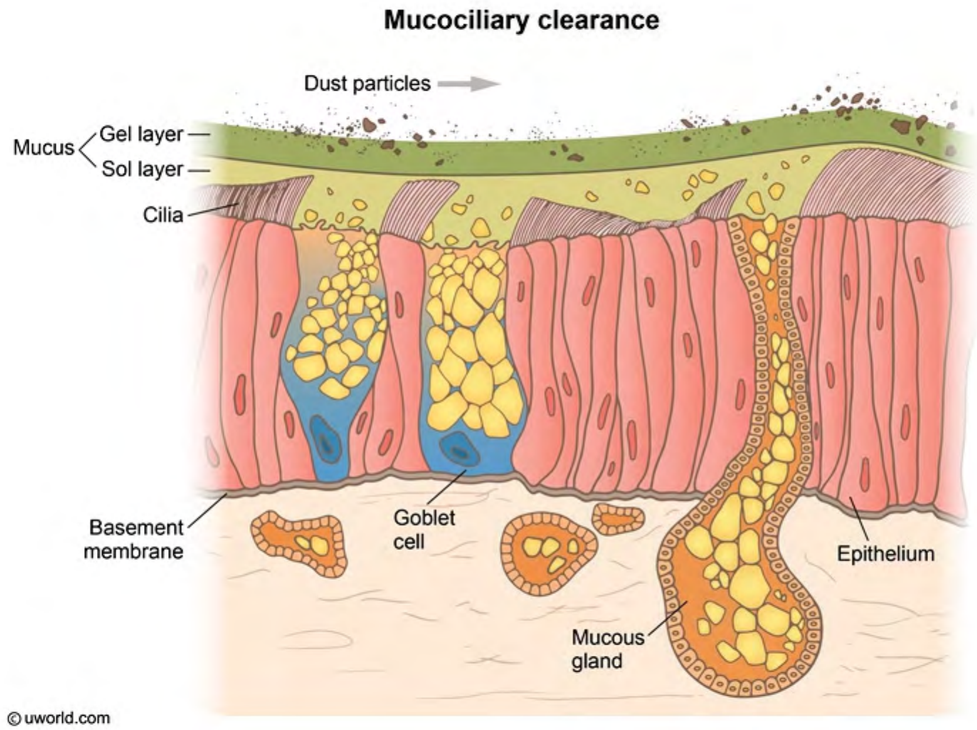

Zoom In | Zoom Out | Reset | New | Existing | My Notebook

Pathology (Subject) | Pulmonary & Critical Care (System) | Alpha1 antitrypsin deficiency (Topic)

https://t.me/USMLEWorldStep1

Elastase is a neutral protease contained in **macrophage** lysosomes and in the azurophilic (primary) granules of **neutr**

the pr
and m
elasta
preser

Exces
emphy

(Choi
pharyn

(Choi
secret
compo

(Choi
of the
bronch

(Choi
squam

(Choi
such a

Educa
Alveol
neutro
in exc

Exhibit Display

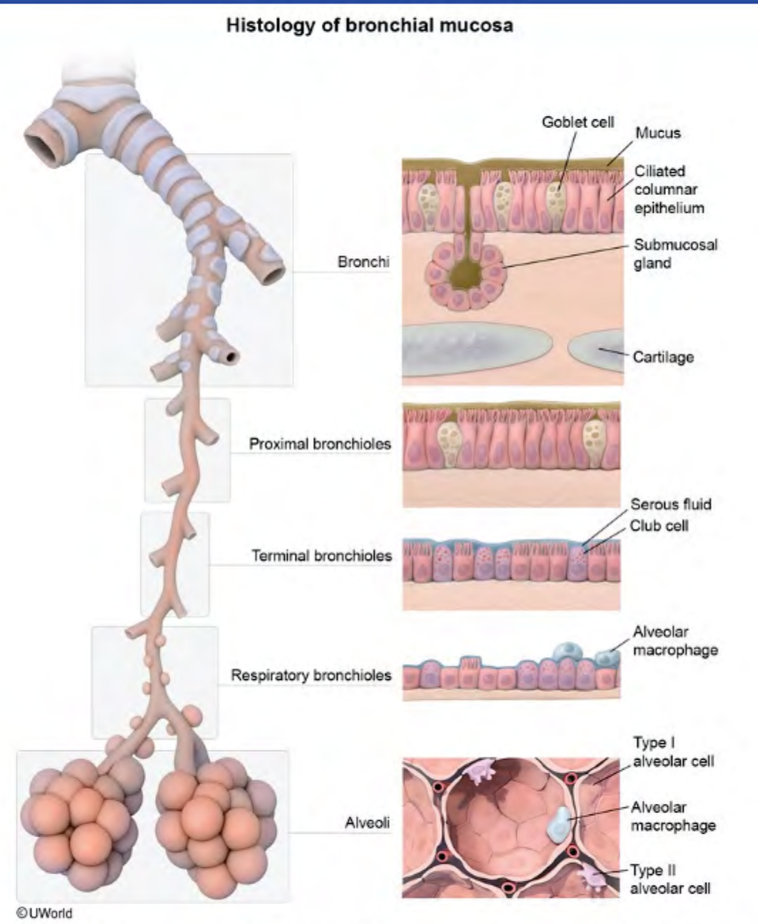

Zoom In | Zoom Out | Reset | New | Existing | My Notebook

Pathology (Subject) | Pulmonary & Critical Care (System) | Alpha1 antitrypsin deficiency (Topic)

https://t.me/USMLEWorldStep1

Elastase is a neutral protease contained in **macrophage** lysosomes and in the azurophilic (primary) granules of **neutr**
the pr
and m
elasta
preser

Exces
emphy

(Choi
pharyn

(Choi
secret
compo

(Choi
of the
bronch

(Choi
squam

(Choi
such a

Educa
Alveol
neutro
in excess (or if left unchecked by deficient antiprotease activity).

Exhibit Display

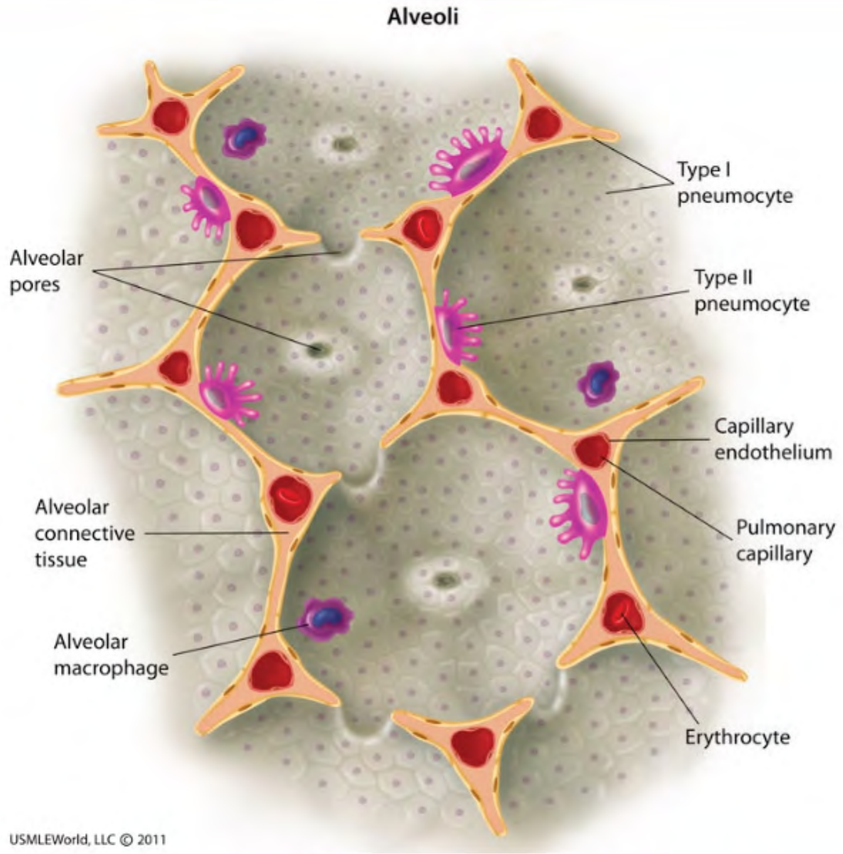

Zoom In | Zoom Out | Reset | New | Existing | My Notebook

Pathology (Subject) | Pulmonary & Critical Care (System) | Alpha1 antitrypsin deficiency (Topic)

https://t.me/USMLEWorldStep1

A 70-year-old woman has been enrolled in a longitudinal research study on aging for the last 30 years. Medical history is significant for osteoporosis; she has developed moderate kyphosis due to gradual loss of vertebral body height. She is otherwise active and healthy with no additional medical issues. She has never smoked. Compared to her physiology testing done years ago, which of the following changes is most consistent with normal aging?

	Lung compliance	Total respiratory system compliance	Physiologic dead space	
A.	↑	↑	↑	(13%)
✗ B.	↑	Unchanged	↓	(6%)
✓ C.	↑	↓	↑	(40%)
D.	↓	↑	↑	(3%)
E.	↓	Unchanged	↓	(4%)
F.	↓	↓	↑	(31%)

Incorrect
Correct answer
C

40%
Answered correctly

09 secs
Time Spent

2023
Version

Explanation

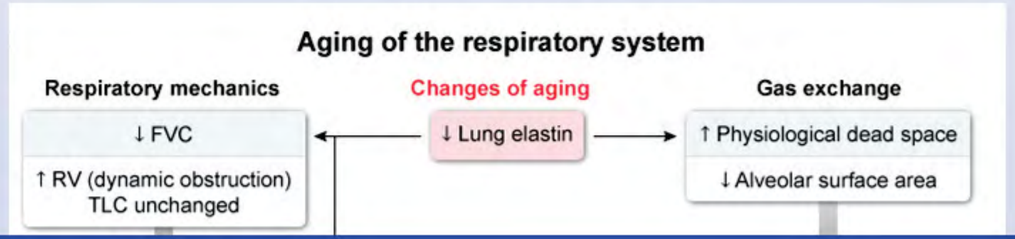

https://t.me/USMLEWorldStep1

Explanation

Exhibit Display

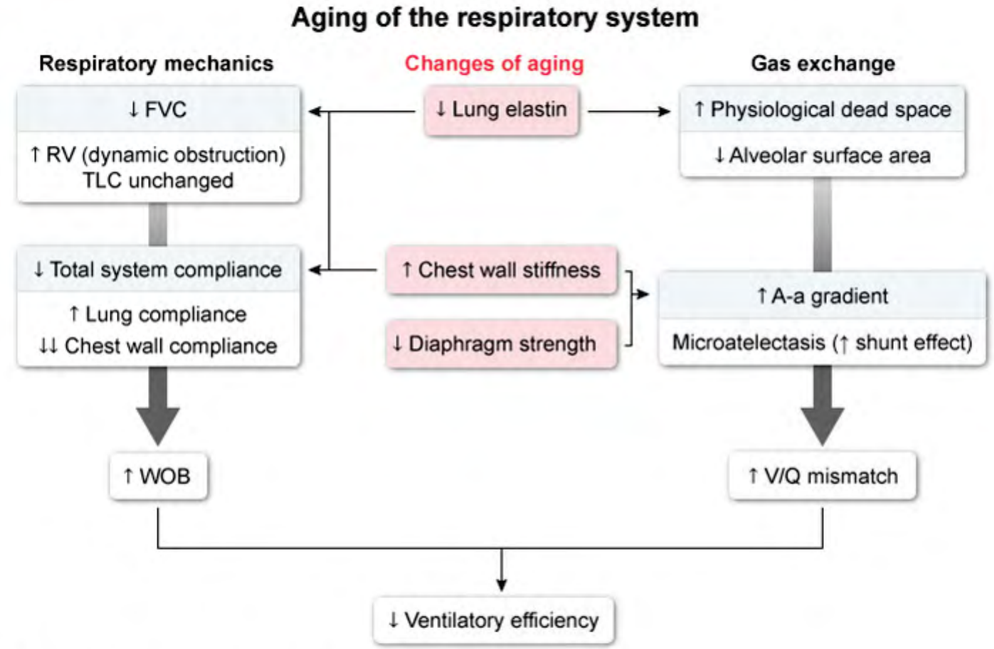

Zoom In | Zoom Out | Reset | New | Existing | My Notebook

The hu
are co

- L
  m
  p
- C
  sternocostal and costovertebral joints and kyphosis of the thoracic spine.

https://t.me/USMLEWorldStep1

A-a = arterial-alveolar; **FVC** = forced vital capacity; **RV** = residual volume; **TLC** = total lung capacity; **V/Q** = ventilation-perfusion; **WOB** = work of breathing.

©UWorld

The human respiratory system undergoes significant changes during **normal aging**. The mechanics of breathing are compromised due to alteration of lung, chest wall, and total respiratory system compliance:

- **Lung compliance increases** ("loose, baggy lungs") due to loss of elastin content. This process resembles mild emphysema and leads to dynamic expiratory airflow obstruction, premature airway closure, and progressive hyperinflation.
- Chest wall compliance decreases ("stiff rib cage") due to degenerative changes (ossification, arthritis) of the sternocostal and costovertebral joints and kyphosis of the thoracic spine.
- Total respiratory system compliance, the combination of lung parenchymal and chest wall compliance, is **decreased** because the **stiffness** of the chest wall **dominates** over the increased laxity of the lung.

As these mechanical changes occur, there is also a marked **increase in dead space ventilation**. Although anatomic dead space (nasopharynx to terminal bronchioles) remains constant after early adulthood when the bronchial tree reaches full maturity, alveolar dead space increases with age due to progressive elastin degeneration, alveolar simplification, and capillary dropout.

The net result is a mechanically disadvantaged respiratory system (lower compliance) that must contend with increased dead space. A **greater work of breathing** is required to maintain the same alveolar minute ventilation and the efficiency of breathing (ventilation per unit of work) steadily declines.

Educational objective:
Normal aging is characterized by decreased respiratory system compliance (increased lung compliance outweighed by higher chest wall stiffness) and increased dead space (loss of alveolar surface area). For this reason, elderly persons are less equipped to tolerate illnesses that impair respiratory compliance and/or gas exchange (eg, pneumonia, pulmonary edema).

Physiology	Pulmonary & Critical Care	Aging
Subject	System	Topic

Copyright © UWorld. All rights reserved.

https://t.me/USMLEWorldStep1

A-a = arterial-alveolar; **FVC** = forced vital capacity; **RV** = residual volume; **TLC** = total lung capacity; **V/Q** = ventilation-perfusion; **WOB** = work of breathing.

©UWorld

The hu
are co

- **L**
  m
  p
- C
  st
- T
  d

As the
anator
bronch
degen

The ne
increa
and th

Educa
Norma
outwei
reason
excha

Exhibit Display

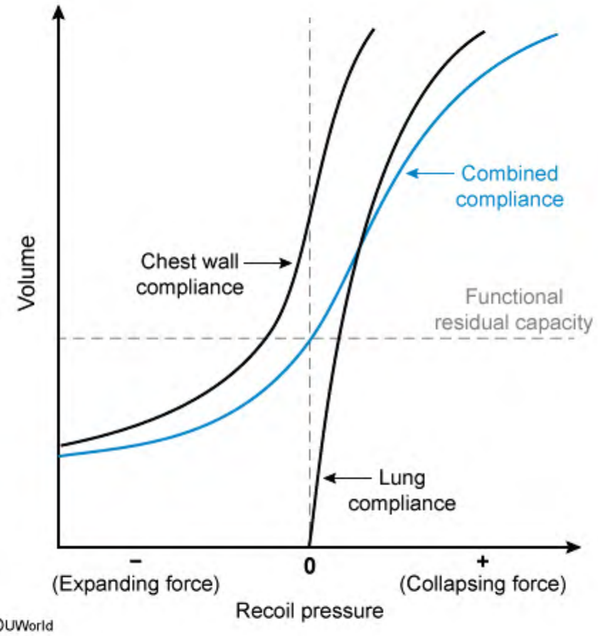

Zoom In Zoom Out Reset New | Existing My Notebook

Physiology
Subject

Pulmonary & Critical Care
System

Aging
Topic

Copyright © UWorld. All rights reserved.

https://t.me/USMLEWorldStep1

A-a = arterial-alveolar; **FVC** = forced vital capacity; **RV** = residual volume; **TLC** = total lung capacity; **V/Q** = ventilation-perfusion; **WOB** = work of breathing.

©UWorld

The hu
are co

- **L**
  m
  p
- C
  st
- T
  d

As the
anator
bronch
degen

The ne
increa
and th

Educa
Norma
outwei
reason
excha

Exhibit Display

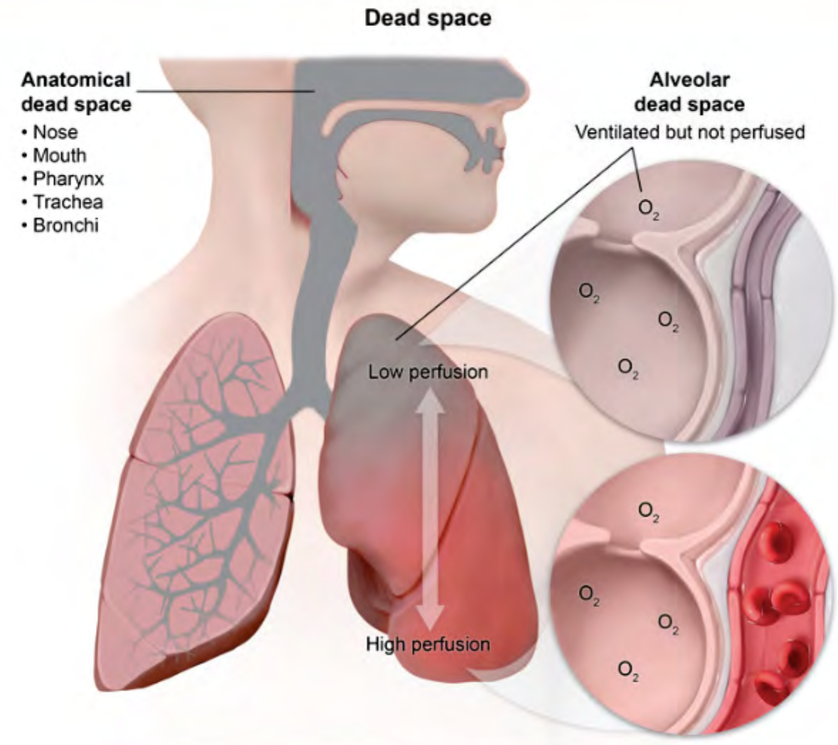

Zoom In | Zoom Out | Reset | New | Existing | My Notebook

Physiology
Subject

Pulmonary & Critical Care
System

Aging
Topic

Copyright © UWorld. All rights reserved.

https://t.me/USMLEWorldStep1

A 35-year-old man comes to the clinic for evaluation of exertional dyspnea and dry cough for 8 months. Oxygen saturation on room air while lying down is 96% and drops to 88% after 6 minutes of walking. Examination shows fine crackles in both lower lungs. Chest x-ray reveals reticular densities in both lung fields. Lung biopsy shows an infiltration of inflammatory cells, predominantly lymphocytes, as well as poorly formed noncaseating granulomas and moderate alveolar septal fibrosis. Which of the following is the most likely diagnosis?

- A. Bronchial asthma
- B. Chronic bronchitis
- C. Hypersensitivity pneumonitis
- D. Idiopathic pulmonary fibrosis
- E. Pulmonary tuberculosis

Submit

https://t.me/USMLEWorldStep1

A 35-year-old man comes to the clinic for evaluation of exertional dyspnea and dry cough for 8 months. Oxygen saturation on room air while lying down is 96% and drops to 88% after 6 minutes of walking. Examination shows fine crackles in both lower lungs. Chest x-ray reveals reticular densities in both lung fields. Lung biopsy shows an infiltration of inflammatory cells, predominantly lymphocytes, as well as poorly formed noncaseating granulomas and moderate alveolar septal fibrosis. Which of the following is the most likely diagnosis?

- A. Bronchial asthma (0%)
- ✗ B. Chronic bronchitis (2%)
- ✓ C. Hypersensitivity pneumonitis (50%)
- D. Idiopathic pulmonary fibrosis (41%)
- E. Pulmonary tuberculosis (4%)

Incorrect
Correct answer
C

50%
Answered correctly

06 secs
Time Spent

2023
Version

Explanation

Hypersensitivity pneumonitis	
Etiology	• Immunologic response to inhaled antigen (eg, mold, animal protein)
Clinical presentation	**Acute** • Abrupt-onset fever, chills, cough, dyspnea, fatigue, leukocytosis • Episodes often recurrent & self-resolving **Chronic** • Progressive cough, dyspnea, fatigue, weight loss

https://t.me/USMLEWorldStep1

Hypersensitivity pneumonitis	
Etiology	• Immunologic response to inhaled antigen (eg, mold, animal protein)
Clinical presentation	**Acute** • Abrupt-onset fever, chills, cough, dyspnea, fatigue, leukocytosis • Episodes often recurrent & self-resolving **Chronic** • Progressive cough, dyspnea, fatigue, weight loss • Hypoxemia that worsens with exertion • Chest x-ray: diffuse reticular interstitial opacities (interstitial fibrosis)
Diagnosis	• PFT: restrictive pattern • BAL: high relative lymphocyte count • Lung biopsy: lymphocytic infiltrate, poorly formed noncaseating granulomas, interstitial fibrosis (chronic only)
Treatment	• Remove antigen exposure (resolves acute disease)
BAL = bronchoalveolar lavage; **PFT** = pulmonary function testing.	

This patient with chronic **dyspnea and cough** accompanied by characteristic lung biopsy findings most likely has **hypersensitivity pneumonitis** (HP). HP is an exaggerated immunologic response to an inhaled antigen; common offending agents include mold, bacteria, animal protein, and chemicals. The condition has variable presentation that is largely dependent on the dose and chronicity of antigen exposure:

- **Acute HP** involves abrupt-onset and often recurring episodes of fever, chills, cough, dyspnea, and fatigue that coincide with intermittent high-dose antigen exposure. Leukocytosis is often present. Chest x-ray may be normal or show scattered micronodular opacification.
- **Chronic HP** involves persistent and **gradually progressive symptoms** (as in this patient) resulting from

https://t.me/USMLEWorldStep1

This patient with chronic **dyspnea and cough** accompanied by characteristic lung biopsy findings most likely has **hypersensitivity pneumonitis** (HP). HP is an exaggerated immunologic response to an inhaled antigen; common offending agents include mold, bacteria, animal protein, and chemicals. The condition has variable presentation that is largely dependent on the dose and chronicity of antigen exposure:

- **Acute HP** involves abrupt-onset and often recurring episodes of fever, chills, cough, dyspnea, and fatigue that coincide with intermittent high-dose antigen exposure. Leukocytosis is often present. Chest x-ray may be normal or show scattered micronodular opacification.
- **Chronic HP** involves persistent and **gradually progressive symptoms** (as in this patient) resulting from long-term, moderate-dose antigen exposure. Patients usually have symptoms of cough, dyspnea, fatigue, and **weight loss** for several months or more. Lung auscultation usually reveals **fine crackles**, and chest x-ray shows **interstitial reticular opacities** consistent with the development of pulmonary fibrosis.

The diagnosis of HP can be aided by pulmonary function testing that reveals a **restrictive pattern**; the restriction is worse with chronic HP and is accompanied by more severe impairments in gas exchange (eg, **hypoxemia**, low DLCO). Biopsy in both acute and chronic disease reveals **lymphocytic infiltrate** with poorly formed **noncaseating granulomas** created by the walling off of inhaled antigens. Chronic HP is associated with progressive **alveolar septal fibrosis**. Removal of antigen exposure usually resolves acute disease; however, the fibrosis occurring in chronic disease is often irreversible.

(Choice A) Asthma presents with intermittent cough and dyspnea. Bronchiolar biopsy can reveal noncaseating granulomas, but fibrosis is not typical and eosinophilic infiltrate is expected.

(Choice B) Chronic bronchitis presents with dyspnea and cough and is expected to cause wheezing on lung auscultation. Lymphocytic infiltrate may be present on biopsy, but granulomas are not typical.

(Choice D) Idiopathic pulmonary fibrosis can present quite similarly to chronic HP, but affected patients are usually older (eg, age >50) and granulomas are not expected on lung biopsy.

(Choice E) Pulmonary tuberculosis typically presents with fever, cough, dyspnea, night sweats, and weight loss. Lung biopsy demonstrates lymphocytic infiltrate, but caseating (rather than noncaseating) granulomas.

Educational objective:

https://t.me/USMLEWorldStep1

- **Acute HP** involves abrupt-onset and often recurring episodes of fever, chills, cough, dyspnea, and fatigue that coincide with intermittent high-dose antigen exposure. Leukocytosis is often present. Chest x-ray may be normal or show scattered micronodular opacification.
- **Chronic HP** involves persistent and **gradually progressive symptoms** (as in this patient) resulting from long-term, moderate-dose antigen exposure. Patients usually have symptoms of cough, dyspnea, fatigue, and **weight loss** for several months or more. Lung auscultation usually reveals **fine crackles**, and chest x-ray shows **interstitial reticular opacities** consistent with the development of pulmonary fibrosis.

The diagnosis of HP can be aided by pulmonary function testing that reveals a **restrictive pattern**; the restriction is worse with chronic HP and is accompanied by more severe impairments in gas exchange (eg, **hypoxemia**, low DLCO). Biopsy in both acute and chronic disease reveals **lymphocytic infiltrate** with poorly formed **noncaseating granulomas** created by the walling off of inhaled antigens. Chronic HP is associated with progressive **alveolar septal fibrosis**. Removal of antigen exposure usually resolves acute disease; however, the fibrosis occurring in chronic disease is often irreversible.

(Choice A) Asthma presents with intermittent cough and dyspnea. Bronchiolar biopsy can reveal noncaseating granulomas, but fibrosis is not typical and eosinophilic infiltrate is expected.

(Choice B) Chronic bronchitis presents with dyspnea and cough and is expected to cause wheezing on lung auscultation. Lymphocytic infiltrate may be present on biopsy, but granulomas are not typical.

(Choice D) Idiopathic pulmonary fibrosis can present quite similarly to chronic HP, but affected patients are usually older (eg, age >50) and granulomas are not expected on lung biopsy.

(Choice E) Pulmonary tuberculosis typically presents with fever, cough, dyspnea, night sweats, and weight loss. Lung biopsy demonstrates lymphocytic infiltrate, but caseating (rather than noncaseating) granulomas.

Educational objective:
Hypersensitivity pneumonitis involves an exaggerated immunologic response to an inhaled antigen and can have an acute or chronic presentation. Chronic disease presents with gradually progressive cough, dyspnea, fatigue, and weight loss, and lung biopsy reveals lymphocytic infiltrate, poorly formed noncaseating granulomas, and septal fibrosis.

https://t.me/USMLEWorldStep1

An 18-year-old man comes to the emergency department with sudden-onset right-sided chest pain and dyspnea. The patient was at home watching a football game on television when his symptoms abruptly started. He now has pain with deep breaths. He has no other medical problems and takes no medications. The patient has smoked a pack of cigarettes daily for the past 2 years. His respirations are 24/min. Physical examination shows a thin, tall patient in acute distress. The right side of the chest is hyperresonant to percussion and lacks audible breath sounds. His chest x-ray is shown below.

Which of the following conditions most likely led to this patient's presentation?

- A. Apical subpleural blebs
- B. Centriacinar emphysema
- C. Compensatory hyperinflation
- D. Obstructive hyperinflation
- E. Panacinar emphysema

Submit

https://t.me/USMLEWorldStep1

An 18-year-old man comes to the emergency department with sudden-onset right-sided chest pain and dyspnea.
The pa
pain w
pack c
patien
sound

Exhibit Display

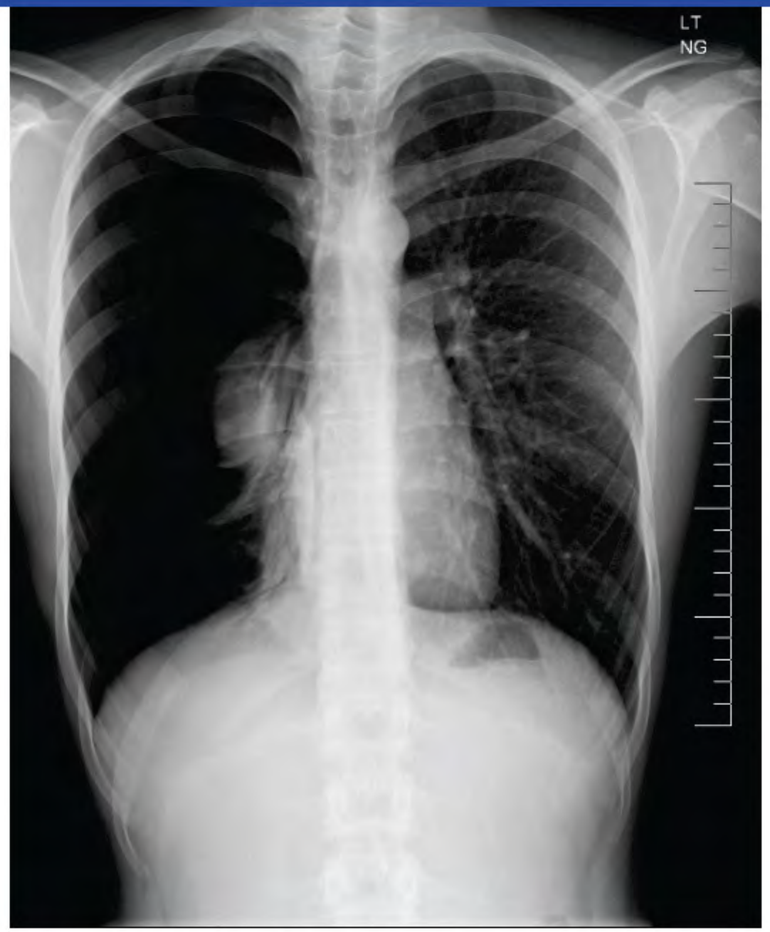

Zoom In Zoom Out Reset New | Existing My Notebook

https://t.me/USMLEWorldStep1

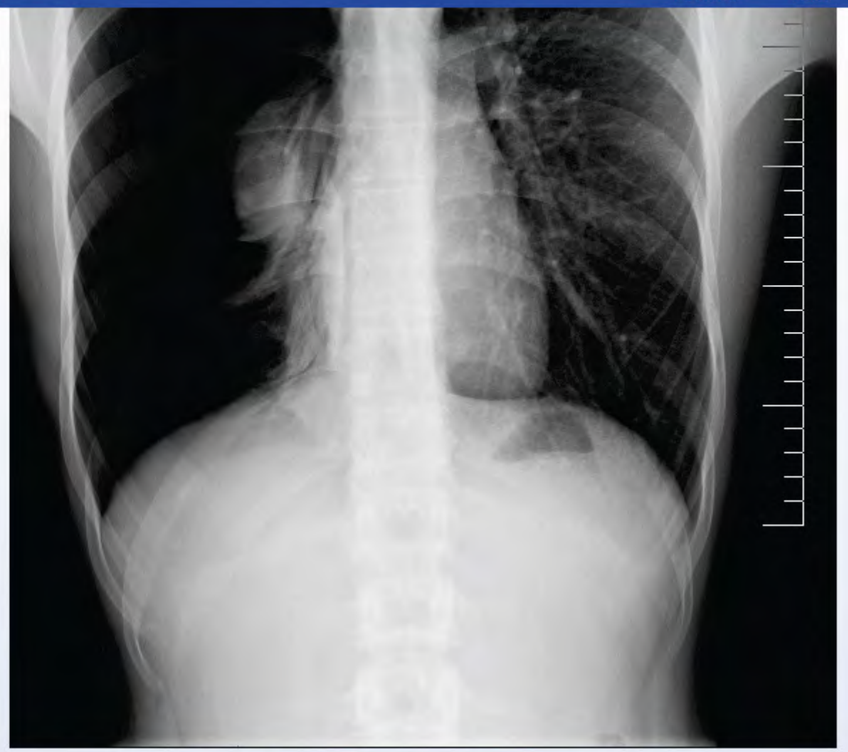

Which of the following conditions most likely led to this patient's presentation?

- A. Apical subpleural blebs
- B. Centriacinar emphysema
- C. Compensatory hyperinflation
- D. Obstructive hyperinflation
- E. Panacinar emphysema

Submit

https://t.me/USMLEWorldStep1

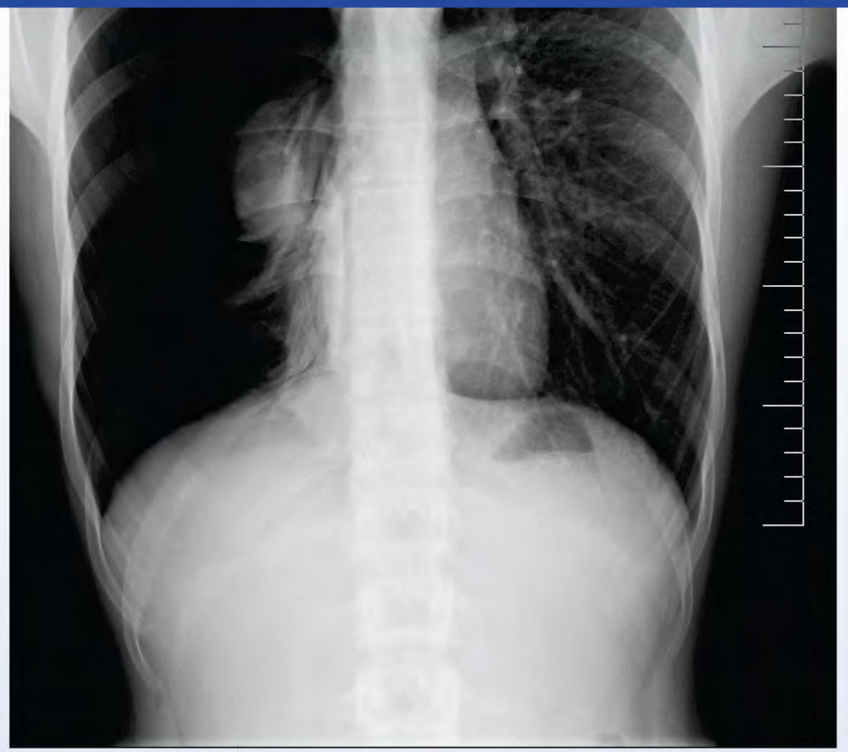

Which of the following conditions most likely led to this patient's presentation?

- ✓ A. Apical subpleural blebs (77%)
- B. Centriacinar emphysema (5%)
- C. Compensatory hyperinflation (4%)
- D. Obstructive hyperinflation (5%)
- ✗ E. Panacinar emphysema (7%)

Incorrect
Correct answer
A

77%
Answered correctly

31 secs
Time Spent

2023
Version

https://t.me/USMLEWorldStep1

Explanation

Exhibit Display

Spontaneous pneumothorax

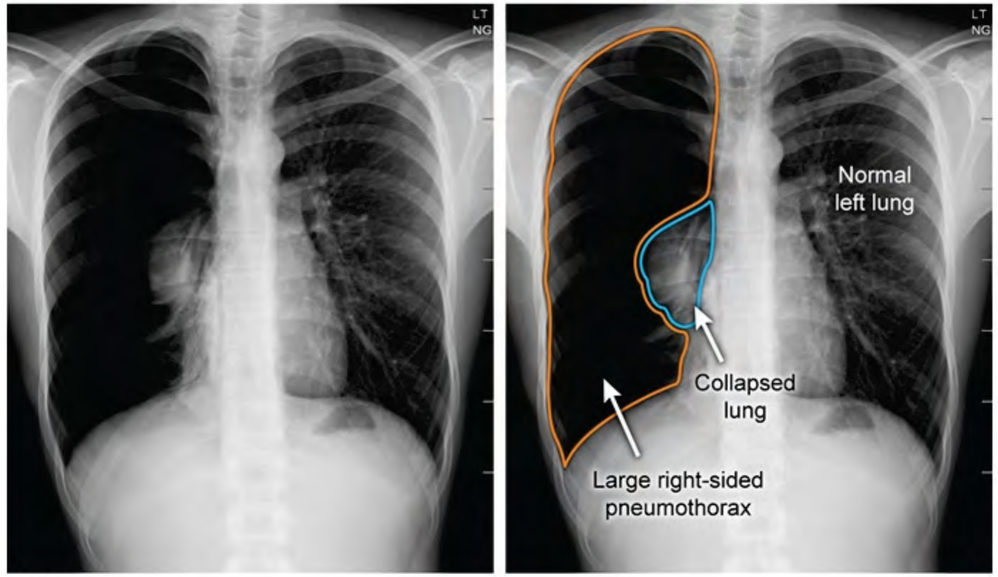

©UWorld

Zoom In | Zoom Out | Reset | New | Existing | My Notebook

This y
exami
withou
intrapl
and vi
of the
then c

Tall, th
smoki
apices.

https://t.me/USMLEWorldStep1

This young male patient with sudden-onset unilateral chest pain, dyspnea, and absent breath sounds on examination likely has **primary spontaneous pneumothorax** (PSP). PSP is nontraumatic and is found in patients without preexisting pulmonary disease (eg, cystic fibrosis). It occurs when a large change in the alveolar or intrapleural pressure results in a break in the visceral pleura and subsequent trapping of air between the parietal and visceral spaces. The superficial alveoli in the apices experience greater pressure changes (due to the weight of the lungs pulling down on the apical tissue), predisposing them to the formation of **subpleural blebs**. The blebs then can spontaneously rupture through the visceral pleura, frequently while the patient is at rest.

Tall, thin males around the age of 20 are most commonly affected. Although the most important risk factor is **smoking**, taller individuals also appear to be at higher risk due to more negative intrapleural pressure in the lung apices.

(Choice B) Centriacinar emphysema occurs as the larger proximal bronchioles are destroyed, usually as a result of exposure to tobacco smoke in patients with chronic obstructive pulmonary disease. It predominantly affects the upper lung lobe and initially spares the superficial alveoli.

(Choice C) Compensatory hyperinflation results when normal lung parenchyma expands in response to loss of adjacent lung volume (eg, segmental/lobar collapse or surgical removal). PSP results in collapse of adjacent lung tissue due to extrinsic compression by intrapleural air and does not result in parenchymal expansion.

(Choice D) Obstructive hyperinflation occurs when a lung segment expands due to a partial obstruction (eg, bronchogenic carcinoma) of the airway supplying it. On inspiration, the airway expands, which allows the movement of air into the segment; however, as the airway closes on expiration, air is trapped behind the obstruction. In an otherwise healthy young patient, it is unlikely to be the cause of PSP.

(Choice E) Panacinar emphysema occurs more commonly in the lower zones and anterior margins of the lungs. It destroys the entire acinus uniformly and is associated with alpha-1 antitrypsin deficiency. Although pneumothorax can occur in these patients, it is usually preceded by symptoms of emphysema.

Educational objective:
Primary spontaneous pneumothorax occurs in patients without preexisting pulmonary disease when a large change in the alveolar or intrapleural pressure results in a break in the visceral (eg, ruptured superficial bleb) pleura and air trapping between the pleural spaces.

https://t.me/USMLEWorldStep1

A 63-year-old man is brought to the emergency department due to high fever, confusion, headache, watery diarrhea, and cough. The patient smokes 2 packs of cigarettes daily and has a history of chronic bronchitis. Temperature is 40.1 C (104.2 F), blood pressure is 100/70 mm Hg, pulse is 91/min, and respirations are 28/min. Sputum Gram staining reveals numerous neutrophils but no bacteria. Which of the following is the most likely cause of this patient's current condition?

- A. *Coccidioides immitis*
- B. *Klebsiella pneumoniae*
- C. *Legionella pneumophila*
- D. *Mycobacterium kansasii*
- E. *Mycoplasma pneumoniae*

Submit

https://t.me/USMLEWorldStep1

A 63-year-old man is brought to the emergency department due to high fever, confusion, headache, watery diarrhea, and cough. The patient smokes 2 packs of cigarettes daily and has a history of chronic bronchitis. Temperature is 40.1 C (104.2 F), blood pressure is 100/70 mm Hg, pulse is 91/min, and respirations are 28/min. Sputum Gram staining reveals numerous neutrophils but no bacteria. Which of the following is the most likely cause of this patient's current condition?

- A. *Coccidioides immitis* (4%)
- ✗ B. *Klebsiella pneumoniae* (3%)
- ✓ C. *Legionella pneumophila* (68%)
- D. *Mycobacterium kansasii* (3%)
- E. *Mycoplasma pneumoniae* (19%)

Incorrect
Correct answer
C

68%
Answered correctly

04 secs
Time Spent

2023
Version

Explanation

Overview of *Legionella* pneumonia	
Clinical features	• High fever with relative bradycardia • Headache & confusion • Watery diarrhea
Laboratory findings	• Hyponatremia • Sputum Gram stain showing many neutrophils but few or no

https://t.me/USMLEWorldStep1

Overview of *Legionella* pneumonia	
Clinical features	• High fever with relative bradycardia • Headache & confusion • Watery diarrhea
Laboratory findings	• Hyponatremia • Sputum Gram stain showing many neutrophils but few or no organisms
Diagnosis	• *Legionella* urine antigen test
Treatment	• Respiratory fluoroquinolones or newer macrolides

This patient likely has ***Legionella pneumophila* infection**, a common cause of community-acquired pneumonia (CAP). Most cases present with **high fever** and fatigue followed by **gastrointestinal** (eg, nausea, vomiting, diarrhea), pulmonary (eg, cough, shortness of breath), and nonspecific (eg, headache, confusion) symptoms. Patients age >50 who **smoke** and have **chronic lung disease** are at greatest risk. Isolated cases are common, but outbreaks can occur when the pathogen contaminates **manmade water reservoirs** (eg, hot tub, air cooling system, drinking water system).

L pneumophila is a facultative intracellular organism that requires specialized media (eg, buffered charcoal yeast extract) to grow; although the pathogen is gram negative, it **stains poorly with Gram stain** due to a unique lipopolysaccharide in its outer membrane. Therefore, the diagnosis is most commonly confirmed based on positive PCR testing or positive urine *Legionella* antigen testing.

(Choice A) *Coccidioides immitis* is a dimorphic fungus endemic to the deserts of the southwestern United States. Although most cases of *C immitis* infection are asymptomatic, it can cause CAP. However, the presence of gastrointestinal symptoms, headache, and confusion makes *Legionella* far more likely.

https://t.me/USMLEWorldStep1

This patient likely has ***Legionella pneumophila* infection**, a common cause of community-acquired pneumonia (CAP). Most cases present with **high fever** and fatigue followed by **gastrointestinal** (eg, nausea, vomiting, diarrhea), pulmonary (eg, cough, shortness of breath), and nonspecific (eg, headache, confusion) symptoms. Patients age >50 who **smoke** and have **chronic lung disease** are at greatest risk. Isolated cases are common, but outbreaks can occur when the pathogen contaminates **manmade water reservoirs** (eg, hot tub, air cooling system, drinking water system).

L pneumophila is a facultative intracellular organism that requires specialized media (eg, buffered charcoal yeast extract) to grow; although the pathogen is gram negative, it **stains poorly with Gram stain** due to a unique lipopolysaccharide in its outer membrane. Therefore, the diagnosis is most commonly confirmed based on positive PCR testing or positive urine *Legionella* antigen testing.

(Choice A) *Coccidioides immitis* is a dimorphic fungus endemic to the deserts of the southwestern United States. Although most cases of *C immitis* infection are asymptomatic, it can cause CAP. However, the presence of gastrointestinal symptoms, headache, and confusion makes *Legionella* far more likely.

(Choice B) *Klebsiella pneumoniae* is a gram-negative rod that causes nosocomial pneumonia and aspiration pneumonia. However, this organism can generally be visualized on sputum Gram stain and does not typically cause concurrent diarrhea.

(Choice D) *Mycobacterium kansasii* is an atypical mycobacterium that causes an illness similar to *Mycobacterium tuberculosis*. However, diarrhea, confusion, and high fever are relatively uncommon.

(Choice E) *Mycoplasma pneumoniae* infection causes tracheobronchitis or walking pneumonia. *M pneumoniae* cannot be detected on Gram stain due to a lack of peptidoglycan in the cell wall. However, symptoms of infection are typically subacute and mild. The presence of high fever and confusion makes an alternate diagnosis far more likely.

Educational objective:
Legionella pneumophila infection is typically marked by high fever and fatigue followed by significant gastrointestinal, pulmonary, and constitutional symptoms. The organism is not well visualized on Gram stain and does not grow on traditional culture media; *L pneumophila* infection is primarily diagnosed by polymerase chain reaction or urine antigen testing.

https://t.me/USMLEWorldStep1

(CAP). Most cases present with **high fever** and fatigue followed by **gastrointestinal** (eg, nausea, vomiting, diarrhea), pulmonary (eg, cough, shortness of breath), and nonspecific (eg, headache, confusion) symptoms. Patients age >50 who **smoke** and have **chronic lung disease** are at greatest risk. Isolated cases are common, but outbreaks can occur when the pathogen contaminates **manmade water reservoirs** (eg, hot tub, air cooling system, drinking water system).

L pneumophila is a facultative intracellular organism that requires specialized media (eg, buffered charcoal yeast extract) to grow; although the pathogen is gram negative, it **stains poorly with Gram stain** due to a unique lipopolysaccharide in its outer membrane. Therefore, the diagnosis is most commonly confirmed based on positive PCR testing or positive urine *Legionella* antigen testing.

(Choice A) *Coccidioides immitis* is a dimorphic fungus endemic to the deserts of the southwestern United States. Although most cases of *C immitis* infection are asymptomatic, it can cause CAP. However, the presence of gastrointestinal symptoms, headache, and confusion makes *Legionella* far more likely.

(Choice B) *Klebsiella pneumoniae* is a gram-negative rod that causes nosocomial pneumonia and aspiration pneumonia. However, this organism can generally be visualized on sputum Gram stain and does not typically cause concurrent diarrhea.

(Choice D) *Mycobacterium kansasii* is an atypical mycobacterium that causes an illness similar to *Mycobacterium tuberculosis*. However, diarrhea, confusion, and high fever are relatively uncommon.

(Choice E) *Mycoplasma pneumoniae* infection causes tracheobronchitis or walking pneumonia. *M pneumoniae* cannot be detected on Gram stain due to a lack of peptidoglycan in the cell wall. However, symptoms of infection are typically subacute and mild. The presence of high fever and confusion makes an alternate diagnosis far more likely.

Educational objective:
Legionella pneumophila infection is typically marked by high fever and fatigue followed by significant gastrointestinal, pulmonary, and constitutional symptoms. The organism is not well visualized on Gram stain and does not grow on traditional culture media; *L pneumophila* infection is primarily diagnosed by polymerase chain reaction or urine antigen testing.

https://t.me/USMLEWorldStep1

A 48-year-old man dies in a motor vehicle crash. He had a history of intravenous drug use and had recently been released from prison. The patient's other medical conditions included hepatitis C and hypertension. On autopsy, he is found to have a small, fibrotic focus in the upper portion of the lower lobe of the right lung and a calcified right hilar lymph node. These autopsy findings are most consistent with which of the following?

- A. Hematogenous dissemination of *Mycobacteria tuberculosis*
- B. Mycobacterial elimination from the body
- C. Poor immunity against mycobacterial infection
- D. Primary *M tuberculosis* infection
- E. Secondary *M tuberculosis* disease

Submit

https://t.me/USMLEWorldStep1

A 48-year-old man dies in a motor vehicle crash. He had a history of intravenous drug use and had recently been released from prison. The patient's other medical conditions included hepatitis C and hypertension. On autopsy, he is found to have a small, fibrotic focus in the upper portion of the lower lobe of the right lung and a calcified right hilar lymph node. These autopsy findings are most consistent with which of the following?

- A. Hematogenous dissemination of *Mycobacteria tuberculosis* (3%)
- ✗ B. Mycobacterial elimination from the body (9%)
- C. Poor immunity against mycobacterial infection (3%)
- ✓ D. Primary *M tuberculosis* infection (54%)
- E. Secondary *M tuberculosis* disease (28%)

Incorrect
Correct answer
D

54%
Answered correctly

16 secs
Time Spent

2023
Version

Explanation

Pathogenesis of pulmonary tuberculosis infection

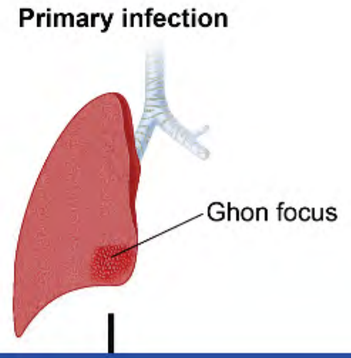

https://t.me/USMLEWorldStep1

A 48-year-old man dies in a motor vehicle crash. He had a history of intravenous drug use and had recently been releas
he is f
hilar ly

Inco
Corre
D

Expl

Exhibit Display

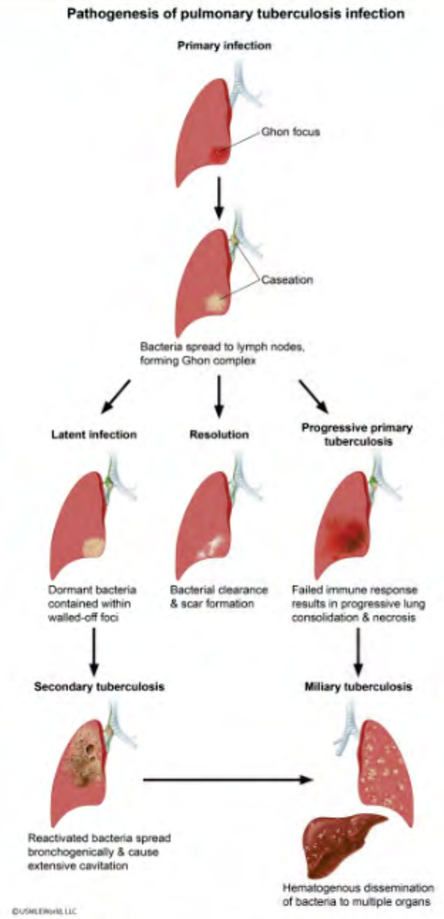

Zoom In Zoom Out Reset New | Existing My Notebook

https://t.me/USMLEWorldStep1

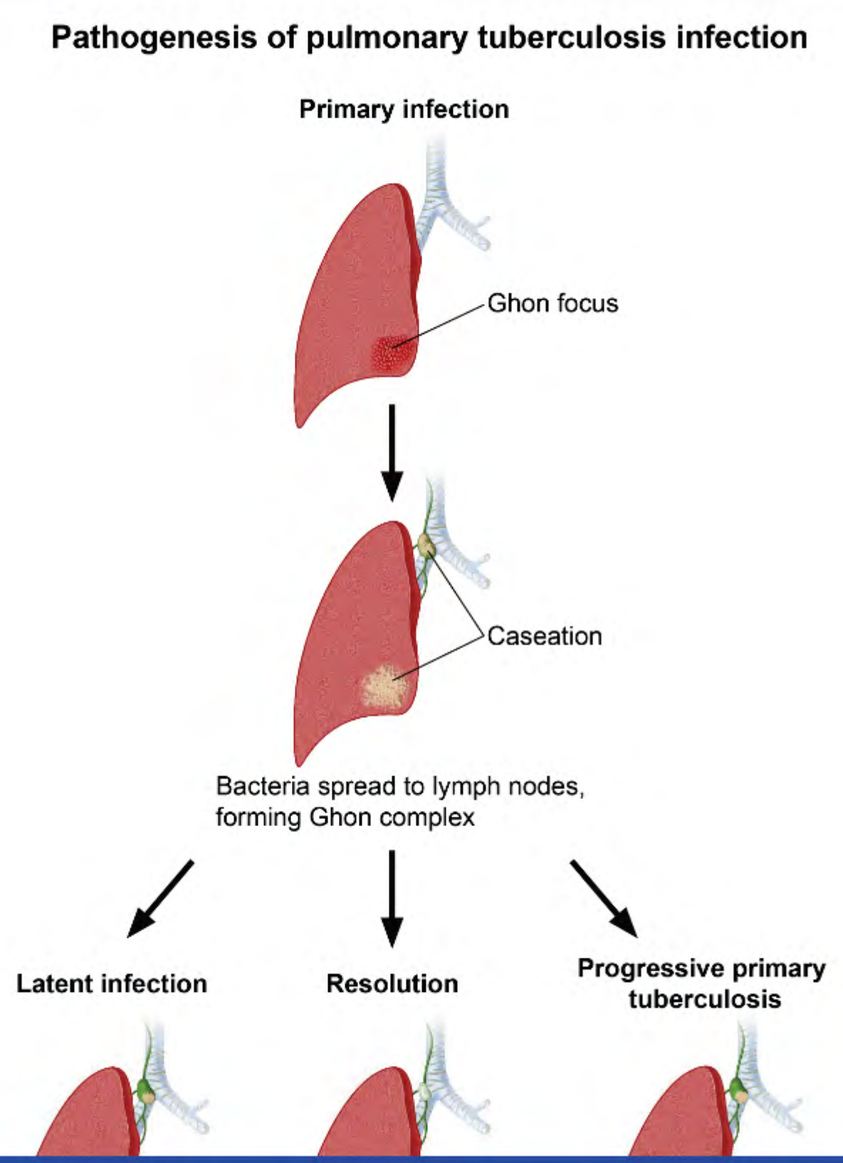

https://t.me/USMLEWorldStep1

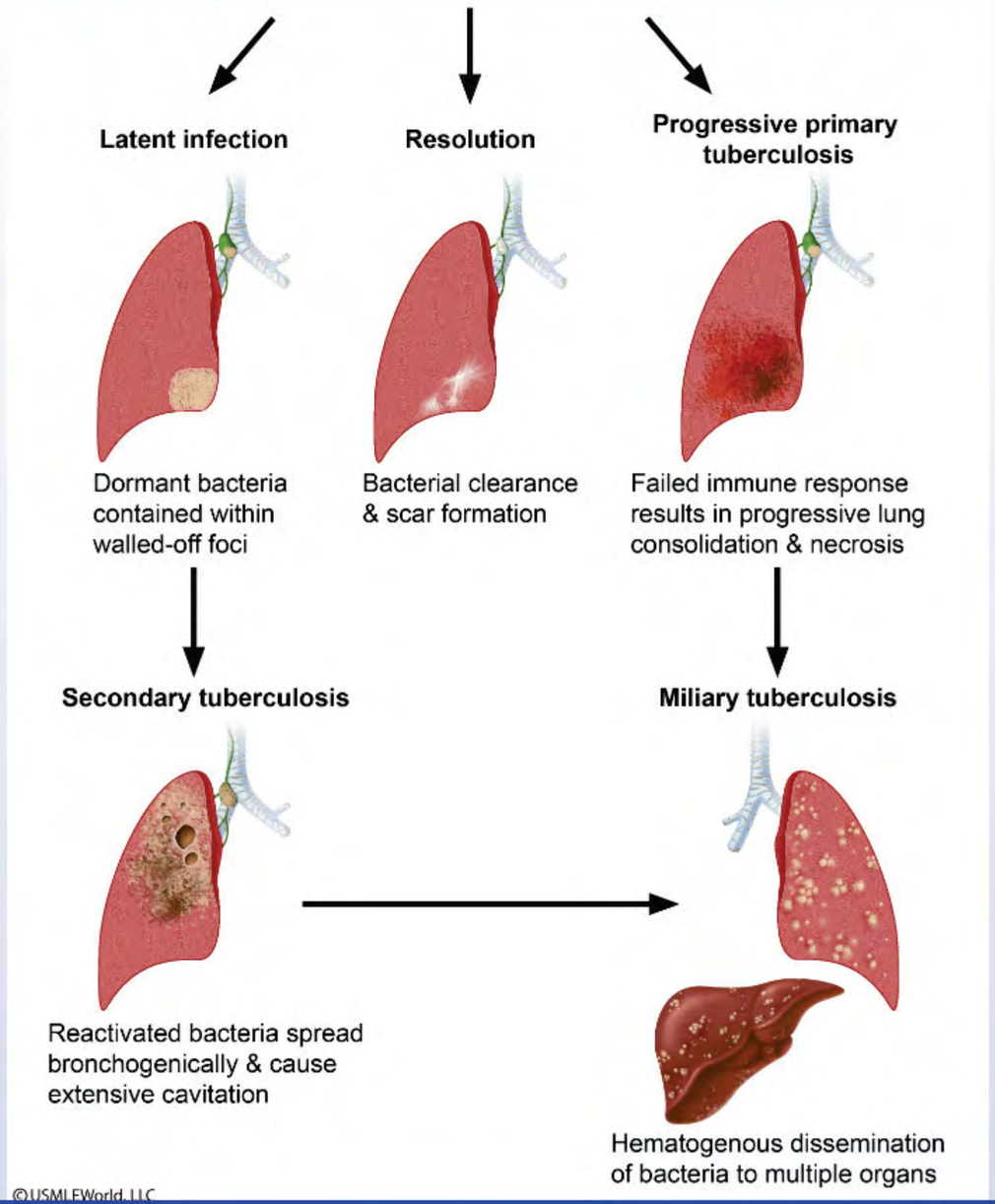

https://t.me/USMLEWorldStep1

©USMLEWorld, LLC

Primary infection with ***Mycobacterium tuberculosis*** begins with the inhalation of contaminated respiratory droplets into the **lower lobe** of the lung. Initially, the organism replicates in an unchecked fashion within the alveoli due to virulence factors (eg, cord factor) that prevent bacterial destruction by alveolar macrophages. The pathogen is also carried by infected macrophages through the draining lymphatic system to **ipsilateral hilar lymph nodes**. These initial areas of infection (lower lobe, ipsilateral hilar lymph node) are collectively referred to as a **Ghon complex**.

After a few weeks, the display of mycobacterial antigens by antigen presenting cells leads to stimulation of CD4 cells, with subsequent cytokine-mediated activation of macrophages. Activated macrophages control the infection (in >95% of patients) by forming mature phagolysosomes to kill intracellular mycobacteria and by differentiating into epithelioid and Langhans giant cells that wall off extracellular mycobacteria within granulomas. Over time, granulomas become **fibrosed and calcified**, which reinforces their structure. It also allows areas of primary infection to be visualized on x-ray or gross pathology. A fibrosed and calcified Ghon complex is referred to as a **Ranke complex**.

(Choices A and C) Most patients with primary tuberculosis contain the infection, but those with ineffective immunity (eg, extremes of age, immunosuppression) can develop progressive illness with hematogenous spread to distant areas (eg, Potts disease, meningitis). Widespread, massive hematogenous dissemination can also occur, resulting in innumerable, small, millet seed-like lesions in multiple organs (miliary tuberculosis).

(Choices B and E) Primary tuberculosis infections are usually contained within granulomas but not fully eliminated. If the walls of the granuloma weaken, *M tuberculosis* can escape and cause reactivation (secondary) disease. This is most common in the setting of acquired immunosuppression (eg, HIV, tumor necrosis factor-alpha inhibitors) and usually presents with symptoms (eg, weight loss, cough, fever) and apical cavitary lesions.

Educational objective:
The Ghon complex describes the two initial sites (lower lobe of lung, ipsilateral hilar lymph node) of primary tuberculosis infection. Over time, these sites become calcified and fibrosed and can be visualized on gross pathology and radiographic imaging (Ranke complex).

References

https://t.me/USMLEWorldStep1

©USMLEWorld, LLC

Primary infection with ***Mycobacterium tuberculosis*** begins with the inhalation of contaminated respiratory
drople
due to
is also
These
compl

After a
cells, v
(in >95
into ep
granul
infecti

Ranke

(Choi
immun
distant
resulti

(Choi
elimina
diseas
inhibit

Educa
The G
tuberc
pathol

References

Exhibit Display

Miliary tuberculosis

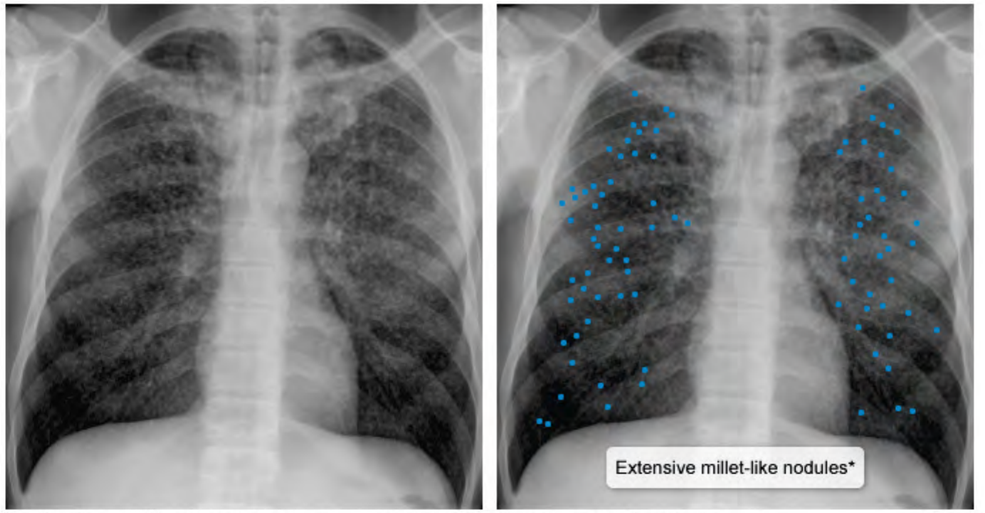

*Small, uniform nodules of caseating granulomas after widespread hematogenous dissemination ©UWorld

Zoom In Zoom Out Reset New | Existing My Notebook

https://t.me/USMLEWorldStep1

©USMLEWorld, LLC

Primary infection with ***Mycobacterium tuberculosis*** begins with the inhalation of contaminated respiratory

drople

due to

is also

These

compl

After a

cells, v

(in >95

into ep

granul

infecti

Ranke

(Choi

immun

distant

resulti

(Choi

elimina

diseas

inhibit

Educa

The G

tuberc

pathol

References

Exhibit Display

Pulmonary tuberculosis

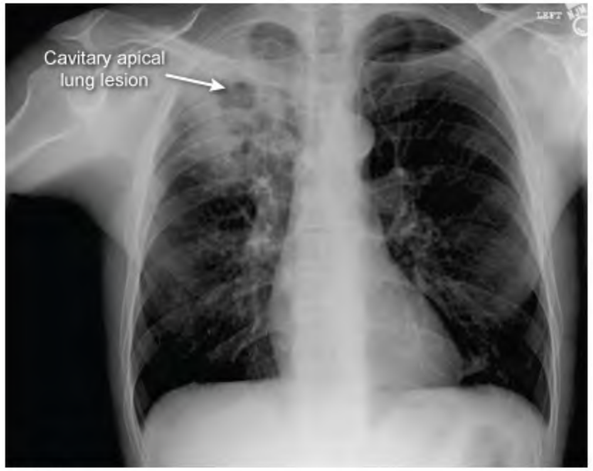

©UWorld

Zoom In
Zoom Out
Reset
New | Existing
My Notebook

https://t.me/USMLEWorldStep1

A 60-year-old man comes to the clinic due to a 3-week history of fatigue, shortness of breath, and fever. The patient has a 35-pack-year history of cigarette smoking but has no other significant medical history. Temperature is 38.6 C (101.5 F), blood pressure is 140/92 mm Hg, pulse is 110/min, and respirations are 24/min. There is dullness to percussion at the right lung base. Chest radiograph shows a moderate-sized loculated pleural effusion on the right side. Ultrasonography reveals multiple separate fluid pockets within the pleural space. Chest tube placement produces only a small amount of thick pus. Intrapleural administration of a medication with which of the following effects would most likely improve chest tube drainage in this patient?

- A. Activation of fibrin-bound plasminogen
- B. Decreased interstitial edema formation
- C. Inhibition of factor Xa production
- D. Inhibition of platelet activity
- E. Irritation of the mesothelial pleural lining

Submit

https://t.me/USMLEWorldStep1

A 60-year-old man comes to the clinic due to a 3-week history of fatigue, shortness of breath, and fever. The patient has a 35-pack-year history of cigarette smoking but has no other significant medical history. Temperature is 38.6 C (101.5 F), blood pressure is 140/92 mm Hg, pulse is 110/min, and respirations are 24/min. There is dullness to percussion at the right lung base. Chest radiograph shows a moderate-sized loculated pleural effusion on the right side. Ultrasonography reveals multiple separate fluid pockets within the pleural space. Chest tube placement produces only a small amount of thick pus. Intrapleural administration of a medication with which of the following effects would most likely improve chest tube drainage in this patient?

- ✓ A. Activation of fibrin-bound plasminogen (40%)
- ✗ B. Decreased interstitial edema formation (24%)
- C. Inhibition of factor Xa production (5%)
- D. Inhibition of platelet activity (7%)
- E. Irritation of the mesothelial pleural lining (22%)

Incorrect
Correct answer
A

40%
Answered correctly

11 secs
Time Spent

2023
Version

Explanation

Parapneumonic effusions		
	Uncomplicated	**Complicated***
Etiology	Sterile exudate in pleural space	Bacterial invasion of pleural space
Radiologic appearance	Small to moderate & free flowing	Moderate to large, free flowing or loculated

https://t.me/USMLEWorldStep1

Parapneumonic effusions		
	Uncomplicated	**Complicated***
Etiology	Sterile exudate in pleural space	Bacterial invasion of pleural space
Radiologic appearance	Small to moderate & free flowing	Moderate to large, free flowing or loculated
Pleural fluid characteristics	• pH ≥7.2 • Glucose ≥60 mg/dL • WBCs ≤50,000/mm^3	• pH <7.2 • Glucose <60 mg/dL • WBCs >50,000/mm^3
Treatment	Antibiotics	Antibiotics + drainage
*Empyema represents advanced progression of a complicated effusion. **WBC** = white blood cell.		

This patient's several weeks of fever, shortness of breath, and fatigue with imaging showing a **loculated pleural effusion** with **complex septations** represents a classic presentation of **empyema**. Empyema is an advanced form of complicated parapneumonic effusion in which bacterial invasion into the pleural space is followed by progressive inflammation with **pus accumulation** and **organized fibrosis**. Treatment requires prompt drainage of the infected fluid via a chest tube, but such effusions are often difficult to drain due to numerous loculations (ie, separated fluid pockets) and high fluid viscosity.

In some cases, intrapleural administration of a **fibrinolytic agent** (eg, tissue plasminogen activator [tPA], streptokinase) in combination with deoxyribonuclease (DNase) can **improve drainage** of a loculated empyema and help resolve the effusion via chest tube drainage. The tPA **activates fibrin-bound plasminogen** to break down organized fibrin, and the DNase enzyme may assist by cleaving nucleic acids that increase fluid viscosity after being deposited by lysed leukocytes (eg, neutrophil extracellular traps).

https://t.me/USMLEWorldStep1

This patient's several weeks of fever, shortness of breath, and fatigue with imaging showing a **loculated pleural effusion** with **complex septations** represents a classic presentation of **empyema**. Empyema is an advanced form of complicated parapneumonic effusion in which bacterial invasion into the pleural space is followed by progressive inflammation with **pus accumulation** and **organized fibrosis**. Treatment requires prompt drainage of the infected fluid via a chest tube, but such effusions are often difficult to drain due to numerous loculations (ie, separated fluid pockets) and high fluid viscosity.

In some cases, intrapleural administration of a **fibrinolytic agent** (eg, tissue plasminogen activator [tPA], streptokinase) in combination with deoxyribonuclease (DNase) can **improve drainage** of a loculated empyema and help resolve the effusion via chest tube drainage. The tPA **activates fibrin-bound plasminogen** to break down organized fibrin, and the DNase enzyme may assist by cleaving nucleic acids that increase fluid viscosity after being deposited by lysed leukocytes (eg, neutrophil extracellular traps).

A complicated parapneumonic effusion or empyema that cannot be successfully drained following the administration of tPA and DNase typically requires surgical drainage via video-assisted thoracoscopic surgery.

(Choice B) Interstitial edema formation occurs early in the development of pleural effusion, causing increased fluid to pass into the pleural space. Once organized fibrosis and empyema develop, reducing interstitial edema formation is of no significant benefit.

(Choices C and D) Factor Xa inhibitors (eg, rivaroxaban, apixaban) are given systemically for the treatment of venous thromboembolic disease, and medications that inhibit platelet activity (eg, aspirin, P2Y12 inhibitors) are used systemically to lower the risk of intra-arterial thrombosis. However, none of these medications target fibrin (the major contributor to development of loculated empyema), and they are therefore not helpful in the management of empyema.

(Choice E) Pleurodesis involves the instillation of a chemical irritant (eg, talc) into the pleural space to fuse the visceral and parietal pleural layers together. It is used to prevent reaccumulation of pleural fluid in patients with recurrent pleural effusion, but it does not assist in drainage of an empyema.

Educational objective:
Empyema involves bacterial invasion of the intrapleural space with progressive inflammation, pus accumulation, and organized fibrosis. Drainage with a chest tube is often difficult due to loculations and high fluid viscosity, but it

https://t.me/USMLEWorldStep1

progressive inflammation with **pus accumulation** and **organized fibrosis**. Treatment requires prompt drainage of the infected fluid via a chest tube, but such effusions are often difficult to drain due to numerous loculations (ie, separated fluid pockets) and high fluid viscosity.

In some cases, intrapleural administration of a **fibrinolytic agent** (eg, tissue plasminogen activator [tPA], streptokinase) in combination with deoxyribonuclease (DNase) can **improve drainage** of a loculated empyema and help resolve the effusion via chest tube drainage. The tPA **activates fibrin-bound plasminogen** to break down organized fibrin, and the DNase enzyme may assist by cleaving nucleic acids that increase fluid viscosity after being deposited by lysed leukocytes (eg, neutrophil extracellular traps).

A complicated parapneumonic effusion or empyema that cannot be successfully drained following the administration of tPA and DNase typically requires surgical drainage via video-assisted thoracoscopic surgery.

(Choice B) Interstitial edema formation occurs early in the development of pleural effusion, causing increased fluid to pass into the pleural space. Once organized fibrosis and empyema develop, reducing interstitial edema formation is of no significant benefit.

(Choices C and D) Factor Xa inhibitors (eg, rivaroxaban, apixaban) are given systemically for the treatment of venous thromboembolic disease, and medications that inhibit platelet activity (eg, aspirin, P2Y12 inhibitors) are used systemically to lower the risk of intra-arterial thrombosis. However, none of these medications target fibrin (the major contributor to development of loculated empyema), and they are therefore not helpful in the management of empyema.

(Choice E) Pleurodesis involves the instillation of a chemical irritant (eg, talc) into the pleural space to fuse the visceral and parietal pleural layers together. It is used to prevent reaccumulation of pleural fluid in patients with recurrent pleural effusion, but it does not assist in drainage of an empyema.

Educational objective:
Empyema involves bacterial invasion of the intrapleural space with progressive inflammation, pus accumulation, and organized fibrosis. Drainage with a chest tube is often difficult due to loculations and high fluid viscosity, but it can be aided by the intrapleural administration of a fibrinolytic agent (eg, tissue plasminogen activator) in combination with a nucleic acid cleaving enzyme (ie, deoxyribonuclease).

References

https://t.me/USMLEWorldStep1

characteristics	• Glucose ≥60 mg/dL • WBCs ≤50,000/mm^3	• Glucose <60 mg/dL • WBCs >50,000/mm^3

Exhibit Display

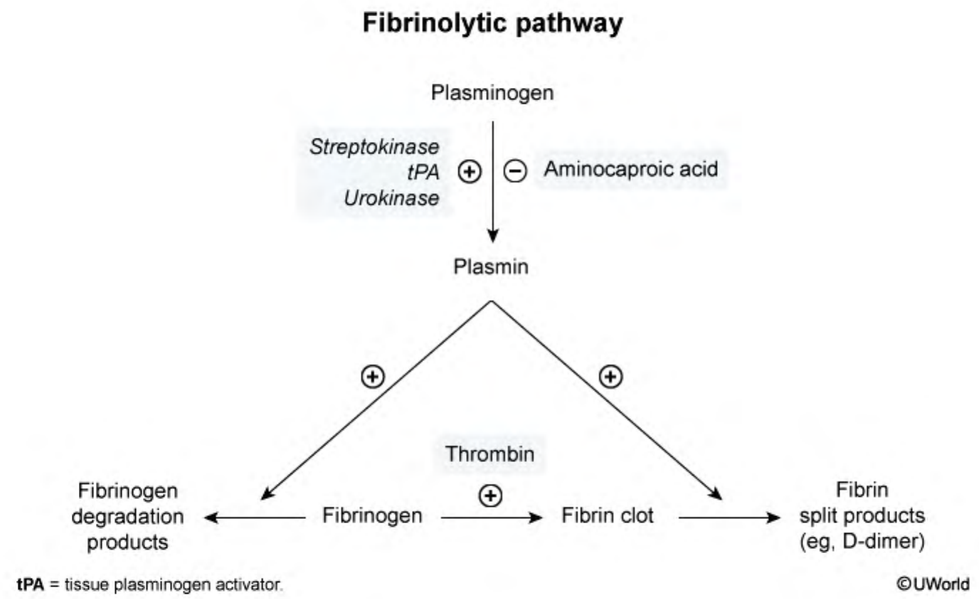

Zoom In | Zoom Out | Reset | New | Existing | My Notebook

This p
effusi
form o
progre
the inf
separa

In som
strepto
and he
down
after b

A com
admin

(Choi
to pas
format

(Choi
venou
used s

(the major contributor to development of loculated empyema), and they are therefore not helpful in the

https://t.me/USMLEWorldStep1

A 27-year-old woman comes to the office due to exertional dyspnea over the past 3 months. The patient initially had shortness of breath during exercise but now becomes dyspneic with routine activities. She has had no cough, fever, or leg swelling but has noticed increased fatigue over this time. The patient does not use tobacco, alcohol, or illicit drugs. Vital signs are within normal limits. Physical examination reveals a loud pulmonic component of S2 but is otherwise unremarkable. Chest x-ray is normal. Echocardiography shows elevated pulmonary artery systolic pressure and right ventricular hypertrophy. Left ventricular structure and function are normal. Which of the following patterns of chemical mediators is most likely present in this patient's pulmonary arteries?

	Prostacyclin	Thromboxane	Nitric Oxide
○ A.	Decreased	Increased	Decreased
○ B.	Decreased	Increased	Increased
○ C.	Increased	Decreased	Decreased
○ D.	Increased	Decreased	Increased
○ E.	Decreased	Decreased	Decreased

Submit

https://t.me/USMLEWorldStep1

A 27-year-old woman comes to the office due to exertional dyspnea over the past 3 months. The patient initially had shortness of breath during exercise but now becomes dyspneic with routine activities. She has had no cough, fever, or leg swelling but has noticed increased fatigue over this time. The patient does not use tobacco, alcohol, or illicit drugs. Vital signs are within normal limits. Physical examination reveals a loud pulmonic component of S2 but is otherwise unremarkable. Chest x-ray is normal. Echocardiography shows elevated pulmonary artery systolic pressure and right ventricular hypertrophy. Left ventricular structure and function are normal. Which of the following patterns of chemical mediators is most likely present in this patient's pulmonary arteries?

	Prostacyclin	Thromboxane	Nitric Oxide	
✓ A.	Decreased	Increased	Decreased	(60%)
B.	Decreased	Increased	Increased	(5%)
C.	Increased	Decreased	Decreased	(11%)
D.	Increased	Decreased	Increased	(13%)
E.	Decreased	Decreased	Decreased	(8%)

Correct

60% Answered correctly

03 secs Time Spent

2023 Version

Explanation

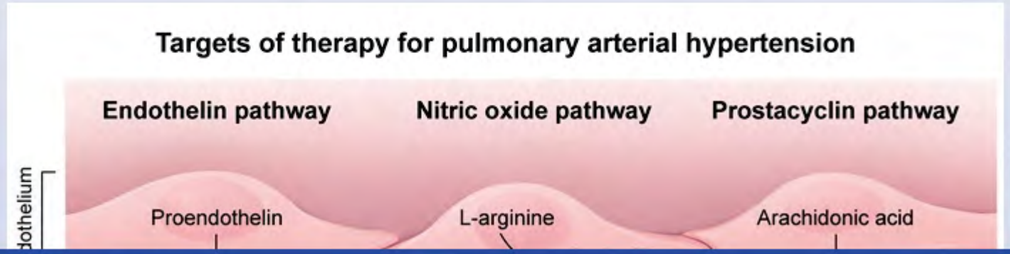

https://t.me/USMLEWorldStep1

Exhibit Display

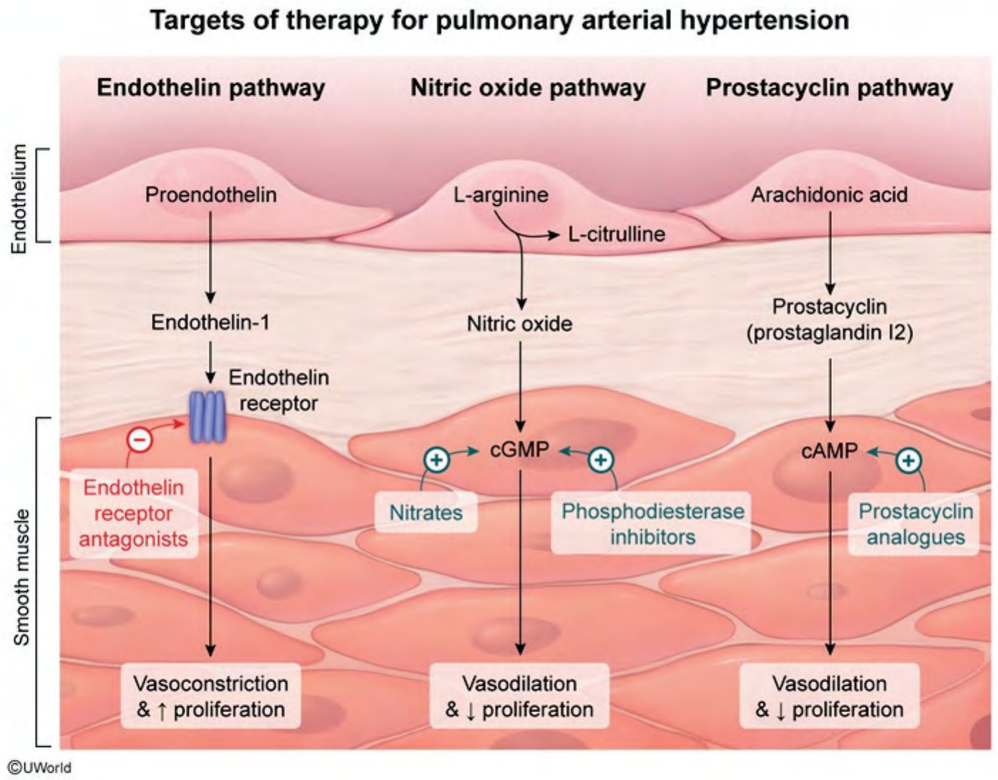

Zoom In | Zoom Out | Reset | New | Existing | My Notebook

Vasoconstriction & ↑ proliferation
Vasodilation & ↓ proliferation
Vasodilation & ↓ proliferation
©UWorld

https://t.me/USMLEWorldStep1

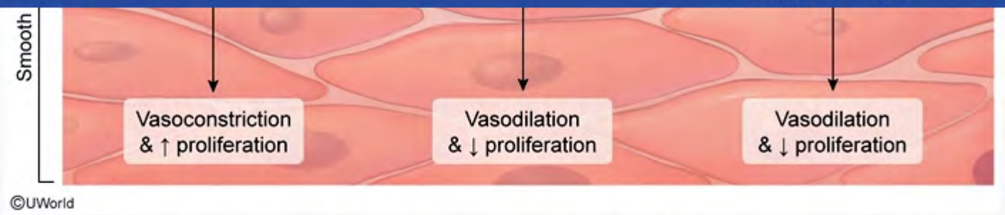

This young woman with progressive dyspnea and fatigue and a loud pulmonic component of S2 on physical examination likely has **pulmonary arterial hypertension** (PAH). PAH results from progressive remodeling of the small- and medium-sized pulmonary arteries/arterioles. Endothelial dysfunction leads to an **increase in vasoconstrictive**, **proproliferative mediators** (eg, endothelin, thromboxane A2) and a **decrease in vasodilative**, **antiproliferative mediators** (eg, nitric oxide, prostacyclin). The relative imbalance of these mediators leads to **vasoconstriction** and **smooth muscle proliferation** with intimal thickening of the vascular walls; consequently, there is increased pulmonary vascular resistance and elevated pulmonary arterial pressure. Over time, the right ventricle is unable to pump against the increased afterload, and right-sided heart failure develops.

Medical therapy for PAH targets the mediator imbalance created by endothelial dysfunction. Endothelin receptor antagonists (eg, bosentan) are used to reduce vasoconstriction, while prostacyclin analogues (eg, epoprostenol) and nitric oxide–enhancing agents (eg, sildenafil) are used to promote vasodilation. All of these agents help reduce tissue proliferation.

(Choices B, C, D, and E) These changes in the levels of prostacyclin, thromboxane, and nitric oxide are not consistent with the changes that occur in PAH.

Educational objective:
Pulmonary arterial hypertension results from endothelial dysfunction that leads to an increase in vasoconstrictive, proproliferative mediators (eg, endothelin, thromboxane A2) and a decrease in vasodilative, antiproliferative mediators (eg, nitric oxide, prostacyclin). The relative imbalance in these mediators leads to vasoconstriction and intimal-wall thickening with a consequent increase in pulmonary vascular resistance.

Pathophysiology	Pulmonary & Critical Care	Pulmonary Arterial Hypertension
Subject	System	Topic

Copyright © UWorld. All rights reserved.

https://t.me/USMLEWorldStep1

A 60-year-old woman comes to the emergency department due to shortness of breath and productive cough. The patient has a 30-pack-year smoking history. Oxygen saturation is 88% on room air. On physical examination, she appears uncomfortable and uses her accessory respiratory muscles to breathe. Expiratory wheezes are heard throughout the lungs. The patient is started on high-flow oxygen supplementation. Shortly afterward, she becomes increasingly lethargic and confused. This patient's clinical decline is most likely attributable to an increase in which of the following parameters?

- A. Pulmonary vascular resistance
- B. Reactive oxygen species production
- C. Renal bicarbonate reabsorption
- D. Respiratory minute ventilation
- E. Ventilation-perfusion mismatch

Submit

https://t.me/USMLEWorldStep1

A 60-year-old woman comes to the emergency department due to shortness of breath and productive cough. The patient has a 30-pack-year smoking history. Oxygen saturation is 88% on room air. On physical examination, she appears uncomfortable and uses her accessory respiratory muscles to breathe. Expiratory wheezes are heard throughout the lungs. The patient is started on high-flow oxygen supplementation. Shortly afterward, she becomes increasingly lethargic and confused. This patient's clinical decline is most likely attributable to an increase in which of the following parameters?

- A. Pulmonary vascular resistance (11%)
- ✕ B. Reactive oxygen species production (22%)
- C. Renal bicarbonate reabsorption (5%)
- D. Respiratory minute ventilation (23%)
- ✓ E. Ventilation-perfusion mismatch (36%)

Incorrect
Correct answer
E

36%
Answered correctly

04 secs
Time Spent

2023
Version

Explanation

Oxygen-induced hypercapnia

	Major effect	Moderate effect	Minimal effect
Baseline hypoxia	Pulmonary vasoconstriction ↓ Vasodilation diverts	High Hgb affinity for CO_2 ↓ ↓ Hgb affinity	Peripheral chemoreceptor stimulation ↓
After O			

https://t.me/USMLEWorldStep1

Oxygen-induced hypercapnia

Exhibit Display

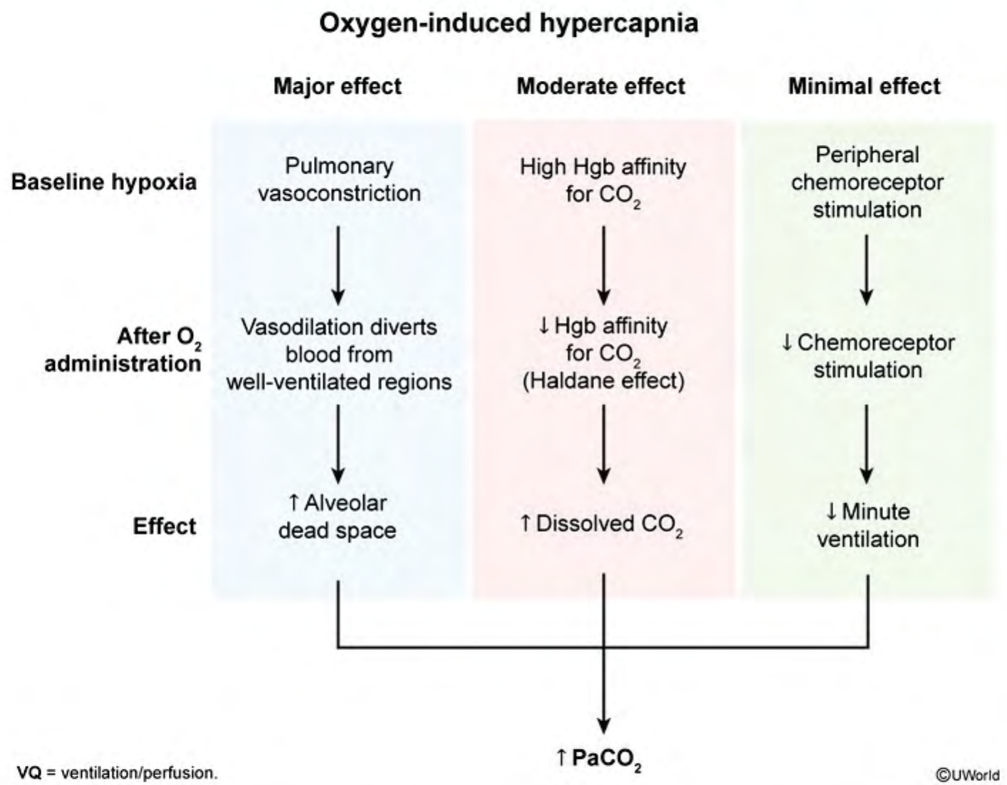

Zoom In | Zoom Out | Reset | New | Existing | My Notebook

This p
muscl
exace
howev
induc

Severa
perfus
toward alveoli with the highest ventilation, thereby minimizing physiologic dead space. Providing high-concentration supplemental oxygen allows lung regions with relatively poor ventilation to have higher oxygen

https://t.me/USMLEWorldStep1

This patient's clinical presentation (ie, dyspnea, productive cough, hypoxemia, expiratory wheezing, accessory muscle use, smoking history) is consistent with a **chronic obstructive pulmonary disease (COPD) exacerbation**. Supplemental oxygen may be warranted in patients with COPD who have significant hypoxemia; however, administration of excessively high oxygen concentrations can lead to increased CO_2 retention (**oxygen-induced hypercapnia**), resulting in confusion and a depressed level of consciousness (eg, lethargy).

Several mechanisms contribute to oxygen-induced hypercapnia, but the major cause is increased **ventilation-perfusion mismatch**. Hypoxia causes vasoconstriction of the pulmonary arterioles, which acts to shunt blood toward alveoli with the highest ventilation, thereby minimizing physiologic dead space. Providing high-concentration supplemental oxygen allows lung regions with relatively poor ventilation to have higher oxygen levels, **reversing pulmonary vasoconstriction**. The redistribution of blood flow away from well-ventilated alveoli leads to an **increase in physiologic dead space** (well-ventilated alveoli are less perfused) with a corresponding reduction in CO_2 excretion.

(Choice A) Oxygen administration alleviates hypoxic pulmonary vasoconstriction, causing an overall decrease in pulmonary vascular resistance.

(Choice B) Hyperoxia can increase production of reactive oxygen species (eg, superoxide, hydroxyl radical, hydrogen peroxide), leading to injury of the airways and lung parenchyma. Oxygen toxicity typically manifests with substernal heaviness, pleuritic chest pain, and cough/dyspnea within 24 hours after breathing pure oxygen.

(Choice C) In patients with hypercapnia and respiratory acidosis, the kidneys compensate by increasing bicarbonate reabsorption and normalizing the serum pH level. This response occurs slowly over several days and would tend to ameliorate the effects of hypercapnia.

(Choice D) Peripheral chemoreceptors in the carotid and aortic bodies sense arterial PaO_2 and are normally stimulated by hypoxemia. High-flow oxygen reduces chemoreceptor stimulation, resulting in a decreased (not increased) respiratory rate and minute ventilation.

Educational objective:

https://t.me/USMLEWorldStep1

muscle use, smoking history) is consistent with a **chronic obstructive pulmonary disease (COPD) exacerbation**. Supplemental oxygen may be warranted in patients with COPD who have significant hypoxemia; however, administration of excessively high oxygen concentrations can lead to increased CO_2 retention (**oxygen-induced hypercapnia**), resulting in confusion and a depressed level of consciousness (eg, lethargy).

Several mechanisms contribute to oxygen-induced hypercapnia, but the major cause is increased **ventilation-perfusion mismatch**. Hypoxia causes vasoconstriction of the pulmonary arterioles, which acts to shunt blood toward alveoli with the highest ventilation, thereby minimizing physiologic dead space. Providing high-concentration supplemental oxygen allows lung regions with relatively poor ventilation to have higher oxygen levels, **reversing pulmonary vasoconstriction**. The redistribution of blood flow away from well-ventilated alveoli leads to an **increase in physiologic dead space** (well-ventilated alveoli are less perfused) with a corresponding reduction in CO_2 excretion.

(Choice A) Oxygen administration alleviates hypoxic pulmonary vasoconstriction, causing an overall decrease in pulmonary vascular resistance.

(Choice B) Hyperoxia can increase production of reactive oxygen species (eg, superoxide, hydroxyl radical, hydrogen peroxide), leading to injury of the airways and lung parenchyma. Oxygen toxicity typically manifests with substernal heaviness, pleuritic chest pain, and cough/dyspnea within 24 hours after breathing pure oxygen.

(Choice C) In patients with hypercapnia and respiratory acidosis, the kidneys compensate by increasing bicarbonate reabsorption and normalizing the serum pH level. This response occurs slowly over several days and would tend to ameliorate the effects of hypercapnia.

(Choice D) Peripheral chemoreceptors in the carotid and aortic bodies sense arterial PaO_2 and are normally stimulated by hypoxemia. High-flow oxygen reduces chemoreceptor stimulation, resulting in a decreased (not increased) respiratory rate and minute ventilation.

Educational objective:
Supplemental oxygen administration in patients with chronic obstructive pulmonary disease can lead to increased CO_2 retention (oxygen-induced hypercapnia), resulting in confusion and depressed consciousness. The major cause is reversal of hypoxic pulmonary vasoconstriction, which increases physiologic dead space as blood is shunted away from well-ventilated alveoli.

https://t.me/USMLEWorldStep1

A 62-year-old man comes to the emergency department due to a 2-week history of worsening shortness of breath. The patient reports feeling dyspneic while lying flat and has been sleeping upright in his recliner. Temperature is 36.7 C (98.1 F), blood pressure is 110/70 mm Hg, pulse is 88/min, and respirations are 20/min. On physical examination, jugular venous distension is present. Heart sounds are normal. Decreased breath sounds and dullness to percussion can be heard at the bilateral bases. Pitting edema is present in the bilateral lower extremities. Chest x-ray shows cardiomegaly and bilateral pleural effusions. Serum protein is 6 g/dL and serum lactate dehydrogenase (LDH) is 60 U/L. Which of the following sets of pleural fluid findings is most likely to be seen in this patient?

	Protein (g/dL)	LDH (U/L)	Glucose (mg/dL)	Total nucleated cell count (per mm^3)
○ A.	2	30	90	500
○ B.	2	90	10	10,000
○ C.	2	90	90	500
○ D.	4	90	10	10,000
○ E.	4	30	90	500

Submit

https://t.me/USMLEWorldStep1

A 62-year-old man comes to the emergency department due to a 2-week history of worsening shortness of breath. The patient reports feeling dyspneic while lying flat and has been sleeping upright in his recliner. Temperature is 36.7 C (98.1 F), blood pressure is 110/70 mm Hg, pulse is 88/min, and respirations are 20/min. On physical examination, jugular venous distension is present. Heart sounds are normal. Decreased breath sounds and dullness to percussion can be heard at the bilateral bases. Pitting edema is present in the bilateral lower extremities. Chest x-ray shows cardiomegaly and bilateral pleural effusions. Serum protein is 6 g/dL and serum lactate dehydrogenase (LDH) is 60 U/L. Which of the following sets of pleural fluid findings is most likely to be seen in this patient?

	Protein (g/dL)	LDH (U/L)	Glucose (mg/dL)	Total nucleated cell count (per mm^3)	
✓ A.	2	30	90	500	(60%)
B.	2	90	10	10,000	(6%)
C.	2	90	90	500	(14%)
D.	4	90	10	10,000	(8%)
E.	4	30	90	500	(9%)

Correct

60% Answered correctly

08 secs Time Spent

2023 Version

Explanation

Exudative & transudative pleural effusions		
	Exudate	Transudate

https://t.me/USMLEWorldStep1

Exudative & transudative pleural effusions		
	Exudate	**Transudate**
Light criteria	Pleural protein/serum protein >0.5 **OR** Pleural LDH/serum LDH >0.6 **OR** Pleural LDH greater than two-thirds upper limit of normal of serum LDH	Exudate criteria not met
Pathophysiology	Inflammatory increase in membrane permeability	Change in hydrostatic or oncotic pressure
Common causes	• Infection (eg, pneumonia, TB) • Malignancy • Rheumatologic disease	• Heart failure • Cirrhosis (hepatic hydrothorax) • Nephrotic syndrome
LDH = lactate dehydrogenase; **TB** = tuberculosis.		

This patient with dyspnea, orthopnea, jugular venous distension, and lower extremity swelling likely has an acute **heart failure** exacerbation. Heart failure commonly leads to **pleural effusion** due to poor forward blood flow from the left ventricle and a subsequent **increase in** pulmonary venous and **pulmonary capillary hydrostatic pressure**. Pleural effusions that result from such pressure changes are typically transudative, whereas those that result from an inflammatory increase in vascular membrane permeability are typically exudative.

Because transudative and exudative pleural effusions have differing underlying causes, they also tend to differ in chemical makeup. The Light criteria are used to differentiate the 2 types via analysis of the **total protein** and

https://t.me/USMLEWorldStep1

LDH = lactate dehydrogenase; **TB** = tuberculosis.

This patient with dyspnea, orthopnea, jugular venous distension, and lower extremity swelling likely has an acute **heart failure** exacerbation. Heart failure commonly leads to **pleural effusion** due to poor forward blood flow from the left ventricle and a subsequent **increase in** pulmonary venous and **pulmonary capillary hydrostatic pressure**. Pleural effusions that result from such pressure changes are typically transudative, whereas those that result from an inflammatory increase in vascular membrane permeability are typically exudative.

Because transudative and exudative pleural effusions have differing underlying causes, they also tend to differ in chemical makeup. The Light criteria are used to differentiate the 2 types via analysis of the **total protein** and **lactate dehydrogenase** (LDH) levels. Exudative effusions have a high pleural fluid/serum ratio of these proteins due to increased capillary permeability, while **transudative effusions** are associated with a **low pleural fluid/serum ratio**.

Glucose levels and leukocyte counts can suggest the degree of inflammation in a pleural effusion. Because leukocytes metabolize glucose, highly inflammatory effusions typically have low glucose levels. Transudative effusions are not inflammatory and almost always have low nucleated cell counts and normal (or high) glucose levels.

(Choices B and D) These effusions meet Light criteria for an exudate. The low glucose levels (<60 mg/dL) suggest consumption of glucose by an abundance of metabolically active cells, as can occur with highly inflammatory exudative effusions resulting from bacterial infection, malignancy, or rheumatologic disease.

(Choices C and E) These effusions meet Light criteria for an exudate. The normal glucose levels and low cell counts suggest a relatively low-inflammation exudative effusion such as an uncomplicated parapneumonic effusion or effusion due to pulmonary embolism.

Educational objective:
Transudative pleural effusions result from increased intracapillary pressure (eg, heart failure) and exudative effusions develop from inflammatory disruption of the vascular membrane. Transudative pleural effusions have low fluid/serum ratios of total protein and lactate dehydrogenase and low absolute levels of lactate dehydrogenase compared to exudative effusions.

https://t.me/USMLEWorldStep1

A 36-year-old man comes to the office due to chronic, mild dyspnea and fatigue. The patient also says that his mind seems "foggy" all the time and he is not able to think clearly. He has no significant past medical history and does not take any medication. He lives a sedentary lifestyle and has smoked a half-pack of cigarettes a day for 5 years. Blood pressure is 140/85 mm Hg, pulse is 84/min, and respirations are 18/min. BMI is 32 kg/m^2. Lung auscultation is unremarkable. Chest x-ray is normal. Arterial blood gas analysis shows partial pressure of oxygen (PaO_2) is 66 mm Hg and partial pressure of carbon dioxide ($PaCO_2$) is 58 mm Hg. His estimated alveolar to arterial oxygen gradient is 10 mm Hg. Which of the following best explains this patient's laboratory findings?

- A. Chronic hypoventilation
- B. Decreased lung diffusing capacity
- C. Destruction of lung parenchyma
- D. Increased lung compliance
- E. Increased tissue oxygen consumption
- F. Right-to-left shunt

Submit

https://t.me/USMLEWorldStep1

A 36-year-old man comes to the office due to chronic, mild dyspnea and fatigue. The patient also says that his mind seems "foggy" all the time and he is not able to think clearly. He has no significant past medical history and does not take any medication. He lives a sedentary lifestyle and has smoked a half-pack of cigarettes a day for 5 years. Blood pressure is 140/85 mm Hg, pulse is 84/min, and respirations are 18/min. BMI is 32 kg/m^2. Lung auscultation is unremarkable. Chest x-ray is normal. Arterial blood gas analysis shows partial pressure of oxygen (PaO_2) is 66 mm Hg and partial pressure of carbon dioxide ($PaCO_2$) is 58 mm Hg. His estimated alveolar to arterial oxygen gradient is 10 mm Hg. Which of the following best explains this patient's laboratory findings?

- ✓ A. Chronic hypoventilation (64%)
- ✗ B. Decreased lung diffusing capacity (18%)
- C. Destruction of lung parenchyma (6%)
- D. Increased lung compliance (4%)
- E. Increased tissue oxygen consumption (1%)
- F. Right-to-left shunt (5%)

Incorrect
Correct answer
A

64%
Answered correctly

06 secs
Time Spent

2023
Version

Explanation

Causes of hypoxemia		
	Examples	**A-a gradient**
Reduced PiO_2	High altitude	Normal
Hypoventilation	CNS depression, morbid obesity	Normal

https://t.me/USMLEWorldStep1

Causes of hypoxemia		
	Examples	**A-a gradient**
Reduced PiO_2	High altitude	Normal
Hypoventilation	CNS depression, morbid obesity	Normal
Diffusion limitation	Emphysema, ILD	Increased
V/Q mismatch*	Pulmonary embolism, pneumonia	Increased

*Caused by regional dead-space ventilation and/or intrapulmonary shunting.
A-a gradient = alveolar to arterial oxygen gradient; **ILD** = interstitial lung disease; **PiO_2** = partial pressure of inspired oxygen; **V/Q** = ventilation/perfusion ratio.

This patient with chronic fatigue, dyspnea, difficulty concentrating, **hypoxemia** (PaO_2 <75 mm Hg), and **hypercapnia** ($PaCO_2$ >45 mm Hg) in the setting of **obesity** (BMI >30 kg/m^2) likely has **obesity hypoventilation syndrome** (OHS). OHS results from physical restriction of lung expansion by excessive thoracic tissue mass. As such, the hypoventilation mostly results from **reduced tidal volume** and patients may have normal or increased respiratory rate. Most patients with OHS also have concomitant obstructive sleep apnea (OSA); unlike isolated OSA that involves hypoventilation only with sleep, OHS involves hypoventilation throughout the waking hours.

In healthy individuals, a normal alveolar to arterial (A-a) gradient ranges from 4-15 mm Hg, with older individuals having a gradient towards the higher end of normal. A **normal A-a gradient** indicates that the efficiency of gas exchange between the alveoli and the blood is intact; therefore, hypoxemia must result from low partial pressure of alveolar oxygen (PAO_2). Low PAO_2 can occur due to **alveolar hypoventilation** (eg, OHS, neuromuscular disease, central depression of respiratory drive) or inspiration of low partial pressure of oxygen at high altitude.

(Choices B and C) Destruction of lung parenchyma occurs with both emphysema and interstitial lung disease. This leads to disruption of the alveolar-capillary membrane and impaired diffusion capacity with an increased A-a gradient. In OHS, the lung parenchyma is undamaged and diffusion capacity is intact.

(Choice D) Although the lung parenchyma is unaffected in OHS, restricted expansion of the chest wall secondarily

https://t.me/USMLEWorldStep1

This patient with chronic fatigue, dyspnea, difficulty concentrating, **hypoxemia** (PaO_2 <75 mm Hg), and **hypercapnia** ($PaCO_2$ >45 mm Hg) in the setting of **obesity** (BMI >30 kg/m^2) likely has **obesity hypoventilation syndrome** (OHS). OHS results from physical restriction of lung expansion by excessive thoracic tissue mass. As such, the hypoventilation mostly results from **reduced tidal volume** and patients may have normal or increased respiratory rate. Most patients with OHS also have concomitant obstructive sleep apnea (OSA); unlike isolated OSA that involves hypoventilation only with sleep, OHS involves hypoventilation throughout the waking hours.

In healthy individuals, a normal alveolar to arterial (A-a) gradient ranges from 4-15 mm Hg, with older individuals having a gradient towards the higher end of normal. A **normal A-a gradient** indicates that the efficiency of gas exchange between the alveoli and the blood is intact; therefore, hypoxemia must result from low partial pressure of alveolar oxygen (PAO_2). Low PAO_2 can occur due to **alveolar hypoventilation** (eg, OHS, neuromuscular disease, central depression of respiratory drive) or inspiration of low partial pressure of oxygen at high altitude.

(Choices B and C) Destruction of lung parenchyma occurs with both emphysema and interstitial lung disease. This leads to disruption of the alveolar-capillary membrane and impaired diffusion capacity with an increased A-a gradient. In OHS, the lung parenchyma is undamaged and diffusion capacity is intact.

(Choice D) Although the lung parenchyma is unaffected in OHS, restricted expansion of the chest wall secondarily restricts lung expansion, effectively decreasing lung compliance.

(Choice E) Tissue oxygen consumption does increase with increased body mass, but it is a relatively minor factor and would not cause hypoxemia or hypercapnia in the absence of hypoventilation.

(Choice F) Right-to-left shunting (eg, Eisenmenger syndrome) results in hypoxemia with an elevated A-a gradient because a large percentage of cardiac output bypasses the alveolar capillaries and does not undergo gas exchange.

Educational objective:
Obesity hypoventilation syndrome commonly presents with chronic fatigue, dyspnea, and difficulty concentrating. Patients will have BMI >30 kg/m^2 and arterial blood gas while awake showing evidence of hypoventilation, including hypercapnia ($PaCO_2$ >45 mm Hg) and usually hypoxemia (PaO_2 <75 mm Hg). The expected alveolar to arterial oxygen gradient is normal (4-15 mm Hg) with hypoventilation.

https://t.me/USMLEWorldStep1

A 36-year-old woman comes to the office due to dyspnea and weakness that are brought on while doing ordinary chores around the house. The patient has no other medical conditions and takes no medications. She does not use tobacco, alcohol, or illicit drugs. Her mother had similar symptoms and died at age 42. After an extensive workup, a lung biopsy is performed. Light microscopy of the tissue sample shows medial hypertrophy, intimal fibrosis, and decreased intraluminal diameter of the small branches of the pulmonary artery. Which of the following is the most appropriate pharmacotherapy for this patient's current condition?

- A. Bosentan
- B. Clopidogrel
- C. Enalapril
- D. Etanercept
- E. Indomethacin

Submit

https://t.me/USMLEWorldStep1

A 36-year-old woman comes to the office due to dyspnea and weakness that are brought on while doing ordinary chores around the house. The patient has no other medical conditions and takes no medications. She does not use tobacco, alcohol, or illicit drugs. Her mother had similar symptoms and died at age 42. After an extensive workup, a lung biopsy is performed. Light microscopy of the tissue sample shows medial hypertrophy, intimal fibrosis, and decreased intraluminal diameter of the small branches of the pulmonary artery. Which of the following is the most appropriate pharmacotherapy for this patient's current condition?

- ✓ A. Bosentan (74%)
- B. Clopidogrel (5%)
- C. Enalapril (6%)
- D. Etanercept (7%)
- E. Indomethacin (6%)

Correct

74% Answered correctly

06 secs Time Spent

2023 Version

Explanation

Pathogenesis of pulmonary arterial hypertension

https://t.me/USMLEWorldStep1

Exhibit Display

Pathogenesis of pulmonary arterial hypertension

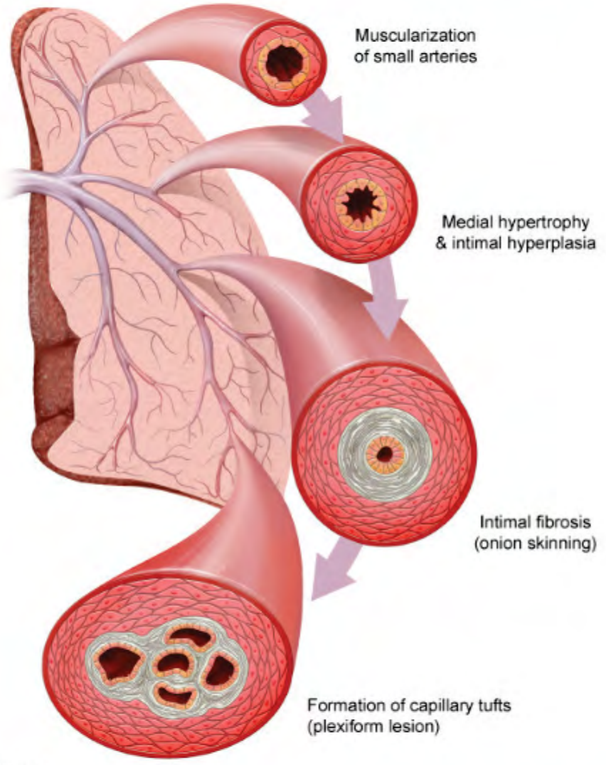

©UWorld

Zoom In | Zoom Out | Reset | New | Existing | My Notebook

https://t.me/USMLEWorldStep1

Pulmonary hypertension causes specific morphologic findings in the branches of the pulmonary arteries, including increased arteriolar smooth muscle thickness (**medial hypertrophy**), **intimal fibrosis**, and significant **luminal narrowing**. In the setting of severe hypertension, lesions can progress to form interlacing tufts of small vascular channels called **plexiform lesions**. These changes can occur in both pulmonary hypertension due to underlying cardiac, lung, or thrombotic disease and in pulmonary arterial hypertension (PAH).

PAH most commonly presents as dyspnea and exercise intolerance in women age 20-40. This patient's family history is suggestive of the familial form of PAH, which is most often caused by inactivating mutations involving the proapoptotic *BMPR2* gene. The resulting increase in endothelial and smooth muscle cell proliferation leads to vascular remodeling, elevated pulmonary vascular resistance, and progressively elevated pulmonary arterial pressure.

Although lung transplantation is the definitive treatment for PAH, medical therapy targeting the effects of endothelial dysfunction can help improve symptoms. **Bosentan** is an **endothelin-receptor antagonist** that blocks the effects of endothelin (a potent vasoconstrictor that also stimulates endothelial proliferation). Bosentan therapy decreases pulmonary arterial pressure and lessens the progression of vascular remodeling and right ventricular hypertrophy.

(Choice B) Clopidogrel inhibits ADP-induced platelet aggregation. It is used in atherosclerotic cardiovascular disease and to prevent acute stent thrombosis following percutaneous coronary intervention.

(Choice C) Enalapril is an angiotensin-converting enzyme inhibitor. It is used for the treatment of congestive heart failure, hypertension, and diabetic nephropathy.

(Choice D) Etanercept inhibits tumor-necrosis factor (TNF) activity by competitively binding to TNF and preventing it from interacting with cell surface receptors. It is an anti-inflammatory agent used for the treatment of rheumatoid arthritis, psoriasis, and psoriatic arthritis.

(Choice E) Indomethacin is a nonselective cyclooxygenase inhibitor that suppresses prostaglandin synthesis. It is used as an anti-inflammatory agent and pain reliever.

Educational objective:
Pulmonary arterial hypertension (PAH) typically affects young women and can be familial. It is characterized by

https://t.me/USMLEWorldStep1

luminal narrowing. In the setting of severe hypertension, lesions can progress to form interlacing tufts of small vascular channels called **plexiform lesions**. These changes can occur in both pulmonary hypertension due to underlying cardiac, lung, or thrombotic disease and in pulmonary arterial hypertension (PAH).

PAH most commonly presents as dyspnea and exercise intolerance in women age 20-40. This patient's family history is suggestive of the familial form of PAH, which is most often caused by inactivating mutations involving the proapoptotic *BMPR2* gene. The resulting increase in endothelial and smooth muscle cell proliferation leads to vascular remodeling, elevated pulmonary vascular resistance, and progressively elevated pulmonary arterial pressure.

Although lung transplantation is the definitive treatment for PAH, medical therapy targeting the effects of endothelial dysfunction can help improve symptoms. **Bosentan** is an **endothelin-receptor antagonist** that blocks the effects of endothelin (a potent vasoconstrictor that also stimulates endothelial proliferation). Bosentan therapy decreases pulmonary arterial pressure and lessens the progression of vascular remodeling and right ventricular hypertrophy.

(Choice B) Clopidogrel inhibits ADP-induced platelet aggregation. It is used in atherosclerotic cardiovascular disease and to prevent acute stent thrombosis following percutaneous coronary intervention.

(Choice C) Enalapril is an angiotensin-converting enzyme inhibitor. It is used for the treatment of congestive heart failure, hypertension, and diabetic nephropathy.

(Choice D) Etanercept inhibits tumor-necrosis factor (TNF) activity by competitively binding to TNF and preventing it from interacting with cell surface receptors. It is an anti-inflammatory agent used for the treatment of rheumatoid arthritis, psoriasis, and psoriatic arthritis.

(Choice E) Indomethacin is a nonselective cyclooxygenase inhibitor that suppresses prostaglandin synthesis. It is used as an anti-inflammatory agent and pain reliever.

Educational objective:
Pulmonary arterial hypertension (PAH) typically affects young women and can be familial. It is characterized by luminal narrowing of the pulmonary arteries and arterioles, with medial hypertrophy, intimal fibrosis, and the eventual development of plexiform lesions. Bosentan is a competitive antagonist of endothelin receptors used for the treatment of PAH.

https://t.me/USMLEWorldStep1

Exhibit Display

Classification of pulmonary hypertension	

Pulmonary arterial hypertension (group 1)	• Primary change in pulmonary arteries
	  ◦ Hereditary (eg, *BMPR2* mutation)
	  ◦ Connective tissue disease (eg, RA, SS)
	  ◦ HIV infection
	• Treatment targeted at endothelial dysfunction

Pulmonary hypertension (groups 2-5)	• Secondary to another disease process
	  ◦ Left-sided heart failure (group 2)
	  ◦ Chronic lung disease/hypoxia (group 3)
	  ◦ Chronic pulmonary thromboembolism (group 4)
	  ◦ Other (eg, sarcoidosis) (group 5)
	• Treatment aimed at underlying disease

RA = rheumatoid arthritis; **SS** = systemic sclerosis.	

New | Existing | My Notebook

Pulmo
includi
lumin
vascul
underl

PAH m
history
proapo
vascul
pressu

Althou
endoth
the eff
decrea
hypert

(Choice B) Clopidogrel inhibits ADP-induced platelet aggregation. It is used in atherosclerotic cardiovascular disease and to prevent acute stent thrombosis following percutaneous coronary intervention.

https://t.me/USMLEWorldStep1

The following vignette applies to the next **2** items. The items in the set must be answered in sequential order. Once you click **Proceed to Next Item**, you will not be able to add or change an answer.

A 47-year-old man comes to the emergency department due to a 30-minute history of sudden-onset severe chest pain and shortness of breath. He is on an RV road trip with his family and has had pain in and swelling of the left leg for the past 2 days. The patient has no significant medical history and takes no medications. Temperature is 37.2 C (99 F), blood pressure is 90/56 mm Hg, pulse is 124/min, and respirations are 32/min. Oxygen saturation is 82% on room air. BMI is 36 kg/m^2. ECG shows sinus tachycardia. Chest x-ray shows no abnormalities.

Item 1 of 2

Which of the following is most likely increased in this patient?

- A. Functional residual capacity
- B. Lung diffusion capacity
- C. Physiologic dead space
- D. Pulmonary compliance
- E. Total airway resistance

Submit

https://t.me/USMLEWorldStep1

Item 2 of 2

During evaluation, the patient becomes unresponsive and develops cardiac arrest with pulseless electrical activity. Cardiopulmonary resuscitation and intubation are performed, and the patient is placed on a mechanical ventilator. Once stabilized, he is admitted to the intensive care unit, and appropriate treatment is administered. Several days later, a spontaneous-breathing trial is performed to determine readiness to wean off the ventilator. After the mechanical ventilator settings are adjusted, the following changes are noted as reflected on the graph below. Dead space ventilation is shaded in black.

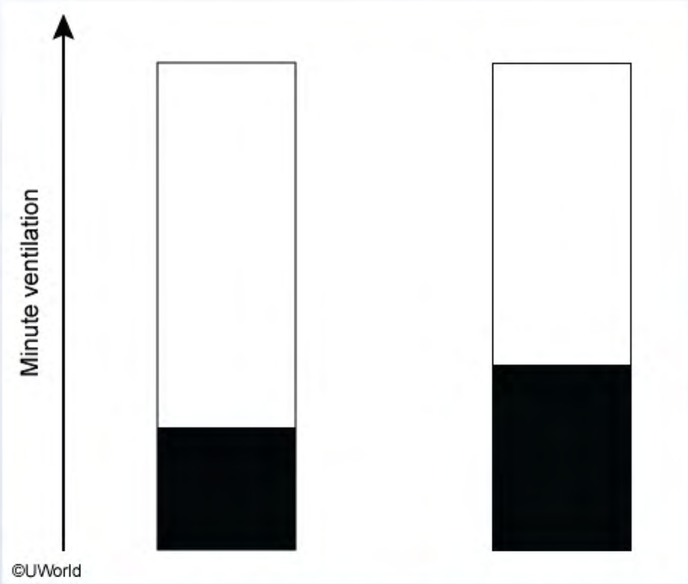

Which of the following breathing patterns most likely contributed to this patient's change from the left bar to the right on the graph above?

	Respiratory Rate	Tidal Volume
○ A.	↑	↑

https://t.me/USMLEWorldStep1

Dead space ventilation is shaded in black.

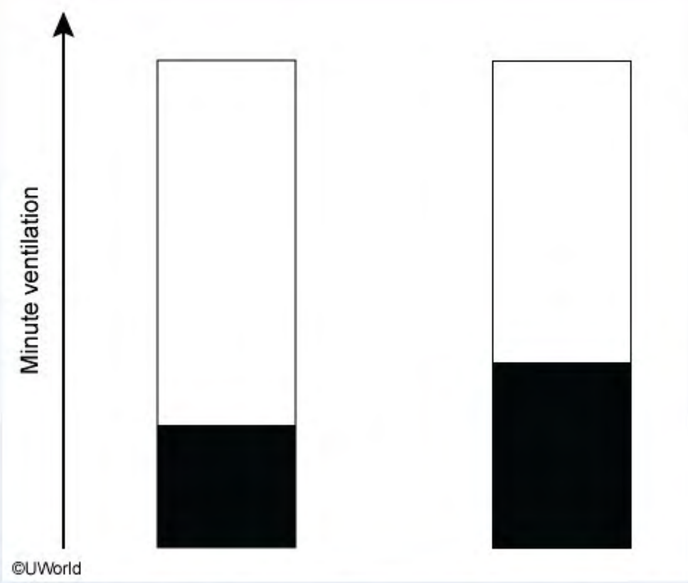

Which of the following breathing patterns most likely contributed to this patient's change from the left bar to the right on the graph above?

	Respiratory Rate	Tidal Volume
A.	↑	↑
B.	↑	↓
C.	↓	↑
D.	↓	↓

Submit

https://t.me/USMLEWorldStep1

The following vignette applies to the next **2** items. The items in the set must be answered in sequential order. Once you click **Proceed to Next Item**, you will not be able to add or change an answer.

A 47-year-old man comes to the emergency department due to a 30-minute history of sudden-onset severe chest pain and shortness of breath. He is on an RV road trip with his family and has had pain in and swelling of the left leg for the past 2 days. The patient has no significant medical history and takes no medications. Temperature is 37.2 C (99 F), blood pressure is 90/56 mm Hg, pulse is 124/min, and respirations are 32/min. Oxygen saturation is 82% on room air. BMI is 36 kg/m^2. ECG shows sinus tachycardia. Chest x-ray shows no abnormalities.

Item 1 of 2

Which of the following is most likely increased in this patient?

- A. Functional residual capacity (2%)
- ✗ B. Lung diffusion capacity (3%)
- ✓ C. Physiologic dead space (83%)
- D. Pulmonary compliance (1%)
- E. Total airway resistance (9%)

Incorrect
Correct answer
C

83%
Answered correctly

07 secs
Time Spent

2023
Version

Explanation

Pulmonary embolism

https://t.me/USMLEWorldStep1

E. Total airway resistance (9%)

Exhibit Display

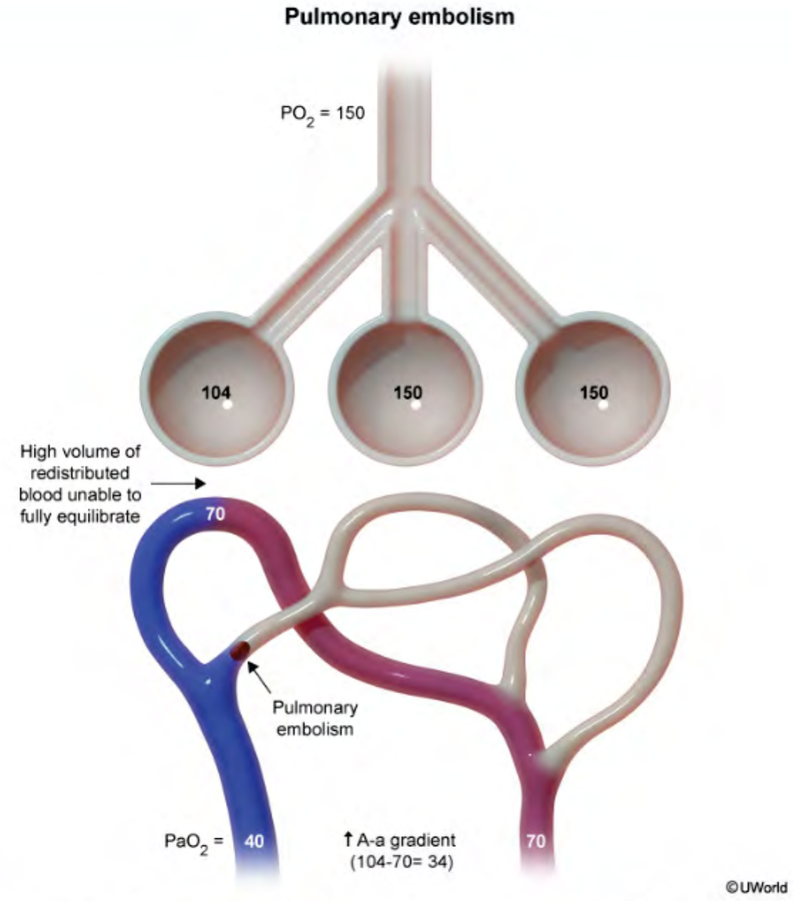

Zoom In | Zoom Out | Reset | New | Existing | My Notebook

https://t.me/USMLEWorldStep1

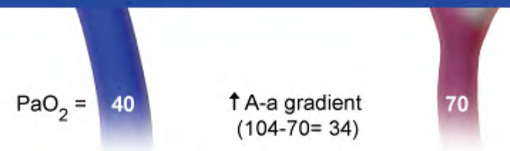

©UWorld

This patient has developed a deep venous thrombosis in his left leg following a lengthy car trip and now has clinical features highly consistent with acute **pulmonary embolism** (PE). Obstruction of the pulmonary circulation by an embolus causes **increased dead space ventilation** (ie, alveoli are ventilated but not perfused); the term "dead space" refers to the volume of inspired air that does not participate in gas exchange. As dead space ventilation increases, blood that continues to flow through the pulmonary circulation cannot be fully oxygenated by the decreased number of accessible alveoli (**ventilation/perfusion (V/Q) mismatch**), leading to **hypoxemia**.

(Choice A) Functional residual capacity refers to the volume of air remaining in the lungs after a normal expiration. It is increased in chronic obstructive pulmonary disease (COPD) due to air trapping; however, it is unchanged in PE.

(Choice B) Diffusion capacity is reduced by conditions that disrupt the alveolar-capillary interface (eg, pulmonary fibrosis), but it is not altered in PE.

(Choice D) Pulmonary compliance (ability to expand) is reduced in restrictive lung disease (eg, pulmonary fibrosis) and is increased in COPD (due to emphysematous destruction of the distal airways). However, it is not significantly altered in the setting of PE.

(Choice E) Total airway resistance is increased by bronchoconstriction, which occurs in patients with asthma. PE does not affect airway resistance.

Educational objective:
Pulmonary embolism causes dead space ventilation, which leads to hypoxemia due to the consequent ventilation/perfusion mismatch.

Physiology	Pulmonary & Critical Care	Pulmonary embolism
Subject	System	Topic

Copyright © UWorld. All rights reserved.

https://t.me/USMLEWorldStep1

Dead space ventilation is shaded in black.

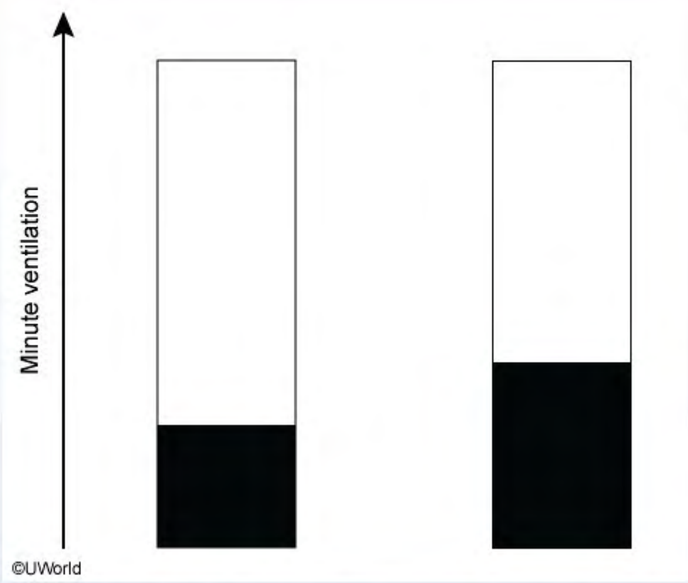

Which of the following breathing patterns most likely contributed to this patient's change from the left bar to the right on the graph above?

	Respiratory Rate	Tidal Volume	
A.	↑	↑	(13%)
✓ B.	↑	↓	(60%)
C.	↓	↑	(15%)
D.	↓	↓	(10%)

Correct

60%
Answered correctly

12 secs
Time Spent

2023
Version

https://t.me/USMLEWorldStep1

Explanation

Exhibit Display

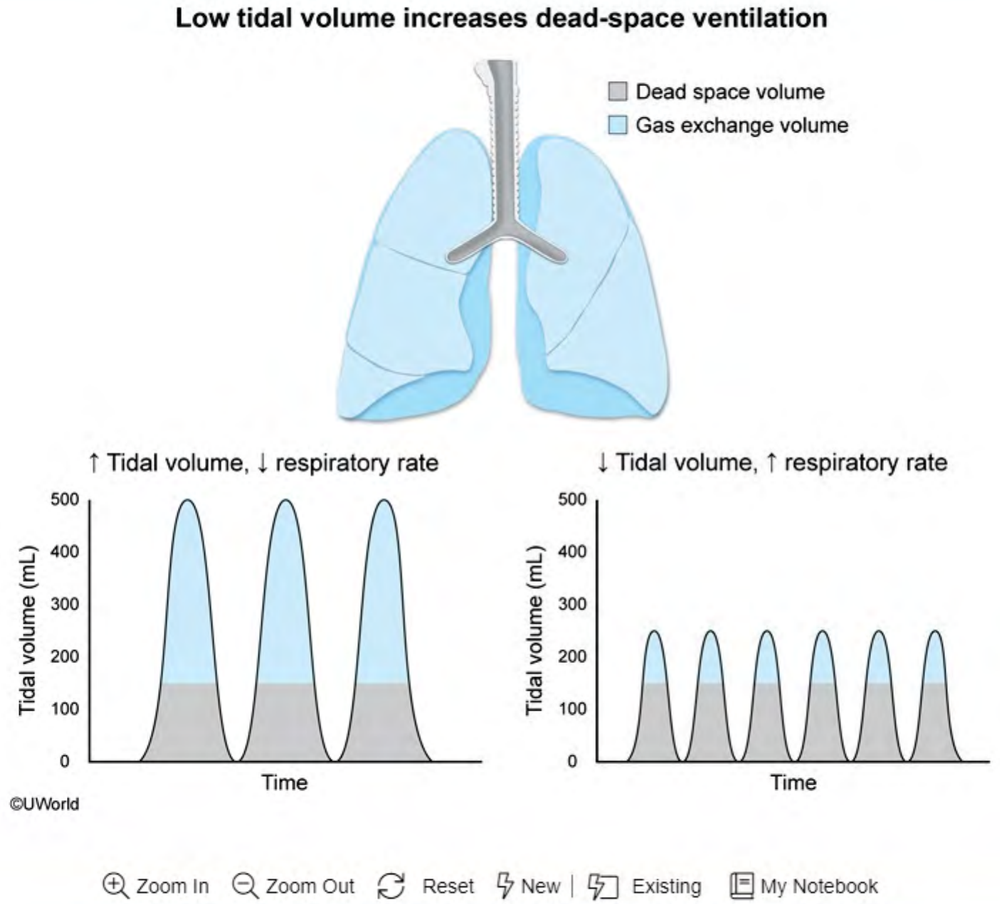

Physic
condu
partici
pulmo

Dead s
increase the proportion of each breath composed of dead space. If **minute ventilation** (tidal volume x respiratory

https://t.me/USMLEWorldStep1

©UWorld

Physiologic (total) dead space includes the anatomic dead space (the permanent volume of dead space within the conducting airways) plus the alveolar dead space (the volume of air in the respiratory zone that does not participate in gas exchange). Increases in physiologic dead space occur in many lung diseases, including pulmonary embolism, emphysema, and acute respiratory distress syndrome.

Dead space volume remains relatively constant on a minute-by-minute basis. However, **lower tidal volumes** increase the proportion of each breath composed of dead space. If **minute ventilation** (tidal volume x respiratory rate) is **unchanged**, the consequence of the low-tidal-volumes is an **increase in dead space ventilation** (inefficient breathing).

Patients undergoing **mechanical ventilation weaning** typically have weakened respiratory muscles and therefore tend to breathe at low tidal volumes to minimize the work of breathing. This hypoventilation triggers an increase in respiratory drive that **increases respiratory rate** to maintain minute ventilation. When patients are being weaned off the ventilator, the ratio of their respiratory rate/tidal volume, known as the rapid shallow breathing index (RSBI), is measured; a low RSBI indicates relatively high tidal volumes, relatively efficient breathing, and a lower likelihood of recurrent respiratory failure once ventilatory support is discontinued.

(Choice A) Increases in both respiratory rate and tidal volume result in increased minute ventilation. However, the graph shows that minute ventilation remains the same after ventilator adjustment.

(Choice C) A decrease in respiratory rate and an increase in tidal volume would keep minute ventilation constant; however, the total volume of dead-space air breathed each minute would decrease rather than increase.

(Choice D) Decreases in both respiratory rate and tidal volume would result in decreased, rather than constant, minute ventilation.

Educational objective:
Patients being weaned from mechanical ventilation typically breathe at low tidal volumes, with a compensatory increase in respiratory rate to maintain minute ventilation. Because at low tidal volumes a higher proportion of each breath is composed of dead space, this type of breathing leads to an increase in wasted ventilation (inefficient breathing).

https://t.me/USMLEWorldStep1

A 64-year-old man comes to the clinic due to several weeks of persistent cough, fever, and weight loss. He smokes a pack of cigarettes daily and drinks 10-12 beers on weekends. Chest x-ray reveals an infiltrate in the left upper lobe. The patient is prescribed broad-spectrum antibiotic therapy for both aspiration and community-acquired pneumonia, but his symptoms worsen despite taking the medication as prescribed. Sputum Gram stain does not reveal any organisms. Lung biopsy findings are shown in the image below:

Which of the following substances is most important for driving the development of this patient's observed microscopic lesion?

- A. C3a
- B. Fibroblast growth factor
- C. Granulocyte-macrophage colony-stimulating factor
- D. IL-4
- E. Interferon-alpha
- F. Interferon-gamma

Submit

https://t.me/USMLEWorldStep1

A 64-year-old man comes to the clinic due to several weeks of persistent cough, fever, and weight loss. He
smoke
upper
acquir
does r

Exhibit Display

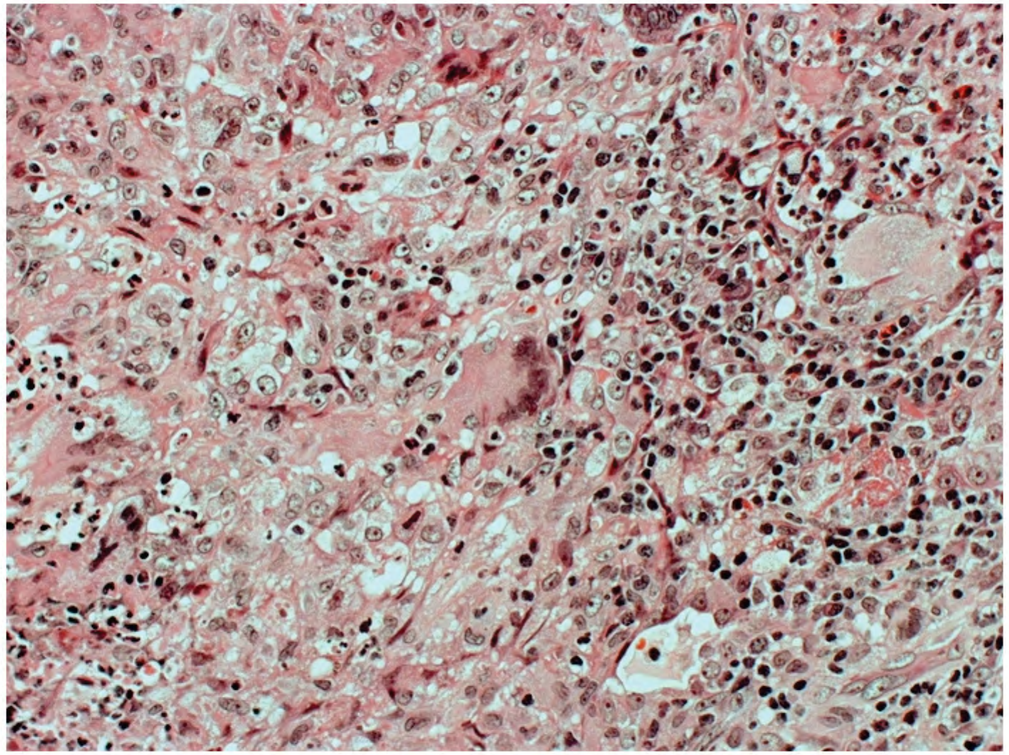

Zoom In | Zoom Out | Reset | New | Existing | My Notebook

Which
micros

B. Fibroblast growth factor

https://t.me/USMLEWorldStep1

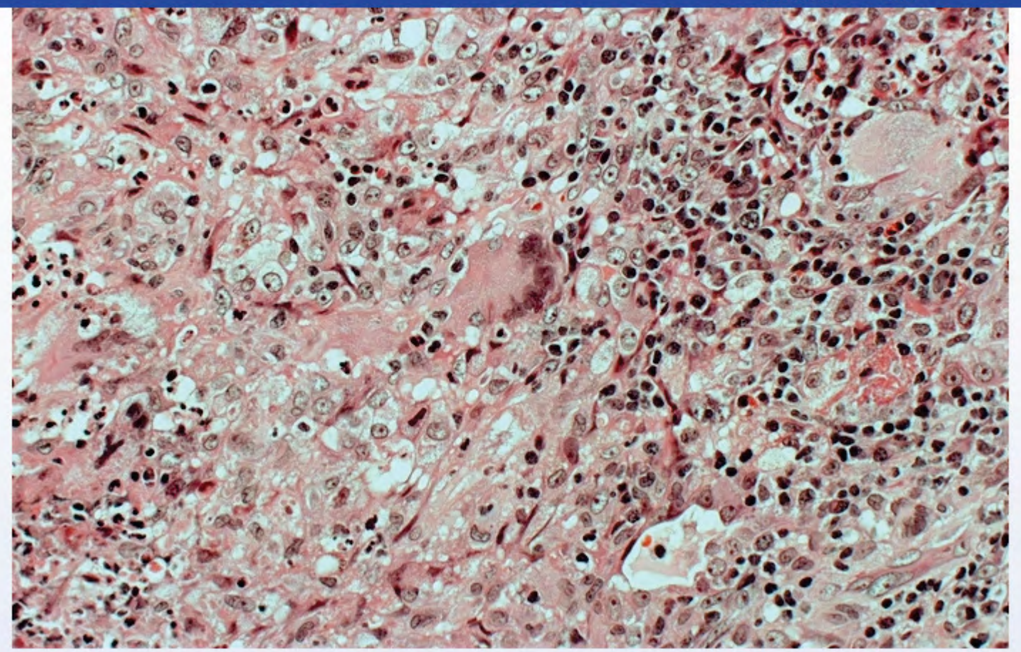

Which of the following substances is most important for driving the development of this patient's observed microscopic lesion?

- A. C3a
- B. Fibroblast growth factor
- C. Granulocyte-macrophage colony-stimulating factor
- D. IL-4
- E. Interferon-alpha
- F. Interferon-gamma

Submit

https://t.me/USMLEWorldStep1

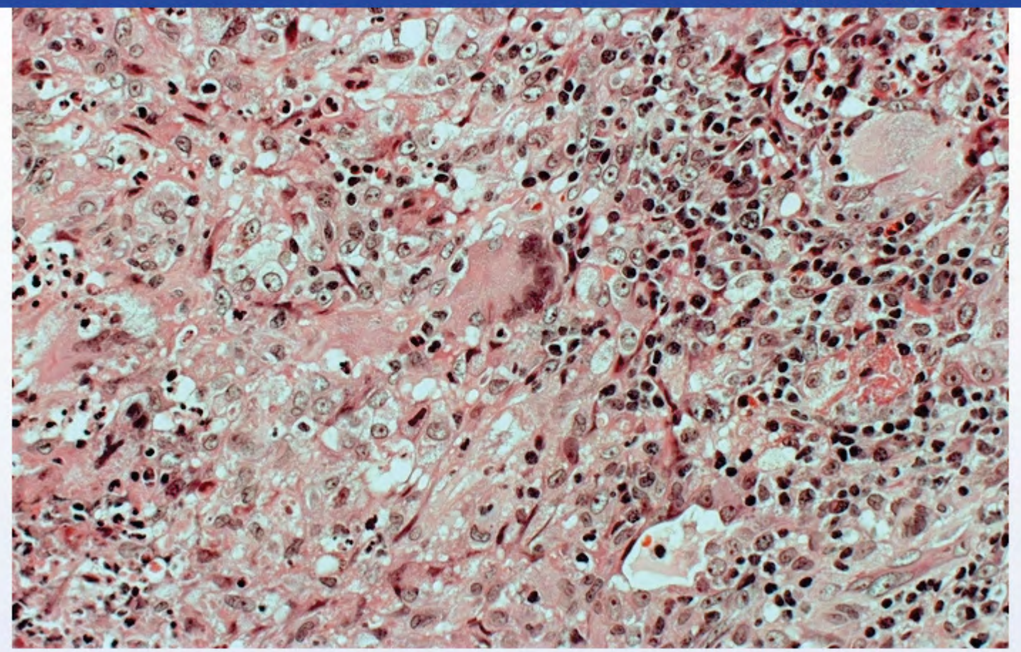

Which of the following substances is most important for driving the development of this patient's observed microscopic lesion?

- A. C3a (2%)
- ✗ B. Fibroblast growth factor (10%)
- C. Granulocyte-macrophage colony-stimulating factor (8%)
- D. IL-4 (3%)
- E. Interferon-alpha (5%)
- ✓ F. Interferon-gamma (69%)

Incorrect
Correct answer
F

69%
Answered correctly

13 secs
Time Spent

2023
Version

https://t.me/USMLEWorldStep1

E. Interferon-alpha (5%)

Exhibit Display

Granulomatous lung disease

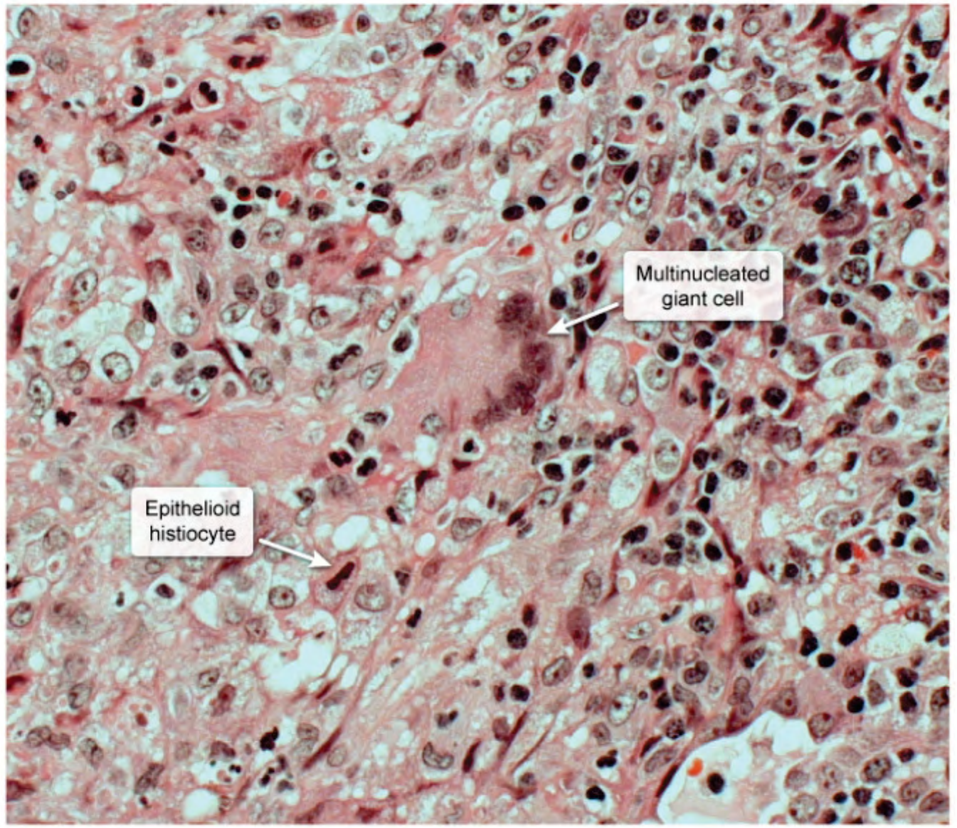

©UWorld

Zoom In | Zoom Out | Reset | New | Existing | My Notebook

https://t.me/USMLEWorldStep1

This patient has cough, fever, weight loss, and an upper lobe lesion on chest x-ray, raising strong suspicion for **active pulmonary tuberculosis**. *Mycobacterium tuberculosis* cannot be visualized on Gram stain due to the high lipid content (mycolic acid) of its cell wall. Most cases are diagnosed by acid-fast sputum testing and culture, but tissue microscopy typically shows granulomas characterized by **epithelioid histiocytes** and **multinucleated Langhans giant cells**.

Granulomas often form after tissue macrophages encounter pathogens or substances that cannot be easily digested or removed. *M tuberculosis* can evade intracellular killing by macrophages and reproduce within phagolysosomes. Infected macrophages present mycobacterial antigens to naïve CD4 helper T cells in pulmonary lymph nodes and secrete IL-12, which induces activated T helper cells to differentiate into **T helper subtype 1 (Th1) cells**.

Proliferating Th1 cells migrate to sites of infection, where they release **interferon-gamma**, which **activates macrophages**, improves intracellular killing of ingested mycobacteria, and recruits additional macrophages by increasing production of **tumor necrosis factor-alpha**. Activated macrophages can also limit the spread of mycobacteria by differentiating into epithelioid and giant cells that surround residual foci of mycobacteria, trapping them inside the necrotic, cheese-like area of a caseating granuloma.

(Choice A) C3a is a split product anaphylatoxin derived from C3. It stimulates the release of histamine by mast cells, which increases vascular permeability and vasodilation.

(Choice B) Fibroblast growth factor has a variety of proliferative effects, including stimulation of angiogenesis and fibroblast proliferation during formation of granulation tissue. It does not have a primary role in the formation of granulomas.

(Choice C) Granulocyte-macrophage colony-stimulating factor induces stem cell differentiation into monocytes and other granulocytes (eg, neutrophils, eosinophils). However, it does not induce granuloma formation.

(Choice D) IL-4 is a cytokine that stimulates the differentiation of naïve CD4 T cells into the Th2 subset, which plays an important role in humoral immunity and allergic reactions by stimulating B-cell proliferation and isotype switching to IgE.

(Choice E) Interferon-alpha is a primary mediator of the immune response to virus-infected cells. However, in

https://t.me/USMLEWorldStep1

Granulomas often form after tissue macrophages encounter pathogens or substances that cannot be easily digested or removed. *M tuberculosis* can evade intracellular killing by macrophages and reproduce within phagolysosomes. Infected macrophages present mycobacterial antigens to naïve CD4 helper T cells in pulmonary lymph nodes and secrete IL-12, which induces activated T helper cells to differentiate into **T helper subtype 1 (Th1) cells**.

Proliferating Th1 cells migrate to sites of infection, where they release **interferon-gamma**, which **activates macrophages**, improves intracellular killing of ingested mycobacteria, and recruits additional macrophages by increasing production of **tumor necrosis factor-alpha**. Activated macrophages can also limit the spread of mycobacteria by differentiating into epithelioid and giant cells that surround residual foci of mycobacteria, trapping them inside the necrotic, cheese-like area of a caseating granuloma.

(Choice A) C3a is a split product anaphylatoxin derived from C3. It stimulates the release of histamine by mast cells, which increases vascular permeability and vasodilation.

(Choice B) Fibroblast growth factor has a variety of proliferative effects, including stimulation of angiogenesis and fibroblast proliferation during formation of granulation tissue. It does not have a primary role in the formation of granulomas.

(Choice C) Granulocyte-macrophage colony-stimulating factor induces stem cell differentiation into monocytes and other granulocytes (eg, neutrophils, eosinophils). However, it does not induce granuloma formation.

(Choice D) IL-4 is a cytokine that stimulates the differentiation of naïve CD4 T cells into the Th2 subset, which plays an important role in humoral immunity and allergic reactions by stimulating B-cell proliferation and isotype switching to IgE.

(Choice E) Interferon-alpha is a primary mediator of the immune response to virus-infected cells. However, in contrast to interferon-gamma, it limits macrophage proliferation and does not drive granuloma formation.

Educational objective:
T helper subtype 1 cells release interferon-gamma, leading to the activation of macrophages, a process critical for control of *Mycobacterium tuberculosis* infection. Activated macrophages form mature phagolysosomes that destroy phagocytosed mycobacteria and can differentiate into epithelioid and Langhans giant cells to wall off extracellular mycobacteria within caseating granulomas.

https://t.me/USMLEWorldStep1

Exhibit Display

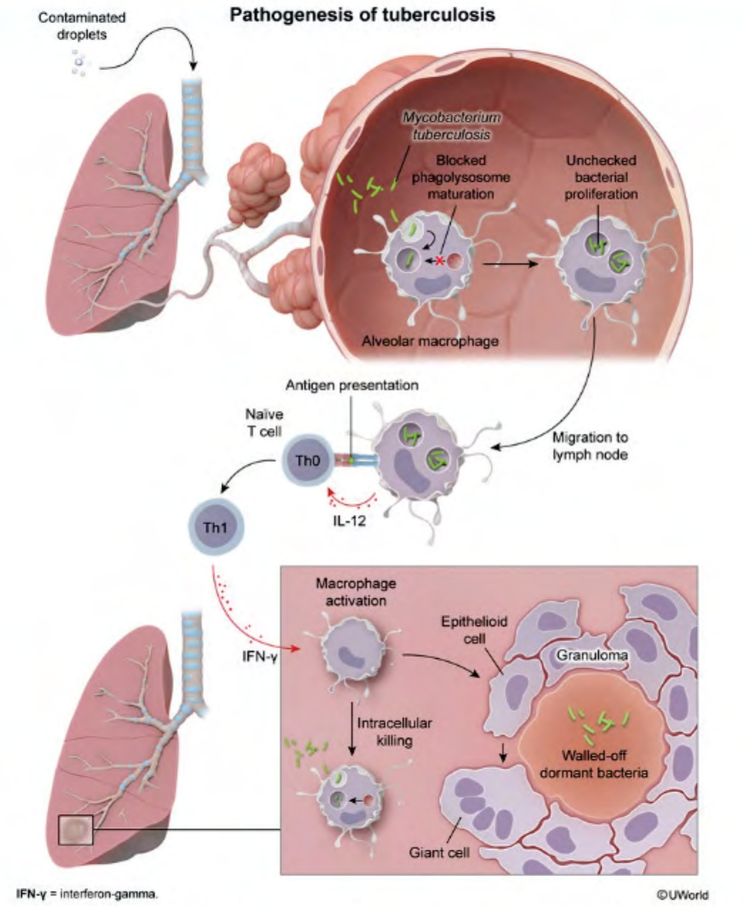

Zoom In | Zoom Out | Reset | New | Existing | My Notebook

This p
active
lipid c
tissue
Langh

Granu
digest
phago
lymph
(Th1)

Prolife
macro
increa
mycob
them i

(Choic
cells, v

(Choic
fibrobl
granul

(Choic
and other granulocytes (eg, neutrophils, eosinophils). However, it does not induce granuloma formation.

(Choice D) IL-4 is a cytokine that stimulates the differentiation of naïve CD4 T cells into the Th2 subset, which

https://t.me/USMLEWorldStep1

Exhibit Display

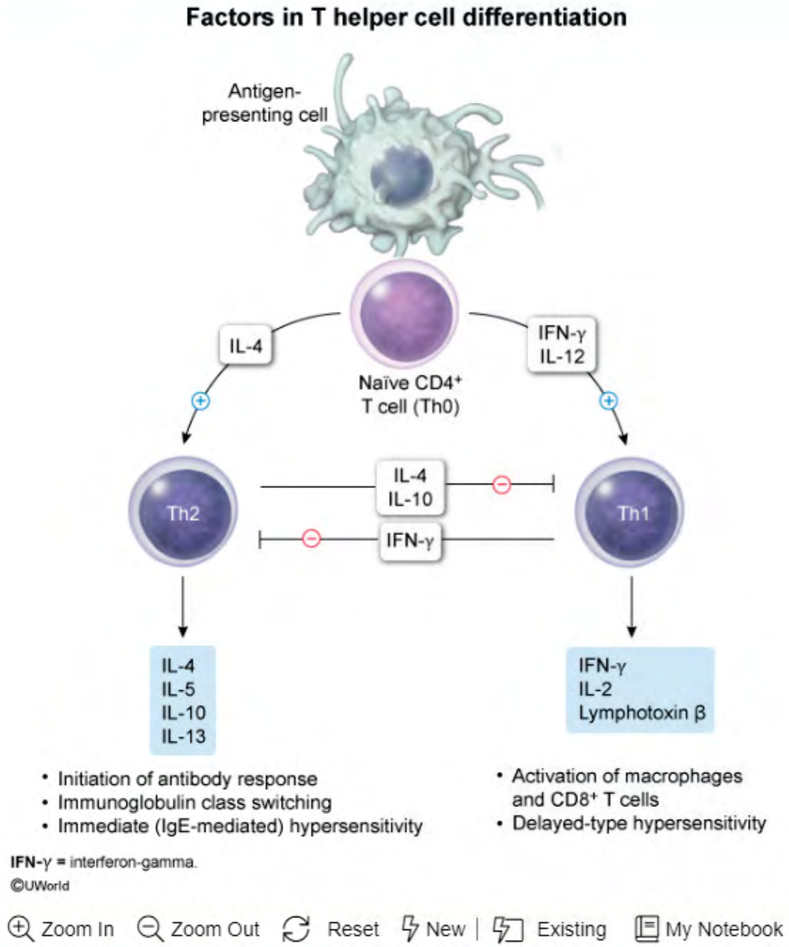

This p
active
lipid c
tissue
Langh

Granu
digest
phago
lymph
(Th1)

Prolife
macro
increa
mycob
them i

(Choic
cells, v

(Choic
fibrobl
granul

(Choic
and other granulocytes (eg, neutrophils, eosinophils). However, it does not induce granuloma formation.

(Choice D) IL-4 is a cytokine that stimulates the differentiation of naïve CD4 T cells into the Th2 subset, which

https://t.me/USMLEWorldStep1

Exhibit Display

Granulation tissue

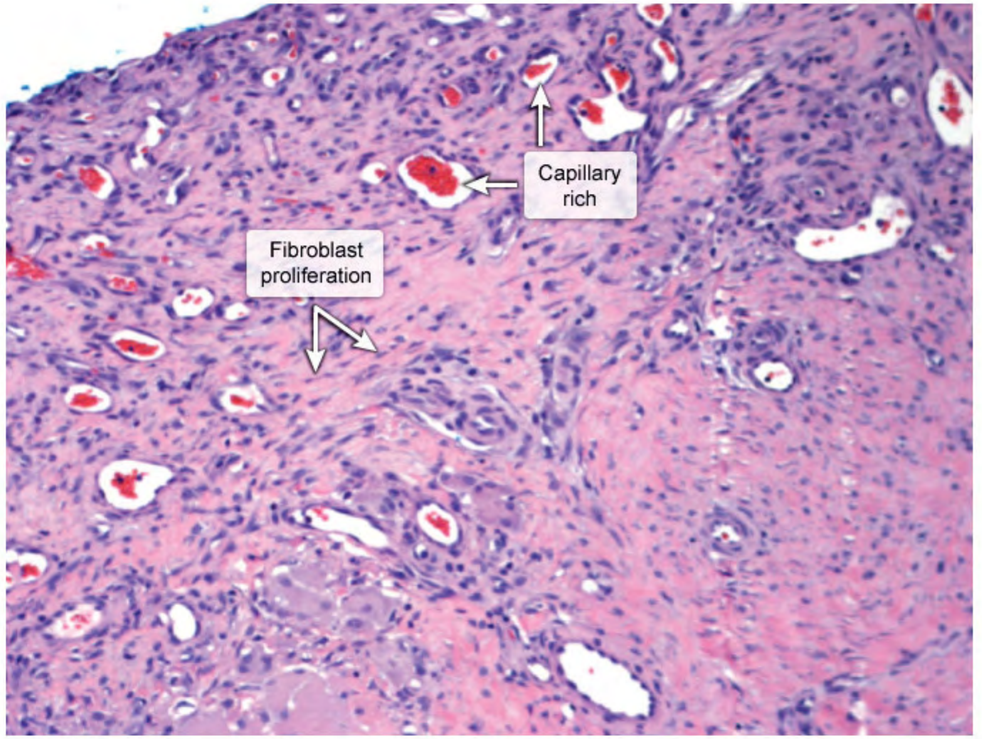

©UWorld

Zoom In | Zoom Out | Reset | New | Existing | My Notebook

This p
active
lipid c
tissue
Langh

Granu
digest
phago
lymph
(Th1)

Prolife
macro
increa
mycob
them i

(Choic
cells, v

(Choic
fibrobl
granul

(Choic
and other granulocytes (eg, neutrophils, eosinophils). However, it does not induce granuloma formation.

(Choice D) IL-4 is a cytokine that stimulates the differentiation of naïve CD4 T cells into the Th2 subset, which

https://t.me/USMLEWorldStep1

A 19-year-old man with a history of chronic lung problems dies due to respiratory distress after a prolonged episode of pneumonia. Autopsy shows dilation of the bronchial tree, which extends almost to the pleural surface. Many of the small airways are filled with mucin plugs containing abundant inflammatory cells and debris. Which of the following is the most likely cause of this patient's autopsy findings?

- A. Accumulation of proteinaceous material within the alveoli
- B. Antigen-mediated aggregation of macrophages
- C. Congenital deficiency of protease inhibitor
- D. Impaired clearance of airway secretions
- E. Increased pulmonary venous pressure

Submit

https://t.me/USMLEWorldStep1

A 19-year-old man with a history of chronic lung problems dies due to respiratory distress after a prolonged episode of pneumonia. Autopsy shows dilation of the bronchial tree, which extends almost to the pleural surface. Many of the small airways are filled with mucin plugs containing abundant inflammatory cells and debris. Which of the following is the most likely cause of this patient's autopsy findings?

- A. Accumulation of proteinaceous material within the alveoli (8%)
- ✗ B. Antigen-mediated aggregation of macrophages (3%)
- C. Congenital deficiency of protease inhibitor (14%)
- ✓ D. Impaired clearance of airway secretions (73%)
- E. Increased pulmonary venous pressure (0%)

Incorrect
Correct answer
D

73%
Answered correctly

08 secs
Time Spent

2023
Version

Explanation

Features of cystic fibrosis	
Pathogenesis	• Autosomal recessive mutation (**ΔF508**) impairs CFTR function • Decreased water content causes **thick, viscous mucus**: ◦ Chronic airway obstruction ◦ Gastrointestinal malabsorption
	• Chronic, productive cough • Recurrent **sinopulmonary infections**

https://t.me/USMLEWorldStep1

Features of cystic fibrosis	

Pathogenesis	• Autosomal recessive mutation (**ΔF508**) impairs CFTR function
	• Decreased water content causes **thick, viscous mucus**:
	  ◦ Chronic airway obstruction
	  ◦ Gastrointestinal malabsorption

Clinical manifestations	• Chronic, productive cough • Recurrent **sinopulmonary infections** (eg, *Staphylococcus aureus*, *Pseudomonas aeruginosa*, & *Burkholderia cepacia* complex) • **Pancreatic insufficiency** • Male infertility (bilateral absence of vas deferens)
Diagnosis	• Elevated sweat chloride levels • Nasal potential difference measurements • Genetic testing for *CFTR* mutations
CFTR = cystic fibrosis transmembrane conductance regulator.	

This patient with chronic lung problems has autopsy findings consistent with **cystic fibrosis** (CF), an autosomal recessive disorder caused by a genetic mutation (eg, ΔF508) affecting the CF transmembrane conductance regulator. A **defect** in this chloride channel prevents normal hydration of mucus and results in the accumulation of **thick, viscous secretions** throughout the body (eg, lungs, pancreas, vas deferens).

Respiratory disease, the most common CF manifestation, is the predominant cause of morbidity and mortality. Patients typically have **chronic cough** due to **impaired clearance** of inspissated secretions in the bronchioles.

https://t.me/USMLEWorldStep1

This patient with chronic lung problems has autopsy findings consistent with **cystic fibrosis** (CF), an autosomal recessive disorder caused by a genetic mutation (eg, ΔF508) affecting the CF transmembrane conductance regulator. A **defect** in this chloride channel prevents normal hydration of mucus and results in the accumulation of **thick, viscous secretions** throughout the body (eg, lungs, pancreas, vas deferens).

Respiratory disease, the most common CF manifestation, is the predominant cause of morbidity and mortality. Patients typically have **chronic cough** due to **impaired clearance** of inspissated secretions in the bronchioles. This buildup leads to **mucus plugging** (ie, obstructive lung disease), **bacterial colonization** (ie, recurrent pneumonia), and chronic infiltration of inflammatory cells. Over time, **elastase** produced by neutrophils causes **bronchiectasis** (weakened, dilated bronchial walls) and parenchymal destruction. Advanced disease is associated with irreversible damage, progressive respiratory failure, and shortened life expectancy.

(Choice A) Accumulation of proteinaceous material within alveoli occurs with pulmonary alveolar proteinosis, a condition in which clearance of surfactant by alveolar macrophages is impaired. Inflammatory cells are not present in this disorder.

(Choice B) Antigen-mediated aggregation of macrophages describes the formation of granulomas, as occurs with *Mycobacterium tuberculosis* and *Histoplasma capsulatum* infection. The inciting organism can usually be identified on microscopy and mucus plugs are not characteristically present.

(Choice C) Deficiency of alpha-1 antitrypsin (protease inhibitor of elastase) causes liver dysfunction, emphysema, and eventually bronchiectasis. The onset of pulmonary symptoms typically occurs at age >20, and mucus plugs would not be expected.

(Choice E) Increased pulmonary venous pressure is characteristic of left-sided heart failure, which results in pulmonary congestion and interstitial and alveolar edema. Bronchiectasis is not an associated finding.

Educational objective:
Cystic fibrosis is an autosomal recessive disorder in which a defective chloride channel causes impaired clearance of thick, viscous airway secretions. Patients typically develop a chronic cough, recurrent pulmonary infections, and bronchiectasis (dilated bronchial tree).

https://t.me/USMLEWorldStep1

This patient with chronic lung problems has autopsy findings consistent with **cystic fibrosis** (CF), an autosomal recess
regula
thick,

Respir
Patien
This b
pneum
bronc
associ

(Choic
conditi
in this

(Choic
with *M*
identifi

(Choic
and ev
would

(Choic
pulmo

Educa
Cystic
of thick, viscous airway secretions. Patients typically develop a chronic cough, recurrent pulmonary infections, and bronchiectasis (dilated bronchial tree).

Exhibit Display

Respiratory mucosa

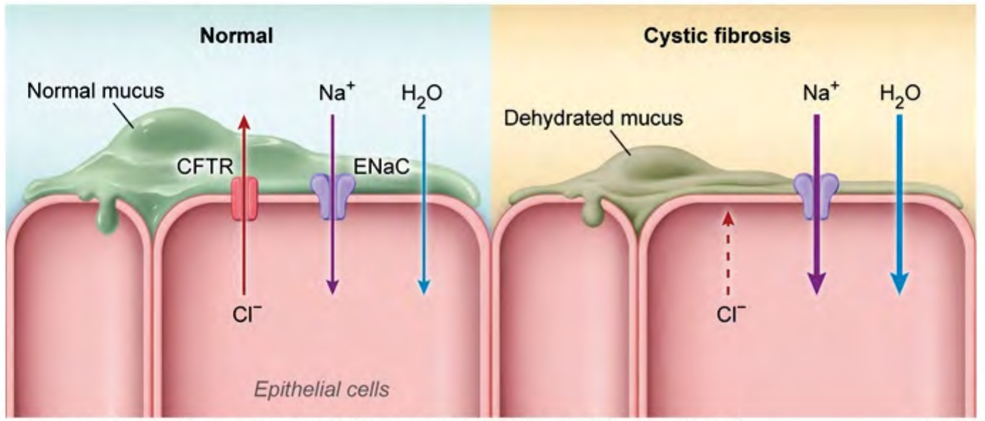

CFTR = cystic fibrosis transmembrane conductance regulator; **ENaC** = epithelial sodium channel. ©UWorld

Zoom In | Zoom Out | Reset | New | Existing | My Notebook

https://t.me/USMLEWorldStep1

This patient with chronic lung problems has autopsy findings consistent with **cystic fibrosis** (CF), an autosomal recess
regula
thick,

Respir
Patien
This b
pneum
bronc
associ

(Choic
conditi
in this

(Choic
with *M*
identifi

(Choic
and ev
would

(Choic
pulmo

Educa
Cystic
of thick, viscous airway secretions. Patients typically develop a chronic cough, recurrent pulmonary infections, and bronchiectasis (dilated bronchial tree).

Exhibit Display

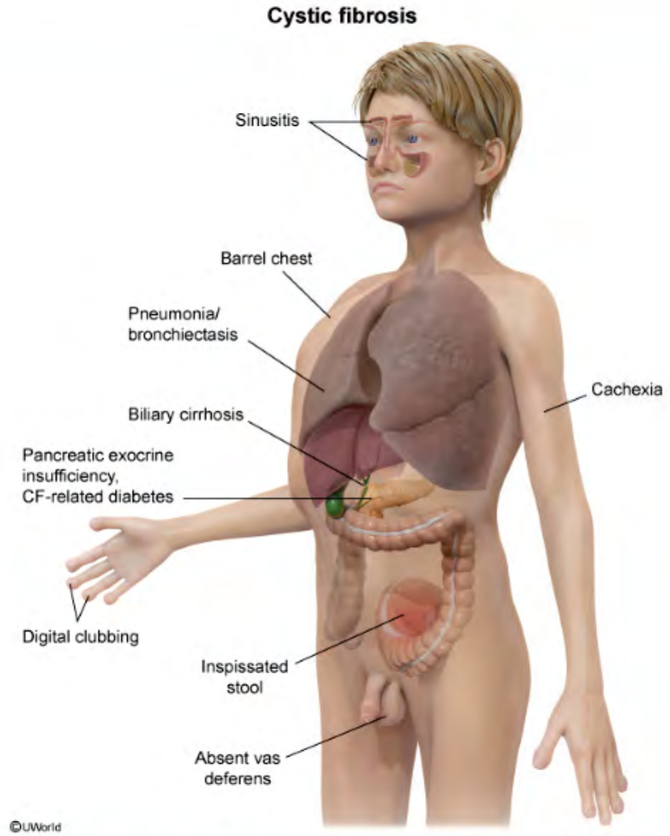

Zoom In Zoom Out Reset New | Existing My Notebook

https://t.me/USMLEWorldStep1

This patient with chronic lung problems has autopsy findings consistent with **cystic fibrosis** (CF), an autosomal recess
regula
thick,

Respir
Patien
This b
pneum
bronc
associ

(Choic
conditi
in this

(Choic
with *M*
identifi

(Choic
and ev
would

(Choic
pulmo

Educa
Cystic
of thick, viscous airway secretions. Patients typically develop a chronic cough, recurrent pulmonary infections, and bronchiectasis (dilated bronchial tree).

Exhibit Display

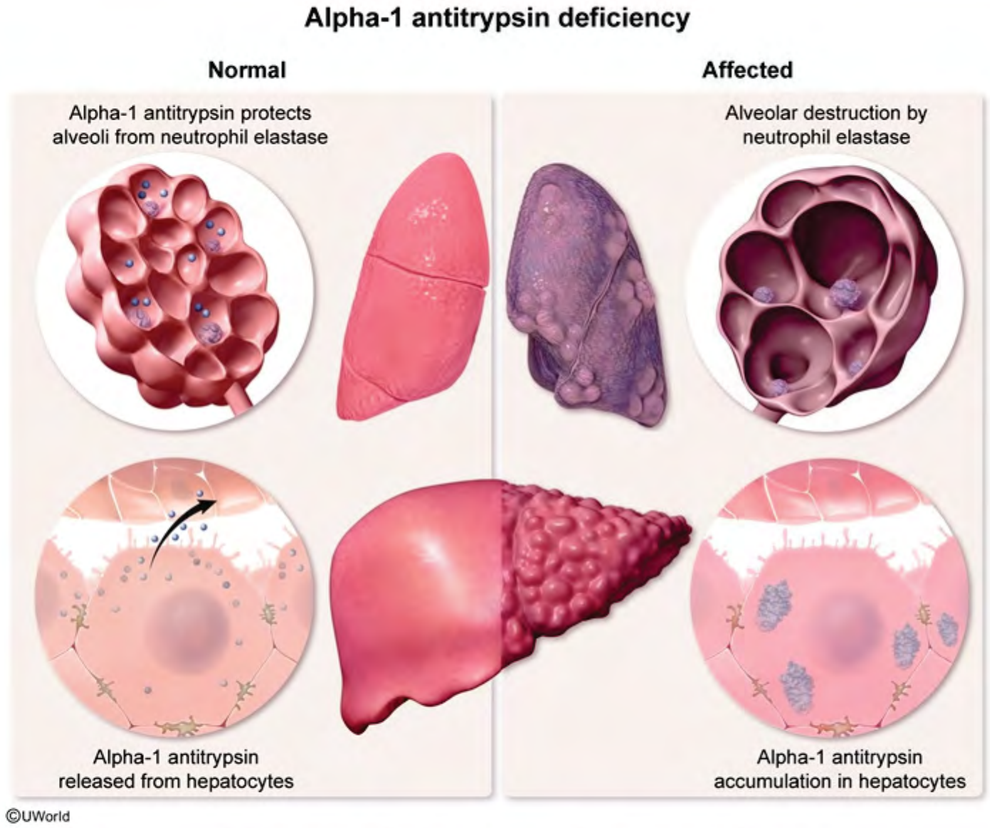

Zoom In Zoom Out Reset New | Existing My Notebook

https://t.me/USMLEWorldStep1

A 63-year-old man undergoes a sleep study, during which he is closely observed for a full night. Several physiologic parameters, such as oxygen saturation, heart rhythm, cerebral electrical activity, respiratory airflow, and movements of the chest and upper abdominal walls, are continuously recorded. The following graph depicts a recording obtained over a period of several minutes:

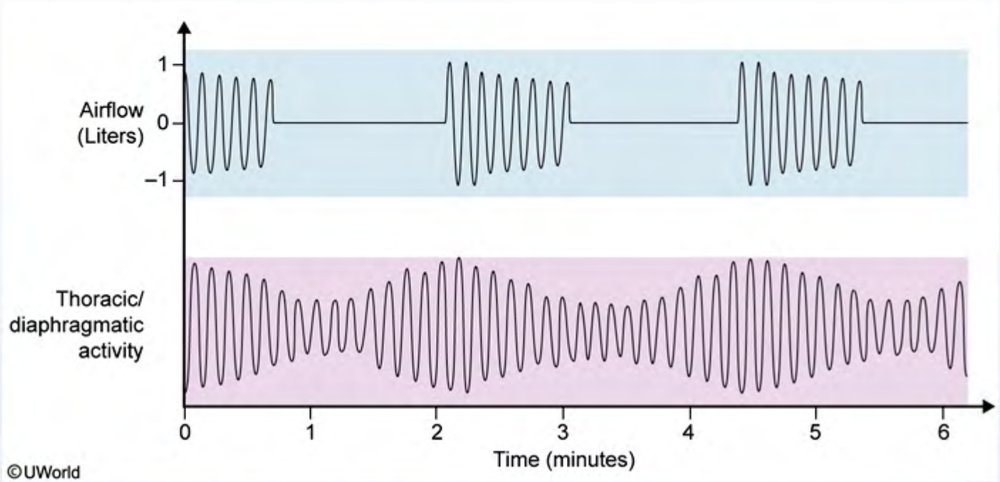

Which of the following is the most likely cause of the observed findings?

- A. Advanced heart failure
- B. Diffuse lung fibrosis
- C. Neuromuscular weakness
- D. Severe ketoacidosis
- E. Upper airway obstruction

Submit

https://t.me/USMLEWorldStep1

A 63-year-old man undergoes a sleep study, during which he is closely observed for a full night. Several
physic
mover
record

Which

Sub

Exhibit Display

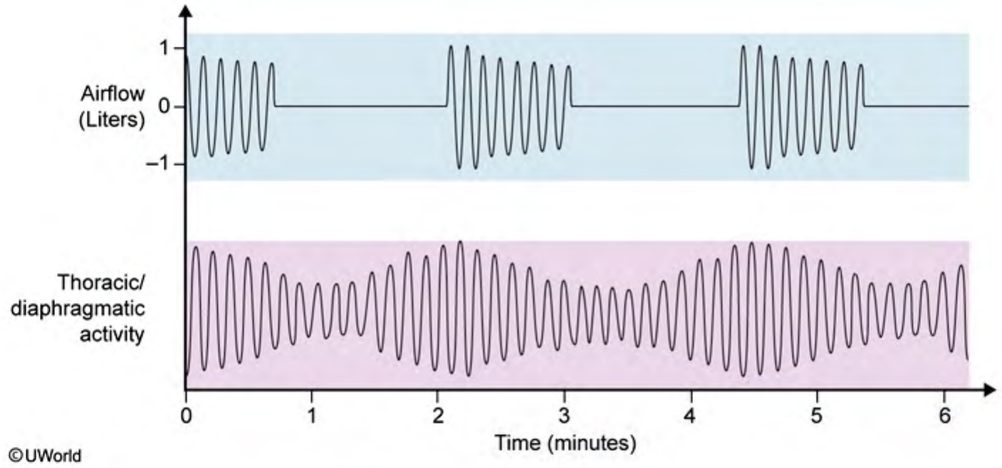

Zoom In | Zoom Out | Reset | New | Existing | My Notebook

https://t.me/USMLEWorldStep1

A 63-year-old man undergoes a sleep study, during which he is closely observed for a full night. Several physiologic parameters, such as oxygen saturation, heart rhythm, cerebral electrical activity, respiratory airflow, and movements of the chest and upper abdominal walls, are continuously recorded. The following graph depicts a recording obtained over a period of several minutes:

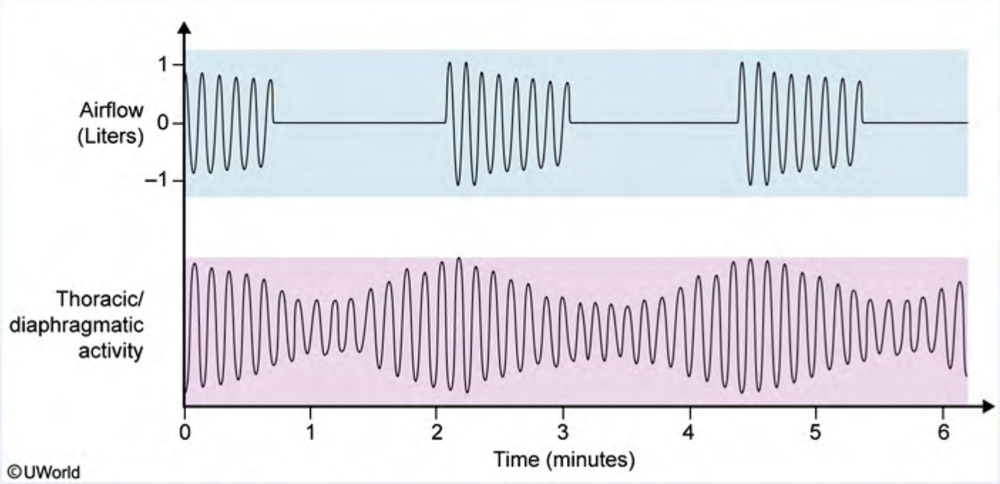

Which of the following is the most likely cause of the observed findings?

- A. Advanced heart failure (9%)
- ✗ B. Diffuse lung fibrosis (5%)
- C. Neuromuscular weakness (18%)
- D. Severe ketoacidosis (4%)
- ✓ E. Upper airway obstruction (62%)

Incorrect
Correct answer
E

62%
Answered correctly

01 min, 04 secs
Time Spent

2023
Version

https://t.me/USMLEWorldStep1

Explanation

This patient with prolonged pauses in airflow despite continued thoracic and diaphragmatic activity has **obstructive sleep apnea** (OSA). OSA, the most common sleep-related breathing disorder, is characterized by **recurrent obstruction of the upper airway**.

During sleep, there is relaxation of the oropharyngeal and/or soft palate musculature. In patients with OSA, this results in a **functional airway collapse** that produces periods of reduced (hypopnea) or absent **(apnea)** airflow despite continued breathing efforts. Apneic episodes may last anywhere from 10 seconds to >1 minute, resulting in **hypoxia** and **hypercapnia**. This eventually triggers chemoreceptors in the carotid body and brainstem, leading to transient arousal and resumption of breathing.

Patients may not be aware of apnea, but bed partners commonly report **loud snoring** with intermittent episodes of silence. This pattern occurs hundreds of times per night, leading to poor sleep quality and **chronic fatigue**. Risk factors for OSA include obesity, large neck circumference, and reduced oropharyngeal diameter (eg, enlarged tonsils or tongue, retro- or micrognathia).

(Choice A) Patients with advanced heart failure may exhibit Cheyne-Stokes breathing, a cyclic breathing pattern in which apnea is followed by gradually increasing then decreasing tidal volumes (crescendo-decrescendo) until the next apneic period.

(Choice B) Reduced lung compliance in pulmonary fibrosis limits tidal volume (TV) per breath. Patients exhibit rapid, shallow breathing (without apnea) to restore minute ventilation (TV × respiratory rate) and minimize the work of breathing.

(Choice C) Neuromuscular weakness (eg, Guillain-Barré syndrome) results in reduced thoracic and diaphragmatic muscle activity with rapid, shallow breathing; recurrent apnea does not occur.

(Choice D) Severe diabetic ketoacidosis can result in Kussmaul breathing (ie, deep, rapid breathing with associated increased thoracic and diaphragmatic activity). It occurs as a respiratory compensation for severe metabolic acidosis.

Educational objective:
Obstructive sleep apnea, the most common sleep-related breathing disorder, is characterized by recurrent

https://t.me/USMLEWorldStep1

recurrent obstruction of the upper airway.

During sleep, there is relaxation of the oropharyngeal and/or soft palate musculature. In patients with OSA, this results in a **functional airway collapse** that produces periods of reduced (hypopnea) or absent **(apnea)** airflow despite continued breathing efforts. Apneic episodes may last anywhere from 10 seconds to >1 minute, resulting in **hypoxia** and **hypercapnia**. This eventually triggers chemoreceptors in the carotid body and brainstem, leading to transient arousal and resumption of breathing.

Patients may not be aware of apnea, but bed partners commonly report **loud snoring** with intermittent episodes of silence. This pattern occurs hundreds of times per night, leading to poor sleep quality and **chronic fatigue**. Risk factors for OSA include obesity, large neck circumference, and reduced oropharyngeal diameter (eg, enlarged tonsils or tongue, retro- or micrognathia).

(Choice A) Patients with advanced heart failure may exhibit Cheyne-Stokes breathing, a cyclic breathing pattern in which apnea is followed by gradually increasing then decreasing tidal volumes (crescendo-decrescendo) until the next apneic period.

(Choice B) Reduced lung compliance in pulmonary fibrosis limits tidal volume (TV) per breath. Patients exhibit rapid, shallow breathing (without apnea) to restore minute ventilation (TV × respiratory rate) and minimize the work of breathing.

(Choice C) Neuromuscular weakness (eg, Guillain-Barré syndrome) results in reduced thoracic and diaphragmatic muscle activity with rapid, shallow breathing; recurrent apnea does not occur.

(Choice D) Severe diabetic ketoacidosis can result in Kussmaul breathing (ie, deep, rapid breathing with associated increased thoracic and diaphragmatic activity). It occurs as a respiratory compensation for severe metabolic acidosis.

Educational objective:
Obstructive sleep apnea, the most common sleep-related breathing disorder, is characterized by recurrent obstruction of the upper airways. Relaxation of the oropharyngeal and/or soft palate musculature during sleep results in a functional collapse of the airway, producing periods of reduced (hypopnea) or absent (apnea) airflow despite continued breathing efforts.

https://t.me/USMLEWorldStep1

recurrent obstruction of the upper airway.

During
results
despit
in **hyp**
to tran

Patien
silence
factors
tonsils

(Choic
in whic
the ne

(Choic
rapid,
of brea

(Choic
muscle

(Choic
associ
metab

Educa
Obstru
obstru
results
despite continued breathing efforts.

Exhibit Display

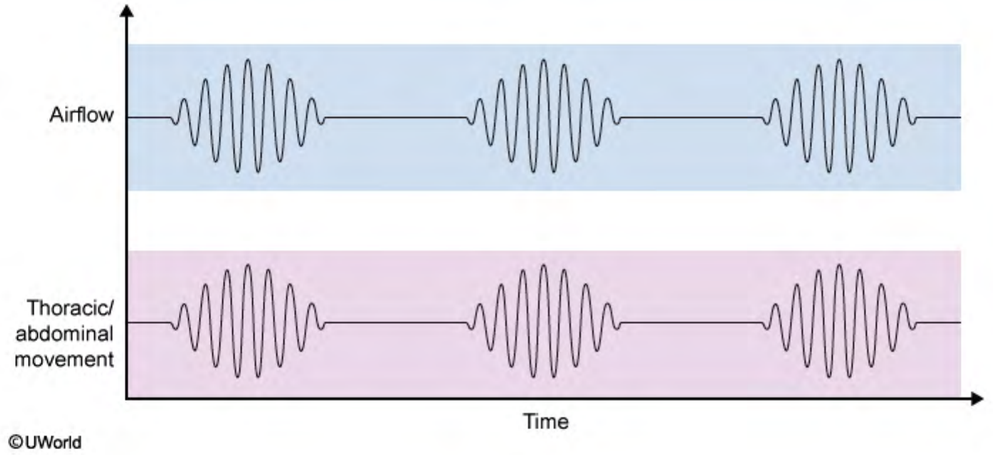

Zoom In Zoom Out Reset New | Existing My Notebook

https://t.me/USMLEWorldStep1

recurrent obstruction of the upper airway.

During
results
despit
in **hyp**
to tran

Patien
silence
factors
tonsils

(Choi
in whi
the ne

(Choi
rapid,
of brea

(Choi
muscl

(Choi
associ
metab

Educa
Obstru
obstru
results
despite continued breathing efforts.

Exhibit Display

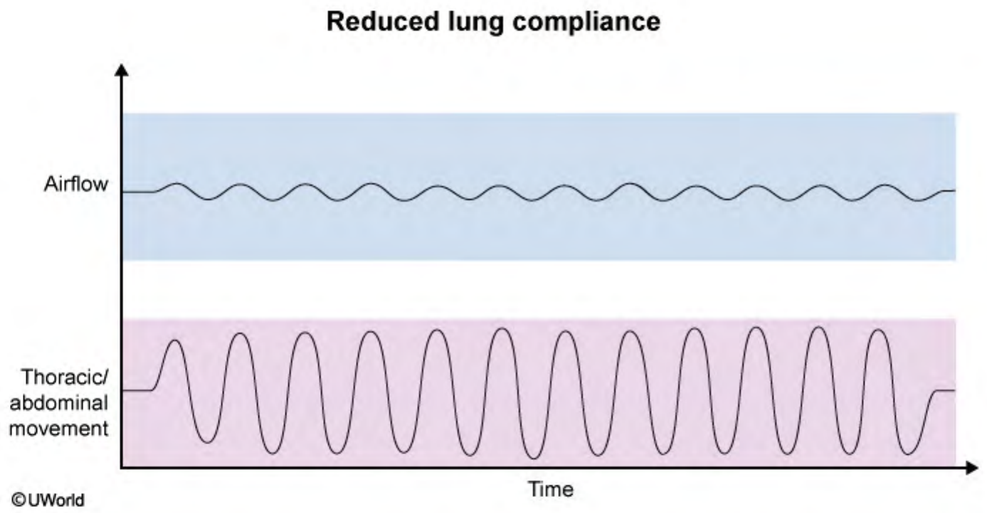

Zoom In Zoom Out Reset New | Existing My Notebook

https://t.me/USMLEWorldStep1

recurrent obstruction of the upper airway.

During
results
despit
in **hyp**
to tran

Patien
silence
factors
tonsils

(Choi
in whi
the ne

(Choi
rapid,
of brea

(Choi
muscl

(Choi
associ
metab

Educa
Obstru
obstru
results
despite continued breathing efforts.

Exhibit Display

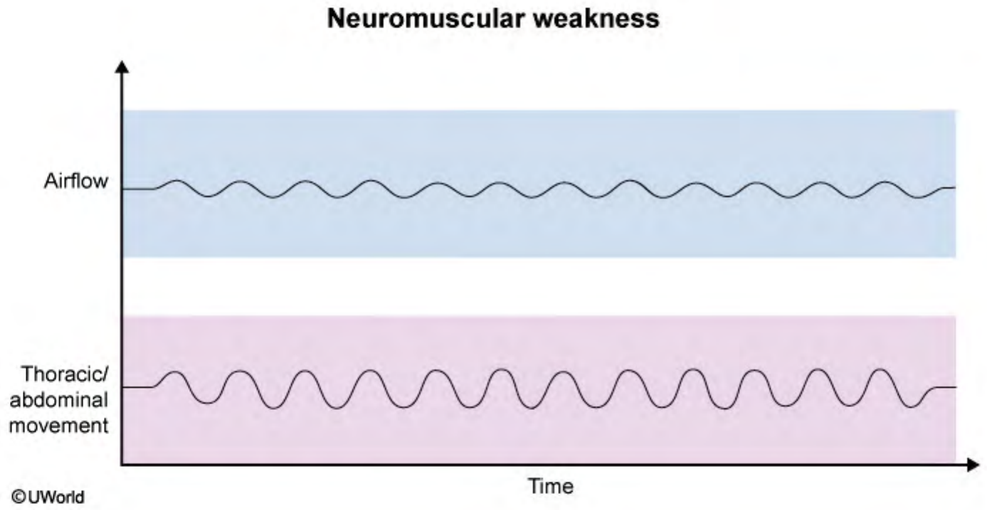

Zoom In Zoom Out Reset New | Existing My Notebook

https://t.me/USMLEWorldStep1

recurrent obstruction of the upper airway.

During
results
despit
in **hyp**
to tran

Patien
silence
factors
tonsils

(Choi
in whi
the ne

(Choi
rapid,
of brea

(Choi
muscl

(Choi
associ
metab

Educa
Obstru
obstru
results
despite continued breathing efforts.

Exhibit Display

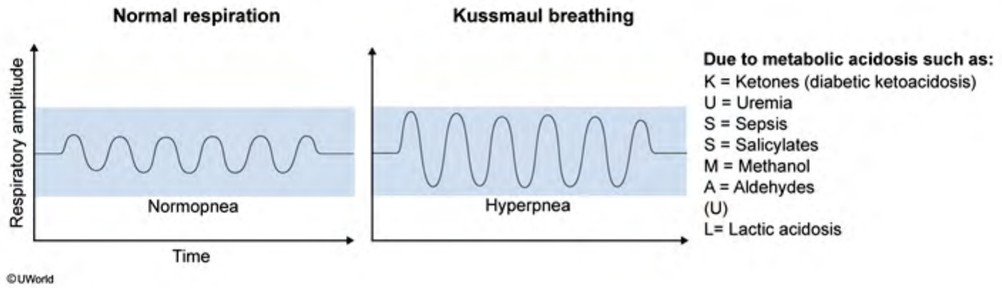

Zoom In Zoom Out Reset New | Existing My Notebook

https://t.me/USMLEWorldStep1

A 46-year-old man comes to the office due to 3 days of fever, shortness of breath, pleuritic chest pain, and cough with purulent sputum. The patient has no prior medical conditions and takes no medications. He has smoked a pack of cigarettes daily for 20 years. Temperature is 38 C (100.4 F). On examination, there are crackles at the base of the left lung. Chest x-ray reveals consolidation in the left lower lobe. Microscopic analysis of a sputum sample shows gram-positive, lancet-shaped cocci in pairs. Which of the following additional characteristics are these bacteria most likely to demonstrate?

- A. Ability to hydrolyze with pyrrolidonyl arylamidase
- B. Complete hemolysis on blood agar
- C. Growth in hypertonic saline
- D. Lysis in the presence of bile salts
- E. Production of the catalase enzyme
- F. Resistance to optochin

Submit

https://t.me/USMLEWorldStep1

A 46-year-old man comes to the office due to 3 days of fever, shortness of breath, pleuritic chest pain, and cough with purulent sputum. The patient has no prior medical conditions and takes no medications. He has smoked a pack of cigarettes daily for 20 years. Temperature is 38 C (100.4 F). On examination, there are crackles at the base of the left lung. Chest x-ray reveals consolidation in the left lower lobe. Microscopic analysis of a sputum sample shows gram-positive, lancet-shaped cocci in pairs. Which of the following additional characteristics are these bacteria most likely to demonstrate?

- A. Ability to hydrolyze with pyrrolidonyl arylamidase (8%)
- ✕ B. Complete hemolysis on blood agar (11%)
- C. Growth in hypertonic saline (2%)
- ✓ D. Lysis in the presence of bile salts (51%)
- E. Production of the catalase enzyme (7%)
- F. Resistance to optochin (19%)

Incorrect
Correct answer
D

51%
Answered correctly

05 secs
Time Spent

2023
Version

Explanation

Microbiologic laboratory identification of streptococci

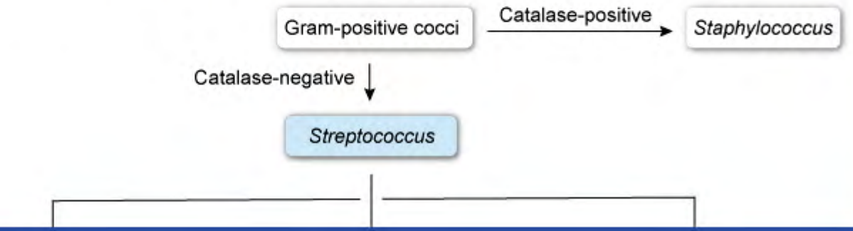

https://t.me/USMLEWorldStep1

E. Resistance to optochin (19%)

Exhibit Display

Microbiologic laboratory identification of streptococci

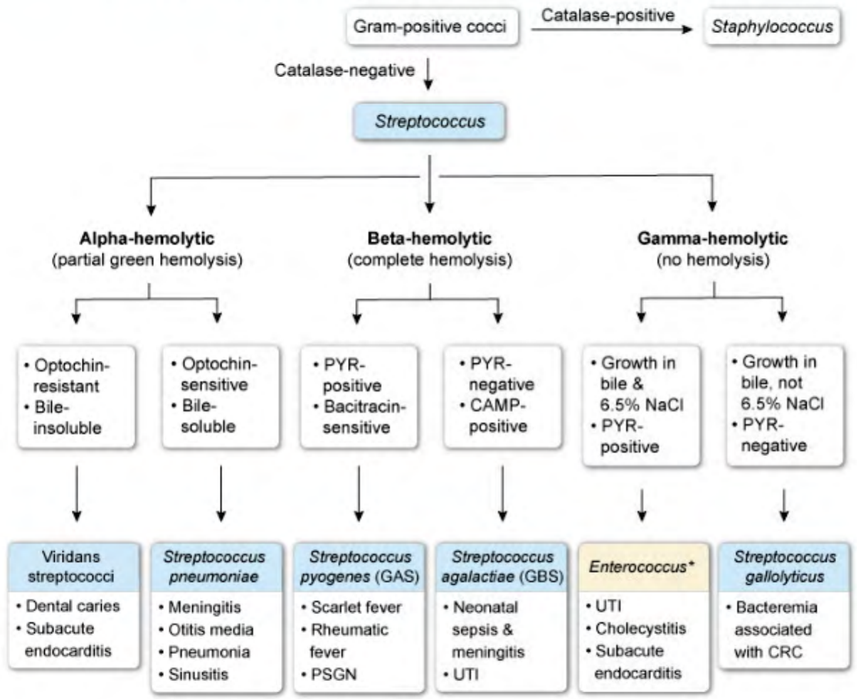

*Formerly group D streptococci

CAMP = Christie, Atkins & Munch-Petersen test; **CRC** = colorectal cancer; **NaCl** = sodium chloride; **PSGN** = poststreptococcal glomerulonephritis; **PYR** = pyrrolidonyl arylamidase; **UTI** = urinary tract infection.

©UWorld

Zoom In | Zoom Out | Reset | New | Existing | My Notebook

• Dental caries
• Subacute endocarditis
• Meningitis
• Otitis media
• Pneumonia
• Sinusitis
• Scarlet fever
• Rheumatic fever
• PSGN
• Neonatal sepsis & meningitis
• UTI
• UTI
• Cholecystitis
• Subacute endocarditis
• Bacteremia associated with CRC

https://t.me/USMLEWorldStep1

Gram-positive cocci → Catalase-positive → *Staphylococcus*

Exhibit Display

Microbiologic laboratory identification of streptococci

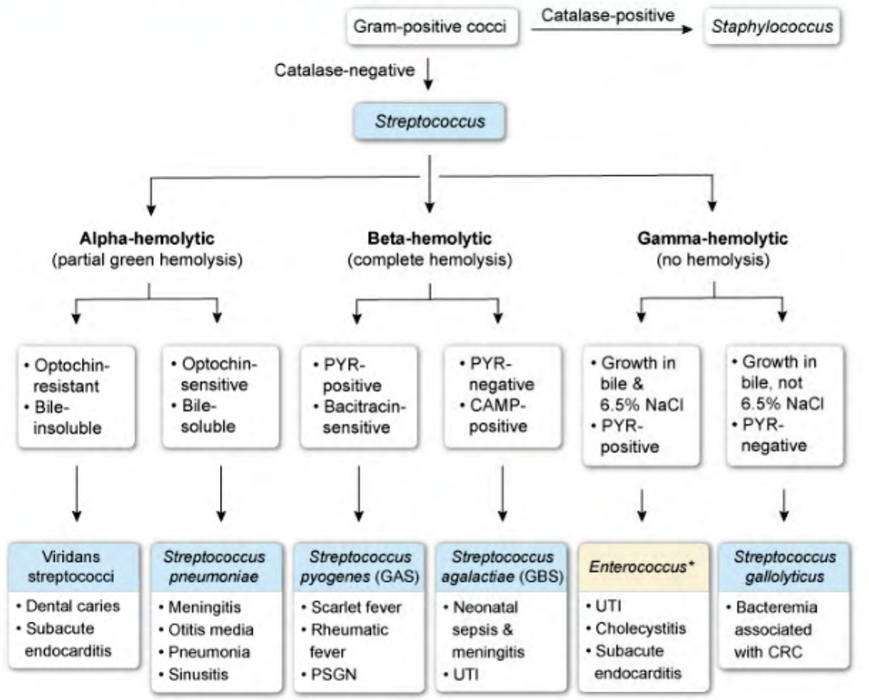

*Formerly group D streptococci

CAMP = Christie, Atkins & Munch-Petersen test; **CRC** = colorectal cancer; **NaCl** = sodium chloride; **PSGN** = poststreptococcal glomerulonephritis; **PYR** = pyrrolidonyl arylamidase; **UTI** = urinary tract infection.

©UWorld

Zoom In | Zoom Out | Reset | New | Existing | My Notebook

The pr
sugge
identifi

- C (catalase positive) or no reaction occurs (catalase negative). Streptococci are **catalase negative**, which distinguishes them from staphylococci (catalase positive) **(Choice E)**.
- Hemolysis pattern, the degree of hemolysis on blood agar, broadly classifies streptococcal species:

https://t.me/USMLEWorldStep1

The presence of lancet-shaped, gram-positive diplococci in the sputum sample of a patient with fever and cough is suggestive of community-acquired pneumonia due to ***Streptococcus pneumoniae***. This pathogen is typically identified in the laboratory based on the following:

- Catalase testing adds hydrogen peroxide to a bacterial sample to determine whether oxygen bubbles form (catalase positive) or no reaction occurs (catalase negative). Streptococci are **catalase negative**, which distinguishes them from staphylococci (catalase positive) **(Choice E)**.
- Hemolysis pattern, the degree of hemolysis on blood agar, broadly classifies streptococcal species:
  - **Alpha-hemolytic** streptococci (eg, *S pneumoniae*, viridans streptococci) cause partial hemolysis on blood agar and turn the agar green due to hemoglobin oxidation.
  - Beta-hemolytic streptococci (eg, *Streptococcus agalactiae*, *Streptococcus pyogenes*) cause complete hemolysis on blood agar, resulting in a clear halo of lysed red blood cells around the colonies **(Choice B)**.
  - Gamma-hemolytic streptococci (eg, *Streptococcus gallolyticus* [formerly *S bovis*]) do not cause hemolysis.
- Optochin and bile-solubility tests differentiate alpha-hemolytic species:
  - The antibiotic optochin inhibits the growth of *S pneumoniae* but not viridans streptococci **(Choice F)**
  - The addition of **bile salts** to a solution of *S pneumoniae* activates pneumolysin (autolytic enzyme) and results in **cell lysis** (clearing of the sample), whereas viridans streptococci are unaffected.

(Choice A) Pyrrolidonyl arylamidase (PYR) enzyme testing is used to differentiate beta- and gamma-hemolytic streptococci. *S pyogenes* and enterococci are PYR positive (ie, can hydrolyze with PYR), whereas *S agalactiae* and *S gallolyticus* are PYR negative (ie, do not produce PYR).

(Choice C) Enterococci and some streptococcal species (eg, *S gallolyticus*) are gamma-hemolytic (no hemolysis), catalase-negative organisms. Enterococci can grow in hypertonic saline (6.5% NaCl) and bile, whereas *S gallolyticus* can grow in the presence of bile but not 6.5% NaCl. *S gallolyticus* bacteremia is associated with colon cancer.

https://t.me/USMLEWorldStep1

- Hemolysis pattern, the degree of hemolysis on blood agar, broadly classifies streptococcal species:
  - **Alpha-hemolytic** streptococci (eg, *S pneumoniae*, viridans streptococci) cause partial hemolysis on blood agar and turn the agar green due to hemoglobin oxidation.
  - Beta-hemolytic streptococci (eg, *Streptococcus agalactiae*, *Streptococcus pyogenes*) cause complete hemolysis on blood agar, resulting in a clear halo of lysed red blood cells around the colonies **(Choice B)**.
  - Gamma-hemolytic streptococci (eg, *Streptococcus gallolyticus* [formerly *S bovis*]) do not cause hemolysis.
- Optochin and bile-solubility tests differentiate alpha-hemolytic species:
  - The antibiotic optochin inhibits the growth of *S pneumoniae* but not viridans streptococci **(Choice F)**
  - The addition of **bile salts** to a solution of *S pneumoniae* activates pneumolysin (autolytic enzyme) and results in **cell lysis** (clearing of the sample), whereas viridans streptococci are unaffected.

(Choice A) Pyrrolidonyl arylamidase (PYR) enzyme testing is used to differentiate beta- and gamma-hemolytic streptococci. *S pyogenes* and enterococci are PYR positive (ie, can hydrolyze with PYR), whereas *S agalactiae* and *S gallolyticus* are PYR negative (ie, do not produce PYR).

(Choice C) Enterococci and some streptococcal species (eg, *S gallolyticus*) are gamma-hemolytic (no hemolysis), catalase-negative organisms. Enterococci can grow in hypertonic saline (6.5% NaCl) and bile, whereas *S gallolyticus* can grow in the presence of bile but not 6.5% NaCl. *S gallolyticus* bacteremia is associated with colon cancer.

Educational objective:
Streptococcus pneumoniae is a gram-positive, lancet-shaped diplococcus that is catalase negative, alpha-hemolytic, optochin sensitive, and bile soluble. Viridans group streptococci are also alpha-hemolytic, but they are optochin resistant and bile insoluble. *Streptococcus pyogenes* (a type of group A streptococcus) is beta-hemolytic and PYR positive and appears as gram-positive cocci in chains.

https://t.me/USMLEWorldStep1

• Sinusitis • PSGN • UTI endocarditis

Exhibit Display

Streptococcus pneumoniae

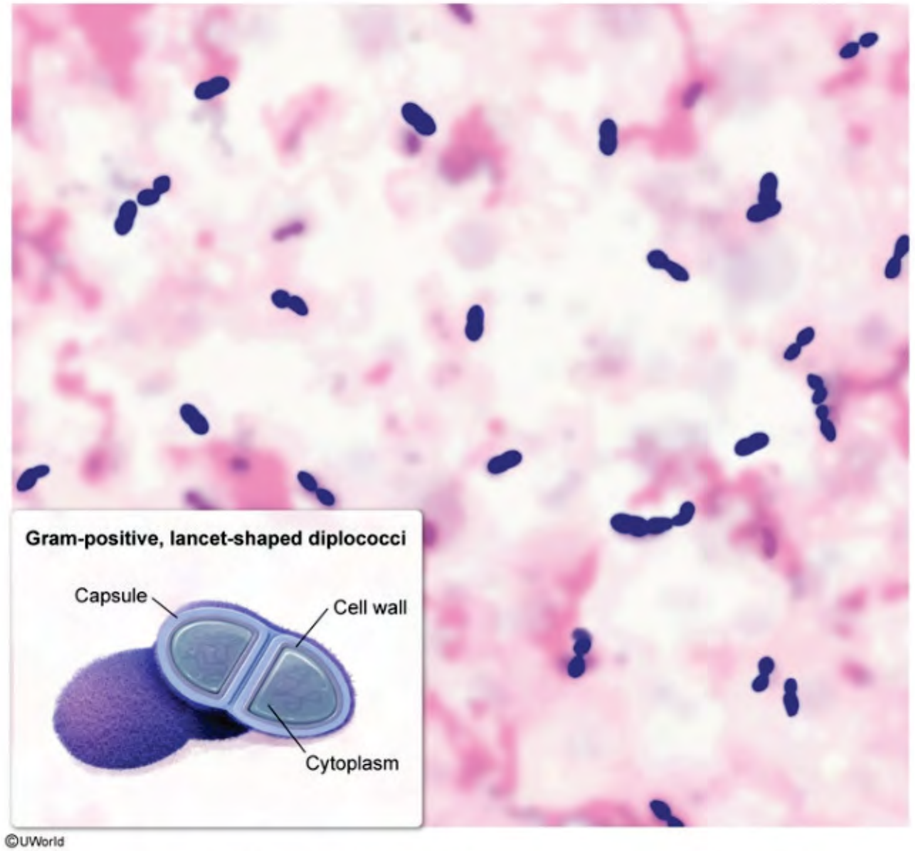

©UWorld

Zoom In Zoom Out Reset New | Existing My Notebook

The pr
sugge
identifi

- C
  (c
  d
- H

- C

(Choi
strept
and *S gallolyticus* are PYR negative (ie, do not produce PYR).

• Sinusitis
• PSGN
• UTI
endocarditis

Exhibit Display

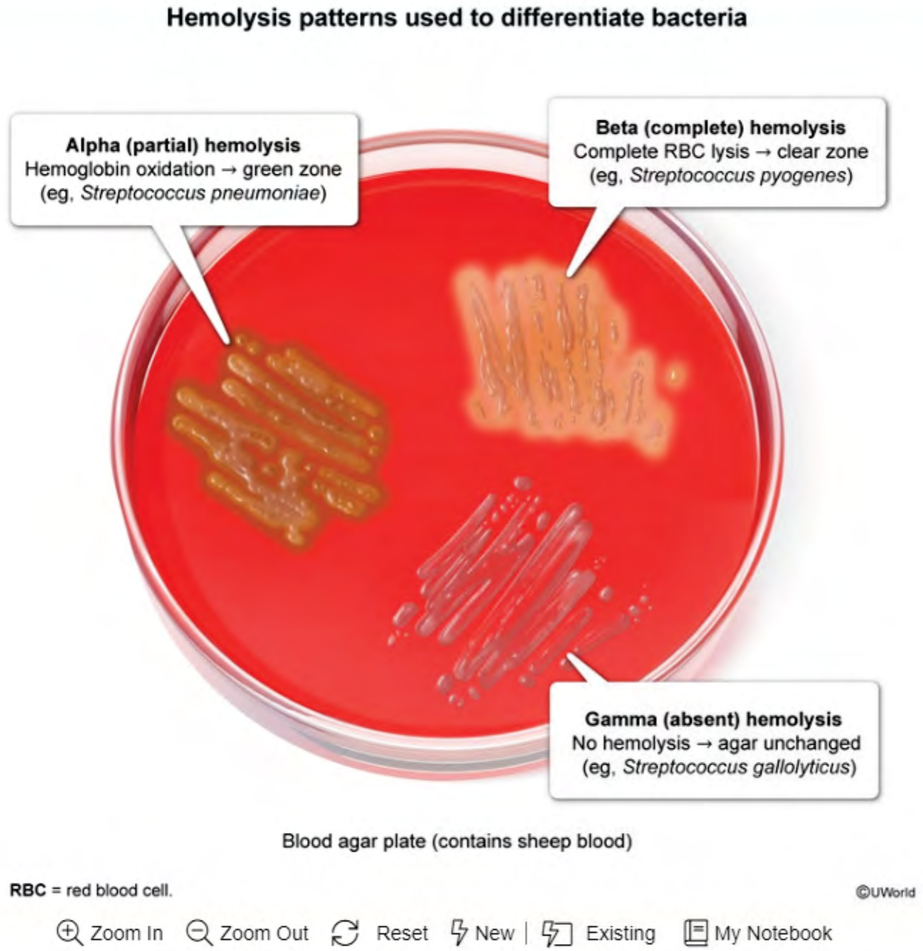

The pr
sugge
identifi

- C
  (c
  d
- H
- C

(Choi
strepto
and *S gallolyticus* are PYR negative (ie, do not produce PYR).

https://t.me/USMLEWorldStep1

The presence of lancet-shaped, gram-positive diplococci in the sputum sample of a patient with fever and cough is sugge
identifi

- C
- H
- C

(Choi
strepto
and *S*

(Choice C) Enterococci and some streptococcal species (eg, *S gallolyticus*) are gamma-hemolytic (no hemolysis), catalase-negative organisms. Enterococci can grow in hypertonic saline (6.5% NaCl) and bile, whereas *S gallolyticus* can grow in the presence of bile but not 6.5% NaCl. *S gallolyticus* bacteremia is associated with colon cancer

Exhibit Display

Streptococcus pneumoniae

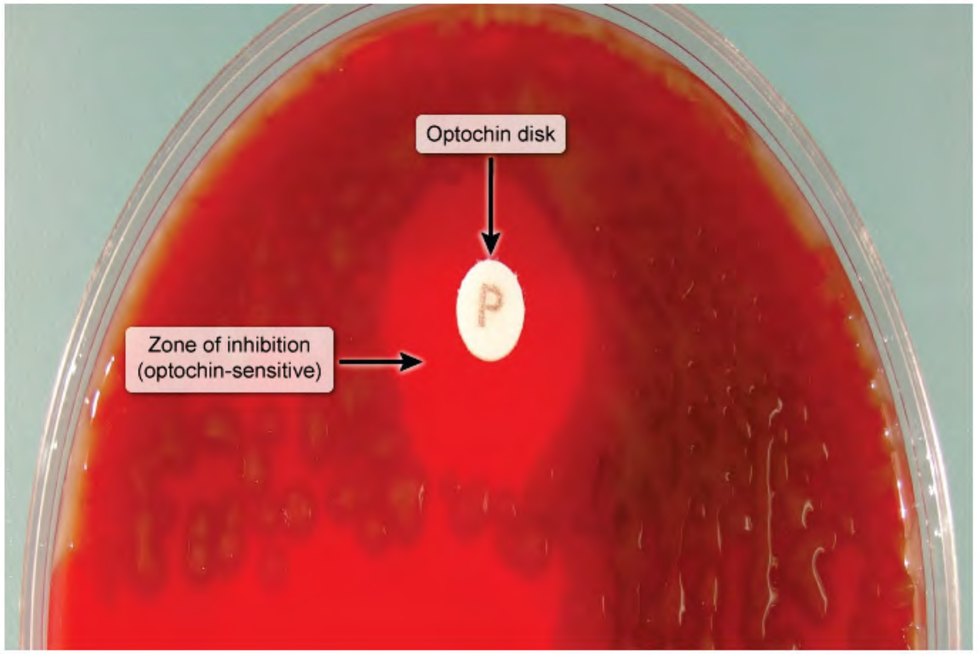

©UWorld

Zoom In | Zoom Out | Reset | New | Existing | My Notebook

https://t.me/USMLEWorldStep1

A novel antimicrobial agent that inhibits bacterial glycosyltransferase enzyme is developed. Bacteria grown in a medium containing this antibiotic become spherical, cease to grow, and subsequently lyse. So that the activity of this antibiotic against various bacteria can be determined, disks enriched with the drug are placed on agar plates containing bacterial colonies. The plates are incubated alongside control plates with the same organisms but no antimicrobial disks. The control plates all show organism growth. In the plates with the diffusion disks, resistance to the drug is determined by measuring the zone of complete growth inhibition around the disk. Which of the following bacteria is most likely to be resistant to this drug?

- A. *Actinomyces israelii*
- B. *Borrelia burgdorferi*
- C. *Helicobacter pylori*
- D. *Mycoplasma hominis*
- E. *Pasteurella multocida*

Submit

https://t.me/USMLEWorldStep1

A novel antimicrobial agent that inhibits bacterial glycosyltransferase enzyme is developed. Bacteria grown in a medium containing this antibiotic become spherical, cease to grow, and subsequently lyse. So that the activity of this antibiotic against various bacteria can be determined, disks enriched with the drug are placed on agar plates containing bacterial colonies. The plates are incubated alongside control plates with the same organisms but no antimicrobial disks. The control plates all show organism growth. In the plates with the diffusion disks, resistance to the drug is determined by measuring the zone of complete growth inhibition around the disk. Which of the following bacteria is most likely to be resistant to this drug?

- A. *Actinomyces israelii* (12%)
- ✗ B. *Borrelia burgdorferi* (7%)
- C. *Helicobacter pylori* (10%)
- ✓ D. *Mycoplasma hominis* (63%)
- E. *Pasteurella multocida* (6%)

Incorrect
Correct answer
D

63%
Answered correctly

06 secs
Time Spent

2023
Version

Explanation

Peptidoglycan is the main component of the bacterial wall in both gram-positive and gram-negative organisms. It is composed of a linear glycan chain of 2 alternating sugars, N-acetylglucosamine and N-acetylmuramic acid, that are cross-linked by short peptides, thereby forming a rigid matrix. The enzyme **glycosyltransferase** is a crucial component of peptidoglycan synthesis; it adds glycan molecules to the growing peptidoglycan chain. Inhibition of this enzyme would result in gaps in the bacterial cell wall, with subsequent loss of bacterial shape and cell lysis from osmotic stress.

Although most bacteria have a cell wall composed of peptidoglycan, organisms from the ***Mycoplasma*** genus (eg,

https://t.me/USMLEWorldStep1

Peptidoglycan is the main component of the bacterial wall in both gram-positive and gram-negative organisms. It is composed of a linear glycan chain of 2 alternating sugars, N-acetylglucosamine and N-acetylmuramic acid, that are cross-linked by short peptides, thereby forming a rigid matrix. The enzyme **glycosyltransferase** is a crucial component of peptidoglycan synthesis; it adds glycan molecules to the growing peptidoglycan chain. Inhibition of this enzyme would result in gaps in the bacterial cell wall, with subsequent loss of bacterial shape and cell lysis from osmotic stress.

Although most bacteria have a cell wall composed of peptidoglycan, organisms from the ***Mycoplasma*** genus (eg, *Ureaplasma urealyticum, M hominis*) completely **lack a cell wall**. These pathogens are separated from the environment by a single phospholipid bilayer membrane composed primarily of cholesterol (similar to human cells). Therefore, antibacterial agents that target the cell wall, including penicillins, cephalosporins, carbapenems, vancomycin, and the drug described in this study, would be ineffective. *Mycoplasma* is treated primarily by medications that **inhibit bacterial ribosomal function** such as macrolides and tetracyclines.

(Choice A) *Actinomyces israelii* is a gram-positive, fungus-like bacterium that has a thick peptidoglycan cell wall. Therefore, it is likely to be inhibited by the drug described in this study. It can be effectively treated with penicillin.

(Choices B and E) *Borrelia burgdorferi* is the spirochete that causes Lyme disease. *Pasteurella multocida* is a gram-negative organism that is well-known for causing wound infections following cat bites. Because these organisms have peptidoglycan cell walls, they would likely be inhibited by a drug that blocks glycosyltransferase.

(Choice C) *Helicobacter pylori*, a gram-negative helical organism with a cell wall, is closely related to the *Campylobacter* genus. The recommended treatment regimen includes a proton pump inhibitor (eg, omeprazole) combined with clarithromycin and amoxicillin, with or without bismuth (triple or quadruple therapy).

Educational objective:
All organisms in the *Mycoplasma* genus, including *Ureaplasma urealyticum*, lack peptidoglycan cell walls and are therefore resistant to agents that target the cell wall such as penicillins, cephalosporins, carbapenems, and vancomycin. *Mycoplasma* infections can be treated with antiribosomal agents (eg, tetracyclines, macrolides).

Microbiology Pulmonary & Critical Care Community acquired pneumonia

https://t.me/USMLEWorldStep1

A 28-year-old previously healthy man comes to the urgent care clinic due to shortness of breath. The patient is on a ski vacation in Breckenridge, Colorado, which is situated at an altitude of 2926 m (9600 ft). On arrival 4 days ago, he experienced mild headache and nausea that resolved spontaneously, but since yesterday, he has had worsening dyspnea and cough. The patient now feels short of breath even with minimal exertion. Temperature is 37.3 C (99.1) F, blood pressure is 134/82 mm Hg, pulse is 98/min, and respirations are 22/min. Oxygen saturation is 86% on ambient air, which rapidly improves to 95% with supplemental oxygen. Physical examination shows pink mucous membranes, flat neck veins, bilateral inspiratory crackles, and no heart murmurs or pedal edema. Chest x-ray reveals patchy alveolar infiltrates. Which of the following is the most likely cause of this patient's current condition?

- A. Alveolar-capillary membrane disruption
- B. Embolic pulmonary arterial occlusion
- C. Excessive decrease in $PaCO_2$ level
- D. Impaired left ventricular function
- E. Increased total red blood cell mass

Submit

https://t.me/USMLEWorldStep1

A 28-year-old previously healthy man comes to the urgent care clinic due to shortness of breath. The patient is on a ski vacation in Breckenridge, Colorado, which is situated at an altitude of 2926 m (9600 ft). On arrival 4 days ago, he experienced mild headache and nausea that resolved spontaneously, but since yesterday, he has had worsening dyspnea and cough. The patient now feels short of breath even with minimal exertion. Temperature is 37.3 C (99.1) F, blood pressure is 134/82 mm Hg, pulse is 98/min, and respirations are 22/min. Oxygen saturation is 86% on ambient air, which rapidly improves to 95% with supplemental oxygen. Physical examination shows pink mucous membranes, flat neck veins, bilateral inspiratory crackles, and no heart murmurs or pedal edema. Chest x-ray reveals patchy alveolar infiltrates. Which of the following is the most likely cause of this patient's current condition?

- ✓ A. Alveolar-capillary membrane disruption (45%)
- ✗ B. Embolic pulmonary arterial occlusion (5%)
- C. Excessive decrease in $PaCO_2$ level (26%)
- D. Impaired left ventricular function (5%)
- E. Increased total red blood cell mass (17%)

Incorrect
Correct answer
A

45%
Answered correctly

06 secs
Time Spent

2023
Version

Explanation

High-altitude illness	
Pathogenesis	• Reduced PiO_2 at high altitude (>2,500 m [~8000 ft])
	• Hyperventilation: helps ↑ PaO_2 but causes ↓

https://t.me/USMLEWorldStep1

High-altitude illness	
Pathogenesis	• Reduced PiO_2 at high altitude (>2,500 m [~8000 ft])
Physiologic responses	• Hyperventilation: helps ↑ PaO_2 but causes ↓ $PaCO_2$ • Erythrocytes: ↑ 2,3-BPG production (↑ O_2 unloading in tissues) • Kidneys: ↑ Erythropoietin production & ↑ HCO_3^- excretion

Complications	• Acute mountain sickness
	  ◦ Headache, fatigue, nausea
	• Cerebral edema (↓ PaO_2 → ↑ cerebral blood flow)
	  ◦ Lethargy, confusion, gait disturbance
	• Pulmonary edema (unbalanced hypoxic vasoconstriction)
	  ◦ Dyspnea, cough ± hemoptysis, respiratory distress

2,3-BPG = 2,3-bisphosphoglycerate; **PiO_2** = partial pressure of inspired oxygen.	

This patient with dyspnea, hypoxemia, and patchy alveolar infiltrates shortly after arriving at high altitude likely has **high-altitude pulmonary edema** (HAPE). HAPE can occur within several days of arrival at an altitude >2,500 m (~8,000 ft), with the risk increasing as altitude increases. The pathophysiology is driven by the **reduced partial pressure of oxygen** (PiO_2) at high altitude, which leads to **hypoxic pulmonary vasoconstriction** and consequent **increased pulmonary arterial pressure**. In some individuals with genetic predisposition, the hypoxic vasoconstriction is unevenly distributed, exposing the capillary beds in relatively less vasoconstricted areas to high

https://t.me/USMLEWorldStep1

This patient with dyspnea, hypoxemia, and patchy alveolar infiltrates shortly after arriving at high altitude likely has **high-altitude pulmonary edema** (HAPE). HAPE can occur within several days of arrival at an altitude >2,500 m (~8,000 ft), with the risk increasing as altitude increases. The pathophysiology is driven by the **reduced partial pressure of oxygen** (PiO_2) at high altitude, which leads to **hypoxic pulmonary vasoconstriction** and consequent **increased pulmonary arterial pressure**. In some individuals with genetic predisposition, the hypoxic vasoconstriction is unevenly distributed, exposing the capillary beds in relatively less vasoconstricted areas to high perfusion pressure. This causes **alveolar-capillary membrane disruption** and leads to patchy, bilateral pulmonary edema.

HAPE typically presents with dyspnea (progressive over 1-2 days) and cough (sometimes with hemoptysis). Accompanying symptoms of **acute mountain sickness** (eg, headache, nausea) are often present, and physical examination reveals bilateral lung crackles. The **hypoxemia** characteristically **improves with supplemental oxygen** (likely due to alleviation of pulmonary vasoconstriction), which differentiates HAPE from other causes of diffuse pulmonary edema. Although potentially fatal, HAPE usually resolves rapidly upon descent to lower altitudes.

(Choice B) Acute pulmonary embolism causes dyspnea and hypoxemia; however, jugular venous distension and an absence of pulmonary edema (eg, no ausculatory crackles, clear lungs on chest x-ray) are also expected.

(Choice C) Hyperventilation leading to reduced $PaCO_2$ and respiratory alkalosis is expected at high altitude. An extreme drop in $PaCO_2$ can cause severe alkalosis with associated tingling, numbness, tetany, and possibly seizures, but it does not cause pulmonary edema.

(Choice D) Left ventricular function is unaffected in HAPE (the pulmonary edema is noncardiogenic). Myocardial infarction can lead to acute left ventricular dysfunction with pulmonary edema, but it would be expected to present with severe chest pain and to cause jugular venous distension.

(Choice E) In response to the reduced PiO_2 at high altitude, the body increases erythrocyte production to increase O_2-carrying capacity. However, this secondary polycythemia does not contribute to pulmonary edema.

Educational objective:
High-altitude pulmonary edema presents with dyspnea and cough within several days of arrival at high altitude. It

https://t.me/USMLEWorldStep1

pressure of oxygen (PiO_2) at high altitude, which leads to **hypoxic pulmonary vasoconstriction** and consequent **increased pulmonary arterial pressure**. In some individuals with genetic predisposition, the hypoxic vasoconstriction is unevenly distributed, exposing the capillary beds in relatively less vasoconstricted areas to high perfusion pressure. This causes **alveolar-capillary membrane disruption** and leads to patchy, bilateral pulmonary edema.

HAPE typically presents with dyspnea (progressive over 1-2 days) and cough (sometimes with hemoptysis). Accompanying symptoms of **acute mountain sickness** (eg, headache, nausea) are often present, and physical examination reveals bilateral lung crackles. The **hypoxemia** characteristically **improves with supplemental oxygen** (likely due to alleviation of pulmonary vasoconstriction), which differentiates HAPE from other causes of diffuse pulmonary edema. Although potentially fatal, HAPE usually resolves rapidly upon descent to lower altitudes.

(Choice B) Acute pulmonary embolism causes dyspnea and hypoxemia; however, jugular venous distension and an absence of pulmonary edema (eg, no ausculatory crackles, clear lungs on chest x-ray) are also expected.

(Choice C) Hyperventilation leading to reduced $PaCO_2$ and respiratory alkalosis is expected at high altitude. An extreme drop in $PaCO_2$ can cause severe alkalosis with associated tingling, numbness, tetany, and possibly seizures, but it does not cause pulmonary edema.

(Choice D) Left ventricular function is unaffected in HAPE (the pulmonary edema is noncardiogenic). Myocardial infarction can lead to acute left ventricular dysfunction with pulmonary edema, but it would be expected to present with severe chest pain and to cause jugular venous distension.

(Choice E) In response to the reduced PiO_2 at high altitude, the body increases erythrocyte production to increase O_2-carrying capacity. However, this secondary polycythemia does not contribute to pulmonary edema.

Educational objective:
High-altitude pulmonary edema presents with dyspnea and cough within several days of arrival at high altitude. It is driven by reduced ambient oxygen, which leads to hypoxic pulmonary vasoconstriction and pulmonary arterial hypertension. Individuals with unevenly distributed pulmonary vasoconstriction can develop areas of high capillary perfusion pressure that disrupts the alveolar-capillary membrane, leading to patchy, bilateral pulmonary edema.

https://t.me/USMLEWorldStep1

distress

2,3-BPG = 2,3-bisphosphoglycerate; PiO_2 = partial pressure of inspired

Exhibit Display

Bilateral pulmonary edema

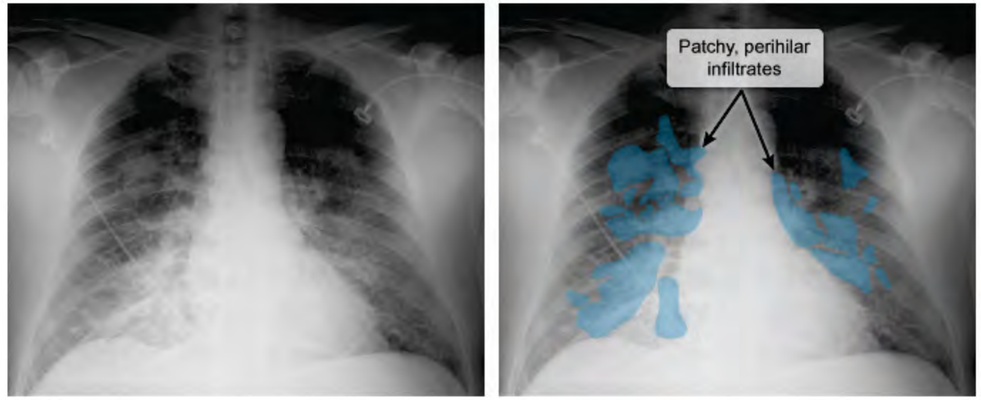

©UWorld

Zoom In | Zoom Out | Reset | New | Existing | My Notebook

This p
high-a
(~8,00
press
conse
vasoc
perfus
pulmo

HAPE
Accom
exami
oxyge
diffuse
altitud

(Choic
an abs

(Choic
extrem
seizur

(Choic
infarct
with se

(Choice E) In response to the reduced PiO_2 at high altitude, the body increases erythrocyte production to increase

https://t.me/USMLEWorldStep1

A 34-year-old woman comes to the office due to progressive exertional dyspnea for the past 6 months. She has no chest pain, lightheadedness, or syncope. Medical history is unremarkable and the patient takes no medications. She does not use tobacco, alcohol, or illicit drugs. The patient's mother died of pulmonary arterial hypertension at age 32. Blood pressure is 125/74 mm Hg and pulse is 75/min. BMI is 23 kg/m^2. On physical examination, breath sounds are clear without wheezes or crackles. There is a loud S2 at the left upper sternal border. Chest x-ray reveals clear lungs. ECG shows right axis deviation. If this patient's condition is inherited, which of the following is the most likely direct cause of her disease?

- A. Elevated left atrial pressure
- B. Hypoxic vasoconstriction
- C. Right ventricular hypertrophy
- D. Thrombotic occlusion of pulmonary arteries
- E. Vascular smooth muscle proliferation

Submit

https://t.me/USMLEWorldStep1

A 34-year-old woman comes to the office due to progressive exertional dyspnea for the past 6 months. She has no chest pain, lightheadedness, or syncope. Medical history is unremarkable and the patient takes no medications. She does not use tobacco, alcohol, or illicit drugs. The patient's mother died of pulmonary arterial hypertension at age 32. Blood pressure is 125/74 mm Hg and pulse is 75/min. BMI is 23 kg/m^2. On physical examination, breath sounds are clear without wheezes or crackles. There is a loud S2 at the left upper sternal border. Chest x-ray reveals clear lungs. ECG shows right axis deviation. If this patient's condition is inherited, which of the following is the most likely direct cause of her disease?

- A. Elevated left atrial pressure (5%)
- ✗ B. Hypoxic vasoconstriction (4%)
- C. Right ventricular hypertrophy (20%)
- D. Thrombotic occlusion of pulmonary arteries (3%)
- ✓ E. Vascular smooth muscle proliferation (65%)

Incorrect
Correct answer
E

65%
Answered correctly

04 secs
Time Spent

2023
Version

Explanation

Pathogenesis of pulmonary arterial hypertension

https://t.me/USMLEWorldStep1

A 34-year-old woman comes to the office due to progressive exertional dyspnea for the past 6 months. She has no chest
She d
age 32
sound
reveal
the mo

Inco
Corre
E

Expl

Exhibit Display

Pathogenesis of pulmonary arterial hypertension

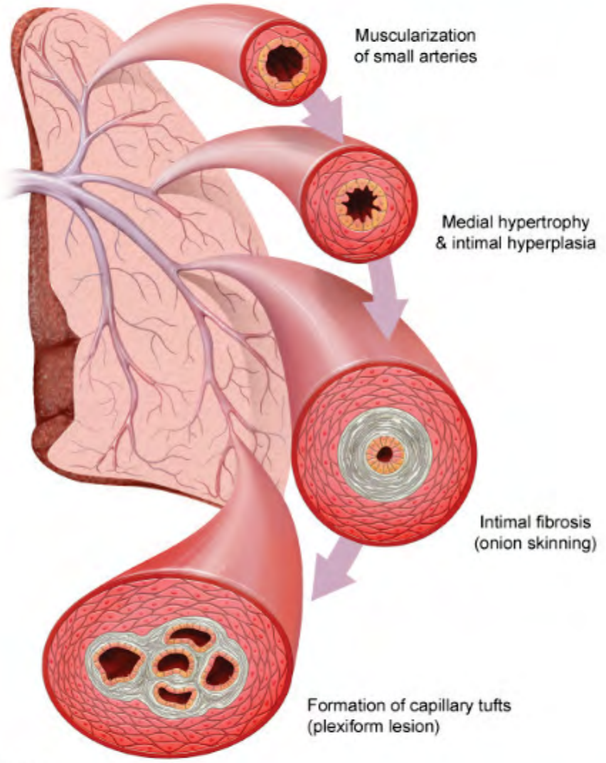

©UWorld

Zoom In | Zoom Out | Reset | New | Existing | My Notebook

https://t.me/USMLEWorldStep1

©UWorld

This patient's presentation and family history are suggestive of **pulmonary arterial hypertension** (PAH). Hereditary PAH is most often due to an inactivating mutation in ***BMPR2***, which is transmitted in an autosomal dominant manner with variable penetrance. Patients with this mutation have a predisposition for dysfunctional endothelial and **smooth muscle cell proliferation**. An insult (eg, infection, drugs) is thought to then activate the disease process, which involves increased levels of vasoconstrictive, proliferative mediators (eg, endothelin) and decreased levels of vasodilative, antiproliferative mediators (eg, nitric oxide, prostacyclin). The end result is vasoconstriction with vascular smooth muscle proliferation, intimal thickening and fibrosis, increased pulmonary vascular resistance, and progressive pulmonary hypertension.

Increased pulmonary artery pressure can cause dyspnea and fatigue and can often be detected as a **loud pulmonic component of S2**. Significant pulmonary hypertension leads to compensatory right ventricular hypertrophy **(Choice C)**, which may cause right axis deviation on ECG. Right-sided heart failure can eventually occur, evidenced by elevated jugular venous pressure, hepatic congestion, and peripheral edema. The lungs remain clear in PAH as the lung parenchyma is unaffected.

(Choice A) Elevated left atrial pressure is indicative of heart failure, most commonly due to left ventricular dysfunction. The elevated pressure transmits back to the pulmonary venous system and can lead to pulmonary hypertension; however, evidence of pulmonary edema (eg, crackles, pulmonary congestion on chest x-ray) would be expected.

(Choice B) Excessive hypoxic vasoconstriction of the pulmonary arteries can lead to pulmonary hypertension in patients with severe hypoxic lung disease, including chronic obstructive pulmonary disease, interstitial lung disease, and obesity hypoventilation syndrome. However, this patient's normal chest x-ray and BMI rule out these disorders.

(Choice D) Chronic pulmonary arterial thromboembolism decreases the cross-sectional area of the pulmonary vasculature and can lead to pulmonary hypertension. However, PAH is more likely in this patient with a positive family history and no evidence of venous thromboembolism.

Educational objective:
Hereditary pulmonary arterial hypertension develops in 2 steps. An abnormal *BMPR2* gene predisposes affected

https://t.me/USMLEWorldStep1

endothelial and **smooth muscle cell proliferation**. An insult (eg, infection, drugs) is thought to then activate the disease process, which involves increased levels of vasoconstrictive, proliferative mediators (eg, endothelin) and decreased levels of vasodilative, antiproliferative mediators (eg, nitric oxide, prostacyclin). The end result is vasoconstriction with vascular smooth muscle proliferation, intimal thickening and fibrosis, increased pulmonary vascular resistance, and progressive pulmonary hypertension.

Increased pulmonary artery pressure can cause dyspnea and fatigue and can often be detected as a **loud pulmonic component of S2**. Significant pulmonary hypertension leads to compensatory right ventricular hypertrophy **(Choice C)**, which may cause right axis deviation on ECG. Right-sided heart failure can eventually occur, evidenced by elevated jugular venous pressure, hepatic congestion, and peripheral edema. The lungs remain clear in PAH as the lung parenchyma is unaffected.

(Choice A) Elevated left atrial pressure is indicative of heart failure, most commonly due to left ventricular dysfunction. The elevated pressure transmits back to the pulmonary venous system and can lead to pulmonary hypertension; however, evidence of pulmonary edema (eg, crackles, pulmonary congestion on chest x-ray) would be expected.

(Choice B) Excessive hypoxic vasoconstriction of the pulmonary arteries can lead to pulmonary hypertension in patients with severe hypoxic lung disease, including chronic obstructive pulmonary disease, interstitial lung disease, and obesity hypoventilation syndrome. However, this patient's normal chest x-ray and BMI rule out these disorders.

(Choice D) Chronic pulmonary arterial thromboembolism decreases the cross-sectional area of the pulmonary vasculature and can lead to pulmonary hypertension. However, PAH is more likely in this patient with a positive family history and no evidence of venous thromboembolism.

Educational objective:
Hereditary pulmonary arterial hypertension develops in 2 steps. An abnormal *BMPR2* gene predisposes affected individuals to excessive endothelial and smooth muscle cell proliferation. An insult (eg, infection, drugs) is thought to then activate the disease process, resulting in vascular remodeling, increased pulmonary vascular resistance, and progressive pulmonary hypertension.

https://t.me/USMLEWorldStep1

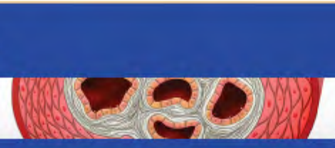

Exhibit Display

Classification of pulmonary hypertension	

Pulmonary arterial hypertension (group 1)	• Primary change in pulmonary arteries
	  ◦ Hereditary (eg, *BMPR2* mutation)
	  ◦ Connective tissue disease (eg, RA, SS)
	  ◦ HIV infection
	• Treatment targeted at endothelial dysfunction

Pulmonary hypertension (groups 2-5)	• Secondary to another disease process
	  ◦ Left-sided heart failure (group 2)
	  ◦ Chronic lung disease/hypoxia (group 3)
	  ◦ Chronic pulmonary thromboembolism (group 4)
	  ◦ Other (eg, sarcoidosis) (group 5)
	• Treatment aimed at underlying disease

RA = rheumatoid arthritis; **SS** = systemic sclerosis.	

New | Existing | My Notebook

This p
Hered
domin
endoth
diseas
decrea
vasoc
vascul

Increa
pulmo
hypert
occur,
remain

(Choi
dysfun
hypert
be exp

(Choi
patien
diseas
disord

(Choi
vasculature and can lead to pulmonary hypertension. However, PAH is more likely in this patient with a positive

https://t.me/USMLEWorldStep1

A 56-year-old man comes to the emergency department due to progressively worsening dyspnea. The patient can walk only a few blocks before becoming short of breath. He also finds it difficult to sleep lying flat and requires 3 pillows to prop himself upright when sleeping. Other medical problems include long-standing hypertension, for which he occasionally takes his prescribed antihypertensive medication. The patient does not use tobacco, alcohol, or illicit drugs. Blood pressure is 170/100 mm Hg, and pulse is 80/min and regular. Physical examination reveals bilateral basilar lung crackles, jugular venous distension, and bilateral lower extremity edema. Chest x-ray reveals cardiomegaly and hilar prominence. ECG shows left ventricular hypertrophy. Echocardiogram shows elevated pressures in the pulmonary artery. Which of the following is the most likely underlying cause of the observed echocardiographic finding in this patient?

- A. Hypoxia-induced pulmonary vasoconstriction
- B. Increased pulmonary arterial blood flow
- C. Increased pulmonary venous pressure
- D. Inflammatory pulmonary vascular disease
- E. Obliteration of the pulmonary vascular bed
- F. Thrombotic obstruction of the pulmonary arterial tree

Submit

https://t.me/USMLEWorldStep1

A 56-year-old man comes to the emergency department due to progressively worsening dyspnea. The patient can walk only a few blocks before becoming short of breath. He also finds it difficult to sleep lying flat and requires 3 pillows to prop himself upright when sleeping. Other medical problems include long-standing hypertension, for which he occasionally takes his prescribed antihypertensive medication. The patient does not use tobacco, alcohol, or illicit drugs. Blood pressure is 170/100 mm Hg, and pulse is 80/min and regular. Physical examination reveals bilateral basilar lung crackles, jugular venous distension, and bilateral lower extremity edema. Chest x-ray reveals cardiomegaly and hilar prominence. ECG shows left ventricular hypertrophy. Echocardiogram shows elevated pressures in the pulmonary artery. Which of the following is the most likely underlying cause of the observed echocardiographic finding in this patient?

- A. Hypoxia-induced pulmonary vasoconstriction (11%)
- ✗ B. Increased pulmonary arterial blood flow (9%)
- ✓ C. Increased pulmonary venous pressure (71%)
- D. Inflammatory pulmonary vascular disease (1%)
- E. Obliteration of the pulmonary vascular bed (4%)
- F. Thrombotic obstruction of the pulmonary arterial tree (1%)

Incorrect
Correct answer
C

71%
Answered correctly

03 secs
Time Spent

2023
Version

Explanation

https://t.me/USMLEWorldStep1

Correct answer
C

Answered correctly

Time Spent

Version

Exhibit Display

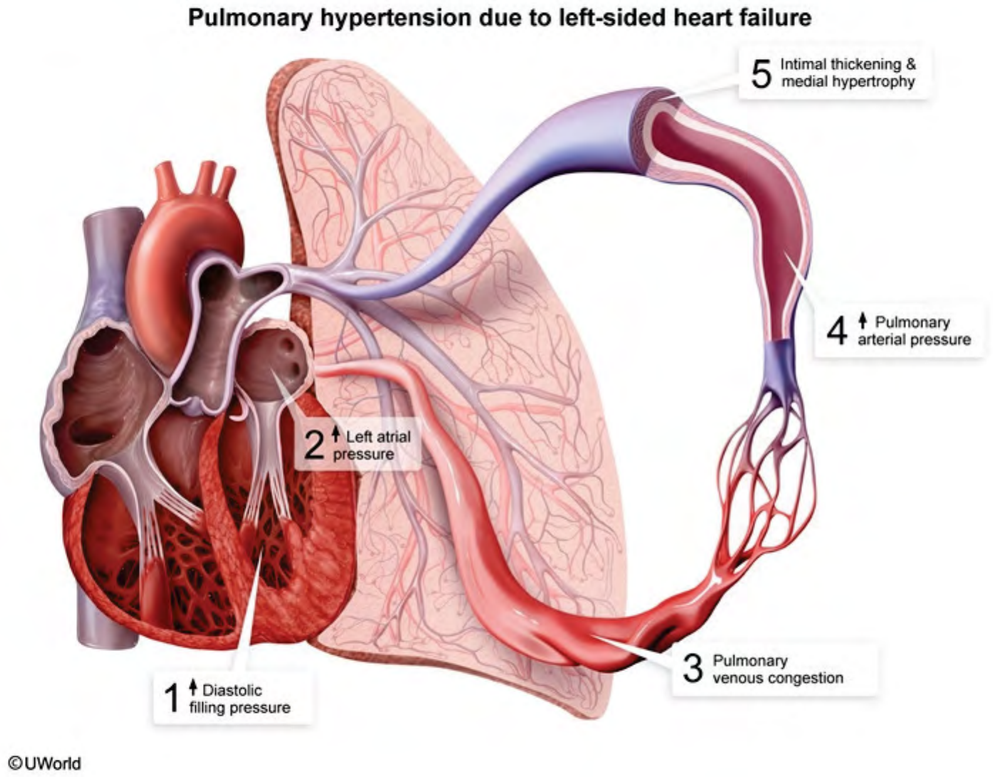

Zoom In | Zoom Out | Reset | New | Existing | My Notebook

This p
long-s
to **con**
(eg, LV
pressure is **transmitted backward** to the left atrium and pulmonary veins, resulting in **pulmonary venous congestion** and consequent elevations in pulmonary capillary and pulmonary arterial pressure. The resulting

https://t.me/USMLEWorldStep1

©UWorld

This patient with dyspnea, orthopnea, and pulmonary crackles has **left-sided heart failure** (LHF) most likely due to long-standing, poorly controlled hypertension. Hypertensive heart disease typically manifests as heart failure due to **concentric left ventricular (LV) hypertrophy** and consequent LV **diastolic dysfunction**. LHF of any cause (eg, LV systolic dysfunction, valvular dysfunction) will result in **higher diastolic filling pressures**. This increase in pressure is **transmitted backward** to the left atrium and pulmonary veins, resulting in **pulmonary venous congestion** and consequent elevations in pulmonary capillary and pulmonary arterial pressure. The resulting **pulmonary hypertension** (PH) can lead to right-sided heart failure with jugular venous distension and peripheral edema.

Over time, **remodeling** of the **pulmonary vasculature** occurs with increased smooth muscle cell proliferation (medial hypertrophy) and collagen deposition (intimal thickening and fibrosis). The remodeling is less extensive than in (primary) pulmonary arterial hypertension; therefore, the PH is at least partially reversible with treatment of the LHF.

(Choices A and E) Hypoxia-induced vasoconstriction and emphysematous obliteration of the vasculature underlie PH that occurs secondary to chronic obstructive pulmonary disease. Although there is a small component of hypoxia-induced pulmonary vasoconstriction in LHF, pulmonary venous congestion is the major cause of PH.

(Choice B) Congenital heart disease that causes left-to-right shunting (eg, ventricular septal defect, atrial septal defect) can lead to PH via an increase in pulmonary arterial blood flow. In LHF, PH occurs due to backwards transmission of pressure from increased pulmonary venous blood volume; pulmonary arterial blood flow remains the same or decreases as LHF worsens.

(Choice D) Inflammatory large-vessel vasculitis (ie, Takayasu arteritis, giant cell arteritis) can sometimes involve the pulmonary arteries and cause PH. However, pulmonary vascular inflammation does not play a role in PH occurring secondary to LHF.

(Choice F) Thrombotic obstruction of the pulmonary arterial tree occurs in acute pulmonary embolism, and some patients can develop chronic thromboembolic PH despite receiving appropriate anticoagulation therapy. However, this patient has no history of thromboembolic disease, and his orthopnea and crackles are more suggestive of PH due to LHF.

https://t.me/USMLEWorldStep1

pulmonary hypertension (PH) can lead to right-sided heart failure with jugular venous distension and peripheral edema.

Over time, **remodeling** of the **pulmonary vasculature** occurs with increased smooth muscle cell proliferation (medial hypertrophy) and collagen deposition (intimal thickening and fibrosis). The remodeling is less extensive than in (primary) pulmonary arterial hypertension; therefore, the PH is at least partially reversible with treatment of the LHF.

(Choices A and E) Hypoxia-induced vasoconstriction and emphysematous obliteration of the vasculature underlie PH that occurs secondary to chronic obstructive pulmonary disease. Although there is a small component of hypoxia-induced pulmonary vasoconstriction in LHF, pulmonary venous congestion is the major cause of PH.

(Choice B) Congenital heart disease that causes left-to-right shunting (eg, ventricular septal defect, atrial septal defect) can lead to PH via an increase in pulmonary arterial blood flow. In LHF, PH occurs due to backwards transmission of pressure from increased pulmonary venous blood volume; pulmonary arterial blood flow remains the same or decreases as LHF worsens.

(Choice D) Inflammatory large-vessel vasculitis (ie, Takayasu arteritis, giant cell arteritis) can sometimes involve the pulmonary arteries and cause PH. However, pulmonary vascular inflammation does not play a role in PH occurring secondary to LHF.

(Choice F) Thrombotic obstruction of the pulmonary arterial tree occurs in acute pulmonary embolism, and some patients can develop chronic thromboembolic PH despite receiving appropriate anticoagulation therapy. However, this patient has no history of thromboembolic disease, and his orthopnea and crackles are more suggestive of PH due to LHF.

Educational objective:
Left-sided heart failure can cause secondary pulmonary hypertension via elevated left-sided diastolic filling pressures transmitting backward to the pulmonary veins, resulting in pulmonary venous congestion. Over time, pulmonary arterial remodeling (medial hypertrophy and intimal thickening with fibrosis) can occur, but not to the extent that occurs in (primary) pulmonary arterial hypertension.

References

https://t.me/USMLEWorldStep1

(eg, LV systolic dysfunction, valvular dysfunction) will result in **higher diastolic filling pressures**. This increase in

Exhibit Display

Classification of pulmonary hypertension	
Pulmonary arterial hypertension (group 1)	• Primary change in pulmonary arteries ◦ Hereditary (eg, *BMPR2* mutation) ◦ Connective tissue disease (eg, RA, SS) ◦ HIV infection • Treatment targeted at endothelial dysfunction
Pulmonary hypertension (groups 2-5)	• Secondary to another disease process ◦ Left-sided heart failure (group 2) ◦ Chronic lung disease/hypoxia (group 3) ◦ Chronic pulmonary thromboembolism (group 4) ◦ Other (eg, sarcoidosis) (group 5) • Treatment aimed at underlying disease
RA = rheumatoid arthritis; **SS** = systemic sclerosis.	

New | Existing | My Notebook

pressures transmitting backward to the pulmonary veins, resulting in pulmonary venous congestion. Over time,

https://t.me/USMLEWorldStep1

A 66-year-old man comes to the office due to increasing shortness of breath over the past 3 weeks. He has had a nonproductive cough for several months, which he attributes to allergies, but also notes a 9-kg (20-lb), unintentional weight loss over this time. The patient has no prior medical conditions and takes no medications. He has a 50-pack-year smoking history. Temperature is 36.7 C (98 F), blood pressure is 120/80 mm Hg, pulse is 72/min, and respirations are 18/min. Chest x-ray is shown below.

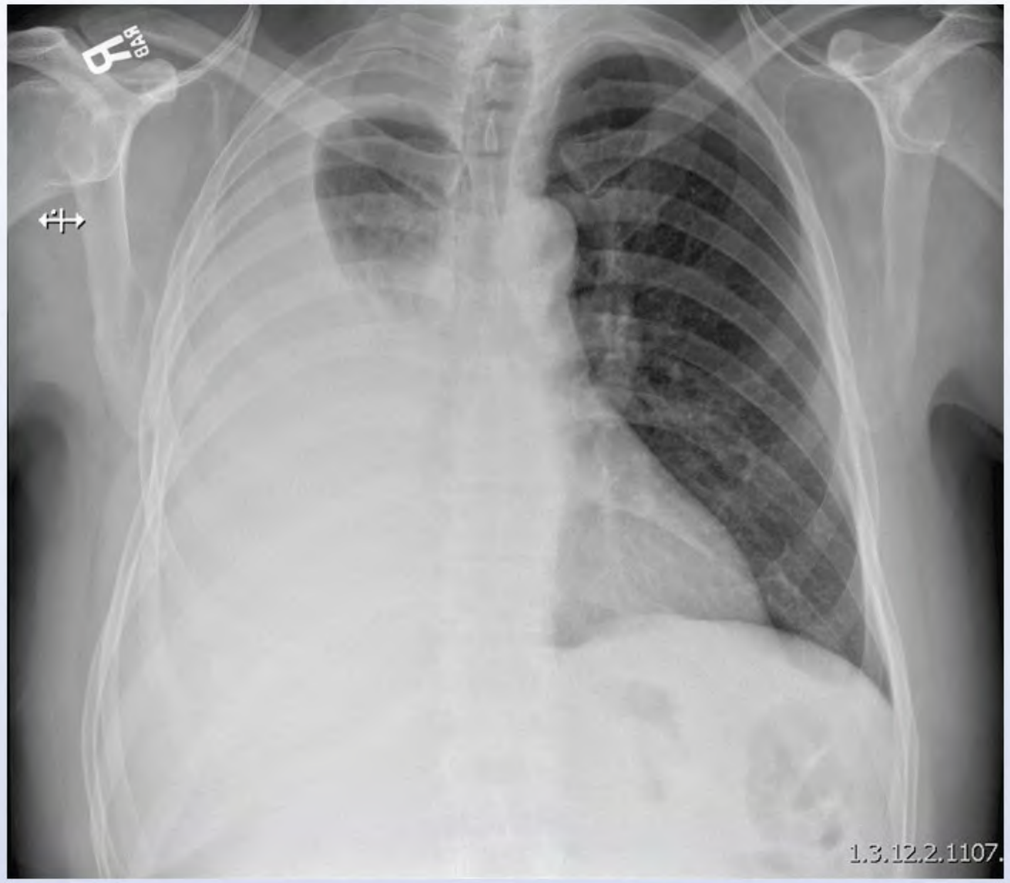

Which of the following would be the expected physical examination finding over the right lower chest?

https://t.me/USMLEWorldStep1

A 66-year-old man comes to the office due to increasing shortness of breath over the past 3 weeks. He has had a nonpr
uninte
has a
72/mir

Exhibit Display

Zoom In Zoom Out Reset New | Existing My Notebook

Which of the following would be the expected physical examination finding over the right lower chest?

https://t.me/USMLEWorldStep1

Which of the following would be the expected physical examination finding over the right lower chest?

- A. Bronchial breath sounds
- B. Decreased tactile fremitus
- C. Fine inspiratory crackles
- D. Focal, monophasic wheeze
- E. Increased resonance on percussion
- F. Rhonchi that clear with cough

Submit

https://t.me/USMLEWorldStep1

Which of the following would be the expected physical examination finding over the right lower chest?

- A. Bronchial breath sounds (12%)
- ✓ B. Decreased tactile fremitus (54%)
- C. Fine inspiratory crackles (13%)
- D. Focal, monophasic wheeze (3%)
- E. Increased resonance on percussion (14%)
- F. Rhonchi that clear with cough (1%)

Correct

54%
Answered correctly

12 secs
Time Spent

2023
Version

https://t.me/USMLEWorldStep1

Explanation

Pulmonary auscultation examination findings			
Condition	**Breath sounds**	**Tactile fremitus**	**Percussion**
Normal lung	Normal	Normal	Resonance
Consolidation	Increased	Increased	Dullness
Pleural effusion	Decreased or absent	Decreased	Dullness
Pneumothorax	Decreased or absent	Decreased	Hyperresonance
Atelectasis	Decreased or absent	Decreased	Dullness

This patient's chest x-ray shows blunting of the right costophrenic angle and opacification of much of the right lung consistent with a large, right-sided **pleural effusion**. His unintentional weight loss and smoking history suggest a malignant etiology.

Pleural effusions are collections of fluid that form between the visceral pleura that lines the lung and the parietal pleura that lines the thoracic cavity. On physical examination, the fluid acts to insulate vibrations and sounds originating within the airways of the lung. Therefore, both **tactile fremitus**, the vibration created by vocalized sound (eg, saying "ninety-nine"), and **breath sounds** are **decreased** over a pleural effusion. In addition, the relatively high density of pleural fluid compared with air creates **dullness to percussion**.

(Choice A) Bronchial breath sounds describe the loud and relatively high-pitched breath sounds that are normally heard over the trachea and main bronchi; breath sounds at the periphery of the lung are typically vesicular (soft and relatively low-pitched) in nature. Bronchial breath sounds in the periphery of the lung suggest alveolar consolidation (eg, pneumonia) or fibrosis, but they should not be present with pleural effusion.

https://t.me/USMLEWorldStep1

Atelectasis	Decreased or absent	Decreased	Dullness

This patient's chest x-ray shows blunting of the right costophrenic angle and opacification of much of the right lung consistent with a large, right-sided **pleural effusion**. His unintentional weight loss and smoking history suggest a malignant etiology.

Pleural effusions are collections of fluid that form between the visceral pleura that lines the lung and the parietal pleura that lines the thoracic cavity. On physical examination, the fluid acts to insulate vibrations and sounds originating within the airways of the lung. Therefore, both **tactile fremitus**, the vibration created by vocalized sound (eg, saying "ninety-nine"), and **breath sounds** are **decreased** over a pleural effusion. In addition, the relatively high density of pleural fluid compared with air creates **dullness to percussion**.

(Choice A) Bronchial breath sounds describe the loud and relatively high-pitched breath sounds that are normally heard over the trachea and main bronchi; breath sounds at the periphery of the lung are typically vesicular (soft and relatively low-pitched) in nature. Bronchial breath sounds in the periphery of the lung suggest alveolar consolidation (eg, pneumonia) or fibrosis, but they should not be present with pleural effusion.

(Choice C) Inspiratory crackles are formed by alveoli and small airways popping open and may be heard with pneumonia and atelectasis. The descriptor "fine" is often used to describe soft, high-pitch inspiratory crackles associated with pulmonary fibrosis.

(Choice D) A focal, monophasic wheeze may suggest partial obstruction of a large airway (eg, due to a foreign body or tumor).

(Choice E) Percussion notes exist on a spectrum. Normal lung, which represents a composite of parenchymal tissue and air, generates sound that is considered resonant to percussion. The relatively lower density of air alone (ie, pneumothorax) causes hyperresonance to percussion.

(Choice F) Rhonchi are coarse rattling or wheezing sounds that are caused by mucus secretions in the airways and may be heard in patients with chronic obstructive pulmonary disease or bronchiectasis. Rhonchi will often clear with coughing. They are not an expected finding with pleural effusion.

Educational objective:

https://t.me/USMLEWorldStep1

Pleural effusions are collections of fluid that form between the visceral pleura that lines the lung and the parietal pleura that lines the thoracic cavity. On physical examination, the fluid acts to insulate vibrations and sounds originating within the airways of the lung. Therefore, both **tactile fremitus**, the vibration created by vocalized sound (eg, saying "ninety-nine"), and **breath sounds** are **decreased** over a pleural effusion. In addition, the relatively high density of pleural fluid compared with air creates **dullness to percussion**.

(Choice A) Bronchial breath sounds describe the loud and relatively high-pitched breath sounds that are normally heard over the trachea and main bronchi; breath sounds at the periphery of the lung are typically vesicular (soft and relatively low-pitched) in nature. Bronchial breath sounds in the periphery of the lung suggest alveolar consolidation (eg, pneumonia) or fibrosis, but they should not be present with pleural effusion.

(Choice C) Inspiratory crackles are formed by alveoli and small airways popping open and may be heard with pneumonia and atelectasis. The descriptor "fine" is often used to describe soft, high-pitch inspiratory crackles associated with pulmonary fibrosis.

(Choice D) A focal, monophasic wheeze may suggest partial obstruction of a large airway (eg, due to a foreign body or tumor).

(Choice E) Percussion notes exist on a spectrum. Normal lung, which represents a composite of parenchymal tissue and air, generates sound that is considered resonant to percussion. The relatively lower density of air alone (ie, pneumothorax) causes hyperresonance to percussion.

(Choice F) Rhonchi are coarse rattling or wheezing sounds that are caused by mucus secretions in the airways and may be heard in patients with chronic obstructive pulmonary disease or bronchiectasis. Rhonchi will often clear with coughing. They are not an expected finding with pleural effusion.

Educational objective:
A pleural effusion is a collection of fluid between the visceral pleura that lines the lungs and the parietal pleura that lines the thoracic cavity. The fluid acts to insulate vibrations and sounds that originate in the airways of the lung; therefore, tactile fremitus and breath sounds are decreased over a pleural effusion. Dullness to percussion is also present.

Pathology	Pulmonary & Critical Care	Pleural effusion
Subject	System	Topic

https://t.me/USMLEWorldStep1

A 62-year-old man is evaluated for shortness of breath. During pulmonary function testing, the patient performs a forceful and complete exhalation after maximal inhalation. The results (red curve) are compared to a healthy individual of the same age and sex (black curve), as shown in the image below:

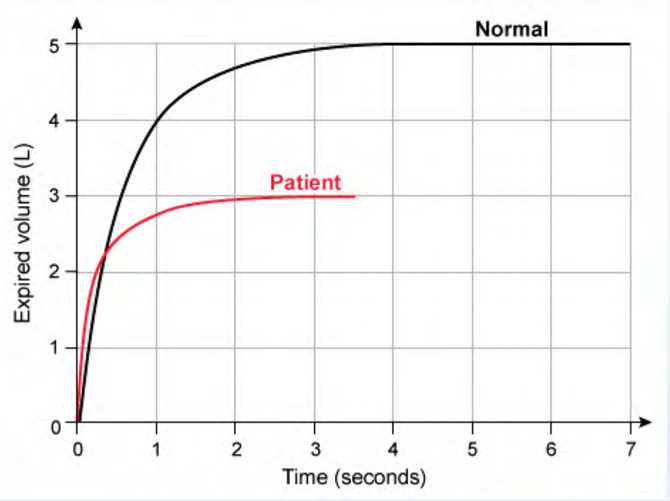

Which of the following is the most likely cause of this patient's dyspnea?

- A. Adult-onset asthma
- B. Chronic obstructive pulmonary disease
- C. Idiopathic pulmonary fibrosis
- D. Unable to determine without bronchodilator testing

Submit

https://t.me/USMLEWorldStep1

A 62-year-old man is evaluated for shortness of breath. During pulmonary function testing, the patient performs a forcefu
individ

Which

Sub

Exhibit Display

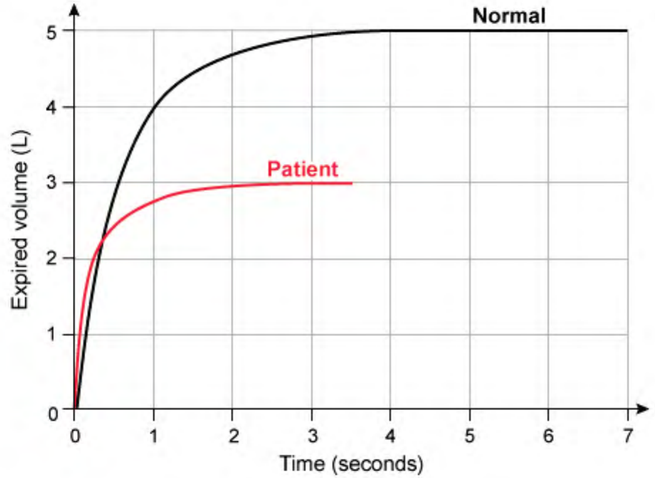

Zoom In Zoom Out Reset New | Existing My Notebook

https://t.me/USMLEWorldStep1

A 62-year-old man is evaluated for shortness of breath. During pulmonary function testing, the patient performs a forceful and complete exhalation after maximal inhalation. The results (red curve) are compared to a healthy individual of the same age and sex (black curve), as shown in the image below:

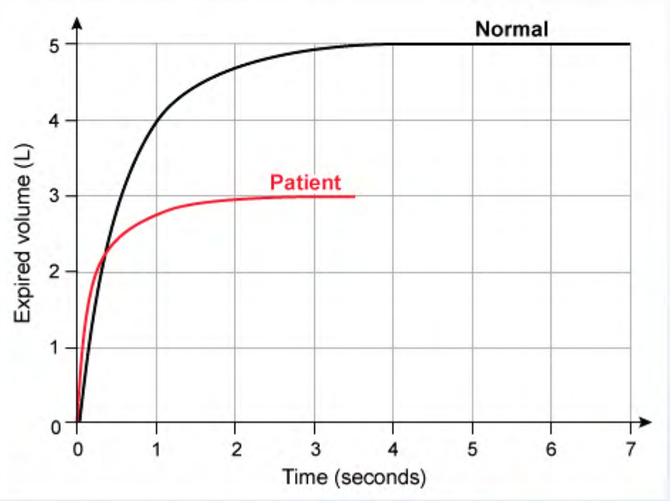

Which of the following is the most likely cause of this patient's dyspnea?

- A. Adult-onset asthma (1%)
- ✗ B. Chronic obstructive pulmonary disease (44%)
- ✓ C. Idiopathic pulmonary fibrosis (37%)
- D. Unable to determine without bronchodilator testing (16%)

Incorrect
Correct answer
C

37%
Answered correctly

08 secs
Time Spent

2023
Version

Explanation

https://t.me/USMLEWorldStep1

Explanation

Exhibit Display

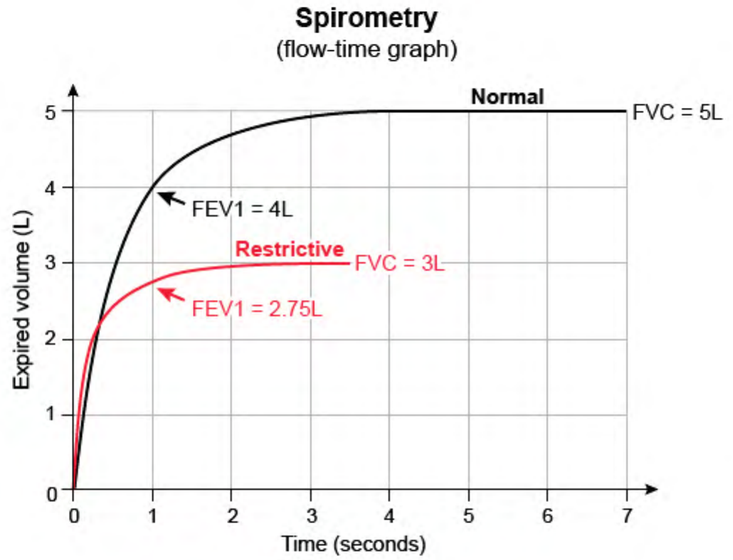

Normal: FEV1/FVC = 4L/5L = 0.8

Restrictive: FEV1/FVC = 2.75L/3L = 0.92

FEV1 = forced expiratory volume in 1 second; **FVC** = forced vital capacity.

©UWorld

Zoom In | Zoom Out | Reset | New | Existing | My Notebook

Pulmo
reach
this qu
secon
repres

The bl
FEV1/
and a
therefore, the patient's dyspnea is most likely due to **interstitial lung disease**. Neuromuscular weakness and

https://t.me/USMLEWorldStep1

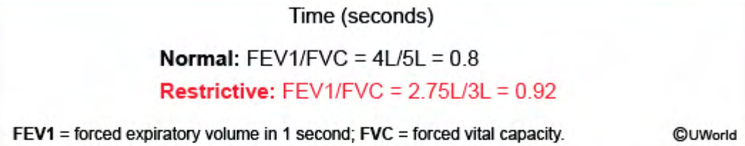

Pulmonary function testing (PFT) usually involves spirometry, during which the patient completely inhales (to reach total lung capacity) and then forcefully exhales as much air as possible as quickly as possible. The graph in this question depicts the measured results following this procedure. The volume of air expelled during the first second of exhalation is the **forced expiratory volume in 1 second** (FEV1), and the total volume of air expelled represents the **forced vital capacity** (FVC).

The black curve on the graph depicts normal PFT results with an FEV1 of 4 liters, an FVC of 5 liters, and an FEV1/FVC ratio of 80%. The patient's red curve shows a reduced FEV1 of 3 liters, a reduced FVC of 3.5 liters, and a slightly increased FEV1/FVC ratio of 86%. These findings are consistent with a **restrictive pattern**; therefore, the patient's dyspnea is most likely due to **interstitial lung disease**. Neuromuscular weakness and obesity hypoventilation syndrome also demonstrate a restrictive pattern on PFT.

(Choices A, B, and D) Asthma and chronic obstructive pulmonary disease (COPD) both demonstrate an obstructive pattern on PFT with reduced FEV1 (eg, 2 liters), normal or reduced FVC (eg, 4.5 liters), and reduced FEV1/FVC ratio (eg, 45%). Bronchodilator testing may be helpful in differentiating asthma and COPD as airway obstruction due to asthma typically has a much higher degree of reversibility than that due to COPD. However, bronchodilator testing does not play a role in evaluating restrictive lung disease.

Educational objective:
Pulmonary function testing involves having the patient inhale completely and then forcefully exhale as much air as possible as quickly as possible. Restrictive lung disease causes reduced total volume of air expelled (ie, reduced forced vital capacity [FVC]), reduced volume of air expelled in 1 second (ie, reduced forced expiratory volume in 1 second [FEV1]), and a normal or sometimes increased FEV1/FVC ratio.

Pathophysiology	Pulmonary & Critical Care	Pulmonary function test
Subject	System	Topic

Copyright © UWorld. All rights reserved.

https://t.me/USMLEWorldStep1

Time (seconds)

Exhibit Display

Spirometry
(flow-time graph)

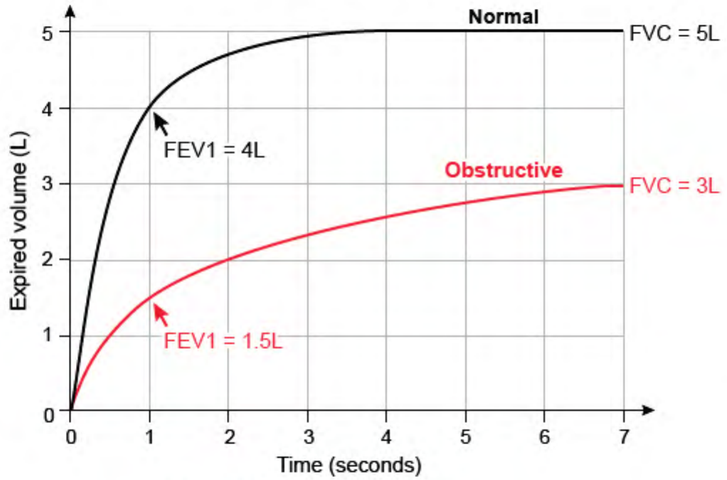

Normal: FEV1/FVC = 4L/5L = 0.8
Obstructive: FEV1/FVC = 1.5L/3L = 0.5

FEV1 = forced expiratory volume in 1 second; **FVC** = forced vital capacity.

©UWorld

Zoom In | Zoom Out | Reset | New | Existing | My Notebook

Pulmo
reach
this qu
secon
repres

The bl
FEV1/
and a
therefo
obesit

(Choi
obstru
FEV1/
obstru
bronch

Educa
Pulmo
possib
forced
secon

Pathoph
Subject

Copyright © UWorld. All rights reserved.

https://t.me/USMLEWorldStep1

Time (seconds)

Exhibit Display

Pulmonary function tests						
Type	**Normal**	**Obstructive lung disease**			**Restrictive lung disease**	
		Emphysema	*Chronic bronchitis*	*Asthma*	*Intrinsic*	*Extrinsic*
DLCO*	Normal	Normal to decreased	Normal	Normal to high	Decreased	Normal
FEV_1	> 80% (of predicted)	Decreased			Decreased	
FEV_1/FVC	> 70%	Decreased			Normal to increased	
FVC	> 80% (of predicted)	Normal to decreased			Decreased	

*DLCO is directly proportional to alveolar surface area and solubility of the gas (eg, more blood volume). DLCO is inversely proportional to membrane thickness.
FEV_1 = forced expiratory volume in 1 second; **FVC** = forced vital capacity; **DLCO** = Diffusing capacity of lung for carbon monoxide.

New | Existing | My Notebook

Pulmo
reach
this qu
secon
repres

The bl
FEV1/
and a
therefo
obesit

(Choi
obstru
FEV1/
obstru
bronch

Educa
Pulmo
possib
forced
secon

Pathoph
Subject

Copyright © UWorld. All rights reserved.

https://t.me/USMLEWorldStep1

Time (seconds)

Exhibit Display

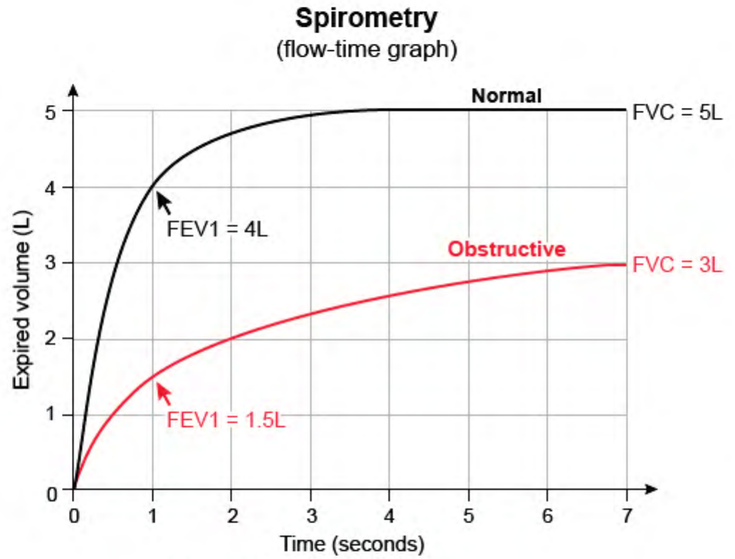

Normal: FEV1/FVC = 4L/5L = 0.8

Obstructive: FEV1/FVC = 1.5L/3L = 0.5

FEV1 = forced expiratory volume in 1 second; **FVC** = forced vital capacity. ©UWorld

Zoom In | Zoom Out | Reset | New | Existing | My Notebook

Pulmo
reach
this qu
secon
repres

The bl
FEV1/
and a
therefo
obesit

(Choi
obstru
FEV1/
obstru
bronch

Educa
Pulmo
possib
forced
secon

Pathoph
Subject

Copyright © UWorld. All rights reserved.

https://t.me/USMLEWorldStep1

A 3-year-old boy who recently immigrated to the United States is brought to the emergency department with fever, malaise, and a painful, swollen right knee. He is hypotensive and tachycardic. Medical history is significant for a recent episode of acute otitis media and several vaccinations that are not up to date. Arthrocentesis of the right knee shows cloudy synovial fluid. Gram stain of the aspirate reveals pleomorphic, gram-negative coccobacilli. Cultures performed on a blood agar plate supplemented with a disk containing hematin and nicotinamide adenine dinucleotide (NAD^+) grow colonies only near the disk. The organism responsible for this patient's condition most likely produces which of the following virulence factors?

- A. Capsule
- B. Cytotoxic exotoxin
- C. Fimbriae
- D. Hemolysins
- E. Hyaluronidase

Submit

https://t.me/USMLEWorldStep1

A 3-year-old boy who recently immigrated to the United States is brought to the emergency department with fever, malaise, and a painful, swollen right knee. He is hypotensive and tachycardic. Medical history is significant for a recent episode of acute otitis media and several vaccinations that are not up to date. Arthrocentesis of the right knee shows cloudy synovial fluid. Gram stain of the aspirate reveals pleomorphic, gram-negative coccobacilli. Cultures performed on a blood agar plate supplemented with a disk containing hematin and nicotinamide adenine dinucleotide (NAD^+) grow colonies only near the disk. The organism responsible for this patient's condition most likely produces which of the following virulence factors?

- ✓ A. Capsule (75%)
- B. Cytotoxic exotoxin (3%)
- C. Fimbriae (5%)
- D. Hemolysins (7%)
- E. Hyaluronidase (7%)

Correct

75% Answered correctly

04 secs Time Spent

2023 Version

Explanation

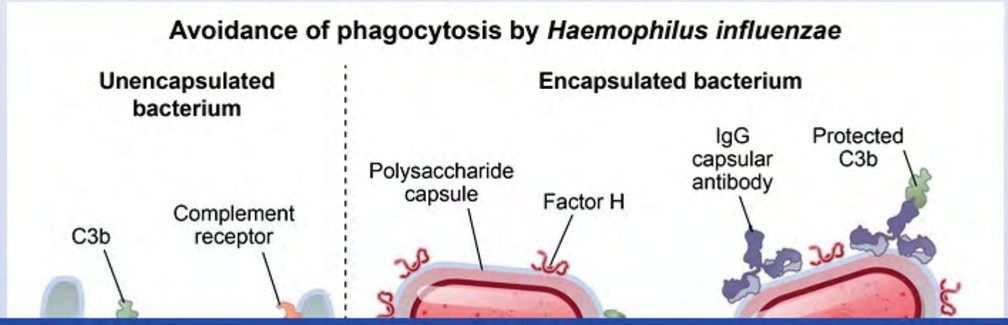

https://t.me/USMLEWorldStep1

E. Hyaluronidase (7%)

Exhibit Display

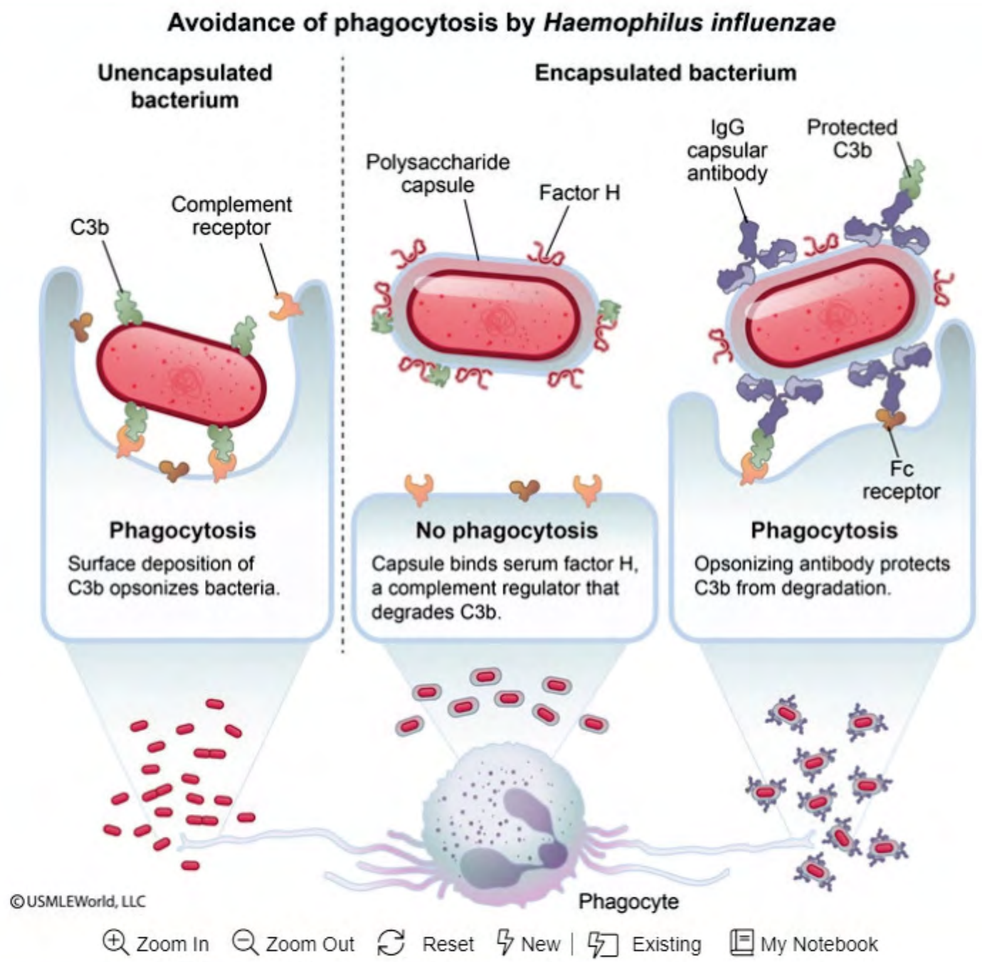

Zoom In | Zoom Out | Reset | New | Existing | My Notebook

https://t.me/USMLEWorldStep1

This patient's arthrocentesis findings are diagnostic for **septic arthritis** due to *Haemophilus influenzae*. *H influenzae* is a small, pleomorphic, **gram-negative coccobacillus** that requires both X factor (**hematin**) and V factor (**NAD^+**) to grow. Because these factors are found within erythrocytes, optimal concentrations are present only in lysed blood agar (chocolate agar). Growth on regular blood agar requires exogenous supplementation of X and V factors, which are typically provided by an impregnated disk.

Localized infections (eg, acute otitis media, sinusitis) are caused predominantly by unencapsulated (nontypeable) strains of *H influenzae*, although ***H influenzae* type b** (Hib) can also cause these infections in **undervaccinated** patients. Type b strains have a polyribosylribitol phosphate polysaccharide **capsule** that prevents phagocytosis. This allows the organism to invade the vasculature and spread hematogenously to distant sites, predisposing to **invasive disease** (eg, septic arthritis, meningitis, bacteremia). In vaccinated patients, antibodies against the type b capsule provide immunity by promoting complement fixation and opsonization. Therefore, invasive Hib infections have been rare since the advent of the Hib immunization.

(Choice B) Cytotoxic exotoxins are secreted by certain bacteria (*Clostridium botulinum*, *Clostridium tetani*, *Corynebacterium diphtheriae*) to promote host cell death. No strains of *H influenzae* produce an exotoxin.

(Choice C) Fimbriae are proteinaceous projections from bacterial cells that attach to target tissues during the initial stages of an infectious process. Fimbriae on *H influenzae* enable attachment to endothelial cells during colonization of the respiratory tract but are not the major virulence factor contributing to invasive disease.

(Choice D) *Staphylococcus aureus* produces alpha-hemolysin, which causes infection by destroying the cell membrane of red and white blood cells. Hemolysins are not secreted by *H influenzae*.

(Choice E) Hyaluronidase is an enzyme used by bacteria (eg, *S aureus*, *Streptococcus pyogenes*, *Clostridium perfringens*) to digest extracellular ground substance and enhance their ability to spread. Hyaluronidase is not produced by *H influenzae*.

Educational objective:
Haemophilus influenzae is a gram-negative coccobacillus that requires both X factor (hematin) and V factor (NAD^+) to grow. *H influenzae* type b has an antiphagocytic polysaccharide capsule, which allows it to spread hematogenously and cause invasive disease such as septic arthritis and meningitis.

https://t.me/USMLEWorldStep1

A 55-year-old woman comes to the office due to a persistent cough, exertional dyspnea, and recent, unintentional weight loss. She has no chronic medical problems and takes no medication regularly. She has never smoked and has no history of exposure to industrial pollutants. She works as an accountant at a large accounting firm. Vital signs are normal. Physical examination reveals decreased breath sounds and dullness to percussion at the left lung base. Imaging studies show an irregular mass in the lower lobe of the left lung and a left pleural effusion. A diagnostic thoracocentesis is performed and the aspirated fluid is sent for cytological evaluation. If a malignancy is diagnosed, it is most likely to be which of the following types?

- A. Adenocarcinoma
- B. Bronchial carcinoid
- C. Mesothelioma
- D. Small cell carcinoma
- E. Squamous cell carcinoma

Submit

https://t.me/USMLEWorldStep1

A 55-year-old woman comes to the office due to a persistent cough, exertional dyspnea, and recent, unintentional weight loss. She has no chronic medical problems and takes no medication regularly. She has never smoked and has no history of exposure to industrial pollutants. She works as an accountant at a large accounting firm. Vital signs are normal. Physical examination reveals decreased breath sounds and dullness to percussion at the left lung base. Imaging studies show an irregular mass in the lower lobe of the left lung and a left pleural effusion. A diagnostic thoracocentesis is performed and the aspirated fluid is sent for cytological evaluation. If a malignancy is diagnosed, it is most likely to be which of the following types?

- ✓ A. Adenocarcinoma (82%)
- B. Bronchial carcinoid (2%)
- C. Mesothelioma (5%)
- D. Small cell carcinoma (4%)
- E. Squamous cell carcinoma (4%)

Correct

82% Answered correctly

03 secs Time Spent

2023 Version

Explanation

Lung cancer			
Tumor type	**Incidence**	**Location**	**Clinical associations**
Adenocarcinoma	40%-50%	Peripheral	• Clubbing • Hypertrophic osteoarthropathy
Squamous cell carcinoma	20%-25%	Central	• Hypercalcemia • Necrosis & cavitation

https://t.me/USMLEWorldStep1

Lung cancer			
Tumor type	**Incidence**	**Location**	**Clinical associations**
Adenocarcinoma	40%-50%	Peripheral	• Clubbing • Hypertrophic osteoarthropathy
Squamous cell carcinoma	20%-25%	Central	• Hypercalcemia • Necrosis & cavitation
Small cell carcinoma	10%-15%	Central	• Cushing syndrome • SIADH • Lambert-Eaton syndrome
Large cell carcinoma	5%-10%	Peripheral	• Gynecomastia • Galactorrhea
SIADH = syndrome of inappropriate antidiuretic hormone.			

This nonsmoking woman with cough and weight loss has a peripheral lung mass with an associated pleural effusion. This presentation is concerning for **adenocarcinoma** of the lung, the **most common lung cancer** in the general population, **women**, and **nonsmokers**. Although tobacco is the most significant risk factor, the etiology in nonsmokers is thought to be multifactorial. Risk factors include environmental exposures (eg, radon, second-hand smoke) and underlying lung disease. In addition, certain molecular alterations are seen more commonly in nonsmokers; these "driver mutations" are thought to be responsible for the development of the malignancy and include epidermal growth factor receptor **(EGFR) mutations** and ***ALK* gene rearrangements**. *KRAS* mutations, another driver in the formation of adenocarcinoma, are seen more commonly in smokers.

Adenocarcinoma typically presents with cough, weight loss, and hemoptysis. Changes to the distal extremities, including **clubbing** (increased curvature of the nail plate) and hypertrophic osteoarthropathy (proliferation of the bones, skin, and nails of the fingers), may occur and are thought to be due to tumor-derived growth factors. The tumor tends to be **located peripherally** (as in this patient) and may present as a nodule, mass, or obstructive

https://t.me/USMLEWorldStep1

This nonsmoking woman with cough and weight loss has a peripheral lung mass with an associated pleural effusion. This presentation is concerning for **adenocarcinoma** of the lung, the **most common lung cancer** in the general population, **women**, and **nonsmokers**. Although tobacco is the most significant risk factor, the etiology in nonsmokers is thought to be multifactorial. Risk factors include environmental exposures (eg, radon, second-hand smoke) and underlying lung disease. In addition, certain molecular alterations are seen more commonly in nonsmokers; these "driver mutations" are thought to be responsible for the development of the malignancy and include epidermal growth factor receptor **(EGFR) mutations** and ***ALK* gene rearrangements**. *KRAS* mutations, another driver in the formation of adenocarcinoma, are seen more commonly in smokers.

Adenocarcinoma typically presents with cough, weight loss, and hemoptysis. Changes to the distal extremities, including **clubbing** (increased curvature of the nail plate) and hypertrophic osteoarthropathy (proliferation of the bones, skin, and nails of the fingers), may occur and are thought to be due to tumor-derived growth factors. The tumor tends to be **located peripherally** (as in this patient) and may present as a nodule, mass, or obstructive pneumonia. Like all malignancies, metastatic disease to the pleura can cause pleural effusions.

(Choice B) Bronchial carcinoid is a rare malignancy that tends to be located centrally, within or adjacent to large bronchi. It typically presents with wheezing due to bronchial obstruction and occasionally also causes carcinoid syndrome (ie, episodic diarrhea, flushing, bronchospasm).

(Choice C) Mesothelioma most commonly arises from the mesothelium lining the pleural cavity; tumors are pleural based (ie, pleural mass with associated pleural effusion, pleural thickening), rather than intraparenchymal. In addition, it is extremely rare in nonsmokers with no history of asbestos exposure.

(Choice D) Small cell carcinoma is strongly associated with smoking; only 1% of cases occur in nonsmokers. It arises from the basal cells of the bronchial epithelium and displays some neuroendocrine features. Small cell carcinoma usually occurs in major bronchi.

(Choice E) Squamous cell carcinoma is also strongly associated with smoking. It usually affects larger bronchi (centrally located) and arises from areas of squamous bronchial metaplasia.

Educational objective:
Adenocarcinoma is the most common primary lung cancer in the general population, women, and nonsmokers.

https://t.me/USMLEWorldStep1

nonsmokers is thought to be multifactorial. Risk factors include environmental exposures (eg, radon, second-hand smoke) and underlying lung disease. In addition, certain molecular alterations are seen more commonly in nonsmokers; these "driver mutations" are thought to be responsible for the development of the malignancy and include epidermal growth factor receptor **(EGFR) mutations** and ***ALK* gene rearrangements**. *KRAS* mutations, another driver in the formation of adenocarcinoma, are seen more commonly in smokers.

Adenocarcinoma typically presents with cough, weight loss, and hemoptysis. Changes to the distal extremities, including **clubbing** (increased curvature of the nail plate) and hypertrophic osteoarthropathy (proliferation of the bones, skin, and nails of the fingers), may occur and are thought to be due to tumor-derived growth factors. The tumor tends to be **located peripherally** (as in this patient) and may present as a nodule, mass, or obstructive pneumonia. Like all malignancies, metastatic disease to the pleura can cause pleural effusions.

(Choice B) Bronchial carcinoid is a rare malignancy that tends to be located centrally, within or adjacent to large bronchi. It typically presents with wheezing due to bronchial obstruction and occasionally also causes carcinoid syndrome (ie, episodic diarrhea, flushing, bronchospasm).

(Choice C) Mesothelioma most commonly arises from the mesothelium lining the pleural cavity; tumors are pleural based (ie, pleural mass with associated pleural effusion, pleural thickening), rather than intraparenchymal. In addition, it is extremely rare in nonsmokers with no history of asbestos exposure.

(Choice D) Small cell carcinoma is strongly associated with smoking; only 1% of cases occur in nonsmokers. It arises from the basal cells of the bronchial epithelium and displays some neuroendocrine features. Small cell carcinoma usually occurs in major bronchi.

(Choice E) Squamous cell carcinoma is also strongly associated with smoking. It usually affects larger bronchi (centrally located) and arises from areas of squamous bronchial metaplasia.

Educational objective:
Adenocarcinoma is the most common primary lung cancer in the general population, women, and nonsmokers. Epidermal growth factor receptor (EGFR) mutations and *ALK* gene rearrangements are seen more commonly in nonsmokers and thought to contribute to disease formation in this subgroup. Adenocarcinoma is typically located peripherally and may be associated with clubbing or hypertrophic osteoarthropathy.

https://t.me/USMLEWorldStep1

Large cell carcinoma	5%-10%	Peripheral	• Gynecomastia • Galactorrhea

Exhibit Display

Digital clubbing

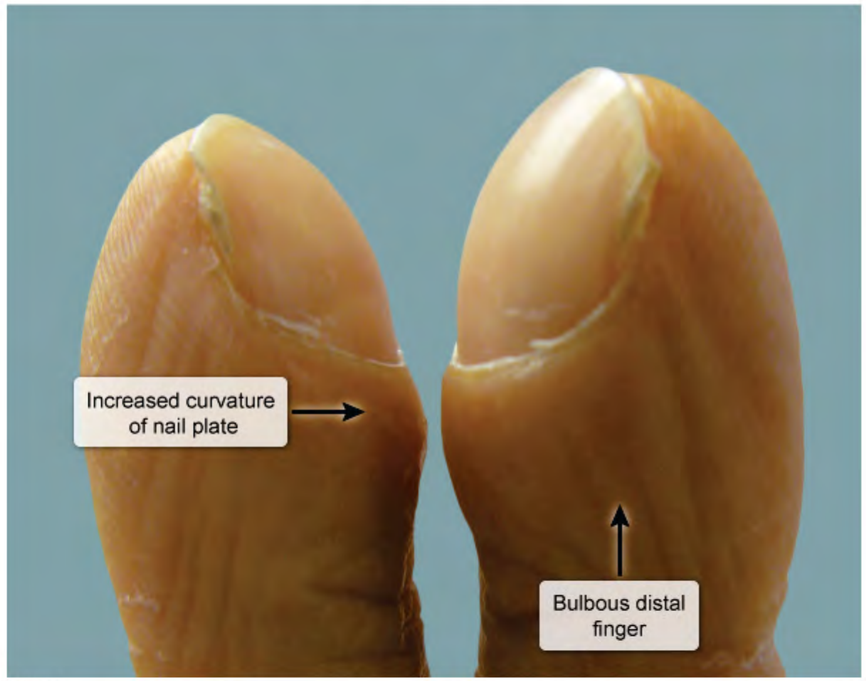

©UWorld

Zoom In | Zoom Out | Reset | New | Existing | My Notebook

This n
effusic
genera
nonsm
smoke
nonsm
include
anothe

Adenc
includi
bones
tumor
pneum

(Choic
bronch
syndro

(Choic
based
additic

(Choic
arises
carcin

(Choice E) Squamous cell carcinoma is also strongly associated with smoking. It usually affects larger bronchi

https://t.me/USMLEWorldStep1

A 63-year-old woman comes to the office due to shortness of breath and cough productive of thick, green sputum for the past 2 days. The patient has chronic obstructive pulmonary disease and mild dyspnea on exertion at baseline. The dyspnea has worsened over the past several days, and she is now also short of breath at rest. Other medical conditions include hypertension, gastroesophageal reflux, and seasonal allergies. She has been using her albuterol rescue inhaler more frequently than usual. The patient says she has cut down to 4 or 5 cigarettes per day and is trying to quit. Pulse oximetry shows 91% on room air. She appears to be in mild respiratory distress. Lung examination demonstrates diffuse bilateral wheezes. Chest x-ray reveals hyperinflation and increased bronchial markings. There is no evidence of alveolar infiltrates in either lung. Which of the following is most likely responsible for the acute worsening of this patient's symptoms?

- A. Air pollution
- B. Gastroesophageal reflux
- C. Pulmonary embolism
- D. Rhinovirus infection
- E. Staphylococcal infection

Submit

https://t.me/USMLEWorldStep1

A 63-year-old woman comes to the office due to shortness of breath and cough productive of thick, green sputum for the past 2 days. The patient has chronic obstructive pulmonary disease and mild dyspnea on exertion at baseline. The dyspnea has worsened over the past several days, and she is now also short of breath at rest. Other medical conditions include hypertension, gastroesophageal reflux, and seasonal allergies. She has been using her albuterol rescue inhaler more frequently than usual. The patient says she has cut down to 4 or 5 cigarettes per day and is trying to quit. Pulse oximetry shows 91% on room air. She appears to be in mild respiratory distress. Lung examination demonstrates diffuse bilateral wheezes. Chest x-ray reveals hyperinflation and increased bronchial markings. There is no evidence of alveolar infiltrates in either lung. Which of the following is most likely responsible for the acute worsening of this patient's symptoms?

- A. Air pollution (16%)
- ✗ B. Gastroesophageal reflux (9%)
- C. Pulmonary embolism (4%)
- ✓ D. Rhinovirus infection (37%)
- E. Staphylococcal infection (32%)

Incorrect
Correct answer
D

37%
Answered correctly

04 secs
Time Spent

2023
Version

Explanation

Acute exacerbation of chronic obstructive pulmonary disease	
Precipitants	• Infectious (70%) ◦ Viral: rhinovirus, influenza, RSV ◦ Bacterial: *Haemophilus influenzae* (nontypeable), *Moraxella catarrhalis*, *Streptococcus pneumoniae*

https://t.me/USMLEWorldStep1

Acute exacerbation of chronic obstructive pulmonary disease	

Precipitants	• Infectious (70%)
	  ◦ Viral: rhinovirus, influenza, RSV
	  ◦ Bacterial: *Haemophilus influenzae* (nontypeable), *Moraxella catarrhalis, Streptococcus pneumoniae*
	• Noninfectious (30%)*

Pathophysiology & presentation	• Inflammation/infection mainly** contained within bronchi (vs alveoli) • ↓ Expiratory airflow, ↑ hyperinflation, ↑ V/Q mismatch (hypoxia, hypercapnia) • Cardinal symptoms: ↑ dyspnea, ↑ sputum volume &/or purulence
Management	• Maximize expiratory flow (inhaled bronchodilators) • Reduce airway inflammation (systemic glucocorticoids) • Treat potential underlying infection (± antibiotics &/or antivirals)
*For example, spontaneous sterile inflammation (underlying disease), pulmonary embolism, inhaled irritants. **In some cases, acute exacerbation of chronic obstructive pulmonary disease is precipitated by community-acquired pneumonia (alveolar opacities, fever, or leukocytosis). **RSV** = respiratory syncytial virus; **V/Q** = ventilation/perfusion.	

This patient with a history of chronic obstructive pulmonary disease (**COPD**) has increasing dyspnea and purulent (thick, green) sputum production consistent with an **acute exacerbation** (AECOPD). Precipitants of AECOPD are categorized into infectious and noninfectious etiologies. Respiratory tract infections are the most common cause of AECOPD.

- The 3 most common viral precipitants are **rhinovirus**, influenza viruses, and respiratory syncytial virus. Other important viruses include adenovirus, parainfluenza, coronavirus, and human metapneumovirus.
- The 3 bacteria most commonly recovered from respiratory cultures during AECOPD are nontypeable *Haemophilus influenzae, Moraxella catarrhalis*, and *Streptococcus pneumoniae*.

https://t.me/USMLEWorldStep1

pneumonia (alveolar opacities, fever, or leukocytosis).

RSV = respiratory syncytial virus; **V/Q** = ventilation/perfusion.

This patient with a history of chronic obstructive pulmonary disease (**COPD**) has increasing dyspnea and purulent (thick, green) sputum production consistent with an **acute exacerbation** (AECOPD). Precipitants of AECOPD are categorized into infectious and noninfectious etiologies. Respiratory tract infections are the most common cause of AECOPD.

- The 3 most common viral precipitants are **rhinovirus**, influenza viruses, and respiratory syncytial virus. Other important viruses include adenovirus, parainfluenza, coronavirus, and human metapneumovirus.
- The 3 bacteria most commonly recovered from respiratory cultures during AECOPD are nontypeable *Haemophilus influenzae*, *Moraxella catarrhalis*, and *Streptococcus pneumoniae*.

Infection promotes worsening of underlying lower respiratory tract inflammation (eg, increased bronchial markings) and airflow obstruction (eg, hyperinflation) in COPD. Purulent **green sputum** results from the release of myeloperoxidase from activated neutrophils, which are recruited to the airways as part of the general innate inflammatory response. Therefore, green sputum coloration is a nonspecific indicator of **infection** and does not reliably distinguish between viral and bacterial pathogens.

(Choices A and C) AECOPD can also be triggered by sterile inflammation (noninfectious causes) in a minority of cases. Environmental air pollution and pulmonary embolism are implicated in noninfectious exacerbations. However, this patient's purulent green sputum supports an infectious rather than sterile etiology. Moreover, pulmonary embolism typically presents more acutely (within minutes to hours) with chest pain and dyspnea but without significant sputum production.

(Choice B) Gastroesophageal reflux disease appears to be a weak risk factor for AECOPD, and uncontrolled reflux may be solely responsible for some cases of noninfectious exacerbations. However, this patient's green sputum makes an infectious etiology more likely.

(Choice E) *Staphylococcus aureus* is a very uncommon cause of AECOPD. It typically follows viral respiratory infection (eg, postinfluenza) and presents as a severe lobar pneumonia with alveolar consolidation and cavitations (elaboration on cytolytic toxins) on chest imaging.

https://t.me/USMLEWorldStep1

- The 3 most common viral precipitants are **rhinovirus**, influenza viruses, and respiratory syncytial virus. Other important viruses include adenovirus, parainfluenza, coronavirus, and human metapneumovirus.
- The 3 bacteria most commonly recovered from respiratory cultures during AECOPD are nontypeable *Haemophilus influenzae*, *Moraxella catarrhalis*, and *Streptococcus pneumoniae*.

Infection promotes worsening of underlying lower respiratory tract inflammation (eg, increased bronchial markings) and airflow obstruction (eg, hyperinflation) in COPD. Purulent **green sputum** results from the release of myeloperoxidase from activated neutrophils, which are recruited to the airways as part of the general innate inflammatory response. Therefore, green sputum coloration is a nonspecific indicator of **infection** and does not reliably distinguish between viral and bacterial pathogens.

(Choices A and C) AECOPD can also be triggered by sterile inflammation (noninfectious causes) in a minority of cases. Environmental air pollution and pulmonary embolism are implicated in noninfectious exacerbations. However, this patient's purulent green sputum supports an infectious rather than sterile etiology. Moreover, pulmonary embolism typically presents more acutely (within minutes to hours) with chest pain and dyspnea but without significant sputum production.

(Choice B) Gastroesophageal reflux disease appears to be a weak risk factor for AECOPD, and uncontrolled reflux may be solely responsible for some cases of noninfectious exacerbations. However, this patient's green sputum makes an infectious etiology more likely.

(Choice E) *Staphylococcus aureus* is a very uncommon cause of AECOPD. It typically follows viral respiratory infection (eg, postinfluenza) and presents as a severe lobar pneumonia with alveolar consolidation and cavitations (elaboration on cytolytic toxins) on chest imaging.

Educational objective:
Viral and bacterial respiratory infections are the leading cause of acute exacerbations of chronic obstructive pulmonary disease. The most common viral pathogens are rhinoviruses, influenza, and respiratory syncytial virus.

References

- COPD exacerbations. 2: aetiology.
- Chronic obstructive pulmonary disease exacerbations: latest evidence and clinical implications.

https://t.me/USMLEWorldStep1

A 36-year-old woman comes to the office due to arthralgias and nodules on her legs. She has no prior medical conditions and takes no medications. On physical examination, there is moderate hepatomegaly. A representative skin rash is shown in the image below. The lesions are tender and present predominantly on the anterior surface of the lower extremities.

https://t.me/USMLEWorldStep1

A 36-year-old woman comes to the office due to arthralgias and nodules on her legs. She has no prior medical
conditi
skin ra
of the

Exhibit Display

Zoom In Zoom Out Reset New | Existing My Notebook

https://t.me/USMLEWorldStep1

Chest x-ray demonstrates enlarged hilar lymph nodes, and laboratory testing reveals an elevated ACE level.

Which of the following would most likely be found on liver biopsy in this patient?

- A. Centrilobular necrosis
- B. Fatty change
- C. Nodular regeneration
- D. Periportal fibrosis
- E. Portal inflammation
- F. Scattered granulomas

Submit

https://t.me/USMLEWorldStep1

Chest x-ray demonstrates enlarged hilar lymph nodes, and laboratory testing reveals an elevated ACE level.
Which of the following would most likely be found on liver biopsy in this patient?

- A. Centrilobular necrosis (4%)
- B. Fatty change (1%)
- C. Nodular regeneration (3%)
- D. Periportal fibrosis (7%)
- E. Portal inflammation (4%)
- ✓ F. Scattered granulomas (79%)

Correct

79%
Answered correctly

19 secs
Time Spent

2023
Version

https://t.me/USMLEWorldStep1

Explanation

Common features of sarcoidosis	
Epidemiology	• Young adults • African Americans

Clinical	• Constitutional symptoms
	• Cough, dyspnea & chest pain
	• Extrapulmonary findings
	  ◦ Skin lesions
	  ◦ Anterior/posterior uveitis
	  ◦ Löfgren syndrome
	• Parotid gland swelling

Imaging	• Bilateral hilar adenopathy • Pulmonary reticular infiltrates
Laboratory	• Hypercalcemia/hypercalciuria • Elevated serum ACE level
Pathology	• Biopsy showing noncaseating granulomas that stain negative for fungi & acid-fast bacilli

This patient has tender erythematous nodules on the anterior lower extremities, consistent with **erythema nodosum**, a nonspecific, delayed hypersensitivity reaction that can be seen in a variety of infections or inflammatory disorders. However, in combination with hilar adenopathy and elevated ACE levels (formed by activated macrophages), this presentation is highly suggestive of **sarcoidosis**. Sarcoidosis is a systemic inflammatory disorder of unknown etiology characterized pathologically by noncaseating granulomas.

Granulomas can occur in any organ but commonly involve the lymph nodes (eg, **bilateral hilar adenopathy**), lungs (interstitial lung disease), joints (eg, **arthralgias**), eyes (uveitis), or skin. Most patients with sarcoidosis also develop **liver involvement**, typically in the form of **asymptomatic hepatomegaly** with mild liver function test

https://t.me/USMLEWorldStep1

This patient has tender erythematous nodules on the anterior lower extremities, consistent with **erythema nodosum**, a nonspecific, delayed hypersensitivity reaction that can be seen in a variety of infections or inflammatory disorders. However, in combination with hilar adenopathy and elevated ACE levels (formed by activated macrophages), this presentation is highly suggestive of **sarcoidosis**. Sarcoidosis is a systemic inflammatory disorder of unknown etiology characterized pathologically by noncaseating granulomas.

Granulomas can occur in any organ but commonly involve the lymph nodes (eg, **bilateral hilar adenopathy**), lungs (interstitial lung disease), joints (eg, **arthralgias**), eyes (uveitis), or skin. Most patients with sarcoidosis also develop **liver involvement**, typically in the form of **asymptomatic hepatomegaly** with mild liver function test abnormalities (alkaline phosphatase > aminotransferases). Biopsy will show **scattered noncaseating granulomas**, predominantly around the portal veins.

(Choice A) Centrilobular necrosis is the death of hepatocytes immediately surrounding the terminal hepatic vein. Ischemic injury (as in right-sided heart failure), drugs, toxins, and fulminant hepatitis can be responsible.

(Choice B) Fatty change (steatosis) is most commonly seen in alcohol use or obesity, although it can also be seen with a reversible hypoxic, toxic, or metabolic injury (eg, protein malnutrition).

(Choice C) Nodular regeneration is seen with cirrhosis. Sarcoidosis does not typically progress to hepatic cirrhosis.

(Choice D) Periportal fibrosis may be seen in chronic cholestasis (eg, primary sclerosing cholangitis, primary biliary cholangitis) or chronic viral hepatitis; it is not associated with sarcoidosis.

(Choice E) Portal inflammation is a very nonspecific finding that occurs with many forms of hepatitis, toxin- and drug-induced liver injury, and metabolic and cholestatic liver diseases.

Educational objective:
Sarcoidosis is a systemic inflammatory disorder characterized by noncaseating granulomas in a variety of tissues. Most patients develop liver involvement, which typically manifests as asymptomatic hepatomegaly with mild liver function test abnormalities. Liver biopsy frequently demonstrates scattered noncaseating granulomas.

Pathology Pulmonary & Critical Care Sarcoidosis

https://t.me/USMLEWorldStep1

A 65-year-old man with chronic bronchitis comes to the emergency department due to 2 days of fever, chills, chest pain, and productive cough. He has been hospitalized on several occasions for exacerbations of chronic bronchitis. The patient has been advised to stop smoking but continues to smoke cigarettes. He drinks 6–10 beers daily. Temperature is 40.2 C (104.4 F), blood pressure is 100/70 mm Hg, pulse is 104/min, and respirations are 28/min. On examination, he is in mild respiratory distress. There are crackles and decreased breath sounds in the right upper lobe. His chest x-ray shows right upper lobe consolidation. Sputum microscopy reveals encapsulated gram-negative bacilli. The bacteria grow pink, mucoid colonies on MacConkey agar. Which of the following organisms is the most likely cause of this patient's condition?

- A. *Haemophilus influenzae*
- B. *Klebsiella pneumoniae*
- C. *Legionella pneumophila*
- D. *Moraxella catarrhalis*
- E. *Mycoplasma pneumoniae*
- F. *Pseudomonas aeruginosa*
- G. *Streptococcus pneumoniae*

Submit

https://t.me/USMLEWorldStep1

A 65-year-old man with chronic bronchitis comes to the emergency department due to 2 days of fever, chills, chest pain, and productive cough. He has been hospitalized on several occasions for exacerbations of chronic bronchitis. The patient has been advised to stop smoking but continues to smoke cigarettes. He drinks 6–10 beers daily. Temperature is 40.2 C (104.4 F), blood pressure is 100/70 mm Hg, pulse is 104/min, and respirations are 28/min. On examination, he is in mild respiratory distress. There are crackles and decreased breath sounds in the right upper lobe. His chest x-ray shows right upper lobe consolidation. Sputum microscopy reveals encapsulated gram-negative bacilli. The bacteria grow pink, mucoid colonies on MacConkey agar. Which of the following organisms is the most likely cause of this patient's condition?

- A. *Haemophilus influenzae* (7%)
- ✓ B. *Klebsiella pneumoniae* (82%)
- ✗ C. *Legionella pneumophila* (1%)
- D. *Moraxella catarrhalis* (2%)
- E. *Mycoplasma pneumoniae* (1%)
- F. *Pseudomonas aeruginosa* (4%)
- G. *Streptococcus pneumoniae* (1%)

Incorrect
Correct answer
B

82%
Answered correctly

04 secs
Time Spent

2023
Version

Explanation



https://t.me/USMLEWorldStep1

Exhibit Display

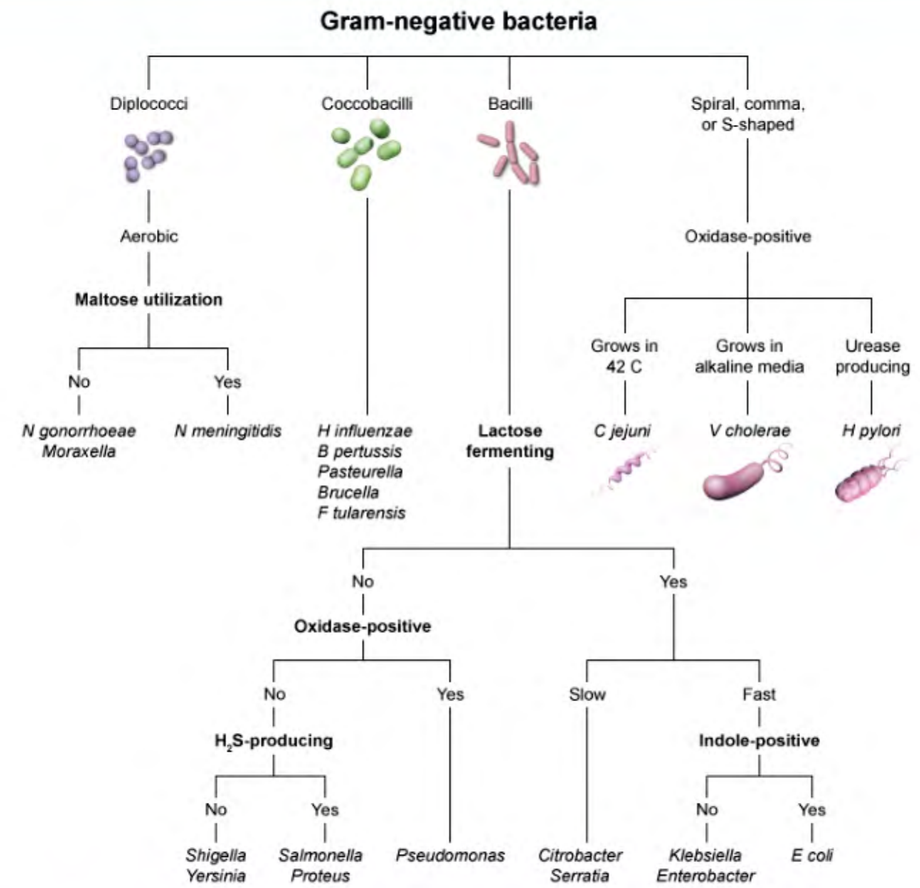

Zoom In | Zoom Out | Reset | New | Existing | My Notebook

Gram-

comm

or impaired host defenses (eg, infants, the elderly, patients with alcohol use disorder) are at increased risk. The

most common pathogens are *Escherichia coli*, *Klebsiella pneumoniae*, *Pseudomonas aeruginosa*, *Enterobacter*

https://t.me/USMLEWorldStep1

Shigella
Yersinia
Salmonella
Proteus
Pseudomonas
Citrobacter
Serratia
Klebsiella
Enterobacter
E coli

Gram-negative bacilli are the leading cause of nosocomial pneumonia but are a relatively rare (<5%) cause of community-acquired pneumonia. However, patients with underlying immunosuppression (especially neutropenia) or impaired host defenses (eg, infants, the elderly, patients with alcohol use disorder) are at increased risk. The most common pathogens are *Escherichia coli*, *Klebsiella pneumoniae*, *Pseudomonas aeruginosa*, *Enterobacter*, *Serratia*, *Proteus*, and *Acinetobacter*.

Klebsiella is a gram-negative bacillus that turns MacConkey agar pink due to its ability to **ferment lactose**. The presence of a **thick capsule** is seen as a clear zone on Gram stain and also causes the characteristic mucoid growth in culture. *Klebsiella* pneumonia classically affects patients with **alcohol use disorder**. Most cases arise due to colonization of the oropharynx followed by microaspiration of upper airway secretions. Because the aspiration usually occurs while supine (during sleep), the posterior segments of the **upper lobes** (particularly the right lung) are classically affected. The hallmarks of *Klebsiella* pneumonia are thick, mucoid, blood-tinged sputum (**currant jelly sputum**) and liquefying necrosis of the lung with early abscess formation.

(Choice A) *Haemophilus influenzae* is a leading cause of community-acquired pneumonia and bacterial meningitis. It is a gram-negative coccobacillus that can form mucoid colonies but does not ferment lactose.

(Choice C) *Legionella pneumophila* is a gram-negative bacillus that causes atypical pneumonia, generally following aerosolization from a contaminated water supply. However, *Legionella* is not an encapsulated organism and does not produce mucoid colonies.

(Choice D) *Moraxella catarrhalis* is a gram-negative diplococcus that is a common cause of upper respiratory infections (eg, bronchitis, laryngitis, sinusitis) and otitis media. It can also cause bronchopneumonia in patients with COPD. However, this pathogen does not ferment lactose.

(Choice E) *Mycoplasma pneumoniae* is a common cause of atypical pneumonia. However, this pathogen has no cell wall so it is not visible on Gram stain. It also does not grow in conventional culture.

(Choice F) *Pseudomonas aeruginosa* is a common nosocomial pathogen that may cause pneumonia in patients with structural lung disease or impaired immunity. It is an encapsulated, gram-negative bacillus that can appear mucoid in culture. However, it does not ferment lactose.

https://t.me/USMLEWorldStep1

due to colonization of the oropharynx followed by microaspiration of upper airway secretions. Because the aspiration usually occurs while supine (during sleep), the posterior segments of the **upper lobes** (particularly the right lung) are classically affected. The hallmarks of *Klebsiella* pneumonia are thick, mucoid, blood-tinged sputum (**currant jelly sputum**) and liquefying necrosis of the lung with early abscess formation.

(Choice A) *Haemophilus influenzae* is a leading cause of community-acquired pneumonia and bacterial meningitis. It is a gram-negative coccobacillus that can form mucoid colonies but does not ferment lactose.

(Choice C) *Legionella pneumophila* is a gram-negative bacillus that causes atypical pneumonia, generally following aerosolization from a contaminated water supply. However, *Legionella* is not an encapsulated organism and does not produce mucoid colonies.

(Choice D) *Moraxella catarrhalis* is a gram-negative diplococcus that is a common cause of upper respiratory infections (eg, bronchitis, laryngitis, sinusitis) and otitis media. It can also cause bronchopneumonia in patients with COPD. However, this pathogen does not ferment lactose.

(Choice E) *Mycoplasma pneumoniae* is a common cause of atypical pneumonia. However, this pathogen has no cell wall so it is not visible on Gram stain. It also does not grow in conventional culture.

(Choice F) *Pseudomonas aeruginosa* is a common nosocomial pathogen that may cause pneumonia in patients with structural lung disease or impaired immunity. It is an encapsulated, gram-negative bacillus that can appear mucoid in culture. However, it does not ferment lactose.

(Choice G) *Streptococcus pneumoniae* is the most common cause of community-acquired pneumonia. However, this pathogen is a gram-positive, lancet-shaped cocci usually found in pairs.

Educational objective:
Klebsiella is an encapsulated, lactose-fermenting, gram-negative bacillus that appears mucoid in culture. It causes pneumonia in individuals with impaired host defenses, especially patients with alcohol use disorder. *Klebsiella* pneumonia is characterized by tissue necrosis and early abscess formation with production of thick, mucoid, blood-tinged sputum (currant jelly sputum).

Microbiology	Pulmonary & Critical Care	Community acquired pneumonia
Subject	System	Topic

https://t.me/USMLEWorldStep1

Oxidase-positive

Exhibit Display

Klebsiella pneumoniae

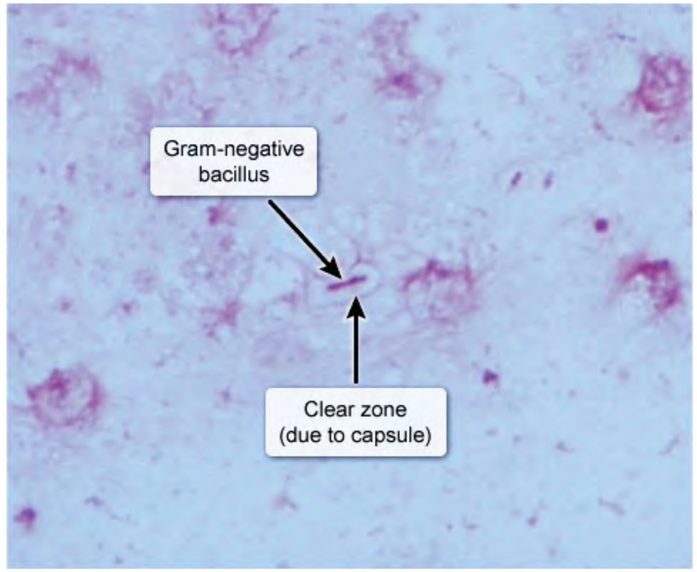

©UWorld

Zoom In | Zoom Out | Reset | New | Existing | My Notebook

Gram-
comm
or imp
most c
Serrat

Klebs
preser
growth
due to
aspira
right lu
(**curra**

(Choic
menin

(Choic
followi
and dc

(Choice D) *Moraxella catarrhalis* is a gram-negative diplococcus that is a common cause of upper respiratory infections (eg, bronchitis, laryngitis, sinusitis) and otitis media. It can also cause bronchopneumonia in patients

https://t.me/USMLEWorldStep1

Oxidase-positive

Exhibit Display

Klebsiella pneumoniae

*Mucus-like due to polysaccharide capsule

©UWorld

Zoom In | Zoom Out | Reset | New | Existing | My Notebook

Gram-
comm
or imp
most c
Serrat

Klebs
preser
growth
due to
aspira
right lu
(**curra**

(Choic
menin

(Choic
followi
and do

(Choice D) *Moraxella catarrhalis* is a gram-negative diplococcus that is a common cause of upper respiratory infections (eg, bronchitis, laryngitis, sinusitis) and otitis media. It can also cause bronchopneumonia in patients

https://t.me/USMLEWorldStep1

Researchers are measuring regional variations in pulmonary ventilation (V) and blood flow (Q) in healthy individuals while they stand in the upright position. The results are graphed with the x-axis denoting the position along the lung from base to apex. Which of the following curves is most likely to be observed?

A.

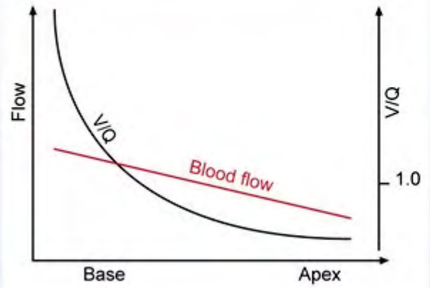

B.

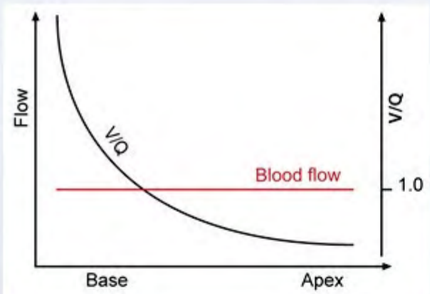

C.

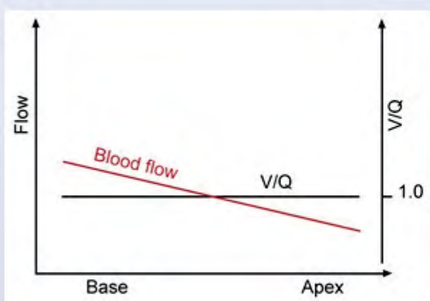

D.

https://t.me/USMLEWorldStep1

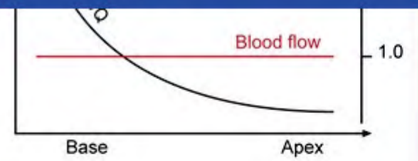

C.

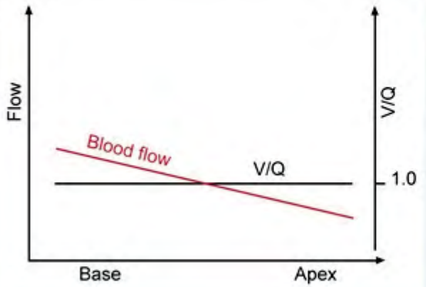

D.

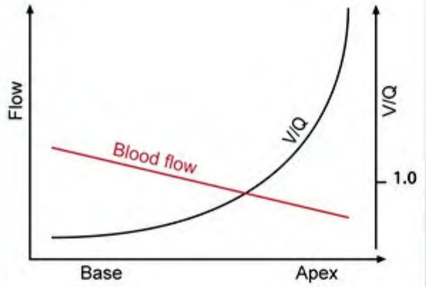

E.

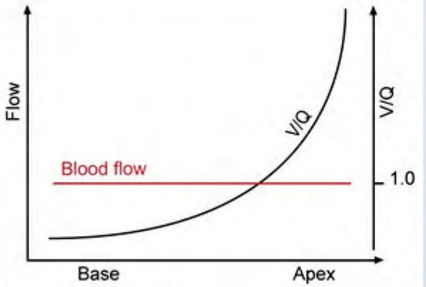

Submit

https://t.me/USMLEWorldStep1

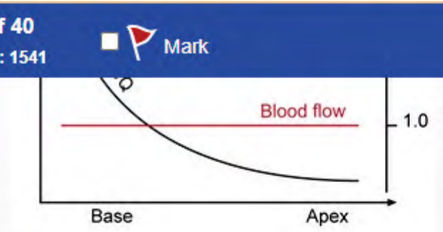

C. (2%)

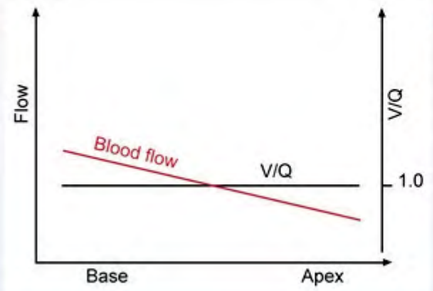

✓ D. (74%)

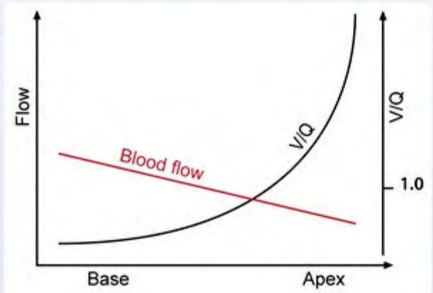

E. (3%)

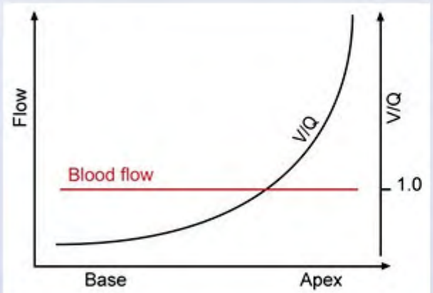

Correct

74%
Answered correctly

13 secs
Time Spent

2023
Version

https://t.me/USMLEWorldStep1

Explanation

Exhibit Display

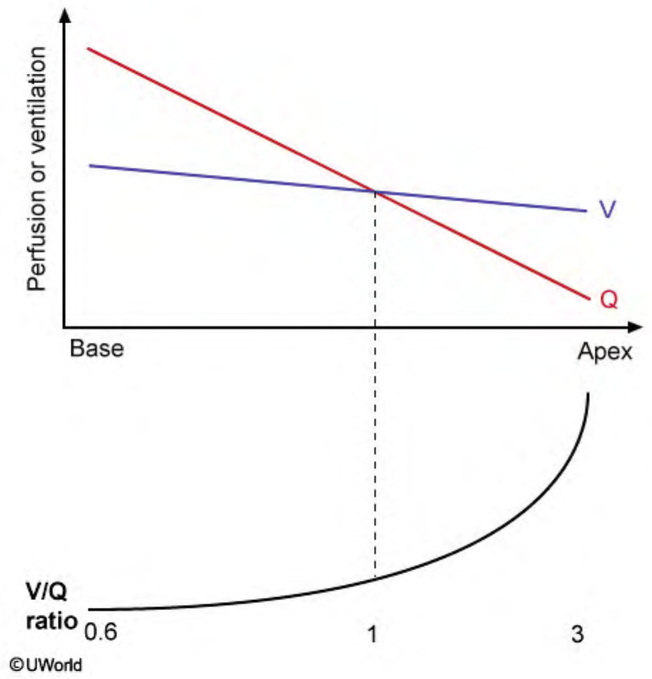

Zoom In | Zoom Out | Reset | New | Existing | My Notebook

In the
Ventil
that th
inspira
goes t
lowes
facilita

Becau
ventilation, leading to **greater variability in perfusion than ventilation** from apex to base. Therefore, perfusion is very low in the apex and very high in the base, whereas ventilation is only somewhat low in the apex and

https://t.me/USMLEWorldStep1

ratio 0.6 1 3

©UWorld

In the upright position, regional differences in ventilation and perfusion occur vertically in the lungs due to gravity. **Ventilation** is **lowest in the apex** and **highest in the base** because gravity acts to stretch the lungs downward so that the alveoli at the apex are expanded more than those at the base (ie, slinky effect). Therefore, during inspiration a small amount of air goes to the apex where alveoli are distended and less compliant, while more air goes to the base where alveoli have ample potential space to fill and are more compliant. **Perfusion** is also **lowest in the apex** and **highest in the base**, as the increased hydrostatic pressure in the lower lung regions facilitates increased blood flow.

Because blood is denser than air or lung tissue, the gravitational effect on perfusion is more pronounced than on ventilation, leading to **greater variability in perfusion than ventilation** from apex to base. Therefore, perfusion is very low in the apex and very high in the base, whereas ventilation is only somewhat low in the apex and somewhat high in the base. This causes the gradient of the ventilation/perfusion (V/Q) ratio to be opposite of the gradient of perfusion or ventilation taken individually. The **V/Q ratio** is **lowest at the base** and **highest at the apex**.

(Choices A and B) These graphs depict the V/Q ratio decreasing from base to apex, which is the opposite of what occurs.

(Choice C) This graph depicts a constant V/Q ratio of 1.0 throughout the lung, which does not occur. The V/Q ratio varies from approximately 0.6 at the base to 3.0 at the apex. A value of 0.8 is often considered the average V/Q ratio for normal lungs.

(Choice E) This graph shows constant perfusion throughout the lung, which does not occur.

Educational objective:
Both perfusion and ventilation are highest in the base of the lung and lowest in the apex; however, the variability in perfusion is greater than that in ventilation. This causes the ventilation/perfusion ratio to follow the opposite gradient: it is lowest in the base and highest in the apex.

Physiology	Pulmonary & Critical Care	Respiratory physiology
Subject	System	Topic

https://t.me/USMLEWorldStep1

ratio 0.6 1 3

©UWorld

In the **Ventil** that th inspira goes t **lowes** facilita

Becau ventila very lo somev gradie **apex**.

(Choi occurs

(Choi ratio v V/Q ra

(Choi

Educa Both p perfus gradie

Exhibit Display

Slinky effect on lungs

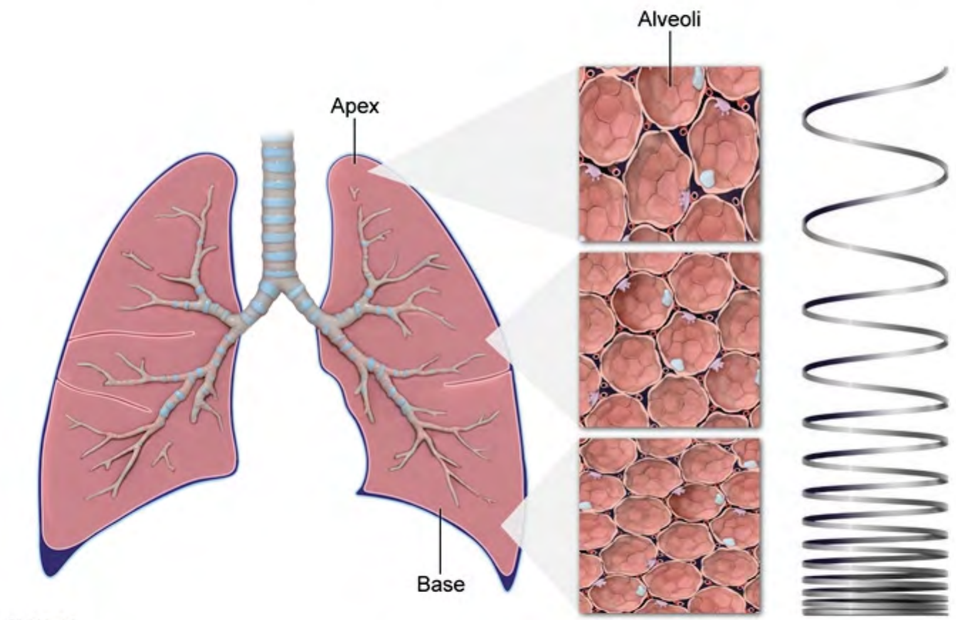

©UWorld

Zoom In Zoom Out Reset New | Existing My Notebook

Physiology
Subject

Pulmonary & Critical Care
System

Respiratory physiology
Topic

https://t.me/USMLEWorldStep1

A 25-year-old man comes to the hospital due to acute-onset shortness of breath. The patient has a history of cystic fibrosis and multiple hospitalizations for recurrent pneumonia. He has a frequent productive cough at baseline. He does not use tobacco. Blood pressure is 80/50 mm Hg, pulse is 110/min, and respirations are 24/min. Examination shows mild cyanosis and subcutaneous crepitus. Breath sounds are decreased on the left. Which of the following is most likely responsible for this patient's acute symptoms?

- A. Alveolar consolidation due to inflammatory exudate
- B. Bronchial obstruction with alveolar air resorption
- C. Diffuse constriction of bronchioles
- D. Increased dead-space ventilation
- E. Loss of intrapleural negative pressure

Submit

https://t.me/USMLEWorldStep1

A 25-year-old man comes to the hospital due to acute-onset shortness of breath. The patient has a history of cystic fibrosis and multiple hospitalizations for recurrent pneumonia. He has a frequent productive cough at baseline. He does not use tobacco. Blood pressure is 80/50 mm Hg, pulse is 110/min, and respirations are 24/min. Examination shows mild cyanosis and subcutaneous crepitus. Breath sounds are decreased on the left. Which of the following is most likely responsible for this patient's acute symptoms?

- A. Alveolar consolidation due to inflammatory exudate (26%)
- ✗ B. Bronchial obstruction with alveolar air resorption (21%)
- C. Diffuse constriction of bronchioles (3%)
- D. Increased dead-space ventilation (7%)
- ✓ E. Loss of intrapleural negative pressure (40%)

Incorrect
Correct answer
E

40%
Answered correctly

04 secs
Time Spent

2023
Version

Explanation

Pneumothorax	
Risk factors	• Primary spontaneous: age <40, tall & thin, male sex, smoking • Secondary spontaneous: COPD, cystic fibrosis, lung malignancy • Provoked: thoracic trauma/procedures
Clinical presentation	• Shortness of breath, chest pain • ↓ Breath sounds unilaterally • Subcutaneous crepitus • Hypotension, tachycardia & tracheal deviation*

https://t.me/USMLEWorldStep1

Pneumothorax	
Risk factors	• Primary spontaneous: age <40, tall & thin, male sex, smoking • Secondary spontaneous: COPD, cystic fibrosis, lung malignancy • Provoked: thoracic trauma/procedures
Clinical presentation	• Shortness of breath, chest pain • ↓ Breath sounds unilaterally • Subcutaneous crepitus • Hypotension, tachycardia & tracheal deviation*
Diagnosis	Chest x-ray: • Pleural line without peripheral lung markings • Contralateral mediastinal shift*
*If tension pathophysiology is present. **COPD** = chronic obstructive pulmonary disease.	

This patient with sudden-onset shortness of breath and a physical examination showing subcutaneous crepitus and unilaterally decreased breath sounds most likely has a **pneumothorax**. In cystic fibrosis, chronic lung damage, combined with mucus plugging and large alveolar pressure surges (eg, coughing), predisposes to spontaneous alveolar rupture.

Pressure in the lungs is normally equivalent to atmospheric pressure at end expiration, and the pressure in the intrapleural space is negative (eg, −5 cm H_2O relative to atmospheric pressure) due to the expanding tendency of the chest wall and collapsing tendency of the lungs. Alveolar rupture creates continuity between the lungs and the pleural space, with pressure equalization and **loss of intrapleural negative pressure**. Shortness of breath results from inability to expand the ruptured lung, and during rupture, air may be forced into the subcutaneous tissues of the chest wall to cause **crepitus**.

Simple pneumothorax is most common, but **tension pneumothorax** can develop if the rupture creates a one-way tissue valve that opens during inspiration to allow air into the pleural space and then closes during expiration to

https://t.me/USMLEWorldStep1

This patient with sudden-onset shortness of breath and a physical examination showing subcutaneous crepitus and unilaterally decreased breath sounds most likely has a **pneumothorax**. In cystic fibrosis, chronic lung damage, combined with mucus plugging and large alveolar pressure surges (eg, coughing), predisposes to spontaneous alveolar rupture.

Pressure in the lungs is normally equivalent to atmospheric pressure at end expiration, and the pressure in the intrapleural space is negative (eg, −5 cm H_2O relative to atmospheric pressure) due to the expanding tendency of the chest wall and collapsing tendency of the lungs. Alveolar rupture creates continuity between the lungs and the pleural space, with pressure equalization and **loss of intrapleural negative pressure**. Shortness of breath results from inability to expand the ruptured lung, and during rupture, air may be forced into the subcutaneous tissues of the chest wall to cause **crepitus**.

Simple pneumothorax is most common, but **tension pneumothorax** can develop if the rupture creates a one-way tissue valve that opens during inspiration to allow air into the pleural space and then closes during expiration to trap that air. As a result, intrapleural pressure increases with each breath and leads to contralateral mediastinal shift with **vena cava compression** and decreased venous return to the heart. The reduced cardiac output causes **hypotension** and **tachycardia** (ie, obstructive shock) and can rapidly lead to cardiac arrest; therefore, emergent decompression of the pleural space is needed.

(Choice A) Alveolar consolidation with inflammatory exudate occurs with pneumonia, which can cause hypotension (ie, septic shock). However, increased breath sounds are expected with pneumonia, and it would not explain subcutaneous crepitus.

(Choice B) Bronchial obstruction with alveolar air reabsorption describes atelectasis (eg, due to a large mucus plug). Shortness of breath and decreased breath sounds are typical, but hypotension and subcutaneous crepitus are not expected.

(Choice C) Diffuse bronchiolar constriction occurs with asthma exacerbation and is not typical of cystic fibrosis. Hypotension and unilaterally decreased breath sounds are not expected with asthma exacerbation.

(Choice D) Increased dead-space ventilation occurs with pulmonary embolism. Although hypotension (ie, obstructive shock) can occur, decreased breath sounds and subcutaneous crepitus are not typical.

https://t.me/USMLEWorldStep1

the chest wall and collapsing tendency of the lungs. Alveolar rupture creates continuity between the lungs and the pleural space, with pressure equalization and **loss of intrapleural negative pressure**. Shortness of breath results from inability to expand the ruptured lung, and during rupture, air may be forced into the subcutaneous tissues of the chest wall to cause **crepitus**.

Simple pneumothorax is most common, but **tension pneumothorax** can develop if the rupture creates a one-way tissue valve that opens during inspiration to allow air into the pleural space and then closes during expiration to trap that air. As a result, intrapleural pressure increases with each breath and leads to contralateral mediastinal shift with **vena cava compression** and decreased venous return to the heart. The reduced cardiac output causes **hypotension** and **tachycardia** (ie, obstructive shock) and can rapidly lead to cardiac arrest; therefore, emergent decompression of the pleural space is needed.

(Choice A) Alveolar consolidation with inflammatory exudate occurs with pneumonia, which can cause hypotension (ie, septic shock). However, increased breath sounds are expected with pneumonia, and it would not explain subcutaneous crepitus.

(Choice B) Bronchial obstruction with alveolar air reabsorption describes atelectasis (eg, due to a large mucus plug). Shortness of breath and decreased breath sounds are typical, but hypotension and subcutaneous crepitus are not expected.

(Choice C) Diffuse bronchiolar constriction occurs with asthma exacerbation and is not typical of cystic fibrosis. Hypotension and unilaterally decreased breath sounds are not expected with asthma exacerbation.

(Choice D) Increased dead-space ventilation occurs with pulmonary embolism. Although hypotension (ie, obstructive shock) can occur, decreased breath sounds and subcutaneous crepitus are not typical.

Educational objective:
Spontaneous pneumothorax is common in cystic fibrosis and involves alveolar rupture, leading to loss of intrapleural negative pressure. Patients have sudden-onset shortness of breath, unilaterally decreased breath sounds, and, sometimes, subcutaneous crepitus. Hypotension and tachycardia suggest the development of tension pathophysiology.

References

https://t.me/USMLEWorldStep1

- Contralateral mediastinal shift*

Exhibit Display

This p
and ur
damag
sponta

Pressu
intrapl
the ch
pleura
from ir
the ch

Simple
tissue
trap th
shift w
hypot
decom

(Choic
hypote
explair

(Choic
plug).
are no

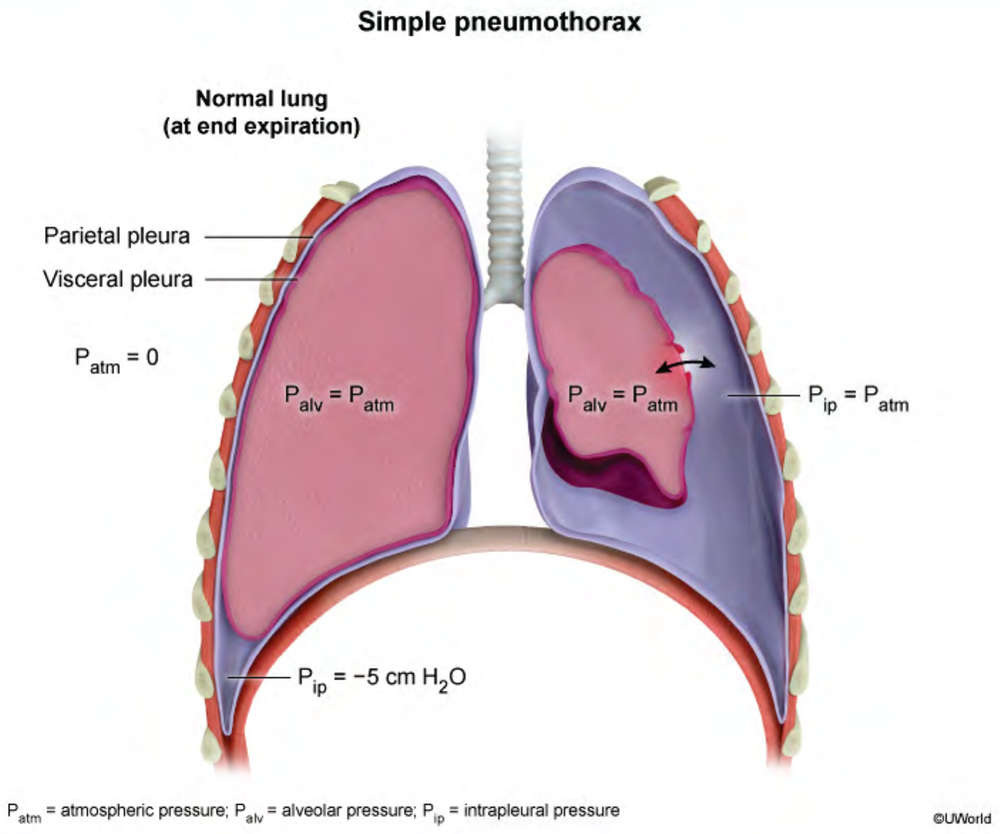

Zoom In Zoom Out Reset New | Existing My Notebook

(Choice C) Diffuse bronchiolar constriction occurs with asthma exacerbation and is not typical of cystic fibrosis.

https://t.me/USMLEWorldStep1

- Contralateral mediastinal shift*

Exhibit Display

This p
and ur
damag
sponta

Pressu
intrapl
the ch
pleura
from ir
the ch

Simple
tissue
trap th
shift w
hypot
decom

(Choic
hypote
explair

(Choic
plug).
are no

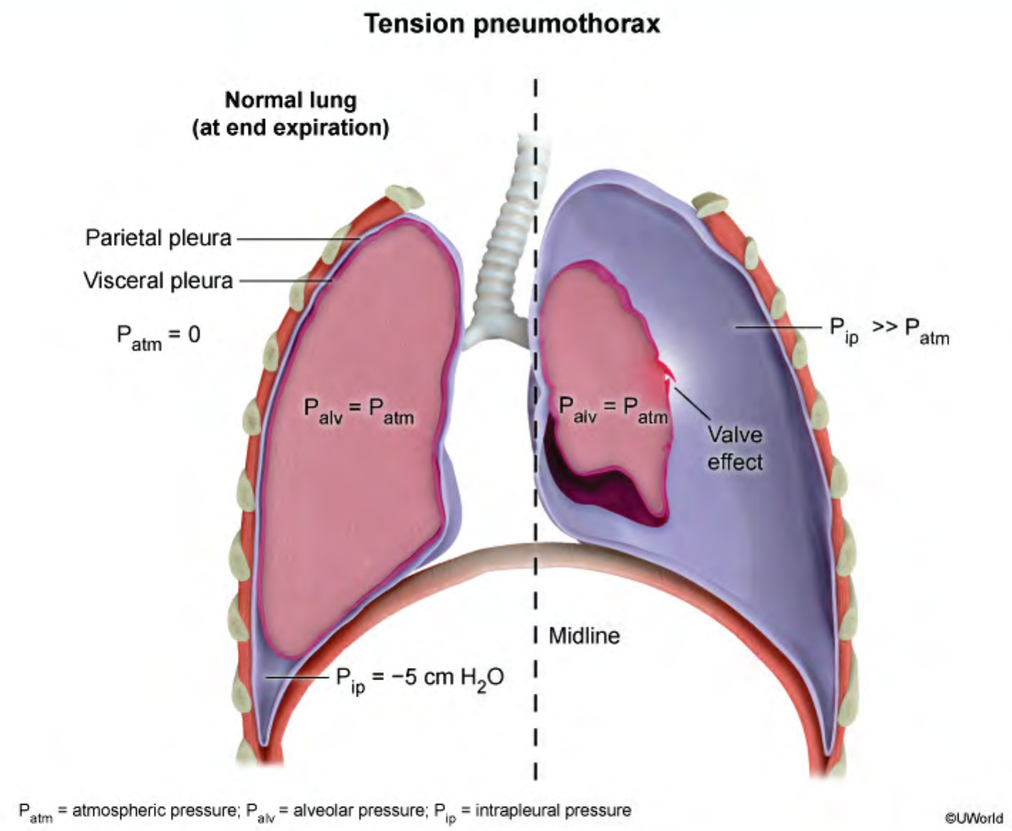

Zoom In Zoom Out Reset New | Existing My Notebook

(Choice C) Diffuse bronchiolar constriction occurs with asthma exacerbation and is not typical of cystic fibrosis.

https://t.me/USMLEWorldStep1

- Contralateral mediastinal shift*

Exhibit Display

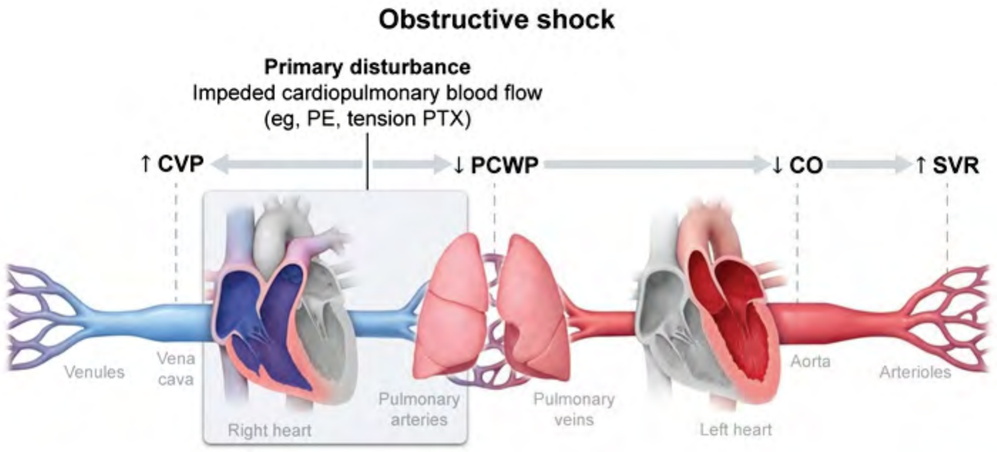

CO = cardiac output; **CVP** = central venous pressure; **PCWP** = pulmonary capillary wedge pressure; **PE** = pulmonary embolism; **PTX** = pneumothorax; **SVR** = systemic vascular resistance.

©UWorld

Zoom In | Zoom Out | Reset | New | Existing | My Notebook

This p
and ur
damag
sponta

Pressu
intrapl
the ch
pleura
from ir
the ch

Simple
tissue
trap th
shift w
hypot
decom

(Choic
hypote
explair

(Choic
plug).
are no

(Choice C) Diffuse bronchiolar constriction occurs with asthma exacerbation and is not typical of cystic fibrosis.

https://t.me/USMLEWorldStep1

A 65-year-old man comes to the office due to worsening exertional dyspnea over the last 3 months. This past year he had 4 respiratory tract infections. The patient does not use alcohol or recreational drugs. He has smoked 1½ packs of cigarettes daily for 30 years. Temperature is 36.7 C (98.1 F), pulse is 76/min, blood pressure is 132/77 mm Hg, and respirations are 18/min. On physical examination, breath sounds are diffusely decreased. Chest radiograph reveals increased lucency of the lungs. This patient's pulmonary function testing will most likely show which of the following patterns of findings?

	Total lung capacity	Forced vital capacity	Residual volume
○ A.	↓	↓	↓
○ B.	↓	↓	↑
○ C.	↓	↑	↑
○ D.	↑	↓	↑
○ E.	↑	↓	↓
○ F.	↑	↑	Normal

Submit

https://t.me/USMLEWorldStep1

A 65-year-old man comes to the office due to worsening exertional dyspnea over the last 3 months. This past year he had 4 respiratory tract infections. The patient does not use alcohol or recreational drugs. He has smoked 1½ packs of cigarettes daily for 30 years. Temperature is 36.7 C (98.1 F), pulse is 76/min, blood pressure is 132/77 mm Hg, and respirations are 18/min. On physical examination, breath sounds are diffusely decreased. Chest radiograph reveals increased lucency of the lungs. This patient's pulmonary function testing will most likely show which of the following patterns of findings?

	Total lung capacity	Forced vital capacity	Residual volume	
A.	↓	↓	↓	(5%)
B.	↓	↓	↑	(10%)
✗ C.	↓	↑	↑	(2%)
✓ D.	↑	↓	↑	(78%)
E.	↑	↓	↓	(1%)
F.	↑	↑	Normal	(1%)

Incorrect
Correct answer
D

78%
Answered correctly

03 secs
Time Spent

2023
Version

Explanation

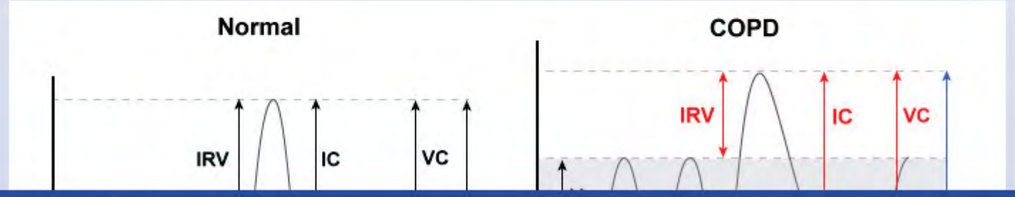

https://t.me/USMLEWorldStep1

Exhibit Display

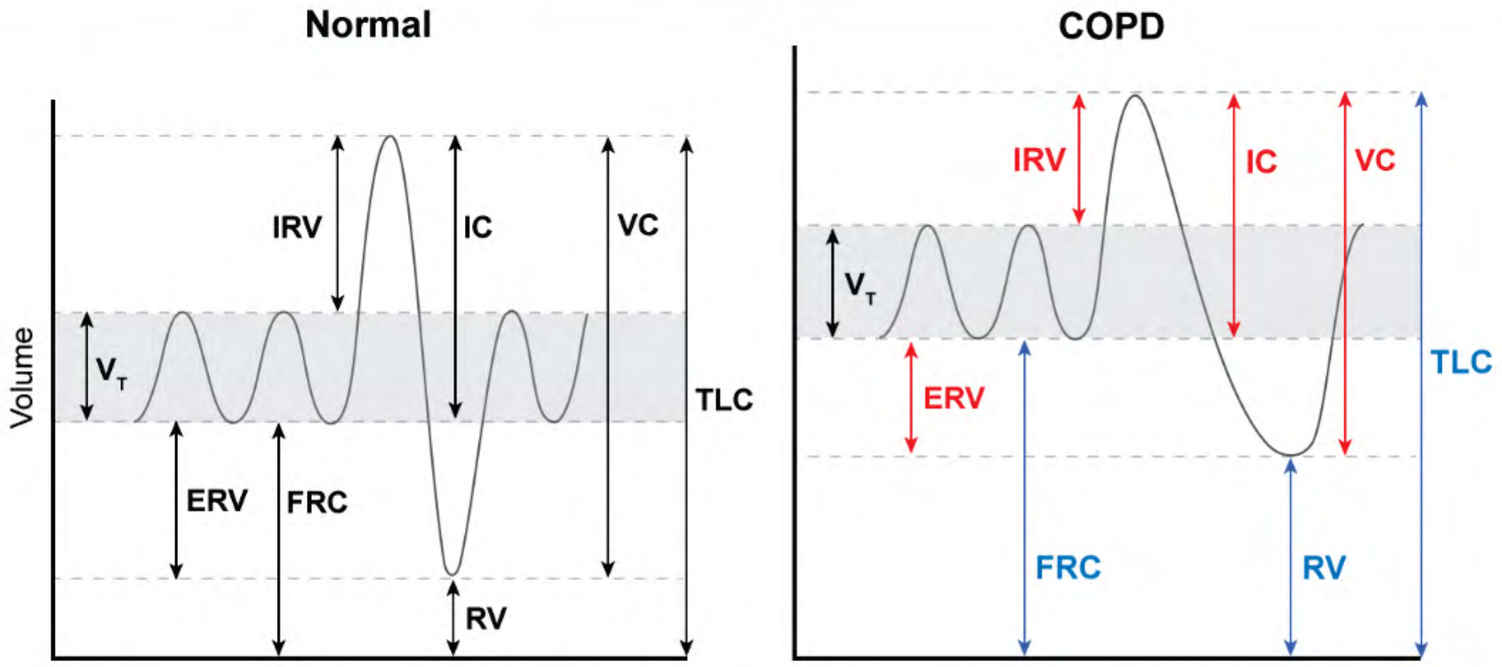

COPD = chronic obstructive pulmonary disease; **ERV** = expiratory reserve volume; **FRC** = functional residual capacity; **IC** = inspiratory capacity; **IRV** = inspiratory reserve volume; **RV** = residual volume; **TLC** = total lung capacity; **VC** = vital capacity; V_T = tidal volume.
©UWorld

Zoom In | Zoom Out | Reset | New | Existing | My Notebook

This p
obstructive pulmonary disease (COPD); his hyperlucency (ie, decreased lung tissue density) on imaging is further consistent with emphysema. Progressive elastin degradation in COPD has significant effects on lung volumes:

https://t.me/USMLEWorldStep1

©UWorld

This patient with a history of heavy smoking and worsening exertional dyspnea most likely has **chronic obstructive pulmonary disease** (COPD); his hyperlucency (ie, decreased lung tissue density) on imaging is further consistent with emphysema. Progressive elastin degradation in COPD has significant effects on lung volumes:

- Beginning early in the disease course, loss of elastin tethering fibers leads to abnormal expiratory collapse of the distal airways. Expiratory flow is reduced, leading to poor lung emptying. This is measured as a markedly **increased residual volume** (RV), known as **air trapping**.
- With continued elastin loss, lung tissue becomes abnormally compliant (ie, distensible, "loose and baggy" alveoli); destruction of the interalveolar septal walls results in alveolar enlargement. These conditions lead to an **increased total lung capacity** (TLC), known as lung **hyperinflation**.

Air trapping limits the lung's ability to expire air, decreasing expiratory reserve volume (ERV). Lung hyperinflation flattens the diaphragm, impairing its ability to descend and draw air into the lungs during inspiration; this leads to reduced inspiratory reserve volume (IRV). The reduced IRV and ERV (ie, decreased air movement during both inspiration and expiration) manifests as a **decrease in forced vital capacity** (the total volume of air that can be forcefully inspired after a maximal expiration).

(Choice A) These findings are consistent with a restrictive process affecting the lung parenchyma (eg, interstitial lung disease) or chest wall (eg, severe kyphosis). All volumes tend to be uniformly reduced due to poor distensibility of the lungs (eg, collagen deposition) and/or thoracic cage (eg, spine deformity).

(Choice B) These findings are consistent with a restrictive process due to neuromuscular disease (eg, amyotrophic lateral sclerosis, myasthenia gravis). TLC is reduced due to inspiratory muscle (diaphragm) weakness, and RV is elevated due to expiratory muscle (eg, internal intercostals) weakness.

(Choices C and E) Forced VC is the difference between TLC and RV. Therefore, a low TLC and high RV would produce a low VC; conversely, a high TLC and low RV would produce a high VC.

(Choice F) These findings can be seen in highly conditioned athletes due to increased airway diameter and robust respiratory muscle strength.

https://t.me/USMLEWorldStep1

further consistent with emphysema. Progressive elastin degradation in COPD has significant effects on lung volumes:

- Beginning early in the disease course, loss of elastin tethering fibers leads to abnormal expiratory collapse of the distal airways. Expiratory flow is reduced, leading to poor lung emptying. This is measured as a markedly **increased residual volume** (RV), known as **air trapping**.
- With continued elastin loss, lung tissue becomes abnormally compliant (ie, distensible, "loose and baggy" alveoli); destruction of the interalveolar septal walls results in alveolar enlargement. These conditions lead to an **increased total lung capacity** (TLC), known as lung **hyperinflation**.

Air trapping limits the lung's ability to expire air, decreasing expiratory reserve volume (ERV). Lung hyperinflation flattens the diaphragm, impairing its ability to descend and draw air into the lungs during inspiration; this leads to reduced inspiratory reserve volume (IRV). The reduced IRV and ERV (ie, decreased air movement during both inspiration and expiration) manifests as a **decrease in forced vital capacity** (the total volume of air that can be forcefully inspired after a maximal expiration).

(Choice A) These findings are consistent with a restrictive process affecting the lung parenchyma (eg, interstitial lung disease) or chest wall (eg, severe kyphosis). All volumes tend to be uniformly reduced due to poor distensibility of the lungs (eg, collagen deposition) and/or thoracic cage (eg, spine deformity).

(Choice B) These findings are consistent with a restrictive process due to neuromuscular disease (eg, amyotrophic lateral sclerosis, myasthenia gravis). TLC is reduced due to inspiratory muscle (diaphragm) weakness, and RV is elevated due to expiratory muscle (eg, internal intercostals) weakness.

(Choices C and E) Forced VC is the difference between TLC and RV. Therefore, a low TLC and high RV would produce a low VC; conversely, a high TLC and low RV would produce a high VC.

(Choice F) These findings can be seen in highly conditioned athletes due to increased airway diameter and robust respiratory muscle strength.

Educational objective:
Chronic obstructive pulmonary disease is characterized by elevated residual volume (air trapping), elevated total lung capacity (hyperinflation), and reduced forced vital capacity.

https://t.me/USMLEWorldStep1

Exhibit Display

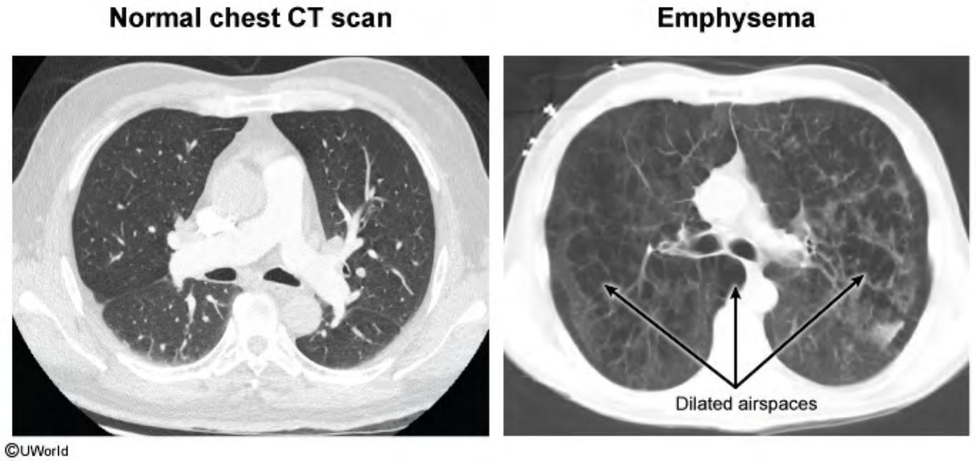

Zoom In Zoom Out Reset New | Existing My Notebook

This p
obstru
further
volum

- B
  th
  ir
- W
  a
  a

Air tra
flatten
reduce
inspiration and expiration) manifests as a **decrease in forced vital capacity** (the total volume of air that can be forcefully inspired after a maximal expiration).

(Choice A) These findings are consistent with a restrictive process affecting the lung parenchyma (eg, interstitial

https://t.me/USMLEWorldStep1

A 42-year-old woman comes to the office due to several months of episodic shortness of breath and cough. The patient has a history of migraines and occasionally takes acetaminophen. She is a school teacher and does not use tobacco, alcohol, or illicit drugs. Temperature is 36.1 C (97 F), blood pressure is 110/80 mm Hg, and pulse is 84/min. Pulse oximetry shows 96% on room air. Lung examination and chest x-ray are normal. Spirometry shows that FEV1 is 71% of the predicted value. Sputum analysis shows predominant eosinophils. Exposure to which of the following is most closely associated with this patient's symptoms?

- A. Acetaminophen
- B. Gliadin-containing grains
- C. *Histoplasma* microconidia
- D. House dust mites
- E. Shellfish and other seafood
- F. Thermophilic actinomycetes

Submit

https://t.me/USMLEWorldStep1

A 42-year-old woman comes to the office due to several months of episodic shortness of breath and cough. The patient has a history of migraines and occasionally takes acetaminophen. She is a school teacher and does not use tobacco, alcohol, or illicit drugs. Temperature is 36.1 C (97 F), blood pressure is 110/80 mm Hg, and pulse is 84/min. Pulse oximetry shows 96% on room air. Lung examination and chest x-ray are normal. Spirometry shows that FEV1 is 71% of the predicted value. Sputum analysis shows predominant eosinophils. Exposure to which of the following is most closely associated with this patient's symptoms?

- A. Acetaminophen (15%)
- ✕ B. Gliadin-containing grains (2%)
- C. *Histoplasma* microconidia (4%)
- ✓ D. House dust mites (70%)
- E. Shellfish and other seafood (4%)
- F. Thermophilic actinomycetes (3%)

Incorrect
Correct answer
D

70%
Answered correctly

04 secs
Time Spent

2023
Version

Explanation

Common triggers of asthma	
Inhaled allergens	• Animal dander • Dust mites & cockroaches • Pollens & molds
Respiratory irritants	• Cigarette smoke & air pollutants • Perfumes

https://t.me/USMLEWorldStep1

Common triggers of asthma	
Inhaled allergens	• Animal dander • Dust mites & cockroaches • Pollens & molds
Respiratory irritants	• Cigarette smoke & air pollutants • Perfumes
Medications	• Aspirin/NSAIDs • Nonselective β blockers
Other	• Upper respiratory tract infection • Exercise & cold, dry air • Gastroesophageal reflux disease
NSAID = nonsteroidal anti-inflammatory drug.	

This patient's **intermittent respiratory symptoms** (eg, dyspnea, cough) in the setting of a **normal chest x-ray**, sputum eosinophils, and **reduced FEV1** (<80% predicted) are highly suggestive of **asthma**.

Asthma is a reversible obstructive pulmonary disease characterized by bronchial hyperresponsiveness to various triggers, such as exercise, cold air, respiratory infection, and exposure to **inhaled allergens**. Common aeroallergens include **dust mites**, cockroaches, pet dander, mold, and pollen. In sensitive individuals, allergens promote bronchospasm and airway inflammation by interacting with IgE bound to pulmonary mast cells; subsequent mast cell activation leads to the release of inflammatory mediators (eg, histamine, prostaglandins, leukotrienes) and recruitment of inflammatory cells, particularly **eosinophils**. Therefore, allergen avoidance is an important preventive measure for patients with asthma.

(Choice A) Aspirin and other nonsteroidal anti-inflammatory drugs that inhibit cyclooxygenase can precipitate asthma attacks due to leukotriene overproduction in the airways. Acetaminophen is only a weak inhibitor of cyclooxygenase, and although some evidence suggests an increased incidence of asthma in patients with frequent

https://t.me/USMLEWorldStep1

This patient's **intermittent respiratory symptoms** (eg, dyspnea, cough) in the setting of a **normal chest x-ray**, sputum eosinophils, and **reduced FEV1** (<80% predicted) are highly suggestive of **asthma**.

Asthma is a reversible obstructive pulmonary disease characterized by bronchial hyperresponsiveness to various triggers, such as exercise, cold air, respiratory infection, and exposure to **inhaled allergens**. Common aeroallergens include **dust mites**, cockroaches, pet dander, mold, and pollen. In sensitive individuals, allergens promote bronchospasm and airway inflammation by interacting with IgE bound to pulmonary mast cells; subsequent mast cell activation leads to the release of inflammatory mediators (eg, histamine, prostaglandins, leukotrienes) and recruitment of inflammatory cells, particularly **eosinophils**. Therefore, allergen avoidance is an important preventive measure for patients with asthma.

(Choice A) Aspirin and other nonsteroidal anti-inflammatory drugs that inhibit cyclooxygenase can precipitate asthma attacks due to leukotriene overproduction in the airways. Acetaminophen is only a weak inhibitor of cyclooxygenase, and although some evidence suggests an increased incidence of asthma in patients with frequent acetaminophen use, a clear association has not been established.

(Choice B) Celiac disease (gluten-sensitive enteropathy) is caused by antibodies to gliadin, a gluten protein found in wheat. Patients classically have signs/symptoms of malabsorption (eg, diarrhea, steatorrhea, weight loss, nutrient/vitamin deficiencies).

(Choice C) Although *Aspergillus* molds are ubiquitous in the environment and are a common trigger of asthma symptoms, *Histoplasma* mold is a relatively uncommon trigger. *Aspergillus* molds can also cause allergic bronchopulmonary aspergillosis, a chronic allergic lung condition that typically affects patients with asthma or cystic fibrosis.

(Choice E) Hypersensitivity to shellfish or other seafood usually presents with urticaria, angioedema, and/or anaphylaxis immediately after food consumption. Food is rarely an inciting factor for asthma. Most commonly, food-related asthma is the result of added preservatives, such as sulfites.

(Choice F) Inhalational exposure to thermophilic actinomycetes species is classically associated with hypersensitivity pneumonitis in farmers (farmer's lung). Patients typically develop respiratory and systemic symptoms (eg, fever, headache, malaise) after exposure to moldy hay or contaminated compost.

https://t.me/USMLEWorldStep1

aeroallergens include **dust mites**, cockroaches, pet dander, mold, and pollen. In sensitive individuals, allergens promote bronchospasm and airway inflammation by interacting with IgE bound to pulmonary mast cells; subsequent mast cell activation leads to the release of inflammatory mediators (eg, histamine, prostaglandins, leukotrienes) and recruitment of inflammatory cells, particularly **eosinophils**. Therefore, allergen avoidance is an important preventive measure for patients with asthma.

(Choice A) Aspirin and other nonsteroidal anti-inflammatory drugs that inhibit cyclooxygenase can precipitate asthma attacks due to leukotriene overproduction in the airways. Acetaminophen is only a weak inhibitor of cyclooxygenase, and although some evidence suggests an increased incidence of asthma in patients with frequent acetaminophen use, a clear association has not been established.

(Choice B) Celiac disease (gluten-sensitive enteropathy) is caused by antibodies to gliadin, a gluten protein found in wheat. Patients classically have signs/symptoms of malabsorption (eg, diarrhea, steatorrhea, weight loss, nutrient/vitamin deficiencies).

(Choice C) Although *Aspergillus* molds are ubiquitous in the environment and are a common trigger of asthma symptoms, *Histoplasma* mold is a relatively uncommon trigger. *Aspergillus* molds can also cause allergic bronchopulmonary aspergillosis, a chronic allergic lung condition that typically affects patients with asthma or cystic fibrosis.

(Choice E) Hypersensitivity to shellfish or other seafood usually presents with urticaria, angioedema, and/or anaphylaxis immediately after food consumption. Food is rarely an inciting factor for asthma. Most commonly, food-related asthma is the result of added preservatives, such as sulfites.

(Choice F) Inhalational exposure to thermophilic actinomycetes species is classically associated with hypersensitivity pneumonitis in farmers (farmer's lung). Patients typically develop respiratory and systemic symptoms (eg, fever, headache, malaise) after exposure to moldy hay or contaminated compost.

Educational objective:
Intermittent respiratory symptoms in a patient with a normal chest x-ray, sputum eosinophils, and reduced FEV1 suggest asthma. Common asthma triggers include exercise, cold air, respiratory infection, and exposure to inhaled allergens (eg, dust mites, cockroaches, pet dander, mold, pollen).

https://t.me/USMLEWorldStep1

leukotrienes) and recruitment of inflammatory cells, particularly **eosinophils**. Therefore, allergen avoidance is an important preventive measure for patients with asthma.

(Choi
asthm
cyclo
acetar

(Choi
in whe
nutrien

(Choi
sympt
bronch
fibrosi

(Choi
anaph
food-r

(Choi
hypers
sympt

Educa
Interm
sugge
allerge

Refere
- Wh
- Bronchial asthma: diagnosis and long-term treatment in adults.

Exhibit Display

Arachidonic acid pathway in NSAID-exacerbated respiratory disease

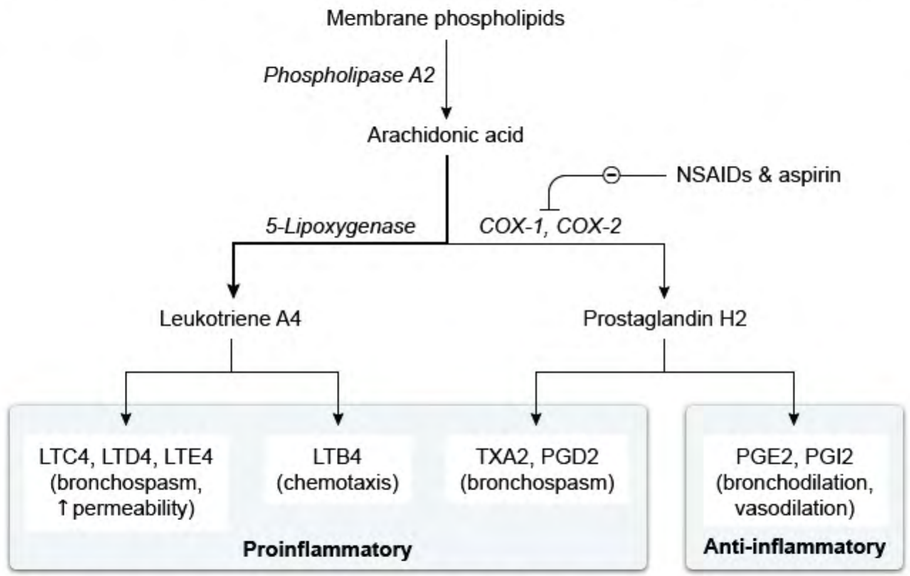

COX = cyclooxygenase; **LT** = leukotriene; **NSAIDs** = nonsteroidal anti-inflammatory drugs; **PG** = prostaglandin; **TX** = thromboxane.

©UWorld

Zoom In | Zoom Out | Reset | New | Existing | My Notebook

https://t.me/USMLEWorldStep1

A 65-year-old man comes to the office due to several weeks of nonproductive cough. The patient also has anorexia and unintentional weight loss. His medical history includes hypothyroidism due to Hashimoto thyroiditis and a 50-pack-year smoking history. Examination shows an enlarged right supraclavicular lymph node. Imaging reveals a large mediastinal mass causing tracheal deviation. The enlarged node is biopsied, and microscopy demonstrates clusters of small, ovoid cells with scant cytoplasm and a high mitotic count. Immunohistochemical staining is positive for chromogranin. This patient most likely has which of the following conditions?

- A. Adenocarcinoma
- B. Hodgkin lymphoma
- C. Papillary thyroid carcinoma
- D. Small cell cancer
- E. Squamous cell cancer

Submit

https://t.me/USMLEWorldStep1

A 65-year-old man comes to the office due to several weeks of nonproductive cough. The patient also has anorexia and unintentional weight loss. His medical history includes hypothyroidism due to Hashimoto thyroiditis and a 50-pack-year smoking history. Examination shows an enlarged right supraclavicular lymph node. Imaging reveals a large mediastinal mass causing tracheal deviation. The enlarged node is biopsied, and microscopy demonstrates clusters of small, ovoid cells with scant cytoplasm and a high mitotic count. Immunohistochemical staining is positive for chromogranin. This patient most likely has which of the following conditions?

- A. Adenocarcinoma (3%)
- ✗ B. Hodgkin lymphoma (3%)
- C. Papillary thyroid carcinoma (3%)
- ✓ D. Small cell cancer (86%)
- E. Squamous cell cancer (3%)

Incorrect
Correct answer
D

86%
Answered correctly

03 secs
Time Spent

2023
Version

Explanation

Small cell carcinoma of the lung	
Clinical features	• Risks: smoking, male > female • Highly aggressive • Central location
Histology	• Sheets of small blue cells with scant cytoplasm • Neuroendocrine markers: NCAM, neuron-specific enolase, chromogranin, synaptophysin

https://t.me/USMLEWorldStep1

Small cell carcinoma of the lung	
Clinical features	• Risks: smoking, male > female • Highly aggressive • Central location
Histology	• Sheets of small blue cells with scant cytoplasm • Neuroendocrine markers: NCAM, neuron-specific enolase, chromogranin, synaptophysin
Associated paraneoplastic syndromes	• SIADH • Cushing syndrome • Lambert-Eaton syndrome
NCAM = neural cell adhesion molecule; **SIADH** = syndrome of inappropriate antidiuretic hormone.	

This patient with a heavy smoking history, weight loss, cough, and a mediastinal mass with evidence of metastases (ie, supraclavicular node elargement) has **small cell lung cancer** (SCLC), also known as oat cell carcinoma. SCLC makes up 10%-20% of all primary lung malignancies and is strongly associated with **smoking**. It is usually **centrally located** and arises from the primitive cells of the basal layer of the bronchial epithelium. On light microscopy, small, round or oval cells with scant cytoplasm, **hyperchromatic (blue) nuclei**, and granular chromatin are visualized. The cells, which may resemble lymphocytes but are typically larger, form clusters or sheets. Abundant mitoses are usually seen.

Small cell carcinomas can display varying degrees of **neuroendocrine differentiation**. Immunohistochemical stains are frequently positive for neuroendocrine markers, such as neuron-specific enolase, **chromogranin**, neural cell adhesion molecule (CD56), and **synaptophysin**. On electron microscopy, some of the cells have secretory granules in the cytoplasm.

(Choice A) Adenocarcinoma is the most common form of cancer in both nonsmokers and the total population. It is histologically characterized by glandular differentiation (eg, gland formation, mucin production), and the tumor cells often show abundant cytoplasm and eccentrically placed nuclei. The cells often stain positive for mucin. It typically arises in the periphery of the lung

https://t.me/USMLEWorldStep1

stains are frequently positive for neuroendocrine markers, such as neuron-specific enolase, **chromogranin**, neural cell adhesion molecule (CD56), and **synaptophysin**. On electron microscopy, some of the cells have secretory granules in the cytoplasm.

(Choice A) Adenocarcinoma is the most common form of cancer in both nonsmokers and the total population. It is histologically characterized by glandular differentiation (eg, gland formation, mucin production), and the tumor cells often show abundant cytoplasm and eccentrically placed nuclei. The cells often stain positive for mucin. It typically arises in the periphery of the lung.

(Choice B) Hodgkin lymphoma typically presents with cervical lymphadenopathy and can cause a mediastinal mass. However, microscopy demonstrates Reed-Sternberg cells (large cell with multilobed nucleus or multiple nuclei, prominent nucleoli, abundant cytoplasm, and an "owl's eye" appearance) in a background of inflammatory cells. In addition, other B symptoms (eg, fever, night sweats) are common.

(Choice C) Papillary thyroid carcinoma presents with a thyroid nodule and cervical lymphadenopathy but can also cause an anterior mediastinal mass. Histology reveals branching papillae, which are composed of a fibrovascular stalk covered by neoplastic cuboidal cells with clear ("ground-glass") nuclei. Psammoma bodies (laminated calcium deposits) can sometimes be seen.

(Choice E) Squamous cell carcinoma typically arises centrally and is composed of polygonal cells with eosinophilic cytoplasm and distinct borders. Well-differentiated squamous cell carcinomas show keratin pearls and intercellular bridges on light microscopy.

Educational objective:
Small cell lung cancer is strongly associated with smoking and is usually centrally located. Histopathology shows small round/oval cells with scant cytoplasm, hyperchromatic (blue) nuclei, and granular chromatin; abundant mitoses are also usually seen. Immunohistochemical stains are frequently positive for neuroendocrine markers (eg, chromogranin, synaptophysin, neural cell adhesion molecule [CD56]).

Pathology	Pulmonary & Critical Care	Lung cancer
Subject	System	Topic

Copyright © UWorld. All rights reserved.

https://t.me/USMLEWorldStep1

Associated paraneoplastic	• SIADH

NC

This p
(ie, su
SCLC
centra
micros
chrom
sheets

Small
stains
cell ad
granul

(Choi
is histo
cells o
typical

(Choi
mass.
nuclei,
cells.

(Choi
cause an anterior mediastinal mass. Histology reveals branching papillae, which are composed of a fibrovascular stalk covered by neoplastic cuboidal cells with clear ("ground-glass") nuclei. Psammoma bodies (laminated

Exhibit Display

Small cell lung carcinoma

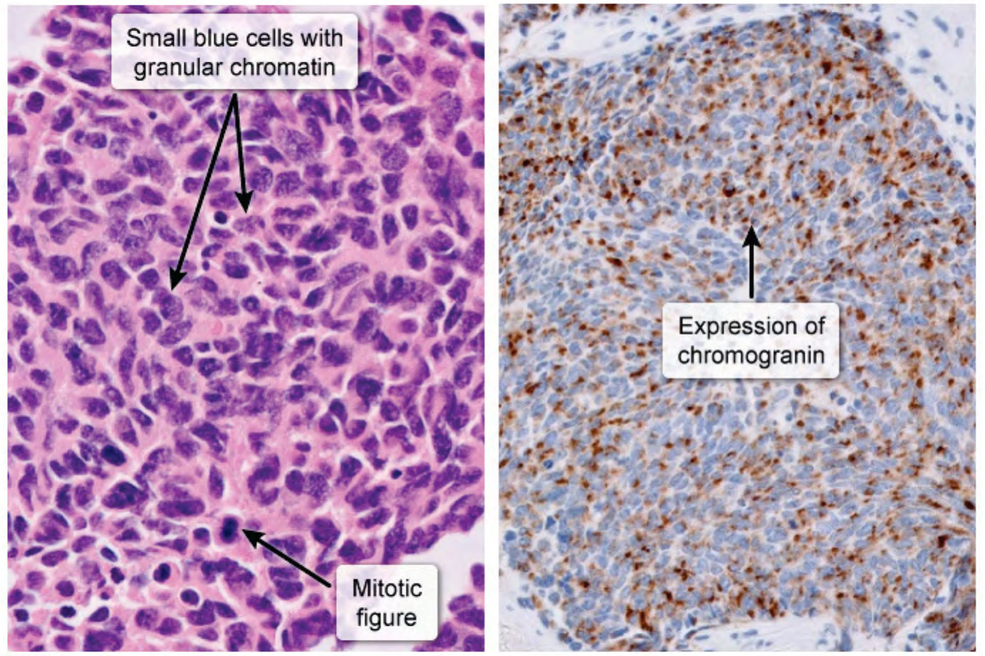

©UWorld

Zoom In | Zoom Out | Reset | New | Existing | My Notebook

https://t.me/USMLEWorldStep1

Associated paraneoplastic	• SIADH
NC	

Exhibit Display

Lung adenocarcinoma

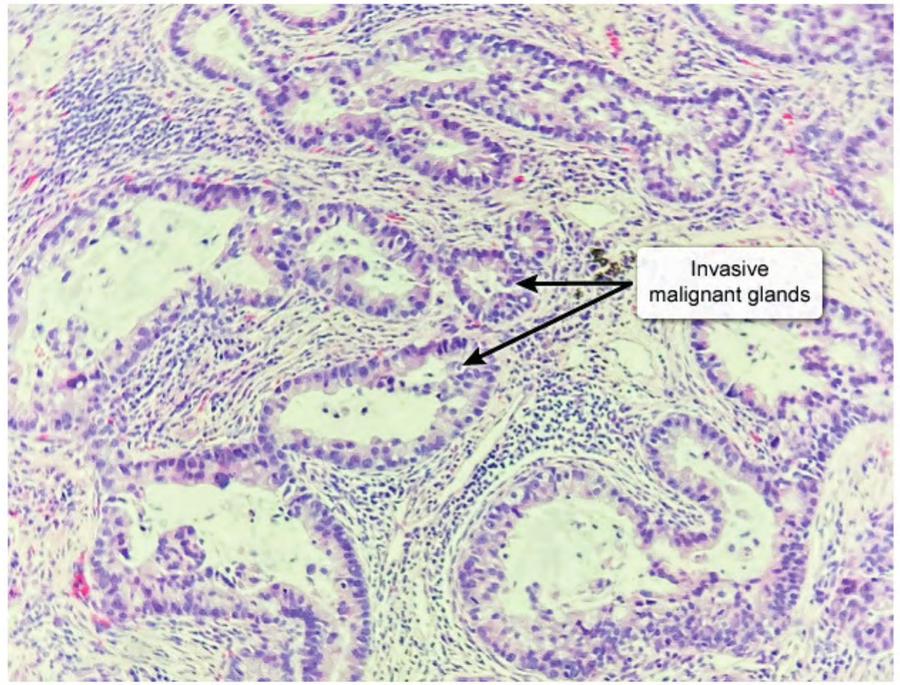

©UWorld

Zoom In | Zoom Out | Reset | New | Existing | My Notebook

This p
(ie, su
SCLC
centra
micros
chrom
sheets

Small
stains
cell ad
granul

(Choi
is histo
cells o
typical

(Choi
mass.
nuclei,
cells.

(Choi
cause an anterior mediastinal mass. Histology reveals branching papillae, which are composed of a fibrovascular stalk covered by neoplastic cuboidal cells with clear ("ground-glass") nuclei. Psammoma bodies (laminated

https://t.me/USMLEWorldStep1

	• SIADH
NC	

Exhibit Display

Hodgkin lymphoma

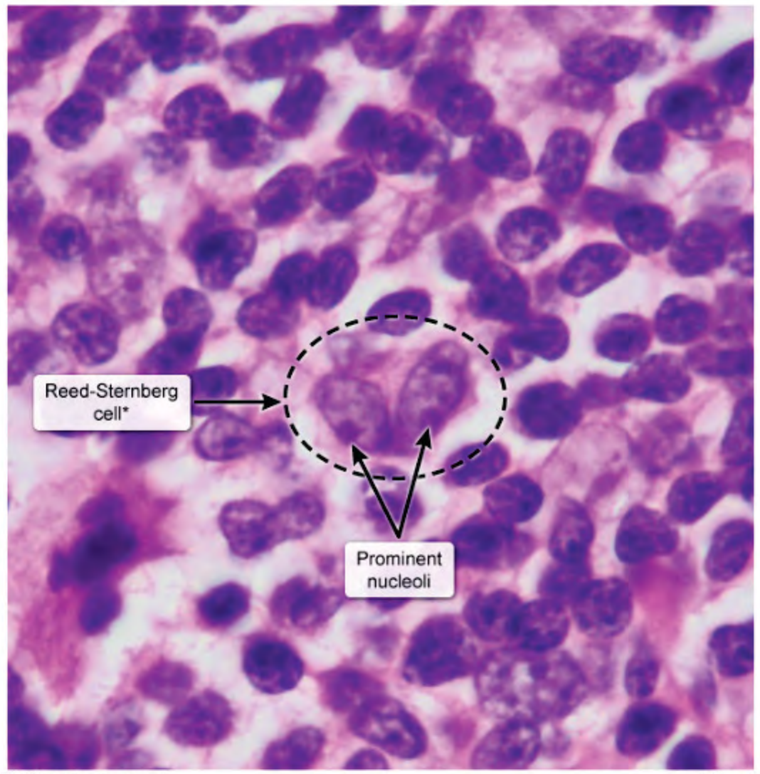

*"Owl's eye" appearance.

©UWorld

Zoom In | Zoom Out | Reset | New | Existing | My Notebook

This p
(ie, su
SCLC
centra
micros
chrom
sheets

Small
stains
cell ad
granul

(Choi
is histo
cells o
typical

(Choi
mass.
nuclei,
cells.

(Choice C) Papillary thyroid carcinoma presents with a thyroid nodule and cervical lymphadenopathy but can also cause an anterior mediastinal mass. Histology reveals branching papillae, which are composed of a fibrovascular stalk covered by neoplastic cuboidal cells with clear ("ground-glass") nuclei. Psammoma bodies (laminated

https://t.me/USMLEWorldStep1

NCAM = neural cell adhesion molecule; **SIADH** = syndrome of inappropriate antidiuretic hormone.

This p
(ie, su
SCLC
centra
micros
chrom
sheets

Small
stains
cell ad
granul

(Choi
is histo
cells o
typical

(Choi
mass.
nuclei,
cells.

(Choi
cause
stalk c
calciur

(Choice E) Squamous cell carcinoma typically arises centrally and is composed of polygonal cells with eosinophilic cytoplasm and distinct borders. Well-differentiated squamous cell carcinomas show keratin pearls and

Exhibit Display

Papillary thyroid carcinoma

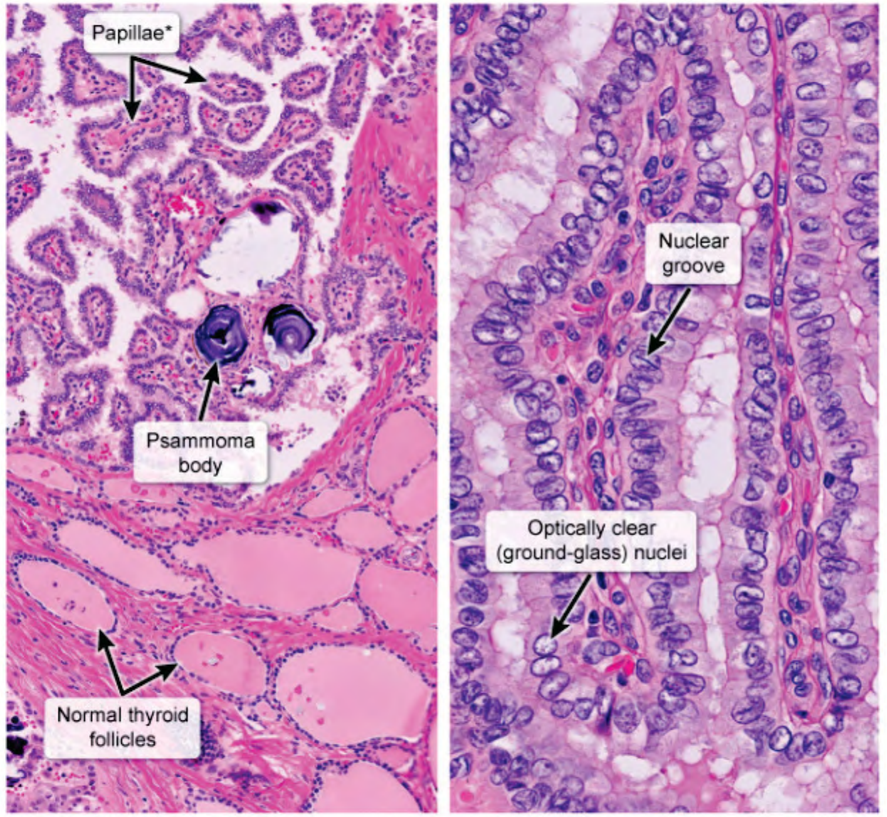

*Fibrovascular cores lined by epithelial cells

©UWorld

Zoom In Zoom Out Reset New | Existing My Notebook

https://t.me/USMLEWorldStep1

chromatin are visualized. The cells, which may resemble lymphocytes but are typically larger, form clusters or sheets

Small
stains
cell ad
granul

(Choi
is hist
cells o
typical

(Choi
mass.
nuclei,
cells.

(Choi
cause
stalk c
calciur

(Choi
eosinc
interce

Educa
Small
small r
mitose

(eg, chromogranin, synaptophysin, neural cell adhesion molecule [CD56]).

Exhibit Display

Squamous cell carcinoma

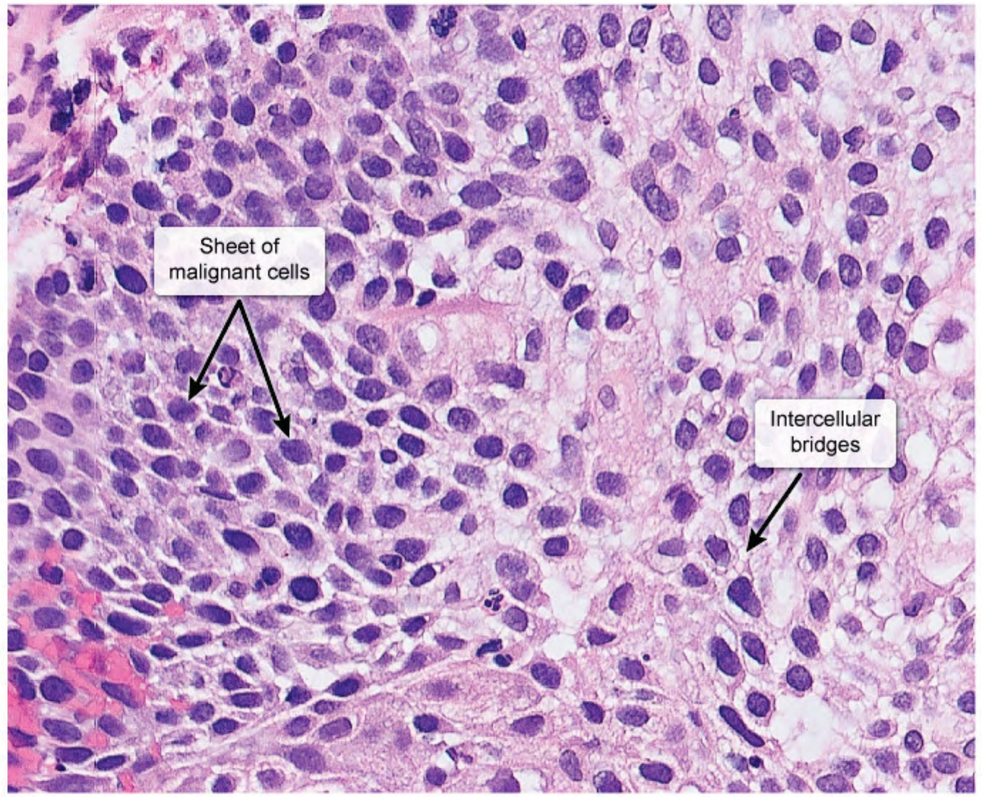

©UWorld

Zoom In | Zoom Out | Reset | New | Existing | My Notebook

https://t.me/USMLEWorldStep1

A 60-year-old woman is brought to the hospital due to progressive shortness of breath and cough for 2 weeks. The patient was diagnosed with right breast cancer and completed radiation therapy 6 weeks ago. Temperature is 37.3 C (99.1 F), blood pressure is 110/70 mm Hg, pulse is 90/min, and respirations are 22/min. Oxygen saturation is 93% on room air. Examination reveals inspiratory crackles over the right lung anteriorly; the lungs are otherwise clear to auscultation. Chest radiograph shows ground-glass opacities in the right lung where radiation was delivered. Laboratory studies reveal no significant changes. Acute radiation-induced lung injury is suspected. Histopathologic examination would most likely reveal formation of which of the following?

- A. Alveolar hyaline membranes
- B. Hemosiderin-laden macrophages
- C. Necrotizing vasculitis
- D. Neutrophilic abscess

Submit

https://t.me/USMLEWorldStep1

A 60-year-old woman is brought to the hospital due to progressive shortness of breath and cough for 2 weeks. The patient was diagnosed with right breast cancer and completed radiation therapy 6 weeks ago. Temperature is 37.3 C (99.1 F), blood pressure is 110/70 mm Hg, pulse is 90/min, and respirations are 22/min. Oxygen saturation is 93% on room air. Examination reveals inspiratory crackles over the right lung anteriorly; the lungs are otherwise clear to auscultation. Chest radiograph shows ground-glass opacities in the right lung where radiation was delivered. Laboratory studies reveal no significant changes. Acute radiation-induced lung injury is suspected. Histopathologic examination would most likely reveal formation of which of the following?

- ✓ A. Alveolar hyaline membranes (68%)
- ✗ B. Hemosiderin-laden macrophages (9%)
- C. Necrotizing vasculitis (15%)
- D. Neutrophilic abscess (6%)

Incorrect
Correct answer
A

68%
Answered correctly

04 secs
Time Spent

2023
Version

Explanation

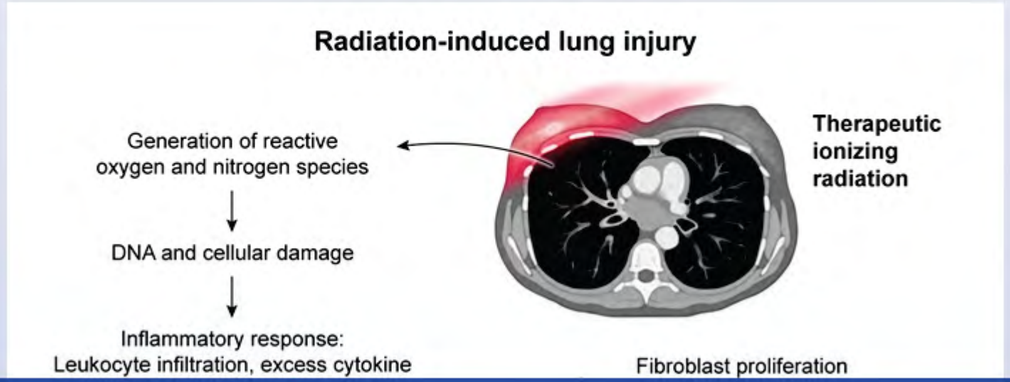

https://t.me/USMLEWorldStep1

Radiation-induced lung injury

Exhibit Display

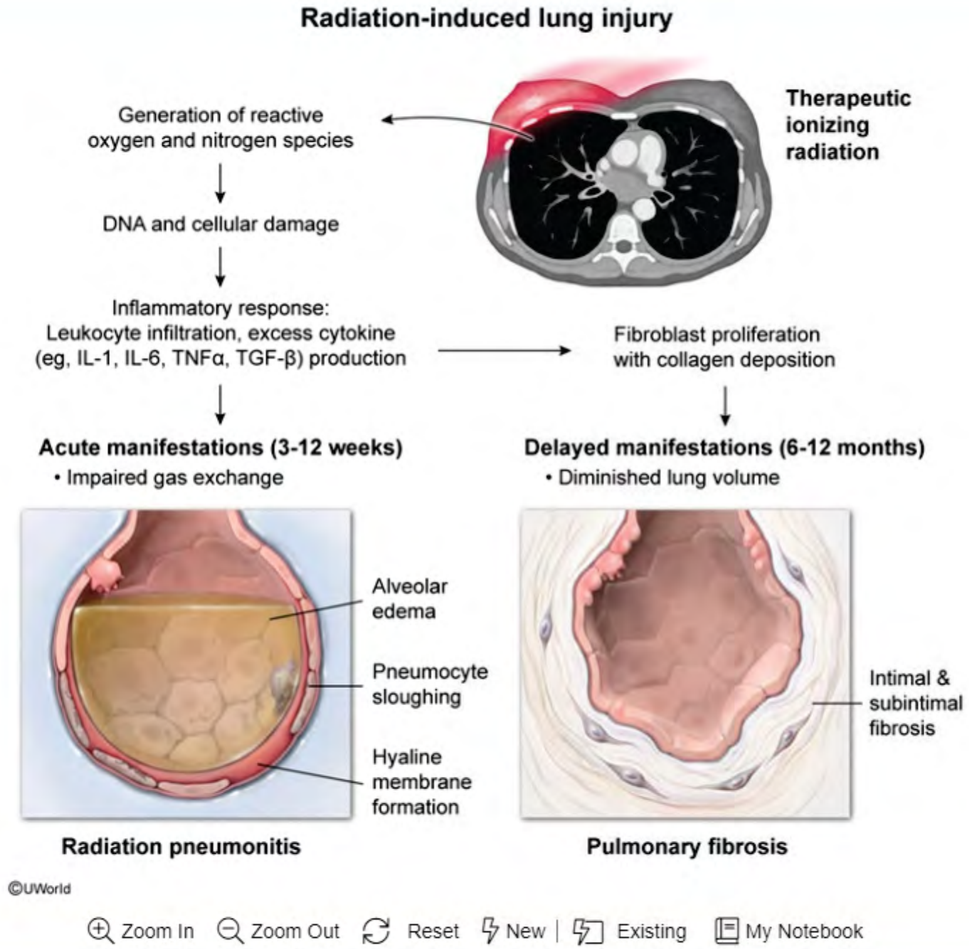

Zoom In | Zoom Out | Reset | New | Existing | My Notebook

Radiat
breast
and in
cellula

In the lung, this damage primarily affects the alveolar-capillary barrier, formed from alveolar epithelial cells (ie, **pneumocytes**) and vascular endothelial cells, and initiates an **inflammatory response** with a cascade of

https://t.me/USMLEWorldStep1

Radiation-induced lung injury usually occurs following **thoracic irradiation** for the treatment of malignancy (eg, breast or lung cancers, lymphoma). Ionizing radiation causes **DNA damage** directly (eg, double-strand breaks) and indirectly through generation of reactive oxygen and nitrogen species that can damage both DNA and other cellular components.

In the lung, this damage primarily affects the alveolar-capillary barrier, formed from alveolar epithelial cells (ie, **pneumocytes**) and vascular endothelial cells, and initiates an **inflammatory response** with a cascade of cytokines (eg, IL-1, TNFα) and growth factors (eg, PDGF, TGF-β). Manifestation vary based on chronicity:

- **Acutely**, immune-mediated damage results in impaired gas exchange due to **exudative alveolitis**, with sloughing of pneumocytes and vascular endothelial cells, alveolar/interstitial edema, and **hyaline membrane formation**. Clinically, this usually manifests as dyspnea and cough 3-12 weeks after initial radiation exposure.
- **Radiation fibrosis** is a **delayed** manifestation of radiation-induced lung injury that can develop 6-12 months after initial radiation exposure. TGF-β released by immune cells and the surrounding tissue initiates fibroblast proliferation, collagen deposition, and formation of **dense fibrous bands**. The result is decreased lung volume, dilated bronchi and bronchioles (ie, traction bronchiectasis), impaired mucociliary clearance, and predisposition to **chronic infections**.

(Choices B and C) Hemosiderin-laden macrophages (due to diffuse alveolar hemorrhage) and necrotizing vasculitis are both associated with autoimmune vasculitis (eg, anti-GBM disease). These patients typically have hemoptysis and/or other systemic effects of vasculitis (eg, glomerulonephritis, arthralgias).

(Choice D) Although significant neutrophilic infiltrate occurs in patients with radiation-induced lung injury, frank formation of an abscess usually occurs following introduction of anaerobic bacteria to the lung parenchyma due to aspiration (eg, alcohol use disorder) or septic embolism.

Educational objective:
Radiation-induced lung injury typically occurs following thoracic irradiation (eg, breast cancer), which damages pneumocytes and vascular endothelial cells and initiates an inflammatory response (eg, IL-1, TNFα, TGF-β). This immune response can have both acute (eg, exudative alveolitis, hyaline membrane formation) and delayed (eg, dense fibrosis) effects that typically manifest with cough and dyspnea.

https://t.me/USMLEWorldStep1

A 54-year-old man comes to the office due to daytime sleepiness and lack of energy. The symptoms began 6 months ago and have progressively worsened so that he feels "completely drained" by the end of the day. The patient's wife mentions that he snores loudly. His past medical history is unremarkable, although he has not seen a physician in over 10 years. The patient does not use tobacco or alcohol, and he works in the warehouse of an agricultural supply company. BMI is 34 kg/m^2. Physical examination shows a narrow oropharynx and a large neck circumference. The patient is at increased risk of developing which of the following?

- A. Bronchiectasis
- B. Hypertrophic cardiomyopathy
- C. Laryngeal carcinoma
- D. Narcolepsy
- E. Pulmonary hypertension

Submit

https://t.me/USMLEWorldStep1

A 54-year-old man comes to the office due to daytime sleepiness and lack of energy. The symptoms began 6 months ago and have progressively worsened so that he feels "completely drained" by the end of the day. The patient's wife mentions that he snores loudly. His past medical history is unremarkable, although he has not seen a physician in over 10 years. The patient does not use tobacco or alcohol, and he works in the warehouse of an agricultural supply company. BMI is 34 kg/m^2. Physical examination shows a narrow oropharynx and a large neck circumference. The patient is at increased risk of developing which of the following?

- ✗ A. Bronchiectasis (6%)
- B. Hypertrophic cardiomyopathy (9%)
- C. Laryngeal carcinoma (3%)
- D. Narcolepsy (7%)
- ✓ E. Pulmonary hypertension (73%)

Incorrect
Correct answer
E

73%
Answered correctly

04 secs
Time Spent

2023
Version

Explanation

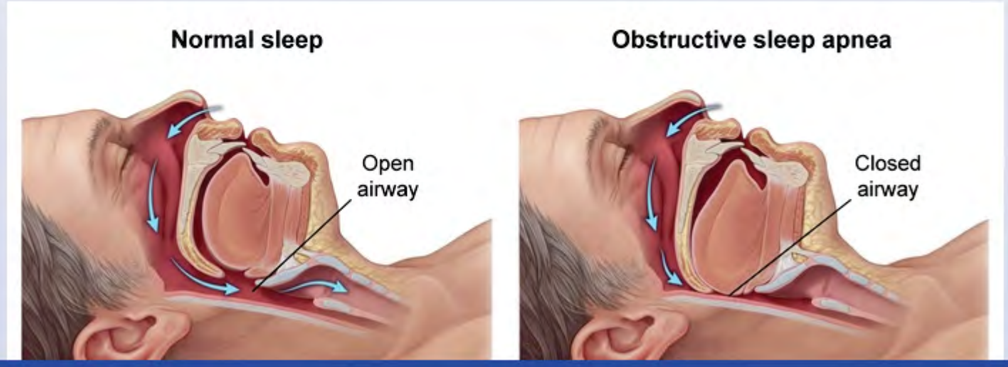

https://t.me/USMLEWorldStep1

A 54-year-old man comes to the office due to daytime sleepiness and lack of energy. The symptoms began 6
month
patien
a phys
agricu
circum

Exhibit Display

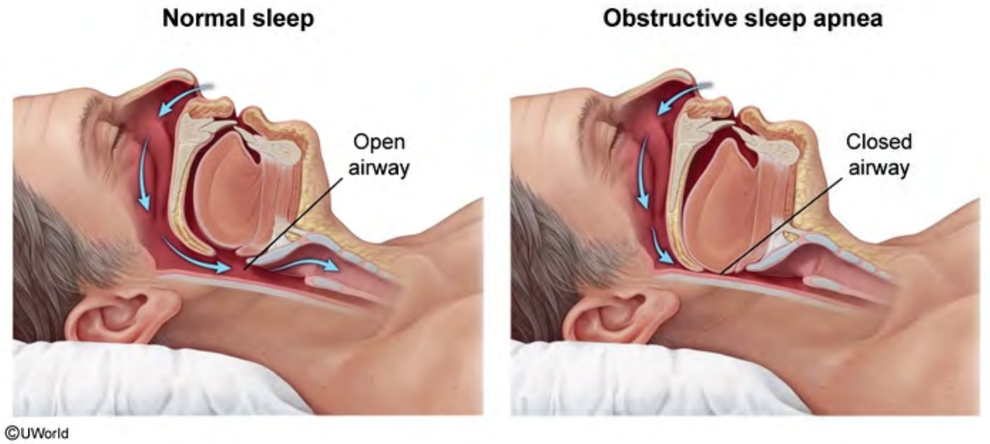

Zoom In | Zoom Out | Reset | New | Existing | My Notebook

Inco
Corre
E

Expl

https://t.me/USMLEWorldStep1

This patient, an obese man with loud snoring, daytime sleepiness, and suggestive examination findings (eg, thick neck, narrow airway) most likely has **obstructive sleep apnea** (OSA). OSA is characterized by recurrent obstruction of the upper airway during sleep; each nocturnal episode of reduced ventilation causes transient **hypercapnia** and **hypoxemia**. These blood gas derangements result in reflexive systemic and pulmonary **vasoconstriction**, endothelial dysfunction, abnormal venous return and cardiac output, and **sympathetic** cardiac stimulation.

Prolonged, untreated OSA can cause **pulmonary hypertension** and right heart failure. Most patients with OSA will develop **systemic hypertension** due to chronic sympathetic stimulation and elevated plasma norepinephrine levels. Patients also lose the normal diurnal variation in blood pressure. Other cardiovascular complications of OSA include atrial fibrillation and other arrhythmias, coronary artery disease, and increased risk of sudden cardiac death.

(Choice A) Acquired bronchiectasis may be seen in patients with recurrent infection, impaired drainage (eg, cystic fibrosis), airway obstruction (eg, foreign body aspiration), or inadequate host defense (eg, hypogammaglobulinemia).

(Choice B) Systemic hypertension, as seen in OSA, can lead to mild-to-moderate left ventricular hypertrophy and impaired systolic and diastolic function. In contrast, hypertrophic cardiomyopathy is an autosomal dominant disease of the cardiac sarcomere characterized by severe myocardial hypertrophy. It is not associated with hypertension or OSA.

(Choice C) Laryngeal carcinoma is associated with cigarette smoking and heavy alcohol use.

(Choice D) Like OSA, narcolepsy can also cause daytime drowsiness. However, narcolepsy is also associated with cataplexy (sudden loss of muscle tone), sleep attacks, sleep paralysis, and hypnagogic hallucinations. OSA is not a risk factor for narcolepsy.

Educational objective:
Obstructive sleep apnea presents in obese individuals with excessive daytime sleepiness and signs of nocturnal upper airway obstruction (eg, snoring, gasping). The condition is associated with systemic hypertension. Prolonged, untreated obstructive sleep apnea can also cause pulmonary hypertension and right heart failure.

https://t.me/USMLEWorldStep1

A 66-year-old man with poorly controlled type 2 diabetes is admitted to the hospital due to a 2-day history of fever and confusion. Blood pressure is 110/50 mm Hg. Pulse oximetry shows an oxygen saturation of 97% on room air. Examination reveals warm extremities with full peripheral pulses, an infected neuropathic foot ulcer with surrounding cellulitis, and normal lung sounds. A central venous catheter terminating in the superior vena cava is placed. Blood aspirated from the catheter appears red. Blood gas analysis of this venous sample reveals an oxygen saturation of 87% (normal: 65%-70%), and lactate is moderately elevated. Which of the following is the most likely cause of this patient's abnormal blood gas findings?

- A. Decreased cardiac output to the vital organs
- B. Impaired mitochondrial oxidative respiration in the vital organs
- C. Large-vessel thrombosis throughout the vital organs
- D. Poor uptake of oxygen in the lungs
- E. Stronger oxygen-hemoglobin binding in peripheral tissues

Submit

https://t.me/USMLEWorldStep1

A 66-year-old man with poorly controlled type 2 diabetes is admitted to the hospital due to a 2-day history of fever and confusion. Blood pressure is 110/50 mm Hg. Pulse oximetry shows an oxygen saturation of 97% on room air. Examination reveals warm extremities with full peripheral pulses, an infected neuropathic foot ulcer with surrounding cellulitis, and normal lung sounds. A central venous catheter terminating in the superior vena cava is placed. Blood aspirated from the catheter appears red. Blood gas analysis of this venous sample reveals an oxygen saturation of 87% (normal: 65%-70%), and lactate is moderately elevated. Which of the following is the most likely cause of this patient's abnormal blood gas findings?

- A. Decreased cardiac output to the vital organs (7%)
- ✓ B. Impaired mitochondrial oxidative respiration in the vital organs (48%)
- C. Large-vessel thrombosis throughout the vital organs (3%)
- D. Poor uptake of oxygen in the lungs (3%)
- E. Stronger oxygen-hemoglobin binding in peripheral tissues (36%)

Correct

48% Answered correctly

04 secs Time Spent

2023 Version

Explanation

Abnormal oxygen metabolism in sepsis	
↓ **Global O_2 delivery**	• Hypovolemia: ↓ ECBV (capillary leak) • Hypoxemia: ↓ PaO_2 (ARDS)
↓ **Microcirculatory O_2 extraction**	• Vasodilation: rapid shunting of blood through organs • Edema: ↓ O_2 diffusion (↑ interstitial distance) • Microthrombosis: capillary obstruction

https://t.me/USMLEWorldStep1

Abnormal oxygen metabolism in sepsis	
↓ Global O_2 delivery	• Hypovolemia: ↓ ECBV (capillary leak) • Hypoxemia: ↓ PaO_2 (ARDS)
↓ Microcirculatory O_2 extraction	• Vasodilation: rapid shunting of blood through organs • Edema: ↓ O_2 diffusion (↑ interstitial distance) • Microthrombosis: capillary obstruction
↓ Mitochondrial O_2 use	• ROS ⇄ mitochondrial damage & ↓ ETC function • Result: ↓ oxidative phosphorylation & ↓ ATP production

ARDS = acute respiratory distress syndrome; **ATP** = adenosine triphosphate; **ECBV** = effective circulatory blood volume; **ETC** = electron transport chain; **PaO_2** = arterial partial pressure of oxygen; **ROS** = reactive oxygen species.

This patient has **sepsis** due to an infected diabetic foot ulcer with surrounding cellulitis. Sepsis is a florid host inflammatory response to infection that can lead to multiple organ system dysfunction.

Septic organ dysfunction is driven mainly by **poor tissue oxygen use**. This cellular dysoxia is caused by 3 major mechanisms:

- Bacterial components (eg, endotoxin) and acute phase cytokines (eg, IL-1-beta) trigger production of free radicals that damage mitochondria and interfere with the electron transport chain. Immediate postmortem analysis of patients with sepsis reveals surprisingly minimal tissue necrosis but, often, extensive mitochondrial damage. This mitochondrial dysfunction leads to **decreased oxidative phosphorylation** with loss of ATP production. A compensatory bioenergetic shift toward glycolysis often results in **lactic acidosis**.
- Widespread microcirculatory failure with vasodilation causes blood to shunt rapidly through organs, decreasing the opportunity for oxygen extraction.
- Increased capillary permeability causes tissue edema (third spacing), which increases the diffusion distance for oxygen to reach mitochondria of target cells.

https://t.me/USMLEWorldStep1

O_2 use	• Result: ↓ oxidative phosphorylation & ↓ ATP production

ARDS = acute respiratory distress syndrome; **ATP** = adenosine triphosphate; **ECBV** = effective circulatory blood volume; **ETC** = electron transport chain; **PaO_2** = arterial partial pressure of oxygen; **ROS** = reactive oxygen species.

This patient has **sepsis** due to an infected diabetic foot ulcer with surrounding cellulitis. Sepsis is a florid host inflammatory response to infection that can lead to multiple organ system dysfunction.

Septic organ dysfunction is driven mainly by **poor tissue oxygen use**. This cellular dysoxia is caused by 3 major mechanisms:

- Bacterial components (eg, endotoxin) and acute phase cytokines (eg, IL-1-beta) trigger production of free radicals that damage mitochondria and interfere with the electron transport chain. Immediate postmortem analysis of patients with sepsis reveals surprisingly minimal tissue necrosis but, often, extensive mitochondrial damage. This mitochondrial dysfunction leads to **decreased oxidative phosphorylation** with loss of ATP production. A compensatory bioenergetic shift toward glycolysis often results in **lactic acidosis**.
- Widespread microcirculatory failure with vasodilation causes blood to shunt rapidly through organs, decreasing the opportunity for oxygen extraction.
- Increased capillary permeability causes tissue edema (third spacing), which increases the diffusion distance for oxygen to reach mitochondria of target cells.

Because oxygen use decreases, the transorgan arteriovenous oxygen gradient is small; therefore, **oxygen saturation of central venous blood** ($ScvO_2$) (superior vena cava) – returning from the periphery – **increases**. Central venous catheters are often placed therapeutically to deliver medications; they can be used diagnostically to differentiate septic (↑ **$ScvO_2$**) from cardiogenic (↓ $ScvO_2$) shock.

(Choice A) Cardiac output (oxygen delivery) is typically increased in sepsis due to systemic vasodilation (warm extremities, wide pulse pressure). Decreased cardiac output is the hallmark of severe heart failure (cold extremities, narrow pulse pressure), and $ScvO_2$ decreases with heart failure because peripheral oxygen consumption outstrips its delivery.

(Choice C) Sepsis is associated with *microvascular* (rather than macrovascular) thrombosis due to endothelial

https://t.me/USMLEWorldStep1

- Widespread microcirculatory failure with vasodilation causes blood to shunt rapidly through organs, decreasing the opportunity for oxygen extraction.
- Increased capillary permeability causes tissue edema (third spacing), which increases the diffusion distance for oxygen to reach mitochondria of target cells.

Because oxygen use decreases, the transorgan arteriovenous oxygen gradient is small; therefore, **oxygen saturation of central venous blood** ($ScvO_2$) (superior vena cava) – returning from the periphery – **increases**. Central venous catheters are often placed therapeutically to deliver medications; they can be used diagnostically to differentiate septic (↑ **$ScvO_2$**) from cardiogenic (↓ $ScvO_2$) shock.

(Choice A) Cardiac output (oxygen delivery) is typically increased in sepsis due to systemic vasodilation (warm extremities, wide pulse pressure). Decreased cardiac output is the hallmark of severe heart failure (cold extremities, narrow pulse pressure), and $ScvO_2$ decreases with heart failure because peripheral oxygen consumption outstrips its delivery.

(Choice C) Sepsis is associated with *microvascular* (rather than macrovascular) thrombosis due to endothelial injury and focal or disseminated intravascular coagulation, further impairing oxygenation. Widespread large-vessel thrombosis and infarction are seen in conditions such as catastrophic antiphospholipid-antibody syndrome.

(Choice D) Sepsis can induce capillary permeability in the lung, leading to pulmonary edema with resultant arterial hypoxemia (acute respiratory distress syndrome). However, this patient's pulmonary function and oxygenation are intact, as evidenced by normal lung examination (no crackles) and arterial oxygen saturation.

(Choice E) Hemoglobin oxygen unloading to peripheral tissues is facilitated by sepsis-induced (lactic) acidosis and fever, which lead to rightward shifting of the oxyhemoglobin dissociation curve (ie, weaker oxygen-hemoglobin binding).

Educational objective:
Sepsis is a host inflammatory response to infection that can lead to multiple organ dysfunction due to defective mitochondrial oxidative respiration, resulting in a widespread dissociation between oxygen delivery and extraction. This manifests as elevated central venous oxygen saturation.

https://t.me/USMLEWorldStep1

O_2 extraction	• Edema: ↓ O_2 diffusion (↑ interstitial distance) • Microthrombosis: capillary obstruction
AR vol	

This p
inflam

Septic
mecha

- B
  r
  a
  d
  p
- W
  d
- In
  fo

Becau
satura
Centra

Exhibit Display

Septic organ dysfunction	
CNS	• Delirium ("septic encephalopathy")
Cardiovascular	• Vasodilation & distributive shock • Capillary leak (edema) • Myocardial depression (severe)
Pulmonary	• Noncardiogenic pulmonary edema (ARDS)
Renal	• Acute kidney injury (ATN)
Hematologic	• Disseminated intravascular coagulation • Acute bone marrow suppression (eg, thrombocytopenia)
Endocrine	• Glucose dysregulation (hypoglycemia, hyperglycemia) • Primary adrenal insufficiency
Gastrointestinal & hepatic	• Cholestatic & hepatocellular liver injury • Paralytic ileus
Neuromuscular	• Polyneuropathy & myopathy
ARDS = acute respiratory distress syndrome; **ATN** = acute tubular necrosis.	

New | Existing | My Notebook

differentiate septic (↑ **$ScvO_2$**) from cardiogenic (↓ $ScvO_2$) shock.

(Choice A) Cardiac output (oxygen delivery) is typically increased in sepsis due to systemic vasodilation (warm extremities, wide pulse pressure). Decreased cardiac output is the hallmark of severe heart failure (cold

https://t.me/USMLEWorldStep1

Because oxygen use decreases, the transorgan arteriovenous oxygen gradient is small; therefore, **oxygen saturation of central venous blood** ($ScvO_2$) (superior vena cava) – returning from the periphery – **increases**.

Centra
differe

(Choi
extrem
extrem
consu

(Choi
injury
thromb

(Choi
hypox
intact,

(Choi
and fe
bindin

Educa
Sepsis
mitoch
This m

Refere
- Oxi

Pathoph
Subject

Copyright © UWorld. All rights reserved.

Exhibit Display

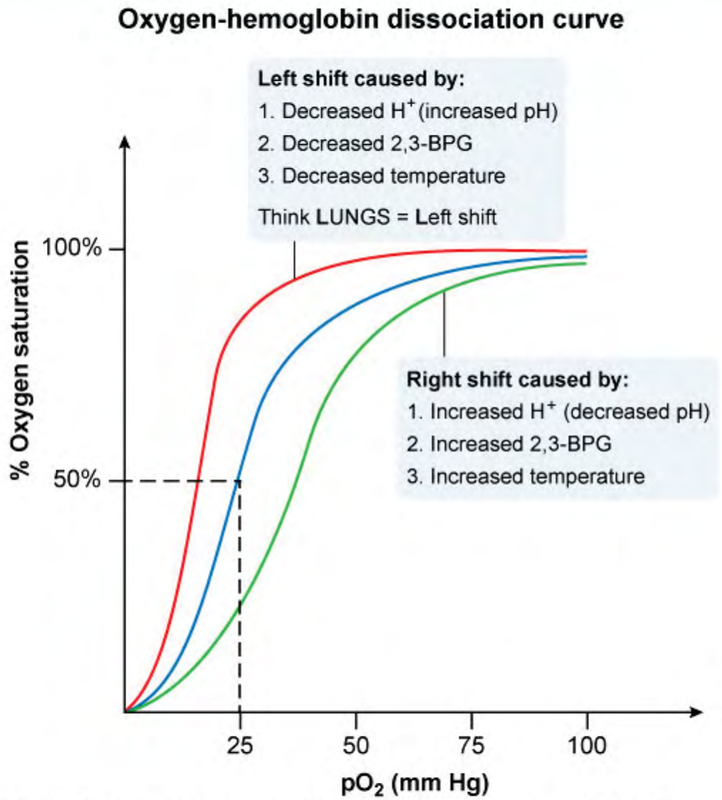

2,3-BPG = 2,3-bisphosphoglycerate; **pO_2** = partial pressure of oxygen in the blood.

©UWorld

Zoom In | Zoom Out | Reset | New | Existing | My Notebook

https://t.me/USMLEWorldStep1

A 56-year-old man is hospitalized due to worsening fever, chills, and perirectal pain. Physical examination reveals a large perirectal abscess. Empiric antibiotics are begun, and surgical drainage is planned. The patient receives succinylcholine and propofol prior to the procedure. The intraoperative course is uneventful, but postoperative spontaneous recovery of respiration and voluntary muscle activity does not occur. Mechanical respiratory support is continued, and several hours later, the patient is successfully weaned from the ventilator. Which of the following is the most likely underlying cause of this patient's postoperative complications?

- A. Decreased renal clearance
- B. Drug redistribution to other tissues
- C. Genetic polymorphism
- D. Impaired hepatic function
- E. Neuromuscular junction autoantibodies

Submit

https://t.me/USMLEWorldStep1

A 56-year-old man is hospitalized due to worsening fever, chills, and perirectal pain. Physical examination reveals a large perirectal abscess. Empiric antibiotics are begun, and surgical drainage is planned. The patient receives succinylcholine and propofol prior to the procedure. The intraoperative course is uneventful, but postoperative spontaneous recovery of respiration and voluntary muscle activity does not occur. Mechanical respiratory support is continued, and several hours later, the patient is successfully weaned from the ventilator. Which of the following is the most likely underlying cause of this patient's postoperative complications?

- A. Decreased renal clearance (8%)
- ✗ B. Drug redistribution to other tissues (15%)
- ✓ C. Genetic polymorphism (54%)
- D. Impaired hepatic function (10%)
- E. Neuromuscular junction autoantibodies (11%)

Incorrect
Correct answer
C

54%
Answered correctly

03 secs
Time Spent

2023
Version

Explanation

Succinylcholine is a depolarizing neuromuscular blocking agent used to induce skeletal relaxation during intubation and surgery. It acts as a **competitive agonist** of nicotinic acetylcholine receptors of the motor endplate, where it induces persistent depolarization, leading to endplate desensitization and skeletal muscle paralysis. Succinylcholine is rapidly metabolized by **plasma pseudocholinesterase**; only around 10% of the administered dose reaches the neuromuscular junction, where it typically has a duration of action of <10 minutes.

This patient, who developed **prolonged muscle weakness** (eg, failure of spontaneous respiration and voluntary muscle activity) after receiving succinylcholine, most likely has **pseudocholinesterase deficiency**, an autosomal recessive disorder caused by a **genetic polymorphism** in the *BCHE* gene. Patients are unable to metabolize

https://t.me/USMLEWorldStep1

Succinylcholine is a depolarizing neuromuscular blocking agent used to induce skeletal relaxation during intubation and surgery. It acts as a **competitive agonist** of nicotinic acetylcholine receptors of the motor endplate, where it induces persistent depolarization, leading to endplate desensitization and skeletal muscle paralysis. Succinylcholine is rapidly metabolized by **plasma pseudocholinesterase**; only around 10% of the administered dose reaches the neuromuscular junction, where it typically has a duration of action of <10 minutes.

This patient, who developed **prolonged muscle weakness** (eg, failure of spontaneous respiration and voluntary muscle activity) after receiving succinylcholine, most likely has **pseudocholinesterase deficiency**, an autosomal recessive disorder caused by a **genetic polymorphism** in the *BCHE* gene. Patients are unable to metabolize succinylcholine, leading to a large amount of the drug reaching the neuromuscular junction and prolonged paralysis. Heterozygotes may experience double the normal duration of paralysis, and homozygotes can have persistent paralysis for **several hours**. Patients with pseudocholinesterase deficiency also experience prolonged effects of mivacurium (a nondepolarizing neuromuscular blocker) and cocaine.

(Choices A and D) Succinylcholine is metabolized by plasma pseudocholinesterase, not the liver or kidneys. Because pseudocholinesterase is produced in the liver, patients with severe liver disease may have prolonged drug effects due to impaired synthetic function. However, paralysis would not be expected to last for hours.

(Choice B) Propofol is highly lipid soluble and has a very short duration of action (seconds) because of rapid redistribution from the brain, where it activates the GABA-A receptor, to other tissues. Propofol is a hypnotic agent; it does not cause muscle paralysis.

(Choice E) Patients with myasthenia gravis (ie, autoantibodies to the acetylcholine receptors of the neuromuscular junction) have fewer active acetylcholine receptors and are therefore highly resistant to succinylcholine. Paralysis can occur with high doses but is unpredictable. Use is usually avoided in this population.

Educational objective:
Succinylcholine is a depolarizing neuromuscular blocking agent used to induce skeletal muscle relaxation; it typically has a very short duration of action due to metabolism by plasma pseudocholinesterase. Pseudocholinesterase deficiency is an autosomal recessive disorder that results in the inability to metabolize succinylcholine, leading to prolonged neuromuscular paralysis after drug administration.

https://t.me/USMLEWorldStep1

Succinylcholine is a depolarizing neuromuscular blocking agent used to induce skeletal relaxation during intubation and surgery. It acts as a **competitive agonist** of nicotinic acetylcholine receptors of the motor endplate, where it induces persistent depolarization, leading to endplate desensitization and skeletal muscle paralysis. Succinylcholine is rapidly metabolized by **plasma pseudocholinesterase**; only around 10% of the administered dose reaches the neuromuscular junction, where it typically has a duration of action of <10 minutes.

This patient, who developed **prolonged muscle weakness** (eg, failure of spontaneous respiration and voluntary muscle activity) after receiving succinylcholine, most likely has **pseudocholinesterase deficiency**, an autosomal recessive disorder caused by a **genetic polymorphism** in the *BCHE* gene. Patients are unable to metabolize succinylcholine, leading to a large amount of the drug reaching the neuromuscular junction and prolonged paralysis. Heterozygotes may experience double the normal duration of paralysis, and homozygotes can have persistent paralysis for **several hours**. Patients with pseudocholinesterase deficiency also experience prolonged effects of mivacurium (a nondepolarizing neuromuscular blocker) and cocaine.

(Choices A and D) Succinylcholine is metabolized by plasma pseudocholinesterase, not the liver or kidneys. Because pseudocholinesterase is produced in the liver, patients with severe liver disease may have prolonged drug effects due to impaired synthetic function. However, paralysis would not be expected to last for hours.

(Choice B) Propofol is highly lipid soluble and has a very short duration of action (seconds) because of rapid redistribution from the brain, where it activates the GABA-A receptor, to other tissues. Propofol is a hypnotic agent; it does not cause muscle paralysis.

(Choice E) Patients with myasthenia gravis (ie, autoantibodies to the acetylcholine receptors of the neuromuscular junction) have fewer active acetylcholine receptors and are therefore highly resistant to succinylcholine. Paralysis can occur with high doses but is unpredictable. Use is usually avoided in this population.

Educational objective:
Succinylcholine is a depolarizing neuromuscular blocking agent used to induce skeletal muscle relaxation; it typically has a very short duration of action due to metabolism by plasma pseudocholinesterase. Pseudocholinesterase deficiency is an autosomal recessive disorder that results in the inability to metabolize succinylcholine, leading to prolonged neuromuscular paralysis after drug administration.

https://t.me/USMLEWorldStep1

A 7-year-old girl is brought to the emergency department due to 2 days of fever, productive cough, and shortness of breath. Medical history is significant for recurrent lung infections and cystic fibrosis. Weight is at the 5th percentile. Temperature is 38.1 C (100.6 F), pulse is 104/min, and respirations are 30/min. Pulse oximetry is 86% on room air. Examination shows a thin girl with digital clubbing and a hyperexpanded chest. Diffuse wheezes and crackles are present bilaterally. The rest of the examination is unremarkable. Chest x-ray reveals hyperinflation, chronic interstitial changes, and an infiltrate in the right lower lobe. Gram stain of sputum shows gram-negative rods. Which of the following is the most likely cause of this patient's recurrent infections?

- A. Deficient natural killer cell formation
- B. Development of bacterial macrocolonies
- C. Dysfunctional free radical production by neutrophils
- D. Inability to form the membrane attack complex
- E. Reduced endobronchial protease activity

Submit

https://t.me/USMLEWorldStep1

A 7-year-old girl is brought to the emergency department due to 2 days of fever, productive cough, and shortness of breath. Medical history is significant for recurrent lung infections and cystic fibrosis. Weight is at the 5th percentile. Temperature is 38.1 C (100.6 F), pulse is 104/min, and respirations are 30/min. Pulse oximetry is 86% on room air. Examination shows a thin girl with digital clubbing and a hyperexpanded chest. Diffuse wheezes and crackles are present bilaterally. The rest of the examination is unremarkable. Chest x-ray reveals hyperinflation, chronic interstitial changes, and an infiltrate in the right lower lobe. Gram stain of sputum shows gram-negative rods. Which of the following is the most likely cause of this patient's recurrent infections?

- A. Deficient natural killer cell formation (2%)
- ✓ B. Development of bacterial macrocolonies (59%)
- C. Dysfunctional free radical production by neutrophils (10%)
- D. Inability to form the membrane attack complex (7%)
- E. Reduced endobronchial protease activity (20%)

Correct

59% Answered correctly

03 secs Time Spent

2023 Version

Explanation

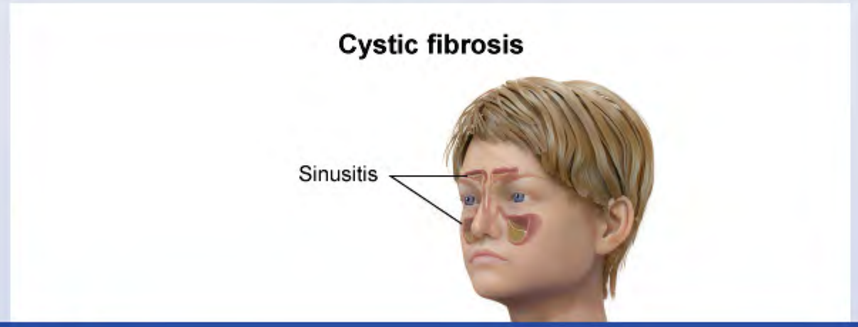

https://t.me/USMLEWorldStep1

E. Reduced endobronchial protease activity (20%)

Exhibit Display

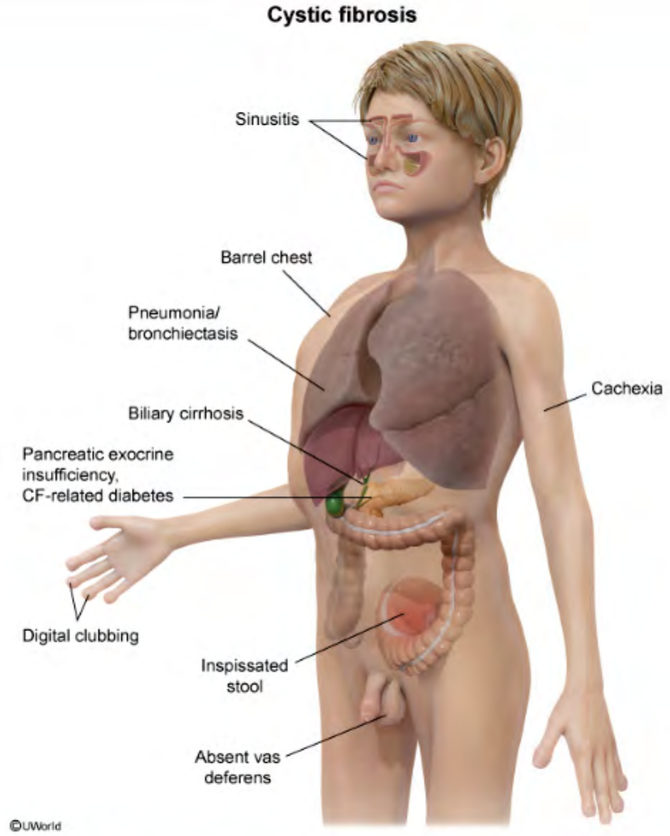

Zoom In | Zoom Out | Reset | New | Existing | My Notebook

https://t.me/USMLEWorldStep1

Cystic fibrosis (CF) is a multisystem disorder in which a **defective chloride channel** (CF transmembrane conductance regulator) prevents the normal hydration of mucus. Accumulation of **thick, viscous secretions** in the lungs leads to mucus plugging and progressive bronchiectasis, which manifest as obstructive lung disease (eg, hyperinflated lungs, barrel chest) and chronic hypoxia (eg, digital clubbing). Gastrointestinal involvement can also lead to malabsorption with decreased body weight.

The abnormal airway secretions in patients with CF impair mucociliary clearance and allow **colonization** of bacteria such as *Haemophilus influenzae*, *Staphylococcus aureus*, and, over time, **gram-negative rods** such as ***Pseudomonas aeruginosa*** and *Burkholderia cepacia* complex.

The microenvironment is particularly suitable to mucoid *P aeruginosa* because localized hypoxia within the airway mucus causes the bacterium to lose motility and produce alginate, a polysaccharide involved in **biofilm formation**. The biofilm acts as a **protective matrix** for the development of *Pseudomonas* **macrocolonies**, which are difficult to eradicate and cause recurrent and **persistent infection**.

(Choice A) Natural killer cell deficiency is associated with severe, disseminated viral infections (eg, herpes simplex virus, cytomegalovirus). This patient's infiltrate in the right lower lobe and Gram stain findings are consistent with bacterial pneumonia, and she has no history of severe or recurrent viral infection.

(Choice C) Neutrophil free radical formation is impaired in chronic granulomatous disease, which is characterized by recurrent multiorgan (eg, lungs, liver, lymph nodes, skin) infections by catalase-positive organisms (eg, *Aspergillus*, *S aureus*). In contrast, this patient has isolated, chronic pulmonary findings. Moreover, CF results in excessive neutrophil free radical formation due to persistent pulmonary infection, which contributes to the progressive lung damage seen in these patients.

(Choice D) Inability to form the membrane attack complex occurs with terminal complement deficiency. These patients have recurrent *Neisseria* meningitis, not lung infections.

(Choice E) Bacterial colonization in the lungs of patients with CF induces a massive infiltration of neutrophils, which results in the release of elastase, a protease that promotes bronchiectasis. Therefore, chronic lung disease

https://t.me/USMLEWorldStep1

lead to malabsorption with decreased body weight.

The abnormal airway secretions in patients with CF impair mucociliary clearance and allow **colonization** of bacteria such as *Haemophilus influenzae*, *Staphylococcus aureus*, and, over time, **gram-negative rods** such as ***Pseudomonas aeruginosa*** and *Burkholderia cepacia* complex.

The microenvironment is particularly suitable to mucoid *P aeruginosa* because localized hypoxia within the airway mucus causes the bacterium to lose motility and produce alginate, a polysaccharide involved in **biofilm formation**. The biofilm acts as a **protective matrix** for the development of *Pseudomonas* **macrocolonies**, which are difficult to eradicate and cause recurrent and **persistent infection**.

(Choice A) Natural killer cell deficiency is associated with severe, disseminated viral infections (eg, herpes simplex virus, cytomegalovirus). This patient's infiltrate in the right lower lobe and Gram stain findings are consistent with bacterial pneumonia, and she has no history of severe or recurrent viral infection.

(Choice C) Neutrophil free radical formation is impaired in chronic granulomatous disease, which is characterized by recurrent multiorgan (eg, lungs, liver, lymph nodes, skin) infections by catalase-positive organisms (eg, *Aspergillus*, *S aureus*). In contrast, this patient has isolated, chronic pulmonary findings. Moreover, CF results in excessive neutrophil free radical formation due to persistent pulmonary infection, which contributes to the progressive lung damage seen in these patients.

(Choice D) Inability to form the membrane attack complex occurs with terminal complement deficiency. These patients have recurrent *Neisseria* meningitis, not lung infections.

(Choice E) Bacterial colonization in the lungs of patients with CF induces a massive infiltration of neutrophils, which results in the release of elastase, a protease that promotes bronchiectasis. Therefore, chronic lung disease in CF is characterized by excessive, not reduced, endobronchial protease activity.

Educational objective:
Patients with cystic fibrosis have thick, viscous mucus that accumulates in the airways and promotes colonization of bacteria, particularly *Pseudomonas*. This gram-negative rod can produce biofilms, which act as a protective matrix that allows bacterial macrocolonies to develop, causing persistent infection.

https://t.me/USMLEWorldStep1

Exhibit Display

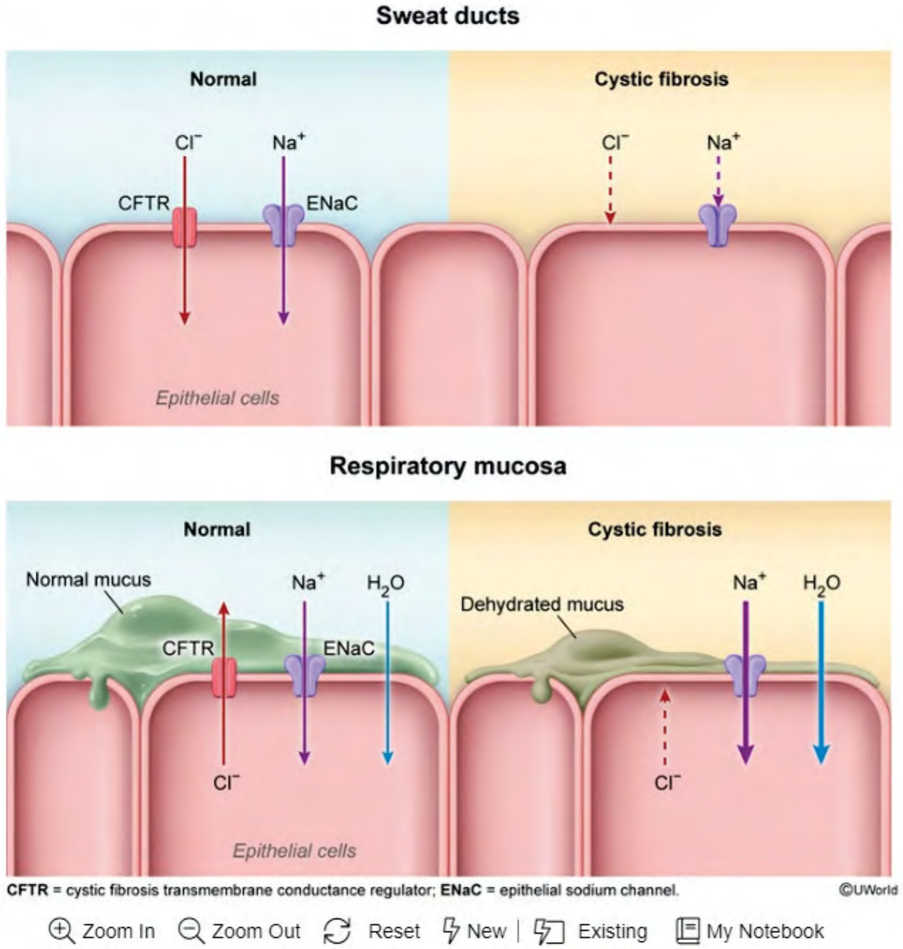

CFTR = cystic fibrosis transmembrane conductance regulator; **ENaC** = epithelial sodium channel. ©UWorld

Zoom In | Zoom Out | Reset | New | Existing | My Notebook

Cystic
condu
lungs
hyperi
lead to

The ab
bacter
Pseud

The m
mucus
forma
are dif

(Choic
simple
consis

(Choic
by recurrent multiorgan (eg, lungs, liver, lymph nodes, skin) infections by catalase-positive organisms (eg, *Aspergillus*, *S aureus*). In contrast, this patient has isolated, chronic pulmonary findings. Moreover, CF results in

https://t.me/USMLEWorldStep1

Exhibit Display

Digital clubbing

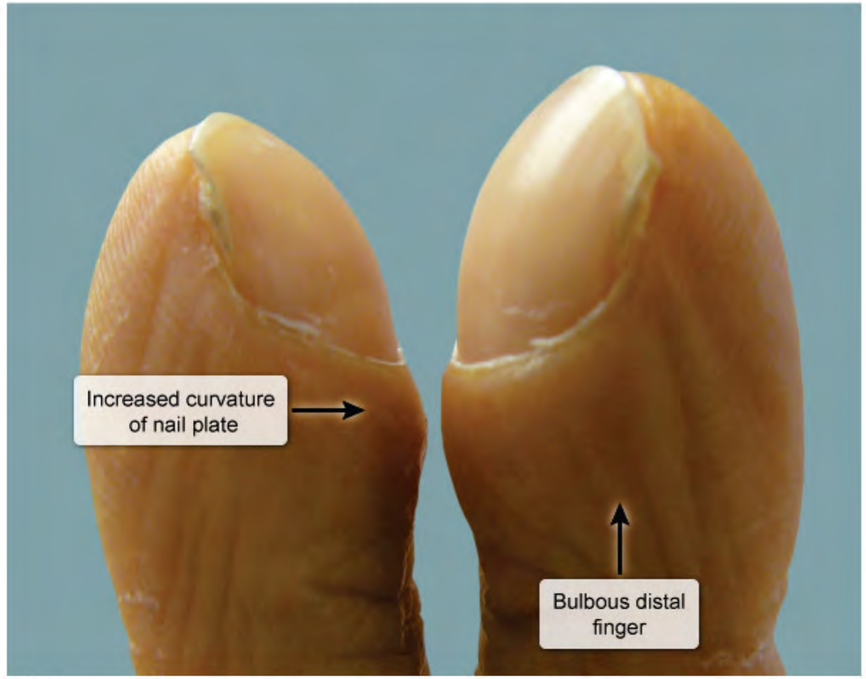

©UWorld

Zoom In | Zoom Out | Reset | New | Existing | My Notebook

Cystic
condu
lungs
hyperi
lead to

The ab
bacter
Pseud

The m
mucus
forma
are dif

(Choic
simple
consis

(Choic
by recurrent multiorgan (eg, lungs, liver, lymph nodes, skin) infections by catalase-positive organisms (eg, *Aspergillus*, *S aureus*). In contrast, this patient has isolated, chronic pulmonary findings. Moreover, CF results in

https://t.me/USMLEWorldStep1

A 37-year-old woman is evaluated for progressive shortness of breath and dry cough. The patient has seasonal allergies and takes no medications. There is no significant family history. On physical examination, the lungs are clear to auscultation. Chest imaging studies reveal pulmonary infiltrates and hilar adenopathy. The patient undergoes lung biopsy; the findings are shown below.

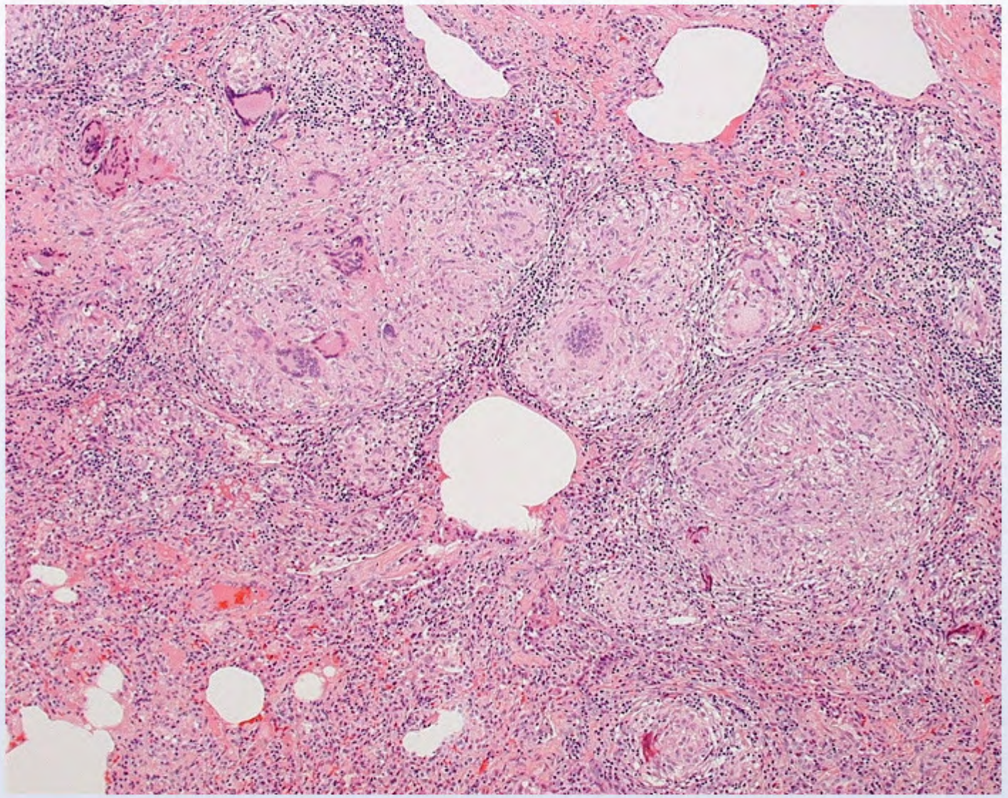

Which of the following sets of immune cells and cytokines is most likely responsible for the development of this patient's pathologic findings?

- A. Th1, IL-2, interferon-γ
- B. Th1, IL-5, IL-10

https://t.me/USMLEWorldStep1

A 37-year-old woman is evaluated for progressive shortness of breath and dry cough. The patient has seasonal allergi
clear t
underg

Exhibit Display

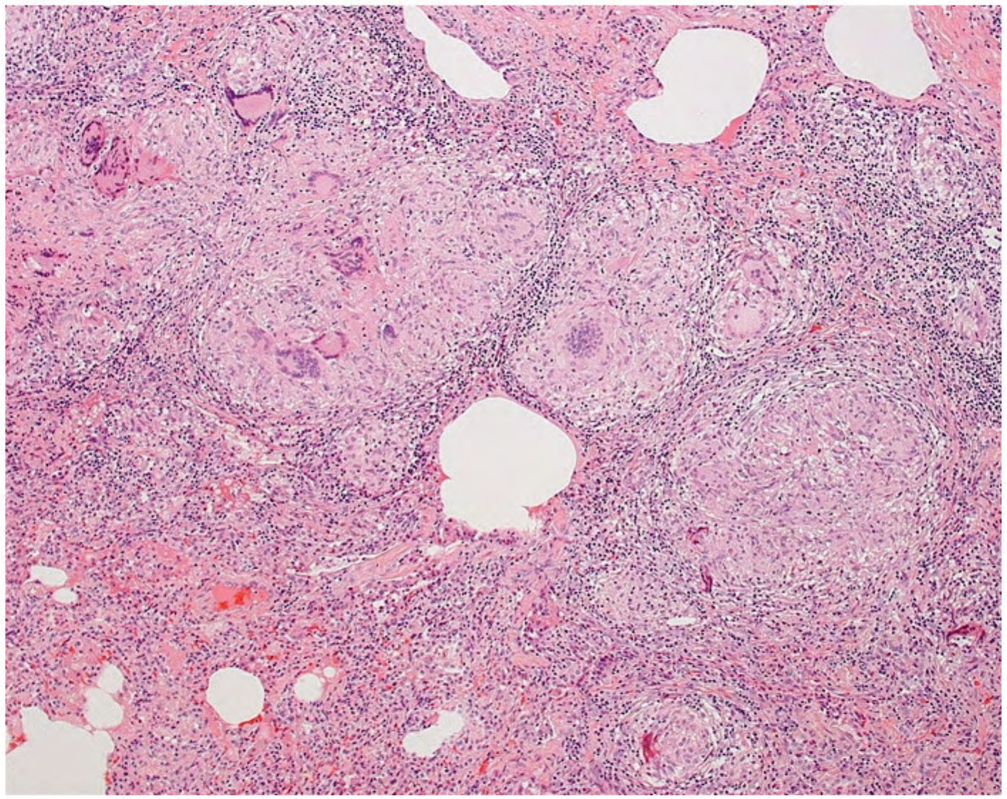

Zoom In | Zoom Out | Reset | New | Existing | My Notebook

Which
patien

B. Th1, IL-5, IL-10

https://t.me/USMLEWorldStep1

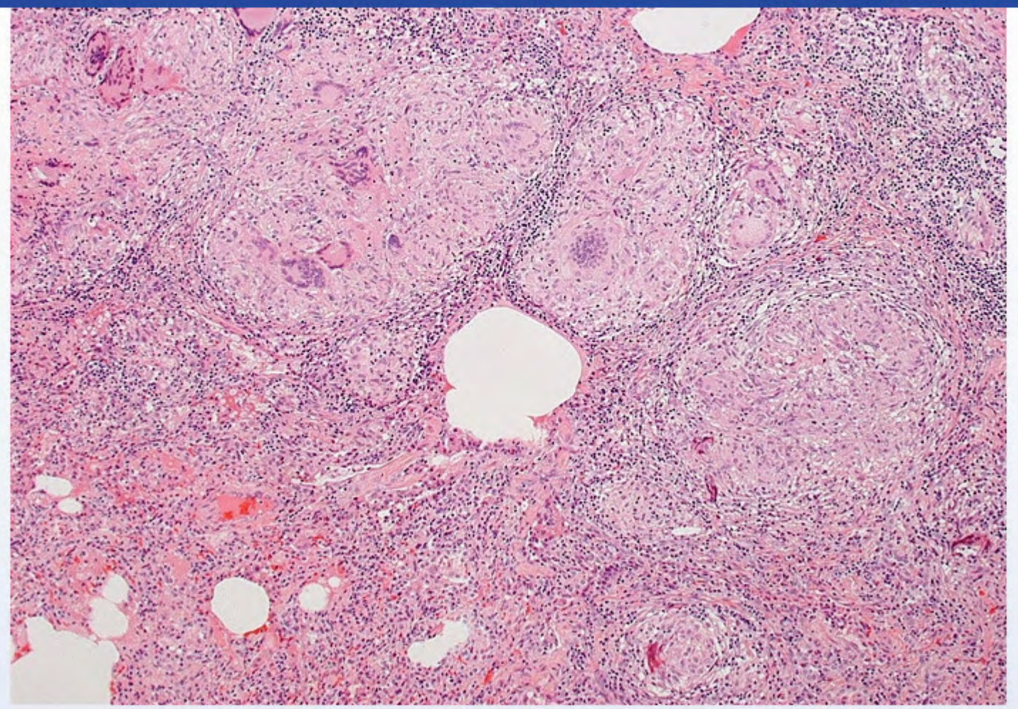

Which of the following sets of immune cells and cytokines is most likely responsible for the development of this patient's pathologic findings?

- A. Th1, IL-2, interferon-γ
- B. Th1, IL-5, IL-10
- C. Th2, IL-3, interferon-γ
- D. Th2, IL-4, IL-5
- E. Th2, IL-5, tumor necrosis factor-alpha

Submit

https://t.me/USMLEWorldStep1

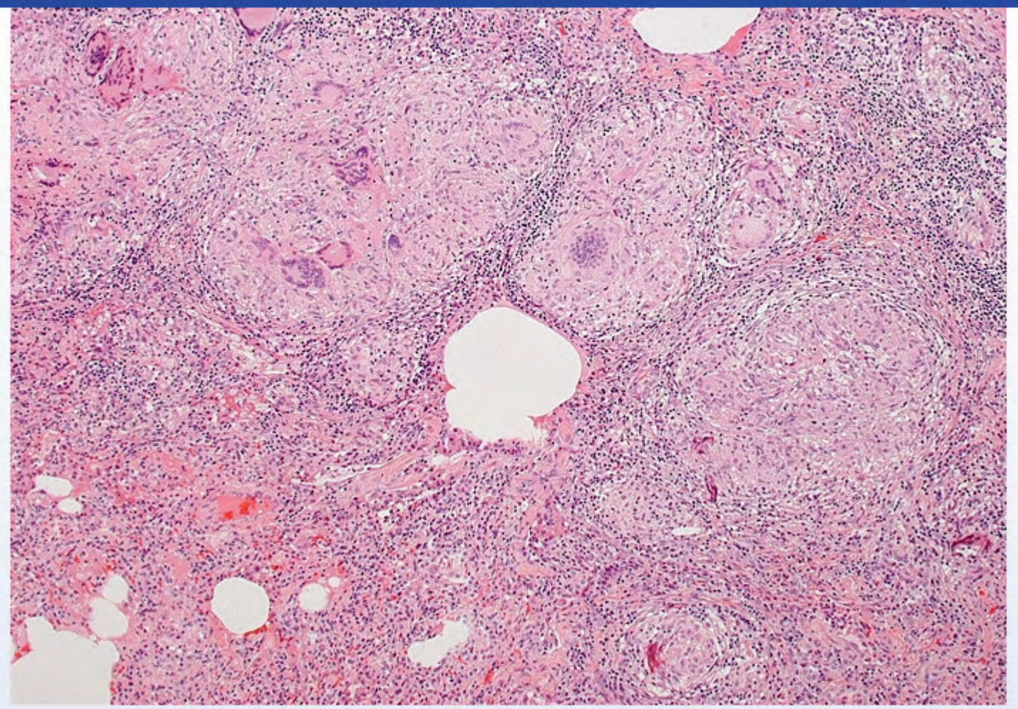

Which of the following sets of immune cells and cytokines is most likely responsible for the development of this patient's pathologic findings?

- ✓ A. Th1, IL-2, interferon-γ (68%)
- ✗ B. Th1, IL-5, IL-10 (1%)
- C. Th2, IL-3, interferon-γ (6%)
- D. Th2, IL-4, IL-5 (10%)
- E. Th2, IL-5, tumor necrosis factor-alpha (12%)

Incorrect
Correct answer
A

68%
Answered correctly

43 secs
Time Spent

2023
Version

https://t.me/USMLEWorldStep1

Incorrect
Correct answer
A

68%
Answered correctly

43 secs
Time Spent

2023
Version

Exhibit Display

Sarcoidosis

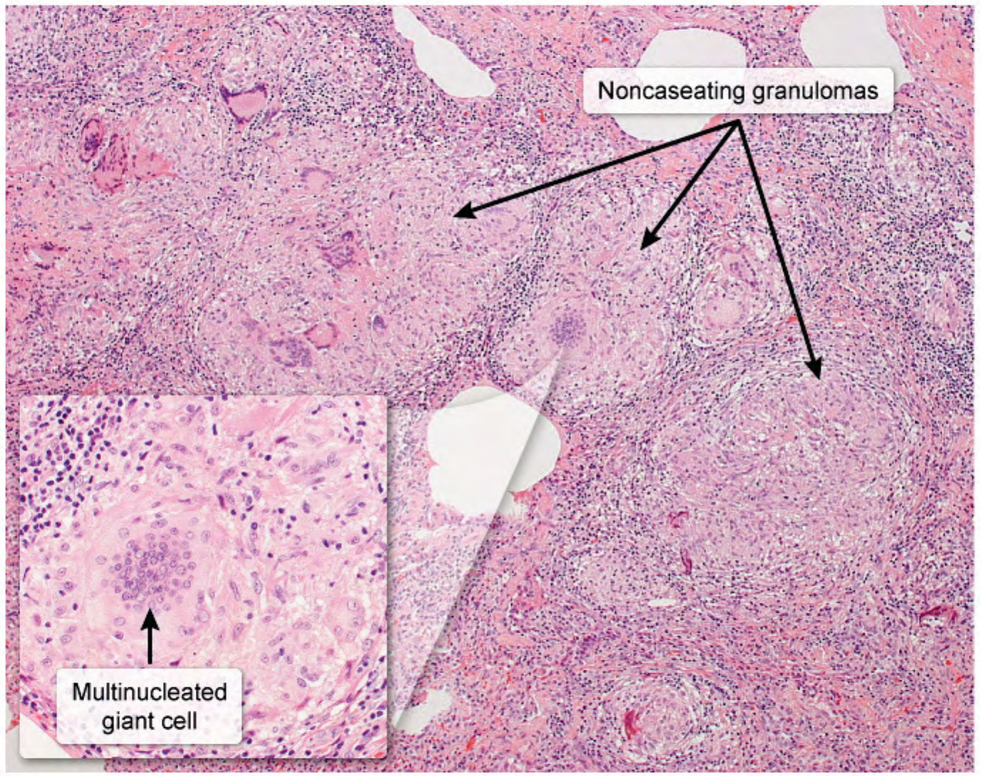

©UWorld

Zoom In | Zoom Out | Reset | New | Existing | My Notebook

This p

pulmonary **sarcoidosis**. The biopsy specimen with multiple, **noncaseating granulomas**—characterized by a

https://t.me/USMLEWorldStep1

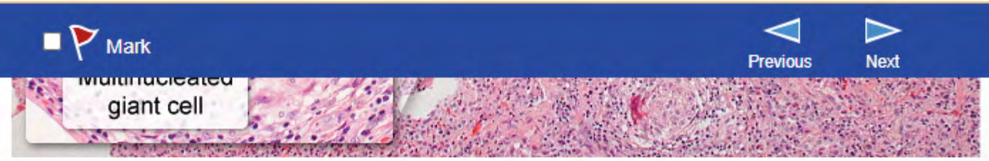

©UWorld

This patient with dyspnea and dry cough has pulmonary infiltrates and hilar adenopathy; this presentation suggests pulmonary **sarcoidosis**. The biopsy specimen with multiple, **noncaseating granulomas**—characterized by a central collection of tightly clustered epithelioid macrophages with abundant pink cytoplasm surrounded by a rim of mononuclear cells—confirms the diagnosis. Multinucleated giant cells, formed by macrophage fusion, are discernable at higher magnification.

Sarcoidosis is thought to result from a dysregulated cell-mediated immune response to an unidentified antigen, which causes the formation of granulomas. Cell-mediated immunity is stimulated by production of **IL-12** from activated antigen-presenting cells. IL-12 stimulates **CD4+ helper T cells** to differentiate into the **Th1 subtype**. Th1 cells then secrete **IL-2** and **interferon-γ** (IFN-γ). IL-2 stimulates the autocrine proliferation of Th1 cells and furthers Th1 recruitment. IFN-γ activates **macrophages** and promotes granuloma formation. Activated macrophages and T cells also produce **tumor necrosis factor-alpha**, further assisting in leukocyte recruitment and granuloma maintenance.

(Choice B) Th1 cells are central to cell-mediated immunity. However, IL-5 is a product of Th2 cells. Moreover, IL-10 is a cytokine involved in the downregulation of immune responses.

(Choices C, D, and E) Th2 cells are involved in humoral immunity and defense against extracellular parasites. Asthma, a Th2-driven disease, causes dyspnea and cough but is not associated with granuloma formation. Cytokines involved with asthma include IL-4 and IL-5, which are secreted by Th2 cells. IL-4 promotes B-cell class switching to form IgE antibodies, and IL-5 promotes eosinophil production and activation. IL-3 is also involved in asthma (as it promotes survival of mast cells) but mainly supports the growth and differentiation of bone marrow stem cells.

Educational objective:
Sarcoidosis is characterized by noncaseating granulomas due to dysregulated cell-mediated immunity. Activated antigen-presenting cells produce IL-12, which stimulates the differentiation of Th1-type $CD4^+$ cells. Th1 cells produce IL-2 and interferon-γ, which stimulate Th1 cell proliferation and macrophage activation, respectively.

https://t.me/USMLEWorldStep1

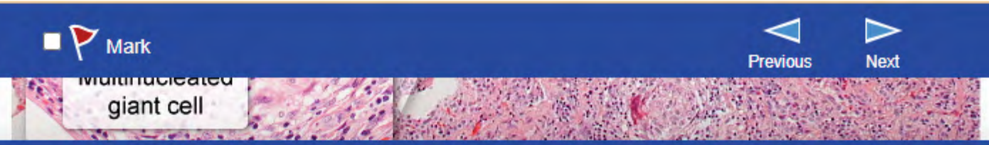

Exhibit Display

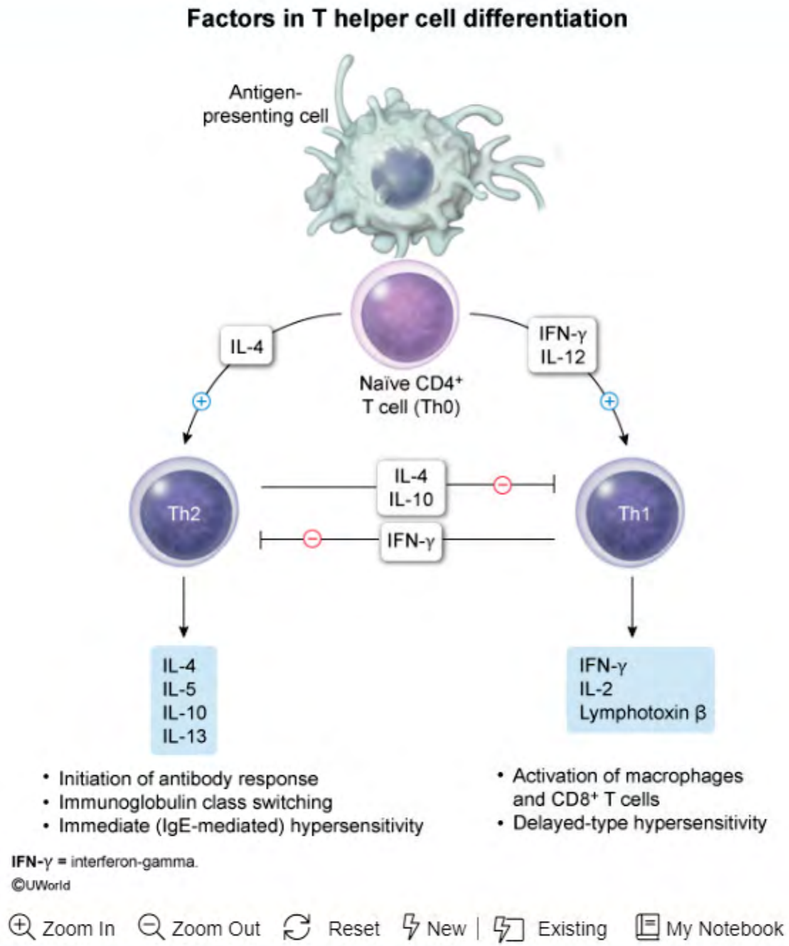

Zoom In | Zoom Out | Reset | New | Existing | My Notebook

This p
pulmo
centra
monor
discer

Sarcoi
which
activat
Th1 ce
further
macro
and gr

(Choi
10 is a

(Choi
Asthm
Cytoki
switch
asthm
stem c

Educa
Sarcoi
antige

produce IL-2 and interferon-γ, which stimulate Th1 cell proliferation and macrophage activation, respectively.

https://t.me/USMLEWorldStep1

A 35-year-old woman comes to the emergency department due to fatigue, exertional dyspnea, and cough. She has had subjective fevers but no upper respiratory symptoms, and no family members have had a similar illness. Medical history is unremarkable, and the patient does not use tobacco. Temperature is 37.5 C (99.5 F), blood pressure is 118/75 mm Hg, pulse is 90/min, and respirations are 22/min. Pulmonary examination shows normal air exchange with scattered crackles and no wheezes. The patient also has nontender cervical lymphadenopathy. Serum chemistry shows a calcium level of 12.0 mg/dL. Chest x-ray demonstrates scattered nodules and parenchymal infiltrates, as shown in the image below.

https://t.me/USMLEWorldStep1

A 35-year-old woman comes to the emergency department due to fatigue, exertional dyspnea, and cough. She has ha
Medic
pressu
excha
Serum
paren

Exhibit Display

Zoom In | Zoom Out | Reset | New | Existing | My Notebook

https://t.me/USMLEWorldStep1

Lymph node biopsy reveals noncaseating granulomas. Which of the following is the most likely cause of the elevated calcium level in this patient?

- A. Accelerated bone turnover (6%)
- ✓ B. Activated macrophages (67%)
- C. Destruction of bone tissue (4%)
- D. Increased parathyroid hormone secretion (18%)
- E. Phosphate retention (2%)

Correct

67%
Answered correctly

25 secs
Time Spent

2023
Version

https://t.me/USMLEWorldStep1

Explanation

Common features of sarcoidosis	
Epidemiology	• Young adults • African Americans

Clinical	• Constitutional symptoms
	• Cough, dyspnea & chest pain
	• Extrapulmonary findings
	  ◦ Skin lesions
	  ◦ Anterior/posterior uveitis
	  ◦ Löfgren syndrome
	• Parotid gland swelling

Imaging	• Bilateral hilar adenopathy • Pulmonary reticular infiltrates
Laboratory	• Hypercalcemia/hypercalciuria • Elevated serum ACE level
Pathology	• Biopsy showing noncaseating granulomas that stain negative for fungi & acid-fast bacilli

This patient, with systemic and respiratory symptoms, pulmonary infiltrates, lymphadenopathy, and noncaseating granulomas, has typical features of **sarcoidosis**. **Hypercalcemia** is a common feature of sarcoidosis, and even patients with normal serum calcium levels may have increased urinary excretion of calcium, suggesting abnormal calcium metabolism.

In normal individuals, 25-hydroxyvitamin D is converted to 1,25-dihydroxyvitamin D by 1-alpha-hydroxylase in the kidneys. This step is regulated primarily by parathyroid hormone (PTH) in response to blood calcium levels. However, in sarcoidosis and other granulomatous disorders, 1-alpha-hydroxylase expression in **activated**

https://t.me/USMLEWorldStep1

This patient, with systemic and respiratory symptoms, pulmonary infiltrates, lymphadenopathy, and noncaseating granulomas, has typical features of **sarcoidosis**. **Hypercalcemia** is a common feature of sarcoidosis, and even patients with normal serum calcium levels may have increased urinary excretion of calcium, suggesting abnormal calcium metabolism.

In normal individuals, 25-hydroxyvitamin D is converted to 1,25-dihydroxyvitamin D by 1-alpha-hydroxylase in the kidneys. This step is regulated primarily by parathyroid hormone (PTH) in response to blood calcium levels. However, in sarcoidosis and other granulomatous disorders, 1-alpha-hydroxylase expression in **activated macrophages** in the lung and lymph nodes causes PTH-independent production of **1,25-dihydroxyvitamin D**. This leads to increased intestinal absorption of calcium and subsequent hypercalcemia.

(Choice A) Increased bone turnover may be seen in patients with sarcoidosis who have very high 1,25-dihydroxyvitamin D levels, but this is a less significant source than intestinal absorption of calcium. Regardless, the underlying cause of both of these mechanisms is excess 1-alpha-hydroxylase expression by activated macrophages.

(Choice C) Osteolytic metastases can cause hypercalcemia due to increased bone resorption in areas surrounding malignant cells. However, this patient, a nonsmoker with noncaseating granulomas on biopsy, has no specific signs of malignancy.

(Choice D) PTH levels in sarcoidosis are typically suppressed due to elevated levels of calcium and 1,25-dihydroxyvitamin D.

(Choice E) Chronic renal failure causes phosphorus retention. The excess serum phosphorus can cause hypocalcemia by combining with intravascular calcium.

Educational objective:
Hypercalcemia in sarcoidosis is caused by parathyroid hormone-independent formation of 1,25-dihydroxyvitamin D by activated macrophages. This leads to increased intestinal absorption of calcium.

Pathology	Pulmonary & Critical Care	Sarcoidosis
Subject	System	Topic

https://t.me/USMLEWorldStep1

This patient, with systemic and respiratory symptoms, pulmonary infiltrates, lymphadenopathy, and noncaseating granul
patien
calciu

In nor
kidney
Howev
macro
This le

(Choi
dihydr
the un
macro

(Choi
surrou
specifi

(Choi
dihydr

(Choi
hypoc

Educa
Hyper
by acti

Exhibit Display

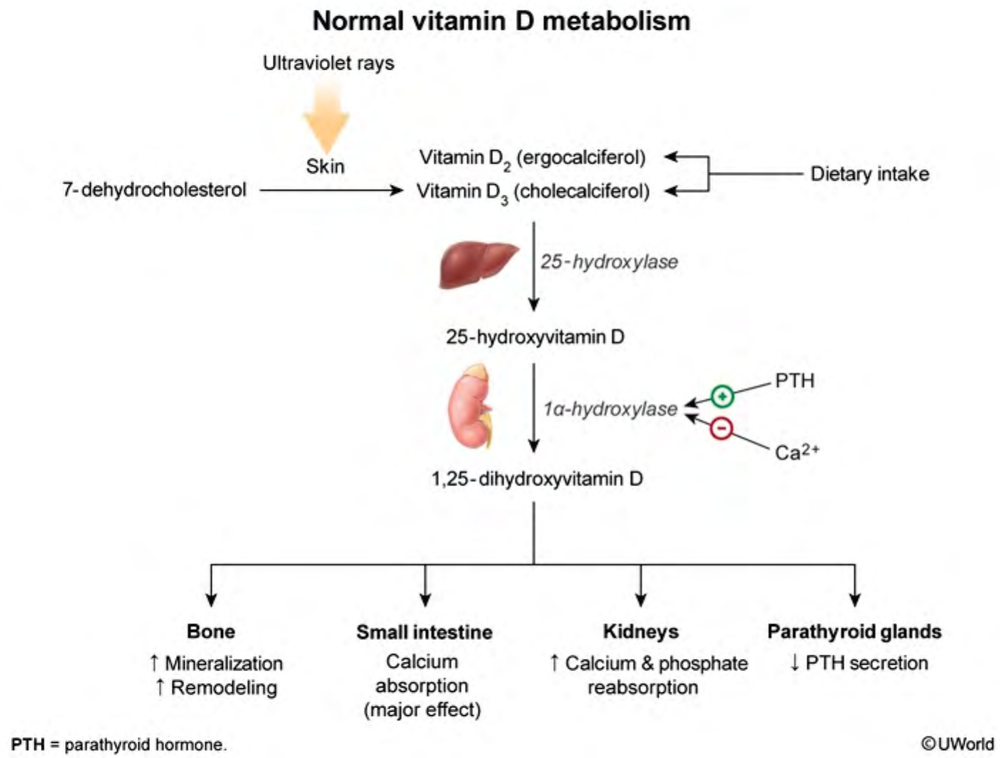

Zoom In | Zoom Out | Reset | New | Existing | My Notebook

Pathology
Subject
Pulmonary & Critical Care
System
Sarcoidosis
Topic

https://t.me/USMLEWorldStep1

A 34-year-old man travels to Peru to participate in a mountain-climbing expedition. He has no prior medical problems and takes no medications. The patient does not use tobacco, alcohol, or illicit drugs. During his trip, he stays in a high-altitude camp in the mountains at over 4,000 m (13,000 ft) above sea level. After 2 days at the camp, the patient has blood drawn by the camp's physician while breathing ambient air. Which of the following sets of arterial blood gas values is most likely to be seen in this patient?

	pH	PaO_2 (mm Hg)	$PaCO_2$ (mm Hg)	Plasma HCO_3^- (mEq/L)
○ A.	7.22	62	60	24
○ B.	7.25	101	21	9
○ C.	7.38	96	40	23
○ D.	7.46	100	26	18
○ E.	7.48	60	29	21
○ F.	7.51	75	50	39

Submit

https://t.me/USMLEWorldStep1

A 34-year-old man travels to Peru to participate in a mountain-climbing expedition. He has no prior medical problems and takes no medications. The patient does not use tobacco, alcohol, or illicit drugs. During his trip, he stays in a high-altitude camp in the mountains at over 4,000 m (13,000 ft) above sea level. After 2 days at the camp, the patient has blood drawn by the camp's physician while breathing ambient air. Which of the following sets of arterial blood gas values is most likely to be seen in this patient?

		pH	PaO_2 (mm Hg)	$PaCO_2$ (mm Hg)	Plasma HCO_3^- (mEq/L)	
	A.	7.22	62	60	24	(8%)
✗	B.	7.25	101	21	9	(2%)
	C.	7.38	96	40	23	(10%)
	D.	7.46	100	26	18	(19%)
✓	E.	7.48	60	29	21	(53%)
	F.	7.51	75	50	39	(6%)

Incorrect
Correct answer
E

53%
Answered correctly

03 secs
Time Spent

2023
Version

Explanation

Arterial blood gas interpretation of acid-base disorders

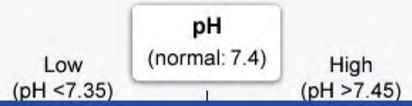

https://t.me/USMLEWorldStep1

A 34-year-old man travels to Peru to participate in a mountain-climbing expedition. He has no prior medical proble
stays i
camp,
sets o

Exhibit Display

Arterial blood gas interpretation of acid-base disorders

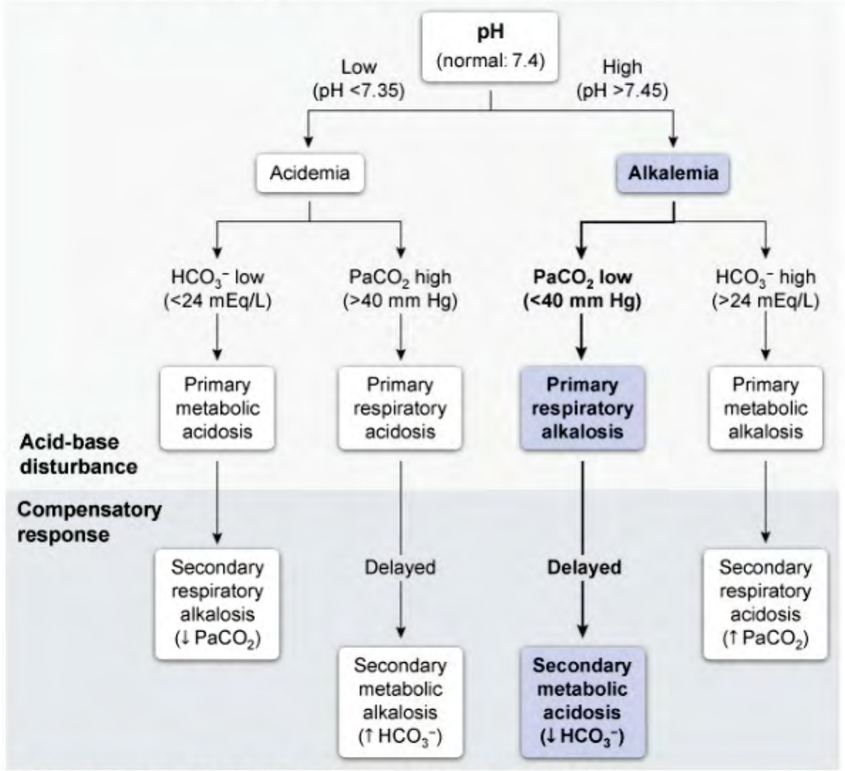

* The normal ranges for $PaCO_2$ and HCO_3^- vary slightly around 40 mm Hg and 24 mEq/L.
For simplicity, these numbers should be used as a normal baseline for acid-base calculations.

HCO_3^- = bicarbonate; **$PaCO_2$** = partial pressure of carbon dioxide in arterial blood.

©UWorld

Zoom In | Zoom Out | Reset | New | Existing | My Notebook

Low
(pH <7.35)
(normal: 7.4)
High
(pH >7.45)

https://t.me/USMLEWorldStep1

The partial pressure of inspired oxygen (PiO_2) is decreased at **high altitude**, meaning that fewer oxygen molecules are inspired with each breath. This leads to **hypoxemia** with a marked reduction in the arterial partial pressure of O_2 (PaO_2). Hypoxemia triggers chemoreceptors in the carotid bodies to stimulate ventilation, and with hyperventilation, there is **increased exhalation of CO_2**, leading to respiratory alkalosis. Over several days, the kidneys compensate by increasing bicarbonate (HCO_3^-) excretion to **decrease serum HCO_3^-** and help normalize pH.

Hypoxemia persists because the low PiO_2 allows hyperventilation to increase PaO_2 only slightly. Accordingly, the body makes several adjustments that improve O_2 delivery and O_2-carrying capacity to optimize O_2 use in the setting of persistently low PaO_2. These adjustments include:

- Increased 2,3-bisphosphoglycerate to encourage O_2 unloading in the tissues
- Increased angiogenesis via increased production of vascular endothelial growth factor
- Increased hemoglobin via increased production of erythropoietin

Therefore, in this individual who spent 2 days at high altitude, the expected arterial blood gas findings reflect **partially compensated respiratory alkalosis** (slightly elevated pH, low partial pressure of arterial CO_2 [$PaCO_2$], somewhat low HCO_3^-) and **persistent hypoxemia** (PaO_2 <75 mm Hg).

(Choice A) Low pH with high $PaCO_2$ indicates respiratory acidosis. Near-normal HCO_3^- is consistent with acute respiratory acidosis because there has been little time for renal metabolic compensation. Acute respiratory acidosis with hypoxemia can occur due to hypoventilation (eg, from opioid overdose).

(Choice B) Low pH with low HCO_3^- indicates metabolic acidosis. The low $PaCO_2$ reflects respiratory compensation via hyperventilation.

(Choice C) These values are close to approximate normal values: pH of 7.4, $PaCO_2$ of 40 mm Hg, and HCO_3^- of 24 mEq/L. This reflects an absence of acid-base disturbance.

(Choice D) Slightly elevated pH with low $PaCO_2$ and low HCO_3^- is consistent with chronic respiratory alkalosis with appropriate metabolic compensation. These acid-base findings are expected after >72 hours at high altitude (adequate time for full renal compensation); however, PaO_2 does not normalize.

https://t.me/USMLEWorldStep1

body makes several adjustments that improve O_2 delivery and O_2-carrying capacity to optimize O_2 use in the setting of persistently low PaO_2. These adjustments include:

- Increased 2,3-bisphosphoglycerate to encourage O_2 unloading in the tissues
- Increased angiogenesis via increased production of vascular endothelial growth factor
- Increased hemoglobin via increased production of erythropoietin

Therefore, in this individual who spent 2 days at high altitude, the expected arterial blood gas findings reflect **partially compensated respiratory alkalosis** (slightly elevated pH, low partial pressure of arterial CO_2 [$PaCO_2$], somewhat low HCO_3^-) and **persistent hypoxemia** (PaO_2 <75 mm Hg).

(Choice A) Low pH with high $PaCO_2$ indicates respiratory acidosis. Near-normal HCO_3^- is consistent with acute respiratory acidosis because there has been little time for renal metabolic compensation. Acute respiratory acidosis with hypoxemia can occur due to hypoventilation (eg, from opioid overdose).

(Choice B) Low pH with low HCO_3^- indicates metabolic acidosis. The low $PaCO_2$ reflects respiratory compensation via hyperventilation.

(Choice C) These values are close to approximate normal values: pH of 7.4, $PaCO_2$ of 40 mm Hg, and HCO_3^- of 24 mEq/L. This reflects an absence of acid-base disturbance.

(Choice D) Slightly elevated pH with low $PaCO_2$ and low HCO_3^- is consistent with chronic respiratory alkalosis with appropriate metabolic compensation. These acid-base findings are expected after >72 hours at high altitude (adequate time for full renal compensation); however, PaO_2 does not normalize.

(Choice F) High pH with high HCO_3^- indicates metabolic alkalosis. The elevated $PaCO_2$ represents respiratory compensation via hypoventilation. Such findings can occur with excessive vomiting or overuse of diuretics.

Educational objective:
At high altitude, the low partial pressure of inspired oxygen (PiO_2) leads to hypoxemia that triggers hyperventilation with increased exhalation of CO_2 and resulting respiratory alkalosis. The kidneys compensate by increasing bicarbonate (HCO_3^-) excretion to decrease serum HCO_3^- and help normalize pH. Hypoxemia persists, but physiologic adjustments take place to improve O_2 use.

https://t.me/USMLEWorldStep1

are inspired with each breath. This leads to **hypoxemia** with a marked reduction in the arterial partial pressure of O_2 (PaO_2). Hypoxemia triggers chemoreceptors in the carotid bodies to stimulate ventilation, and with hyperv
kidney
pH.

Hypox
body r
of pers

- In
- In
- In

Theref
partia
somev

(Choic
respira
acidos

(Choic
compe

(Choic
24 mE

(Choic
approp
(adequ

Exhibit Display

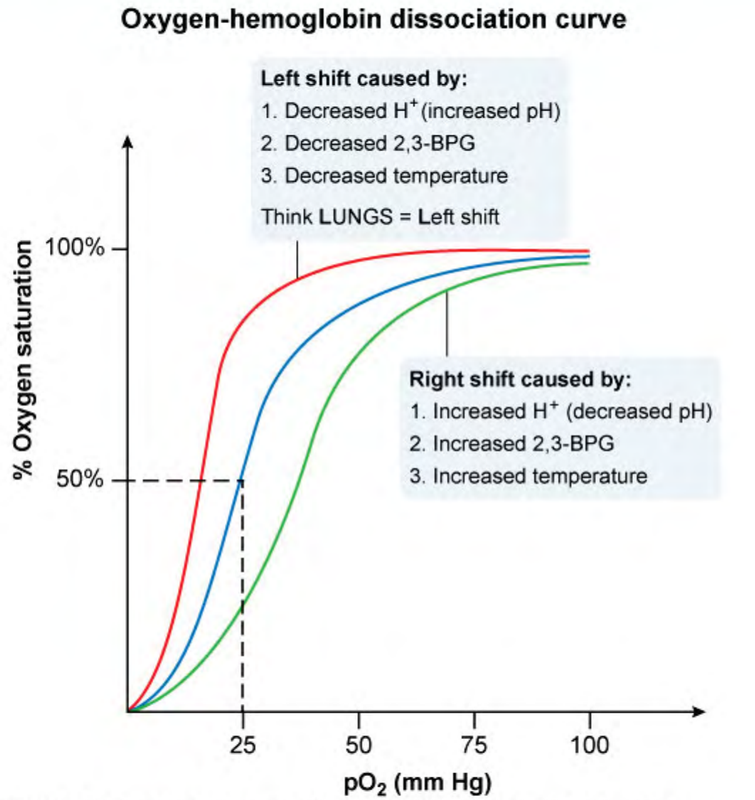

2,3-BPG = 2,3-bisphosphoglycerate; **pO_2** = partial pressure of oxygen in the blood.

©UWorld

Zoom In | Zoom Out | Reset | New | Existing | My Notebook

(Choice F) High pH with high HCO_3^- indicates metabolic alkalosis. The elevated $PaCO_2$ represents respiratory

https://t.me/USMLEWorldStep1

are inspired with each breath. This leads to **hypoxemia** with a marked reduction in the arterial partial pressure of O_2 (PaO_2). Hypoxemia triggers chemoreceptors in the carotid bodies to stimulate ventilation, and with hyperv
kidney
pH.

Hypox
body r
of pers

- In
- In
- In

Theref
partia
somev

(Choi
respira
acidos

(Choi
compe

(Choi
24 mE

(Choi
appropriate metabolic compensation. These acid-base findings are expected after >72 hours at high altitude (adequate time for full renal compensation); however, PaO_2 does not normalize.

(Choice F) High pH with high HCO_3^- indicates metabolic alkalosis. The elevated $PaCO_2$ represents respiratory

Exhibit Display

Appropriate compensatory $PaCO_2$ or HCO_3^- changes in acid-base disorders	
Metabolic acidosis (acute or chronic)	Expected $PaCO_2 = (1.5 \times HCO_3^-) + 8 \pm 2$ (Winters formula)
Metabolic alkalosis (acute or chronic)	~7 mm Hg ↑ in $PaCO_2$ per 10 mEq/L ↑ in HCO_3^-
Respiratory acidosis (chronic only*)	~4 mEq/L ↑ in HCO_3^- per 10 mm Hg ↑ in $PaCO_2$
Respiratory alkalosis (chronic only*)	~4 mEq/L ↓ in HCO_3^- per 10 mm Hg ↓ in $PaCO_2$
*Compensation for respiratory disturbances is minimal in the acute setting. The full level of chronic compensation is achieved after ~72 hr. For simplicity, normal baseline $PaCO_2$ & HCO_3^- should be considered 40 mm Hg & 24 mEq/L, respectively.	

New | Existing | My Notebook

https://t.me/USMLEWorldStep1

A 52-year-old man is brought to the emergency department after being found unresponsive on the street. The patient's medical history is unknown. Temperature is 36.2 C (97.2 F), blood pressure is 108/62 mm Hg, and pulse is 72/min. On physical examination, he is unresponsive to verbal and tactile stimuli but moans to deep sternal rub. An arterial blood gas analysis on room air shows a partial pressure of oxygen of 60 mm Hg. The partial pressure of oxygen in his alveoli is calculated to be 68 mm Hg. Which of the following is the most likely cause of this patient's symptoms?

- A. Alveolar hypoventilation
- B. Dead space ventilation
- C. Diffusion impairment
- D. Intrapulmonary shunt
- E. Left-to-right shunt

Submit

https://t.me/USMLEWorldStep1

A 52-year-old man is brought to the emergency department after being found unresponsive on the street. The patient's medical history is unknown. Temperature is 36.2 C (97.2 F), blood pressure is 108/62 mm Hg, and pulse is 72/min. On physical examination, he is unresponsive to verbal and tactile stimuli but moans to deep sternal rub. An arterial blood gas analysis on room air shows a partial pressure of oxygen of 60 mm Hg. The partial pressure of oxygen in his alveoli is calculated to be 68 mm Hg. Which of the following is the most likely cause of this patient's symptoms?

- ✓ A. Alveolar hypoventilation (58%)
- ✗ B. Dead space ventilation (9%)
- C. Diffusion impairment (20%)
- D. Intrapulmonary shunt (8%)
- E. Left-to-right shunt (2%)

Incorrect
Correct answer
A

58%
Answered correctly

03 secs
Time Spent

2023
Version

Explanation

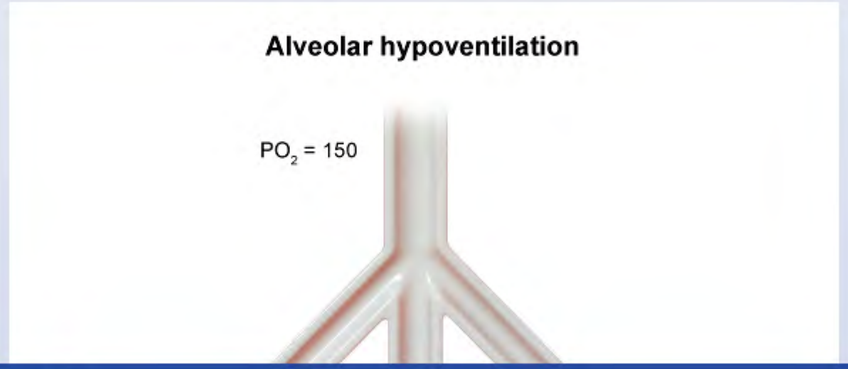

https://t.me/USMLEWorldStep1

A 52-year-old man is brought to the emergency department after being found unresponsive on the street. The patient
is 72/
An art
of oxy
patien

Exhibit Display

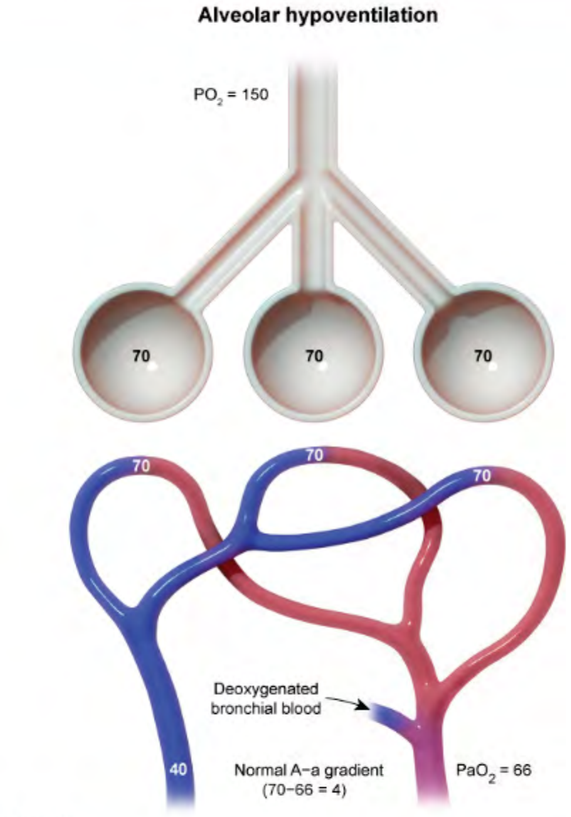

Zoom In | Zoom Out | Reset | New | Existing | My Notebook

https://t.me/USMLEWorldStep1

The partial pressure of oxygen in the alveoli (PAO_2) is normally 104 mm Hg, and due to the high rate of O_2 diffusion across the alveolar-capillary membrane, the O_2 level in the alveolar capillary blood rapidly equilibrates with the PAO_2. However, the blood O_2 level then drops slightly due to the addition of deoxygenated blood from the bronchial circulation; therefore, the partial pressure of oxygen in arterial blood (PaO_2) is normally around 100 mm Hg. This discrepancy between alveolar and arterial O_2 concentration is termed the alveolar-arterial (A-a) gradient. In healthy individuals, a **normal A-a gradient** is typically between **4 and 15 mm Hg**, with older individuals having higher normal values due to an age-related decline in O_2-diffusing capacity.

This patient has low PaO_2 and PAO_2 with a normal A-a gradient (68 − 60 = 8), indicating that his low PaO_2 is directly due to low PAO_2. Possible causes of hypoxemia in the setting of a normal A-a gradient include **alveolar hypoventilation** and low partial pressure of inspired oxygen (PiO_2) (ie, high altitude). Common causes of alveolar hypoventilation include suppressed central respiratory drive (eg, sedative overdose) and diseases that decrease inspiratory capacity (eg, myasthenia gravis, obesity).

(Choices B and D) Dead space ventilation is one extreme of ventilation-perfusion mismatch that occurs when the alveoli are adequately ventilated, but there is no alveolar perfusion (eg, pulmonary embolism). An intrapulmonary shunt is the other extreme of ventilation-perfusion mismatch that occurs when blood perfuses alveoli that are not ventilated (eg, pneumonia, pulmonary edema). The A-a gradient is elevated in ventilation-perfusion mismatch.

(Choice C) Gas diffusion is impaired in diseases that disrupt the alveolar-capillary membrane, such as alveolar hyaline membrane disease (acutely) or emphysema (chronically). Diffusion impairment causes an elevated A-a gradient because O_2 cannot be effectively transported into the blood.

(Choice E) A left-to-right shunt occurs when oxygenated blood from the left side of the heart is shunted into the right side of the heart (eg, atrial or ventricular septal defect). Left-to-right shunts do not cause hypoxemia; however, if left untreated, they may progress into a right-to-left shunt (ie, Eisenmenger syndrome) with hypoxemia, cyanosis, and an elevated A-a gradient.

Educational objective:
There are 5 major causes of hypoxemia (low arterial partial pressure of oxygen [PaO_2]): alveolar hypoventilation, low partial pressure of inspired oxygen, ventilation-perfusion mismatch, diffusion impairment, and right-to-left

https://t.me/USMLEWorldStep1

bronchial circulation; therefore, the partial pressure of oxygen in arterial blood (PaO_2) is normally around 100 mm Hg. This discrepancy between alveolar and arterial O_2 concentration is termed the alveolar-arterial (A-a) gradient. In healthy individuals, a **normal A-a gradient** is typically between **4 and 15 mm Hg**, with older individuals having higher normal values due to an age-related decline in O_2-diffusing capacity.

This patient has low PaO_2 and PAO_2 with a normal A-a gradient (68 − 60 = 8), indicating that his low PaO_2 is directly due to low PAO_2. Possible causes of hypoxemia in the setting of a normal A-a gradient include **alveolar hypoventilation** and low partial pressure of inspired oxygen (PiO_2) (ie, high altitude). Common causes of alveolar hypoventilation include suppressed central respiratory drive (eg, sedative overdose) and diseases that decrease inspiratory capacity (eg, myasthenia gravis, obesity).

(Choices B and D) Dead space ventilation is one extreme of ventilation-perfusion mismatch that occurs when the alveoli are adequately ventilated, but there is no alveolar perfusion (eg, pulmonary embolism). An intrapulmonary shunt is the other extreme of ventilation-perfusion mismatch that occurs when blood perfuses alveoli that are not ventilated (eg, pneumonia, pulmonary edema). The A-a gradient is elevated in ventilation-perfusion mismatch.

(Choice C) Gas diffusion is impaired in diseases that disrupt the alveolar-capillary membrane, such as alveolar hyaline membrane disease (acutely) or emphysema (chronically). Diffusion impairment causes an elevated A-a gradient because O_2 cannot be effectively transported into the blood.

(Choice E) A left-to-right shunt occurs when oxygenated blood from the left side of the heart is shunted into the right side of the heart (eg, atrial or ventricular septal defect). Left-to-right shunts do not cause hypoxemia; however, if left untreated, they may progress into a right-to-left shunt (ie, Eisenmenger syndrome) with hypoxemia, cyanosis, and an elevated A-a gradient.

Educational objective:
There are 5 major causes of hypoxemia (low arterial partial pressure of oxygen [PaO_2]): alveolar hypoventilation, low partial pressure of inspired oxygen, ventilation-perfusion mismatch, diffusion impairment, and right-to-left shunting. The A-a gradient is normal with alveolar hypoventilation and low partial pressure of inspired oxygen, which helps distinguish these causes from other causes of hypoxemia.

Physiology Pulmonary & Critical Care Acute respiratory failure

https://t.me/USMLEWorldStep1

40 Normal A–a gradient PaO_2 = 66

Exhibit Display

Normal bronchopulmonary shunting

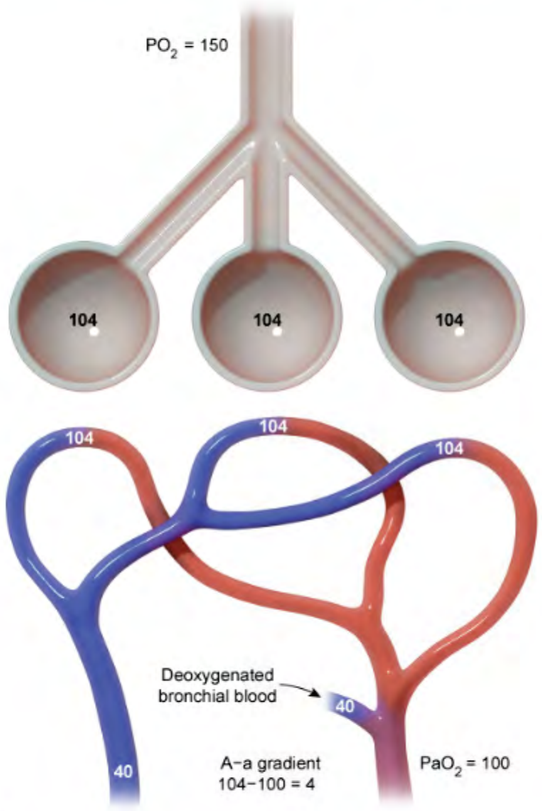

Zoom In | Zoom Out | Reset | New | Existing | My Notebook

The pa
across
PAO_2.
bronch
Hg. T
In hea
higher

This p
directl
hypov
hypov
inspira

(Choi
alveoli
shunt
ventila

(Choi
hyalin
gradie

(Choi
right s
howev
cyanosis, and an elevated A-a gradient.

https://t.me/USMLEWorldStep1

40 Normal A–a gradient PaO_2 = 66

Exhibit Display

Causes of hypoxemia

	Examples	A-a gradient
Reduced PiO_2	High altitude	Normal
Hypoventilation	CNS depression, morbid obesity	Normal
Diffusion limitation	Emphysema, ILD	Increased
V/Q mismatch*	Pulmonary embolism, pneumonia	Increased

*Caused by regional dead-space ventilation and/or intrapulmonary shunting.
A-a gradient = alveolar to arterial oxygen gradient; **ILD** = interstitial lung disease; **PiO_2** = partial pressure of inspired oxygen; **V/Q** = ventilation/perfusion ratio.

New | Existing | My Notebook

The pa
across
PAO_2.
bronch
Hg. T
In hea
higher

This p
directly
hypov
hypov
inspira

(Choi
alveoli
shunt
ventila

(Choi
hyalin
gradie

(Choi
right s
howev

cyanosis, and an elevated A-a gradient.

https://t.me/USMLEWorldStep1

40 Normal A–a gradient PaO_2 = 66

Exhibit Display

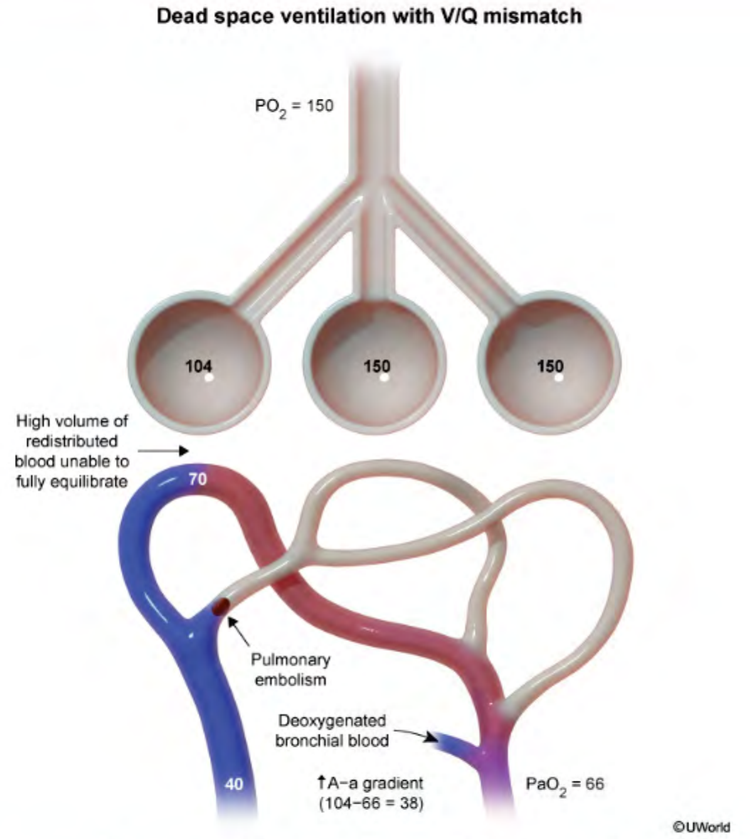

Zoom In Zoom Out Reset New | Existing My Notebook

The pa
across
PAO_2.
bronch
Hg. T
In hea
higher

This p
directl
hypov
hypov
inspira

(Choi
alveoli
shunt
ventila

(Choi
hyalin
gradie

(Choi
right side of the heart (eg, atrial or ventricular septal defect). Left-to-right shunts do not cause hypoxemia; however, if left untreated, they may progress into a right-to-left shunt (ie, Eisenmenger syndrome) with hypoxemia, cyanosis, and an elevated A-a gradient.

https://t.me/USMLEWorldStep1

40 Normal A–a gradient PaO_2 = 66

Exhibit Display

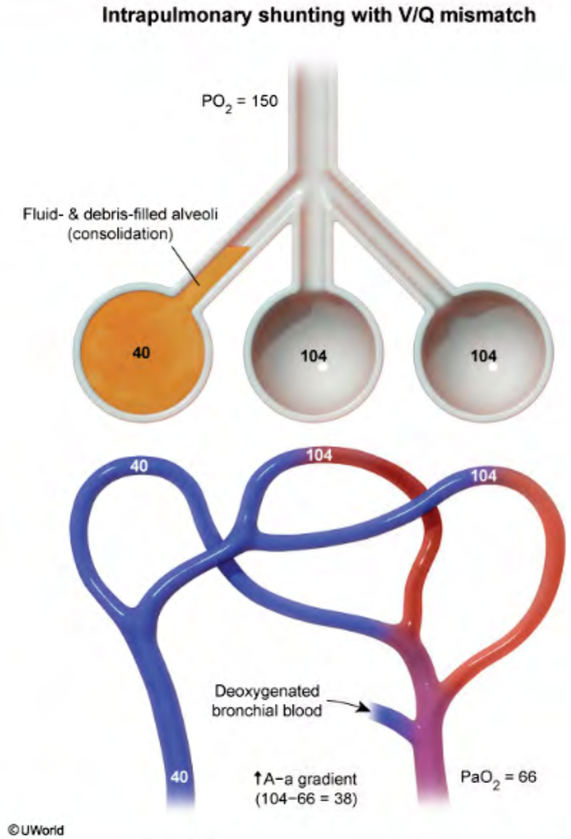

Zoom In Zoom Out Reset New | Existing My Notebook

The pa
across
PAO_2.
bronch
Hg. T
In hea
higher

This p
directl
hypov
hypov
inspira

(Choi
alveoli
shunt
ventila

(Choi
hyalin
gradie

(Choi
right side of the heart (eg, atrial or ventricular septal defect). Left-to-right shunts do not cause hypoxemia; however, if left untreated, they may progress into a right-to-left shunt (ie, Eisenmenger syndrome) with hypoxemia, cyanosis, and an elevated A-a gradient.

https://t.me/USMLEWorldStep1

40 Normal A–a gradient PaO_2 = 66

Exhibit Display

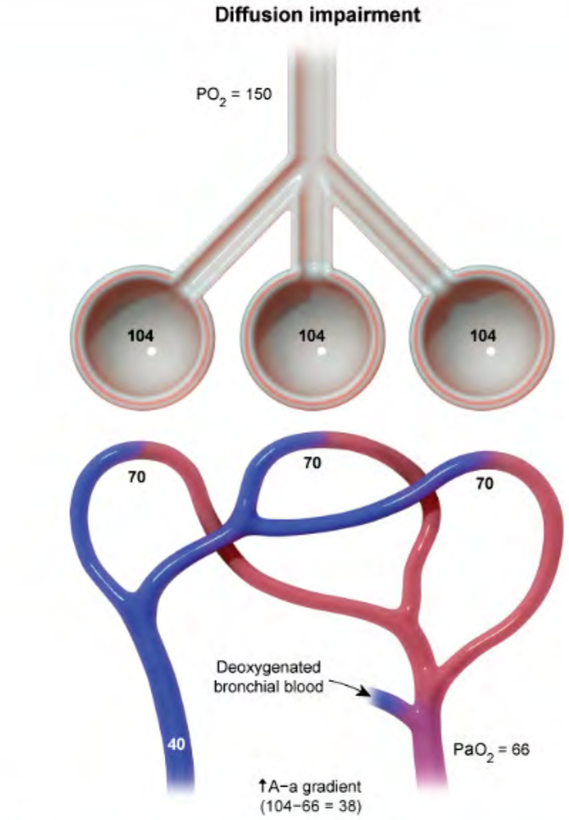

Zoom In Zoom Out Reset New | Existing My Notebook

The pa
across
PAO_2.
bronch
Hg. T
In hea
higher

This p
directl
hypov
hypov
inspira

(Choi
alveoli
shunt
ventila

(Choi
hyalin
gradie

(Choi
right side of the heart (eg, atrial or ventricular septal defect). Left-to-right shunts do not cause hypoxemia; however, if left untreated, they may progress into a right-to-left shunt (ie, Eisenmenger syndrome) with hypoxemia, cyanosis, and an elevated A-a gradient.

https://t.me/USMLEWorldStep1

A 24-year-old previously healthy man is brought to the emergency department after a motor vehicle collision in which he sustained trauma to the left side of the chest and the abdomen. On arrival, the patient is hypotensive and tachycardic. Evaluation reveals left-sided rib fractures and hemoperitoneum due to splenic laceration. Urgent exploratory laparotomy under general anesthesia is planned. In the operating room, etomidate is administered for rapid sequence induction. Which of the following characteristics best describes etomidate as compared to propofol?

- A. Analgesic effect in addition to sedation
- B. Higher risk of lipid abnormalities
- C. Lower risk of adrenocortical suppression
- D. No cardiovascular depressant effect
- E. Possible use for maintenance anesthesia

Submit

https://t.me/USMLEWorldStep1

A 24-year-old previously healthy man is brought to the emergency department after a motor vehicle collision in which he sustained trauma to the left side of the chest and the abdomen. On arrival, the patient is hypotensive and tachycardic. Evaluation reveals left-sided rib fractures and hemoperitoneum due to splenic laceration. Urgent exploratory laparotomy under general anesthesia is planned. In the operating room, etomidate is administered for rapid sequence induction. Which of the following characteristics best describes etomidate as compared to propofol?

- A. Analgesic effect in addition to sedation (10%)
- ✗ B. Higher risk of lipid abnormalities (3%)
- C. Lower risk of adrenocortical suppression (5%)
- ✓ D. No cardiovascular depressant effect (68%)
- E. Possible use for maintenance anesthesia (12%)

Incorrect
Correct answer
D

68%
Answered correctly

06 secs
Time Spent

2023
Version

Explanation

This patient is hemodynamically unstable (ie, hypotensive, tachycardic). Prior to operative intervention, anesthesia must be induced. Three medications are commonly used because of their rapid onset of action and short duration of effect:

- **Propofol:** A highly lipophilic GABA agonist that has the advantage of reducing airway resistance. Disadvantages include **vasodilation**, which can result in hypotension and an increase in serum triglycerides and lipase **(Choice B)**.
- **Etomidate:** A GABA agonist that has the advantage of being the most **hemodynamically neutral**. It does not cause changes in heart rate, blood pressure, or cardiac output. However, it inhibits cortisol synthesis

https://t.me/USMLEWorldStep1

This patient is hemodynamically unstable (ie, hypotensive, tachycardic). Prior to operative intervention, anesthesia must be induced. Three medications are commonly used because of their rapid onset of action and short duration of effect:

- **Propofol:** A highly lipophilic GABA agonist that has the advantage of reducing airway resistance. Disadvantages include **vasodilation**, which can result in hypotension and an increase in serum triglycerides and lipase **(Choice B)**.
- **Etomidate:** A GABA agonist that has the advantage of being the most **hemodynamically neutral**. It does not cause changes in heart rate, blood pressure, or cardiac output. However, it inhibits cortisol synthesis, which can lead to **adrenocortical suppression** that is typically reversible. Because of this, etomidate is often avoided in patients with septic shock, and it should not be used as maintenance of sedation after induction **(Choices C and E)**.
- **Ketamine:** An N-methyl-d-aspartate antagonist that is similar to PCP, it preserves the respiratory drive during induction of anesthesia. Ketamine also provides an **analgesic effect**. It stimulates the release of catecholamines, which can cause **bronchodilation** but also increase heart rate, myocardial contractility, and cerebral blood flow.

In **hypotensive patients**, anesthesia is often induced with either a hemodynamically neutral agent (**etomidate**) or one that may improve hemodynamics due to catecholamine release (**ketamine**).

(Choice A) In contrast to ketamine, neither propofol nor etomidate provide an analgesic effect.

Educational objective:
Etomidate, a GABA agonist, is often used for anesthesia induction to provide sedation and amnesia. It is hemodynamically neutral, but it can result in transient adrenocortical suppression because it inhibits cortisol synthesis.

Pharmacology	Pulmonary & Critical Care	Anesthesia
Subject	System	Topic

https://t.me/USMLEWorldStep1

A 64-year-old woman is hospitalized after injuring her right hip when she slipped on ice while carrying groceries. X-ray reveals a right femoral neck fracture, and the patient undergoes a total hip arthroplasty with no operative complications. Two days after surgery, the patient develops acute hemodynamic decompensation. A contrast-enhanced CT scan of the chest is immediately obtained; a sagittal view is shown below.

In-hospital administration of which of the following is most appropriate for reducing the risk of patients developing this complication?

- A. Beta-adrenergic antagonist
- B. Fresh-frozen plasma
- C. Intravenous hydration
- D. Low-molecular-weight heparin
- E. Perioperative antibiotics
- F. Tissue plasminogen activator

Submit

https://t.me/USMLEWorldStep1

A 64-year-old woman is hospitalized after injuring her right hip when she slipped on ice while carrying groceries.

X-ray

compli

enhan

Exhibit Display

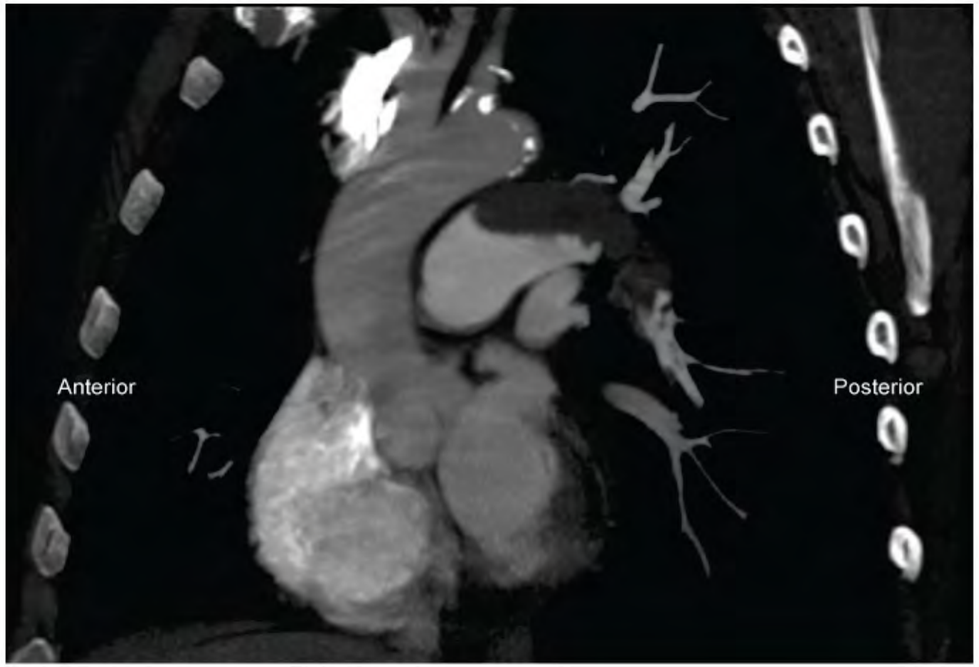

Zoom In | Zoom Out | Reset | New | Existing | My Notebook

In-hos

this co

D. Low-molecular-weight heparin

https://t.me/USMLEWorldStep1

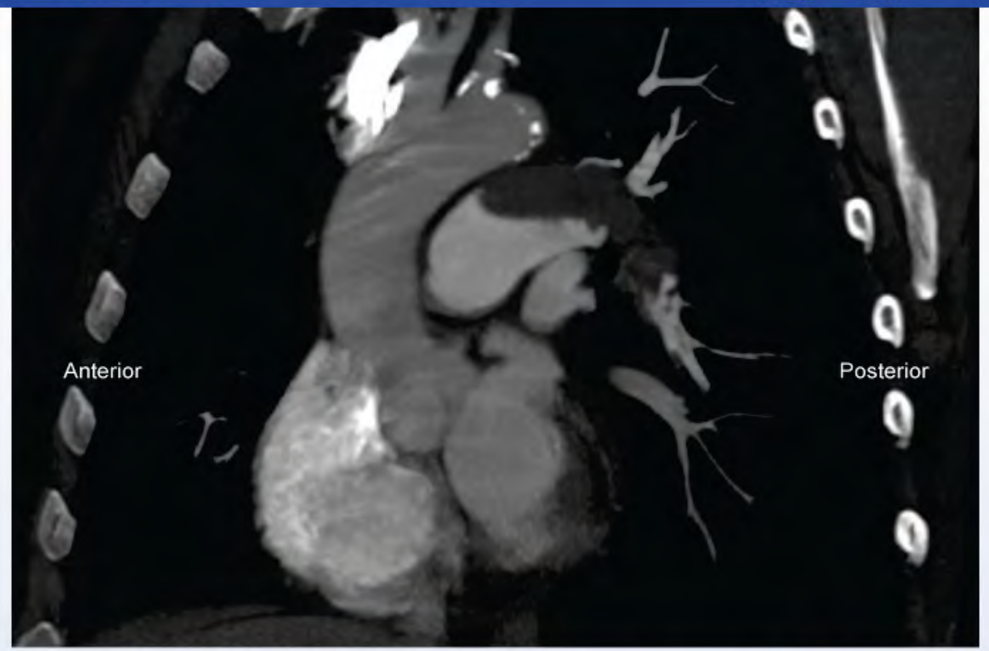

In-hospital administration of which of the following is most appropriate for reducing the risk of patients developing this complication?

- A. Beta-adrenergic antagonist
- B. Fresh-frozen plasma
- C. Intravenous hydration
- D. Low-molecular-weight heparin
- E. Perioperative antibiotics
- F. Tissue plasminogen activator

Submit

https://t.me/USMLEWorldStep1

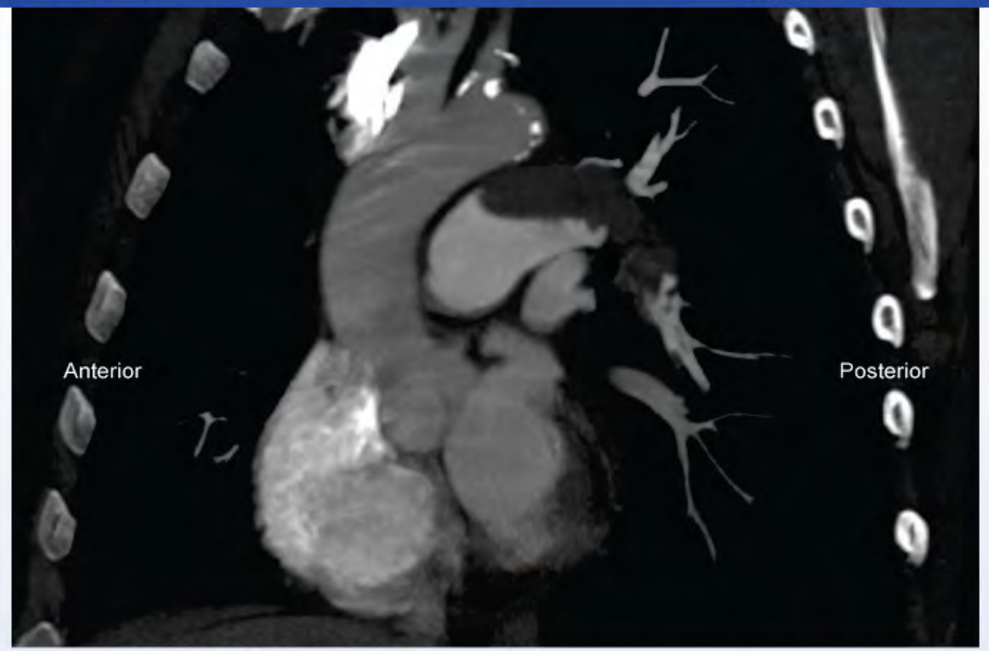

In-hospital administration of which of the following is most appropriate for reducing the risk of patients developing this complication?

- A. Beta-adrenergic antagonist (1%)
- B. Fresh-frozen plasma (1%)
- C. Intravenous hydration (1%)
- ✓ D. Low-molecular-weight heparin (84%)
- E. Perioperative antibiotics (1%)
- F. Tissue plasminogen activator (8%)

Correct

84% Answered correctly

14 secs Time Spent

2023 Version

https://t.me/USMLEWorldStep1

Explanation

Pulmonary embolism

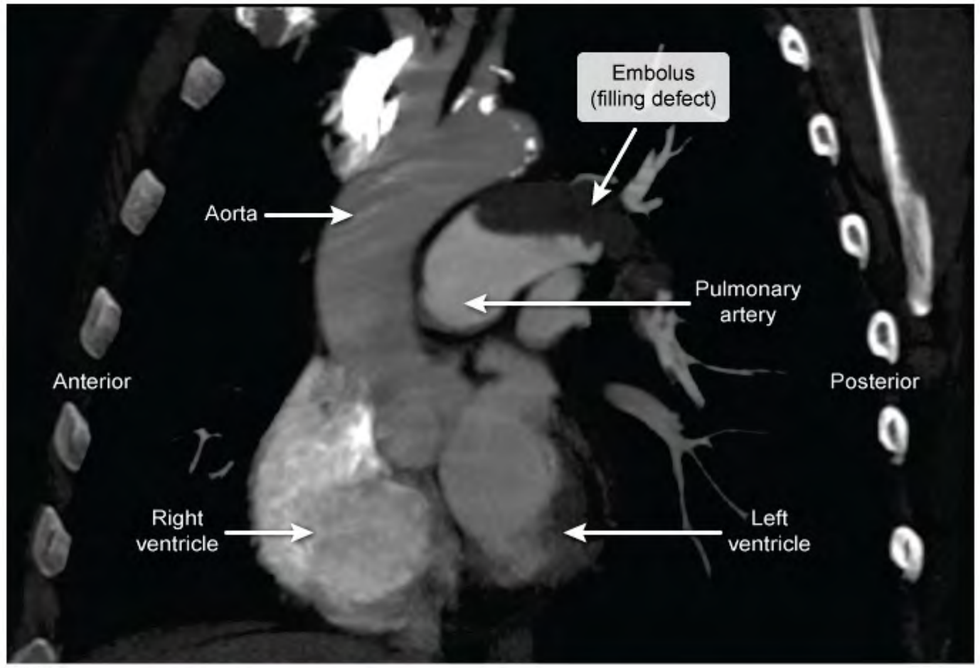

©UWorld

This contrast-enhanced CT image reveals a large filling defect within the lumen of the pulmonary artery, which is consistent with **pulmonary embolism** (PE). The thromboembolus usually originates in the deep veins of the lower extremities and travels through the inferior vena cava and right side of the heart to reach the pulmonary circulation. Large emboli lodge in the pulmonary artery bifurcation ("saddle emboli") and may cause severe hypotension or sudden cardiac death, whereas smaller emboli occlude peripheral pulmonary arterial branches. In most cases, pulmonary emboli are multiple, with the lower lobes involved more often than the upper lobes.

Many hospitalized patients are at increased risk for venous thromboembolism (VTE) (ie, PE or deep vein thrombosis) due to trauma, prolonged immobilization, or underlying conditions that contribute to a hypercoagulable

https://t.me/USMLEWorldStep1

Exhibit Display

Pulmonary embolism

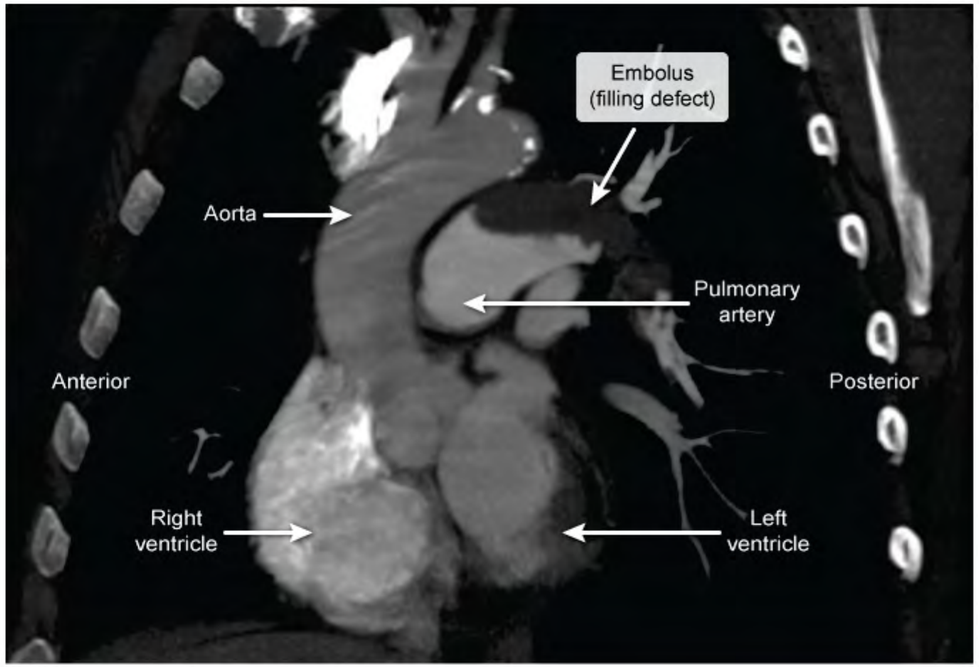

©UWorld

Zoom In | Zoom Out | Reset | New | Existing | My Notebook

This c
consis
extrem
circula
hypote
most c

Many
thromb
state (
are at
elimina
(eg, e

In pati
VTE (a
the ris

(Choi
or aort

(Choi
patien
underl

(Choi

(Choi

(Choice F) Tissue plasminogen activator is indicated in the treatment of massive PE complicated by

https://t.me/USMLEWorldStep1

This contrast-enhanced CT image reveals a large filling defect within the lumen of the pulmonary artery, which is consistent with **pulmonary embolism** (PE). The thromboembolus usually originates in the deep veins of the lower extremities and travels through the inferior vena cava and right side of the heart to reach the pulmonary circulation. Large emboli lodge in the pulmonary artery bifurcation ("saddle emboli") and may cause severe hypotension or sudden cardiac death, whereas smaller emboli occlude peripheral pulmonary arterial branches. In most cases, pulmonary emboli are multiple, with the lower lobes involved more often than the upper lobes.

Many hospitalized patients are at increased risk for venous thromboembolism (VTE) (ie, PE or deep vein thrombosis) due to trauma, prolonged immobilization, or underlying conditions that contribute to a hypercoagulable state (eg, cancer, infection, pregnancy). Patients undergoing large **orthopedic surgeries** (eg, hip replacement) are at particularly **high risk of VTE**. Although the risk of VTE in hospitalized patients cannot be completely eliminated, administration of prophylactic **anticoagulation greatly reduces risk**. Low-molecular-weight heparin (eg, enoxaparin) is preferred in most patients due to proven efficacy and relatively low risk of adverse effects.

In patients at high risk of VTE, the slightly increased risk of bleeding is strongly outweighed by the reduced risk of VTE (and its associated mortality) provided by prophylactic anticoagulation. Early ambulation also helps reduce the risk of VTE.

(Choice A) Beta-adrenergic antagonists (eg, metoprolol) may lower the risk of perioperative myocardial infarction or aortic dissection, but they do not reduce the risk of VTE.

(Choice B) Fresh frozen plasma is used to reverse the effects of warfarin or to provide coagulation factors to patients experiencing massive hemorrhage. It does not reduce the risk of VTE and may even exacerbate an underlying hypercoagulable state.

(Choice C) Intravenous hydration can help prevent perioperative dehydration and prerenal acute kidney injury.

(Choice E) Perioperative antibiotics (eg, cefazolin) may help prevent surgical wound infections.

(Choice F) Tissue plasminogen activator is indicated in the treatment of massive PE complicated by hemodynamic instability. However, it is not appropriate for VTE prophylaxis due to the relatively high risk of serious bleeding complications (eg, intracranial hemorrhage).

Educational objective:

https://t.me/USMLEWorldStep1

circulation. Large emboli lodge in the pulmonary artery bifurcation ("saddle emboli") and may cause severe hypotension or sudden cardiac death, whereas smaller emboli occlude peripheral pulmonary arterial branches. In most cases, pulmonary emboli are multiple, with the lower lobes involved more often than the upper lobes.

Many hospitalized patients are at increased risk for venous thromboembolism (VTE) (ie, PE or deep vein thrombosis) due to trauma, prolonged immobilization, or underlying conditions that contribute to a hypercoagulable state (eg, cancer, infection, pregnancy). Patients undergoing large **orthopedic surgeries** (eg, hip replacement) are at particularly **high risk of VTE**. Although the risk of VTE in hospitalized patients cannot be completely eliminated, administration of prophylactic **anticoagulation greatly reduces risk**. Low-molecular-weight heparin (eg, enoxaparin) is preferred in most patients due to proven efficacy and relatively low risk of adverse effects.

In patients at high risk of VTE, the slightly increased risk of bleeding is strongly outweighed by the reduced risk of VTE (and its associated mortality) provided by prophylactic anticoagulation. Early ambulation also helps reduce the risk of VTE.

(Choice A) Beta-adrenergic antagonists (eg, metoprolol) may lower the risk of perioperative myocardial infarction or aortic dissection, but they do not reduce the risk of VTE.

(Choice B) Fresh frozen plasma is used to reverse the effects of warfarin or to provide coagulation factors to patients experiencing massive hemorrhage. It does not reduce the risk of VTE and may even exacerbate an underlying hypercoagulable state.

(Choice C) Intravenous hydration can help prevent perioperative dehydration and prerenal acute kidney injury.

(Choice E) Perioperative antibiotics (eg, cefazolin) may help prevent surgical wound infections.

(Choice F) Tissue plasminogen activator is indicated in the treatment of massive PE complicated by hemodynamic instability. However, it is not appropriate for VTE prophylaxis due to the relatively high risk of serious bleeding complications (eg, intracranial hemorrhage).

Educational objective:
The risk of venous thromboembolism (ie, pulmonary embolism or deep vein thrombosis) in hospitalized patients can be greatly reduced with the administration of prophylactic anticoagulation, usually with low-molecular-weight heparin.

https://t.me/USMLEWorldStep1

A 53-year-old man comes to the emergency department due to progressive shortness of breath and nonproductive cough. Medical history is significant for long-standing hypertension and type 2 diabetes mellitus, for which he takes lisinopril and metformin. The patient has no drug allergies. Blood pressure is 160/100 mm Hg, pulse is 110/min, and respirations are 20/min. On physical examination, heart sounds are regular. Lung examination reveals decreased tactile fremitus over the lower right lung along with dullness to percussion. Which of the following is the most likely diagnosis?

- A. Bronchospasm
- B. Emphysema
- C. Lobar consolidation
- D. Pericardial effusion
- E. Pleural effusion
- F. Pneumothorax
- G. Pulmonary edema

Submit

https://t.me/USMLEWorldStep1

A 53-year-old man comes to the emergency department due to progressive shortness of breath and nonproductive cough. Medical history is significant for long-standing hypertension and type 2 diabetes mellitus, for which he takes lisinopril and metformin. The patient has no drug allergies. Blood pressure is 160/100 mm Hg, pulse is 110/min, and respirations are 20/min. On physical examination, heart sounds are regular. Lung examination reveals decreased tactile fremitus over the lower right lung along with dullness to percussion. Which of the following is the most likely diagnosis?

- A. Bronchospasm (0%)
- B. Emphysema (1%)
- ✗ C. Lobar consolidation (30%)
- D. Pericardial effusion (0%)
- ✓ E. Pleural effusion (47%)
- F. Pneumothorax (2%)
- G. Pulmonary edema (17%)

Incorrect
Correct answer
E

47%
Answered correctly

04 secs
Time Spent

2023
Version

Explanation

Pulmonary auscultation examination findings			
Condition	**Breath sounds**	**Tactile fremitus**	**Percussion**
Normal lung	Normal	Normal	Resonance

https://t.me/USMLEWorldStep1

Pulmonary auscultation examination findings			
Condition	**Breath sounds**	**Tactile fremitus**	**Percussion**
Normal lung	Normal	Normal	Resonance
Consolidation	Increased	Increased	Dullness
Pleural effusion	Decreased or absent	Decreased	Dullness
Pneumothorax	Decreased or absent	Decreased	Hyperresonance
Atelectasis	Decreased or absent	Decreased	Dullness

This patient most likely has a right-sided **pleural effusion**. Excess fluid within the pleural space acts to insulate vibrations and breath sounds that originate in the airways of the lungs. Consequently, **tactile fremitus**, the transmission of vibration from vocalized sound (eg, saying "ninety-nine"), is **decreased** over a pleural effusion. **Breath sounds** are also **decreased** or absent. The high density of pleural fluid compared to normal lung (alveolus-air composite) causes **dullness to percussion** over the effusion.

(Choice A) Bronchospasm is likely to have minimal effect on tactile fremitus and dullness to percussion.

(Choice B) The hyperinflated alveoli in emphysema should demonstrate hyperresonance to percussion and decreased tactile fremitus.

(Choices C and G) Because sound vibrations travel faster and more efficiently through liquids than through gases, alveolar filling processes such as lobar consolidation (alveoli filled with pus) and pulmonary edema (alveoli filled with transudate) create increased breath sound intensity and increased tactile fremitus.

(Choice D) A large pericardial effusion might cause dullness to percussion with decreased tactile fremitus over the precordium, but not over the lower lung.

https://t.me/USMLEWorldStep1

Atelectasis	Decreased or absent	Decreased	Dullness

This patient most likely has a right-sided **pleural effusion**. Excess fluid within the pleural space acts to insulate vibrations and breath sounds that originate in the airways of the lungs. Consequently, **tactile fremitus**, the transmission of vibration from vocalized sound (eg, saying "ninety-nine"), is **decreased** over a pleural effusion. **Breath sounds** are also **decreased** or absent. The high density of pleural fluid compared to normal lung (alveolus-air composite) causes **dullness to percussion** over the effusion.

(Choice A) Bronchospasm is likely to have minimal effect on tactile fremitus and dullness to percussion.

(Choice B) The hyperinflated alveoli in emphysema should demonstrate hyperresonance to percussion and decreased tactile fremitus.

(Choices C and G) Because sound vibrations travel faster and more efficiently through liquids than through gases, alveolar filling processes such as lobar consolidation (alveoli filled with pus) and pulmonary edema (alveoli filled with transudate) create increased breath sound intensity and increased tactile fremitus.

(Choice D) A large pericardial effusion might cause dullness to percussion with decreased tactile fremitus over the precordium, but not over the lower lung.

(Choice F) Like pleural effusion, pneumothorax (air in the pleural space) acts to insulate sound originating in the airways; therefore, tactile fremitus and breath sounds are decreased. However, the low density of air compared to normal lung creates hyperresonance to percussion.

Educational objective:
Fluid in the pleural space acts to insulate sound vibrations that originate in the airways; therefore, pleural effusion causes decreased tactile fremitus and decreased intensity of breath sounds. The high density of pleural fluid compared to normal lung tissue also causes dullness to percussion.

Pathophysiology	Pulmonary & Critical Care	Pleural effusion
Subject	System	Topic

Copyright © UWorld. All rights reserved.

https://t.me/USMLEWorldStep1

Bacteria isolated from the lung tissue of a 32-year-old patient fail to decolorize with hydrochloric acid and alcohol after staining carbolfuchsin. Which of the following cell wall components is most likely responsible for this staining phenomenon?

- A. N-acetylmuramic acid
- B. Teichoic acid
- C. Lipopolysaccharide
- D. Mycolic acid
- E. Ergosterol

Submit

https://t.me/USMLEWorldStep1

Bacteria isolated from the lung tissue of a 32-year-old patient fail to decolorize with hydrochloric acid and alcohol after staining carbolfuchsin. Which of the following cell wall components is most likely responsible for this staining phenomenon?

- A. N-acetylmuramic acid (7%)
- ✗ B. Teichoic acid (14%)
- C. Lipopolysaccharide (12%)
- ✓ D. Mycolic acid (60%)
- E. Ergosterol (4%)

Incorrect
Correct answer
D

60%
Answered correctly

04 secs
Time Spent

2023
Version

Explanation

The procedure described above is the acid-fast stain, which is used in the detection of a select few pathogenic organisms (eg, *Mycobacterium* and some *Nocardia* species). Although it is less sensitive than culture, the acid-fast stained smear allows for immediate microscopic evaluation.

In the acid-fast stain for mycobacteria, the smear is first treated with an aniline dye (eg, carbolfuchsin). The dye (red color) penetrates the bacterial cell wall, where it binds with mycolic acids. The slide is then treated with hydrochloric acid and alcohol. This acid alcohol dissolves the outer cell membranes of nontuberculous bacteria, but the presence of mycolic acids prevents decolorization of mycobacteria. A counterstain (eg, methylene blue) is then applied and taken up by decolorized bacteria. As a result, the carbolfuchsin acid-fast stain produces red mycobacteria (initial stain) and blue non-acid fast bacteria.

The cell membrane and cell wall of mycobacteria are most similar to those in Gram-positive organisms, causing mycobacteria to appear weakly positive on Gram stain. However, the mycobacterial cell wall differs from that of the

https://t.me/USMLEWorldStep1

The procedure described above is the acid-fast stain, which is used in the detection of a select few pathogenic organisms (eg, *Mycobacterium* and some *Nocardia* species). Although it is less sensitive than culture, the acid-fast stained smear allows for immediate microscopic evaluation.

In the acid-fast stain for mycobacteria, the smear is first treated with an aniline dye (eg, carbolfuchsin). The dye (red color) penetrates the bacterial cell wall, where it binds with mycolic acids. The slide is then treated with hydrochloric acid and alcohol. This acid alcohol dissolves the outer cell membranes of nontuberculous bacteria, but the presence of mycolic acids prevents decolorization of mycobacteria. A counterstain (eg, methylene blue) is then applied and taken up by decolorized bacteria. As a result, the carbolfuchsin acid-fast stain produces red mycobacteria (initial stain) and blue non-acid fast bacteria.

The cell membrane and cell wall of mycobacteria are most similar to those in Gram-positive organisms, causing mycobacteria to appear weakly positive on Gram stain. However, the mycobacterial cell wall differs from that of the typical Gram-positive organism in that they are encapsulated with mycolic acid, a waxy, long-chain fatty acid that is covalently bound to the sugars within the cell wall. Another organism that will also stain positive with the acid-fast technique is *Nocardia*. *Nocardia* is a Gram-positive rod that contains mycolic acid in its cell wall. Because *Nocardia* possesses less mycolic acid than do mycobacteria, *Nocardia* is more weakly acid fast.

(Choice A) N-acetylmuramic acid and N-acetylglucosamine are the saccharides that combine with an amino acid chain to form the peptidoglycan layer in both Gram-positive and Gram-negative cell walls.

(Choice B) Teichoic acid is a molecule linked to the peptidoglycan cell wall of Gram-positive bacteria (but not Gram-negative bacteria). Teichoic acid serves as an antigenic determinant for organism identification in the laboratory and an antigenic target for the human immune system.

(Choice C) Lipopolysaccharide (LPS) is a component of the outer cell envelope of Gram-negative bacteria.

(Choice E) Unique to fungi, ergosterol is the sterol component of fungal cell membranes. This molecule is not found in human cell membranes, as human cells have cholesterol in their cell membranes instead.

Educational Objective:
The acid-fast stain identifies organisms that have mycolic acid present in their cell walls, including *Mycobacterium* and some *Nocardia* species. Acid-fast staining is carried out by applying an aniline dye (eg, carbolfuchsin) to a

https://t.me/USMLEWorldStep1

organisms (eg, *Mycobacterium* and some *Nocardia* species). Although it is less sensitive than culture, the acid-fast stained smear allows for immediate microscopic evaluation.

In the acid-fast stain for mycobacteria, the smear is first treated with an aniline dye (eg, carbolfuchsin). The dye (red color) penetrates the bacterial cell wall, where it binds with mycolic acids. The slide is then treated with hydrochloric acid and alcohol. This acid alcohol dissolves the outer cell membranes of nontuberculous bacteria, but the presence of mycolic acids prevents decolorization of mycobacteria. A counterstain (eg, methylene blue) is then applied and taken up by decolorized bacteria. As a result, the carbolfuchsin acid-fast stain produces red mycobacteria (initial stain) and blue non-acid fast bacteria.

The cell membrane and cell wall of mycobacteria are most similar to those in Gram-positive organisms, causing mycobacteria to appear weakly positive on Gram stain. However, the mycobacterial cell wall differs from that of the typical Gram-positive organism in that they are encapsulated with mycolic acid, a waxy, long-chain fatty acid that is covalently bound to the sugars within the cell wall. Another organism that will also stain positive with the acid-fast technique is *Nocardia*. *Nocardia* is a Gram-positive rod that contains mycolic acid in its cell wall. Because *Nocardia* possesses less mycolic acid than do mycobacteria, *Nocardia* is more weakly acid fast.

(Choice A) N-acetylmuramic acid and N-acetylglucosamine are the saccharides that combine with an amino acid chain to form the peptidoglycan layer in both Gram-positive and Gram-negative cell walls.

(Choice B) Teichoic acid is a molecule linked to the peptidoglycan cell wall of Gram-positive bacteria (but not Gram-negative bacteria). Teichoic acid serves as an antigenic determinant for organism identification in the laboratory and an antigenic target for the human immune system.

(Choice C) Lipopolysaccharide (LPS) is a component of the outer cell envelope of Gram-negative bacteria.

(Choice E) Unique to fungi, ergosterol is the sterol component of fungal cell membranes. This molecule is not found in human cell membranes, as human cells have cholesterol in their cell membranes instead.

Educational Objective:
The acid-fast stain identifies organisms that have mycolic acid present in their cell walls, including *Mycobacterium* and some *Nocardia* species. Acid-fast staining is carried out by applying an aniline dye (eg, carbolfuchsin) to a smear and then decolorizing with acid alcohol to reveal whether the organisms present are "acid fast."

https://t.me/USMLEWorldStep1

A 32-year-old woman is brought to the emergency department due to worsening shortness of breath. Pulse oximetry shows 99% on room air. Results from analysis of an arterial blood sample are as follows:

Partial pressure of oxygen (PaO_2)	normal
Oxygen saturation (SaO_2)	normal
Total arterial oxygen content (CaO_2)	low

Which of the following is the most likely cause of this patient's laboratory findings?

- A. Chronic blood loss
- B. Cyanide intoxication
- C. Primary overproduction of red blood cells
- D. Recent high-altitude exposure
- E. Right to left intrapulmonary shunting

Submit

https://t.me/USMLEWorldStep1

A 32-year-old woman is brought to the emergency department due to worsening shortness of breath. Pulse oximetry shows 99% on room air. Results from analysis of an arterial blood sample are as follows:

Partial pressure of oxygen (PaO_2)	normal
Oxygen saturation (SaO_2)	normal
Total arterial oxygen content (CaO_2)	low

Which of the following is the most likely cause of this patient's laboratory findings?

- ✓ A. Chronic blood loss (40%)
- ✗ B. Cyanide intoxication (32%)
- C. Primary overproduction of red blood cells (4%)
- D. Recent high-altitude exposure (8%)
- E. Right to left intrapulmonary shunting (14%)

Incorrect
Correct answer
A

40%
Answered correctly

05 secs
Time Spent

2023
Version

Explanation

	PaO_2	SaO_2	Oxygen content
CO poisoning	Normal	↓*	↓
Cyanide poisoning	Normal	Normal	Normal
Anemia (↓ Hb)	Normal	Normal	↓
Polycythemia (↑ Hb)	Normal	Normal	↑

https://t.me/USMLEWorldStep1

	PaO_2	SaO_2	Oxygen content
CO poisoning	Normal	↓*	↓
Cyanide poisoning	Normal	Normal	Normal
Anemia (↓ Hb)	Normal	Normal	↓
Polycythemia (↑ Hb)	Normal	Normal	↑
High altitude	↓	↓	↓

*Detected as normal using standard probes.

CO = carbon monoxide; **Hb** = hemoglobin; **PaO_2** = partial pressure of oxygen; **SaO_2** = arterial oxygen saturation.

Oxygen (O_2) is carried in the blood, both as a dissolved gas and in combination with hemoglobin. The **total O_2 content** of the blood (CaO_2) is determined primarily by the **amount of hemoglobin** in the blood and its **percentage of O_2 saturation** (SaO_2), which is directly influenced by changes in arterial O_2 tension (PaO_2) of the dissolved O_2 according to the oxygen-hemoglobin dissociation curve. Freely dissolved O_2 normally accounts for only a very small proportion of the total O_2 content of blood due to its low solubility in plasma.

This patient's **low CaO_2** in the arterial blood but **normal PaO_2 and SaO_2** are suggestive of **low hemoglobin** (ie, anemia), which reduces the total O_2 content in the blood despite a normal partial pressure and percentage of O_2 saturation. A common cause of anemia in this patient's age group includes **chronic blood loss** (eg, heavy menses).

(Choice B) Cyanide inhibits oxidative phosphorylation by inhibiting ferric iron (Fe^{3+}) in cytochrome c oxidase, lowering O_2 consumption in peripheral tissue. Arterial PaO_2, SaO_2, and CaO_2 remain unchanged, but venous O_2 content rises and the arterial-venous O_2 gradient falls. Cyanide may also bind to the ferrous (Fe^{2+}) iron of hemoglobin to form cyanhemoglobin but typically only in small amounts that do not appreciably change arterial O_2 content.

(Choice C) Primary polycythemia (polycythemia vera) is due to a genetic mutation causing increased red blood

https://t.me/USMLEWorldStep1

Oxygen (O_2) is carried in the blood, both as a dissolved gas and in combination with hemoglobin. The **total O_2 content** of the blood (CaO_2) is determined primarily by the **amount of hemoglobin** in the blood and its **percentage of O_2 saturation** (SaO_2), which is directly influenced by changes in arterial O_2 tension (PaO_2) of the dissolved O_2 according to the oxygen-hemoglobin dissociation curve. Freely dissolved O_2 normally accounts for only a very small proportion of the total O_2 content of blood due to its low solubility in plasma.

This patient's **low CaO_2** in the arterial blood but **normal PaO_2 and SaO_2** are suggestive of **low hemoglobin** (ie, anemia), which reduces the total O_2 content in the blood despite a normal partial pressure and percentage of O_2 saturation. A common cause of anemia in this patient's age group includes **chronic blood loss** (eg, heavy menses).

(Choice B) Cyanide inhibits oxidative phosphorylation by inhibiting ferric iron (Fe^{3+}) in cytochrome c oxidase, lowering O_2 consumption in peripheral tissue. Arterial PaO_2, SaO_2, and CaO_2 remain unchanged, but venous O_2 content rises and the arterial-venous O_2 gradient falls. Cyanide may also bind to the ferrous (Fe^{2+}) iron of hemoglobin to form cyanhemoglobin but typically only in small amounts that do not appreciably change arterial O_2 content.

(Choice C) Primary polycythemia (polycythemia vera) is due to a genetic mutation causing increased red blood cell (RBC) production. The hemoglobin within RBCs functions normally (normal SaO_2), but there is a greater total amount of hemoglobin (increased CaO_2). There are no effects on dissolved oxygen (normal PaO_2).

(Choice D) The O_2 tension in high-altitude settings is relatively low compared to that at sea level. Recent exposure to a high-altitude environment would result in reduced alveolar O_2 tension, leading to reduced PaO_2 and SaO_2, with a corresponding decrease in CaO_2.

(Choice E) Right to left intrapulmonary shunting occurs when venous blood flows through inadequately ventilated alveoli (eg, pulmonary edema). This blood remains deoxygenated as it reenters the systemic circulation. It has a low PaO_2 and SaO_2, with a corresponding decrease in CaO_2.

Educational objective:
The total oxygen content of blood (CaO_2) is affected primarily by 2 variables: hemoglobin concentration and its

https://t.me/USMLEWorldStep1

dissolved O_2 according to the oxygen-hemoglobin dissociation curve. Freely dissolved O_2 normally accounts for only a very small proportion of the total O_2 content of blood due to its low solubility in plasma.

This patient's **low CaO_2** in the arterial blood but **normal PaO_2 and SaO_2** are suggestive of **low hemoglobin** (ie, anemia), which reduces the total O_2 content in the blood despite a normal partial pressure and percentage of O_2 saturation. A common cause of anemia in this patient's age group includes **chronic blood loss** (eg, heavy menses).

(Choice B) Cyanide inhibits oxidative phosphorylation by inhibiting ferric iron (Fe^{3+}) in cytochrome c oxidase, lowering O_2 consumption in peripheral tissue. Arterial PaO_2, SaO_2, and CaO_2 remain unchanged, but venous O_2 content rises and the arterial-venous O_2 gradient falls. Cyanide may also bind to the ferrous (Fe^{2+}) iron of hemoglobin to form cyanhemoglobin but typically only in small amounts that do not appreciably change arterial O_2 content.

(Choice C) Primary polycythemia (polycythemia vera) is due to a genetic mutation causing increased red blood cell (RBC) production. The hemoglobin within RBCs functions normally (normal SaO_2), but there is a greater total amount of hemoglobin (increased CaO_2). There are no effects on dissolved oxygen (normal PaO_2).

(Choice D) The O_2 tension in high-altitude settings is relatively low compared to that at sea level. Recent exposure to a high-altitude environment would result in reduced alveolar O_2 tension, leading to reduced PaO_2 and SaO_2, with a corresponding decrease in CaO_2.

(Choice E) Right to left intrapulmonary shunting occurs when venous blood flows through inadequately ventilated alveoli (eg, pulmonary edema). This blood remains deoxygenated as it reenters the systemic circulation. It has a low PaO_2 and SaO_2, with a corresponding decrease in CaO_2.

Educational objective:
The total oxygen content of blood (CaO_2) is affected primarily by 2 variables: hemoglobin concentration and its percentage of oxygen saturation (SaO_2), which is directly affected by the arterial oxygen tension (PaO_2). Anemia is characterized by decreased hemoglobin concentration in the setting of normal SaO_2 and PaO_2.

Physiology Pulmonary & Critical Care Iron deficiency anemia

https://t.me/USMLEWorldStep1

High altitude	↓	↓	↓

*Detected as normal using standard probes

Exhibit Display

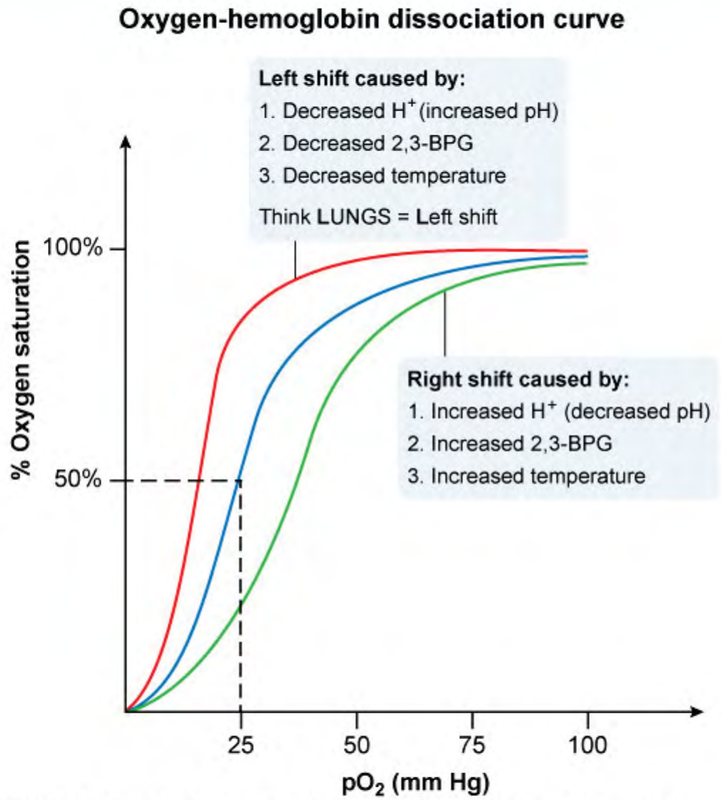

2,3-BPG = 2,3-bisphosphoglycerate; **pO_2** = partial pressure of oxygen in the blood.

©UWorld

Zoom In | Zoom Out | Reset | New | Existing | My Notebook

Oxyge
O_2 cor
perce
dissolv
only a

This p
anemi
satura
mense

(Choi
loweri
conter
hemog
conter

(Choi
cell (R
amour

(Choi
expos
SaO_2,

(Choi
alveoli (eg, pulmonary edema). This blood remains deoxygenated as it reenters the systemic circulation. It has a
low PaO_2 and SaO_2 with a corresponding decrease in CaO_2

https://t.me/USMLEWorldStep1

A 2-day-old boy is evaluated in the neonatal intensive care unit for lethargy and respiratory distress. The patient was born at home via spontaneous vaginal delivery at term gestation to a mother who did not receive routine prenatal care. Temperature is 38.9 C (102 F) and pulse is 162/min. Physical examination shows tachypnea and grunting. Blood cultures grow beta-hemolytic, gram-positive cocci in chains that elicit a narrow zone of complete hemolysis on blood agar. Which of the following virulence factors most likely contributed to the development of this patient's current condition?

- A. Antigenic variation
- B. Endotoxin
- C. Exotoxin
- D. M protein
- E. Polysaccharide capsule

Submit

https://t.me/USMLEWorldStep1

A 2-day-old boy is evaluated in the neonatal intensive care unit for lethargy and respiratory distress. The patient was born at home via spontaneous vaginal delivery at term gestation to a mother who did not receive routine prenatal care. Temperature is 38.9 C (102 F) and pulse is 162/min. Physical examination shows tachypnea and grunting. Blood cultures grow beta-hemolytic, gram-positive cocci in chains that elicit a narrow zone of complete hemolysis on blood agar. Which of the following virulence factors most likely contributed to the development of this patient's current condition?

- A. Antigenic variation (1%)
- ✕ B. Endotoxin (6%)
- C. Exotoxin (9%)
- D. M protein (17%)
- ✓ E. Polysaccharide capsule (64%)

Incorrect
Correct answer
E

64%
Answered correctly

04 secs
Time Spent

2023
Version

Explanation

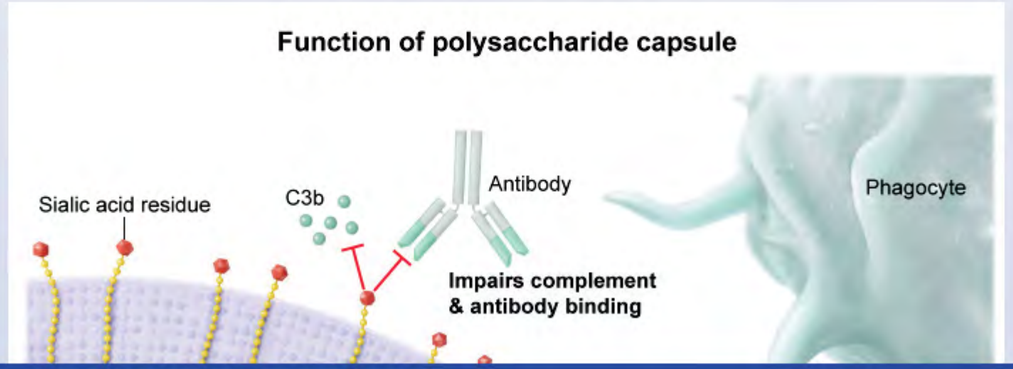

https://t.me/USMLEWorldStep1

A 2-day-old boy is evaluated in the neonatal intensive care unit for lethargy and respiratory distress. The patient was b
prenat
gruntir
hemol
patien

Exhibit Display

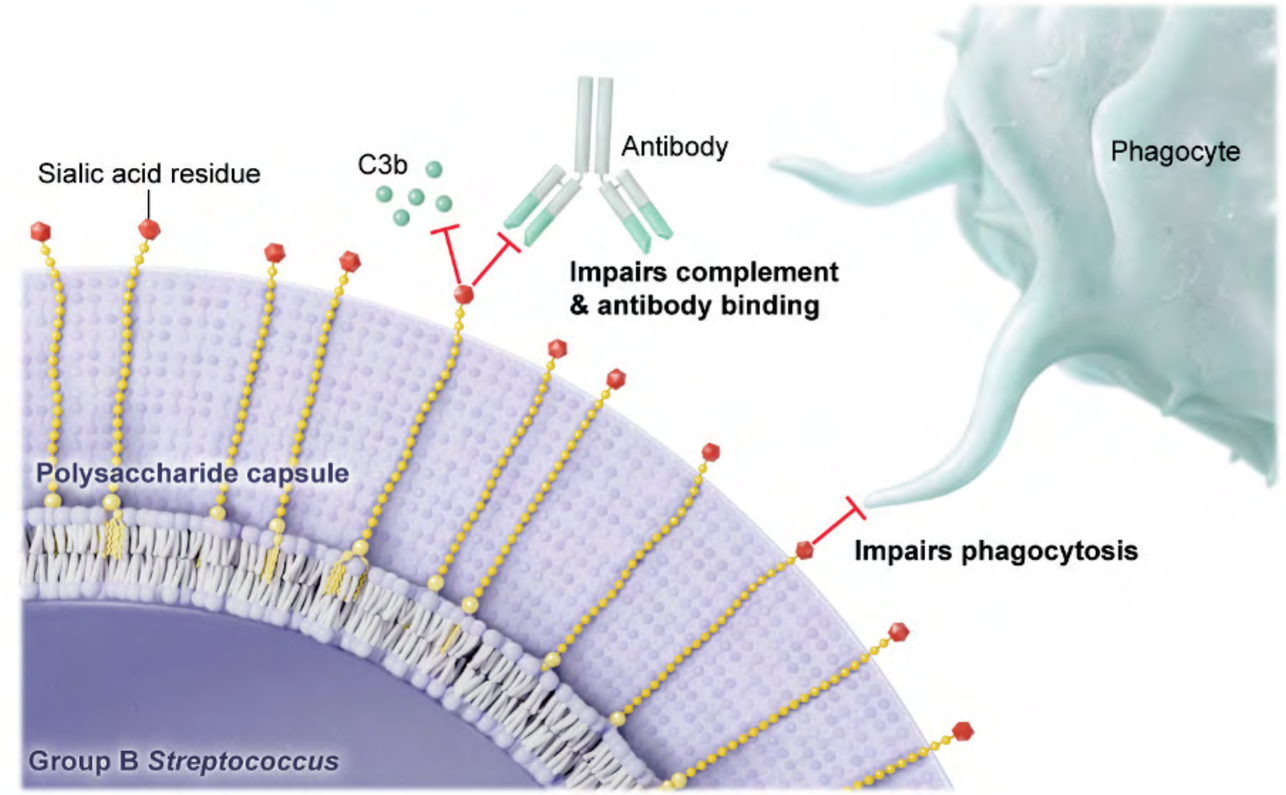

Zoom In | Zoom Out | Reset | New | Existing | My Notebook

https://t.me/USMLEWorldStep1

This neonate has sepsis (eg, fever, lethargy, respiratory distress) due to **group B *Streptococcus*** (GBS), a **gram-positive coccus** that forms **chains** and exhibits a **narrow zone** of complete hemolysis on blood agar (beta-hemolytic).

GBS colonizes the gastrointestinal or genitourinary tract of approximately 50% of pregnant women. These women are treated with intrapartum antibiotic prophylaxis (eg, penicillin) as part of routine prenatal care to prevent **vertical transmission** during rupture of membranes or vaginal delivery. Women who are colonized and do not receive prophylaxis, like this patient's mother, are more likely to transmit the organism to the neonate, leading to increased risk for **sepsis**, pneumonia, or meningitis within hours to days after birth (ie, early-onset disease).

The virulence of GBS stems from the presence of a thick **polysaccharide capsule** composed of galactose with terminal **sialic acid** (SA) residues. These residues are identical to SA epitopes on glycoproteins/glycolipids of host cells, allowing bacteria to evade host defenses via **molecular mimicry**. Bacterial SA residues are also recognized as "self" by phagocytes, which **limits phagocytosis**, oxidative burst generation, and production of neutrophil extracellular traps. In addition, SA residues inhibit binding of the opsonin C3b (limits opsonophagocytosis) and the generation of the anaphylatoxin C5a (limits immune cell recruitment).

(Choice A) Antigenic variation involves rapid mutation/recombination of surface antigens so that antibody formed during a previous infection is unable to prevent future infection. This is commonly seen with viruses (eg, influenza) and some bacteria (eg, *Neisseria meningitidis*) but not GBS.

(Choice B) Endotoxin (lipopolysaccharide) is a major virulence factor of gram-negative bacteria (eg, *Escherichia coli*). Although *E coli* is a common cause of neonatal sepsis, gram-negative rods would be seen in the bloodstream.

(Choice C) Listeriolysin O, the primary virulence factor of *Listeria monocytogenes*, is an exotoxin that causes pores in the phagosome membrane. This allows the organisms to escape into the cytoplasm of phagocytic cells prior to phagolysosomal destruction. Although *Listeria* can cause neonatal infection (less commonly than GBS and *E coli*), it is a gram-positive rod, not a coccus.

(Choice D) M protein, a virulence factor of group A *Streptococcus* (GAS), prevents opsonization. Although GAS is a beta-hemolytic, gram-positive coccus in chains, it is not a common cause of neonatal sepsis.

https://t.me/USMLEWorldStep1

GBS colonizes the gastrointestinal or genitourinary tract of approximately 50% of pregnant women. These women are treated with intrapartum antibiotic prophylaxis (eg, penicillin) as part of routine prenatal care to prevent **vertical transmission** during rupture of membranes or vaginal delivery. Women who are colonized and do not receive prophylaxis, like this patient's mother, are more likely to transmit the organism to the neonate, leading to increased risk for **sepsis**, pneumonia, or meningitis within hours to days after birth (ie, early-onset disease).

The virulence of GBS stems from the presence of a thick **polysaccharide capsule** composed of galactose with terminal **sialic acid** (SA) residues. These residues are identical to SA epitopes on glycoproteins/glycolipids of host cells, allowing bacteria to evade host defenses via **molecular mimicry**. Bacterial SA residues are also recognized as "self" by phagocytes, which **limits phagocytosis**, oxidative burst generation, and production of neutrophil extracellular traps. In addition, SA residues inhibit binding of the opsonin C3b (limits opsonophagocytosis) and the generation of the anaphylatoxin C5a (limits immune cell recruitment).

(Choice A) Antigenic variation involves rapid mutation/recombination of surface antigens so that antibody formed during a previous infection is unable to prevent future infection. This is commonly seen with viruses (eg, influenza) and some bacteria (eg, *Neisseria meningitidis*) but not GBS.

(Choice B) Endotoxin (lipopolysaccharide) is a major virulence factor of gram-negative bacteria (eg, *Escherichia coli*). Although *E coli* is a common cause of neonatal sepsis, gram-negative rods would be seen in the bloodstream.

(Choice C) Listeriolysin O, the primary virulence factor of *Listeria monocytogenes*, is an exotoxin that causes pores in the phagosome membrane. This allows the organisms to escape into the cytoplasm of phagocytic cells prior to phagolysosomal destruction. Although *Listeria* can cause neonatal infection (less commonly than GBS and *E coli*), it is a gram-positive rod, not a coccus.

(Choice D) M protein, a virulence factor of group A *Streptococcus* (GAS), prevents opsonization. Although GAS is a beta-hemolytic, gram-positive coccus in chains, it is not a common cause of neonatal sepsis.

Educational objective:
Group B *Streptococcus* is a major cause of neonatal sepsis. Its virulence factor is the polysaccharide capsule, which contains sialic acid residues that prevent phagocytosis via molecular mimicry.

https://t.me/USMLEWorldStep1

A 45-year-old man comes to the office due to progressive dyspnea on exertion and cough for the past several weeks. He has had no fever, chills, chest pain, or leg swelling. The patient is a former smoker with 5-pack-year history. Temperature is 37.2 C (99 F), blood pressure is 120/70 mm Hg, pulse is 82/min, and respirations are 16/min. The patient is hypoxemic at rest, with an oxygen saturation of 88% on room air. Jugular venous pressure is normal. Lung auscultation shows scattered crackles. Heart sounds are normal. Chest x-ray reveals bilateral midalveolar and lower alveolar opacities. Transbronchial lung biopsy reveals lipoproteinaceous material that is positive on periodic acid–Schiff stain and fills up the terminal bronchioles and alveoli. Electron microscopy of the substance shows lamellar bodies. Impaired function of which of the following most likely caused excessive accumulation of the substance in this patient's alveoli?

- A. Alveolar macrophages
- B. Ciliated airway epithelium
- C. Club cells
- D. Fibroblasts
- E. Type 1 pneumocytes

Submit

https://t.me/USMLEWorldStep1

A 45-year-old man comes to the office due to progressive dyspnea on exertion and cough for the past several weeks. He has had no fever, chills, chest pain, or leg swelling. The patient is a former smoker with 5-pack-year history. Temperature is 37.2 C (99 F), blood pressure is 120/70 mm Hg, pulse is 82/min, and respirations are 16/min. The patient is hypoxemic at rest, with an oxygen saturation of 88% on room air. Jugular venous pressure is normal. Lung auscultation shows scattered crackles. Heart sounds are normal. Chest x-ray reveals bilateral midalveolar and lower alveolar opacities. Transbronchial lung biopsy reveals lipoproteinaceous material that is positive on periodic acid–Schiff stain and fills up the terminal bronchioles and alveoli. Electron microscopy of the substance shows lamellar bodies. Impaired function of which of the following most likely caused excessive accumulation of the substance in this patient's alveoli?

- ✓ A. Alveolar macrophages (58%)
- B. Ciliated airway epithelium (15%)
- C. Club cells (10%)
- D. Fibroblasts (3%)
- ✗ E. Type 1 pneumocytes (11%)

Incorrect
Correct answer
A

58%
Answered correctly

05 secs
Time Spent

2023
Version

Explanation

Lung cells & functions		
Cell type	**Normal function(s)**	**Example disease association(s)**
	• Clearance of alveolar	• PAP: impaired

https://t.me/USMLEWorldStep1

Lung cells & functions		
Cell type	**Normal function(s)**	**Example disease association(s)**
Alveolar macrophage	• Clearance of alveolar debris (surfactant, pathogens, inhaled particulate matter)	• PAP: impaired macrophage clearance of surfactant
Type 1 pneumocyte	• Alveolar epithelial lining for gas exchange	• ARDS due to inhalational injury
Type 2 pneumocyte	• Surfactant production • Stem cell reservoir for type 1 pneumocytes	• Hyaline membrane disease of prematurity
Ciliated airway epithelial cell	• Mucociliary escalator • Salt, water & moisture homeostasis	• Ciliary dyskinesia (Kartagener syndrome) • Cystic fibrosis: airway desiccation
Club cell	• Protection & repair of distal airway	• COPD: tobacco smoke detoxification
Goblet cell	• Secretion of mucins	• COPD & asthma: goblet cell metaplasia & mucus hypersecretion
		• IPF: increased

https://t.me/USMLEWorldStep1

Cell type	Normal function(s)	Example disease association(s)
Alveolar macrophage	• Clearance of alveolar debris (surfactant, pathogens, inhaled particulate matter)	• PAP: impaired macrophage clearance of surfactant
Type 1 pneumocyte	• Alveolar epithelial lining for gas exchange	• ARDS due to inhalational injury
Type 2 pneumocyte	• Surfactant production • Stem cell reservoir for type 1 pneumocytes	• Hyaline membrane disease of prematurity
Ciliated airway epithelial cell	• Mucociliary escalator • Salt, water & moisture homeostasis	• Ciliary dyskinesia (Kartagener syndrome) • Cystic fibrosis: airway desiccation
Club cell	• Protection & repair of distal airway	• COPD: tobacco smoke detoxification
Goblet cell	• Secretion of mucins	• COPD & asthma: goblet cell metaplasia & mucus hypersecretion
Fibroblast	• Maintenance of interstitial lung tissue	• IPF: increased fibroblast activity • Emphysema: decreased fibroblast activity

https://t.me/USMLEWorldStep1

pneumocyte	for gas exchange	inhalational injury
Type 2 pneumocyte	• Surfactant production • Stem cell reservoir for type 1 pneumocytes	• Hyaline membrane disease of prematurity
Ciliated airway epithelial cell	• Mucociliary escalator • Salt, water & moisture homeostasis	• Ciliary dyskinesia (Kartagener syndrome) • Cystic fibrosis: airway desiccation
Club cell	• Protection & repair of distal airway	• COPD: tobacco smoke detoxification
Goblet cell	• Secretion of mucins	• COPD & asthma: goblet cell metaplasia & mucus hypersecretion
Fibroblast	• Maintenance of interstitial lung tissue	• IPF: increased fibroblast activity • Emphysema: decreased fibroblast activity

ARDS = acute respiratory distress syndrome; **COPD** = chronic obstructive pulmonary disease; **IPF** = idiopathic pulmonary fibrosis; **PAP** = pulmonary alveolar proteinosis.

This patient's presentation is consistent with **pulmonary alveolar proteinosis (PAP)**, a rare condition characterized by progressive respiratory dysfunction due to the **accumulation of surfactant** debris within alveolar spaces. Surfactant is a lipoproteinaceous material that appears pink with **periodic acid–Schiff** staining; it forms

https://t.me/USMLEWorldStep1

This patient's presentation is consistent with **pulmonary alveolar proteinosis (PAP)**, a rare condition characterized by progressive respiratory dysfunction due to the **accumulation of surfactant** debris within alveolar spaces. Surfactant is a lipoproteinaceous material that appears pink with **periodic acid–Schiff** staining; it forms concentrically laminated structures (ie, **lamellar bodies**) that can be seen on electron microscopy.

PAP is caused by an imbalance between surfactant production and clearance. In healthy lungs, surfactant is secreted by type 2 pneumocytes and eventually cleared by **alveolar macrophages**. In PAP, surfactant removal is impaired due to compromised alveolar macrophage function (eg, usually because of defects in granulocyte-monocyte colony-stimulating factor **[GM-CSF]** signaling).

Treatment involves therapeutic whole-lung lavage to wash away surfactant and inhaled GM-CSF replacement therapy.

(Choice B) Ciliated epithelial cells line the conducting airways and are responsible for mucociliary escalator function, a key process in airway clearance. Primary ciliary dyskinesia (eg, Kartagener syndrome) is characterized by impaired ciliary function and leads to mucostasis, recurrent pneumonia, and bronchiectasis.

(Choice C) Club cells (bronchiolar cells) are located at the bronchoalveolar alveolar junction and protect and repair the distal airway (terminal bronchioles). Club cell dysfunction has been implicated in the pathogenesis of COPD.

(Choice D) Fibroblasts produce and maintain the connective tissue matrix of the lung, lending structural support and elasticity. Loss of fibroblast function contributes to degenerative airspace dilation in emphysema.

(Choice E) Type 1 pneumocytes form the alveolar gas-exchanging surface. Rapid destruction and loss of type 1 pneumocytes occurs in early acute lung injury. It does not result in the abnormal accumulation of surfactant products.

Educational objective:
Pulmonary alveolar proteinosis is a rare condition characterized by progressive respiratory dysfunction due to the accumulation of surfactant (periodic acid–Schiff positive material forming lamellar bodies) within the alveolar spaces. The condition occurs most often due to the impaired clearance of surfactant by alveolar macrophages (eg, decreased granulocyte-monocyte colony-stimulating factor signaling).

https://t.me/USMLEWorldStep1

A 67-year-old man abruptly develops severe chest pain and respiratory distress before collapsing. The emergency medical team finds him unresponsive with no pulse, and he cannot be revived despite appropriate resuscitation efforts. A photograph of the patient's lung as seen at autopsy is shown below.

Which of the following underlying histopathologic changes are most likely to be present on microscopy?

- A. Ferruginous bodies embedded within interstitial fibrous tissue
- B. Hemosiderin-laden macrophages within congested airspaces
- C. Interalveolar septal destruction with airspace enlargement
- D. Multinucleated giant cells surrounding caseating granulomas
- E. Patchy interstitial fibrosis with the presence of fibroblastic foci

Submit

https://t.me/USMLEWorldStep1

A 67-year-old man abruptly develops severe chest pain and respiratory distress before collapsing. The emergency medic
efforts

Exhibit Display

Zoom In | Zoom Out | Reset | New | Existing | My Notebook

Which

A. Ferruginous bodies embedded within interstitial fibrous tissue

https://t.me/USMLEWorldStep1

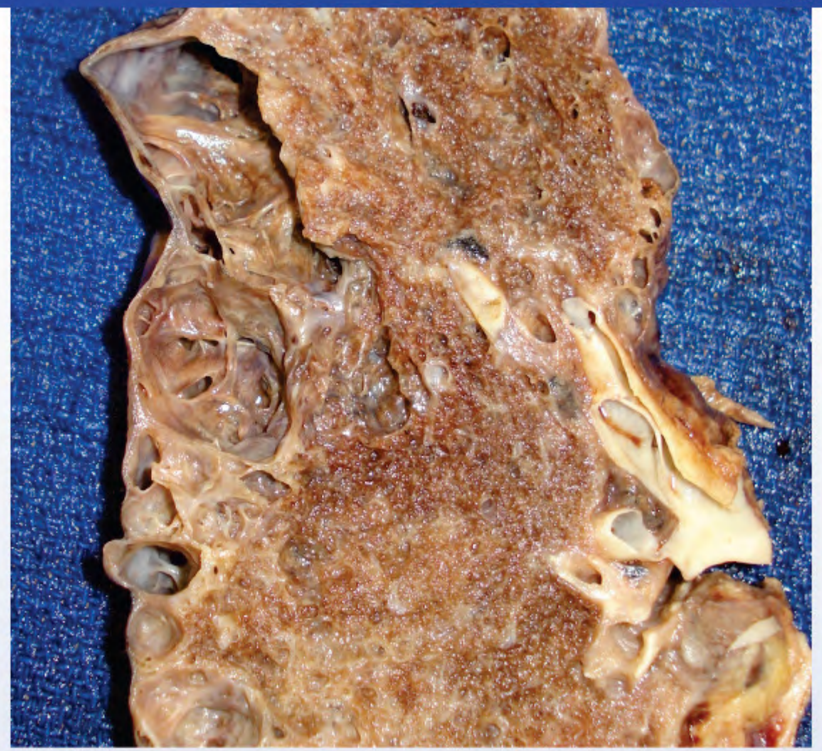

Which of the following underlying histopathologic changes are most likely to be present on microscopy?

- A. Ferruginous bodies embedded within interstitial fibrous tissue
- B. Hemosiderin-laden macrophages within congested airspaces
- C. Interalveolar septal destruction with airspace enlargement
- D. Multinucleated giant cells surrounding caseating granulomas
- E. Patchy interstitial fibrosis with the presence of fibroblastic foci

Submit

https://t.me/USMLEWorldStep1

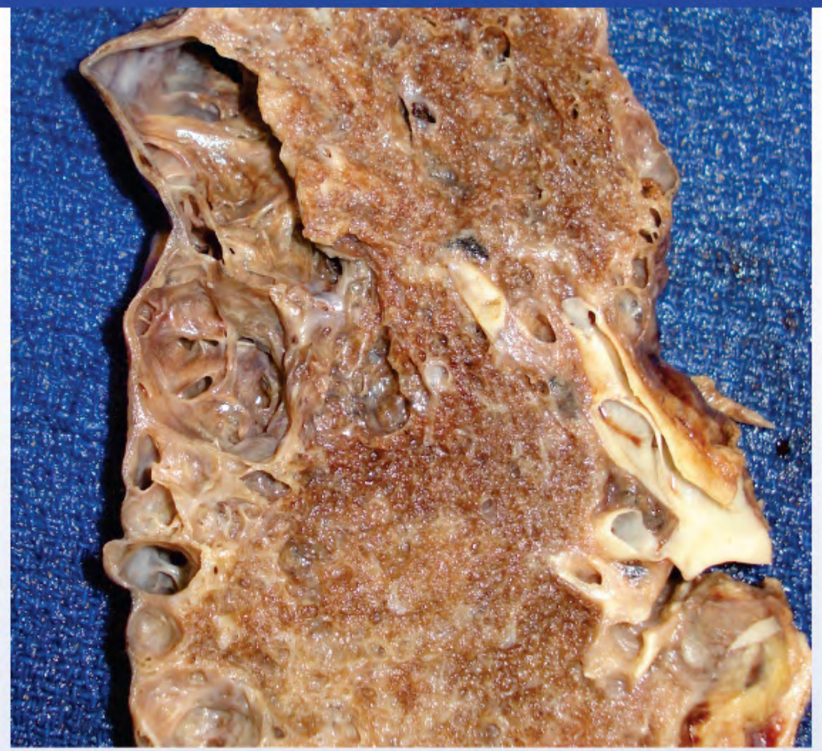

Which of the following underlying histopathologic changes are most likely to be present on microscopy?

- A. Ferruginous bodies embedded within interstitial fibrous tissue (7%)
- ✗ B. Hemosiderin-laden macrophages within congested airspaces (21%)
- ✓ C. Interalveolar septal destruction with airspace enlargement (56%)
- D. Multinucleated giant cells surrounding caseating granulomas (5%)
- E. Patchy interstitial fibrosis with the presence of fibroblastic foci (9%)

Incorrect
Correct answer
C

56%
Answered correctly

11 secs
Time Spent

2023
Version

https://t.me/USMLEWorldStep1

Explanation

Exhibit Display

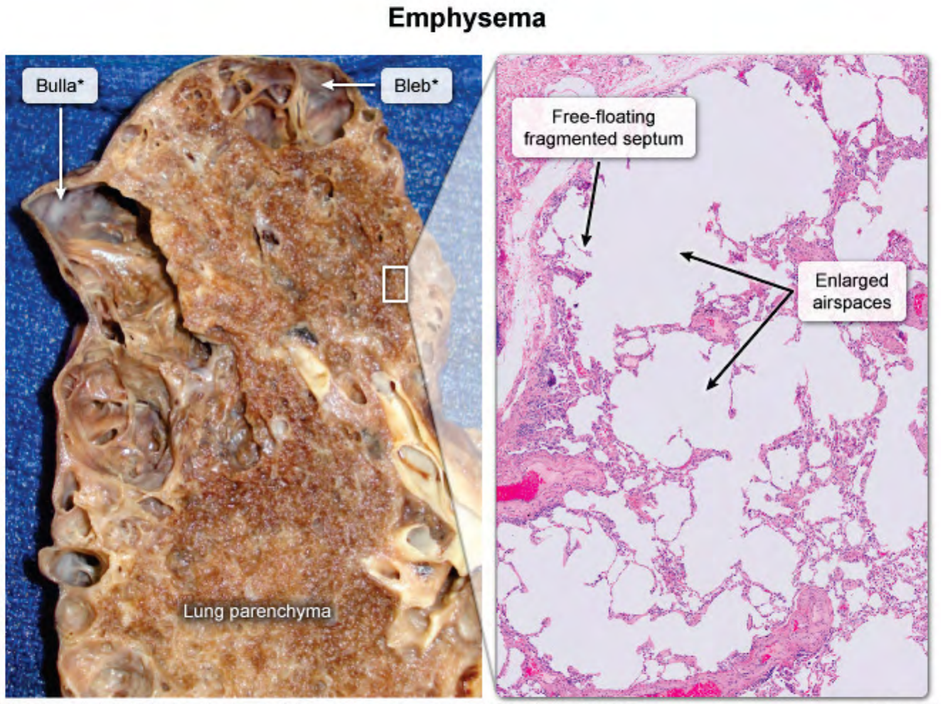

Zoom In | Zoom Out | Reset | New | Existing | My Notebook

Gross
emphy
mecha

- In
  in
  re
- Protease-antiprotease imbalance: Infiltrating inflammatory cells produce **tissue-destructive proteases** (eg, elastase, matrix metalloproteinases). Tobacco smoke also inactivates alpha-1 antitrypsin, causing insufficient

https://t.me/USMLEWorldStep1

Gross examination of this patient's lung shows multiple large **subpleural blebs** consistent with severe **emphysema**. Emphysema most commonly develops due to chronic exposure to cigarette smoke via the following mechanisms:

- Inflammation and leukocyte infiltration: Tobacco exposure stimulates an **inflammatory response** in which immune cells (eg, alveolar macrophages) release inflammatory cytokines (eg, tumor necrosis factor) and recruit **neutrophils** and $CD8^+$ T lymphocytes to the alveolar tissue.
- Protease-antiprotease imbalance: Infiltrating inflammatory cells produce **tissue-destructive proteases** (eg, elastase, matrix metalloproteinases). Tobacco smoke also inactivates alpha-1 antitrypsin, causing insufficient antiprotease activity.
- Oxidative stress: Cigarette smoke and chronic inflammation increase exposure to reactive oxygen species, which impart further tissue damage.

The ongoing tissue damage leads to destruction of the alveolar septa, producing **enlarged alveolar airspaces**. The lung apices are most heavily affected ("smoke rises"). As the emphysema progresses, the enlarged airspaces merge into subpleural blebs concentrated at the apices. Blebs can further expand to form massive bullae. These bullae and blebs can sometimes rupture, leading to spontaneous pneumothorax (ipsilateral pleuritic chest pain, reduced breath sounds, respiratory distress).

(Choice A) Ferruginous bodies embedded within interstitial fibrous tissue are characteristic of pulmonary asbestosis. These bodies represent asbestos fibers enclosed in iron-rich material; histologically, they appear as golden-brown, barbell-shaped structures. Gross pathology typically shows shrunken, fibrotic lungs with calcified pleural plaques.

(Choice B) Hemosiderin-laden macrophages with congested airspaces are consistent with cardiogenic pulmonary edema. Gross pathology typically shows wet, heavy, congested lungs with a red-brown hue due to increased blood volume.

(Choice D) Multinucleated giant cells surrounding caseating granulomas characterize tuberculosis. Occasionally, tuberculosis produces cavitary lung lesions that can mimic the appearance of emphysematous blebs, but on gross pathology the cavities typically contain caseous necrotic debris.

https://t.me/USMLEWorldStep1

- Protease-antiprotease imbalance: Infiltrating inflammatory cells produce **tissue-destructive proteases** (eg, elastase, matrix metalloproteinases). Tobacco smoke also inactivates alpha-1 antitrypsin, causing insufficient antiprotease activity.
- Oxidative stress: Cigarette smoke and chronic inflammation increase exposure to reactive oxygen species, which impart further tissue damage.

The ongoing tissue damage leads to destruction of the alveolar septa, producing **enlarged alveolar airspaces**. The lung apices are most heavily affected ("smoke rises"). As the emphysema progresses, the enlarged airspaces merge into subpleural blebs concentrated at the apices. Blebs can further expand to form massive bullae. These bullae and blebs can sometimes rupture, leading to spontaneous pneumothorax (ipsilateral pleuritic chest pain, reduced breath sounds, respiratory distress).

(Choice A) Ferruginous bodies embedded within interstitial fibrous tissue are characteristic of pulmonary asbestosis. These bodies represent asbestos fibers enclosed in iron-rich material; histologically, they appear as golden-brown, barbell-shaped structures. Gross pathology typically shows shrunken, fibrotic lungs with calcified pleural plaques.

(Choice B) Hemosiderin-laden macrophages with congested airspaces are consistent with cardiogenic pulmonary edema. Gross pathology typically shows wet, heavy, congested lungs with a red-brown hue due to increased blood volume.

(Choice D) Multinucleated giant cells surrounding caseating granulomas characterize tuberculosis. Occasionally, tuberculosis produces cavitary lung lesions that can mimic the appearance of emphysematous blebs, but on gross pathology the cavities typically contain caseous necrotic debris.

(Choice E) Patchy interstitial fibrosis with the presence of fibroblastic foci is consistent with idiopathic pulmonary fibrosis. Gross pathology shows hardened, shrunken lungs (fibrotic retraction) and subpleural honeycombing. These changes are often most severe in the lower lobes.

Educational objective:
Emphysema involves inflammatory and proteolytic destruction of the alveolar septa. In severe disease, dilated alveolar pockets progressively merge into subpleural blebs. These are prone to rupture, leading to pneumothorax

https://t.me/USMLEWorldStep1

Exhibit Display

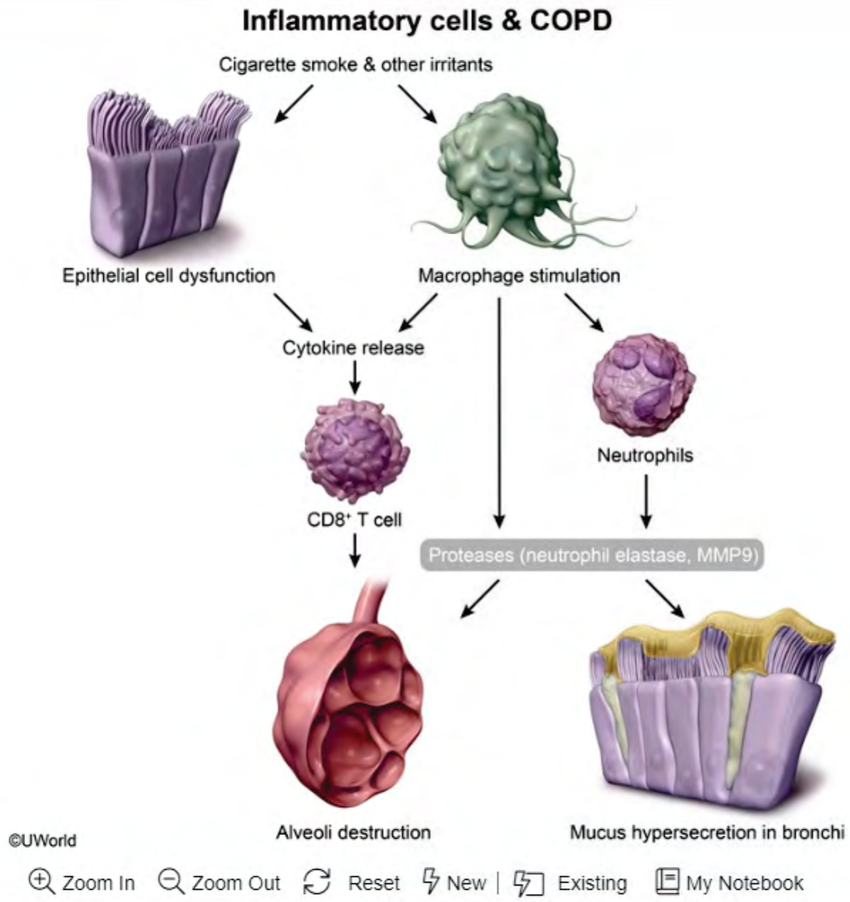

Zoom In | Zoom Out | Reset | New | Existing | My Notebook

Gross
emphy
mecha

- In
  in
  re
- P
  e
  a
- C
  w

The or
The lu
merge
bullae
reduce

(Choi
asbestosis. These bodies represent asbestos fibers enclosed in iron-rich material; histologically, they appear as golden-brown, barbell-shaped structures. Gross pathology typically shows shrunken, fibrotic lungs with calcified pleural plaques.

https://t.me/USMLEWorldStep1

Gross examination of this patient's lung shows multiple large **subpleural blebs** consistent with severe **emphysema**. Emphysema most commonly develops due to chronic exposure to cigarette smoke via the following mecha

- In
- P
- C

The or
The lu
merge
bullae
reduce

(Choi
asbes
golder
pleura

(Choi
edema
blood

(Choi
tuberc
pathology the cavities typically contain caseous necrotic debris.

Exhibit Display

Ferruginous bodies

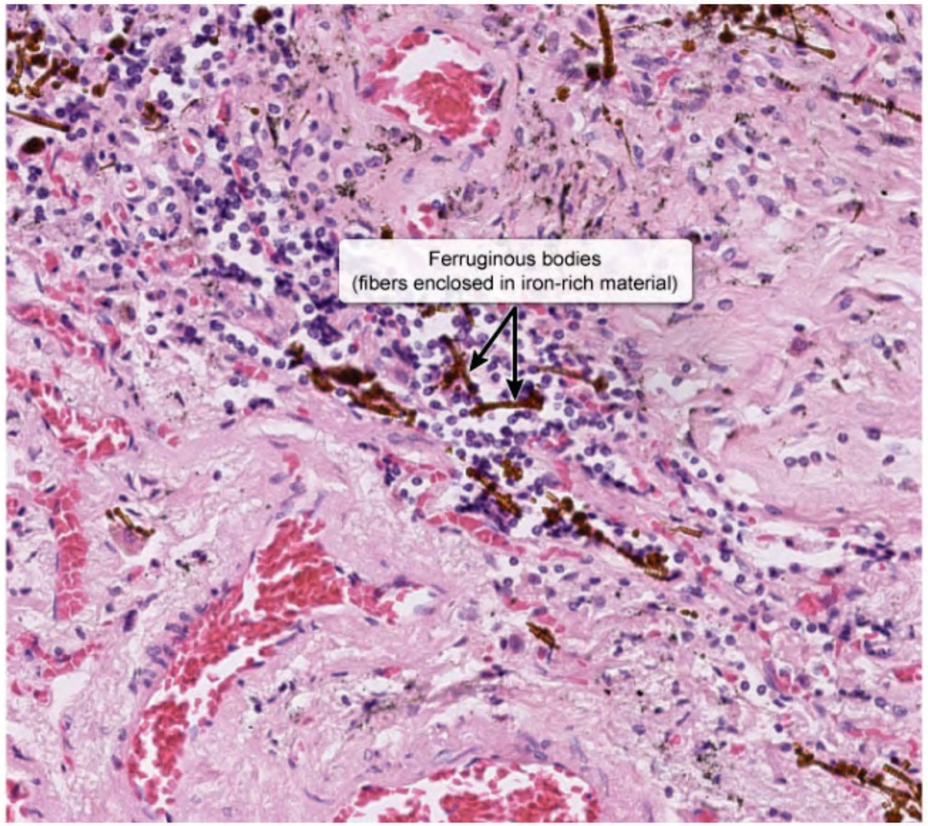

©UWorld

Zoom In | Zoom Out | Reset | New | Existing | My Notebook

https://t.me/USMLEWorldStep1

Gross examination of this patient's lung shows multiple large **subpleural blebs** consistent with severe **emphysema**. Emphysema most commonly develops due to chronic exposure to cigarette smoke via the following mecha

- In
- P
- C

The or
The lu
merge
bullae
reduce

(Choi
asbest
golden
pleura

(Choi
edema
blood

(Choi
tuberc
pathology the cavities typically contain caseous necrotic debris.

Exhibit Display

Asbestos exposure

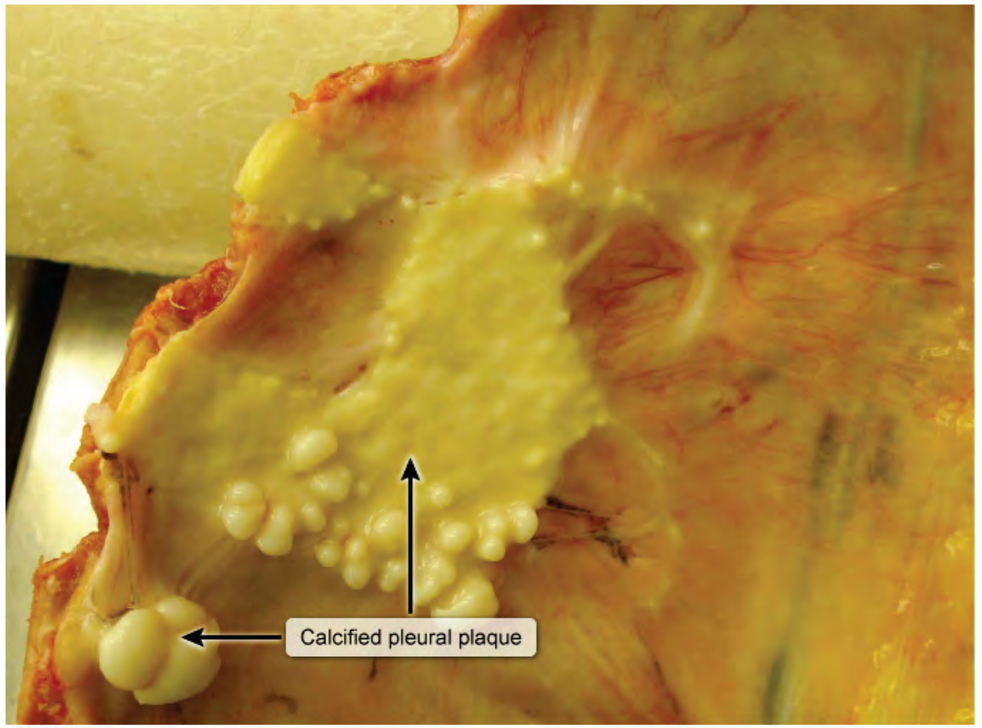

©UWorld

Zoom In | Zoom Out | Reset | New | Existing | My Notebook

https://t.me/USMLEWorldStep1

- Protease-antiprotease imbalance: Infiltrating inflammatory cells produce **tissue-destructive proteases** (eg, elastase, matrix metalloproteinases). Tobacco smoke also inactivates alpha-1 antitrypsin, causing insufficient a

- C
w

The or
The lu
merge
bullae
reduce

(Choi
asbes
golder
pleura

(Choi
edema
blood

(Choi
tuberc
pathol

(Choi
fibrosi
These

Educational objective:
Emphysema involves inflammatory and proteolytic destruction of the alveolar septa. In severe disease, dilated alveolar pockets progressively merge into subpleural blebs. These are prone to rupture, leading to pneumothorax

Exhibit Display

Chronic pulmonary congestion

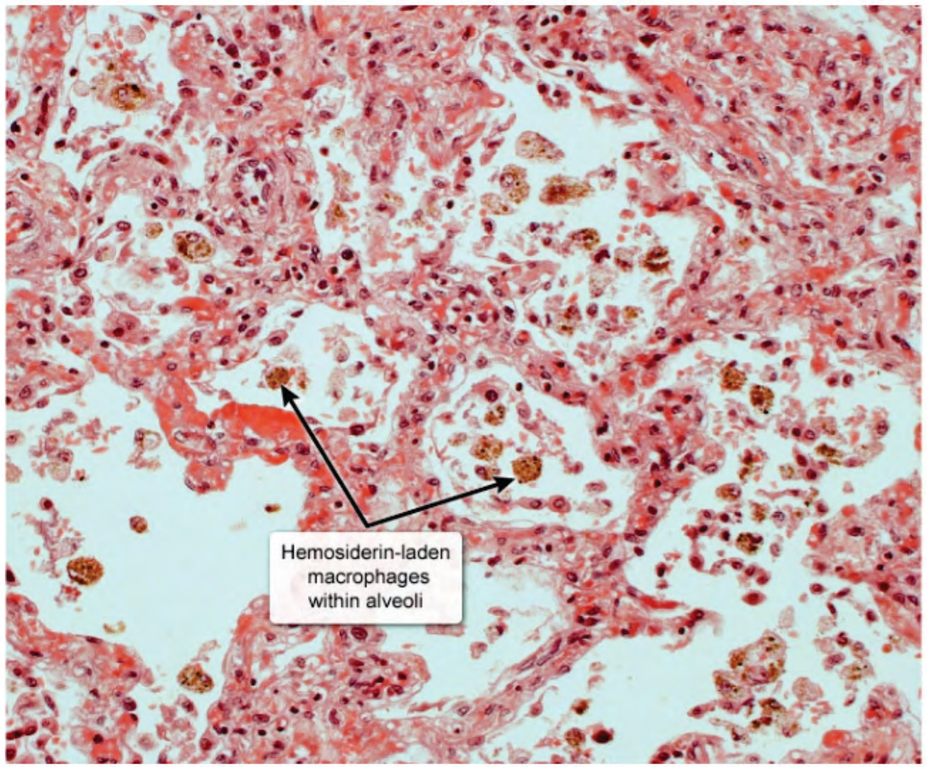

©UWorld

Zoom In Zoom Out Reset New | Existing My Notebook

https://t.me/USMLEWorldStep1

- Oxidative stress: Cigarette smoke and chronic inflammation increase exposure to reactive oxygen species;

Display

Pulmonary tuberculosis

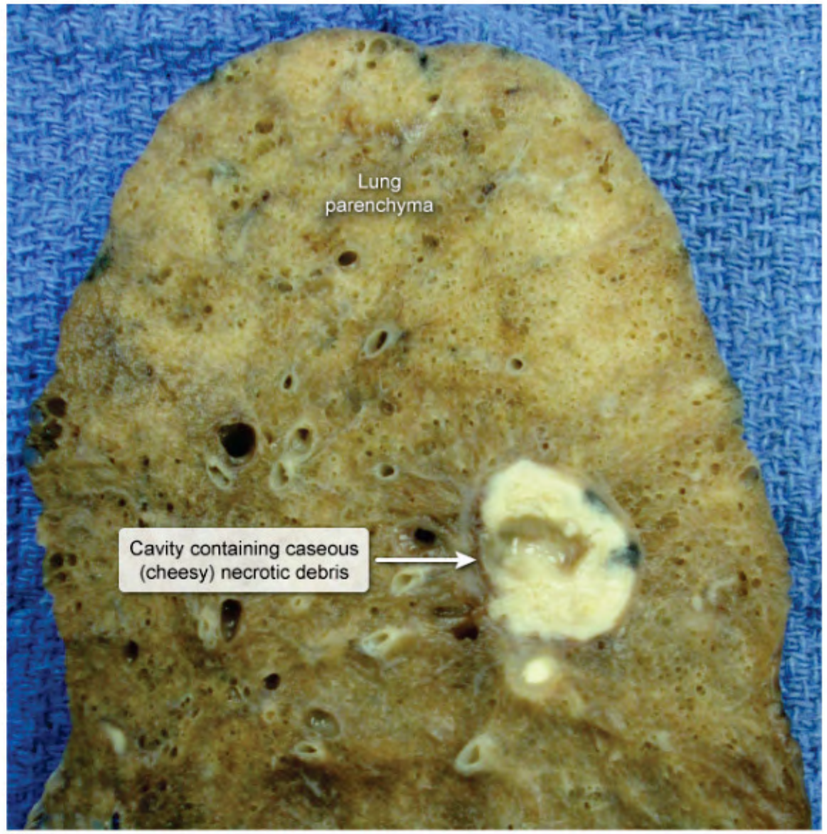

©UWorld

Zoom In | Zoom Out | Reset | New | Existing | My Notebook

- Pathogenesis of emphysema: from the bench to the bedside.

Pathology | Pulmonary & Critical Care | COPD

https://t.me/USMLEWorldStep1

- Oxidative stress: Cigarette smoke and chronic inflammation increase exposure to reactive oxygen species, which impart further tissue damage.

The or
The lu
merge
bullae
reduce

(Choi
asbes
golder
pleura

(Choi
edema
blood

(Choi
tuberc
pathol

(Choi
fibrosi
These

Educa
Emphy
alveola

References

- Pathogenesis of emphysema: from the bench to the bedside.

Pathology Pulmonary & Critical Care COPD

Exhibit Display

Caseating granuloma

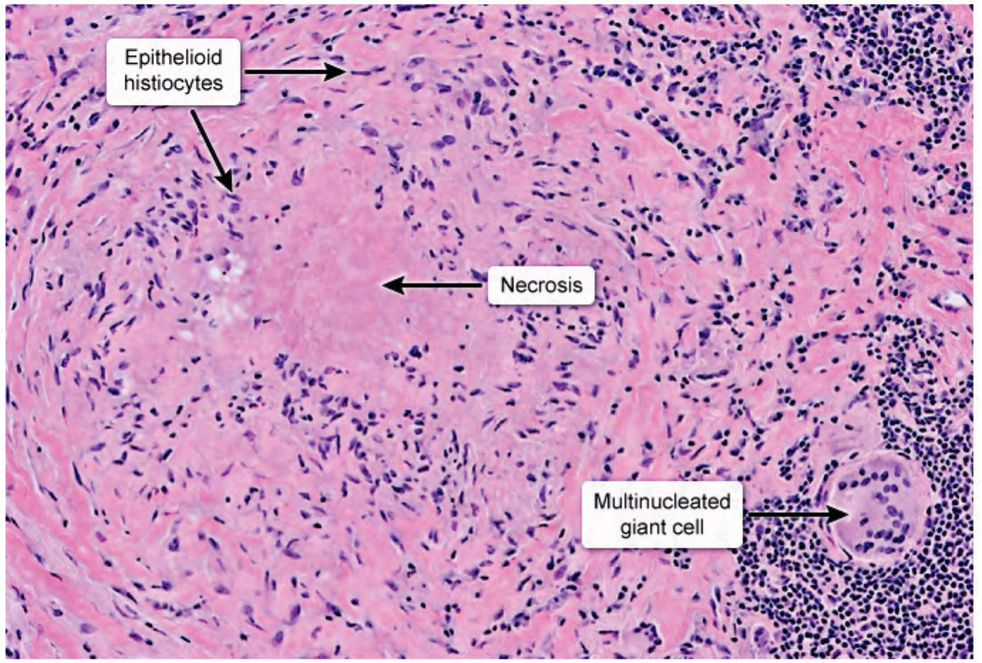

©UWorld

Zoom In Zoom Out Reset New | Existing My Notebook

https://t.me/USMLEWorldStep1

- Oxidative stress: Cigarette smoke and chronic inflammation increase exposure to reactive oxygen species, which impart further tissue damage.

The or
The lu
merge
bullae
reduce

(Choi
asbes
golder
pleura

(Choi
edema
blood

(Choi
tuberc
pathol

(Choi
fibrosi
These

Educa
Emphy
alveol

Refere
- Pat

Exhibit Display

Idiopathic pulmonary fibrosis

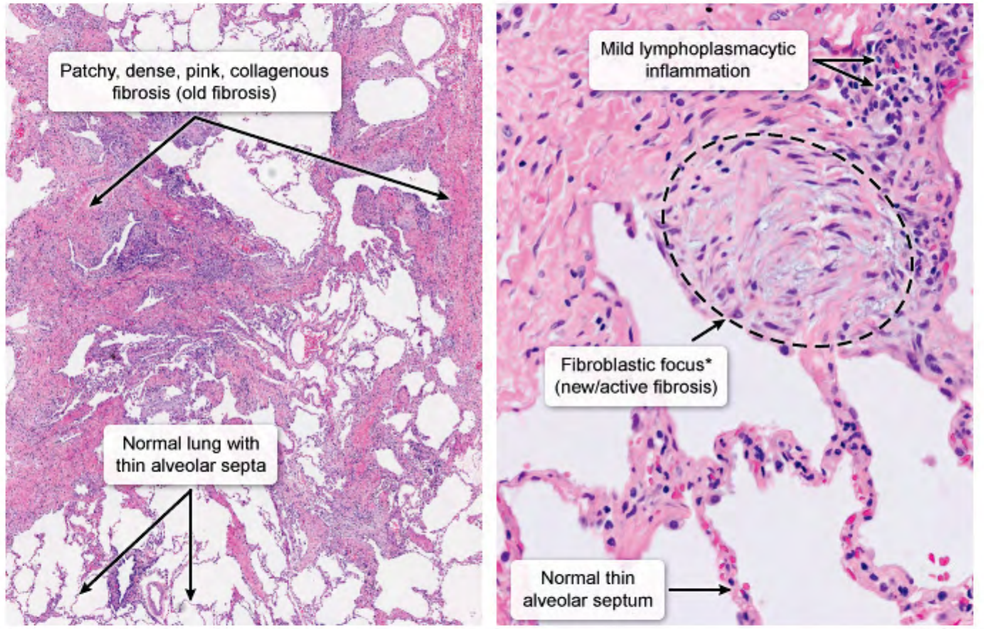

*Proliferation of fibroblasts and myofibroblasts with pale gray stroma.

©UWorld

Zoom In | Zoom Out | Reset | New | Existing | My Notebook

Pathology | Pulmonary & Critical Care | COPD

https://t.me/USMLEWorldStep1

- Oxidative stress: Cigarette smoke and chronic inflammation increase exposure to reactive oxygen species, which impart further tissue damage.

The or
The lu
merge
bullae
reduce

(Choi
asbes
golder
pleura

(Choi
edema
blood

(Choi
tuberc
pathol

(Choi
fibrosi
These

Educa
Emphy
alveol

Refere
- Pat

Exhibit Display

Idiopathic pulmonary fibrosis

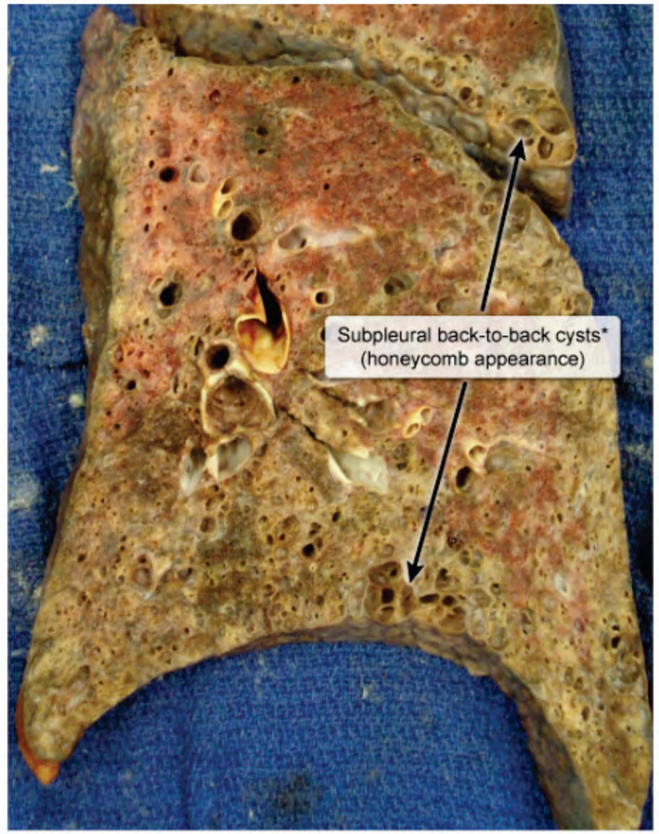

*Fibrosis destroys normal architecture & creates cystic airspaces.
©UWorld

Zoom In | Zoom Out | Reset | New | Existing | My Notebook

Pathology | Pulmonary & Critical Care | COPD

https://t.me/USMLEWorldStep1

A 63-year-old man with a history of chronic obstructive pulmonary disease comes to the office for a follow-up visit. He uses a tiotropium inhaler daily, and his pulmonary symptoms are sufficiently controlled. During a previous visit, the patient was counseled on the benefits of smoking cessation. He reports that despite trying he has been unable to stop smoking due to overwhelming cravings. The physician prescribes a drug that reduces nicotine cravings and decreases the pleasurable effects of cigarettes and other tobacco products. Which of the following medications was most likely prescribed to the patient?

- A. Clonazepam
- B. Fluoxetine
- C. Nicotine patch
- D. Topiramate
- E. Varenicline

Submit

https://t.me/USMLEWorldStep1

A 63-year-old man with a history of chronic obstructive pulmonary disease comes to the office for a follow-up visit. He uses a tiotropium inhaler daily, and his pulmonary symptoms are sufficiently controlled. During a previous visit, the patient was counseled on the benefits of smoking cessation. He reports that despite trying he has been unable to stop smoking due to overwhelming cravings. The physician prescribes a drug that reduces nicotine cravings and decreases the pleasurable effects of cigarettes and other tobacco products. Which of the following medications was most likely prescribed to the patient?

- A. Clonazepam (2%)
- ✗ B. Fluoxetine (5%)
- C. Nicotine patch (12%)
- D. Topiramate (5%)
- ✓ E. Varenicline (73%)

Incorrect
Correct answer
E

73%
Answered correctly

06 secs
Time Spent

2023
Version

Explanation



https://t.me/USMLEWorldStep1

Exhibit Display

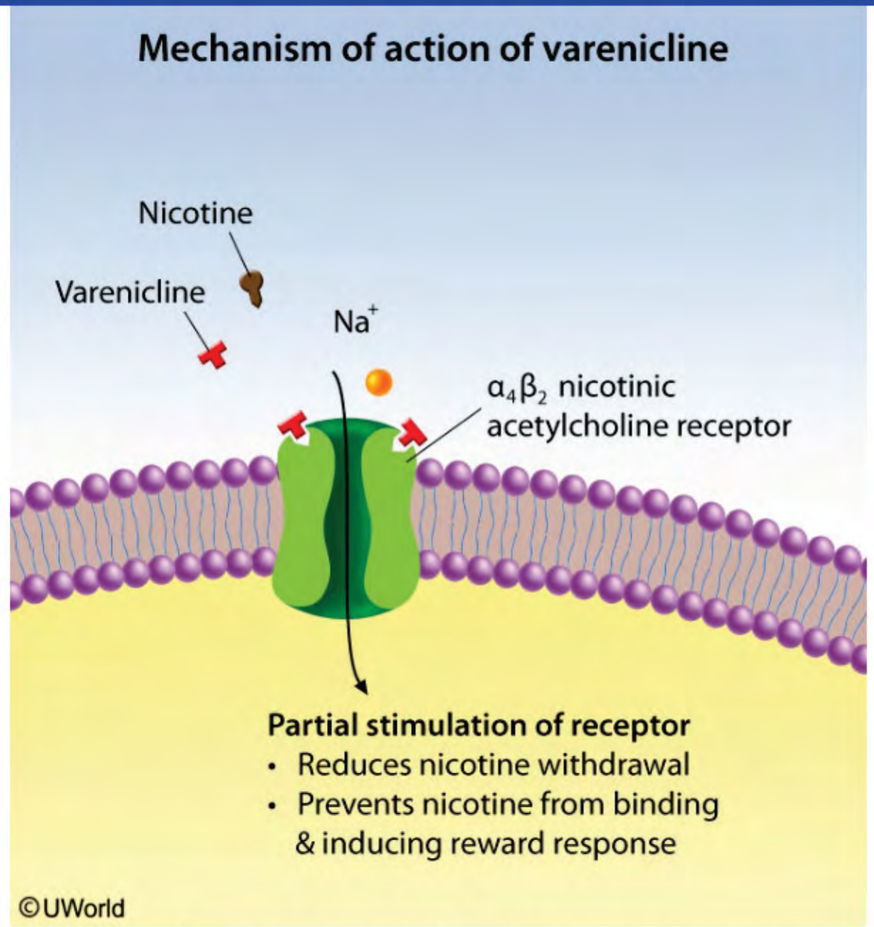

Zoom In | Zoom Out | Reset | New | Existing | My Notebook

Quitting smoking cigarettes is difficult due to nicotine content and its activation of reward pathways in the brain.

https://t.me/USMLEWorldStep1

©UWorld

Quitting smoking cigarettes is difficult due to nicotine content and its activation of reward pathways in the brain. The reinforcing effects of nicotine that lead to dependence are thought to be caused by stimulation of the alpha-4 beta-2 **nicotinic acetylcholine receptor** present in the CNS. **Varenicline** is a **partial agonist** of this receptor that competes with nicotine (a full agonist) and prevents it from binding to the receptor.

Because varenicline is a partial agonist, it helps **reduce** the symptoms of **nicotine withdrawal** by mildly stimulating the receptor. However, because varenicline is not a full agonist, downstream release of dopamine is modest, resulting in **less stimulation of reward pathways** than nicotine.

(Choices A and B) Benzodiazepines (eg, clonazepam) and selective serotonin reuptake inhibitors (eg, fluoxetine) have not been shown to be effective for smoking cessation.

(Choice C) Nicotine patches slowly release nicotine, thus preventing withdrawal symptoms when the patient stops using cigarettes. However, because nicotine is a full agonist (and does not partially block the receptor like varenicline does), patches do not prevent the pleasurable effects of additional nicotine received by smoking cigarettes.

(Choice D) Topiramate is an anticonvulsant used to treat epilepsy, and it is also effective for migraine prophylaxis. Several studies have tested the effectiveness of topiramate for smoking cessation; however, the current evidence shows little or no significant difference in long-term tobacco abstinence over placebo.

Educational objective:
Varenicline is a partial agonist of nicotinic acetylcholine receptors. It can help patients stop using tobacco by reducing withdrawal symptoms and attenuating the rewarding effects of nicotine.

References

- Varenicline: mode of action, efficacy, safety and accumulated experience salient for clinical populations.

Pharmacology	Pulmonary & Critical Care	Smoking Cessation
Subject	System	Topic

Copyright © UWorld. All rights reserved.

https://t.me/USMLEWorldStep1

A 56-year-old man comes to the office due to chronic cough and fatigue. The patient has smoked 2 packs of cigarettes daily since age 18. Physical examination shows cyanosis and expiratory wheezes scattered throughout the lungs. During evaluation for long-term oxygen therapy, his respiratory rate decreases shortly after he begins nasal cannular oxygen supplementation. This patient's reduced respiratory rate is most likely caused by a sudden decrease in stimulation of which of the following sensory receptors?

- A. Carotid bodies
- B. Central chemoreceptors
- C. Juxtaglomerular apparatus
- D. Pulmonary C fibers
- E. Pulmonary stretch receptors

Submit

https://t.me/USMLEWorldStep1

A 56-year-old man comes to the office due to chronic cough and fatigue. The patient has smoked 2 packs of cigarettes daily since age 18. Physical examination shows cyanosis and expiratory wheezes scattered throughout the lungs. During evaluation for long-term oxygen therapy, his respiratory rate decreases shortly after he begins nasal cannular oxygen supplementation. This patient's reduced respiratory rate is most likely caused by a sudden decrease in stimulation of which of the following sensory receptors?

- ✓ A. Carotid bodies (39%)
- ✗ B. Central chemoreceptors (50%)
- C. Juxtaglomerular apparatus (0%)
- D. Pulmonary C fibers (2%)
- E. Pulmonary stretch receptors (7%)

Incorrect
Correct answer
A

39%
Answered correctly

04 secs
Time Spent

2023
Version

Explanation

Baroreceptors & peripheral chemoreceptors

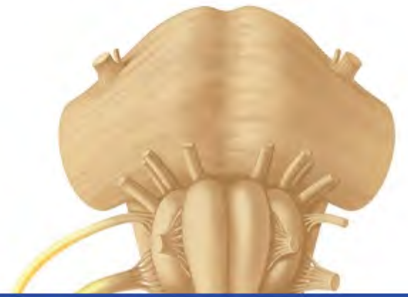

https://t.me/USMLEWorldStep1

D. Pulmonary C fibers (2%)

Exhibit Display

Baroreceptors & peripheral chemoreceptors

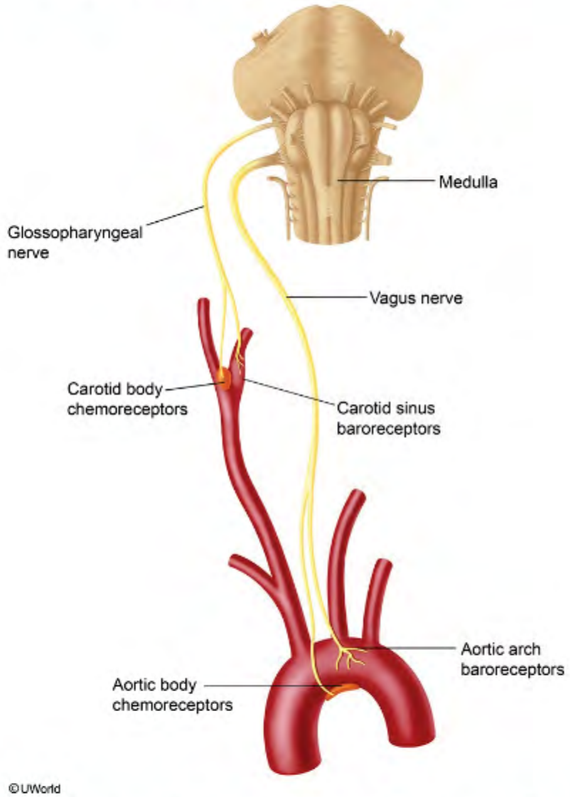

Zoom In | Zoom Out | Reset | New | Existing | My Notebook

https://t.me/USMLEWorldStep1

©UWorld

This patient with **chronic obstructive pulmonary disease** (COPD) developed a **decrease in respiratory rate** as a result of oxygen supplementation. Oxygen has a minimal effect on respiratory drive unless the arterial partial pressure of oxygen (PaO_2) drops below 60-70 mm Hg; therefore, the arterial partial pressure of carbon dioxide ($PaCO_2$) is the major stimulator of respiration in healthy individuals. However, patients with long-standing COPD have decreased sensitivity to $PaCO_2$ (due to chronic CO_2 retention) and may also have profound hypoxemia (PaO_2 <60 mm Hg); therefore, PaO_2 levels can become a significant contributor to respiratory drive.

The depth and rate of respirations are controlled by the medullary respiratory center based on input from central and peripheral chemoreceptors and airway mechanoreceptors. Peripheral chemoreceptors found in the **carotid and aortic bodies** are the primary sites for sensing PaO_2 and are stimulated by hypoxemia. When **supplemental oxygen** is administered, the rapid increase in PaO_2 can **reduce peripheral chemoreceptor stimulation** and decrease the respiratory rate.

Reduced respiratory rate is a minor contributor to the oxygen-induced hypercapnia that can occur in patients with COPD; increased ventilation-perfusion mismatch triggered by alleviation of pulmonary vasoconstriction in poorly ventilated areas is the major mechanism.

(Choice B) Central chemoreceptors, located in the medulla, are more involved in the respiratory response to hypercapnia than to hypoxemia. CO_2 readily diffuses through the blood-brain barrier and forms hydrogen ions in the cerebrospinal fluid; the resulting decrease in pH is detected by medullary neurons, triggering an increase in respiration. Because the blood-brain barrier is relatively impermeable to hydrogen ions, blood pH itself has little effect on central chemoreceptors.

(Choice C) The juxtaglomerular apparatus is located in the kidneys and consists of juxtaglomerular cells and the macula densa. It helps regulate renal blood flow and the glomerular filtration rate via renin secretion.

(Choices D and E) Pulmonary stretch receptors include myelinated and unmyelinated C fibers in the lungs and airways. These receptors regulate the duration of inspiration depending on the degree of lung distension (Hering-Breuer reflex).

Educational objective:

https://t.me/USMLEWorldStep1

<60 mm Hg); therefore, PaO_2 levels can become a significant contributor to respiratory drive.

The depth and rate of respirations are controlled by the medullary respiratory center based on input from central and peripheral chemoreceptors and airway mechanoreceptors. Peripheral chemoreceptors found in the **carotid and aortic bodies** are the primary sites for sensing PaO_2 and are stimulated by hypoxemia. When **supplemental oxygen** is administered, the rapid increase in PaO_2 can **reduce peripheral chemoreceptor stimulation** and decrease the respiratory rate.

Reduced respiratory rate is a minor contributor to the oxygen-induced hypercapnia that can occur in patients with COPD; increased ventilation-perfusion mismatch triggered by alleviation of pulmonary vasoconstriction in poorly ventilated areas is the major mechanism.

(Choice B) Central chemoreceptors, located in the medulla, are more involved in the respiratory response to hypercapnia than to hypoxemia. CO_2 readily diffuses through the blood-brain barrier and forms hydrogen ions in the cerebrospinal fluid; the resulting decrease in pH is detected by medullary neurons, triggering an increase in respiration. Because the blood-brain barrier is relatively impermeable to hydrogen ions, blood pH itself has little effect on central chemoreceptors.

(Choice C) The juxtaglomerular apparatus is located in the kidneys and consists of juxtaglomerular cells and the macula densa. It helps regulate renal blood flow and the glomerular filtration rate via renin secretion.

(Choices D and E) Pulmonary stretch receptors include myelinated and unmyelinated C fibers in the lungs and airways. These receptors regulate the duration of inspiration depending on the degree of lung distension (Hering-Breuer reflex).

Educational objective:
Arterial partial pressure of carbon dioxide ($PaCO_2$) is the major stimulator of respiration in healthy individuals; even a slight increase in $PaCO_2$ stimulates central chemoreceptors and triggers increased ventilation. In patients with chronic obstructive pulmonary disease, the response to $PaCO_2$ is blunted and hypoxemia can contribute to respiratory drive. Peripheral chemoreceptors are primarily responsible for sensing arterial partial pressure of oxygen (PaO_2) and can be suppressed with oxygen administration.

https://t.me/USMLEWorldStep1

©UWorld

This p
a resu
pressu
(PaCC
have c
<60 m

The de
and pe
and a
oxyge
decrea

Reduc
COPD
ventila

(Choi
hyperc
the ce
respira
effect

(Choi
macula

(Choi
airway
Breuer reflex).

Educational objective:

Exhibit Display

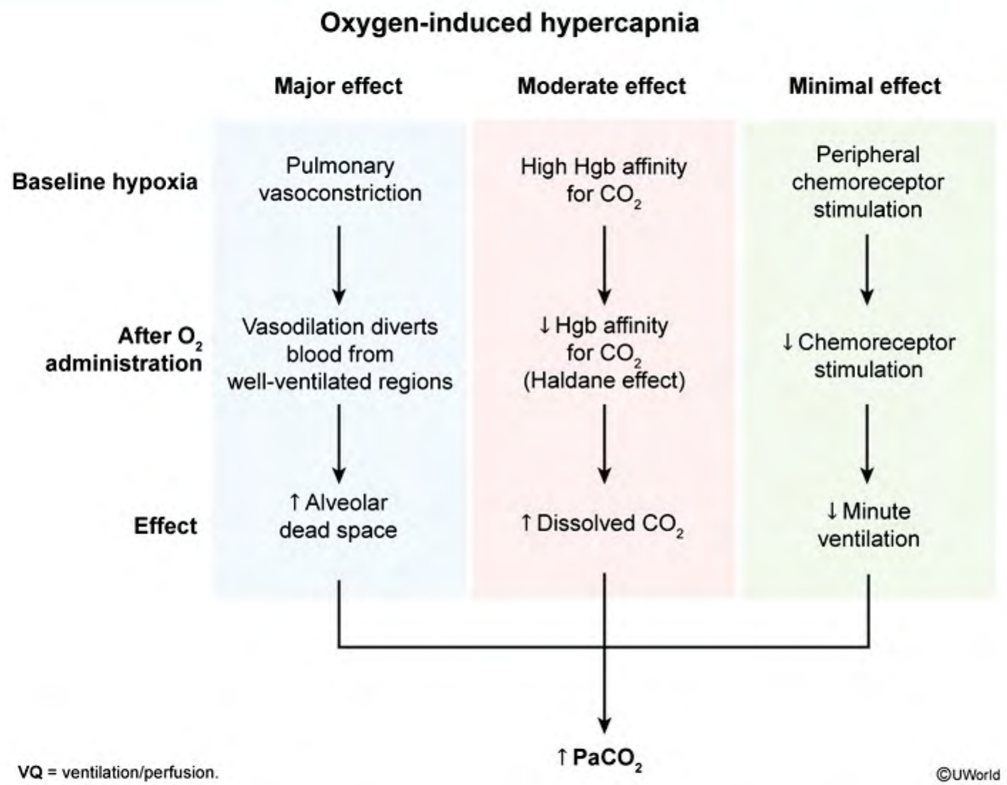

Zoom In | Zoom Out | Reset | New | Existing | My Notebook

https://t.me/USMLEWorldStep1

A 54-year-old man with HIV comes to the emergency department due to nonproductive cough, low-grade fevers, and worsening fatigue for the past month. He has also lost 3.6 kg (8 lb) over the same period. The patient does not take antiretroviral therapy consistently and has not followed up with his primary care physician for the past several months. Physical examination reveals hepatosplenomegaly. Laboratory testing shows pancytopenia and elevated liver aminotransferases. Bone marrow aspiration is performed, and light microscopy of the specimen is shown below.

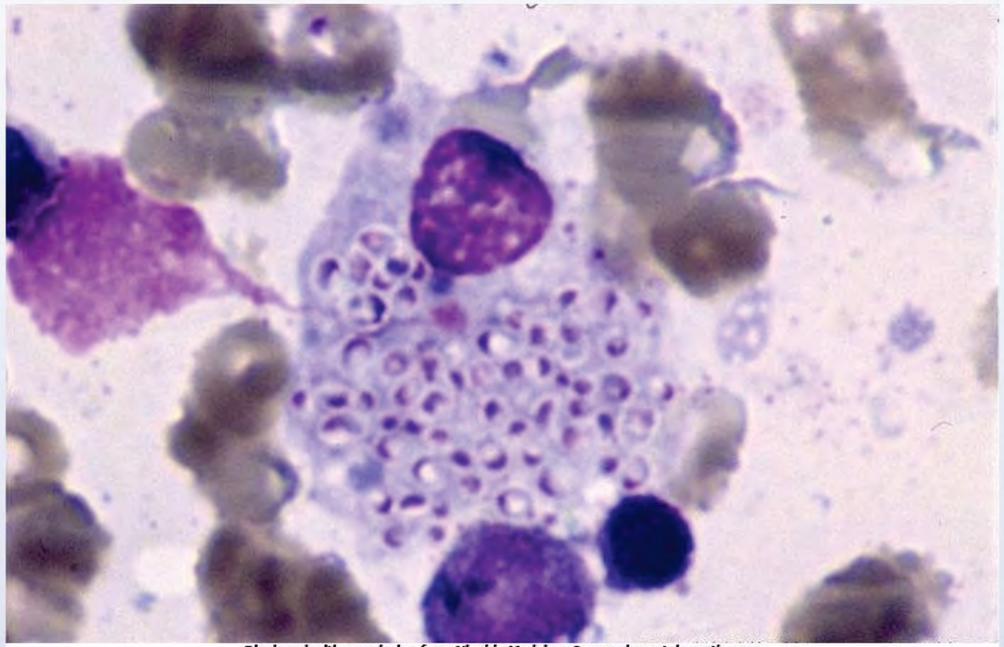

Displayed with permission from Nivaldo Medeiros © www.hematologyatlas.com

Which of the following is the most likely cause of this patient's current condition?

- A. *Aspergillus fumigatus*
- B. *Blastomyces dermatitidis*
- C. *Candida albicans*

https://t.me/USMLEWorldStep1

A 54-year-old man with HIV comes to the emergency department due to nonproductive cough, low-grade fevers,
and w
not tak
severa
elevat
shown

Exhibit Display

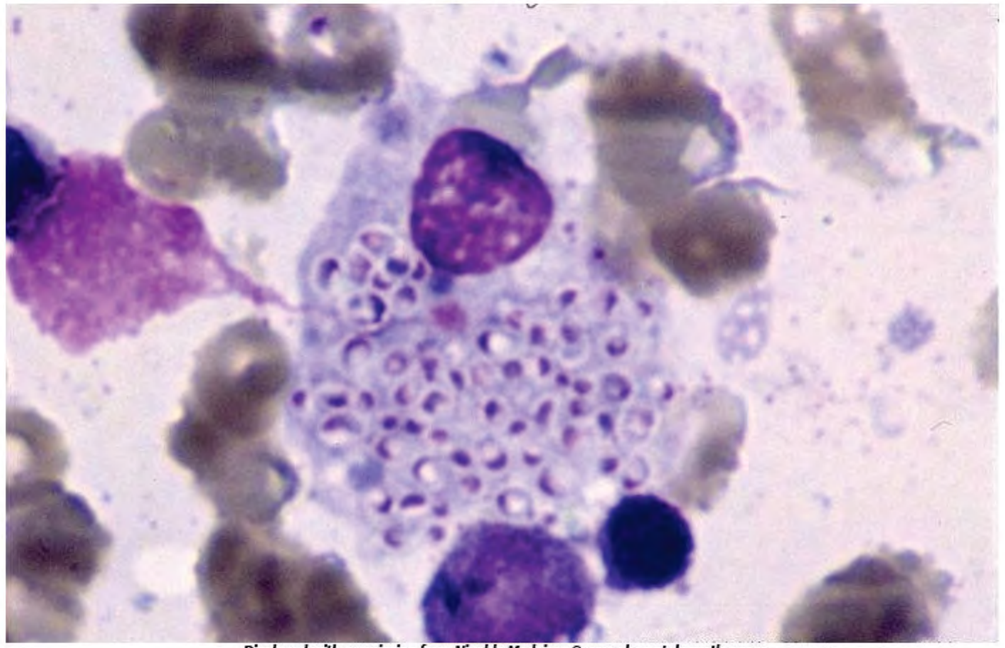

Displayed with permission from Nivaldo Medeiros © www.hematologyatlas.com

Zoom In Zoom Out Reset New | Existing My Notebook

Which

C. *Candida albicans*

https://t.me/USMLEWorldStep1

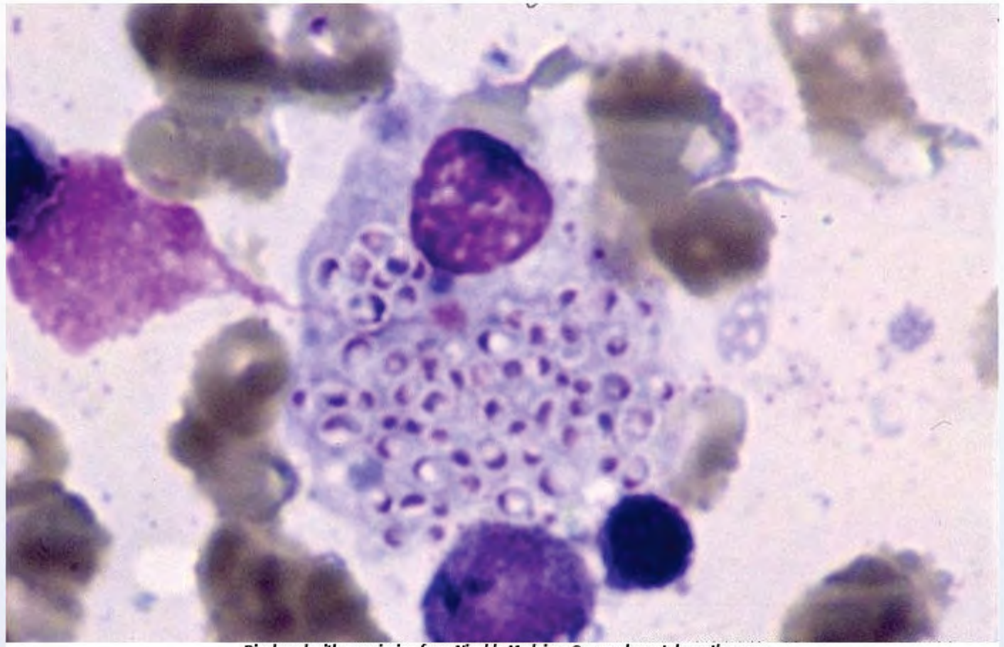

Displayed with permission from Nivaldo Medeiros © www.hematologyatlas.com

Which of the following is the most likely cause of this patient's current condition?

- A. *Aspergillus fumigatus*
- B. *Blastomyces dermatitidis*
- C. *Candida albicans*
- D. *Coccidioides immitis*
- E. *Cryptococcus neoformans*
- F. *Histoplasma capsulatum*

Submit

https://t.me/USMLEWorldStep1

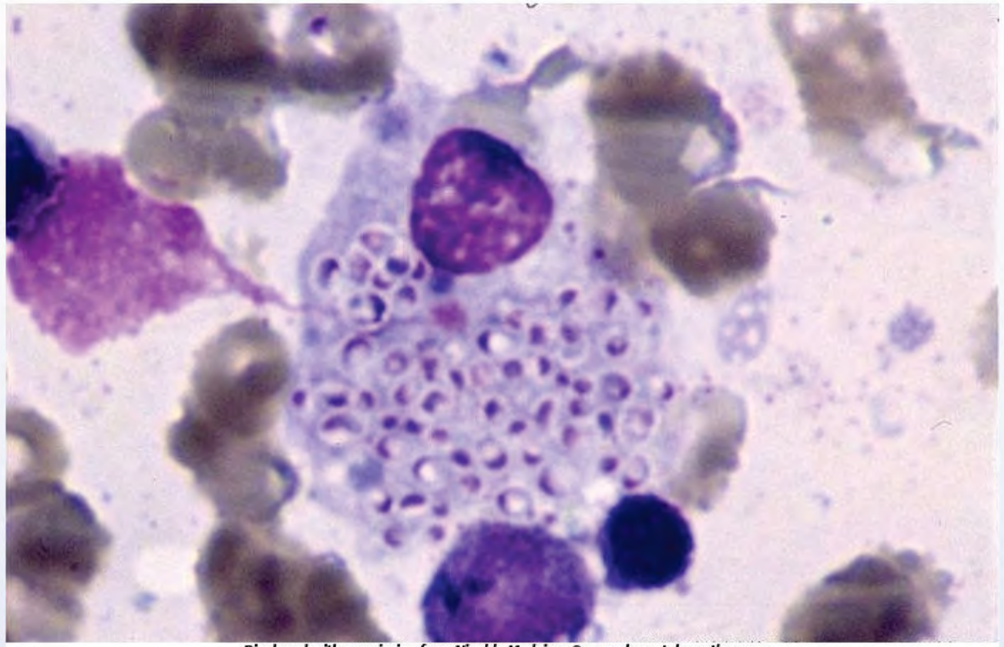

Which of the following is the most likely cause of this patient's current condition?

- A. *Aspergillus fumigatus* (4%)
- B. *Blastomyces dermatitidis* (3%)
- C. *Candida albicans* (0%)
- ✗ D. *Coccidioides immitis* (19%)
- E. *Cryptococcus neoformans* (8%)
- ✓ F. *Histoplasma capsulatum* (62%)

Incorrect
Correct answer
F

62%
Answered correctly

17 secs
Time Spent

2023
Version

https://t.me/USMLEWorldStep1

Explanation

Exhibit Display

Histoplasma capsulatum

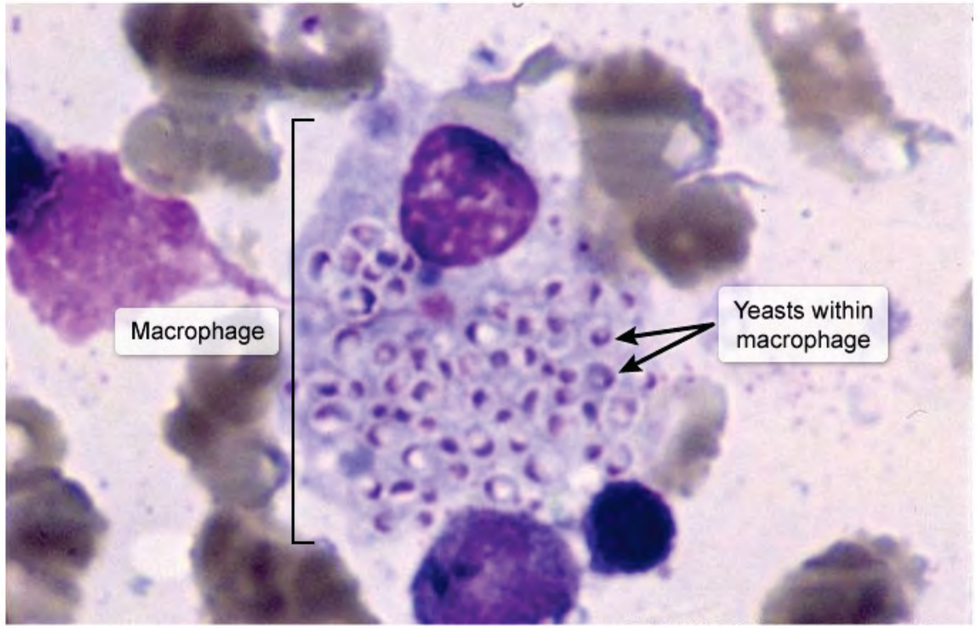

Displayed with permission from Nivaldo Medeiros © www.hematologyatlas.com

Zoom In | Zoom Out | Reset | New | Existing | My Notebook

Light r
Histop
lungs,
asymp
respor
the **ret**
manife
tongue are also very characteristic of disseminated histoplasmosis.

Disseminated infection is often diagnosed when histopathology shows oval or round **yeasts within**

https://t.me/USMLEWorldStep1

Light microscopy reveals several small, ovoid bodies within a macrophage, raising strong suspicion for ***Histoplasma capsulatum***. This dimorphic fungus is transmitted by inhalation, converts to a yeast form in the lungs, and replicates within the phagosome of macrophages. Patients with intact immunity usually have an asymptomatic or self-limited pulmonary infection that is contained over time by the cell-mediated immune response. However, those with **impaired immunity** (eg, advanced AIDS) are at risk for **dissemination** through the **reticuloendothelial system** due to the organism's affinity for mononuclear phagocytic cells. Common manifestations include hepatosplenomegaly, lymphadenopathy, and pancytopenia. Ulcerated lesions on the tongue are also very characteristic of disseminated histoplasmosis.

Disseminated infection is often diagnosed when histopathology shows oval or round **yeasts within macrophages**. Culture on Sabouraud agar grows hyphae (*Histoplasma* is a mold at cooler temperatures). *Histoplasma* antigen in blood and urine can also be detected by immunoassay.

(Choice A) *Aspergillus fumigatus* is a monomorphic fungus with only a mold form. It is seen in tissue as septate hyphae with acute-angle V-shaped branching.

(Choices B and D) Both *Blastomyces* and *Coccidioides* are dimorphic fungi that are inhaled into the lungs and replicate within macrophages. However, *Blastomyces* is a large yeast with thick walls and broad-based buds that disseminates primarily to the skin (not the reticuloendothelial system), and *Coccidioides immitis* appears as large, thick-walled spherules containing endospores.

(Choice C) *Candida albicans* is an ovoid yeast that forms pseudohyphae. Mucocutaneous *Candida* infections (eg, thrush) are common in patients with HIV, but invasive infections (eg, pneumonia) are rare. In addition, *Candida* is an extracellular pathogen.

(Choice E) *Cryptococcus neoformans* is a large yeast with a thick polysaccharide capsule. It can replicate within macrophages and cause pulmonary infection in patients with advanced AIDS. However, dissemination usually leads to meningoencephalitis (eg, slowly worsening headache, confusion, neurologic symptoms), not hepatosplenomegaly and pancytopenia.

Educational objective:
Histoplasma capsulatum is a dimorphic fungus that exists as a small, ovoid yeast at tissue temperatures. It

https://t.me/USMLEWorldStep1

asymptomatic or self-limited pulmonary infection that is contained over time by the cell-mediated immune response. However, those with **impaired immunity** (eg, advanced AIDS) are at risk for **dissemination** through the **reticuloendothelial system** due to the organism's affinity for mononuclear phagocytic cells. Common manifestations include hepatosplenomegaly, lymphadenopathy, and pancytopenia. Ulcerated lesions on the tongue are also very characteristic of disseminated histoplasmosis.

Disseminated infection is often diagnosed when histopathology shows oval or round **yeasts within macrophages**. Culture on Sabouraud agar grows hyphae (*Histoplasma* is a mold at cooler temperatures). *Histoplasma* antigen in blood and urine can also be detected by immunoassay.

(Choice A) *Aspergillus fumigatus* is a monomorphic fungus with only a mold form. It is seen in tissue as septate hyphae with acute-angle V-shaped branching.

(Choices B and D) Both *Blastomyces* and *Coccidioides* are dimorphic fungi that are inhaled into the lungs and replicate within macrophages. However, *Blastomyces* is a large yeast with thick walls and broad-based buds that disseminates primarily to the skin (not the reticuloendothelial system), and *Coccidioides immitis* appears as large, thick-walled spherules containing endospores.

(Choice C) *Candida albicans* is an ovoid yeast that forms pseudohyphae. Mucocutaneous *Candida* infections (eg, thrush) are common in patients with HIV, but invasive infections (eg, pneumonia) are rare. In addition, *Candida* is an extracellular pathogen.

(Choice E) *Cryptococcus neoformans* is a large yeast with a thick polysaccharide capsule. It can replicate within macrophages and cause pulmonary infection in patients with advanced AIDS. However, dissemination usually leads to meningoencephalitis (eg, slowly worsening headache, confusion, neurologic symptoms), not hepatosplenomegaly and pancytopenia.

Educational objective:
Histoplasma capsulatum is a dimorphic fungus that exists as a small, ovoid yeast at tissue temperatures. It replicates within macrophages and spreads through the lymphatic and reticuloendothelial system. Immunocompetent patients usually have an asymptomatic pulmonary infection, but those who are immunocompromised (eg, advanced AIDS) can develop disseminated disease to the liver, spleen, and bone marrow.

https://t.me/USMLEWorldStep1

Light microscopy reveals several small, ovoid bodies within a macrophage, raising strong suspicion for

Histoplasma capsulatum. This dimorphic fungus is transmitted by inhalation, converts to a yeast form in the lungs, asymp respor the **ret** manife tongue

Disser **macro** *Histop*

(Choi hypha

(Choi replica dissen thick-v

(Choi (eg, th *Candi*

(Choi macro leads hepato

Educa

Histoplasma capsulatum is a dimorphic fungus that exists as a small, ovoid yeast at tissue temperatures. It replicates within macrophages and spreads through the lymphatic and reticuloendothelial system

Exhibit Display

Aspergillus

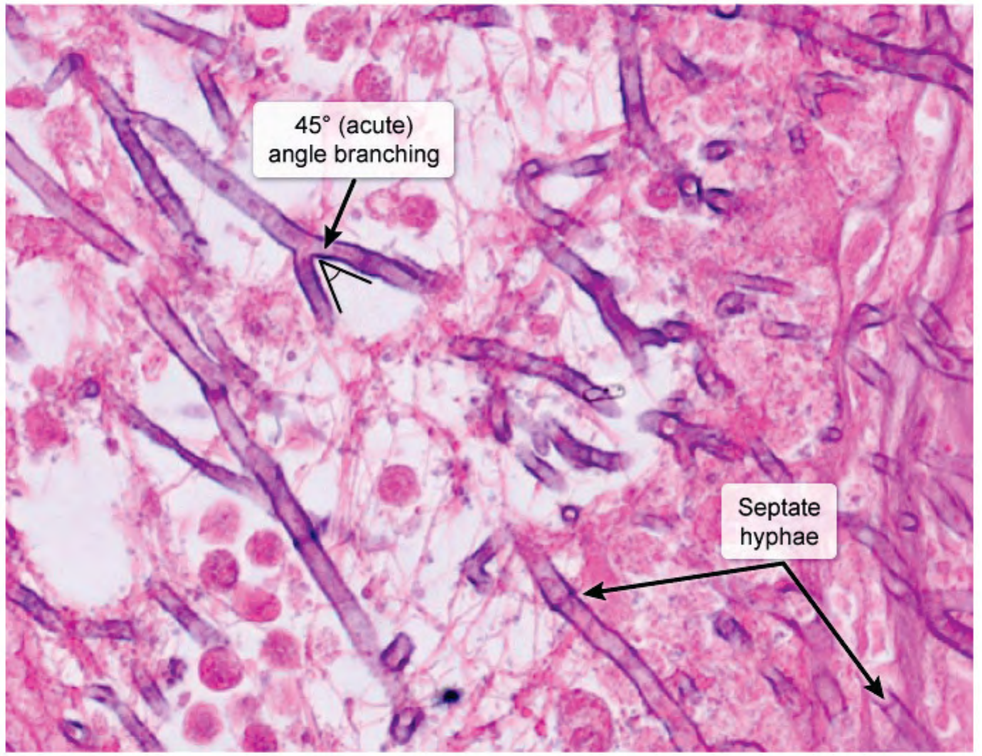

©UWorld

Zoom In | Zoom Out | Reset | New | Existing | My Notebook

https://t.me/USMLEWorldStep1

Light microscopy reveals several small, ovoid bodies within a macrophage, raising strong suspicion for

Histop

lungs,

asymp

respor

the **ret**

manife

tongue

Disser

macro

Histop

(Choi

hypha

(Choi

replica

dissen

thick-v

(Choi

(eg, th

Candi

(Choi

macro

leads

hepato

Exhibit Display

Blastomyces dermatitidis

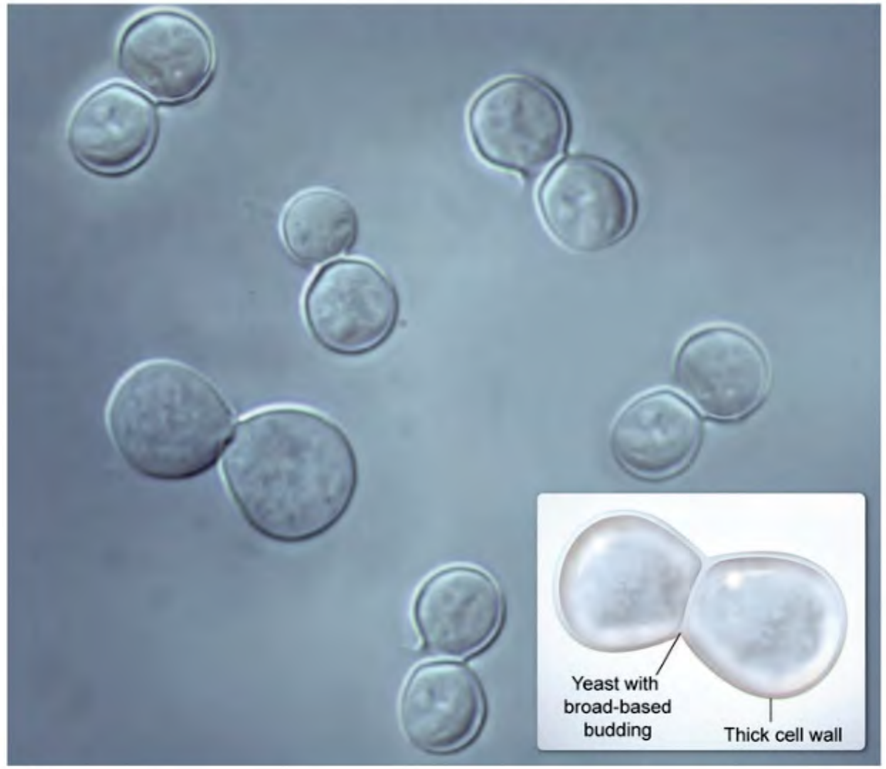

©UWorld

Zoom In | Zoom Out | Reset | New | Existing | My Notebook

Educational objective:

Histoplasma capsulatum is a dimorphic fungus that exists as a small, ovoid yeast at tissue temperatures. It replicates within macrophages and spreads through the lymphatic and reticuloendothelial system.

https://t.me/USMLEWorldStep1

Light microscopy reveals several small, ovoid bodies within a macrophage, raising strong suspicion for

Histoplasma capsulatum. This dimorphic fungus is transmitted by inhalation, converts to a yeast form in the lungs, asymp respor the **ret** manife tongue

Disser **macro** *Histop*

(Choi hypha

(Choi replica dissen thick-v

(Choi (eg, th *Candi*

(Choi macro leads hepato

Educa

Histoplasma capsulatum is a dimorphic fungus that exists as a small, ovoid yeast at tissue temperatures. It replicates within macrophages and spreads through the lymphatic and reticuloendothelial system

Exhibit Display

Coccidioides

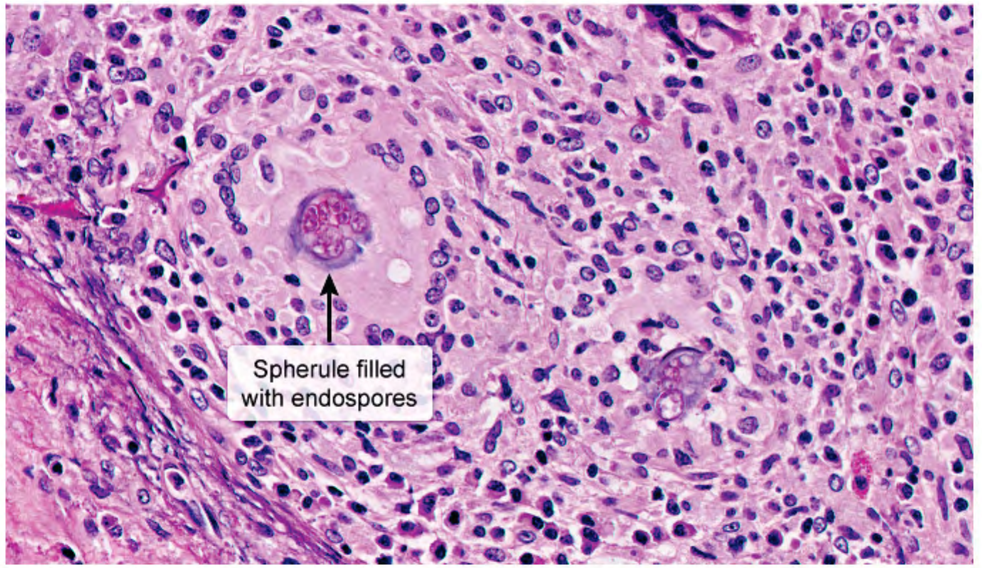

©UWorld

Zoom In | Zoom Out | Reset | New | Existing | My Notebook

https://t.me/USMLEWorldStep1

Light microscopy reveals several small, ovoid bodies within a macrophage, raising strong suspicion for

Histoplasma capsulatum. This dimorphic fungus is transmitted by inhalation, converts to a yeast form in the lungs, asymp respor the **ret** manife tongue

Disser **macro** *Histop*

(Choi hypha

(Choi replica dissen thick-v

(Choi (eg, th *Candi*

(Choi macro leads hepato

Educa

Histoplasma capsulatum is a dimorphic fungus that exists as a small, ovoid yeast at tissue temperatures. It replicates within macrophages and spreads through the lymphatic and reticuloendothelial system

Exhibit Display

Candidal esophagitis

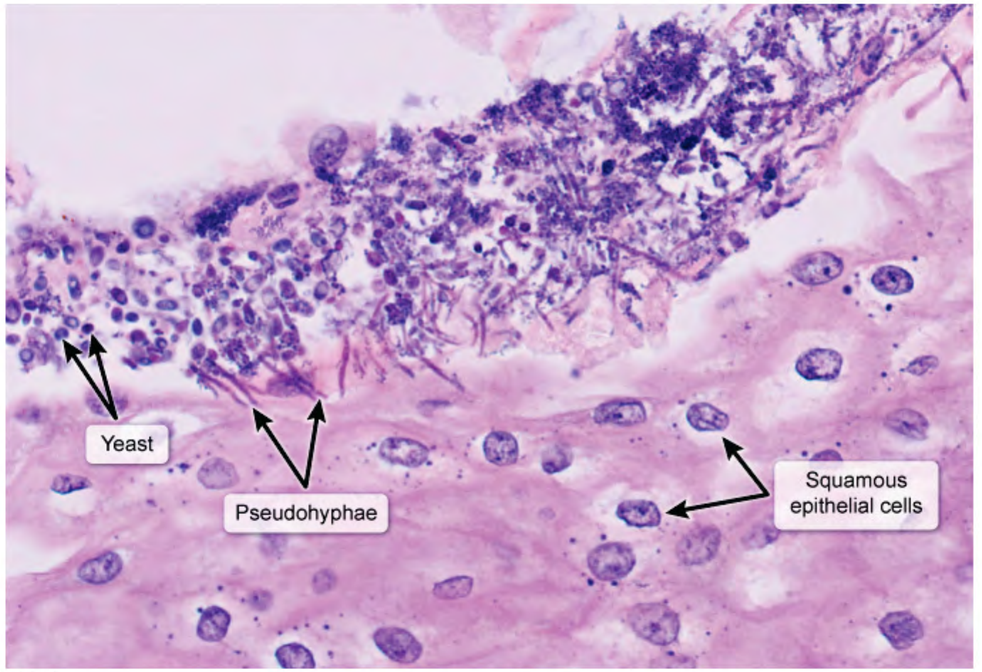

©UWorld

Zoom In | Zoom Out | Reset | New | Existing | My Notebook

https://t.me/USMLEWorldStep1

Light microscopy reveals several small, ovoid bodies within a macrophage, raising strong suspicion for

Histop

lungs,

asymp

respor

the **ret**

manife

tongue

Disser

macro

Histop

(Choi

hypha

(Choi

replica

dissen

thick-v

(Choi

(eg, th

Candi

(Choi

macro

leads

hepato

Educa

Histoplasma capsulatum is a dimorphic fungus that exists as a small, ovoid yeast at tissue temperatures. It replicates within macrophages and spreads through the lymphatic and reticuloendothelial system

Exhibit Display

Cryptococcus

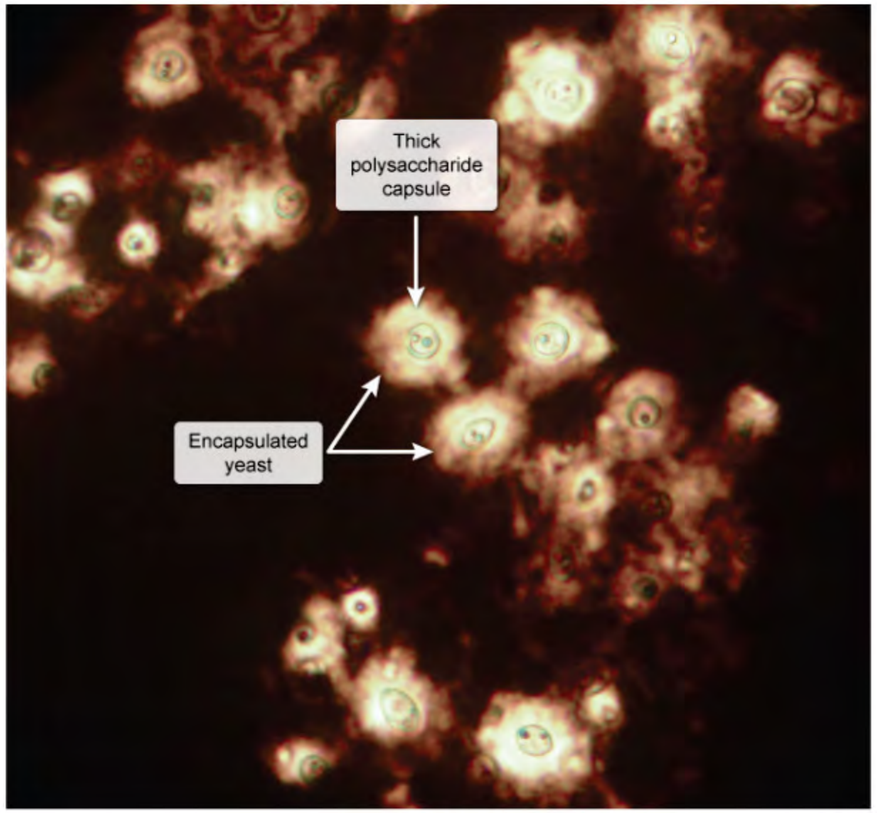

India ink stain

©UWorld

Zoom In | Zoom Out | Reset | New | Existing | My Notebook

https://t.me/USMLEWorldStep1

A 78-year-old man is brought to the emergency department due to fever, cough, and shortness of breath. The patient recently moved into an assisted living facility after living with his family that owned several pets. He has a 40-pack-year smoking history. Temperature is 39.4 C (103 F), blood pressure is 106/62 mm Hg, pulse is 112/min, and respirations are 28/min. There is dullness to percussion and bronchial breath sounds over the left lung. Chest x-ray reveals a left lower lobe consolidation. Sputum microscopy shows gram-positive diplococci. Which of the following would have been most helpful in preventing this patient's lung infection?

- A. Avoidance of exposure to bird droppings
- B. Immediate chemoprophylaxis after exposure
- C. Immunization with inactivated microbial agent
- D. Periodic culture and disinfection of water supply
- E. Vaccination with bacterial polysaccharide

Submit

https://t.me/USMLEWorldStep1

A 78-year-old man is brought to the emergency department due to fever, cough, and shortness of breath. The patient recently moved into an assisted living facility after living with his family that owned several pets. He has a 40-pack-year smoking history. Temperature is 39.4 C (103 F), blood pressure is 106/62 mm Hg, pulse is 112/min, and respirations are 28/min. There is dullness to percussion and bronchial breath sounds over the left lung. Chest x-ray reveals a left lower lobe consolidation. Sputum microscopy shows gram-positive diplococci. Which of the following would have been most helpful in preventing this patient's lung infection?

- A. Avoidance of exposure to bird droppings (4%)
- ✗ B. Immediate chemoprophylaxis after exposure (3%)
- C. Immunization with inactivated microbial agent (11%)
- D. Periodic culture and disinfection of water supply (3%)
- ✓ E. Vaccination with bacterial polysaccharide (76%)

Incorrect
Correct answer
E

76%
Answered correctly

03 secs
Time Spent

2023
Version

Explanation

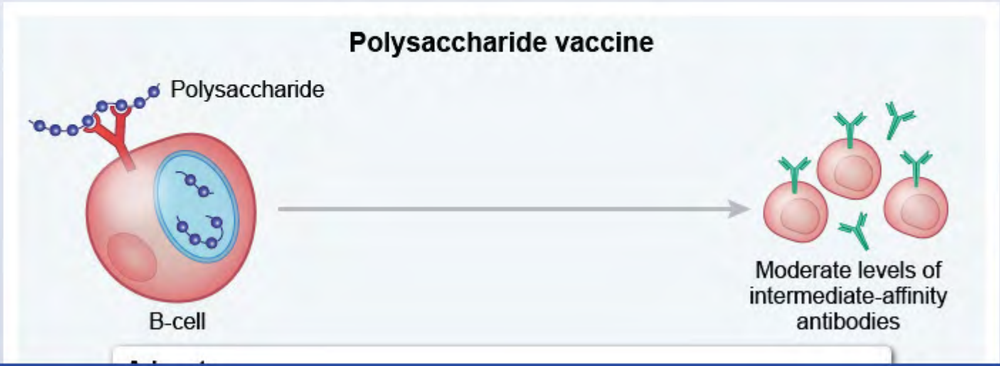

https://t.me/USMLEWorldStep1

Exhibit Display

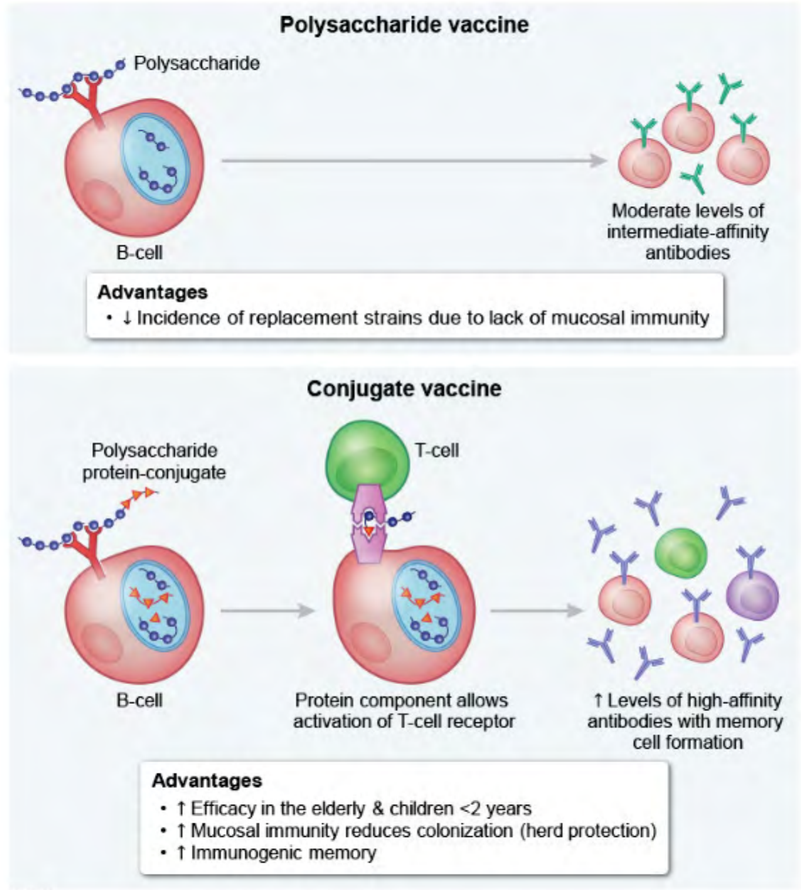

Zoom In | Zoom Out | Reset | New | Existing | My Notebook

• ↑ Mucosal immunity reduces colonization (herd protection)
• ↑ Immunogenic memory

https://t.me/USMLEWorldStep1

This patient with fever, pulmonary symptoms, and a lobar consolidation on chest x-ray has **pneumonia**. The presence of gram-positive diplococci in the sputum indicates the underlying pathogen is ***Streptococcus pneumoniae***, the leading cause of community-acquired pneumonia. Over 90 strains of *S pneumoniae* have been identified; they are distinguished based on antigenic variations in the **capsular polysaccharide**, the major virulence factor of the bacteria. Antibodies against the polysaccharide capsule are generated during infection and provide long-lasting immunity against that strain.

The pneumococcal vaccine contains polysaccharide antigens from the most common disease-causing serotypes leading to the generation of protective antibodies against these strains. In the United States, 2 types of pneumococcal vaccinations are available:

1. **Pneumococcal polysaccharide vaccine** contains capsular material from 23 serotypes. Because polysaccharides cannot be displayed by the major histocompatibility complex of antigen-presenting cells (only peptides can), immunogenicity to this vaccine is T-cell independent and generates a mild antibody response with no memory cells. Although polysaccharide vaccines are fairly effective for most adult patients, they are not useful for infants (age <2).
2. **Pneumococcal conjugate vaccine** consists of capsular polysaccharides from 13 serotypes that have been covalently attached to recombinant, inactivated diphtheria toxin. Protein conjugation allows the polysaccharide to be displayed by the major histocompatibility complex and induces a much stronger immunogenic response that involves T-cell–mediated B-lymphocyte activation. This generates high- affinity IgG antibodies and memory B-cells and also creates mucosal IgA antibodies, which reduce colonization rates.

Pneumococcal vaccination significantly reduces the risk of invasive pneumococcal disease. Routine vaccination is recommended for all children as part of their childhood immunization series. Adults age >65 and those at high risk for invasive disease (eg, HIV, asplenia, other immunosuppressed states) should also be vaccinated.

(Choice A) Histoplasma is a fungal infection that is primarily transmitted by inhalation of particles from soil contaminated with bird or bat droppings. Diagnosis is usually made by urine or serum antigen testing, but yeasts can sometimes be identified on histology/culture using specialized stains.

(Choice B) Close contacts of patients who have pertussis should be given antibiotic chemoprophylaxis. Pertussis

https://t.me/USMLEWorldStep1

not useful for infants (age <2).

2. **Pneumococcal conjugate vaccine** consists of capsular polysaccharides from 13 serotypes that have been covalently attached to recombinant, inactivated diphtheria toxin. Protein conjugation allows the polysaccharide to be displayed by the major histocompatibility complex and induces a much stronger immunogenic response that involves T-cell–mediated B-lymphocyte activation. This generates high- affinity IgG antibodies and memory B-cells and also creates mucosal IgA antibodies, which reduce colonization rates.

Pneumococcal vaccination significantly reduces the risk of invasive pneumococcal disease. Routine vaccination is recommended for all children as part of their childhood immunization series. Adults age >65 and those at high risk for invasive disease (eg, HIV, asplenia, other immunosuppressed states) should also be vaccinated.

(Choice A) Histoplasma is a fungal infection that is primarily transmitted by inhalation of particles from soil contaminated with bird or bat droppings. Diagnosis is usually made by urine or serum antigen testing, but yeasts can sometimes be identified on histology/culture using specialized stains.

(Choice B) Close contacts of patients who have pertussis should be given antibiotic chemoprophylaxis. Pertussis is a gram-negative encapsulated coccobacillus; infected adults usually develop a few weeks of malaise and rhinorrhea followed by several weeks of severe, paroxysmal cough.

(Choice C) The influenza vaccine contains 3 or 4 strains of inactivated influenza virus. Influenza usually causes abrupt-onset fever, headache, myalgia, and malaise and would not appear on Gram stain.

(Choice D) *Legionella* is a common cause of atypical pneumonia and is usually transmitted by contaminated water systems. However, *Legionella* is a gram-negative bacterium (not a gram-positive diplococcus) and is usually diagnosed with urine antigen testing.

Educational objective:
Streptococcus pneumoniae vaccination reduces the risk of invasive disease and is recommended for young patients and the elderly. The pneumococcal polysaccharide vaccine is an unconjugated vaccine that induces a T-cell–independent humoral immune response. In contrast, the pneumococcal conjugate vaccine contains polysaccharide material attached to a protein antigen, which creates a robust T-cell–mediated humoral immune response.

https://t.me/USMLEWorldStep1

This patient with fever, pulmonary symptoms, and a lobar consolidation on chest x-ray has **pneumonia**. The presence of gram-positive diplococci in the sputum indicates the underlying pathogen is ***Streptococcus pneumoniae***, the leading cause of community-acquired pneumonia. Over 90 strains of *S pneumoniae* have been identified; they are distinguished based on antigenic variations in the **capsular polysaccharide**, the major virulence factor of the bacteria. Antibodies against the polysaccharide capsule are generated during infection and provide long-lasting immunity against that strain.

The pneumococcal vaccine contains polysaccharide antigens from the most common disease-causing serotypes leading to the generation of protective antibodies against these strains. In the United States, 2 types of pneumococcal vaccinations are available:

1. **Pneumococcal polysaccharide vaccine** contains capsular material from 23 serotypes. Because polysaccharides cannot be displayed by the major histocompatibility complex of antigen-presenting cells (only peptides can), immunogenicity to this vaccine is T-cell independent and generates a mild antibody response with no memory cells. Although polysaccharide vaccines are fairly effective for most adult patients, they are not useful for infants (age <2).
2. **Pneumococcal conjugate vaccine** consists of capsular polysaccharides from 13 serotypes that have been covalently attached to recombinant, inactivated diphtheria toxin. Protein conjugation allows the polysaccharide to be displayed by the major histocompatibility complex and induces a much stronger immunogenic response that involves T-cell–mediated B-lymphocyte activation. This generates high- affinity IgG antibodies and memory B-cells and also creates mucosal IgA antibodies, which reduce colonization rates.

Pneumococcal vaccination significantly reduces the risk of invasive pneumococcal disease. Routine vaccination is recommended for all children as part of their childhood immunization series. Adults age >65 and those at high risk for invasive disease (eg, HIV, asplenia, other immunosuppressed states) should also be vaccinated.

(Choice A) Histoplasma is a fungal infection that is primarily transmitted by inhalation of particles from soil contaminated with bird or bat droppings. Diagnosis is usually made by urine or serum antigen testing, but yeasts can sometimes be identified on histology/culture using specialized stains.

(Choice B) Close contacts of patients who have pertussis should be given antibiotic chemoprophylaxis. Pertussis is a gram-negative encapsulated coccobacillus; infected adults usually develop a few weeks of malaise and

https://t.me/USMLEWorldStep1

A 25-year-old man with cystic fibrosis comes to the clinic for a routine follow-up appointment. The patient has had multiple hospital admissions over the last few years for pulmonary exacerbations. Pulmonary function testing today will most likely reveal which of the following results?

	TLC	FEV1/FVC	FVC	RV
A.	↓	↓	normal	↑
B.	↓	↑	↓	↓
C.	↑	↓	↓	↓
D.	↑	↓	↓	↑
E.	↑	normal	↑	normal

Submit

https://t.me/USMLEWorldStep1

A 25-year-old man with cystic fibrosis comes to the clinic for a routine follow-up appointment. The patient has had multiple hospital admissions over the last few years for pulmonary exacerbations. Pulmonary function testing today will most likely reveal which of the following results?

	TLC	FEV1/FVC	FVC	RV	
A.	↓	↓	normal	↑	(9%)
✗ B.	↓	↑	↓	↓	(25%)
C.	↑	↓	↓	↓	(3%)
✓ D.	↑	↓	↓	↑	(59%)
E.	↑	normal	↑	normal	(2%)

Incorrect
Correct answer
D

59%
Answered correctly

04 secs
Time Spent

2023
Version

Explanation

Pulmonary function tests						
Type	**Normal**	**Obstructive lung disease**			**Restrictive lung disease**	
		Emphysema	*Chronic bronchitis*	*Asthma*	*Intrinsic*	*Extrinsic*
DLCO*	Normal	Normal to decreased	Normal	Normal to high	Decreased	Normal
FEV_1	> 80% (of predicted)	Decreased			Decreased	

https://t.me/USMLEWorldStep1

Pulmonary function tests						
Type	**Normal**	**Obstructive lung disease**			**Restrictive lung disease**	
		Emphysema	*Chronic bronchitis*	*Asthma*	*Intrinsic*	*Extrinsic*
DLCO*	Normal	Normal to decreased	Normal	Normal to high	Decreased	Normal
FEV_1	> 80% (of predicted)	Decreased			Decreased	
FEV_1/FVC	> 70%	Decreased			Normal to increased	
FVC	> 80% (of predicted)	Normal to decreased			Decreased	

*DLCO is directly proportional to alveolar surface area and solubility of the gas (eg, more blood volume). DLCO is inversely proportional to membrane thickness.
FEV_1 = forced expiratory volume in 1 second; **FVC** = forced vital capacity; **DLCO** = Diffusing capacity of lung for carbon monoxide.

Cystic fibrosis (CF) is an autosomal recessive disorder caused by a mutation (eg, ΔF508) in the gene encoding the CF transmembrane conductance regulator. A defect in this chloride channel results in the build-up of thick, dehydrated mucus, which causes progressive damage to various organ systems, such as the respiratory and gastrointestinal tracts.

The lungs are the predominant organ affected in CF due to the accumulation of viscous secretions in the airways. Bacteria colonize the airways and cause recurrent infection and chronic inflammation that eventually leads to scarring of the bronchial walls (ie, bronchiectasis). Progressive **bronchiectasis** (ie, weakened, dilated bronchioles that collapse easily) and **mucus-plugging** result in **obstructive lung disease**.

An obstructive pattern on spirometry is characterized by **decreased** forced expiratory volume in 1 second (**FEV1**)

https://t.me/USMLEWorldStep1

FEV_1 = forced expiratory volume in 1 second; **FVC** = forced vital capacity; **DLCO** = Diffusing capacity of lung for carbon monoxide.

Cystic fibrosis (CF) is an autosomal recessive disorder caused by a mutation (eg, ΔF508) in the gene encoding the CF transmembrane conductance regulator. A defect in this chloride channel results in the build-up of thick, dehydrated mucus, which causes progressive damage to various organ systems, such as the respiratory and gastrointestinal tracts.

The lungs are the predominant organ affected in CF due to the accumulation of viscous secretions in the airways. Bacteria colonize the airways and cause recurrent infection and chronic inflammation that eventually leads to scarring of the bronchial walls (ie, bronchiectasis). Progressive **bronchiectasis** (ie, weakened, dilated bronchioles that collapse easily) and **mucus-plugging** result in **obstructive lung disease**.

An obstructive pattern on spirometry is characterized by **decreased** forced expiratory volume in 1 second (**FEV1**) and forced vital capacity (**FVC**). Because the decrease in FEV1 is more profound in obstructive disease, **FEV1/FVC ratio** is also **reduced**. The airway obstruction prevents full expiration (ie, causes air trapping), leading to **increased residual volume** (RV) and hyperinflated lungs with **increased total lung capacity** (TLC). This progressive increase is clinically apparent by a barrel-shaped chest on examination and lung hyperexpansion on x-ray.

(Choices A and C) As RV increases or decreases, TLC follows concordantly; therefore, these results are unlikely to represent a true clinical situation.

(Choice B) Restrictive lung disease (eg, pulmonary fibrosis) is characterized by a normal-to-increased FEV1/FVC ratio because FVC decreases to a greater extent than FEV1. RV and TLC are both decreased.

(Choice E) Normal RV with increased TLC can be seen in highly trained athletes due to increased FVC.

Educational objective:
Pulmonary function testing in cystic fibrosis reveals an obstructive pattern, characterized by a decreased FEV1/FVC ratio and an increased total lung capacity and residual volume.

Pathophysiology	Pulmonary & Critical Care	Cystic fibrosis
Subject	System	Topic

https://t.me/USMLEWorldStep1

FEV_1 = forced expiratory volume in 1 second; **FVC** = forced vital capacity; **DLCO** = Diffusing capacity of lung for carbon monoxide.

Exhibit Display

Cystic
the CF
dehyd
gastro

The lu
Bacter
scarrir
that co

An obs
and fo
FEV1/
to **incr**
progre
ray.

(Choi
to repr

(Choi
ratio b

(Choi

Educa
Pulmo
FEV1/

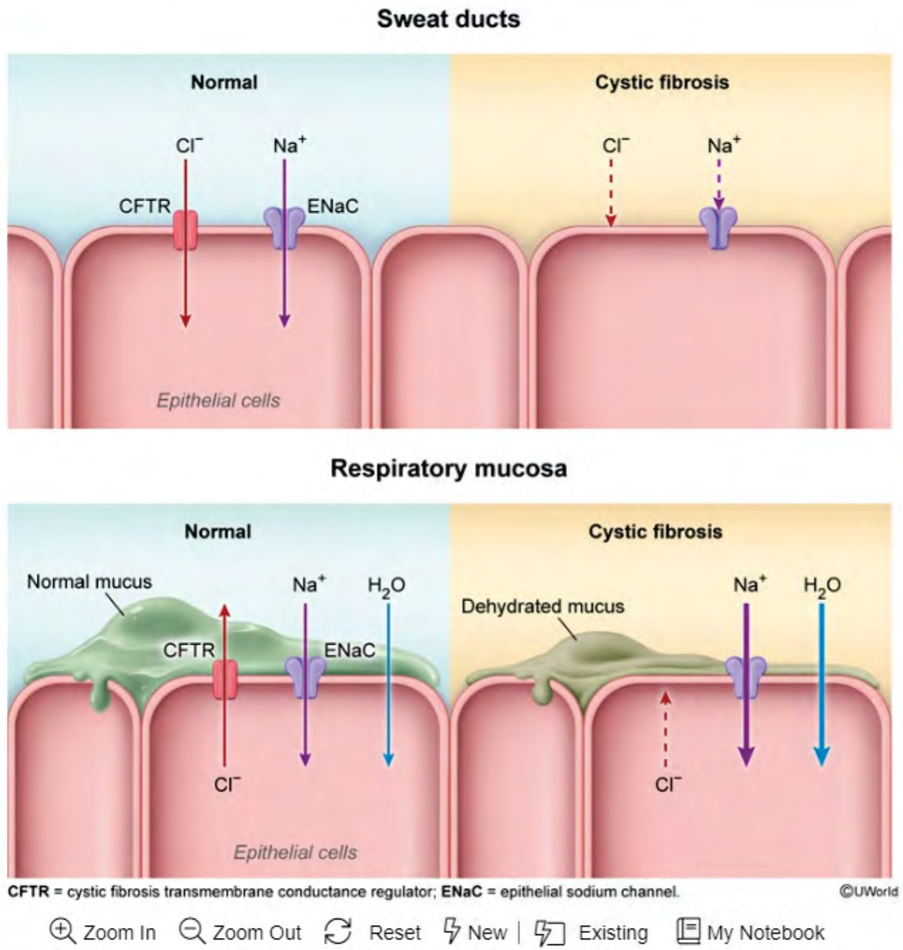

CFTR = cystic fibrosis transmembrane conductance regulator; **ENaC** = epithelial sodium channel.

©UWorld

Zoom In | Zoom Out | Reset | New | Existing | My Notebook

Pathophysiology
Subject

Pulmonary & Critical Care
System

Cystic fibrosis
Topic

https://t.me/USMLEWorldStep1

FEV_1 = forced expiratory volume in 1 second; **FVC** = forced vital capacity; **DLCO** = Diffusing capacity of lung for carbon monoxide

Exhibit Display

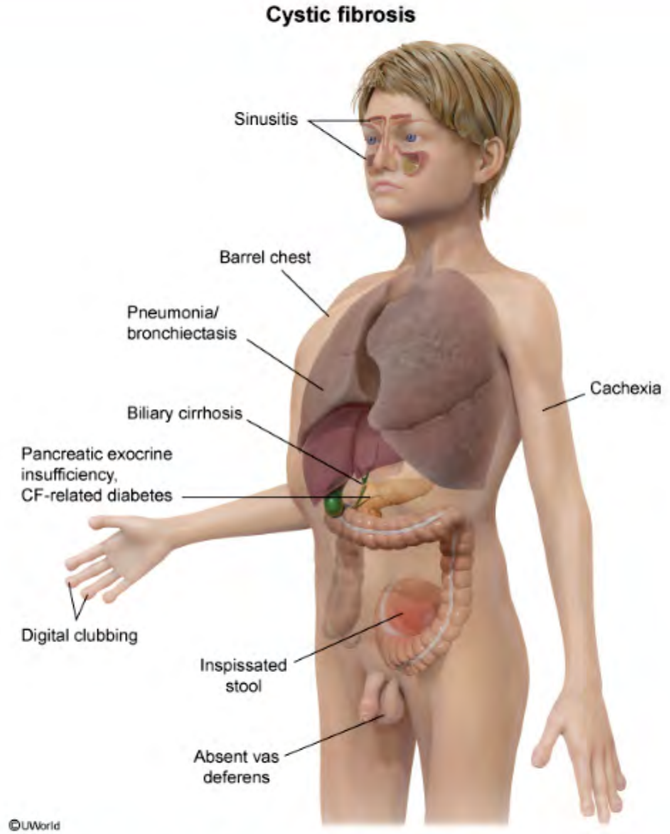

Zoom In | Zoom Out | Reset | New | Existing | My Notebook

Cystic
the CF
dehyd
gastro

The lu
Bacter
scarrin
that co

An obs
and fo
FEV1/
to **incr**
progre
ray.

(Choic
to repr

(Choic
ratio b

(Choic

Educa
Pulmo
FEV1/FVC ratio and an increased total lung capacity and residual volume.

Pathophysiology	Pulmonary & Critical Care	Cystic fibrosis
Subject	System	Topic

https://t.me/USMLEWorldStep1

FEV_1 = forced expiratory volume in 1 second; **FVC** = forced vital capacity; **DLCO** = Diffusing capacity of lung for carbon monoxide.

Exhibit Display

Cystic
the CF
dehyd
gastro

The lu
Bacter
scarrir
that co

An obs
and fo
FEV1/
to **incr**
progre
ray.

(Choic
to repr

(Choic
ratio b

(Choic

Educa
Pulmo
FEV1/

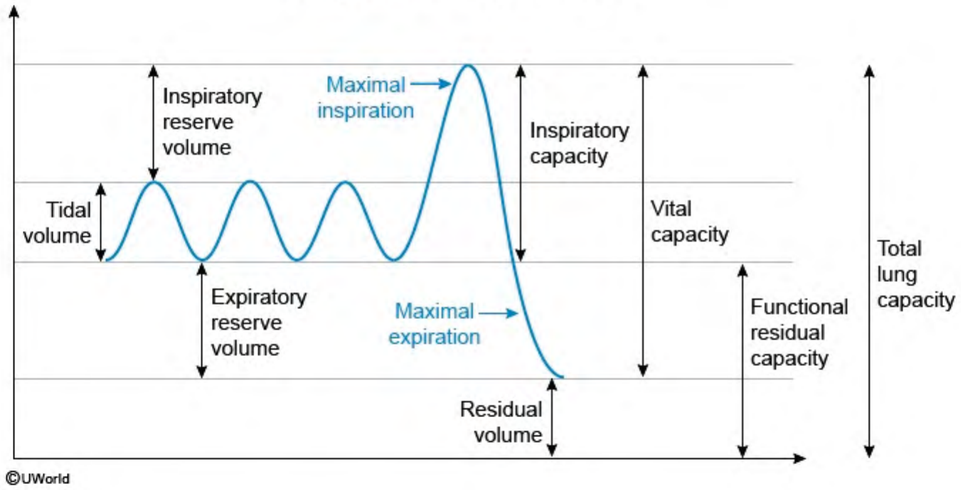

Zoom In | Zoom Out | Reset | New | Existing | My Notebook

Pathophysiology
Subject
Pulmonary & Critical Care
System
Cystic fibrosis
Topic

https://t.me/USMLEWorldStep1

A 3-year-old boy is brought to the emergency department with breathing difficulty and drooling that have worsened rapidly over the last 8 hours. He has no chronic medical conditions. Temperature is 39.4 C (102.9 F). Examination shows a toxic-appearing patient leaning forward while sitting on the bed; he has inspiratory stridor and suprasternal retractions. There are pooled oral secretions, and the patient is unable to swallow. Which of the following is the greatest risk factor for this patient's condition?

- A. Foreign body aspiration
- B. History of food allergy
- C. Incomplete vaccination series
- D. Recent international travel
- E. Secondhand smoke exposure

Submit

https://t.me/USMLEWorldStep1

A 3-year-old boy is brought to the emergency department with breathing difficulty and drooling that have worsened rapidly over the last 8 hours. He has no chronic medical conditions. Temperature is 39.4 C (102.9 F). Examination shows a toxic-appearing patient leaning forward while sitting on the bed; he has inspiratory stridor and suprasternal retractions. There are pooled oral secretions, and the patient is unable to swallow. Which of the following is the greatest risk factor for this patient's condition?

- A. Foreign body aspiration (11%)
- ✗ B. History of food allergy (4%)
- ✓ C. Incomplete vaccination series (80%)
- D. Recent international travel (1%)
- E. Secondhand smoke exposure (2%)

Incorrect
Correct answer
C

80%
Answered correctly

04 secs
Time Spent

2023
Version

Explanation

Epiglottitis	
Microbiology	• *Haemophilus influenzae* type b (Hib)
Clinical features	• Distress (tripod position, sniffing position, stridor) • Dysphagia, dysphonia • Drooling • High fever
X-ray	• "Thumb sign" (enlarged epiglottis)
	• Endotracheal intubation

https://t.me/USMLEWorldStep1

Epiglottitis	
Microbiology	• *Haemophilus influenzae* type b (Hib)
Clinical features	• Distress (tripod position, sniffing position, stridor) • Dysphagia, dysphonia • Drooling • High fever
X-ray	• "Thumb sign" (enlarged epiglottis)
Management	• Endotracheal intubation • Antibiotics
Prevention	• Immunization against Hib

This ill-appearing patient likely has epiglottitis, a **rapidly progressive**, life-threatening infection that classically presents with high **fever**, **dysphagia**, and **drooling** (often with pooled oral secretions) in young children. Older children and adults may initially have severe sore throat. Narrowing of the larynx causes signs of respiratory distress (eg, retractions) with inspiratory **stridor**, and patients classically assume tripod positioning (ie, leaning forward with the neck extended) to maximize airflow.

***Haemophilus influenzae* type b** (Hib) was historically the most common pathogen that caused epiglottitis, but routine immunization in infancy has greatly decreased its incidence. Individuals with **incomplete vaccination** against Hib remain at **greatest risk** of developing epiglottitis. Pathogens implicated in immunized children more commonly include nontypeable *H influenzae* and *Streptococcus pneumoniae*, in addition to rare cases of Hib.

(Choice A) A foreign body obstructing the larynx or trachea can present with stridor and acute respiratory distress. However, fever and pooled oral secretions would not be expected.

(Choice B) Anaphylaxis, triggered by IgE-mediated mast cell degranulation, causes acute airway edema and respiratory distress, but other allergic symptoms (eg, hives, angioedema) are usually present. In addition, anaphylaxis does not cause fever.

https://t.me/USMLEWorldStep1

Prevention	• Immunization against Hib

This ill-appearing patient likely has epiglottitis, a **rapidly progressive**, life-threatening infection that classically presents with high **fever**, **dysphagia**, and **drooling** (often with pooled oral secretions) in young children. Older children and adults may initially have severe sore throat. Narrowing of the larynx causes signs of respiratory distress (eg, retractions) with inspiratory **stridor**, and patients classically assume tripod positioning (ie, leaning forward with the neck extended) to maximize airflow.

***Haemophilus influenzae* type b** (Hib) was historically the most common pathogen that caused epiglottitis, but routine immunization in infancy has greatly decreased its incidence. Individuals with **incomplete vaccination** against Hib remain at **greatest risk** of developing epiglottitis. Pathogens implicated in immunized children more commonly include nontypeable *H influenzae* and *Streptococcus pneumoniae*, in addition to rare cases of Hib.

(Choice A) A foreign body obstructing the larynx or trachea can present with stridor and acute respiratory distress. However, fever and pooled oral secretions would not be expected.

(Choice B) Anaphylaxis, triggered by IgE-mediated mast cell degranulation, causes acute airway edema and respiratory distress, but other allergic symptoms (eg, hives, angioedema) are usually present. In addition, anaphylaxis does not cause fever.

(Choice D) The incidence of epiglottitis is not increased with international travel in an immunocompetent, vaccinated child. Incomplete vaccination against Hib remains the greatest risk factor.

(Choice E) Secondhand smoke exposure is a risk factor for asthma, which can present with acute respiratory distress due to lower airway hyperreactivity and inflammation. Examination would reveal wheezing due to bronchoconstriction, not signs of upper airway obstruction (eg, stridor).

Educational objective:
Epiglottitis causes rapidly progressive airway obstruction and classically presents with fever, dysphagia, drooling, stridor, and tripod positioning. Individuals with incomplete immunization against *Haemophilus influenzae* type b are at greatest risk.

References

- Review of epiglottitis in the post Haemophilus influenzae type-b vaccine era

https://t.me/USMLEWorldStep1

Prevention	• Immunization against Hib

This ill
preser
childre
distres
forwar

Haem
routine
agains
comm

(Choi
distres

(Choi
respira
anaph

(Choi
vaccin

(Choi
distres
bronch

Educa
Epiglo
stridor
at grea

References

- Review of epiglottitis in the post Haemophilus influenzae type-b vaccine era

Exhibit Display

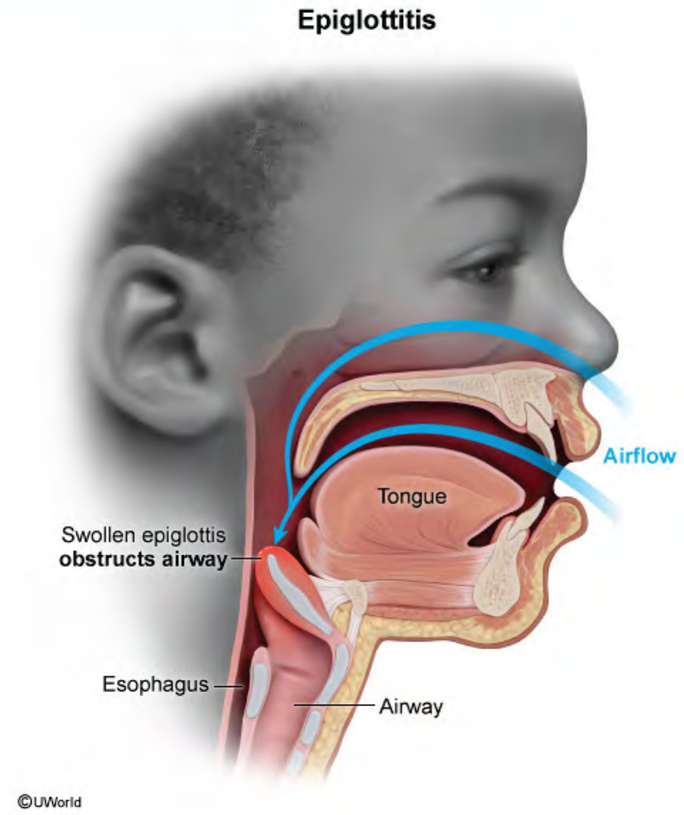

Zoom In | Zoom Out | Reset | New | Existing | My Notebook

https://t.me/USMLEWorldStep1

Prevention	• Immunization against Hib

This ill
preser
childre
distres
forwar

Haem
routine
agains
comm

(Choi
distres

(Choi
respira
anaph

(Choi
vaccin

(Choi
distres
bronch

Educa
Epiglo
stridor
at grea

References

- Review of epiglottitis in the post Haemophilus influenzae type-b vaccine era

Exhibit Display

Zoom In Zoom Out Reset New | Existing My Notebook

https://t.me/USMLEWorldStep1

A 78-year-old woman is brought to the hospital due to 2 days of nausea, vomiting, abdominal pain, and headache. She was recently hospitalized due to a stroke, and the hospitalization was complicated by a urinary tract infection and delirium. The patient has a history of chronic obstructive pulmonary disease and her treatment regimen includes theophylline. Temperature is 37 C (98.6 F), blood pressure is 110/70 mm Hg, pulse is 118/min, and respirations are 22/min. On physical examination, the patient appears agitated and restless. There is a coarse tremor of the outstretched arms. Chest auscultation reveals mild expiratory wheezing. Serum theophylline levels are markedly elevated. Treatment with which of the following agents most likely precipitated this patient's current symptoms?

- A. Amoxicillin
- B. Cephalexin
- C. Ciprofloxacin
- D. Haloperidol
- E. Nitrofurantoin

Submit

https://t.me/USMLEWorldStep1

A 78-year-old woman is brought to the hospital due to 2 days of nausea, vomiting, abdominal pain, and headache. She was recently hospitalized due to a stroke, and the hospitalization was complicated by a urinary tract infection and delirium. The patient has a history of chronic obstructive pulmonary disease and her treatment regimen includes theophylline. Temperature is 37 C (98.6 F), blood pressure is 110/70 mm Hg, pulse is 118/min, and respirations are 22/min. On physical examination, the patient appears agitated and restless. There is a coarse tremor of the outstretched arms. Chest auscultation reveals mild expiratory wheezing. Serum theophylline levels are markedly elevated. Treatment with which of the following agents most likely precipitated this patient's current symptoms?

- ✗ A. Amoxicillin (5%)
- B. Cephalexin (4%)
- ✓ C. Ciprofloxacin (57%)
- D. Haloperidol (16%)
- E. Nitrofurantoin (15%)

Incorrect
Correct answer
C

57%
Answered correctly

04 secs
Time Spent

2023
Version

Explanation

Cytochrome P450 (CYP450) interactions	
Inducers	**Inhibitors**
Alcohol (chronic use) Barbiturates (eg, phenobarbital) Carbamazepine	Alcohol (acute use) Amiodarone Azoles (eg, fluconazole)

https://t.me/USMLEWorldStep1

Explanation

Cytochrome P450 (CYP450) interactions	
Inducers	**Inhibitors**
Alcohol (chronic use) Barbiturates (eg, phenobarbital) Carbamazepine Griseofulvin Modafinil Phenytoin Rifampin St. John's wort	Alcohol (acute use) Amiodarone Azoles (eg, fluconazole) Cimetidine Diltiazem, verapamil Grapefruit juice Isoniazid, macrolides,* quinolones Protease inhibitors (eg, ritonavir) SSRIs (eg, fluoxetine)
Drugs commonly affected Antiepileptics, theophylline, warfarin	
SSRIs = selective serotonin reuptake inhibitors. *Except azithromycin.	

This patient was most likely treated with **ciprofloxacin** (a fluoroquinolone) for her urinary tract infection and experienced subsequent **theophylline toxicity**. Theophylline is an adenosine receptor antagonist and phosphodiesterase inhibitor that is sometimes used as an alternate therapy for asthma and chronic obstructive pulmonary disease. It causes bronchodilation primarily by increasing intracellular cyclic AMP levels (similar to beta-adrenergic agonists) and also has mild anti-inflammatory effects.

Theophylline is metabolized predominantly by **hepatic cytochrome oxidases**. **Inhibition** of these enzymes by concurrent illness (eg, infection with fever) or ingestion of certain drugs or substances (eg, ciprofloxacin) can **raise serum concentrations** and cause theophylline toxicity due to the drug's narrow therapeutic index. Toxicity presents with excessive CNS stimulation (eg, tremor, insomnia, **seizures**), gastrointestinal disturbances, and

https://t.me/USMLEWorldStep1

SSRIs = selective serotonin reuptake inhibitors.
*Except azithromycin.

This patient was most likely treated with **ciprofloxacin** (a fluoroquinolone) for her urinary tract infection and experienced subsequent **theophylline toxicity**. Theophylline is an adenosine receptor antagonist and phosphodiesterase inhibitor that is sometimes used as an alternate therapy for asthma and chronic obstructive pulmonary disease. It causes bronchodilation primarily by increasing intracellular cyclic AMP levels (similar to beta-adrenergic agonists) and also has mild anti-inflammatory effects.

Theophylline is metabolized predominantly by **hepatic cytochrome oxidases**. **Inhibition** of these enzymes by concurrent illness (eg, infection with fever) or ingestion of certain drugs or substances (eg, ciprofloxacin) can **raise serum concentrations** and cause theophylline toxicity due to the drug's narrow therapeutic index. Toxicity presents with excessive CNS stimulation (eg, tremor, insomnia, **seizures**), gastrointestinal disturbances, and cardiovascular abnormalities (eg, hypotension, tachycardia, **cardiac arrhythmias**).

(Choices A, B, and E) Amoxicillin and cephalexin are beta-lactams that inhibit bacterial cell wall synthesis. Nitrofurantoin inactivates or alters bacterial ribosomal proteins to inhibit protein and cell wall synthesis. These antibiotics do not interact significantly with the hepatic cytochrome oxidase system.

(Choice D) Haloperidol blocks postsynaptic dopamine (D2) receptors in the brain but does not interact significantly with theophylline to cause toxicity. Chronic haloperidol use can cause neuroleptic malignant syndrome presenting with fever, mental status changes, muscle rigidity, and autonomic instability.

Educational objective:
Theophylline is an adenosine receptor antagonist and indirect adrenergic agent with a narrow therapeutic index. It is predominantly metabolized by the hepatic cytochrome oxidases. Inhibition of these enzymes by concurrent illness (eg, infection with fever) or ingestion of certain drugs or substances (eg, ciprofloxacin) can raise serum theophylline concentrations and cause toxicity (eg, seizures, cardiac arrhythmias).

References

- Ciprofloxacin-induced theophylline toxicity: a population-based study.
- Pharmacokinetic drug interactions with theophylline.

https://t.me/USMLEWorldStep1

A 2-week-old girl is brought to the office for a weight check. She was born at 36 weeks gestation due to preterm labor. The patient has been gaining weight appropriately, and her parents have no concerns. When questioned about the home environment, the mother says that she started smoking cigarettes after delivery due to the stress of sleep deprivation. The mother did not smoke during pregnancy, and the father is a nonsmoker. Support is provided, and the mother is counseled regarding the risks of secondhand smoke exposure. Which of the following conditions is the patient at increased risk for developing due to this exposure?

- A. Apnea of prematurity
- B. Epilepsy
- C. Failure to thrive
- D. Sudden infant death syndrome
- E. Ventricular arrhythmia

Submit

https://t.me/USMLEWorldStep1

A 2-week-old girl is brought to the office for a weight check. She was born at 36 weeks gestation due to preterm labor. The patient has been gaining weight appropriately, and her parents have no concerns. When questioned about the home environment, the mother says that she started smoking cigarettes after delivery due to the stress of sleep deprivation. The mother did not smoke during pregnancy, and the father is a nonsmoker. Support is provided, and the mother is counseled regarding the risks of secondhand smoke exposure. Which of the following conditions is the patient at increased risk for developing due to this exposure?

- A. Apnea of prematurity (16%)
- B. Epilepsy (1%)
- ✗ C. Failure to thrive (13%)
- ✓ D. Sudden infant death syndrome (66%)
- E. Ventricular arrhythmia (1%)

Incorrect
Correct answer
D

66%
Answered correctly

03 secs
Time Spent

2023
Version

Explanation

Risks of secondhand smoke exposure in children	
Risks	**Pathophysiology**
Respiratory disease (eg, pneumonia, asthma)	• Impaired mucociliary clearance of respiratory tract • Impaired phagocytosis by alveolar macrophages • Immune & inflammatory cell recruitment to lung tissue
Recurrent otitis media	• Impaired mucociliary clearance of eustachian tube
Prematurity &	

https://t.me/USMLEWorldStep1

Risks of secondhand smoke exposure in children	
Risks	**Pathophysiology**
Respiratory disease (eg, pneumonia, asthma)	• Impaired mucociliary clearance of respiratory tract • Impaired phagocytosis by alveolar macrophages • Immune & inflammatory cell recruitment to lung tissue
Recurrent otitis media	• Impaired mucociliary clearance of eustachian tube
Prematurity & low birth weight	• Transplacental exposure to components of tobacco smoke
Sudden infant death syndrome	• Likely related to impaired arousal & cardiovascular responses to stimuli

Secondhand smoke (SHS) exposure can adversely affect nearly every organ system, most notably the respiratory tract (eg, pneumonia, asthma). One of the most serious effects of SHS exposure is the increased risk for **sudden infant death syndrome (SIDS)**.

SIDS refers to the unexpected death of a previously healthy infant with an inconclusive postmortem examination. Almost all cases are associated with at least 1 risk factor, such as prematurity, an unsafe sleep environment, and smoke exposure. Smoke exposure likely contributes to SIDS by causing **impaired arousal** and cardiovascular response to stimuli (eg, hypoxemia).

The risk of SIDS is further increased in cases of **maternal cigarette use during pregnancy**, which is associated with impaired fetal oxygenation and direct exposure of the fetus to toxins (eg, nicotine, carbon monoxide). The degree of risk correlates with the amount of cigarette use, suggesting a dose-response relationship between smoking and SIDS.

(Choice A) Because maternal smoking during pregnancy (not seen here) increases the risk of preterm delivery, the risk of prematurity-associated complications (eg, apnea of prematurity) is also increased. However, these risks do not increase with postnatal SHS exposure. Moreover, apnea of prematurity typically presents with apneic episodes in the first 2-3 days of life.

https://t.me/USMLEWorldStep1

tract (eg, pneumonia, asthma). One of the most serious effects of SHS exposure is the increased risk for **sudden infant death syndrome (SIDS)**.

SIDS refers to the unexpected death of a previously healthy infant with an inconclusive postmortem examination. Almost all cases are associated with at least 1 risk factor, such as prematurity, an unsafe sleep environment, and smoke exposure. Smoke exposure likely contributes to SIDS by causing **impaired arousal** and cardiovascular response to stimuli (eg, hypoxemia).

The risk of SIDS is further increased in cases of **maternal cigarette use during pregnancy**, which is associated with impaired fetal oxygenation and direct exposure of the fetus to toxins (eg, nicotine, carbon monoxide). The degree of risk correlates with the amount of cigarette use, suggesting a dose-response relationship between smoking and SIDS.

(Choice A) Because maternal smoking during pregnancy (not seen here) increases the risk of preterm delivery, the risk of prematurity-associated complications (eg, apnea of prematurity) is also increased. However, these risks do not increase with postnatal SHS exposure. Moreover, apnea of prematurity typically presents with apneic episodes in the first 2-3 days of life.

(Choice B) SHS increases the risk for respiratory tract disease and recurrent otitis media in children; parents who smoke outside the home should be counseled on cessation because chemicals from cigarette smoke are adsorbed and retained by clothing, skin, and hair and therefore still pose a risk to children. SHS is not associated with an increased risk for epilepsy.

(Choice C) SHS does not increase the risk for failure to thrive in infancy. In fact, SHS may be associated with childhood obesity.

(Choice E) SHS exposure in childhood increases the risk for atrial fibrillation in adulthood but is not associated with ventricular arrhythmias.

Educational objective:
Maternal tobacco use during pregnancy and secondhand smoke exposure are associated with an increased risk for sudden infant death syndrome (SIDS). Pathophysiology of the association between smoke exposure and SIDS may relate to impaired arousal and cardiovascular response to stimuli (eg, airflow obstruction).

https://t.me/USMLEWorldStep1

A 69-year-old man comes to the office due to progressive pain beneath his right scapula and in his right arm for the last several months. He has taken over-the-counter analgesics, which provide short-term relief, but the pain has become more severe and awakens him at night. The pain is associated with numbness in his right forearm extending up to the tips of the fourth and fifth fingers. The patient has also had persistent nonproductive cough and lately has been coughing up streaks of blood. He has a history of hypertension, gastroesophageal reflux disease, and osteoarthritis. He has smoked 2 packs of cigarettes daily for more than 40 years but recently cut down to 4 or 5 cigarettes a day. Which of the following is the most likely cause of this patient's symptoms?

- A. Abnormal hormone secretion
- B. Airway obstruction
- C. Anterior mediastinum mass
- D. Autoimmune disease
- E. Pericardial effusion
- F. Pleural effusion
- G. Superior sulcus tumor

Submit

https://t.me/USMLEWorldStep1

A 69-year-old man comes to the office due to progressive pain beneath his right scapula and in his right arm for the last several months. He has taken over-the-counter analgesics, which provide short-term relief, but the pain has become more severe and awakens him at night. The pain is associated with numbness in his right forearm extending up to the tips of the fourth and fifth fingers. The patient has also had persistent nonproductive cough and lately has been coughing up streaks of blood. He has a history of hypertension, gastroesophageal reflux disease, and osteoarthritis. He has smoked 2 packs of cigarettes daily for more than 40 years but recently cut down to 4 or 5 cigarettes a day. Which of the following is the most likely cause of this patient's symptoms?

- A. Abnormal hormone secretion (2%)
- ✗ B. Airway obstruction (1%)
- C. Anterior mediastinum mass (18%)
- D. Autoimmune disease (3%)
- E. Pericardial effusion (0%)
- F. Pleural effusion (4%)
- ✓ G. Superior sulcus tumor (70%)

Incorrect
Correct answer
G

70%
Answered correctly

04 secs
Time Spent

2023
Version

Explanation

This patient with an extensive smoking history who now has hemoptysis and shoulder pain likely has lung cancer, which can be associated with symptoms due to local or distant spread. **Pancoast syndrome** is caused by a tumor at the lung apex. Such tumors often arise in the **superior sulcus** (groove formed by the subclavian vessels). The apical location allows for extensive local tumor spread. Invasion of surrounding structures can cause the following:

- **Shoulder pain** radiating toward the axilla and scapula (**most common** presenting symptom). It occurs due to

https://t.me/USMLEWorldStep1

This patient with an extensive smoking history who now has hemoptysis and shoulder pain likely has lung cancer, which can be associated with symptoms due to local or distant spread. **Pancoast syndrome** is caused by a tumor at the lung apex. Such tumors often arise in the **superior sulcus** (groove formed by the subclavian vessels). The apical location allows for extensive local tumor spread. Invasion of surrounding structures can cause the following:

- **Shoulder pain** radiating toward the axilla and scapula (**most common** presenting symptom). It occurs due to involvement of the lower brachial plexus. Other associated symptoms include arm paresthesia, weakness, and muscle atrophy.
- **Horner syndrome** occurs due to involvement of the cervical sympathetic ganglia. Symptoms include ipsilateral ptosis, miosis, and anhidrosis.
- Upper extremity edema may be due to compression of subclavian vessels.
- **Spinal cord compression** and paraplegia can result from tumor extension into the intervertebral foramina.

(Choice A) Squamous cell carcinoma is associated with parathyroid-related peptide secretion and hypercalcemia. Cushing syndrome and syndrome of inappropriate antidiuretic hormone secretion can accompany small cell carcinoma of the lung.

(Choice B) Centrally located lung cancers (squamous cell and small cell carcinomas) frequently obstruct the main bronchi, producing dyspnea and cough. Airway obstruction would not cause shoulder pain or muscle atrophy.

(Choice C) Anterior mediastinal masses include thymoma, teratoma, thyroid cancer, and (terrible) lymphoma ("terrible Ts"). They are less likely to lead to hemoptysis or brachial plexus involvement.

(Choice D) Lung cancers are associated with a number of autoimmune syndromes, most commonly Lambert-Eaton (progressive proximal muscle weakness, often in the legs).

(Choice E) Pericardial effusions are characterized by dyspnea, distended neck veins, distant heart sounds, and - particularly if tamponade is present - pulsus paradoxus (decrease in systolic blood pressure >10 mm Hg during inspiration).

(Choice F) A pleural effusion can lead to dyspnea and irritate the mediastinal and diaphragmatic pleura, causing referred shoulder pain (via the phrenic nerve); however, it would not cause hemoptysis.

https://t.me/USMLEWorldStep1

and muscle atrophy.

- **Horner syndrome** occurs due to involvement of the cervical sympathetic ganglia. Symptoms include ipsilateral ptosis, miosis, and anhidrosis.
- Upper extremity edema may be due to compression of subclavian vessels.
- **Spinal cord compression** and paraplegia can result from tumor extension into the intervertebral foramina.

(Choice A) Squamous cell carcinoma is associated with parathyroid-related peptide secretion and hypercalcemia. Cushing syndrome and syndrome of inappropriate antidiuretic hormone secretion can accompany small cell carcinoma of the lung.

(Choice B) Centrally located lung cancers (squamous cell and small cell carcinomas) frequently obstruct the main bronchi, producing dyspnea and cough. Airway obstruction would not cause shoulder pain or muscle atrophy.

(Choice C) Anterior mediastinal masses include thymoma, teratoma, thyroid cancer, and (terrible) lymphoma ("terrible Ts"). They are less likely to lead to hemoptysis or brachial plexus involvement.

(Choice D) Lung cancers are associated with a number of autoimmune syndromes, most commonly Lambert-Eaton (progressive proximal muscle weakness, often in the legs).

(Choice E) Pericardial effusions are characterized by dyspnea, distended neck veins, distant heart sounds, and - particularly if tamponade is present - pulsus paradoxus (decrease in systolic blood pressure >10 mm Hg during inspiration).

(Choice F) A pleural effusion can lead to dyspnea and irritate the mediastinal and diaphragmatic pleura, causing referred shoulder pain (via the phrenic nerve); however, it would not cause hemoptysis.

Educational objective:
Tumors located in the lung apex (superior sulcus) are called Pancoast tumors. Invasion of surrounding structures can lead to ipsilateral Horner syndrome, rib destruction, atrophy of hand muscles, and pain in the distribution of C8, T1, and T2 nerve roots.

Pathophysiology | Pulmonary & Critical Care | Lung cancer

https://t.me/USMLEWorldStep1

A 52-year-old woman with a history of cirrhosis due to chronic hepatitis C experiences worsening dyspnea. She has no other medical conditions. Vital signs are within normal limits. Physical examination shows normal jugular venous pressure, right-sided dullness to percussion and decreased breath sounds, normal heart sounds, and moderate-sized ascites. Chest x-ray reveals a large right-sided pleural effusion with no parenchymal lesions. Thoracentesis yields transudative fluid with normal cell counts. Which of the following is the most likely underlying mechanism of this patient's pulmonary findings?

- A. Fluid movement across the diaphragm
- B. Inflammatory disruption of pleural mesothelium
- C. Malignant obstruction of pleural lymphatic drainage
- D. Mechanical disruption of thoracic lymphatic flow
- E. Rapid decrease in intrapleural pressure

Submit

https://t.me/USMLEWorldStep1

A 52-year-old woman with a history of cirrhosis due to chronic hepatitis C experiences worsening dyspnea. She has no other medical conditions. Vital signs are within normal limits. Physical examination shows normal jugular venous pressure, right-sided dullness to percussion and decreased breath sounds, normal heart sounds, and moderate-sized ascites. Chest x-ray reveals a large right-sided pleural effusion with no parenchymal lesions. Thoracentesis yields transudative fluid with normal cell counts. Which of the following is the most likely underlying mechanism of this patient's pulmonary findings?

- ✓ A. Fluid movement across the diaphragm (43%)
- ✗ B. Inflammatory disruption of pleural mesothelium (9%)
- C. Malignant obstruction of pleural lymphatic drainage (11%)
- D. Mechanical disruption of thoracic lymphatic flow (25%)
- E. Rapid decrease in intrapleural pressure (10%)

Incorrect
Correct answer
A

43%
Answered correctly

04 secs
Time Spent

2023
Version

Explanation

This patient with **cirrhosis** complicated by ascites who presents with a right-sided, transudative pleural effusion most likely has a **hepatic hydrothorax**. As ascites fluid accumulates in the abdomen, **increased intraabdominal pressure** can force fluid into the chest cavity through small fenestrations in the diaphragm; **fluid movement across the diaphragm** occurs most often on the **right side**.

Because the development of ascites in patients with cirrhosis is driven by changes in hydrostatic and oncotic pressure (ie, increased hydrostatic pressure due to portal venous hypertension and decreased oncotic pressure due to hypoalbuminemia), the pleural fluid in hepatic hydrothorax is **transudative** by Light criteria.

(Choice B) Inflammatory disruption of the visceral pleural mesothelium can occur in pneumonia, allowing bacteria

https://t.me/USMLEWorldStep1

This patient with **cirrhosis** complicated by ascites who presents with a right-sided, transudative pleural effusion most likely has a **hepatic hydrothorax**. As ascites fluid accumulates in the abdomen, **increased intraabdominal pressure** can force fluid into the chest cavity through small fenestrations in the diaphragm; **fluid movement across the diaphragm** occurs most often on the **right side**.

Because the development of ascites in patients with cirrhosis is driven by changes in hydrostatic and oncotic pressure (ie, increased hydrostatic pressure due to portal venous hypertension and decreased oncotic pressure due to hypoalbuminemia), the pleural fluid in hepatic hydrothorax is **transudative** by Light criteria.

(Choice B) Inflammatory disruption of the visceral pleural mesothelium can occur in pneumonia, allowing bacteria in the alveoli to translocate into the pleural space and cause a complicated parapneumonic effusion. Parapneumonic effusions and other pleural effusions resulting from an inflammatory disruption of membrane permeability (eg, rheumatologic effusions, most malignant effusions) are exudative by Light criteria and usually have elevated leukocyte count.

(Choice C) Malignant cells that have metastasized to the pleural space can cause pleural effusion by obstructing pleural fluid drainage via parietal pleura lymphatics. Liver cirrhosis predisposes to the development of hepatocellular carcinoma, which could metastasize to the pleural space; however, malignant effusions typically have high lymphocyte count and cytology frequently reveals malignant cells.

(Choice D) Mechanical disruption of thoracic lymphatic flow (eg, injury to the thoracic duct) can cause a chylothorax, which is a milky white pleural effusion with very high triglyceride content. Chylothorax is usually exudative by Light criteria.

(Choice E) Atelectasis causes a rapid decrease in intrapleural pressure (as alveoli collapse and pull farther away from the chest wall), and the pressure gradient created between the pleural space and the lung may drive the movement of interstitial fluid into the pleural space, causing a transudative pleural effusion. Pleural effusions due to atelectasis are usually relatively small; hepatic hydrothorax is more likely in this patient with a large, right-sided pleural effusion and a history of cirrhosis.

Educational objective:
Patients with cirrhosis complicated by abdominal ascites may develop a hepatic hydrothorax, which is a transudative, usually right-sided pleural effusion that results from passage of intraabdominal fluid into the chest

https://t.me/USMLEWorldStep1

across the diaphragm occurs most often on the **right side**.

Because the development of ascites in patients with cirrhosis is driven by changes in hydrostatic and oncotic pressure (ie, increased hydrostatic pressure due to portal venous hypertension and decreased oncotic pressure due to hypoalbuminemia), the pleural fluid in hepatic hydrothorax is **transudative** by Light criteria.

(Choice B) Inflammatory disruption of the visceral pleural mesothelium can occur in pneumonia, allowing bacteria in the alveoli to translocate into the pleural space and cause a complicated parapneumonic effusion. Parapneumonic effusions and other pleural effusions resulting from an inflammatory disruption of membrane permeability (eg, rheumatologic effusions, most malignant effusions) are exudative by Light criteria and usually have elevated leukocyte count.

(Choice C) Malignant cells that have metastasized to the pleural space can cause pleural effusion by obstructing pleural fluid drainage via parietal pleura lymphatics. Liver cirrhosis predisposes to the development of hepatocellular carcinoma, which could metastasize to the pleural space; however, malignant effusions typically have high lymphocyte count and cytology frequently reveals malignant cells.

(Choice D) Mechanical disruption of thoracic lymphatic flow (eg, injury to the thoracic duct) can cause a chylothorax, which is a milky white pleural effusion with very high triglyceride content. Chylothorax is usually exudative by Light criteria.

(Choice E) Atelectasis causes a rapid decrease in intrapleural pressure (as alveoli collapse and pull farther away from the chest wall), and the pressure gradient created between the pleural space and the lung may drive the movement of interstitial fluid into the pleural space, causing a transudative pleural effusion. Pleural effusions due to atelectasis are usually relatively small; hepatic hydrothorax is more likely in this patient with a large, right-sided pleural effusion and a history of cirrhosis.

Educational objective:
Patients with cirrhosis complicated by abdominal ascites may develop a hepatic hydrothorax, which is a transudative, usually right-sided pleural effusion that results from passage of intraabdominal fluid into the chest cavity through small fenestrations in the diaphragm.

References

- Diagnostic approach to pleural effusion in adults

https://t.me/USMLEWorldStep1

This patient with **cirrhosis** complicated by ascites who presents with a right-sided, transudative pleural effusion most li... **hepatic hydrothorax**. Ascitic fluid ... **increased intraabdominal press... across...**

Becau... pressu... due to...

(Choi... in the ... Parapl... perme... have e...

(Choi... pleura... hepato... have h...

(Choi... chyloth... exuda...

(Choi... from th... mover... to atel... pleura...

Educa...

Patients with cirrhosis complicated by abdominal ascites may develop a hepatic hydrothorax, which is a transudative, usually right-sided pleural effusion that results from passage of intraabdominal fluid into the chest

Exhibit Display

Exudative & transudative pleural effusions

	Exudate	Transudate
Light criteria	Pleural protein/serum protein >0.5 **OR** Pleural LDH/serum LDH >0.6 **OR** Pleural LDH greater than two-thirds upper limit of normal of serum LDH	Exudate criteria not met
Pathophysiology	Inflammatory increase in membrane permeability	Change in hydrostatic or oncotic pressure
Common causes	• Infection (eg, pneumonia, TB) • Malignancy • Rheumatologic disease	• Heart failure • Cirrhosis (hepatic hydrothorax) • Nephrotic syndrome

LDH = lactate dehydrogenase; **TB** = tuberculosis.

New | Existing | My Notebook

https://t.me/USMLEWorldStep1

A 47-year-old woman comes to the office due to progressive exertional dyspnea and fatigue. She also reports painful episodes of bluish discoloration of the fingers and toes that are triggered by cold exposure and improve with rewarming. Medical history is significant for severe gastroesophageal reflux disease. Physical examination shows skin tightening over the fingers. The oral aperture is small, and scattered telangiectasias are present over the lips. Cardiac examination demonstrates an increased intensity of S2 over the upper left sternal border. Lungs are clear to auscultation with normal air movement and no crackles. The abdomen is soft with mild hepatomegaly. There is bilateral lower extremity pitting edema. Chest x-ray reveals no abnormalities. Results of office spirometry are as follows:

Forced vital capacity (FVC)	Normal
Forced expiratory volume in 1 second (FEV_1)	Normal
FEV_1/FVC ratio (%)	Normal

Which of the following is the most likely cause of this patient's dyspnea?

- A. Chest wall restriction
- B. Lung interstitial fibrosis
- C. Pericardial constriction
- D. Pulmonary arteriolar narrowing
- E. Pulmonic valve stenosis

Submit

https://t.me/USMLEWorldStep1

A 47-year-old woman comes to the office due to progressive exertional dyspnea and fatigue. She also reports painful episodes of bluish discoloration of the fingers and toes that are triggered by cold exposure and improve with rewarming. Medical history is significant for severe gastroesophageal reflux disease. Physical examination shows skin tightening over the fingers. The oral aperture is small, and scattered telangiectasias are present over the lips. Cardiac examination demonstrates an increased intensity of S2 over the upper left sternal border. Lungs are clear to auscultation with normal air movement and no crackles. The abdomen is soft with mild hepatomegaly. There is bilateral lower extremity pitting edema. Chest x-ray reveals no abnormalities. Results of office spirometry are as follows:

Forced vital capacity (FVC)	Normal
Forced expiratory volume in 1 second (FEV_1)	Normal
FEV_1/FVC ratio (%)	Normal

Which of the following is the most likely cause of this patient's dyspnea?

- A. Chest wall restriction (10%)
- ✗ B. Lung interstitial fibrosis (22%)
- C. Pericardial constriction (8%)
- ✓ D. Pulmonary arteriolar narrowing (33%)
- E. Pulmonic valve stenosis (24%)

Incorrect
Correct answer
D

33%
Answered correctly

08 secs
Time Spent

2023
Version

Explanation

https://t.me/USMLEWorldStep1

Exhibit Display

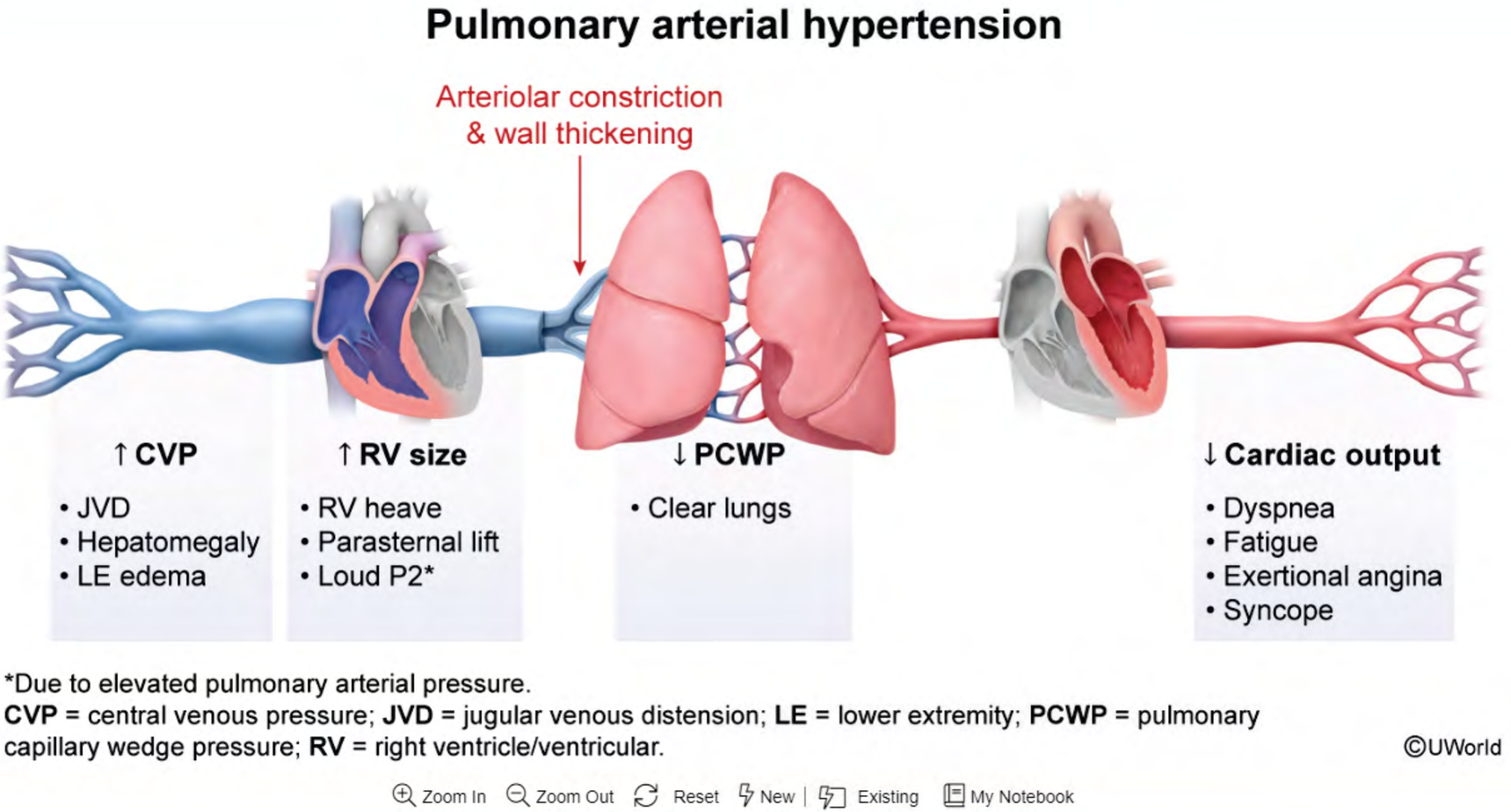

Zoom In | Zoom Out | Reset | New | Existing | My Notebook

This p
of the
(ie, sc
Esoph

Syster
extrem
(PAH),
fibropr
lumina

Pulmo
the inc
pulmo
venous congestion (eg, hepatomegaly, lower extremity edema).

(Choice A) Systemic sclerosis can induce extrapulmonary restriction via chest wall skin tightening that limits

https://t.me/USMLEWorldStep1

This patient displays Raynaud phenomenon (cold-induced painful digital vasospasm), sclerodactyly (skin tightening of the hands/ feet), telangiectasias, gastroesophageal dysfunction. These findings suggest **systemic sclerosis** (ie, scleroderma), specifically the limited cutaneous variant, or **CREST** (Calcinosis cutis, Raynaud phenomenon, Esophageal dysmotility, Sclerodactyly, Telangiectasia) syndrome.

Systemic sclerosis frequently involves multisystem vasculopathy affecting several vessel beds, including distal extremities (digital ischemia), kidneys (renal crisis), and pulmonary arteries. **Pulmonary arterial hypertension** (PAH), a leading cause of mortality in patients with systemic sclerosis, is driven by abnormal inflammatory and fibroproliferative signaling (eg, transforming growth factor beta), leading to neointimal/medial thickening and luminal narrowing. Histologically, vessels have a concentric onion-skin, sclerotic appearance.

Pulmonary vascular remodeling is progressive and relentless. Over time, the right ventricle cannot pump against the increased afterload, leading to **right ventricular failure**. In this patient, PAH is suggested by a prominent pulmonic component of S2 (ie, **loud P2**, reflecting high pressure in pulmonary artery) with signs of right-sided venous congestion (eg, hepatomegaly, lower extremity edema).

(Choice A) Systemic sclerosis can induce extrapulmonary restriction via chest wall skin tightening that limits thoracic expansion. Clear lungs are expected on auscultation and imaging; however, pulmonary function testing would show a restrictive pattern (ie, low FVC).

(Choice B) Fibrotic interstitial lung disease is another pulmonary complication of systemic sclerosis (particularly the diffuse cutaneous variant), characterized by lung parenchymal inflammation and collagen deposition. However, inspiratory crackles, reticular interstitial thickening on chest x-ray, and a restrictive pattern on pulmonary function testing are expected.

(Choice C) Pericardial fibrosis, occasionally a complication of systemic sclerosis, typically manifests as right-sided heart failure due to impaired diastolic filling of the right ventricle. However, this impaired filling prevents elevation of pulmonary artery pressure; therefore, a loud P2 is not expected.

(Choice E) Pulmonic stenosis can lead to right-sided heart failure. However, right ventricular outflow obstruction leads to low pulmonary artery pressures, resulting in a soft P2. In addition, pulmonic stenosis (almost always a congenital lesion) does not explain the additional findings of CREST syndrome.

https://t.me/USMLEWorldStep1

(PAH), a leading cause of mortality in patients with systemic sclerosis, is driven by abnormal inflammatory and fibroproliferative signaling (eg, transforming growth factor beta), leading to neointimal/medial thickening and luminal narrowing. Histologically, vessels have a concentric onion-skin, sclerotic appearance.

Pulmonary vascular remodeling is progressive and relentless. Over time, the right ventricle cannot pump against the increased afterload, leading to **right ventricular failure**. In this patient, PAH is suggested by a prominent pulmonic component of S2 (ie, **loud P2**, reflecting high pressure in pulmonary artery) with signs of right-sided venous congestion (eg, hepatomegaly, lower extremity edema).

(Choice A) Systemic sclerosis can induce extrapulmonary restriction via chest wall skin tightening that limits thoracic expansion. Clear lungs are expected on auscultation and imaging; however, pulmonary function testing would show a restrictive pattern (ie, low FVC).

(Choice B) Fibrotic interstitial lung disease is another pulmonary complication of systemic sclerosis (particularly the diffuse cutaneous variant), characterized by lung parenchymal inflammation and collagen deposition. However, inspiratory crackles, reticular interstitial thickening on chest x-ray, and a restrictive pattern on pulmonary function testing are expected.

(Choice C) Pericardial fibrosis, occasionally a complication of systemic sclerosis, typically manifests as right-sided heart failure due to impaired diastolic filling of the right ventricle. However, this impaired filling prevents elevation of pulmonary artery pressure; therefore, a loud P2 is not expected.

(Choice E) Pulmonic stenosis can lead to right-sided heart failure. However, right ventricular outflow obstruction leads to low pulmonary artery pressures, resulting in a soft P2. In addition, pulmonic stenosis (almost always a congenital lesion) does not explain the additional findings of CREST syndrome.

Educational objective:
Pulmonary arterial hypertension, a vascular complication of systemic sclerosis, involves fibroproliferative remodeling of the vessel wall, leading to increased pulmonary vascular resistance and right-sided heart failure.

References

- Pulmonary arterial hypertension in systemic sclerosis: challenges in diagnosis, screening, and treatment.

https://t.me/USMLEWorldStep1

• Hepatomegaly
• LE edema
• Parasternal lift
• Loud P2*
• Fatigue
• Exertional angina
• Syncope

Exhibit Display

Systemic sclerosis		
	Limited cutaneous	**Diffuse cutaneous**
Manifestations	• Distal sclerosis (most prominent in the fingers) • CREST syndrome	• Proximal sclerosis (involves the trunk & proximal extremities)
Serology	• Anticentromere	• Anti–Scl-70
Complications	• Pulmonary hypertension	• Interstitial lung disease • Scleroderma renal crisis
Anti–Scl-70 = anti–topoisomerase type I; **CREST** = Calcinosis, Raynaud phenomenon, Esophageal dysmotility, Sclerodactyly & Telangiectasia.		

New | Existing | My Notebook

This p
of the
(ie, scl
Esoph

Syster
extrem
(PAH),
fibropr
lumina

Pulmo
the inc
pulmo
venou

(Choi
thorac
would

(Choi
the dif
inspira
testing

(Choi
heart f
of pulmonary artery pressure; therefore, a loud P2 is not expected.

https://t.me/USMLEWorldStep1

• Hepatomegaly
• LE edema
• Parasternal lift
• Loud P2*
• Fatigue
• Exertional angina
• Syncope

Exhibit Display

Pulmonary involvement in systemic sclerosis

	PAH alone	ILD
Clinical presentation	• Dyspnea • Exertional syncope • Clear lungs	• Dyspnea • Cough • Velcro-like crackles
Pulmonary function testing	• Normal FEV_1 & FVC • Normal FEV_1/FVC ratio • ↓ DLCO	• ↓ FEV_1 & FVC • Normal or ↑ FEV_1/FVC ratio • ↓ DLCO

DLCO = diffusion capacity of the lungs for carbon monoxide; **ILD** = interstitial lung disease; **PAH** = pulmonary arterial hypertension.

New | Existing | My Notebook

This p
of the
(ie, sc
Esoph

Syster
extrem
(PAH),
fibropr
lumina

Pulmo
the inc
pulmo
venou

(Choi
thorac
would

(Choi
the dif
inspira
testing

(Choi
heart f
of pulmonary artery pressure; therefore, a loud P2 is not expected.

https://t.me/USMLEWorldStep1

A 50-year-old man comes to the clinic for evaluation prior to a left total knee arthroplasty. Medical history is significant for osteoarthritis. The patient does not smoke. Preoperative chest x-ray demonstrates a 1.5-cm, round lesion in the periphery of the right upper lobe of the lung. Further imaging studies are suggestive of a pulmonary hamartoma. If a transthoracic biopsy were performed, which of the following microscopic features would be most consistent with this diagnosis?

- A. Atypical cells lining alveoli without invasion
- B. Expression of neuroendocrine markers
- C. Invasive nests with keratin pearl formation
- D. Nodules of cartilaginous tissue
- E. Sheets of large pleomorphic cells

Submit

https://t.me/USMLEWorldStep1

A 50-year-old man comes to the clinic for evaluation prior to a left total knee arthroplasty. Medical history is significant for osteoarthritis. The patient does not smoke. Preoperative chest x-ray demonstrates a 1.5-cm, round lesion in the periphery of the right upper lobe of the lung. Further imaging studies are suggestive of a pulmonary hamartoma. If a transthoracic biopsy were performed, which of the following microscopic features would be most consistent with this diagnosis?

- A. Atypical cells lining alveoli without invasion (21%)
- ✗ B. Expression of neuroendocrine markers (6%)
- C. Invasive nests with keratin pearl formation (4%)
- ✓ D. Nodules of cartilaginous tissue (55%)
- E. Sheets of large pleomorphic cells (11%)

Incorrect
Correct answer
D

55%
Answered correctly

04 secs
Time Spent

2023
Version

Explanation

Pulmonary hamartoma

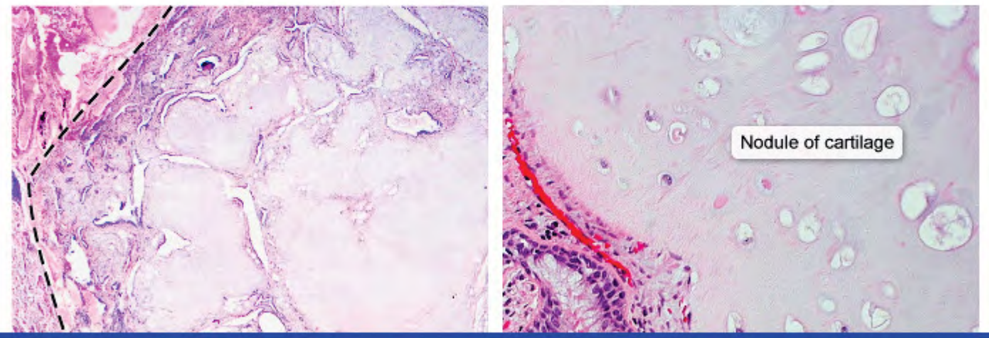

https://t.me/USMLEWorldStep1

A 50-year-old man comes to the clinic for evaluation prior to a left total knee arthroplasty. Medical history is signifi
lesion
hamar
consis

Inco
Corre
D

Expl

Exhibit Display

Pulmonary hamartoma

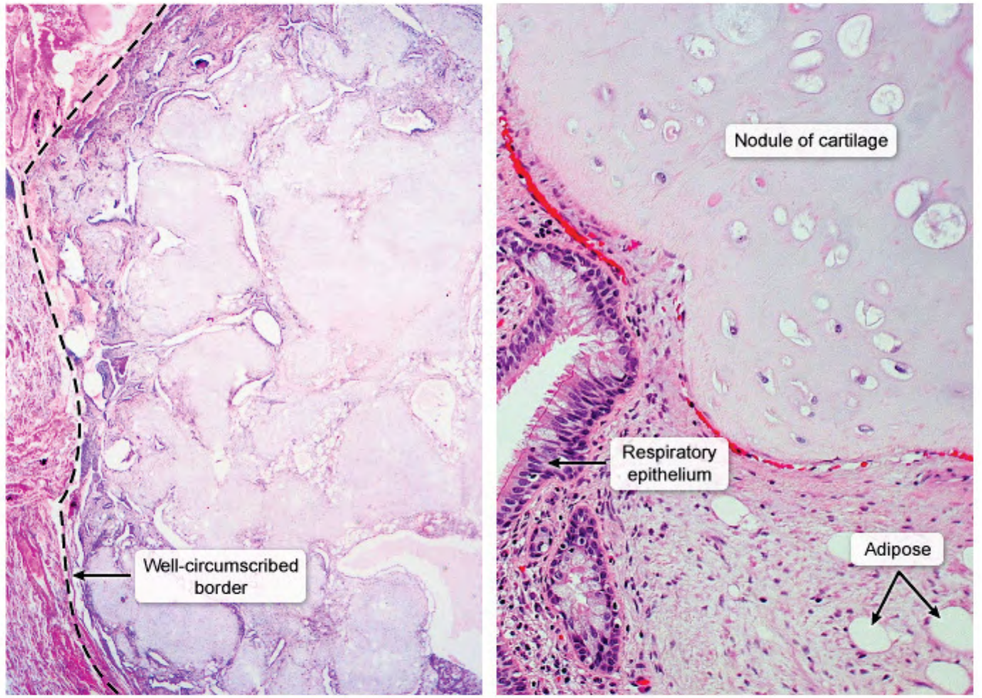

©UWorld

Zoom In | Zoom Out | Reset | New | Existing | My Notebook

https://t.me/USMLEWorldStep1

©UWorld

Pulmonary hamartomas are common, **benign** lung lesions that usually present as asymptomatic, **incidental** findings on chest imaging in middle-aged adults. In radiographs, they are typically **solitary**, small (<3 cm), round, **well-circumscribed** lesions (ie, coin lesions) with a popcorn pattern of calcification; they often **grow slowly** at the **periphery** of the lung. Microscopy shows nodules of mature connective tissue (eg, **cartilage**, fat) and clefts lined by entrapped respiratory epithelium.

Hamartomas are lesions composed of tissue types that are native to the organ of involvement but show an abnormal, disorganized arrangement. Many hamartomas, including pulmonary hamartomas, are now thought to be benign **neoplastic** lesions (rather than malformations), as evidenced by the demonstration of clonal chromosomal abnormalities.

(Choice A) Microscopic features of adenocarcinoma in situ include atypical cells lining the alveolar septa (ie, lepidic growth) without invasion. On chest x-ray, adenocarcinoma in situ often appears as a solitary, peripheral mass or as a pneumonia-like consolidation.

(Choice B) Neuroendocrine marker (eg, synaptophysin, chromogranin) expression is characteristic of neuroendocrine tumors (eg, small cell carcinoma, carcinoid tumors). Small cell lung carcinoma commonly presents as a rapidly growing, central mass in patients with a history of smoking. Carcinoid tumors often arise within the bronchi and may present with symptoms of bronchial obstruction.

(Choice C) Invasive nests of tumor cells with keratin pearl formation are a feature of squamous cell carcinoma, which is typically a centrally located lung lesion in patients with a history of smoking.

(Choice E) Large cell carcinoma is an aggressive neoplasm that demonstrates large, pleomorphic, epithelial tumor cells without squamous, glandular, or neuroendocrine differentiation (ie, diagnosis of exclusion). Large cell carcinoma frequently presents as an enlarging, necrotic, peripheral lung mass.

Educational objective:
Hamartomas are common, slow-growing, benign lung neoplasms microscopically characterized by nodules of disorganized, mature connective tissue (eg, cartilage, fat) and entrapped respiratory epithelium. They are often detected incidentally by imaging, appearing as well-circumscribed, peripheral, solitary lung lesions.

https://t.me/USMLEWorldStep1

©UWorld

Exhibit Display

Lung adenocarcinoma in situ

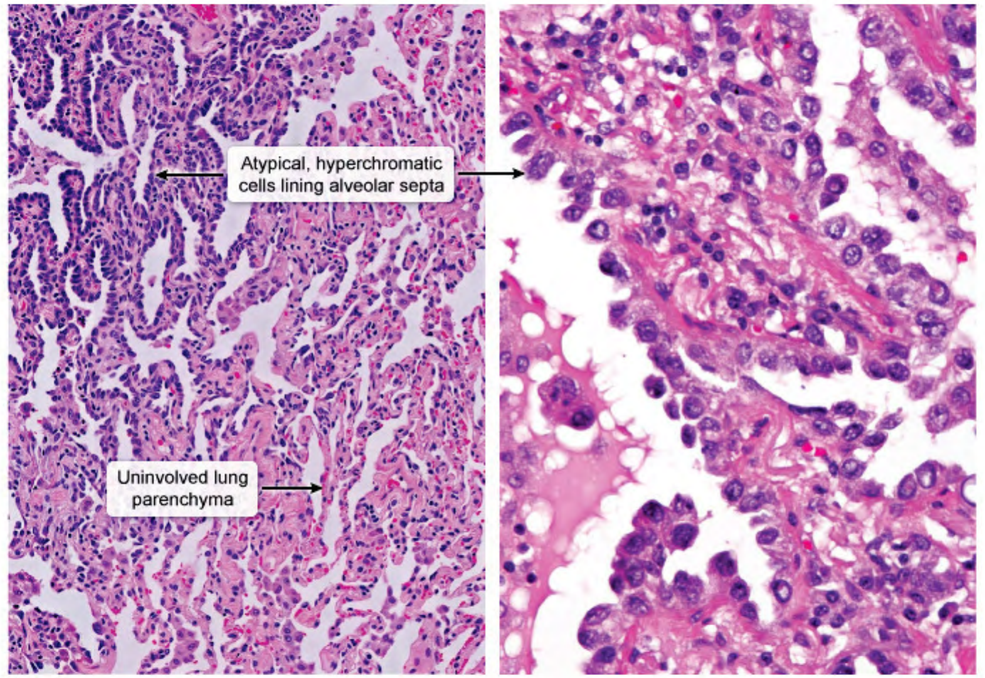

©UWorld

Zoom In | Zoom Out | Reset | New | Existing | My Notebook

detected incidentally by imaging, appearing as well-circumscribed, peripheral, solitary lung lesions.

https://t.me/USMLEWorldStep1

©UWorld

Pulmo
findin
well-c
periph
by ent

Hamar
abnorr
be ber
chrom

(Choi
lepidic
mass

(Choi
neuroe
as a ra
bronch

(Choi
which

(Choi
tumor
carcin

Educa
Hamar
disorg

Exhibit Display

Small cell carcinoma

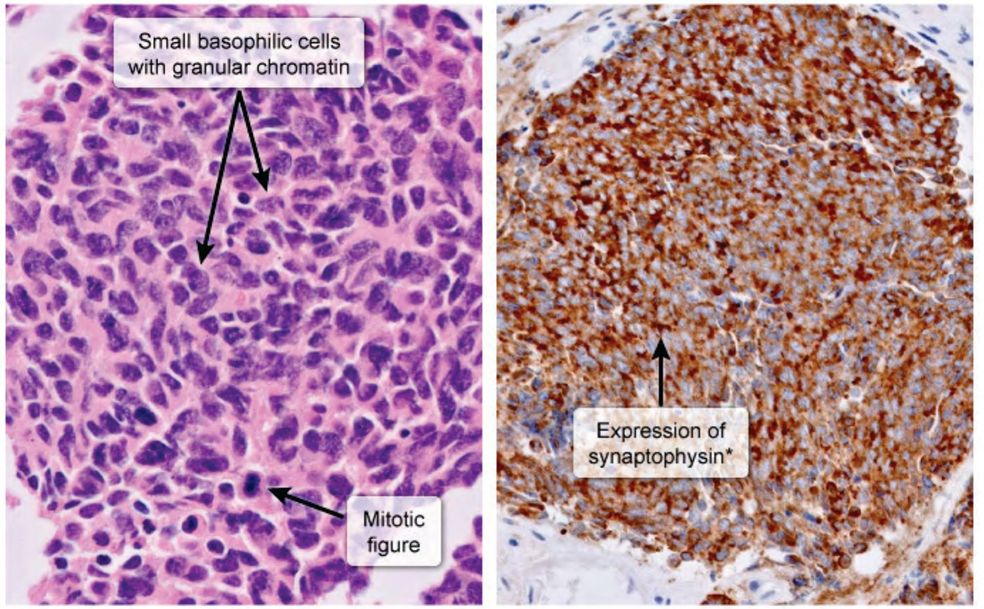

*Synaptophysin and chromogranin are neuroendocrine markers

©UWorld

Zoom In | Zoom Out | Reset | New | Existing | My Notebook

detected incidentally by imaging, appearing as well-circumscribed, peripheral, solitary lung lesions.

https://t.me/USMLEWorldStep1

©UWorld

Pulmo
findin
well-c
periph
by ent

Hamar
abnorr
be ber
chrom

(Choi
lepidic
mass

(Choi
neuroe
as a ra
bronch

(Choi
which

(Choi
tumor
carcin

Educa
Hamar
disorg

Exhibit Display

Squamous cell carcinoma

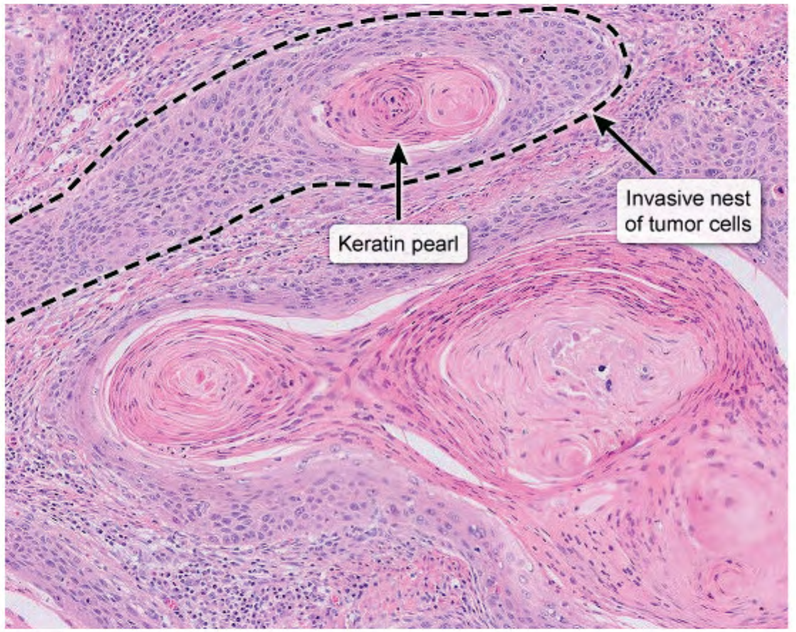

©UWorld

Zoom In | Zoom Out | Reset | New | Existing | My Notebook

detected incidentally by imaging, appearing as well-circumscribed, peripheral, solitary lung lesions.

https://t.me/USMLEWorldStep1

©UWorld

Pulmo
findin
well-c
periph
by ent

Hamar
abnorr
be ber
chrom

(Choi
lepidic
mass

(Choi
neuroe
as a ra
bronch

(Choi
which

(Choi
tumor
carcin

Educa
Hamar
disorg

Exhibit Display

Pulmonary large cell carcinoma

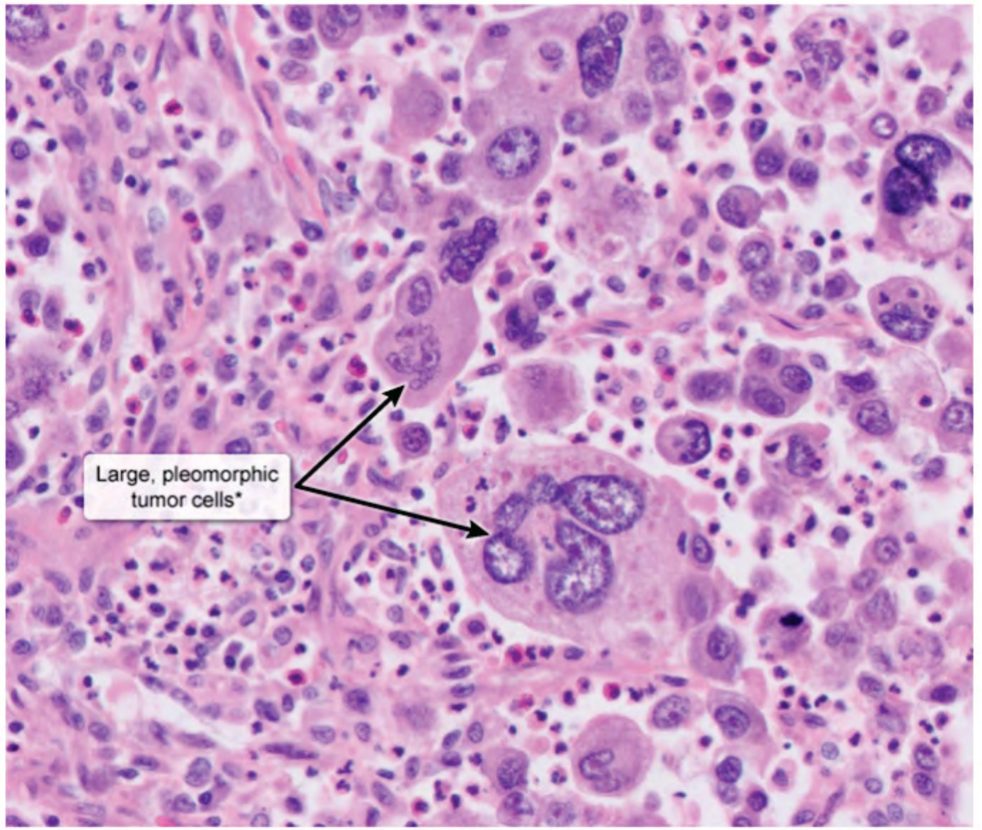

*Without squamous, glandular, or neuroendocrine differentiation.

©UWorld

Zoom In | Zoom Out | Reset | New | Existing | My Notebook

detected incidentally by imaging, appearing as well-circumscribed, peripheral, solitary lung lesions.

https://t.me/USMLEWorldStep1

A 42-year-old man comes to his primary care physician due to daytime sleepiness. He often falls asleep during meetings and while watching television and has even fallen asleep while driving. The patient does not feel refreshed when waking and has occasional morning headaches. He has not had abnormal dreams or visual hallucinations when falling asleep or on waking. The patient has no significant past medical history and is a lifetime non-smoker. He drinks 2 or 3 beers on Friday nights. Blood pressure is 148/100 mm Hg and pulse is 78/min and regular; BMI is 32 kg/m^2. Cardiopulmonary examination shows no abnormalities. Arterial blood gas analysis is normal. What is this patient's most likely diagnosis?

- A. Central sleep apnea
- B. Narcolepsy
- C. Obesity hypoventilation syndrome
- D. Obstructive sleep apnea
- E. Primary insomnia
- F. Restless leg syndrome

Submit

https://t.me/USMLEWorldStep1

A 42-year-old man comes to his primary care physician due to daytime sleepiness. He often falls asleep during meetings and while watching television and has even fallen asleep while driving. The patient does not feel refreshed when waking and has occasional morning headaches. He has not had abnormal dreams or visual hallucinations when falling asleep or on waking. The patient has no significant past medical history and is a lifetime non-smoker. He drinks 2 or 3 beers on Friday nights. Blood pressure is 148/100 mm Hg and pulse is 78/min and regular; BMI is 32 kg/m^2. Cardiopulmonary examination shows no abnormalities. Arterial blood gas analysis is normal. What is this patient's most likely diagnosis?

- A. Central sleep apnea (3%)
- B. Narcolepsy (14%)
- ✗ C. Obesity hypoventilation syndrome (8%)
- ✓ D. Obstructive sleep apnea (71%)
- E. Primary insomnia (2%)
- F. Restless leg syndrome (0%)

Incorrect
Correct answer
D

71%
Answered correctly

04 secs
Time Spent

2023
Version

Explanation

Obstructive sleep apnea	
Pathophysiology	• Relaxation of pharyngeal muscles, leading to closure of airway • Loud snoring with periods of apnea
	• Daytime somnolence • Nonrestorative sleep with frequent awakenings

https://t.me/USMLEWorldStep1

Explanation

Obstructive sleep apnea	
Pathophysiology	• Relaxation of pharyngeal muscles, leading to closure of airway • Loud snoring with periods of apnea
Symptoms	• Daytime somnolence • Nonrestorative sleep with frequent awakenings • Morning headaches • Affective & cognitive symptoms
Sequelae	• Systemic hypertension • Pulmonary hypertension & right-sided heart failure

This patient has several features that suggest **obstructive sleep apnea** (OSA), including daytime somnolence, nonrestorative sleep, and elevated blood pressure in the setting of underlying obesity. OSA is caused by closure of the upper airway due to **relaxation of pharyngeal muscle tone** during sleep. Additional contributing factors include **obesity**, tonsillar hypertrophy, and hypothyroidism. When the airway is occluded, PO_2 declines and PCO_2 rises until chemoreceptors in the carotid body and brainstem trigger arousal and pharyngeal tone returns. Sleep is repeatedly disrupted throughout the night, even in the absence of cortical awareness.

Typical symptoms include excessive daytime sleepiness, **morning headaches**, cognitive impairment, and depression. Most patients also experience loud **snoring** due to partial closure of the airway. Chronic OSA can lead to systemic and pulmonary hypertension with **right heart failure** and an increased risk for cardiac arrhythmias.

(Choice A) Central sleep apnea is due to diminished respiratory drive from a neurologic disorder. Symptoms may superficially resemble OSA, but it is usually associated with significant underlying chronic illness (eg, congestive heart failure, cerebrovascular disease, renal insufficiency) and is not more common in obesity.

(Choice B) Narcolepsy is characterized by poorly regulated rapid eye movement (REM) sleep. It frequently

https://t.me/USMLEWorldStep1

include **obesity**, tonsillar hypertrophy, and hypothyroidism. When the airway is occluded, PO_2 declines and PCO_2 rises until chemoreceptors in the carotid body and brainstem trigger arousal and pharyngeal tone returns. Sleep is repeatedly disrupted throughout the night, even in the absence of cortical awareness.

Typical symptoms include excessive daytime sleepiness, **morning headaches**, cognitive impairment, and depression. Most patients also experience loud **snoring** due to partial closure of the airway. Chronic OSA can lead to systemic and pulmonary hypertension with **right heart failure** and an increased risk for cardiac arrhythmias.

(Choice A) Central sleep apnea is due to diminished respiratory drive from a neurologic disorder. Symptoms may superficially resemble OSA, but it is usually associated with significant underlying chronic illness (eg, congestive heart failure, cerebrovascular disease, renal insufficiency) and is not more common in obesity.

(Choice B) Narcolepsy is characterized by poorly regulated rapid eye movement (REM) sleep. It frequently causes excessive daytime sleepiness, but patients also suffer from cataplexy, sleep attacks, hypnagogic/hypnopompic hallucinations, and sleep paralysis.

(Choice C) Obesity hypoventilation syndrome (Pickwickian syndrome) is caused by restricted expansion of the chest wall due to severe obesity. This leads to hypoventilation with a chronically elevated PCO_2 and reduced PO_2. This patient's normal blood gases and mild obesity are not consistent with obesity hypoventilation.

(Choice E) Patients with simple insomnia may have daytime fatigue, but nonrestorative sleep, morning headaches, and elevated blood pressure suggest OSA.

(Choice F) Restless leg syndrome is characterized by vague discomfort in the limbs that is brought on when trying to sleep and relieved with movement. Symptoms may recur through the night and lead to nonrestorative sleep, but patients are usually aware of the symptoms.

Educational objective:
Obstructive sleep apnea is due to relaxation of oropharyngeal muscle tone with occlusion of the upper airway. Symptoms include daytime sleepiness, headaches, and depression. Complications include systemic and pulmonary hypertension, right heart failure, and an increased risk for cardiac events.

References

https://t.me/USMLEWorldStep1

Obstructive sleep apnea
Relaxation of pharyngeal muscles, leading to closure of airway

Exhibit Display

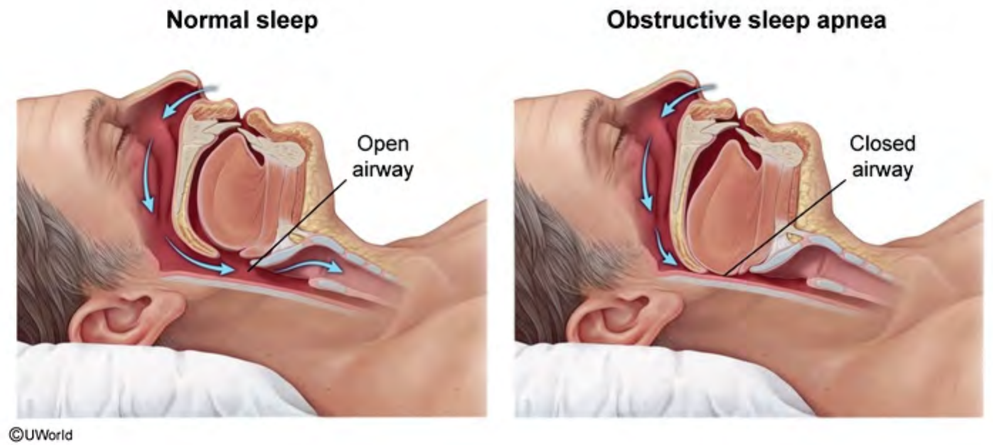

Zoom In | Zoom Out | Reset | New | Existing | My Notebook

This p
nonres
the up
include
rises u
repeat

Typica
depres
lead to
arrhyth

(Choic
superf
heart f

(Choic
cause
hypna

(Choice C) Obesity hypoventilation syndrome (Pickwickian syndrome) is caused by restricted expansion of the

https://t.me/USMLEWorldStep1

A 70-year-old man comes to the emergency department due to severe right-sided chest pain and shortness of breath after a fall. While doing yard work, the patient fell off of a ladder, striking his back on several large stones. Immediately afterward, he felt sharp pain over his posterior chest and had trouble catching his breath. Blood pressure is 120/80 mm Hg, pulse is 88/min, and respirations are 24/min. Chest x-ray is shown in the exhibit. Physical examination of the right side of the chest would most likely reveal which of the following?

- A. Bronchophony
- B. Dullness to percussion
- C. Increased diaphragmatic excursion
- D. Prolonged expiration
- E. Subcutaneous crepitus
- F. Wheezing

Submit

https://t.me/USMLEWorldStep1

A 70-year-old man comes to the emergency department due to severe right-sided chest pain and shortness of breath
Immed
pressu
Physic

Sub

Exhibit Display

Zoom In | Zoom Out | Reset | New | Existing | My Notebook

https://t.me/USMLEWorldStep1

A 70-year-old man comes to the emergency department due to severe right-sided chest pain and shortness of breath after a fall. While doing yard work, the patient fell off of a ladder, striking his back on several large stones. Immediately afterward, he felt sharp pain over his posterior chest and had trouble catching his breath. Blood pressure is 120/80 mm Hg, pulse is 88/min, and respirations are 24/min. Chest x-ray is shown in the exhibit. Physical examination of the right side of the chest would most likely reveal which of the following?

- A. Bronchophony (14%)
- B. Dullness to percussion (16%)
- C. Increased diaphragmatic excursion (15%)
- ✗ D. Prolonged expiration (3%)
- ✓ E. Subcutaneous crepitus (46%)
- F. Wheezing (3%)

Incorrect
Correct answer
E

46%
Answered correctly

15 secs
Time Spent

2023
Version

Explanation

Pneumothorax	
Risk factors	• Primary spontaneous: age <40, tall & thin, male sex, smoking • Secondary spontaneous: COPD, cystic fibrosis, lung malignancy • Provoked: thoracic trauma/procedures
Clinical presentation	• Shortness of breath, chest pain • ↓ Breath sounds unilaterally • Subcutaneous crepitus

https://t.me/USMLEWorldStep1

Pneumothorax	
Risk factors	• Primary spontaneous: age <40, tall & thin, male sex, smoking • Secondary spontaneous: COPD, cystic fibrosis, lung malignancy • Provoked: thoracic trauma/procedures
Clinical presentation	• Shortness of breath, chest pain • ↓ Breath sounds unilaterally • Subcutaneous crepitus • Hypotension, tachycardia & tracheal deviation*
Diagnosis	Chest x-ray: • Pleural line without peripheral lung markings • Contralateral mediastinal shift*
*If tension pathophysiology is present. **COPD** = chronic obstructive pulmonary disease.	

This patient experienced sudden-onset shortness of breath and chest pain following chest trauma; chest x-ray shows several rib fractures and a collapsed right lung, findings consistent with **traumatic pneumothorax**.

Traumatic pneumothorax can result from puncture of either the chest wall (eg, penetrating chest trauma) or the lung (eg, by fractured ribs), allowing air to enter the pleural space. The communication pathway causes intrapleural pressure to equalize with atmospheric pressure (ie, **loss of intrapleural negative pressure**), which prevents lung expansion during inspiration and leads to **breathing difficulty**.

Because air in the pleural space insulates sounds and vibrations originating in the airways, physical examination reveals **decreased breath sounds** and **decreased tactile fremitus** on the affected side. In addition, the relatively low density of air compared to normal lung tissue causes **hyperresonance** to percussion. Disruption of the skin or parietal pleura during the initial injury often allows air to enter the subcutaneous tissues of the chest wall, which is detected as **subcutaneous crepitus** (ie, crackling during palpation).

(Choice A) Bronchophony is a phenomenon in which spoken words (eg, "ninety-nine," "toy boat") are heard more

https://t.me/USMLEWorldStep1

This patient experienced sudden-onset shortness of breath and chest pain following chest trauma; chest x-ray shows several rib fractures and a collapsed right lung, findings consistent with **traumatic pneumothorax**.

Traumatic pneumothorax can result from puncture of either the chest wall (eg, penetrating chest trauma) or the lung (eg, by fractured ribs), allowing air to enter the pleural space. The communication pathway causes intrapleural pressure to equalize with atmospheric pressure (ie, **loss of intrapleural negative pressure**), which prevents lung expansion during inspiration and leads to **breathing difficulty**.

Because air in the pleural space insulates sounds and vibrations originating in the airways, physical examination reveals **decreased breath sounds** and **decreased tactile fremitus** on the affected side. In addition, the relatively low density of air compared to normal lung tissue causes **hyperresonance** to percussion. Disruption of the skin or parietal pleura during the initial injury often allows air to enter the subcutaneous tissues of the chest wall, which is detected as **subcutaneous crepitus** (ie, crackling during palpation).

(Choice A) Bronchophony is a phenomenon in which spoken words (eg, "ninety-nine," "toy boat") are heard more loudly and clearly when auscultated over an area of alveolar consolidation (eg, lobar pneumonia) compared to normal lung. It results from increased sound transmission due to increased tissue density.

(Choice B) Dullness to percussion over the chest is expected with conditions that cause increased density (eg, hemothorax, pleural effusion, alveolar consolidation) compared to normal lung tissue.

(Choice C) The increased thoracic pressure with pneumothorax flattens the resting position of the diaphragm and restricts its movement with respiration. Therefore, diaphragmatic excursion (the distance the diaphragm moves between expiration and inspiration) is decreased.

(Choices D and F) Prolonged expiration and wheezing are expected with bronchoconstriction, usually in the setting of obstructive lung disease (eg, asthma, chronic obstructive pulmonary disease). Bronchoconstriction is not expected with pneumothorax.

Educational objective:
Traumatic pneumothorax can involve puncture of either the chest wall (eg, penetrating chest trauma) or the lung (eg, by fractured ribs), allowing air to enter the pleural space. Patients usually experience chest pain and difficulty breathing. Crepitus, caused by air in the subcutaneous tissues of the chest wall, is often present on physical

https://t.me/USMLEWorldStep1

Traumatic pneumothorax can result from puncture of either the chest wall (eg, penetrating chest trauma) or the lung (eg, by fractured ribs), allowing air to enter the pleural space. The communication pathway causes intrapleural pressure to equalize with atmospheric pressure (ie, **loss of intrapleural negative pressure**), which prevents lung expansion during inspiration and leads to **breathing difficulty**.

Because air in the pleural space insulates sounds and vibrations originating in the airways, physical examination reveals **decreased breath sounds** and **decreased tactile fremitus** on the affected side. In addition, the relatively low density of air compared to normal lung tissue causes **hyperresonance** to percussion. Disruption of the skin or parietal pleura during the initial injury often allows air to enter the subcutaneous tissues of the chest wall, which is detected as **subcutaneous crepitus** (ie, crackling during palpation).

(Choice A) Bronchophony is a phenomenon in which spoken words (eg, "ninety-nine," "toy boat") are heard more loudly and clearly when auscultated over an area of alveolar consolidation (eg, lobar pneumonia) compared to normal lung. It results from increased sound transmission due to increased tissue density.

(Choice B) Dullness to percussion over the chest is expected with conditions that cause increased density (eg, hemothorax, pleural effusion, alveolar consolidation) compared to normal lung tissue.

(Choice C) The increased thoracic pressure with pneumothorax flattens the resting position of the diaphragm and restricts its movement with respiration. Therefore, diaphragmatic excursion (the distance the diaphragm moves between expiration and inspiration) is decreased.

(Choices D and F) Prolonged expiration and wheezing are expected with bronchoconstriction, usually in the setting of obstructive lung disease (eg, asthma, chronic obstructive pulmonary disease). Bronchoconstriction is not expected with pneumothorax.

Educational objective:
Traumatic pneumothorax can involve puncture of either the chest wall (eg, penetrating chest trauma) or the lung (eg, by fractured ribs), allowing air to enter the pleural space. Patients usually experience chest pain and difficulty breathing. Crepitus, caused by air in the subcutaneous tissues of the chest wall, is often present on physical examination.

References

- Principles of diagnosis and management of traumatic pneumothorax.

https://t.me/USMLEWorldStep1

This patient experienced sudden-onset shortness of breath and chest pain following chest trauma; chest x-ray shows

Exhibit Display

Rib fractures and pneumothorax

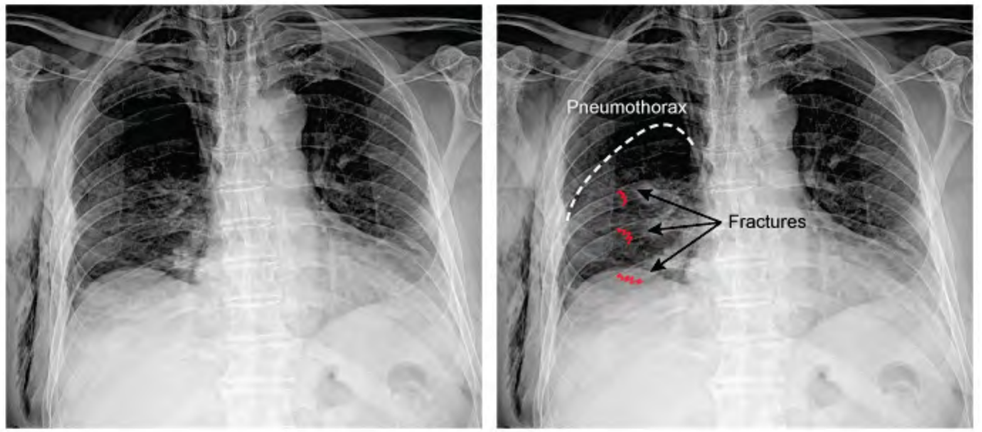

©UWorld

Zoom In | Zoom Out | Reset | New | Existing | My Notebook

Traum
lung (e
intrapl
prever

Becau
reveal
low de
parieta
detect

(Choi
loudly
norma

(Choi
hemot

(Choi
restric
betwe

(Choi
setting
expect

Educa
Traum
(eg, by fractured ribs), allowing air to enter the pleural space. Patients usually experience chest pain and difficulty breathing. Crepitus, caused by air in the subcutaneous tissues of the chest wall, is often present on physical

https://t.me/USMLEWorldStep1

This patient experienced sudden-onset shortness of breath and chest pain following chest trauma; chest x-ray shows

Exhibit Display

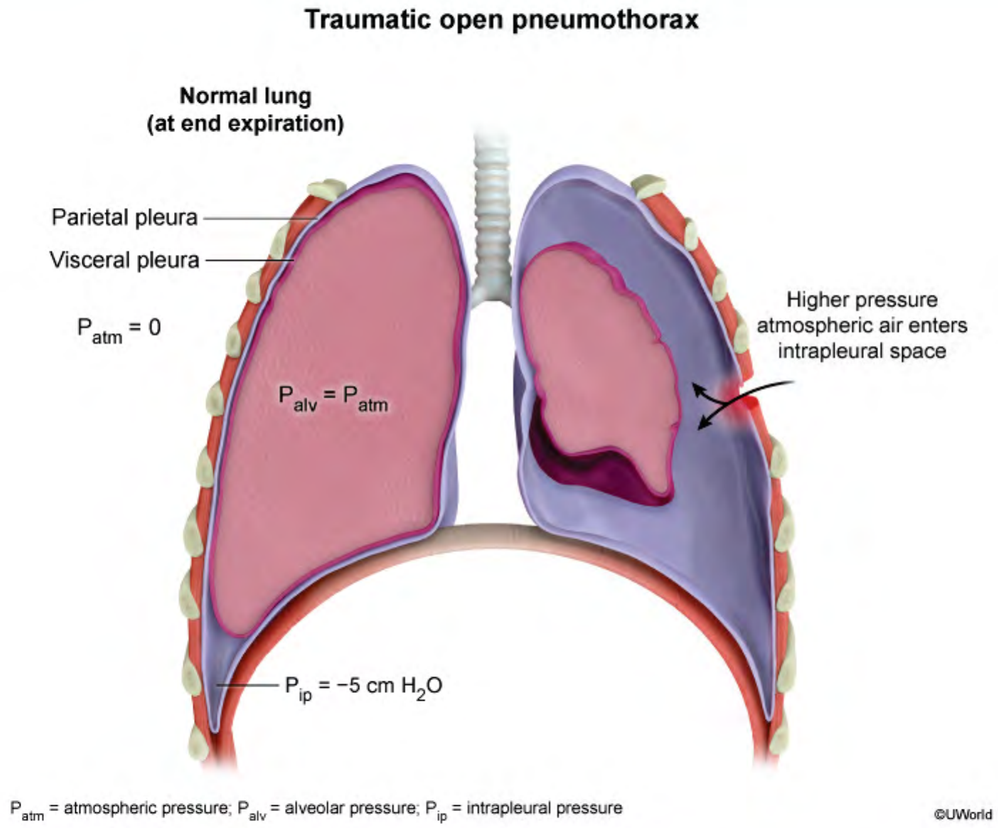

Zoom In | Zoom Out | Reset | New | Existing | My Notebook

Traum
lung (e
intrapl
prever

Becau
reveal
low de
parieta
detect

(Choi
loudly
norma

(Choi
hemot

(Choi
restric
betwe

(Choi
setting
expect

Educa
Traum
(eg, by fractured ribs), allowing air to enter the pleural space. Patients usually experience chest pain and difficulty breathing. Crepitus, caused by air in the subcutaneous tissues of the chest wall, is often present on physical

https://t.me/USMLEWorldStep1

This patient experienced sudden-onset shortness of breath and chest pain following chest trauma; chest x-ray shows

Exhibit Display

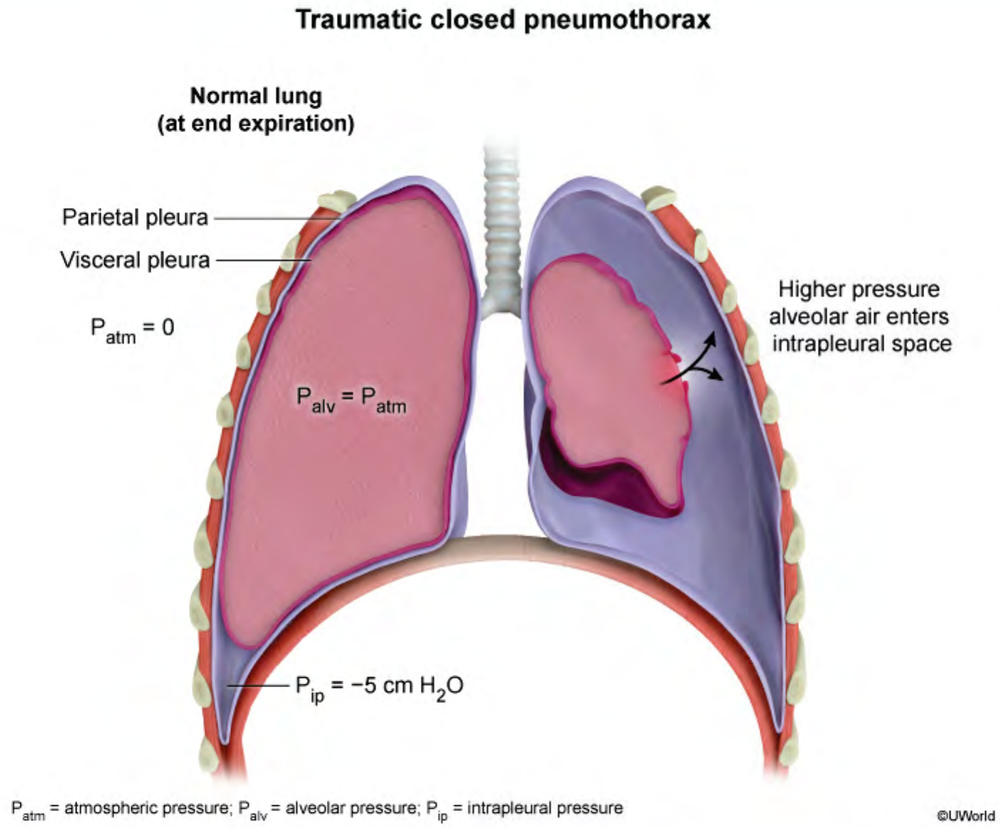

Zoom In | Zoom Out | Reset | New | Existing | My Notebook

Trauma
lung (e
intrapl
prever

Becau
reveal
low de
parieta
detect

(Choi
loudly
norma

(Choi
hemot

(Choi
restric
betwe

(Choi
setting
expect

Educa
Traum
(eg, by fractured ribs), allowing air to enter the pleural space. Patients usually experience chest pain and difficulty breathing. Crepitus, caused by air in the subcutaneous tissues of the chest wall, is often present on physical

https://t.me/USMLEWorldStep1

A 36-year-old woman comes to the clinic for evaluation of a 4-month history of nonproductive cough and exertional dyspnea. Her only other medical problem is frequent heartburn, for which she takes over-the-counter antacids. Temperature is 37.1 C (98.8 F), blood pressure is 126/74 mm Hg, pulse is 88/min, and respirations are 20/min. Examination shows bilateral crackles and normal heart sounds. The remainder of the examination is unremarkable. Chest imaging shows bilateral interstitial opacities. Bronchioalveolar lavage reveals >50% of cells being lymphocytes. Which of the following is the most likely diagnosis?

- A. Asbestosis
- B. Asthma
- C. Chronic aspiration
- D. Hypersensitivity pneumonitis
- E. Pulmonary edema

Submit

https://t.me/USMLEWorldStep1

A 36-year-old woman comes to the clinic for evaluation of a 4-month history of nonproductive cough and exertional dyspnea. Her only other medical problem is frequent heartburn, for which she takes over-the-counter antacids. Temperature is 37.1 C (98.8 F), blood pressure is 126/74 mm Hg, pulse is 88/min, and respirations are 20/min. Examination shows bilateral crackles and normal heart sounds. The remainder of the examination is unremarkable. Chest imaging shows bilateral interstitial opacities. Bronchioalveolar lavage reveals >50% of cells being lymphocytes. Which of the following is the most likely diagnosis?

- A. Asbestosis (3%)
- B. Asthma (7%)
- ✗ C. Chronic aspiration (21%)
- ✓ D. Hypersensitivity pneumonitis (61%)
- E. Pulmonary edema (6%)

Incorrect
Correct answer
D

61%
Answered correctly

12 mins, 45 secs
Time Spent

2023
Version

Explanation

Hypersensitivity pneumonitis	
Etiology	• Immunologic response to inhaled antigen (eg, mold, animal protein)
Clinical presentation	**Acute** • Abrupt-onset fever, chills, cough, dyspnea, fatigue, leukocytosis • Episodes often recurrent & self-resolving **Chronic**

https://t.me/USMLEWorldStep1

Hypersensitivity pneumonitis	
Etiology	• Immunologic response to inhaled antigen (eg, mold, animal protein)
Clinical presentation	**Acute** • Abrupt-onset fever, chills, cough, dyspnea, fatigue, leukocytosis • Episodes often recurrent & self-resolving **Chronic** • Progressive cough, dyspnea, fatigue, weight loss • Hypoxemia that worsens with exertion • Chest x-ray: diffuse reticular interstitial opacities (interstitial fibrosis)
Diagnosis	• PFT: restrictive pattern • BAL: high relative lymphocyte count • Lung biopsy: lymphocytic infiltrate, poorly formed noncaseating granulomas, interstitial fibrosis (chronic only)
Treatment	• Remove antigen exposure (resolves acute disease)
BAL = bronchoalveolar lavage; **PFT** = pulmonary function testing.	

This patient with several months of nonproductive cough and exertional dyspnea as well as a **lymphocyte-predominant bronchoalveolar lavage** (BAL) most likely has **hypersensitivity pneumonitis** (HP). HP results from an exaggerated immunologic response that some individuals develop to an **inhaled antigen** (eg, mold, animal protein). Those most commonly affected include farmers (ie, **farmer's lung** due to exposure to moldy hay) and bird keepers (ie, **bird fancier's lung** due to exposure to avian proteins).

The presentation of HP can be acute or chronic. Acute disease usually involves recurrent episodes of abrupt-onset cough, dyspnea, fever, chills, and fatigue that correlate with intermittent antigen exposure. Chronic disease likely results from chronic, long-term antigen exposure, and presents with gradually progressive cough, dyspnea, fatigue, and weight loss over a period of several months. Lung crackles are present with both acute and chronic disease.

https://t.me/USMLEWorldStep1

This patient with several months of nonproductive cough and exertional dyspnea as well as a **lymphocyte-predominant bronchoalveolar lavage** (BAL) most likely has **hypersensitivity pneumonitis** (HP). HP results from an exaggerated immunologic response that some individuals develop to an **inhaled antigen** (eg, mold, animal protein). Those most commonly affected include farmers (ie, **farmer's lung** due to exposure to moldy hay) and bird keepers (ie, **bird fancier's lung** due to exposure to avian proteins).

The presentation of HP can be acute or chronic. Acute disease usually involves recurrent episodes of abrupt-onset cough, dyspnea, fever, chills, and fatigue that correlate with intermittent antigen exposure. Chronic disease likely results from chronic, long-term antigen exposure, and presents with gradually progressive cough, dyspnea, fatigue, and weight loss over a period of several months. Lung crackles are present with both acute and chronic disease. Chest x-ray in acute disease is frequently normal, whereas **diffuse reticular interstitial opacities** are present with **chronic disease** as a network of interstitial inflammation and **fibrosis** develops.

Normally, the leukocytes in alveolar fluid consist of approximately 85% alveolar macrophages, 10% lymphocytes, and a small percentage of neutrophils and eosinophils. With both acute and chronic HP, **BAL usually shows high relative lymphocyte count** (eg, >20%, often >50%), which helps support the diagnosis. Other causes of high relative lymphocyte count in BAL include sarcoidosis, lymphoma, and chronic fungal or mycobacterial infection.

(Choice A) Asbestosis can present with progressive dyspnea and cough, but BAL typically shows increased neutrophils and characteristic asbestos bodies.

(Choice B) Asthma is expected to cause wheezing rather than crackles on lung auscultation. BAL may show increased eosinophils as well as bronchial epithelial cells.

(Choice C) Patients with gastroesophageal reflux disease can have chronic microaspiration, leading to respiratory symptoms (eg, cough, dyspnea). However, BAL typically shows increased neutrophils and characteristic lipid-laden macrophages that result from the aspiration of lipid-containing food or drink.

(Choice E) BAL in cardiogenic pulmonary edema often demonstrates hemosiderin-laden macrophages, resulting from elevated pulmonary capillary hydrostatic pressure leading to extravasation of red blood cells into the alveoli. Leukocyte percentages are not significantly affected.

Educational objective:

https://t.me/USMLEWorldStep1

animal protein). Those most commonly affected include farmers (ie, **farmer's lung** due to exposure to moldy hay) and bird keepers (ie, **bird fancier's lung** due to exposure to avian proteins).

The presentation of HP can be acute or chronic. Acute disease usually involves recurrent episodes of abrupt-onset cough, dyspnea, fever, chills, and fatigue that correlate with intermittent antigen exposure. Chronic disease likely results from chronic, long-term antigen exposure, and presents with gradually progressive cough, dyspnea, fatigue, and weight loss over a period of several months. Lung crackles are present with both acute and chronic disease. Chest x-ray in acute disease is frequently normal, whereas **diffuse reticular interstitial opacities** are present with **chronic disease** as a network of interstitial inflammation and **fibrosis** develops.

Normally, the leukocytes in alveolar fluid consist of approximately 85% alveolar macrophages, 10% lymphocytes, and a small percentage of neutrophils and eosinophils. With both acute and chronic HP, **BAL usually shows high relative lymphocyte count** (eg, >20%, often >50%), which helps support the diagnosis. Other causes of high relative lymphocyte count in BAL include sarcoidosis, lymphoma, and chronic fungal or mycobacterial infection.

(Choice A) Asbestosis can present with progressive dyspnea and cough, but BAL typically shows increased neutrophils and characteristic asbestos bodies.

(Choice B) Asthma is expected to cause wheezing rather than crackles on lung auscultation. BAL may show increased eosinophils as well as bronchial epithelial cells.

(Choice C) Patients with gastroesophageal reflux disease can have chronic microaspiration, leading to respiratory symptoms (eg, cough, dyspnea). However, BAL typically shows increased neutrophils and characteristic lipid-laden macrophages that result from the aspiration of lipid-containing food or drink.

(Choice E) BAL in cardiogenic pulmonary edema often demonstrates hemosiderin-laden macrophages, resulting from elevated pulmonary capillary hydrostatic pressure leading to extravasation of red blood cells into the alveoli. Leukocyte percentages are not significantly affected.

Educational objective:
Hypersensitivity pneumonitis results from an exaggerated immunologic response to an inhaled antigen (eg, mold, animal protein), and presents with cough and dyspnea of variable acuity. Bronchoalveolar lavage typically shows high relative lymphocyte count (eg, >20%), which helps support the diagnosis.

https://t.me/USMLEWorldStep1

A 63-year-old man comes to the office due to 3 months of increasing cough with occasional hemoptysis, night sweats, and unintentional weight loss. The patient recently emigrated from South Africa, where he had worked for many years in the gold mines. He has a history of silicosis that was diagnosed 10 years ago. Vital signs show a low-grade fever. Physical examination reveals diffuse, fine crackles with right upper lobe predominance. Chest x-ray shows diffuse, small nodules; hilar adenopathy with prominent calcifications; and a cavitary lung lesion in the right upper lobe. A sputum sample is sent for appropriate staining and culture. This patient's increased susceptibility to the current infection is best explained by which of the following factors?

- A. Extensive pulmonary fibrosis
- B. Impaired immunoglobulin G response
- C. Impaired macrophage function
- D. Impaired type 2 helper T cell function
- E. Ineffective mucociliary clearance

Submit

https://t.me/USMLEWorldStep1

A 63-year-old man comes to the office due to 3 months of increasing cough with occasional hemoptysis, night sweats, and unintentional weight loss. The patient recently emigrated from South Africa, where he had worked for many years in the gold mines. He has a history of silicosis that was diagnosed 10 years ago. Vital signs show a low-grade fever. Physical examination reveals diffuse, fine crackles with right upper lobe predominance. Chest x-ray shows diffuse, small nodules; hilar adenopathy with prominent calcifications; and a cavitary lung lesion in the right upper lobe. A sputum sample is sent for appropriate staining and culture. This patient's increased susceptibility to the current infection is best explained by which of the following factors?

- A. Extensive pulmonary fibrosis (15%)
- ✗ B. Impaired immunoglobulin G response (0%)
- ✓ C. Impaired macrophage function (68%)
- D. Impaired type 2 helper T cell function (7%)
- E. Ineffective mucociliary clearance (7%)

Incorrect
Correct answer
C

68%
Answered correctly

05 secs
Time Spent

2023
Version

Explanation

This patient with a history of silicosis has developed hemoptysis, night sweats, weight loss, and a cavitary lung lesion in the upper lobe; this is highly suggestive of tuberculosis infection. **Silicosis** is an occupational lung disease that occurs after inhalation of crystalline silica and is characterized by multiple rounded nodules located in the upper lobes. Patients may also develop calcification of the rim of hilar lymph nodes (eggshell calcification).

Silicosis is associated with increased risk of mycobacterial infections, particularly ***Mycobacterium tuberculosis***, due to **impaired macrophage function**. It is thought that macrophage phagolysosomes are disrupted by internalized silica particles, leading to impaired phagocytosis and increased apoptosis.

https://t.me/USMLEWorldStep1

Explanation

This patient with a history of silicosis has developed hemoptysis, night sweats, weight loss, and a cavitary lung lesion in the upper lobe; this is highly suggestive of tuberculosis infection. **Silicosis** is an occupational lung disease that occurs after inhalation of crystalline silica and is characterized by multiple rounded nodules located in the upper lobes. Patients may also develop calcification of the rim of hilar lymph nodes (eggshell calcification).

Silicosis is associated with increased risk of mycobacterial infections, particularly ***Mycobacterium tuberculosis***, due to **impaired macrophage function**. It is thought that macrophage phagolysosomes are disrupted by internalized silica particles, leading to impaired phagocytosis and increased apoptosis.

(Choice A) Although interstitial fibrosis can be caused by silicosis, fibrosis alone would not greatly predispose to mycobacterial infection. In fact, scarred areas of lung would be less accessible and may limit spread of microbial pathogens.

(Choices B and D) Th2 cells are important for mediating humoral immunity and combating parasitic infections. However, humoral immunity does not play a major role in eliminating mycobacterial infections due to the intracellular survivability of these pathogens.

(Choice E) Impaired mucociliary clearance, which occurs in patients with cystic fibrosis, can result in recurrent pulmonary infections due to impaired pathogen clearance. However, mucociliary clearance is not directly impaired by silicosis.

Educational objective:
In silicosis, internalized silica particles impair macrophage function by disrupting phagocytosis and promoting apoptosis. This increases the risk of mycobacteria infection (particularly *M tuberculosis*).

References

- Silicosis.

Pathophysiology	Pulmonary & Critical Care	Silicosis
Subject	System	Topic

Copyright © UWorld. All rights reserved.

https://t.me/USMLEWorldStep1

A 35-year-old previously healthy woman comes to the hospital due to several days of productive cough associated with chills and fever. Her sputum is purulent with faint pink streaks of blood. The patient also has sharp pain over the right shoulder and neck area brought on by deep inspiration. Past medical history is unremarkable. Her temperature is 38.3 C (101 F), blood pressure is 130/70 mm Hg, pulse is 98/min, and respirations are 22/min. Examination reveals crackles and dullness over the right lower pulmonary lobe. While listening with the stethoscope over the right midback, the examiner has the patient say the letter "E," and the sound is perceived by the examiner as a loud letter "A." A chest x-ray is obtained and is shown in the image below.

https://t.me/USMLEWorldStep1

A 35-year-old previously healthy woman comes to the hospital due to several days of productive cough associated
with ch
the rig
tempe
Exami
stetho
the ex

Exhibit Display

Zoom In Zoom Out Reset New | Existing My Notebook

https://t.me/USMLEWorldStep1

The pain experienced by this patient is most likely carried by which of the following nerves?

- A. Accessory
- B. Intercostal
- C. Long thoracic
- D. Phrenic
- E. Vagus

Submit

https://t.me/USMLEWorldStep1

The pain experienced by this patient is most likely carried by which of the following nerves?

- A. Accessory (4%)
- B. Intercostal (4%)
- C. Long thoracic (4%)
- ✓ D. Phrenic (81%)
- E. Vagus (3%)

Correct

81%
Answered correctly

28 secs
Time Spent

2023
Version

https://t.me/USMLEWorldStep1

Explanation

This patient is experiencing pleuritic chest pain due to acute lower lobe bacterial pneumonia. **Pleuritic chest pain** is characterized by sharp, localized, often severe pain that is exacerbated by coughing, breathing, or changing position. It can result from any condition that causes inflammation of the pleura (eg, infection, pulmonary embolism, uremia). The pleura are divided into segments as follows:

Visceral pleura: The visceral (pulmonary) pleura covers all surfaces of the lungs, including the surfaces within the pulmonary fissures. The visceral pleura does not carry pain fibers.

Parietal pleura: The parietal pleura forms the outer boundary of the pleural space and can be subdivided as follows:

- **Costal pleura:** Covers the thoracic wall, including the ribs, sternum, intercostal spaces, costal cartilages, and sides of the thoracic vertebrae
- **Mediastinal pleura:** Covers the mediastinum
- **Diaphragmatic pleura:** Covers the surface of the diaphragm located within the thoracic cavity
- **Cervical pleura:** Extends with the apices of the lung into the neck

The **phrenic nerve**, which is derived from the C3-C5 nerve roots, delivers motor innervation to the diaphragm and carries pain fibers from the **diaphragmatic and mediastinal pleura**. Irritation of the pleura in either area will cause a sharp pain worsened by inspiration that will be referred to the C3-C5 distribution at the base of the neck and over the shoulder. Sensory innervation of the remainder of the parietal pleura is accomplished by intercostal nerves and is typically felt closer to the source of the pain **(Choice B)**.

(Choice A) The spinal accessory nerve (cranial nerve XI) provides motor innervation to the sternocleidomastoid and trapezius muscles.

(Choice C) The long thoracic nerve innervates the serratus anterior. Damage to this nerve causes a winged scapula.

(Choice E) The vagus nerve (cranial nerve X) is the major source of parasympathetic innervation to the viscera of the chest and the foregut.

https://t.me/USMLEWorldStep1

Visceral pleura: The visceral (pulmonary) pleura covers all surfaces of the lungs, including the surfaces within the pulmonary fissures. The visceral pleura does not carry pain fibers.

Parietal pleura: The parietal pleura forms the outer boundary of the pleural space and can be subdivided as follows:

- **Costal pleura:** Covers the thoracic wall, including the ribs, sternum, intercostal spaces, costal cartilages, and sides of the thoracic vertebrae
- **Mediastinal pleura:** Covers the mediastinum
- **Diaphragmatic pleura:** Covers the surface of the diaphragm located within the thoracic cavity
- **Cervical pleura:** Extends with the apices of the lung into the neck

The **phrenic nerve**, which is derived from the C3-C5 nerve roots, delivers motor innervation to the diaphragm and carries pain fibers from the **diaphragmatic and mediastinal pleura**. Irritation of the pleura in either area will cause a sharp pain worsened by inspiration that will be referred to the C3-C5 distribution at the base of the neck and over the shoulder. Sensory innervation of the remainder of the parietal pleura is accomplished by intercostal nerves and is typically felt closer to the source of the pain **(Choice B)**.

(Choice A) The spinal accessory nerve (cranial nerve XI) provides motor innervation to the sternocleidomastoid and trapezius muscles.

(Choice C) The long thoracic nerve innervates the serratus anterior. Damage to this nerve causes a winged scapula.

(Choice E) The vagus nerve (cranial nerve X) is the major source of parasympathetic innervation to the viscera of the chest and the foregut.

Educational objective:
Irritation of the parietal pleura will cause sharp pain, which is worse on inspiration. Pain arising from the mediastinal or diaphragmatic pleura will be carried by the phrenic nerve and referred to the C3-C5 distribution.

Anatomy	Pulmonary & Critical Care	Community acquired pneumonia
Subject	System	Topic

Copyright © UWorld. All rights reserved.

https://t.me/USMLEWorldStep1

Health authorities are investigating an outbreak of respiratory infections among a group of military recruits. Fifteen recruits reported persistent cough, low-grade fever, and malaise. Apart from the low-grade fever, physical examination was largely unremarkable. Chest x-rays were all notable for pulmonary infiltrates that appeared more severe than what would have been expected based on assessment of the patients' clinical status. Sputum specimens were obtained, and the causative organism required a complex acellular medium enriched with cholesterol to grow. Which of the following organisms is the most likely cause of the outbreak?

- A. *Coccidioides immitis*
- B. *Coxiella burnetii*
- C. *Haemophilus influenzae*
- D. *Histoplasma capsulatum*
- E. *Klebsiella pneumoniae*
- F. *Legionella pneumophila*
- G. *Mycoplasma pneumoniae*
- H. *Pneumocystis jirovecii*
- I. *Streptococcus pneumoniae*

Submit

https://t.me/USMLEWorldStep1

Health authorities are investigating an outbreak of respiratory infections among a group of military recruits. Fifteen recruits reported persistent cough, low-grade fever, and malaise. Apart from the low-grade fever, physical examination was largely unremarkable. Chest x-rays were all notable for pulmonary infiltrates that appeared more severe than what would have been expected based on assessment of the patients' clinical status. Sputum specimens were obtained, and the causative organism required a complex acellular medium enriched with cholesterol to grow. Which of the following organisms is the most likely cause of the outbreak?

- A. *Coccidioides immitis* (0%)
- B. *Coxiella burnetii* (1%)
- ✗ C. *Haemophilus influenzae* (1%)
- D. *Histoplasma capsulatum* (0%)
- E. *Klebsiella pneumoniae* (1%)
- F. *Legionella pneumophila* (7%)
- ✓ G. *Mycoplasma pneumoniae* (84%)
- H. *Pneumocystis jirovecii* (0%)
- I. *Streptococcus pneumoniae* (0%)

Incorrect
Correct answer
G

84%
Answered correctly

04 secs
Time Spent

2023
Version

Explanation

These patients have "**walking pneumonia**," an infection generally caused by ***Mycoplasma pneumoniae***. Patients experience a low-grade fever, malaise, and a chronic, dry nagging cough. A classic sign is a chest x-ray revealing findings that are much **worse** than the clinical appearance of the patient. Another clue for *M pneumoniae*

https://t.me/USMLEWorldStep1

Explanation

These patients have "**walking pneumonia**," an infection generally caused by ***Mycoplasma pneumoniae***. Patients experience a low-grade fever, malaise, and a chronic, dry nagging cough. A classic sign is a chest x-ray revealing findings that are much **worse** than the clinical appearance of the patient. Another clue for *M pneumoniae* infection is that the organisms require **cholesterol** to grow because their cell membrane is composed of a single cholesterol-rich phospholipid bilayer. They completely lack a peptidoglycan cell wall, cell envelope, or capsule. (Fungi also incorporate sterols into their cell membranes; however, fungi use ergosterol, a target for antifungal therapy.)

(Choices A and D) The fungus *Coccidioides immitis* causes San Joaquin Valley fever (known as "valley fever"). It is most common in the Southwest United States and Northern Mexico. *Histoplasma capsulatum* causes a similar illness, but it is typically localized to the Mississippi and Ohio River Valleys. Both organisms grow on standard fungal culture media.

(Choice B) *Coxiella burnetii* causes Q-fever, a pneumonia-like illness resulting from inhalation of *C burnetii* spores that commonly contaminate animal hides. *C burnetii* is an obligate intracellular parasite that must be provided a cell culture to grow.

(Choice C) *Haemophilus influenzae* requires chocolate agar (heat lysed blood agar), supplemented with factor X (hematin) and factor V (NAD+).

(Choice E) *Klebsiella pneumoniae* pneumonia classically presents with cough productive of red jelly-like sputum ("currant jelly sputum") in patients with alcohol use disorder. *K pneumoniae* can be grown on standard agar, but MacConkey agar is often preferred because it contains bile, which will inhibit the growth of contaminant organisms.

(Choice F) *Legionella pneumophila* requires an L-cysteine-supplemented agar to grow.

(Choice H) The fungus *Pneumocystis jirovecii* can cause severe pneumonia in HIV+ patients with CD4 cell counts <200/mm^3. Patients often have characteristic "ground glass" infiltrates on chest x-ray. *P jirovecii* pneumonia is diagnosed by silver staining the fluid collected during bronchoscopy.

(Choice I) *Streptococcus pneumoniae* would cause lobar consolidation on chest x-ray. This organism can grow

https://t.me/USMLEWorldStep1

cholesterol rich phospholipid bilayer. They completely lack a peptidoglycan cell wall, cell envelope, or capsule. (Fungi also incorporate sterols into their cell membranes; however, fungi use ergosterol, a target for antifungal therapy.)

(Choices A and D) The fungus *Coccidioides immitis* causes San Joaquin Valley fever (known as "valley fever"). It is most common in the Southwest United States and Northern Mexico. *Histoplasma capsulatum* causes a similar illness, but it is typically localized to the Mississippi and Ohio River Valleys. Both organisms grow on standard fungal culture media.

(Choice B) *Coxiella burnetii* causes Q-fever, a pneumonia-like illness resulting from inhalation of *C burnetii* spores that commonly contaminate animal hides. *C burnetii* is an obligate intracellular parasite that must be provided a cell culture to grow.

(Choice C) *Haemophilus influenzae* requires chocolate agar (heat lysed blood agar), supplemented with factor X (hematin) and factor V (NAD+).

(Choice E) *Klebsiella pneumoniae* pneumonia classically presents with cough productive of red jelly-like sputum ("currant jelly sputum") in patients with alcohol use disorder. *K pneumoniae* can be grown on standard agar, but MacConkey agar is often preferred because it contains bile, which will inhibit the growth of contaminant organisms.

(Choice F) *Legionella pneumophila* requires an L-cysteine-supplemented agar to grow.

(Choice H) The fungus *Pneumocystis jirovecii* can cause severe pneumonia in HIV+ patients with CD4 cell counts <200/mm^3. Patients often have characteristic "ground glass" infiltrates on chest x-ray. *P jirovecii* pneumonia is diagnosed by silver staining the fluid collected during bronchoscopy.

(Choice I) *Streptococcus pneumoniae* would cause lobar consolidation on chest x-ray. This organism can grow well on standard unenriched blood agar, but it is bile-soluble and cannot grow in the presence of optochin.

Educational objective:
Mycoplasma pneumoniae is the causative agent of "walking pneumonia," an infection typically characterized by a nagging nonproductive cough, low-grade fever, and malaise. Often, the chest x-ray suggests a severe pneumonia even though the patient appears relatively well. *Mycoplasma* species require cholesterol supplementation to grow on artificial media.

https://t.me/USMLEWorldStep1

A 68-year-old woman is brought to the emergency department due to worsening fever, cough, and confusion. The patient has had a "cold and congestion" since last week, which initially improved, but she began feeling worse again 3 days ago. Her daughter reports that the patient has also been eating poorly. Other medical conditions include chronic obstructive pulmonary disease and chronic kidney disease. Temperature is 39.4 C (102.9 F), blood pressure is 74/46 mm Hg, pulse is 128/min, and respirations are 30/min. Oxygen saturation is 94% on 2 L/min. On physical examination, the patient is lethargic with dry mucous membranes and flat neck veins. Lung examination reveals dullness to percussion and crackles at the right base. Chest x-ray shows a right lower lobe consolidation. Intravenous access is established. Intravenous administration of which of the following is the most appropriate next step in management of this patient?

- A. 0.45% saline
- B. 3% saline
- C. 5% dextrose in 0.45% saline
- D. Albumin solution
- E. Lactated Ringer solution
- F. Sodium bicarbonate solution

Submit

https://t.me/USMLEWorldStep1

A 68-year-old woman is brought to the emergency department due to worsening fever, cough, and confusion. The patient has had a "cold and congestion" since last week, which initially improved, but she began feeling worse again 3 days ago. Her daughter reports that the patient has also been eating poorly. Other medical conditions include chronic obstructive pulmonary disease and chronic kidney disease. Temperature is 39.4 C (102.9 F), blood pressure is 74/46 mm Hg, pulse is 128/min, and respirations are 30/min. Oxygen saturation is 94% on 2 L/min. On physical examination, the patient is lethargic with dry mucous membranes and flat neck veins. Lung examination reveals dullness to percussion and crackles at the right base. Chest x-ray shows a right lower lobe consolidation. Intravenous access is established. Intravenous administration of which of the following is the most appropriate next step in management of this patient?

- A. 0.45% saline (16%)
- ✗ B. 3% saline (11%)
- C. 5% dextrose in 0.45% saline (31%)
- D. Albumin solution (3%)
- ✓ E. Lactated Ringer solution (34%)
- F. Sodium bicarbonate solution (3%)

Incorrect
Correct answer
E

34%
Answered correctly

03 secs
Time Spent

2023
Version

Explanation

Intravenous fluids		
Tonicity	**Fluid type**	**Clinical use**
	0.9% (normal) saline	Volume resuscitation

https://t.me/USMLEWorldStep1

Intravenous fluids		
Tonicity	**Fluid type**	**Clinical use**
Isotonic	0.9% (normal) saline	Volume resuscitation (eg, hypovolemia, shock)
	Lactated Ringer solution	
	Albumin (5% or 25%)*	Volume replacement, treatment of SBP or HRS
Hypotonic	Dextrose 5% in water**	Free water deficit
	0.45% (half-normal) saline	
	Dextrose 5% in 0.45% (half-normal) saline**	Maintenance hydration
Hypertonic	3% (hypertonic) saline	Severe, symptomatic hyponatremia

HRS = hepatorenal syndrome; **SBP** = spontaneous bacterial peritonitis.
*Colloid solution; all other listed fluid types are crystalloid solutions.
**Dextrose 5% in water (initially slightly hypotonic) & dextrose 5% in 0.45% saline (initially hypertonic) become markedly hypotonic due to metabolism of glucose.

This patient with fever, cough, and radiologic evidence of consolidation in the right lower lung has **pneumonia**. Her tachycardia, **hypotension**, and confusion (evidence of **end-organ hypoperfusion**) are most likely due to **septic shock**, which is characterized by increased permeability of the vascular endothelium with leakage of intravascular fluid into the extravascular space.

In the management of septic shock, rapid restoration of intravascular volume and adequate end-organ perfusion is critical. This is best accomplished with the administration of boluses of **isotonic crystalloid** in the form of 0.9% (normal) saline or lactated Ringer solution through large-bore, peripheral intravenous catheters. These solutions are ideal for volume resuscitation because they have osmolarity very close to the normal osmolarity of the blood (~285 mOsm/kg H_2O), while the sodium and chloride ions help retain the fluid in the extracellular space.

https://t.me/USMLEWorldStep1

This patient with fever, cough, and radiologic evidence of consolidation in the right lower lung has **pneumonia**. Her tachycardia, **hypotension**, and confusion (evidence of **end-organ hypoperfusion**) are most likely due to **septic shock**, which is characterized by increased permeability of the vascular endothelium with leakage of intravascular fluid into the extravascular space.

In the management of septic shock, rapid restoration of intravascular volume and adequate end-organ perfusion is critical. This is best accomplished with the administration of boluses of **isotonic crystalloid** in the form of 0.9% (normal) saline or lactated Ringer solution through large-bore, peripheral intravenous catheters. These solutions are ideal for volume resuscitation because they have osmolarity very close to the normal osmolarity of the blood (~285 mOsm/kg H_2O), while the sodium and chloride ions help retain the fluid in the extracellular space.

Prompt initiation of appropriate empiric antibiotic therapy is also critical in the management of septic shock.

(Choices A and C) 0.45% (half-normal) saline is hypotonic; 5% dextrose in 0.45% saline is hypertonic initially but becomes hypotonic following infusion because the dextrose is rapidly metabolized. These hypotonic solutions are often used at low infusion rates for patients with a deficiency of free water (ie, hypernatremia) or for maintenance hydration. However, they are not effective for rapid volume resuscitation because the low osmolarity causes much of the fluid volume to shift into the intracellular space following infusion.

(Choice B) Infusion of 3% (hypertonic) saline can lead to rapid fluid-shifting from the intracellular to the extracellular space with potentially devastating consequences (eg, osmotic demyelination syndrome); therefore, 3% saline is not appropriate for rapid volume resuscitation. It is appropriate for careful use in patients with severe symptomatic hyponatremia.

(Choice D) Albumin solution is an isotonic colloid solution that can be used for rapid volume resuscitation. However, it is less preferred due to high cost and limited availability compared to isotonic crystalloid.

(Choice F) Sodium bicarbonate solutions can have variable tonicity and are typically used at low infusion rates for patients with severe metabolic acidosis. These solutions are generally not used for rapid volume resuscitation.

Educational objective:
The initial management of septic shock requires rapid fluid resuscitation to replace intravascular volume and restore adequate end-organ perfusion. This is best accomplished with intravenous boluses of isotonic crystalloid in

https://t.me/USMLEWorldStep1

intravascular fluid into the extravascular space.

In the management of septic shock, rapid restoration of intravascular volume and adequate end-organ perfusion is critical. This is best accomplished with the administration of boluses of **isotonic crystalloid** in the form of 0.9% (normal) saline or lactated Ringer solution through large-bore, peripheral intravenous catheters. These solutions are ideal for volume resuscitation because they have osmolarity very close to the normal osmolarity of the blood (~285 mOsm/kg H_2O), while the sodium and chloride ions help retain the fluid in the extracellular space.

Prompt initiation of appropriate empiric antibiotic therapy is also critical in the management of septic shock.

(Choices A and C) 0.45% (half-normal) saline is hypotonic; 5% dextrose in 0.45% saline is hypertonic initially but becomes hypotonic following infusion because the dextrose is rapidly metabolized. These hypotonic solutions are often used at low infusion rates for patients with a deficiency of free water (ie, hypernatremia) or for maintenance hydration. However, they are not effective for rapid volume resuscitation because the low osmolarity causes much of the fluid volume to shift into the intracellular space following infusion.

(Choice B) Infusion of 3% (hypertonic) saline can lead to rapid fluid-shifting from the intracellular to the extracellular space with potentially devastating consequences (eg, osmotic demyelination syndrome); therefore, 3% saline is not appropriate for rapid volume resuscitation. It is appropriate for careful use in patients with severe symptomatic hyponatremia.

(Choice D) Albumin solution is an isotonic colloid solution that can be used for rapid volume resuscitation. However, it is less preferred due to high cost and limited availability compared to isotonic crystalloid.

(Choice F) Sodium bicarbonate solutions can have variable tonicity and are typically used at low infusion rates for patients with severe metabolic acidosis. These solutions are generally not used for rapid volume resuscitation.

Educational objective:
The initial management of septic shock requires rapid fluid resuscitation to replace intravascular volume and restore adequate end-organ perfusion. This is best accomplished with intravenous boluses of isotonic crystalloid in the form of 0.9% (normal) saline or lactated Ringer solution because these solutions remain in the extracellular space.

https://t.me/USMLEWorldStep1

A 68-year-old man comes to the office for gradually increasing shortness of breath. He initially experienced symptoms with exertion but now feels short of breath at rest. The patient has smoked 2 packs of cigarettes per day for 40 years. Blood pressure is 138/78 mm Hg, pulse is 80/min, and respirations are 22/min. The chest x-ray is shown in the image below:

Which of the following measures is most likely increased in this patient?

- A. Diffusing capacity of the lung for carbon monoxide
- B. Forced expiratory volume in 1 second
- C. Forced expiratory volume in 1 second/forced vital capacity ratio
- D. Forced vital capacity
- E. Residual volume/total lung capacity ratio

Submit

https://t.me/USMLEWorldStep1

A 68-year-old man comes to the office for gradually increasing shortness of breath. He initially experienced
sympt
day fo
is sho

Exhibit Display

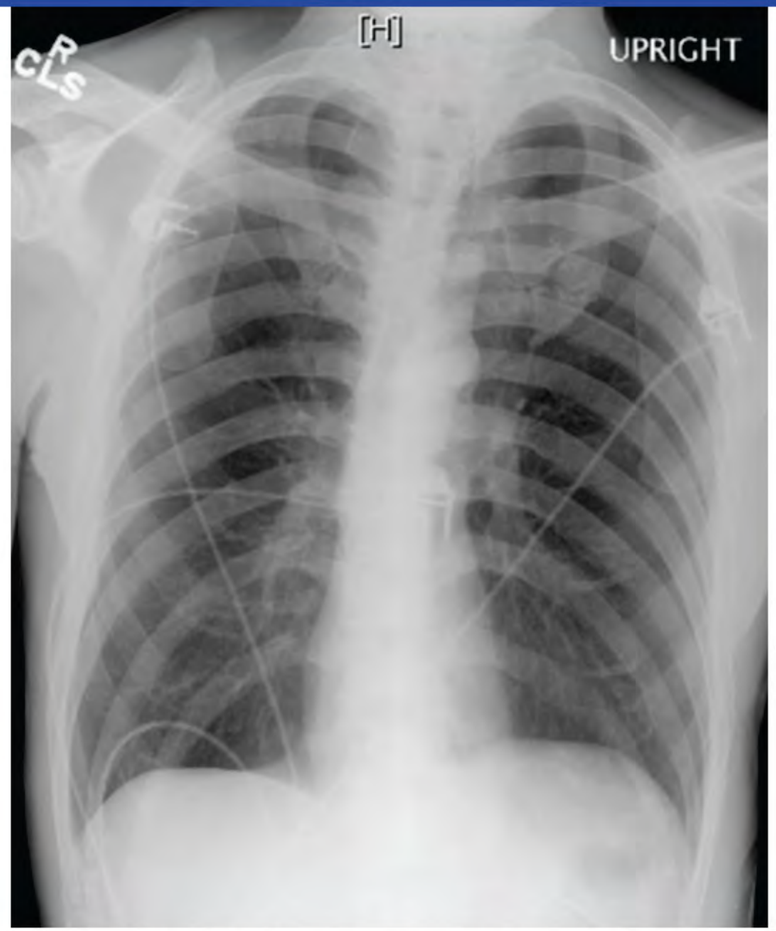

Zoom In Zoom Out Reset New | Existing My Notebook

https://t.me/USMLEWorldStep1

Which of the following measures is most likely increased in this patient?

- A. Diffusing capacity of the lung for carbon monoxide
- B. Forced expiratory volume in 1 second
- C. Forced expiratory volume in 1 second/forced vital capacity ratio
- D. Forced vital capacity
- E. Residual volume/total lung capacity ratio

Submit

https://t.me/USMLEWorldStep1

Which of the following measures is most likely increased in this patient?

- A. Diffusing capacity of the lung for carbon monoxide (3%)
- ✕ B. Forced expiratory volume in 1 second (1%)
- C. Forced expiratory volume in 1 second/forced vital capacity ratio (7%)
- D. Forced vital capacity (4%)
- ✓ E. Residual volume/total lung capacity ratio (83%)

Incorrect
Correct answer
E

83%
Answered correctly

16 secs
Time Spent

2023
Version

https://t.me/USMLEWorldStep1

Incorrect
Correct answer
E

83%
16 secs
2023

Exhibit Display

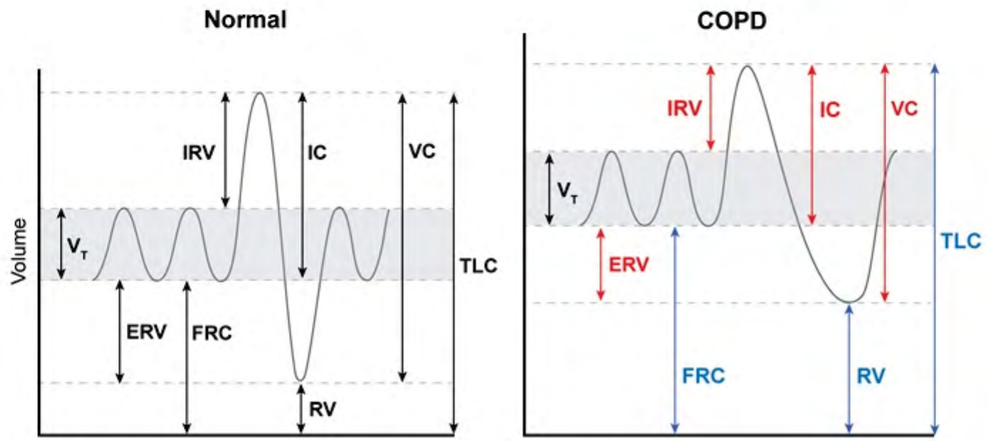

COPD = chronic obstructive pulmonary disease; **ERV** = expiratory reserve volume; **FRC** = functional residual capacity; **IC** = inspiratory capacity; **IRV** = inspiratory reserve volume; **RV** = residual volume; **TLC** = total lung capacity; **VC** = vital capacity; V_T = tidal volume.
©UWorld

Zoom In | Zoom Out | Reset | New | Existing | My Notebook

This p
chest
diseas

COPD
volum
volum
than RV. Therefore, the fraction of air in the lungs that is not involved in respiration, the **RV/TLC ratio**, is also **increased**. A high RV/TLC ratio correlates with poor outcomes in patients with COPD.

(Choice A) Diffusing capacity of the lung for carbon monoxide (DLCO) is decreased in COPD due to

https://t.me/USMLEWorldStep1

COPD = chronic obstructive pulmonary disease; **ERV** = expiratory reserve volume; **FRC** = functional residual capacity; **IC** = inspiratory capacity; **IRV** = inspiratory reserve volume; **RV** = residual volume; **TLC** = total lung capacity; **VC** = vital capacity; V_T = tidal volume.
©UWorld

This patient's presentation with progressive shortness of breath, significant smoking history, and **hyperinflation** on chest x-ray (flattened diaphragm, narrowed mediastinum) is consistent with **chronic obstructive pulmonary disease** (COPD).

COPD causes air trapping and hyperinflation of the lungs, so these patients breathe at higher baseline lung volumes (**higher functional residual capacity**). The volume of air in the lungs that is not respired, the **residual volume** (RV), is substantially **increased**. The **total lung capacity** (TLC) **increases** as well, but to a lesser extent than RV. Therefore, the fraction of air in the lungs that is not involved in respiration, the **RV/TLC ratio**, is also **increased**. A high RV/TLC ratio correlates with poor outcomes in patients with COPD.

(Choice A) Diffusing capacity of the lung for carbon monoxide (DLCO) is decreased in COPD due to emphysematous destruction of the alveolar-arterial membrane.

(Choices B, C, and D) Both forced vital capacity (FVC) and forced expiratory volume in 1 second (FEV1) are decreased in COPD due to airway obstruction. Because FEV1 is decreased more than FVC, the FEV1/FVC ratio is also decreased (<0.7 in COPD).

Educational objective:
Chronic obstructive pulmonary disease causes air trapping and hyperinflation; consequently, these patients breathe at higher baseline lung volumes (higher functional residual capacity). The volume of air in the lungs that is not respired (residual volume) increases substantially, as does the fraction of air in the lungs that is not involved in respiration (residual volume/total lung capacity ratio).

References

- The prognostic value of residual volume/total lung capacity in patients with chronic obstructive pulmonary disease.

https://t.me/USMLEWorldStep1

A 64-year-old man comes to the office due to 4 weeks of progressive dyspnea. For the past several months, he has had a nonproductive cough and fatigue. The patient's medical conditions include degenerative joint disease and peptic ulcer disease. He smoked 2 packs of cigarettes daily for 38 years but quit 4 years ago. On examination, there are decreased breath sounds and percussive dullness at the base of the right lung. Chest CT scan reveals a right-sided pleural effusion and diffuse nodular thickening of the pleura. On thoracentesis, bloody fluid is obtained. Pleural biopsy shows proliferation of epithelioid-type cells that are joined by desmosomes, contain abundant tonofilaments, and are studded with very long microvilli. Which of the following is the most likely diagnosis?

- A. Adenocarcinoma
- B. Carcinoid lung tumor
- C. Mesothelioma
- D. Small cell carcinoma
- E. Squamous cell carcinoma

Submit

https://t.me/USMLEWorldStep1

A 64-year-old man comes to the office due to 4 weeks of progressive dyspnea. For the past several months, he has had a nonproductive cough and fatigue. The patient's medical conditions include degenerative joint disease and peptic ulcer disease. He smoked 2 packs of cigarettes daily for 38 years but quit 4 years ago. On examination, there are decreased breath sounds and percussive dullness at the base of the right lung. Chest CT scan reveals a right-sided pleural effusion and diffuse nodular thickening of the pleura. On thoracentesis, bloody fluid is obtained. Pleural biopsy shows proliferation of epithelioid-type cells that are joined by desmosomes, contain abundant tonofilaments, and are studded with very long microvilli. Which of the following is the most likely diagnosis?

- ✗ A. Adenocarcinoma (9%)
- B. Carcinoid lung tumor (4%)
- ✓ C. Mesothelioma (58%)
- D. Small cell carcinoma (5%)
- E. Squamous cell carcinoma (21%)

Incorrect
Correct answer
C

58%
Answered correctly

06 secs
Time Spent

2023
Version

Explanation

This patient with progressive dyspnea and cough has nodular pleural thickening and a pleural effusion. This presentation, in conjunction with characteristic pathology findings, suggests mesothelioma. **Mesothelioma** is a rare, malignant neoplasm arising from mesothelial cells that line body cavities (eg, pleural, peritoneal, pericardial) and are characterized by numerous **long**, **slender microvilli** and abundant **tonofilaments**. Histopathology of the tumor cells can show an epithelioid (ie, epithelium-like) and/or sarcomatoid (ie, spindle-shaped) appearance. Immunohistochemical markers (eg, cytokeratin, calretinin) are useful in diagnosis.

https://t.me/USMLEWorldStep1

Explanation

This patient with progressive dyspnea and cough has nodular pleural thickening and a pleural effusion. This presentation, in conjunction with characteristic pathology findings, suggests mesothelioma. **Mesothelioma** is a rare, malignant neoplasm arising from mesothelial cells that line body cavities (eg, pleural, peritoneal, pericardial) and are characterized by numerous **long**, **slender microvilli** and abundant **tonofilaments**. Histopathology of the tumor cells can show an epithelioid (ie, epithelium-like) and/or sarcomatoid (ie, spindle-shaped) appearance. Immunohistochemical markers (eg, cytokeratin, calretinin) are useful in diagnosis.

Mesothelioma typically presents with slowly progressive **dyspnea**, **cough**, and chest pain. Pleural effusions are common and are often **hemorrhagic**. Radiography may demonstrate nodular or smooth, unilateral **pleural thickening** and plaque formation; the lung parenchyma is typically uninvolved. **Asbestos** exposure is the primary risk factor; individuals involved in asbestos mining and industrial applications (eg, insulation, shipbuilding) are at risk for mesothelioma.

(Choice A) Adenocarcinoma cells (which typically form glands and/or produce mucin) have short, plump microvilli that distinguish them from mesothelioma cells. Adenocarcinoma tends to involve peripheral lung parenchyma.

(Choice B) Pulmonary carcinoid tumors are neuroendocrine neoplasms that tend to involve the large bronchi. Histopathology typically shows uniform tumor cells with a "salt and pepper" chromatin pattern (ie, with fine and coarse clumps).

(Choice D) Small cell carcinoma is associated with smoking but usually arises from the major bronchi. On chest imaging, it is seen as a hilar mass. Histopathology shows small, blue, oval-shaped tumor cells with scant cytoplasm. Neuroendocrine markers (eg, chromogranin, synaptophysin) are usually positive.

(Choice E) Squamous cell carcinoma is associated with smoking but arises from the major bronchi; a hilar mass would be expected on imaging. Although desmosomes (intercellular bridges) can be seen in squamous cell carcinoma, imaging usually shows a central hilar mass (not pleural thickening).

Educational objective:
Malignant mesothelioma is a rare neoplasm typically arising from the pleura. It is strongly associated with asbestos exposure and presents with progressive dyspnea, cough, and chest pain. Unilateral pleural thickening or

https://t.me/USMLEWorldStep1

presentation, in conjunction with characteristic pathology findings, suggests mesothelioma. **Mesothelioma** is a rare, malignant neoplasm arising from mesothelial cells that line body cavities (eg, pleural, peritoneal, pericardial) and are characterized by numerous **long**, **slender microvilli** and abundant **tonofilaments**. Histopathology of the tumor cells can show an epithelioid (ie, epithelium-like) and/or sarcomatoid (ie, spindle-shaped) appearance. Immunohistochemical markers (eg, cytokeratin, calretinin) are useful in diagnosis.

Mesothelioma typically presents with slowly progressive **dyspnea**, **cough**, and chest pain. Pleural effusions are common and are often **hemorrhagic**. Radiography may demonstrate nodular or smooth, unilateral **pleural thickening** and plaque formation; the lung parenchyma is typically uninvolved. **Asbestos** exposure is the primary risk factor; individuals involved in asbestos mining and industrial applications (eg, insulation, shipbuilding) are at risk for mesothelioma.

(Choice A) Adenocarcinoma cells (which typically form glands and/or produce mucin) have short, plump microvilli that distinguish them from mesothelioma cells. Adenocarcinoma tends to involve peripheral lung parenchyma.

(Choice B) Pulmonary carcinoid tumors are neuroendocrine neoplasms that tend to involve the large bronchi. Histopathology typically shows uniform tumor cells with a "salt and pepper" chromatin pattern (ie, with fine and coarse clumps).

(Choice D) Small cell carcinoma is associated with smoking but usually arises from the major bronchi. On chest imaging, it is seen as a hilar mass. Histopathology shows small, blue, oval-shaped tumor cells with scant cytoplasm. Neuroendocrine markers (eg, chromogranin, synaptophysin) are usually positive.

(Choice E) Squamous cell carcinoma is associated with smoking but arises from the major bronchi; a hilar mass would be expected on imaging. Although desmosomes (intercellular bridges) can be seen in squamous cell carcinoma, imaging usually shows a central hilar mass (not pleural thickening).

Educational objective:
Malignant mesothelioma is a rare neoplasm typically arising from the pleura. It is strongly associated with asbestos exposure and presents with progressive dyspnea, cough, and chest pain. Unilateral pleural thickening or plaque formation is seen on imaging; pleural effusions are also common and may be hemorrhagic. Microscopic examination reveals tumor cells with numerous long, slender microvilli and abundant tonofilaments.

https://t.me/USMLEWorldStep1

Incorrect
Correct answer
C

58%
06 secs
2023

Exhibit Display

Normal mesothelial cell

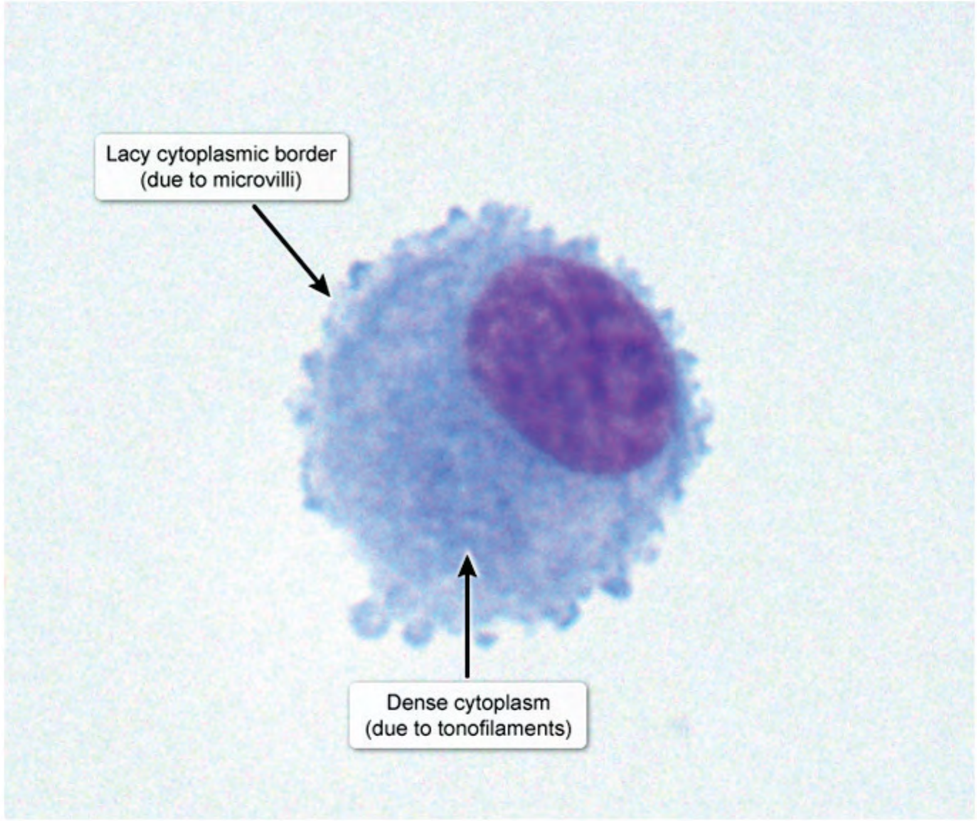

©UWorld

Zoom In | Zoom Out | Reset | New | Existing | My Notebook

Expl

This p
preser
rare, n
and ar
tumor
Immur

Mesot
comm
thicke
risk fa
risk fo

(Choi
that di

(Choi
Histop
coarse

(Choi
imagir
cytopla

(Choi
would be expected on imaging. Although desmosomes (intercellular bridges) can be seen in squamous cell carcinoma, imaging usually shows a central hilar mass (not pleural thickening).

https://t.me/USMLEWorldStep1

Incorrect
Correct answer
C

58%
06 secs
2023

Exhibit Display

Epithelioid mesothelioma

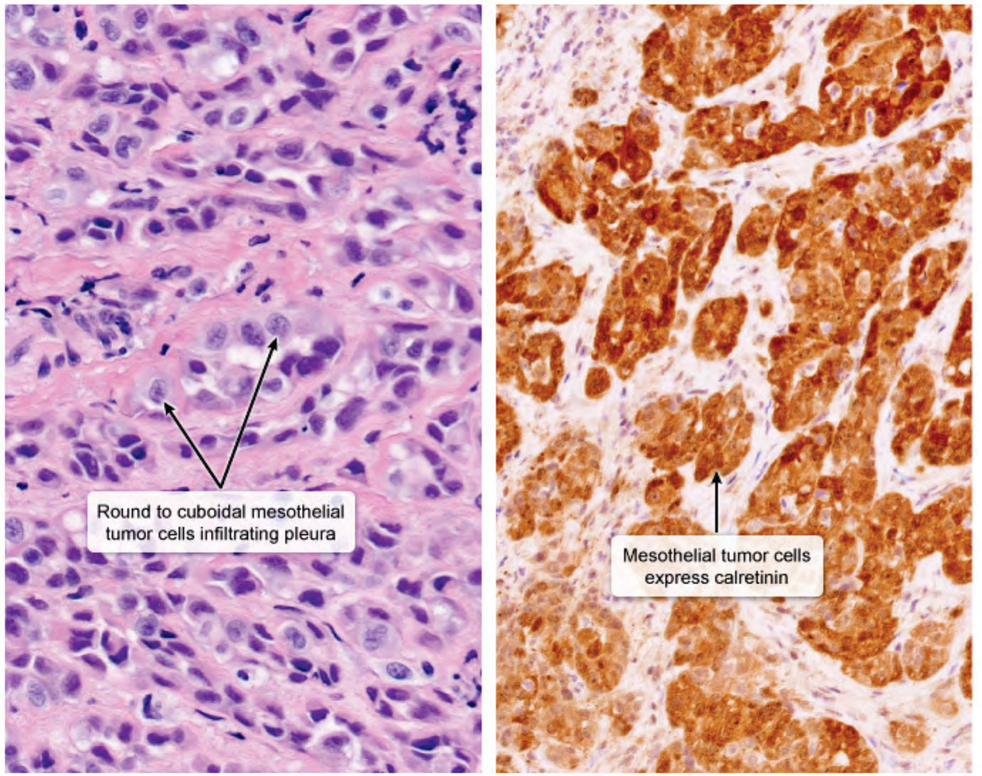

Hematoxylin & eosin stain

Calretinin stain

©UWorld

Zoom In | Zoom Out | Reset | New | Existing | My Notebook

Expl

This p
preser
rare, n
and ar
tumor
Immur

Mesot
comm
thicke
risk fa
risk fo

(Choi
that di

(Choi
Histop
coarse

(Choi
imagir
cytopla

(Choi
would be expected on imaging. Although desmosomes (intercellular bridges) can be seen in squamous cell carcinoma, imaging usually shows a central hilar mass (not pleural thickening).

https://t.me/USMLEWorldStep1

Incorrect
Correct answer
C

58%
Answered correctly

06 secs
Time Spent

2023
Version

Exhibit Display

Mesothelioma

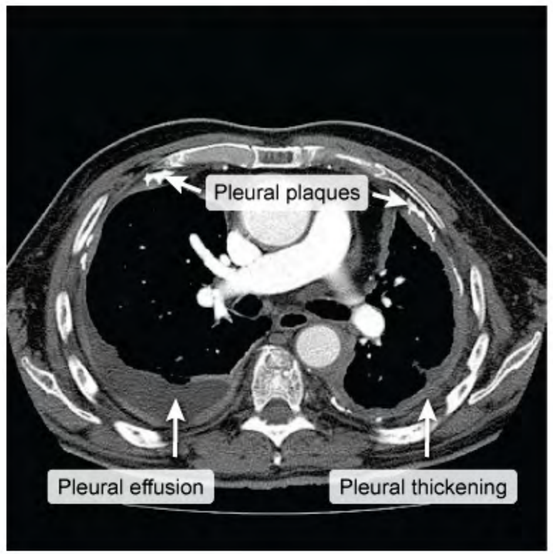

Zoom In | Zoom Out | Reset | New | Existing | My Notebook

Expl

This p
preser
rare, n
and ar
tumor
Immur

Mesot
comm
thicke
risk fa
risk fo

(Choi
that di

(Choi
Histop
coarse

(Choi
imagir
cytopla

(Choi
would be expected on imaging. Although desmosomes (intercellular bridges) can be seen in squamous cell carcinoma, imaging usually shows a central hilar mass (not pleural thickening).

https://t.me/USMLEWorldStep1

Incorrect
Correct answer
C

58%
06 secs
2023

Exhibit Display

Pulmonary adenocarcinoma

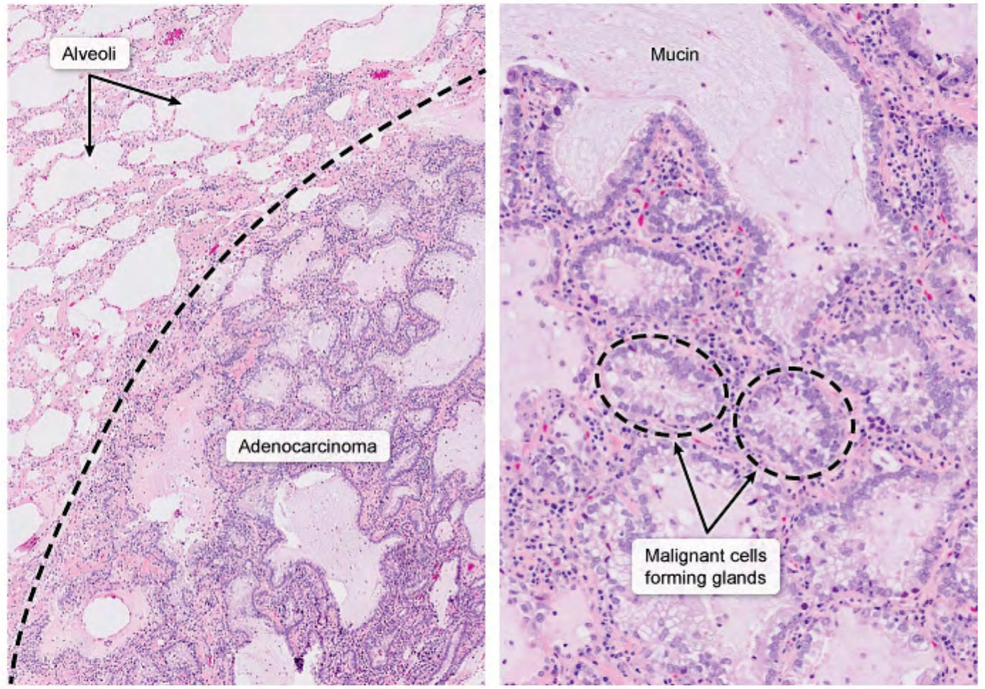

Zoom In | Zoom Out | Reset | New | Existing | My Notebook

Expl

This p
preser
rare, n
and ar
tumor
Immur

Mesot
comm
thicke
risk fa
risk fo

(Choi
that di

(Choi
Histop
coarse

(Choi
imagir
cytopla

(Choi
would be expected on imaging. Although desmosomes (intercellular bridges) can be seen in squamous cell carcinoma, imaging usually shows a central hilar mass (not pleural thickening).

https://t.me/USMLEWorldStep1

Incorrect
Correct answer
C

58%
06 secs
2023

Exhibit Display

Pulmonary carcinoid tumor

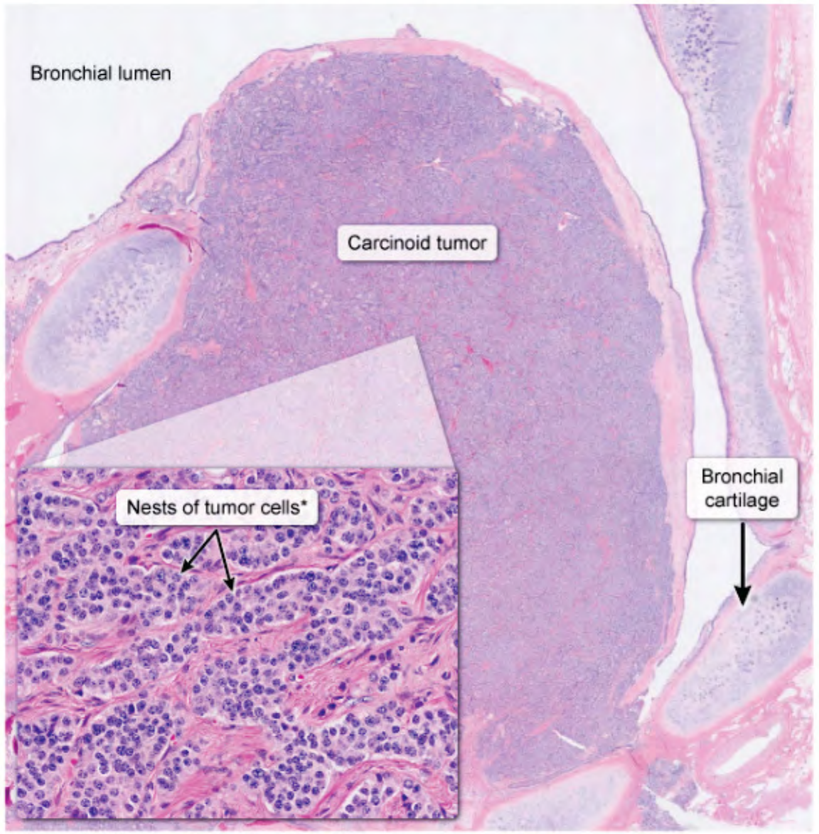

*Uniform cells with salt and pepper chromatin pattern.
©UWorld

Zoom In | Zoom Out | Reset | New | Existing | My Notebook

Expl

This p
preser
rare, n
and ar
tumor
Immur

Mesot
comm
thicke
risk fa
risk fo

(Choi
that di

(Choi
Histop
coarse

(Choi
imagir
cytopla

(Choi
would be expected on imaging. Although desmosomes (intercellular bridges) can be seen in squamous cell carcinoma, imaging usually shows a central hilar mass (not pleural thickening).

https://t.me/USMLEWorldStep1

Incorrect
Correct answer
C

58%
Answered correctly

06 secs
Time Spent

2023
Version

Exhibit Display

Small cell lung carcinoma

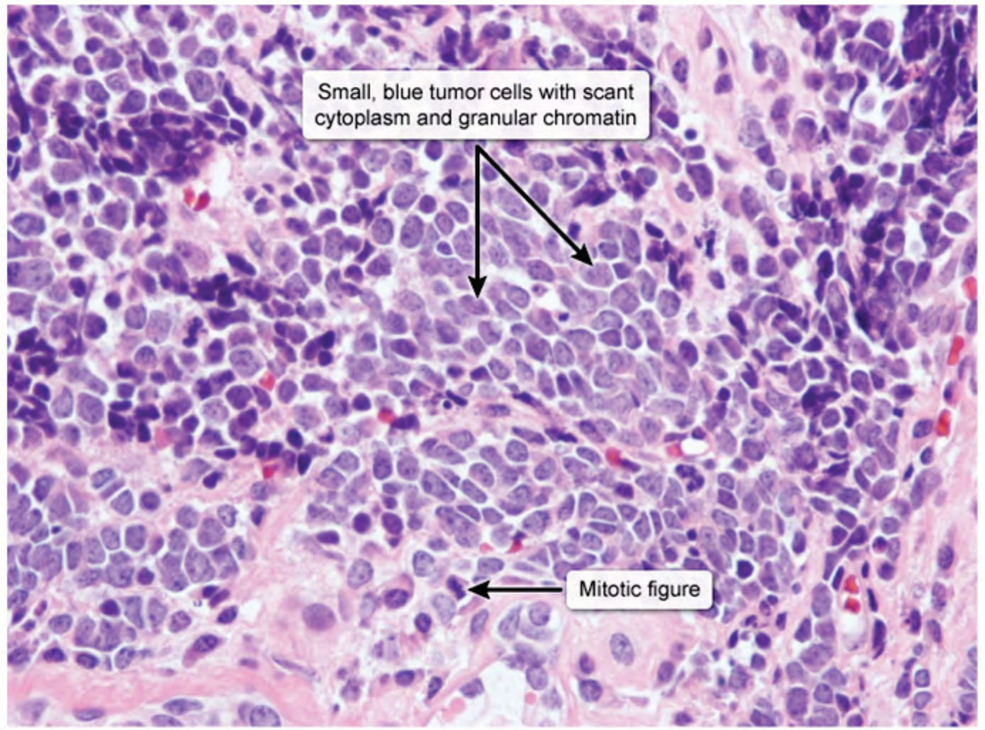

©UWorld

Zoom In | Zoom Out | Reset | New | Existing | My Notebook

Expl

This p
preser
rare, n
and ar
tumor
Immur

Mesot
comm
thicke
risk fa
risk fo

(Choi
that di

(Choi
Histop
coarse

(Choi
imagir
cytopla

(Choi
would be expected on imaging. Although desmosomes (intercellular bridges) can be seen in squamous cell carcinoma, imaging usually shows a central hilar mass (not pleural thickening).

https://t.me/USMLEWorldStep1

Explanation

This p
preser
rare, n
and ar
tumor
Immur

Mesot
comm
thicke
risk fa
risk fo

(Choi
that di

(Choi
Histop
coarse

(Choi
imagir
cytopl

(Choi
would
carcin

Educa
Malignant mesothelioma is a rare neoplasm typically arising from the pleura. It is strongly associated with asbestos exposure and presents with progressive dyspnea, cough, and chest pain. Unilateral pleural thickening or

Exhibit Display

Squamous cell lung carcinoma

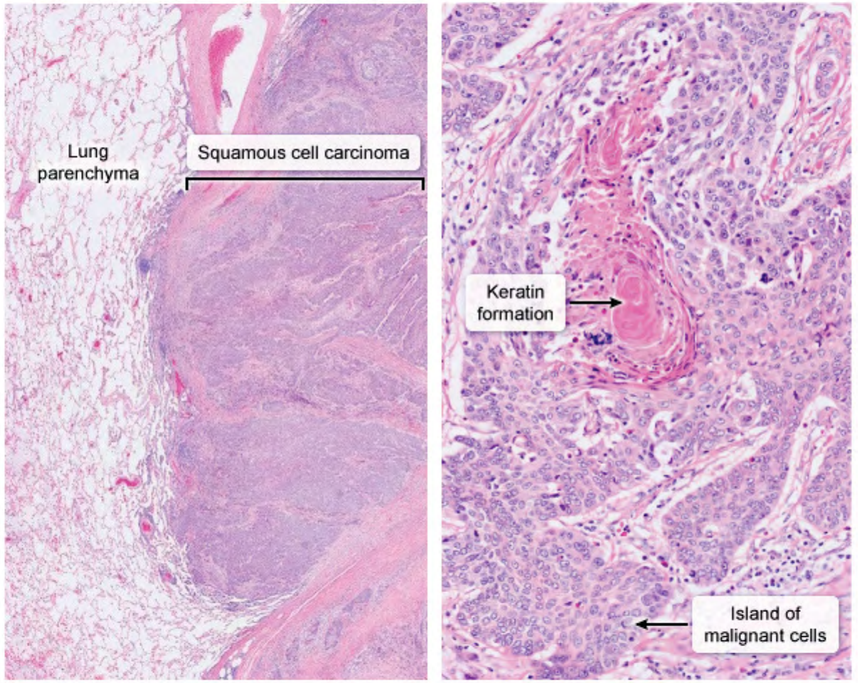

©UWorld

Zoom In | Zoom Out | Reset | New | Existing | My Notebook

https://t.me/USMLEWorldStep1

A 65-year-old man is evaluated for hypotension and increasing shortness of breath shortly after placement of a right-sided subclavian central venous catheter. The patient was recently diagnosed with colon cancer without metastasis and is scheduled for surgical resection. Blood pressure is 80/50 mm Hg, pulse is 110/min, and respirations are 24/min. Examination shows jugular venous distension. Breath sounds are decreased on the right and the trachea is deviated to the left. Which of the following is the most likely cause of this patient's hypotension?

- A. Decreased intravascular volume
- B. Decreased systemic vascular resistance
- C. Decreased venous return
- D. Impaired baroreceptor reflex
- E. Increased intrapericardial pressure

Submit

https://t.me/USMLEWorldStep1

A 65-year-old man is evaluated for hypotension and increasing shortness of breath shortly after placement of a right-sided subclavian central venous catheter. The patient was recently diagnosed with colon cancer without metastasis and is scheduled for surgical resection. Blood pressure is 80/50 mm Hg, pulse is 110/min, and respirations are 24/min. Examination shows jugular venous distension. Breath sounds are decreased on the right and the trachea is deviated to the left. Which of the following is the most likely cause of this patient's hypotension?

- A. Decreased intravascular volume (6%)
- ✕ B. Decreased systemic vascular resistance (5%)
- ✓ C. Decreased venous return (50%)
- D. Impaired baroreceptor reflex (5%)
- E. Increased intrapericardial pressure (30%)

Incorrect
Correct answer
C

50%
Answered correctly

04 secs
Time Spent

2023
Version

Explanation

Pneumothorax	
Risk factors	• Primary spontaneous: age <40, tall & thin, male sex, smoking • Secondary spontaneous: COPD, cystic fibrosis, lung malignancy • Provoked: thoracic trauma/procedures
Clinical presentation	• Shortness of breath, chest pain • ↓ Breath sounds unilaterally • Subcutaneous crepitus • Hypotension, tachycardia & tracheal deviation*

https://t.me/USMLEWorldStep1

Pneumothorax	
Risk factors	• Primary spontaneous: age <40, tall & thin, male sex, smoking • Secondary spontaneous: COPD, cystic fibrosis, lung malignancy • Provoked: thoracic trauma/procedures
Clinical presentation	• Shortness of breath, chest pain • ↓ Breath sounds unilaterally • Subcutaneous crepitus • Hypotension, tachycardia & tracheal deviation*
Diagnosis	Chest x-ray: • Pleural line without peripheral lung markings • Contralateral mediastinal shift*
*If tension pathophysiology is present. **COPD** = chronic obstructive pulmonary disease.	

This patient with shortness of breath, **hypotension**, unilaterally decreased breath sounds, and **tracheal deviation** shortly after subclavian catheter placement likely has a **tension pneumothorax**. Because of the close proximity of the subclavian vein to the apex of the lung, there is risk of lung puncture during the procedure.

Lung puncture allows air to pass into the pleural space. If the puncture is small, the patient may remain asymptomatic. With a large puncture, air rushes into the pleural space, leading to pressure equalization and **loss of intrapleural negative pressure**, which causes shortness of breath due to inability to expand the affected lung. Intrapleural and lung pressures usually remain nearly equivalent (ie, **simple pneumothorax**), and symptoms are limited to chest pain and respiratory difficulty.

Sometimes lung puncture results in formation of a **one-way tissue valve** that opens during inspiration to allow air into the pleural space and closes during expiration to trap that air, causing intrapleural pressure to progressively increase with each breath (ie, **tension pathophysiology**). The increasing pressure leads to contralateral mediastinal shifting (eg, tracheal deviation) and **vena cava collapse**, resulting in **decreased venous return** to the

https://t.me/USMLEWorldStep1

*If tension pathophysiology is present.

COPD = chronic obstructive pulmonary disease.

This patient with shortness of breath, **hypotension**, unilaterally decreased breath sounds, and **tracheal deviation** shortly after subclavian catheter placement likely has a **tension pneumothorax**. Because of the close proximity of the subclavian vein to the apex of the lung, there is risk of lung puncture during the procedure.

Lung puncture allows air to pass into the pleural space. If the puncture is small, the patient may remain asymptomatic. With a large puncture, air rushes into the pleural space, leading to pressure equalization and **loss of intrapleural negative pressure**, which causes shortness of breath due to inability to expand the affected lung. Intrapleural and lung pressures usually remain nearly equivalent (ie, **simple pneumothorax**), and symptoms are limited to chest pain and respiratory difficulty.

Sometimes lung puncture results in formation of a **one-way tissue valve** that opens during inspiration to allow air into the pleural space and closes during expiration to trap that air, causing intrapleural pressure to progressively increase with each breath (ie, **tension pathophysiology**). The increasing pressure leads to contralateral mediastinal shifting (eg, tracheal deviation) and **vena cava collapse**, resulting in **decreased venous return** to the heart. Cardiac output is reduced, leading to hypotension and tachycardia (ie, obstructive shock). Treatment requires emergency decompression of the pleural space with needle insertion or chest-tube placement to prevent cardiac arrest.

(Choices A and B) Decreased intravascular volume is the cause of hypovolemic shock (eg, due to massive hemorrhage), and decreased systemic vascular resistance is the primary disturbance in distributive shock (eg, due to sepsis). The jugular veins are flat with these conditions, and unilaterally decreased breath sounds and tracheal deviation are not expected.

(Choice D) An impaired baroreceptor reflex can cause or worsen hypotension due to failure of reflex-mediated vasoconstriction and increased heart rate. This patient's tachycardia suggests that the baroreceptor reflex is intact.

(Choice E) Increased intrapericardial pressure occurs in cardiac tamponade. The increased pressure impairs diastolic filling of the right ventricle, leading to obstructive shock. Although jugular venous distension is expected, cardiac tamponade does not explain this patient's unilaterally decreased breath sounds and tracheal deviation.

https://t.me/USMLEWorldStep1

the subclavian vein to the apex of the lung, there is risk of lung puncture during the procedure.

Lung puncture allows air to pass into the pleural space. If the puncture is small, the patient may remain asymptomatic. With a large puncture, air rushes into the pleural space, leading to pressure equalization and **loss of intrapleural negative pressure**, which causes shortness of breath due to inability to expand the affected lung. Intrapleural and lung pressures usually remain nearly equivalent (ie, **simple pneumothorax**), and symptoms are limited to chest pain and respiratory difficulty.

Sometimes lung puncture results in formation of a **one-way tissue valve** that opens during inspiration to allow air into the pleural space and closes during expiration to trap that air, causing intrapleural pressure to progressively increase with each breath (ie, **tension pathophysiology**). The increasing pressure leads to contralateral mediastinal shifting (eg, tracheal deviation) and **vena cava collapse**, resulting in **decreased venous return** to the heart. Cardiac output is reduced, leading to hypotension and tachycardia (ie, obstructive shock). Treatment requires emergency decompression of the pleural space with needle insertion or chest-tube placement to prevent cardiac arrest.

(Choices A and B) Decreased intravascular volume is the cause of hypovolemic shock (eg, due to massive hemorrhage), and decreased systemic vascular resistance is the primary disturbance in distributive shock (eg, due to sepsis). The jugular veins are flat with these conditions, and unilaterally decreased breath sounds and tracheal deviation are not expected.

(Choice D) An impaired baroreceptor reflex can cause or worsen hypotension due to failure of reflex-mediated vasoconstriction and increased heart rate. This patient's tachycardia suggests that the baroreceptor reflex is intact.

(Choice E) Increased intrapericardial pressure occurs in cardiac tamponade. The increased pressure impairs diastolic filling of the right ventricle, leading to obstructive shock. Although jugular venous distension is expected, cardiac tamponade does not explain this patient's unilaterally decreased breath sounds and tracheal deviation.

Educational objective:
Tension pneumothorax involves progressively increasing intrapleural pressure that leads to contralateral mediastinal shifting (eg, tracheal deviation) and vena cava collapse. Hypotension, tachycardia, and obstructive shock develop due to decreased venous return to the heart.

References

https://t.me/USMLEWorldStep1

Diagnosis	• Pleural line without peripheral lung markings • Contralateral mediastinal shift*

Exhibit Display

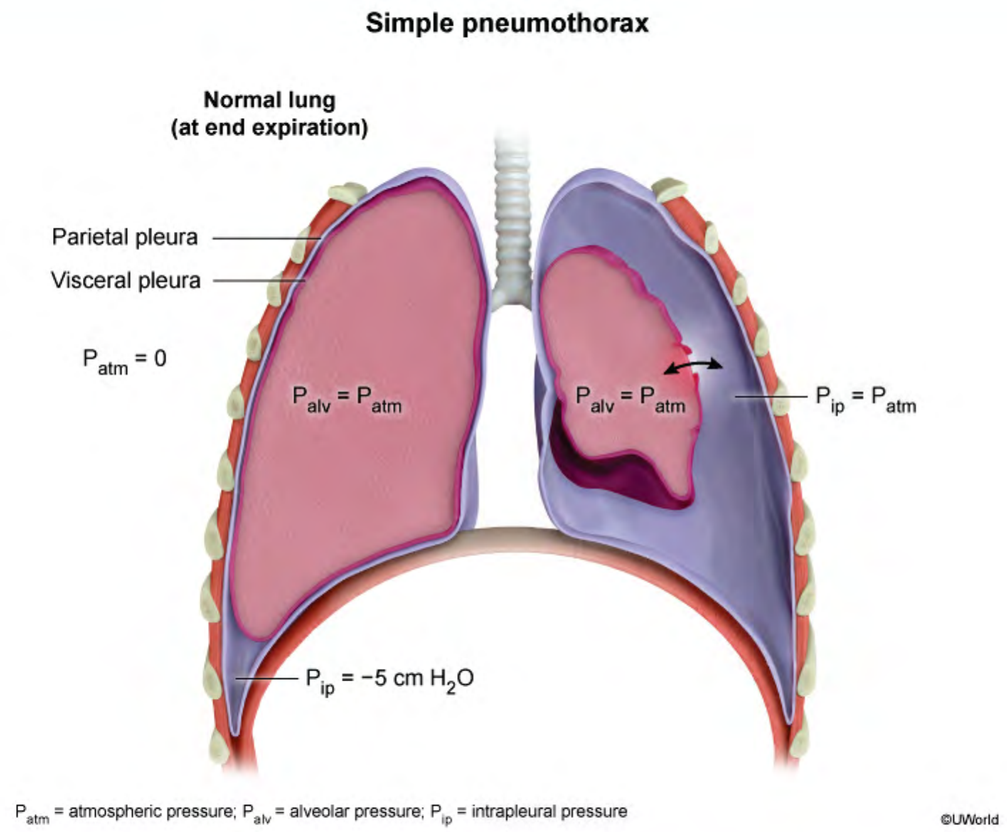

Zoom In Zoom Out Reset New | Existing My Notebook

This p
shortly
the su

Lung p
asymp
of intr
Intrapl
limited

Somet
into th
increa
media
heart.
require
cardia

(Choi
hemor
to sep
deviati

(Choi
vasoc

(Choice E) Increased intrapericardial pressure occurs in cardiac tamponade. The increased pressure impairs

https://t.me/USMLEWorldStep1

Diagnosis	• Pleural line without peripheral lung markings • Contralateral mediastinal shift*

Exhibit Display

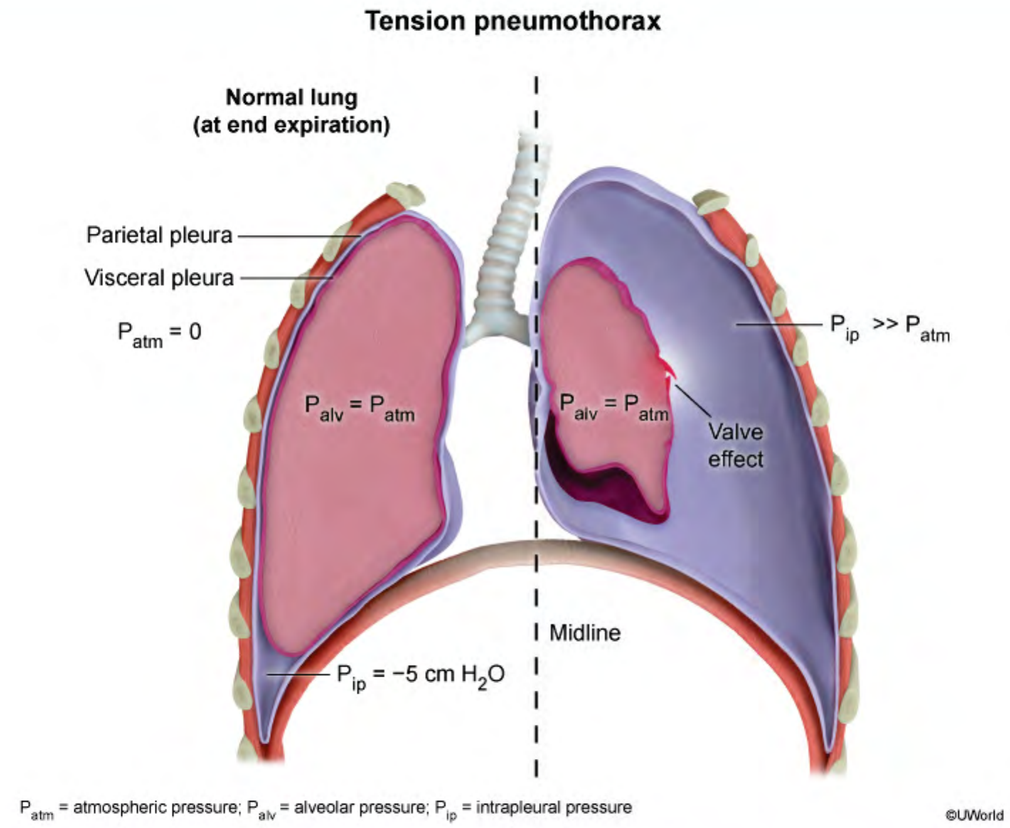

Zoom In | Zoom Out | Reset | New | Existing | My Notebook

This p
shortly
the su

Lung p
asymp
of intr
Intrapl
limited

Somet
into th
increa
media
heart.
require
cardia

(Choi
hemor
to sep
deviati

(Choi
vasoc

(Choice E) Increased intrapericardial pressure occurs in cardiac tamponade. The increased pressure impairs

https://t.me/USMLEWorldStep1

Diagnosis	• Pleural line without peripheral lung markings • Contralateral mediastinal shift*

Exhibit Display

This p
shortly
the su

Lung p
asymp
of intr
Intrapl
limited

Somet
into th
increa
media
heart.
require
cardia

(Choi
hemor
to sep
deviati

(Choi
vasoc

(Choice E) Increased intrapericardial pressure occurs in cardiac tamponade. The increased pressure impairs

Obstructive shock

Primary disturbance
Impeded cardiopulmonary blood flow
(eg, PE, tension PTX)

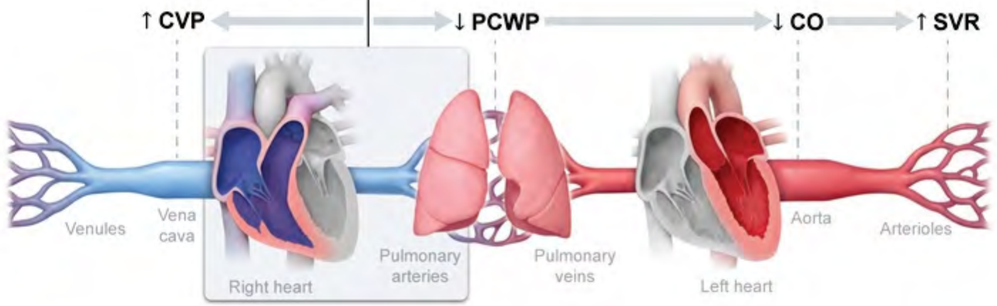

CO = cardiac output; **CVP** = central venous pressure; **PCWP** = pulmonary capillary wedge pressure; **PE** = pulmonary embolism; **PTX** = pneumothorax; **SVR** = systemic vascular resistance.

©UWorld

Zoom In | Zoom Out | Reset | New | Existing | My Notebook

https://t.me/USMLEWorldStep1

Diagnosis	• Pleural line without peripheral lung markings • Contralateral mediastinal shift*

Exhibit Display

This p
shortly
the su

Lung p
asymp
of intr
Intrapl
limited

Somet
into th
increa
media
heart.
require
cardia

(Choi
hemor
to sep
deviati

(Choi
vasoc

(Choice E) Increased intrapericardial pressure occurs in cardiac tamponade. The increased pressure impairs

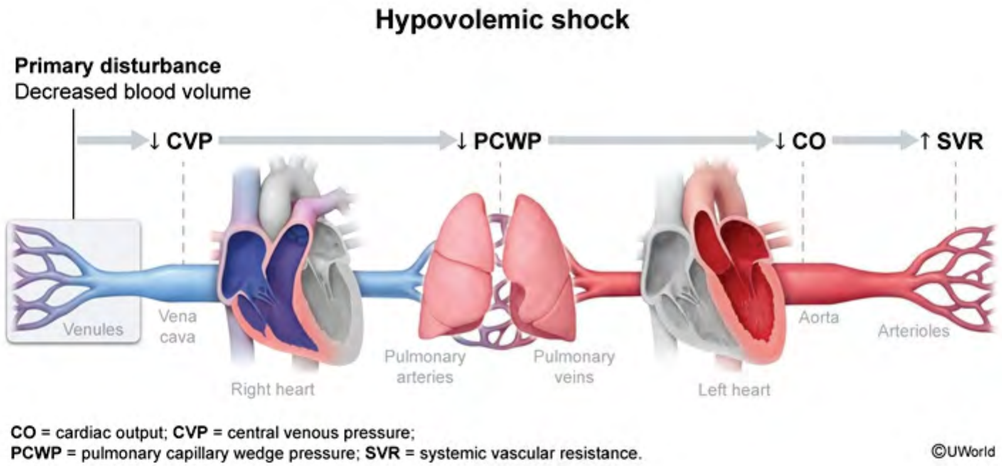

Zoom In | Zoom Out | Reset | New | Existing | My Notebook

https://t.me/USMLEWorldStep1

Diagnosis	• Pleural line without peripheral lung markings • Contralateral mediastinal shift*

Exhibit Display

This p
shortly
the su

Lung p
asymp
of intr
Intrapl
limited

Somet
into th
increa
media
heart.
require
cardia

(Choi
hemor
to sep
deviati

(Choi
vasoc

(Choice E) Increased intrapericardial pressure occurs in cardiac tamponade. The increased pressure impairs

Septic (distributive) shock

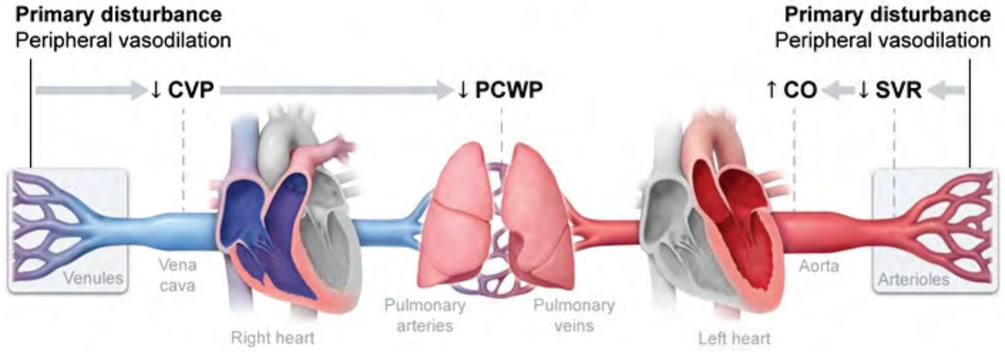

CO = cardiac output; **CVP** = central venous pressure;
PCWP = pulmonary capillary wedge pressure; **SVR** = systemic vascular resistance.

©UWorld

Zoom In | Zoom Out | Reset | New | Existing | My Notebook

https://t.me/USMLEWorldStep1

A 32-year-old hospitalized man is evaluated for new-onset shortness of breath and confusion. The patient was admitted 3 days ago following a motor vehicle collision during which he sustained bilateral femur fractures, a pelvic fracture, and urethral injury. He underwent surgical repair with no operative complications. Temperature is 37.9 C (100.2 F), pulse is 110/min, respirations are 24/min, and oxygen saturation is 84% on room air. On physical examination, the patient appears agitated and disoriented. The lungs are clear to auscultation and there is no lower extremity edema. A petechial rash is present on the chest. ECG shows sinus tachycardia with no ischemic changes. Which of the following histologic changes has most likely taken place in this patient's lung tissue?

- A. Alveolar fluid rich in neutrophils
- B. Fat microglobules in pulmonary arterioles
- C. Prominent interstitial infiltration by mononuclear cells
- D. Red thrombus lodged in the pulmonary artery
- E. Scattered necrosis with alveolar hemorrhage

Submit

https://t.me/USMLEWorldStep1

A 32-year-old hospitalized man is evaluated for new-onset shortness of breath and confusion. The patient was admitted 3 days ago following a motor vehicle collision during which he sustained bilateral femur fractures, a pelvic fracture, and urethral injury. He underwent surgical repair with no operative complications. Temperature is 37.9 C (100.2 F), pulse is 110/min, respirations are 24/min, and oxygen saturation is 84% on room air. On physical examination, the patient appears agitated and disoriented. The lungs are clear to auscultation and there is no lower extremity edema. A petechial rash is present on the chest. ECG shows sinus tachycardia with no ischemic changes. Which of the following histologic changes has most likely taken place in this patient's lung tissue?

- ✗ A. Alveolar fluid rich in neutrophils (3%)
- ✓ B. Fat microglobules in pulmonary arterioles (82%)
- C. Prominent interstitial infiltration by mononuclear cells (2%)
- D. Red thrombus lodged in the pulmonary artery (9%)
- E. Scattered necrosis with alveolar hemorrhage (2%)

Incorrect
Correct answer
B

82%
Answered correctly

05 secs
Time Spent

2023
Version

Explanation

The clinical triad of acute-onset neurologic abnormalities, hypoxemia, and petechiae in a patient with traumatic bone fracture is strongly suggestive of **fat embolism syndrome** (FES). This condition most commonly occurs 24-72 hours following **long-bone and/or pelvic fracture**. Pathophysiologically, the traumatic event **dislodges fat globules** from the bone marrow and allows them to enter disrupted marrow venules, where they can then traverse the systemic veins and deposit in pulmonary microvessels. The **pulmonary capillary occlusion** impairs gas exchange and induces **hypoxemia**; release of free fatty acids from the fat globules also causes local toxic injury to the endothelium, potentially leading to acute respiratory distress syndrome.

https://t.me/USMLEWorldStep1

The clinical triad of acute-onset neurologic abnormalities, hypoxemia, and petechiae in a patient with traumatic bone fracture is strongly suggestive of **fat embolism syndrome** (FES). This condition most commonly occurs 24-72 hours following **long-bone and/or pelvic fracture**. Pathophysiologically, the traumatic event **dislodges fat globules** from the bone marrow and allows them to enter disrupted marrow venules, where they can then traverse the systemic veins and deposit in pulmonary microvessels. The **pulmonary capillary occlusion** impairs gas exchange and induces **hypoxemia**; release of free fatty acids from the fat globules also causes local toxic injury to the endothelium, potentially leading to acute respiratory distress syndrome.

Some fat globules escape the lungs via precapillary arteriovenous shunts that open due to increased pulmonary artery pressure. This phenomenon appears to be responsible for the fat emboli–associated microvascular occlusion that can occur within the CNS, manifesting with confusion and **neurologic impairment**, and in the dermal capillaries, resulting in erythrocyte extravasation and a **petechial rash**.

(Choices A, C, and D) A neutrophil-rich alveolar exudate is not an early histologic manifestation of FES but rather of acute bacterial or aspiration pneumonia. Mononuclear interstitial pulmonary infiltrates are found early in the course of a variety of interstitial lung diseases. A red thrombus lodged in the pulmonary artery is consistent with a thromboembolism from a deep venous source. None of these conditions would typically be associated with the neurologic impairment or petechial rash seen with FES.

(Choice E) Focal necrosis of alveolar walls with associated intra-alveolar hemorrhage is often seen with pulmonary hemorrhage syndromes (eg, anti-glomerular basement membrane antibody disease, granulomatosis with polyangiitis).

Educational objective:
Fat embolism syndrome should be strongly suspected in a patient with severe long-bone and/or pelvic fractures who develops acute-onset neurologic abnormalities, hypoxemia, and a petechial rash. Occlusion of the pulmonary microvessels by fat globules is an early histologic finding of this syndrome.

Pathology	Pulmonary & Critical Care	Fat embolism
Subject	System	Topic

https://t.me/USMLEWorldStep1

A 4-year-old girl is brought to the emergency department by her parents due to difficulty breathing. The patient was in her usual state of health until this morning when she developed a fever. Over the past 8 hours, her breathing has become more rapid and strained. Temperature is 39.8 C (103.6 F), blood pressure is 88/64 mm Hg, pulse is 134/min, and respirations are 34/min. On examination, the patient appears scared. She is sitting up on the bed leaning forward while supported by her arms with her head extended. Cardiac examination reveals tachycardia and a normal rhythm without rubs or murmurs. The abdomen is soft and nondistended. Which of the following additional signs is most likely to be found on examination?

- A. Asymmetrical breath sounds
- B. Diffuse rhonchi
- C. Expiratory stridor
- D. Expiratory wheeze
- E. Inspiratory stridor
- F. Inspiratory wheeze

Submit

https://t.me/USMLEWorldStep1

A 4-year-old girl is brought to the emergency department by her parents due to difficulty breathing. The patient was in her usual state of health until this morning when she developed a fever. Over the past 8 hours, her breathing has become more rapid and strained. Temperature is 39.8 C (103.6 F), blood pressure is 88/64 mm Hg, pulse is 134/min, and respirations are 34/min. On examination, the patient appears scared. She is sitting up on the bed leaning forward while supported by her arms with her head extended. Cardiac examination reveals tachycardia and a normal rhythm without rubs or murmurs. The abdomen is soft and nondistended. Which of the following additional signs is most likely to be found on examination?

- A. Asymmetrical breath sounds (4%)
- B. Diffuse rhonchi (4%)
- ✗ C. Expiratory stridor (8%)
- D. Expiratory wheeze (9%)
- ✓ E. Inspiratory stridor (67%)
- F. Inspiratory wheeze (5%)

Incorrect
Correct answer
E

67%
Answered correctly

03 secs
Time Spent

2023
Version

Explanation

https://t.me/USMLEWorldStep1

B. Diffuse rhonchi (4%)

Exhibit Display

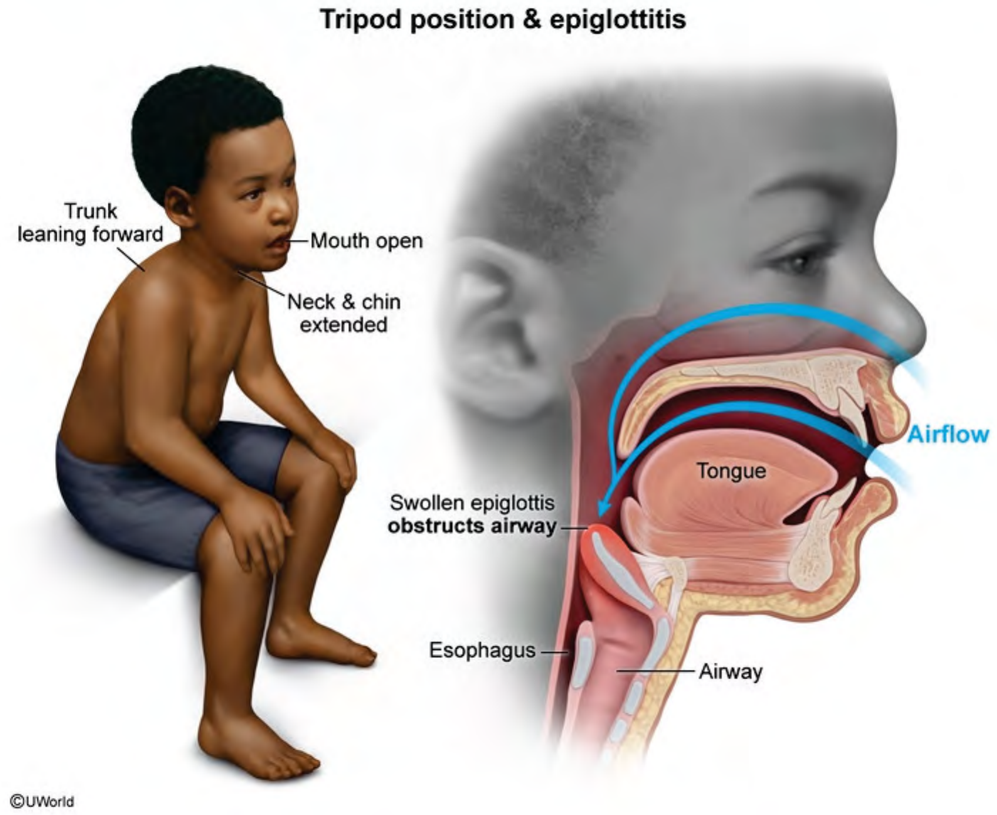

Zoom In | Zoom Out | Reset | New | Existing | My Notebook

https://t.me/USMLEWorldStep1

This febrile, ill-appearing patient with respiratory distress who is in the **tripod position** likely has **epiglottitis**, a rare, potentially fatal infection most commonly caused by *Haemophilus influenzae* type b. **Edema** of the epiglottis can cause **laryngeal obstruction** that leads to inspiratory stridor.

During inspiration, faster airflow causes decreased intraluminal pressure in the airways (eg, drop in intralaryngeal pressure). In patients with airway obstruction at the level of the larynx, this decreased pressure leads to increased airway narrowing and increased turbulent airflow. Therefore, patients with airway obstruction at the level of the larynx (eg, epiglottitis, laryngomalacia, bilateral vocal cord paralysis) would be expected to have **inspiratory stridor**. Tripod positioning (extending neck and chin to the sniffing position) pulls the tongue forward to partially open the laryngeal airway.

(Choice A) Asymmetric breath sounds can occur with unilateral obstruction below the level of the carina (eg, foreign body aspiration) or with pleural disorders (eg, effusion, pneumothorax). This patient's tripod positioning is more suggestive of laryngeal obstruction.

(Choice B) Rhonchi are low-pitched rattling sounds produced when air flows through bronchi that have excessive secretions. Because they are caused by the movement of air through wet secretions, rhonchi can be heard on both inspiration and expiration.

(Choice C) Expiratory stridor often occurs due to tracheal pathology (eg, tracheomalacia) because inspiration decreases intrathoracic pressure (relative to the airways), which widens the intrathoracic trachea. Expiration increases intrathoracic pressure, which narrows the intrathoracic trachea, worsening the obstruction.

(Choices D and F) Wheezing (ie, high-pitched whistling noise) occurs with constriction of the smaller airways of the lungs (eg, asthma). Because these small airways are intrathoracic, the constriction is more pronounced during expiration due to increased intrathoracic pressure.

Educational objective:
Laryngeal airway obstruction can occur with epiglottitis. It leads to inspiratory stridor due to the dynamic collapse of the larynx during inspiration.

https://t.me/USMLEWorldStep1

Exhibit Display

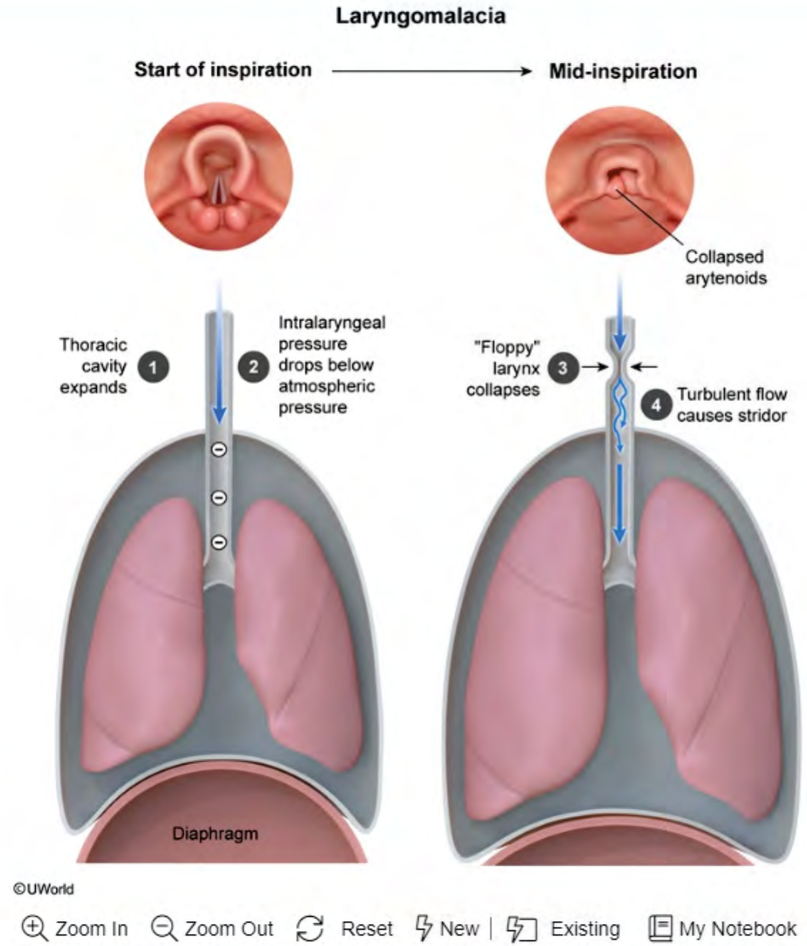

Zoom In | Zoom Out | Reset | New | Existing | My Notebook

This fe
rare, p
can ca

During
pressu
airway
larynx
stridо
open t

(Choi
foreign
more s

(Choi
secret
both ir

(Choi
decrea
increa

(Choi
the lur
expira

Educa
Laryng
of the larynx during inspiration.

https://t.me/USMLEWorldStep1

Exhibit Display

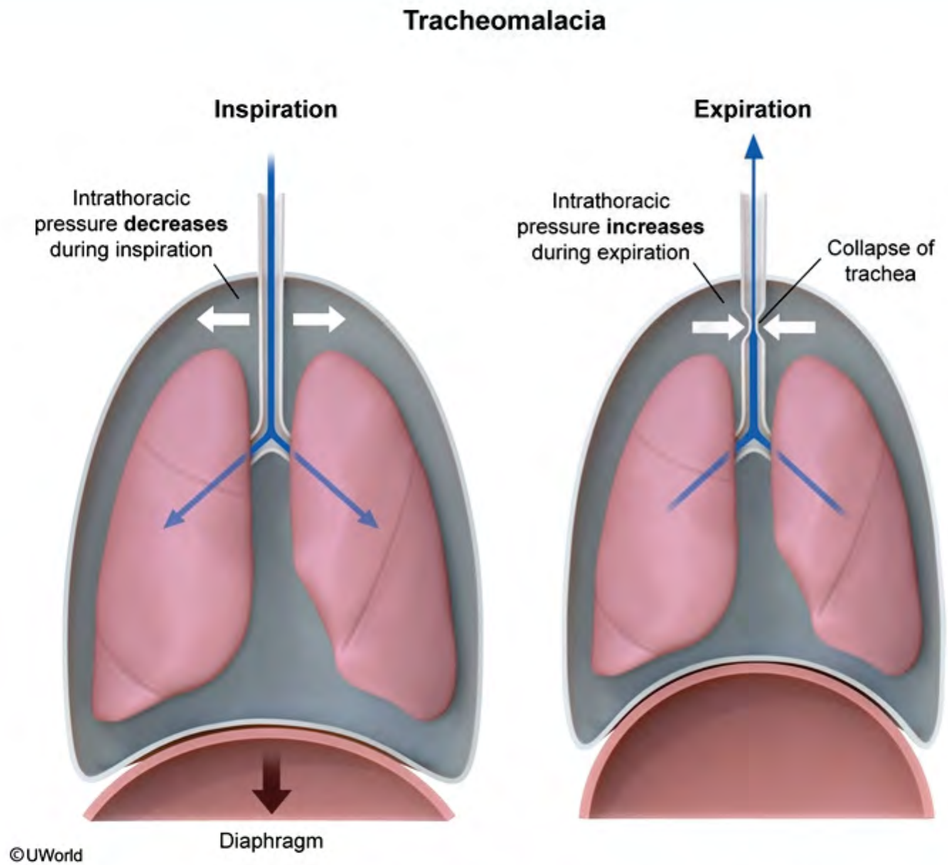

Zoom In | Zoom Out | Reset | New | Existing | My Notebook

This fe
rare, p
can ca

During
pressu
airway
larynx
stridо
open t

(Choi
foreign
more s

(Choi
secret
both ir

(Choi
decrea
increa

(Choi
the lur
expira

Educa
Laryng
of the larynx during inspiration.

https://t.me/USMLEWorldStep1

A 55-year-old man is hospitalized with severe abdominal pain associated with nausea and vomiting. Laboratory studies show marked elevation of serum amylase and lipase. He has a history of heavy alcohol use. During hospitalization, his condition deteriorates and he develops severe respiratory distress. There are crackles bilaterally on physical examination and diffuse patchy infiltrates bilaterally on chest x-ray. The patient fails to improve with mechanical ventilation and 100% oxygen and dies 4 days later due to progressive respiratory failure. Which of the following autopsy findings is most likely in this patient?

- A. Alveolar hyaline membranes
- B. Cardiomegaly
- C. Foci of anaerobic pulmonary infection
- D. Intraalveolar hemorrhage
- E. Lung hyperinflation

Submit

https://t.me/USMLEWorldStep1

A 55-year-old man is hospitalized with severe abdominal pain associated with nausea and vomiting. Laboratory studies show marked elevation of serum amylase and lipase. He has a history of heavy alcohol use. During hospitalization, his condition deteriorates and he develops severe respiratory distress. There are crackles bilaterally on physical examination and diffuse patchy infiltrates bilaterally on chest x-ray. The patient fails to improve with mechanical ventilation and 100% oxygen and dies 4 days later due to progressive respiratory failure. Which of the following autopsy findings is most likely in this patient?

- ✓ A. Alveolar hyaline membranes (76%)
- ✗ B. Cardiomegaly (2%)
- C. Foci of anaerobic pulmonary infection (8%)
- D. Intraalveolar hemorrhage (10%)
- E. Lung hyperinflation (2%)

Incorrect
Correct answer
A

76%
Answered correctly

03 secs
Time Spent

2023
Version

Explanation

Diffuse alveolar damage

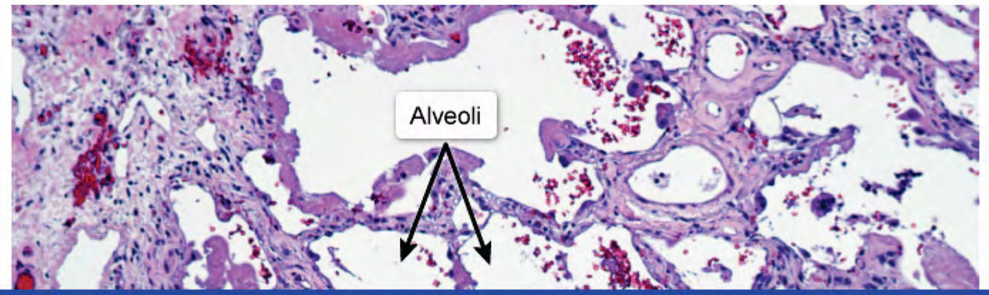

https://t.me/USMLEWorldStep1

A 55-year-old man is hospitalized with severe abdominal pain associated with nausea and vomiting. Laboratory studies
hospit
bilater
improv
Which

Inco
Corre
A

Expl

Exhibit Display

Diffuse alveolar damage

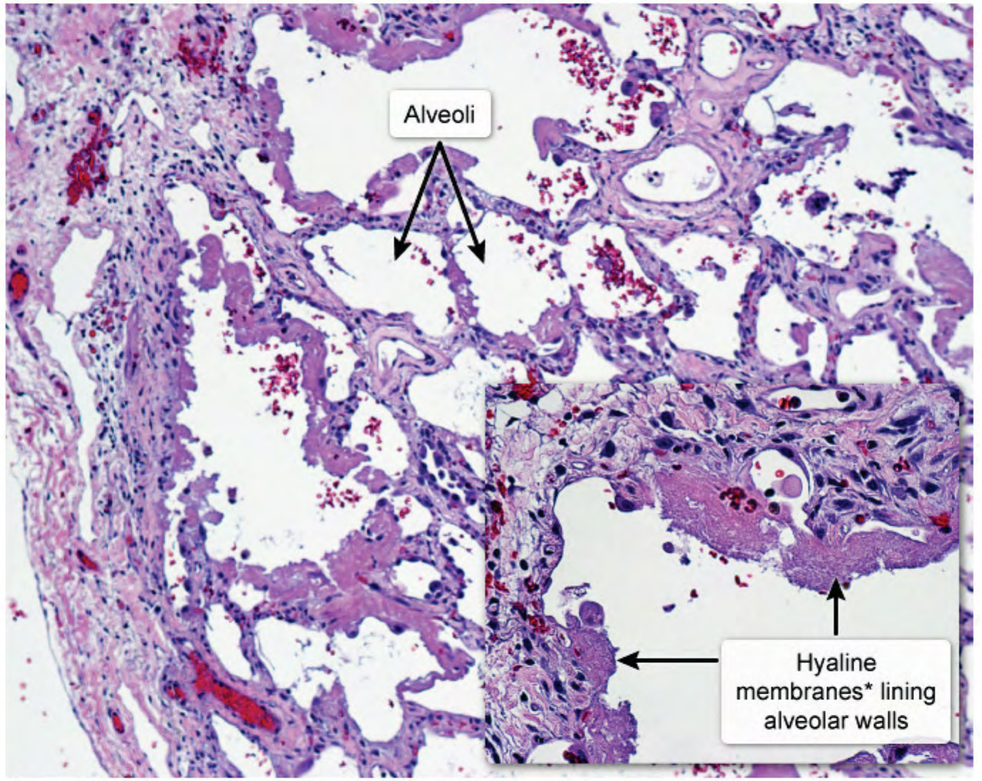

*Dense pink material composed of plasma proteins and necrotic epithelial cells

©UWorld

Zoom In | Zoom Out | Reset | New | Existing | My Notebook

https://t.me/USMLEWorldStep1

*Dense pink material composed of plasma proteins and necrotic epithelial cells

©UWorld

This patient with **pancreatitis** and subsequent respiratory failure likely has **acute respiratory distress syndrome** (ARDS). Pancreatitis is a major risk factor for ARDS as it results in the release of large amounts of inflammatory cytokines and pancreatic enzymes into the circulation, which leads to infiltration of **neutrophils** into the pulmonary interstitium and alveolar spaces. Diffuse injury to the alveolar epithelium and pulmonary microvascular endothelium results in a leaky alveolocapillary membrane and significant pulmonary edema.

ARDS is typically characterized by progressive hypoxemia refractory to oxygen therapy and diffuse interstitial edema in the absence of cardiogenic causes. During the first 1-6 days, interstitial and intraalveolar edema, inflammation, and fibrin deposition cause the alveoli to become lined with waxy **hyaline membranes**. These membranes consist of fibrin exudate and inspissated protein-rich edema fluid mixed with the remnants of necrotic epithelial cells.

(Choice B) If this patient's rapid-onset dyspnea were due to cardiogenic pulmonary edema, as can occur in decompensated heart failure, or if the patient had chronic heart failure due to alcohol use, chest x-ray would likely reveal cardiomegaly.

(Choice C) This patient is at risk of aspiration; however, aspiration pneumonia due to anaerobic bacteria commonly presents more indolently and is more likely to show an abscess or empyema than diffuse patchy opacities on chest x-ray.

(Choice D) Although disseminated intravascular coagulation and ARDS can result in alveolar hemorrhage, the absence of hemoptysis makes this choice less likely.

(Choice E) Lung hyperinflation may be seen in emphysema, which is a chronic, destructive enlargement of the air spaces distal to the terminal bronchiole.

Educational objective:
Pancreatitis is a major risk factor for acute respiratory distress syndrome as it results in the release of large amounts of inflammatory cytokines and pancreatic enzymes, which leads to activation of neutrophils in the alveolar tissues. During the initial phase, interstitial and intraalveolar edema, inflammation, and fibrin deposition cause the alveoli to become lined with waxy hyaline membranes.

https://t.me/USMLEWorldStep1

A 1-hour-old boy is admitted to the neonatal intensive care unit for respiratory failure. The infant was born to a 27-year-old mother, gravida 4 para 2, at 29 weeks gestation via cesarean delivery due to maternal preeclampsia with severe features. Amniotic fluid was clear. Apgar scores were 7 and 8 at 1 and 5 minutes, respectively. Birth weight is 1,120 g (2 lb 8 oz). Temperature is 36.9 C (98.4 F), pulse is 170/min, and respirations are 56/min. Pulse oximetry is 82% on room air. There are intercostal and subcostal retractions. Cardiac examination shows tachycardia without murmurs. The lungs have decreased breath sounds bilaterally. The abdomen is soft without organomegaly. Surfactant is ordered, and the team prepares for intubation. Prior to these clinical interventions, which of the following best describes the condition of this patient's lungs compared to a normal neonate?

	Compliance	Functional residual capacity	Airway resistance
○ A.	↓	↓	↓
○ B.	↓	↓	↑
○ C.	↓	↑	↑
○ D.	↑	↓	↓
○ E.	↑	↑	↓

Submit

https://t.me/USMLEWorldStep1

A 1-hour-old boy is admitted to the neonatal intensive care unit for respiratory failure. The infant was born to a 27-year-old mother, gravida 4 para 2, at 29 weeks gestation via cesarean delivery due to maternal preeclampsia with severe features. Amniotic fluid was clear. Apgar scores were 7 and 8 at 1 and 5 minutes, respectively. Birth weight is 1,120 g (2 lb 8 oz). Temperature is 36.9 C (98.4 F), pulse is 170/min, and respirations are 56/min. Pulse oximetry is 82% on room air. There are intercostal and subcostal retractions. Cardiac examination shows tachycardia without murmurs. The lungs have decreased breath sounds bilaterally. The abdomen is soft without organomegaly. Surfactant is ordered, and the team prepares for intubation. Prior to these clinical interventions, which of the following best describes the condition of this patient's lungs compared to a normal neonate?

	Compliance	Functional residual capacity	Airway resistance	
A.	↓	↓	↓	(6%)
✓ B.	↓	↓	↑	(77%)
C.	↓	↑	↑	(12%)
D.	↑	↓	↓	(2%)
E.	↑	↑	↓	(1%)

Correct

77% Answered correctly

03 secs Time Spent

2023 Version

Explanation

Lung volume changes after surfactant

https://t.me/USMLEWorldStep1

A 1-hour-old boy is admitted to the neonatal intensive care unit for respiratory failure. The infant was born to a 27-
year-o
severe
weight
oxime
tachyc
organ
which

Cor

Expl

Exhibit Display

Lung volume changes after surfactant

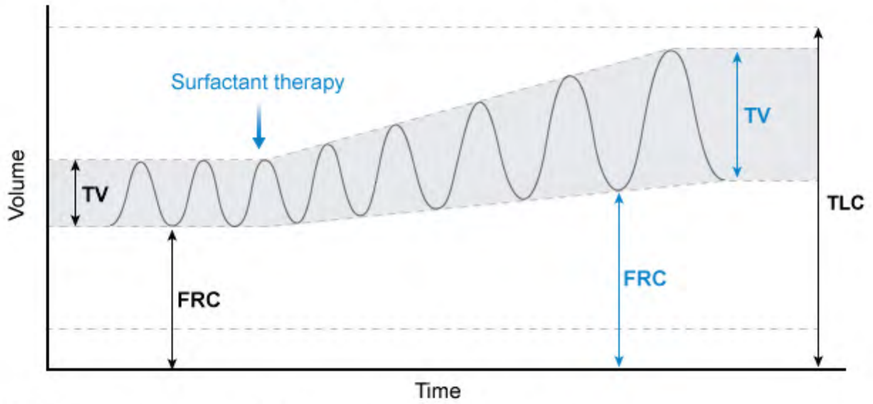

FRC = functional residual capacity; **TLC** = total lung capacity; **TV** = tidal volume.

©UWorld

Zoom In | Zoom Out | Reset | New | Existing | My Notebook

https://t.me/USMLEWorldStep1

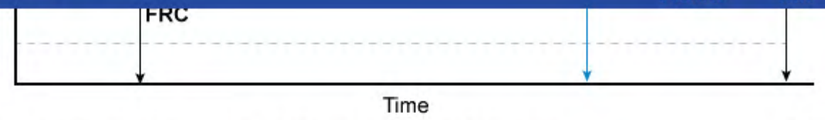

FRC = functional residual capacity; **TLC** = total lung capacity; **TV** = tidal volume. ©UWorld

This **preterm** infant has increased work of breathing, hypoxia, and decreased breath sounds, findings which are concerning for neonatal **respiratory distress syndrome** (RDS). RDS is caused by immaturity of type 2 pneumocytes, resulting in **lack of alveolar surfactant**. Without surfactant, the alveoli have increased surface tension and therefore decreased compliance. These **poorly compliant alveoli** are prone to collapse, resulting in widespread atelectasis that **lowers functional residual capacity** and total lung capacity. Surfactant deficiency also results in pneumocyte injury and lung inflammation; the resulting edema can narrow the airways and **increase airway resistance (Choice A)**.

RDS is treated with respiratory support and exogenous surfactant via an endotracheal tube, which transiently improves pulmonary compliance while the type 2 pneumocytes mature and begin to release endogenous surfactant. After surfactant administration, infants have increased lung expansion (ie, total lung capacity, functional residual capacity) and decreased airway resistance **(Choice E)**.

(Choice C) Decreased compliance, increased functional residual capacity, and increased airway resistance is the pattern seen in newborns with meconium aspiration syndrome. This obstructive process presents with respiratory distress at birth due to air trapping in the distal airways but would be unlikely in this patient with a history of clear amniotic fluid.

(Choice D) Increased compliance with decreased functional residual capacity and airway resistance is suggestive of pulmonary air leak (eg, pneumothorax), which causes respiratory distress at birth due to air within the extraalveolar space. Chest asymmetry and asymmetric breath sounds would be expected.

Educational objective:
Respiratory distress syndrome classically presents in premature infants with increased work of breathing and hypoxia at birth due to surfactant deficiency. Poor alveolar compliance leads to widespread atelectasis and decreased functional residual capacity. Airway resistance is often increased due to lung inflammation and edema.

Pathophysiology Pulmonary & Critical Care Neonatal respiratory distress syndrome

https://t.me/USMLEWorldStep1

FRC

Exhibit Display

Alveoli

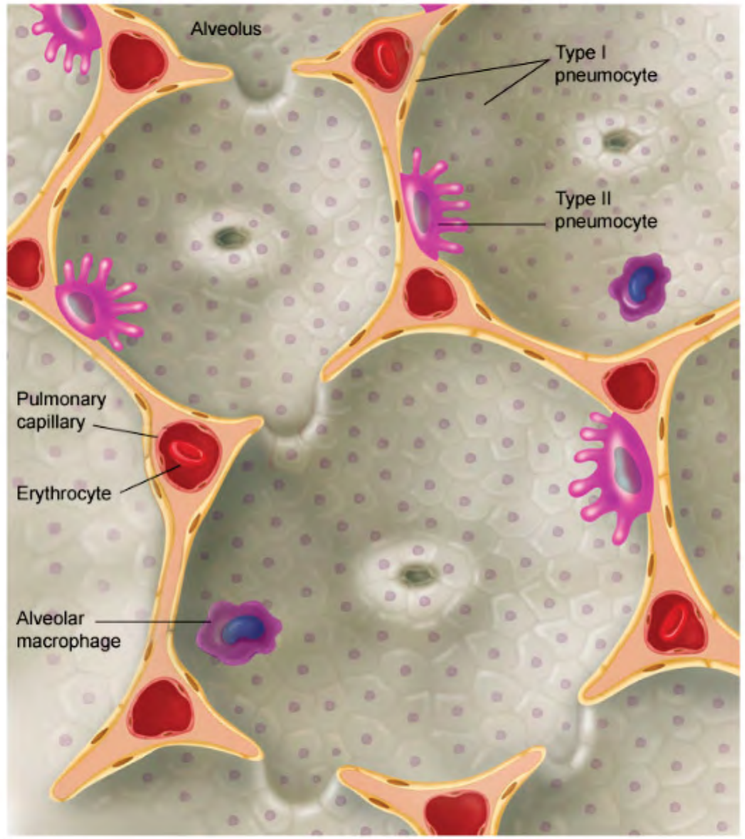

Zoom In | Zoom Out | Reset | New | Existing | My Notebook

This p
concer
pneum
tensio
widesp
also re
airway

RDS is
improv
surfac
residu

(Choi
pattern
distres
amnio

(Choi
of pulr
extraa

Educa
Respir
hypoxi
decrea

Pathophysiology Pulmonary & Critical Care Neonatal respiratory distress syndrome

https://t.me/USMLEWorldStep1

A 55-year-old woman with a history of Crohn disease is admitted to the hospital due to perforated appendicitis. The patient quickly develops respiratory difficulty, and acute respiratory distress syndrome is diagnosed. She is intubated and mechanically ventilated with positive pressure ventilation. Despite the use of high positive end-expiratory pressure, the patient's condition continues to deteriorate. She is intermittently placed in the prone position while mechanically ventilated. Which of the following is most likely to occur due to this position change?

- A. Alveolar hyperdistension
- B. Decreased cardiac output
- C. Decreased functional residual capacity
- D. Decreased right ventricular preload
- E. Improved ventilation-perfusion matching

Submit

https://t.me/USMLEWorldStep1

A 55-year-old woman with a history of Crohn disease is admitted to the hospital due to perforated appendicitis. The patient quickly develops respiratory difficulty, and acute respiratory distress syndrome is diagnosed. She is intubated and mechanically ventilated with positive pressure ventilation. Despite the use of high positive end-expiratory pressure, the patient's condition continues to deteriorate. She is intermittently placed in the prone position while mechanically ventilated. Which of the following is most likely to occur due to this position change?

- A. Alveolar hyperdistension (11%)
- ✗ B. Decreased cardiac output (1%)
- C. Decreased functional residual capacity (7%)
- D. Decreased right ventricular preload (6%)
- ✓ E. Improved ventilation-perfusion matching (72%)

Incorrect
Correct answer
E

72%
Answered correctly

04 secs
Time Spent

2023
Version

Explanation

Improved ventilation in prone positioning

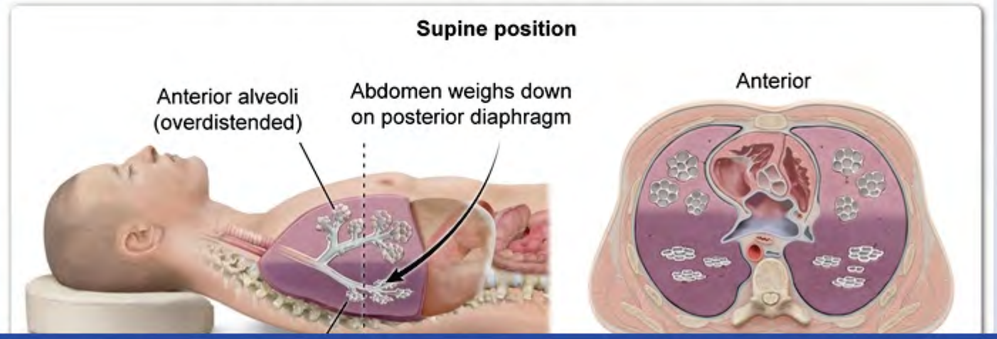

https://t.me/USMLEWorldStep1

A 55-year-old woman with a history of Crohn disease is admitted to the hospital due to perforated appendicitis.
The pa
intuba
expira
positic

Exhibit Display

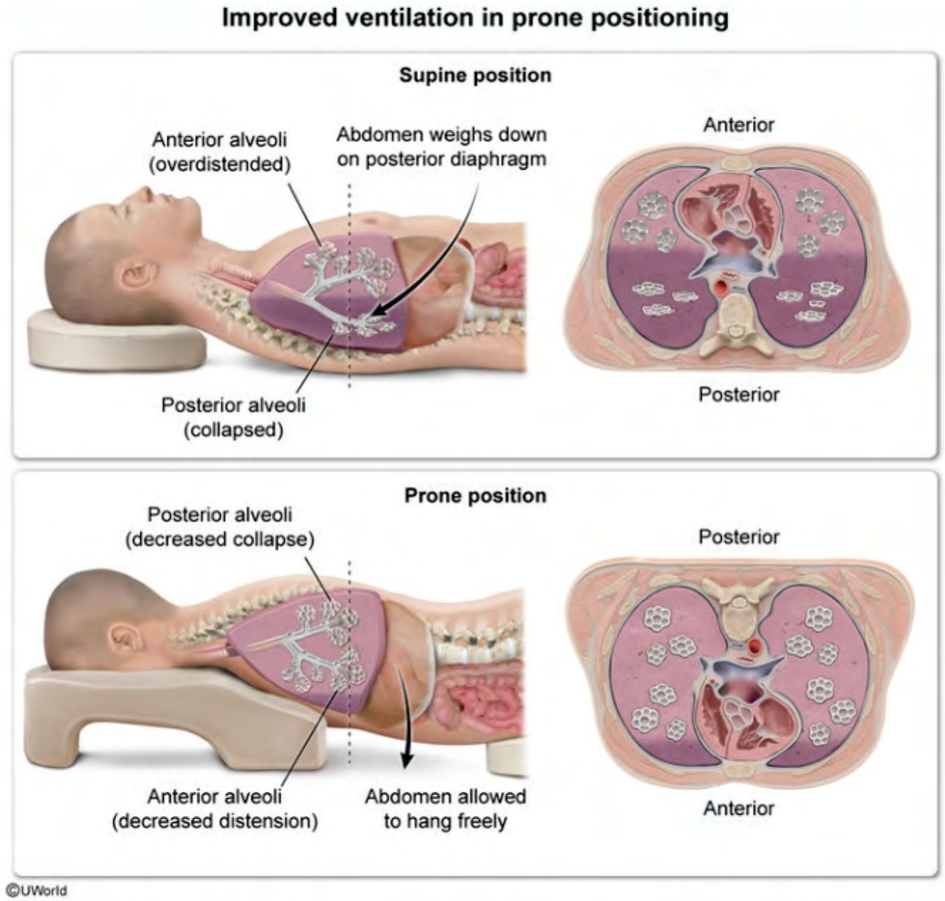

Zoom In | Zoom Out | Reset | New | Existing | My Notebook

https://t.me/USMLEWorldStep1

©UWorld

Prone positioning (lying face down) is sometimes used to improve arterial oxygenation in patients with severe **acute respiratory distress syndrome**. It likely does so by reducing atelectasis of posterior alveoli to reduce intrapulmonary shunting and **improve ventilation-perfusion matching** throughout the lungs.

Because the heart occupies anterior space in the chest cavity, the **majority of lung mass is located posteriorly**. When a patient is in the supine position (lying face up), the weight of the heart and anterior lung segments compresses the posterior lung segments and limits ventilation of posterior alveoli. In addition, abdominal organ and tissue mass weighs considerably on the posterior portion of the diaphragm, displacing it cranially and further contributing to compression of the posterior basal lung segments. The anterior alveoli, subjected to minimal compression and ample ventilation in the supine position, are often hyperinflated, increasing the risk of barotrauma in those regions.

Prone positioning causes the heart and anterior lung mass to rest on the anterior chest wall, **alleviating compression of the posterior lung segments**. In addition, the freely hanging abdomen **removes pressure on the diaphragm**, allowing the diaphragm to move caudally and further open up collapsed posterior basal alveoli. With a higher percentage of total alveoli opened, **ventilation is more evenly distributed**, improving arterial oxygenation and reducing alveolar hyperinflation and hyperdistension (which may decrease the risk of barotrauma) **(Choice A).**

(Choices B and D) Prone positioning may increase venous return (ie, right ventricular preload) and, consequently, cardiac output by positioning the heart slightly below the large reservoir of venous blood in the splanchnic circulation (ie, additional stores of venous blood are mobilized to the right atrium).

(Choice C) By reducing posterior lung compression and decreasing atelectasis, prone positioning increases functional residual capacity (ie, the volume of air in the lungs at the end of tidal expiration).

Educational objective:
Prone positioning may be used to improve arterial oxygenation in patients with severe acute respiratory distress syndrome. The improvement likely results from reduced compression of the posterior lung segments, where the majority of alveoli are located. This leads to more evenly distributed ventilation throughout the lungs with reduced intrapulmonary shunting and improved ventilation-perfusion matching.

https://t.me/USMLEWorldStep1

A 38-year-old woman comes to the office due to progressively worsening exertional dyspnea. She used to jog frequently, but now becomes short of breath while grocery shopping. The patient has no other significant medical history and takes no medications. She smokes a half pack of cigarettes daily and does not use alcohol or illicit drugs. Blood pressure is 124/76 mm Hg, pulse is 78/min, and respirations are 20/min. Pulse oximetry shows 89% on room air. BMI is 27 kg/m^2. Cardiac examination is unremarkable. The chest is hyperresonant to percussion. Laboratory studies show markedly decreased serum alpha-1 antitrypsin levels. Which of the following pulmonary function test patterns is most likely to be present in this patient?

	Forced expiratory volume in 1 sec/forced vital capacity	Total lung capacity	Diffusing capacity for carbon monoxide
○ A.	↓	↑	↑
○ B.	↓	↑	↓
○ C.	Normal	Normal	↓
○ D.	Normal	↓	Normal
○ E.	Normal	↓	↓

Submit

https://t.me/USMLEWorldStep1

A 38-year-old woman comes to the office due to progressively worsening exertional dyspnea. She used to jog frequently, but now becomes short of breath while grocery shopping. The patient has no other significant medical history and takes no medications. She smokes a half pack of cigarettes daily and does not use alcohol or illicit drugs. Blood pressure is 124/76 mm Hg, pulse is 78/min, and respirations are 20/min. Pulse oximetry shows 89% on room air. BMI is 27 kg/m^2. Cardiac examination is unremarkable. The chest is hyperresonant to percussion. Laboratory studies show markedly decreased serum alpha-1 antitrypsin levels. Which of the following pulmonary function test patterns is most likely to be present in this patient?

	Forced expiratory volume in 1 sec/forced vital capacity	Total lung capacity	Diffusing capacity for carbon monoxide	
A.	↓	↑	↑	(16%)
✓ B.	↓	↑	↓	(70%)
C.	Normal	Normal	↓	(1%)
D.	Normal	↓	Normal	(2%)
E.	Normal	↓	↓	(7%)

Correct

70%
Answered correctly

04 secs
Time Spent

2023
Version

Explanation

Classic pulmonary function patterns

Abnormal FEV_1 &/or FVC

https://t.me/USMLEWorldStep1

Exhibit Display

Classic pulmonary function patterns

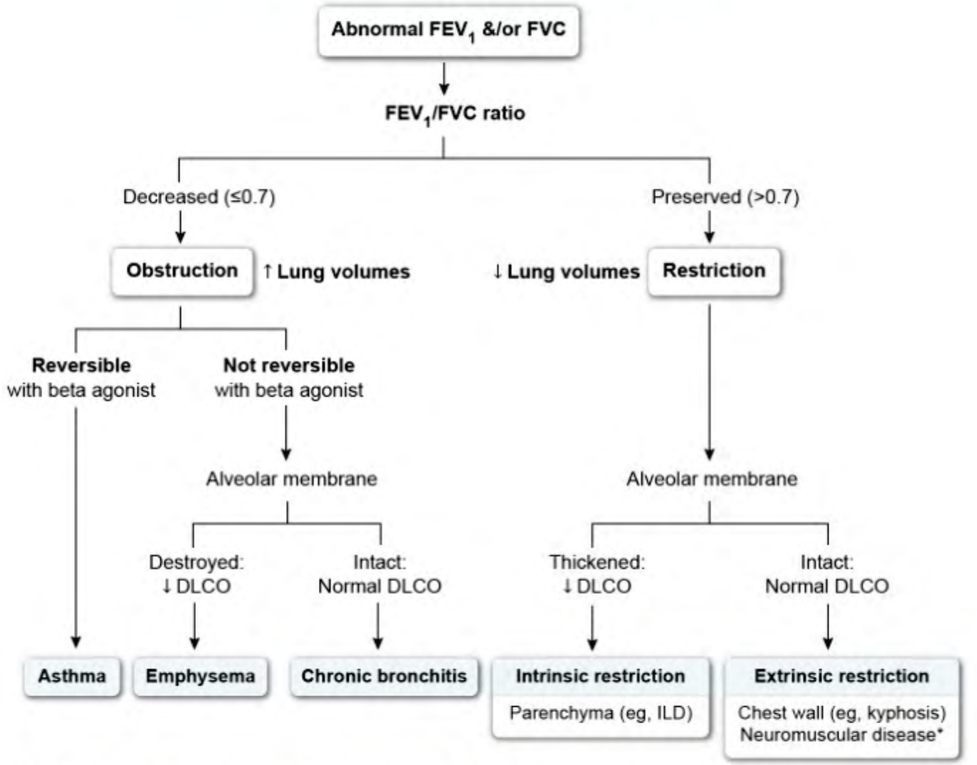

DLCO = diffusion capacity of the lung for carbon monoxide; **FEV_1** = forced expiratory volume in 1 second; **FVC** = forced vital capacity; **ILD** = interstitial lung disease; **RV** = residual volume; **TLC** = total lung capacity.
*Lung volumes show ↓ TLC (inspiratory muscle weakness) but ↑ RV (expiratory muscle weakness)

©UWorld

Zoom In | Zoom Out | Reset | New | Existing | My Notebook

*Lung volumes show ↓ TLC (inspiratory muscle weakness) but ↑ RV (expiratory muscle weakness) ©UWorld

This young woman with progressively worsening dyspnea and decreased alpha-1 antitrypsin (A1AT) levels has

https://t.me/USMLEWorldStep1

This young woman with progressively worsening dyspnea and decreased alpha-1 antitrypsin (A1AT) levels has **A1AT deficiency**. A1AT is a serum protein secreted by the liver that inhibits proteolytic enzymes (particularly neutrophil elastase) released by inflammatory cells. The lungs use A1AT to inhibit low levels of naturally occurring proteolysis. Without A1AT, these proteolytic enzymes go unchecked, causing **emphysematous destruction** of alveoli and the surrounding tissue, typically in a panacinar pattern.

Characteristic pulmonary test findings of emphysema (from any cause) include:

- **Decreased FEV_1/FVC** (ie, an obstructive ratio [≤0.7]) due to significant airflow obstruction by narrow and floppy airways (loss of supporting elastin reduces the radial traction that holds small airways open).
- Increased residual volume due to incomplete lung emptying (air trapping) and **elevated total lung capacity** (TLC) due to emphysematous tissue destruction with subsequent airspace enlargement.
- Diffusing capacity of the lung for carbon monoxide (**DLCO**) tends to be **reduced** due to destruction of the alveolar capillary beds (decreased surface area available for gas exchange).

The development of emphysema (eg, lung hyperresonance) in these patients is greatly **accelerated by cigarette smoking**; even in the absence of smoking, patients with A1AT deficiency typically develop **early-onset emphysema** prior to age 50.

(Choice A) Asthma is another obstructive lung disease that presents with reduced FEV_1/FVC; although TLC can also be increased due to lung hyperinflation, it is more characteristic of COPD (extensive tissue destruction). In contrast to COPD, patients with asthma sometimes develop a high DLCO (increased negative intrathoracic pressure during inspiration increases pulmonary capillary blood volume, causing additional gas uptake).

(Choice C) Pulmonary arterial hypertension presents with reduced DLCO in the setting of normal spirometry and lung volumes, as the poor pulmonary capillary blood flow impairs the lungs' ability to extract oxygen (reduced DLCO); the airways and lung parenchyma are unaffected, resulting in intact lung mechanics (normal FEV_1/FVC ratio and TLC).

(Choices D and E) Restrictive processes demonstrate reduced lung volumes (eg, low TLC) with a normal or an increased FEV_1/FVC ratio (although FEV_1 and FVC are reduced individually). The DLCO differentiates *intrinsic* restriction (eg, interstitial lung disease) from *extrinsic* restriction (eg, kyphosis, neuromuscular disease); it is

https://t.me/USMLEWorldStep1

- **Decreased FEV_1/FVC** (ie, an obstructive ratio [≤0.7]) due to significant airflow obstruction by narrow and floppy airways (loss of supporting elastin reduces the radial traction that holds small airways open).
- Increased residual volume due to incomplete lung emptying (air trapping) and **elevated total lung capacity** (TLC) due to emphysematous tissue destruction with subsequent airspace enlargement.
- Diffusing capacity of the lung for carbon monoxide (**DLCO**) tends to be **reduced** due to destruction of the alveolar capillary beds (decreased surface area available for gas exchange).

The development of emphysema (eg, lung hyperresonance) in these patients is greatly **accelerated by cigarette smoking**; even in the absence of smoking, patients with A1AT deficiency typically develop **early-onset emphysema** prior to age 50.

(Choice A) Asthma is another obstructive lung disease that presents with reduced FEV_1/FVC; although TLC can also be increased due to lung hyperinflation, it is more characteristic of COPD (extensive tissue destruction). In contrast to COPD, patients with asthma sometimes develop a high DLCO (increased negative intrathoracic pressure during inspiration increases pulmonary capillary blood volume, causing additional gas uptake).

(Choice C) Pulmonary arterial hypertension presents with reduced DLCO in the setting of normal spirometry and lung volumes, as the poor pulmonary capillary blood flow impairs the lungs' ability to extract oxygen (reduced DLCO); the airways and lung parenchyma are unaffected, resulting in intact lung mechanics (normal FEV_1/FVC ratio and TLC).

(Choices D and E) Restrictive processes demonstrate reduced lung volumes (eg, low TLC) with a normal or an increased FEV_1/FVC ratio (although FEV_1 and FVC are reduced individually). The DLCO differentiates *intrinsic* restriction (eg, interstitial lung disease) from ***extrinsic*** restriction (eg, kyphosis, neuromuscular disease); it is decreased in the former (thickened basement membrane) and normal in the latter.

Educational objective:
Alpha-1 antitrypsin deficiency can induce early-onset emphysema, which is further accelerated by smoking. Emphysema is characterized by expiratory airflow obstruction (decreased FEV_1/FVC ratio), airspace enlargement and hyperinflation (increased total lung capacity), and a decreased diffusing capacity due to loss of alveolar surface area.

https://t.me/USMLEWorldStep1

Neuromuscular disease*

Exhibit Display

This y
A1AT
neutro
proteo
alveoli

Chara

- **D**
- In
- D

The de
smoki
emphy

(Choi
also b
contra
pressu

(Choice C) Pulmonary arterial hypertension presents with reduced DLCO in the setting of normal spirometry and lung volumes, as the poor pulmonary capillary blood flow impairs the lungs' ability to extract oxygen (reduced DLCO); the airways and lung parenchyma are unaffected, resulting in intact lung mechanics (normal FEV_1/FVC ratio and TLC).

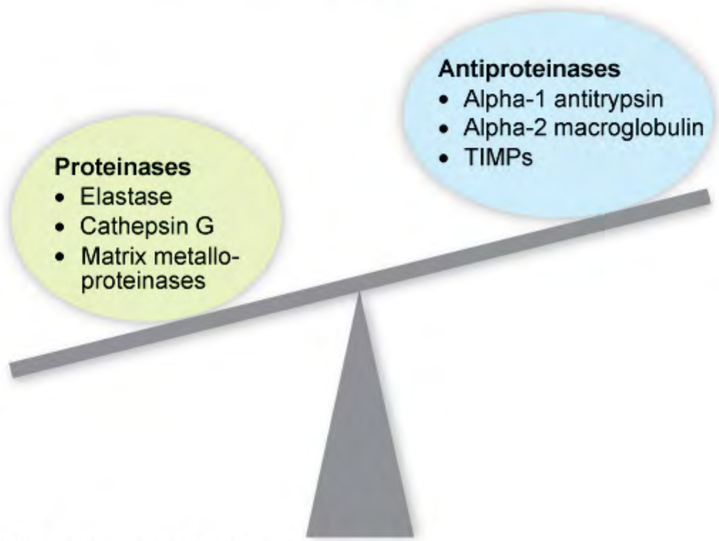

TIMPs = tissue inhibitors of metalloproteinase.
©UWorld

Zoom In Zoom Out Reset New | Existing My Notebook

https://t.me/USMLEWorldStep1

Neuromuscular disease*

Exhibit Display

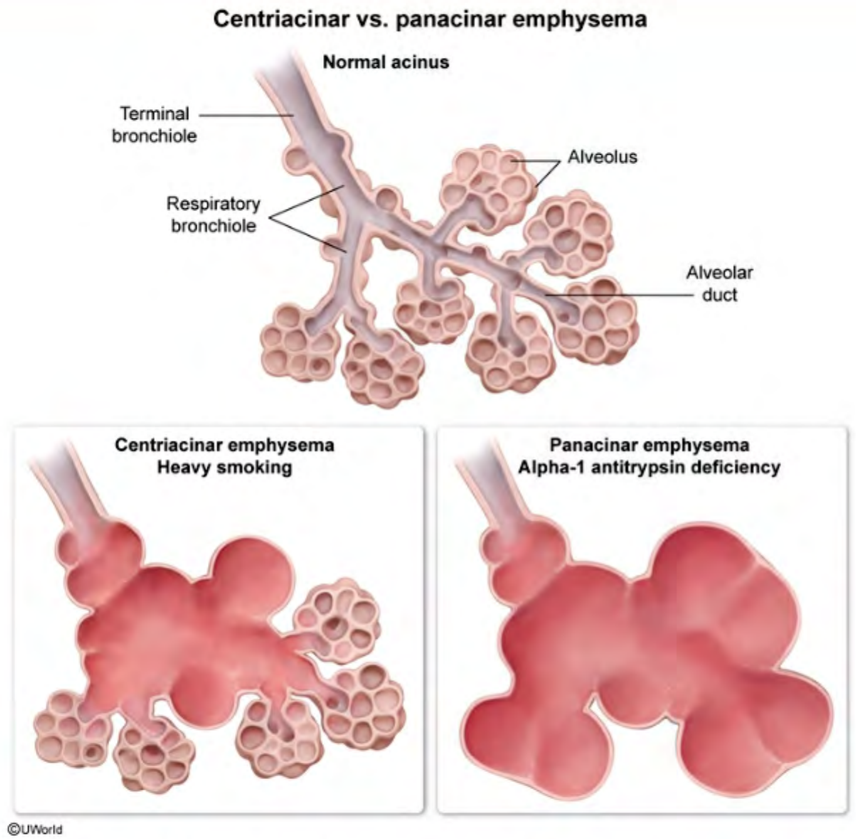

Zoom In | Zoom Out | Reset | New | Existing | My Notebook

This y
A1AT
neutro
proteo
alveoli

Chara

- **D** fl
- In (T
- D a

The de
smoki
emphy

(Choi
also b
contra
pressu

(Choice C) Pulmonary arterial hypertension presents with reduced DLCO in the setting of normal spirometry and lung volumes, as the poor pulmonary capillary blood flow impairs the lungs' ability to extract oxygen (reduced DLCO); the airways and lung parenchyma are unaffected, resulting in intact lung mechanics (normal FEV_1/FVC ratio and TLC).

https://t.me/USMLEWorldStep1

A 65-year-old man comes to the office due to a 6-month history of exertional dyspnea. Over the past few weeks he has also developed a nonproductive cough. Medical history is notable for hypertension and hypercholesterolemia. The patient does not use tobacco, alcohol, or illicit drugs. Temperature is 36.9 C (98.4 F), blood pressure is 130/80 mm Hg, pulse is 80/min, and respirations are 18/min. Examination shows late inspiratory crackles in both lung bases and mild digital clubbing. The patient undergoes lung biopsy; histologic examination shows areas of dense collagen fibrosis, foci of proliferating fibroblasts, mild interstitial inflammation, and honeycomb changes. The interstitial inflammation is patchy and consists of a lymphoplasmacytic infiltrate in the alveolar septa associated with hyperplasia of type 2 pneumocytes. Pharmacotherapy aimed at which of the following is most helpful in treating this patient's lung condition?

- A. Alpha-1 antitrypsin
- B. Endothelin-1
- C. Interleukin-5
- D. Phosphodiesterase-4
- E. Transforming growth factor beta

Submit

https://t.me/USMLEWorldStep1

A 65-year-old man comes to the office due to a 6-month history of exertional dyspnea. Over the past few weeks he has also developed a nonproductive cough. Medical history is notable for hypertension and hypercholesterolemia. The patient does not use tobacco, alcohol, or illicit drugs. Temperature is 36.9 C (98.4 F), blood pressure is 130/80 mm Hg, pulse is 80/min, and respirations are 18/min. Examination shows late inspiratory crackles in both lung bases and mild digital clubbing. The patient undergoes lung biopsy; histologic examination shows areas of dense collagen fibrosis, foci of proliferating fibroblasts, mild interstitial inflammation, and honeycomb changes. The interstitial inflammation is patchy and consists of a lymphoplasmacytic infiltrate in the alveolar septa associated with hyperplasia of type 2 pneumocytes. Pharmacotherapy aimed at which of the following is most helpful in treating this patient's lung condition?

- A. Alpha-1 antitrypsin (14%)
- ✗ B. Endothelin-1 (14%)
- C. Interleukin-5 (6%)
- D. Phosphodiesterase-4 (7%)
- ✓ E. Transforming growth factor beta (57%)

Incorrect
Correct answer
E

57%
Answered correctly

01 min, 24 secs
Time Spent

2023
Version

Explanation

This patient with progressive dyspnea, dry cough, digital clubbing, and crackles on examination has signs of an interstitial lung disease. The histologic findings of **patchy dense collagen fibrosis** in the interstitium, foci of **fibroblastic proliferation**, honeycombing, and mild lymphoplasmacytic infiltrates with hyperplasia of type 2

https://t.me/USMLEWorldStep1

This patient with progressive dyspnea, dry cough, digital clubbing, and crackles on examination has signs of an interstitial lung disease. The histologic findings of **patchy dense collagen fibrosis** in the interstitium, foci of **fibroblastic proliferation**, honeycombing, and mild lymphoplasmacytic infiltrates with hyperplasia of type 2 pneumocytes are highly suggestive of **idiopathic pulmonary fibrosis** (IPF).

IPF is a chronic, progressive fibrotic lung disease thought to be due to recurrent episodes of lung injury and disordered healing. Persistent inflammation likely triggers excessive activity of growth factors normally involved in wound healing, including transforming growth factor-beta (TGF-β), platelet-derived growth factor (PDGF), fibroblastic growth factor (FGF), and vascular endothelial growth factor (VEGF). This leads to increased fibroblast activity, myofibroblast formation, and collagen production, which contribute to pulmonary fibrosis. **Pirfenidone** is an antifibrotic agent that **inhibits TGF-β**; another treatment option is nintedanib, a tyrosine kinase inhibitor that inhibits PDGF, FGF, and VEGF. Although neither drug is curative, these therapies have been shown to slow progressive fibrosis in patients with IPF.

(Choice A) Alpha-1 antitrypsin infusion is used to treat patients with alpha-1 antitrypsin deficiency, which causes panacinar emphysema and typically presents in young patients with dyspnea and cough. Histologic findings in emphysema include large alveoli with thin septa.

(Choice B) Endothelin-1 inhibitors (eg, ambrisentan, bosentan) are used to treat idiopathic pulmonary hypertension. Histologic findings of pulmonary hypertension include pulmonary vascular media and intima hypertrophy and intimal fibrosis.

(Choice C) Monoclonal antibodies directed at interleukin-5 (eg, reslizumab) inhibit eosinophil recruitment and proliferation, and are used in patients with severe eosinophilic asthma. Histologic findings in asthma include goblet cell hyperplasia, bronchial smooth muscle hypertrophy, edema, eosinophilia, and Charcot-Leyden crystals.

(Choice D) Phosphodiesterase-4 inhibitors (ie, roflumilast) block the degradation of cyclic AMP, leading to reduced airway inflammation and smooth muscle relaxation in patients with chronic obstructive pulmonary disease. Histologic findings include both airspace enlargement with thin septa (emphysema) and goblet cell hyperplasia with

https://t.me/USMLEWorldStep1

wound healing, including transforming growth factor-beta (TGF-β), platelet-derived growth factor (PDGF), fibroblastic growth factor (FGF), and vascular endothelial growth factor (VEGF). This leads to increased fibroblast activity, myofibroblast formation, and collagen production, which contribute to pulmonary fibrosis. **Pirfenidone** is an antifibrotic agent that **inhibits TGF-β**; another treatment option is nintedanib, a tyrosine kinase inhibitor that inhibits PDGF, FGF, and VEGF. Although neither drug is curative, these therapies have been shown to slow progressive fibrosis in patients with IPF.

(Choice A) Alpha-1 antitrypsin infusion is used to treat patients with alpha-1 antitrypsin deficiency, which causes panacinar emphysema and typically presents in young patients with dyspnea and cough. Histologic findings in emphysema include large alveoli with thin septa.

(Choice B) Endothelin-1 inhibitors (eg, ambrisentan, bosentan) are used to treat idiopathic pulmonary hypertension. Histologic findings of pulmonary hypertension include pulmonary vascular media and intima hypertrophy and intimal fibrosis.

(Choice C) Monoclonal antibodies directed at interleukin-5 (eg, reslizumab) inhibit eosinophil recruitment and proliferation, and are used in patients with severe eosinophilic asthma. Histologic findings in asthma include goblet cell hyperplasia, bronchial smooth muscle hypertrophy, edema, eosinophilia, and Charcot-Leyden crystals.

(Choice D) Phosphodiesterase-4 inhibitors (ie, roflumilast) block the degradation of cyclic AMP, leading to reduced airway inflammation and smooth muscle relaxation in patients with chronic obstructive pulmonary disease. Histologic findings include both airspace enlargement with thin septa (emphysema) and goblet cell hyperplasia with excess mucus production (chronic bronchitis).

Educational objective:
Histologic findings of idiopathic pulmonary fibrosis include patchy dense collagen fibrosis in the interstitium, focal fibroblastic proliferation, honeycombing, and mild lymphoplasmacytic infiltrates with hyperplasia of type 2 pneumocytes. Therapies are directed at slowing the progression of fibrosis by inhibiting transforming growth factor-beta and other fibrogenic growth factors (eg, PDGF, fibroblastic growth factor, and VEGF).

https://t.me/USMLEWorldStep1

Incorrect
Correct answer
E

57%
01 min, 24 secs
2023

Explanation

This patient wi
interstitial lung
fibroblastic pr
pneumocytes a

IPF is a chroni
disordered hea
wound healing
fibroblastic gro
activity, myofib
an antifibrotic a
inhibits PDGF,
progressive fib

(Choice A) Al
panacinar emp
emphysema in

(Choice B) Er
hypertension.
hypertrophy ar

(Choice C) M

Exhibit Display

Idiopathic pulmonary fibrosis

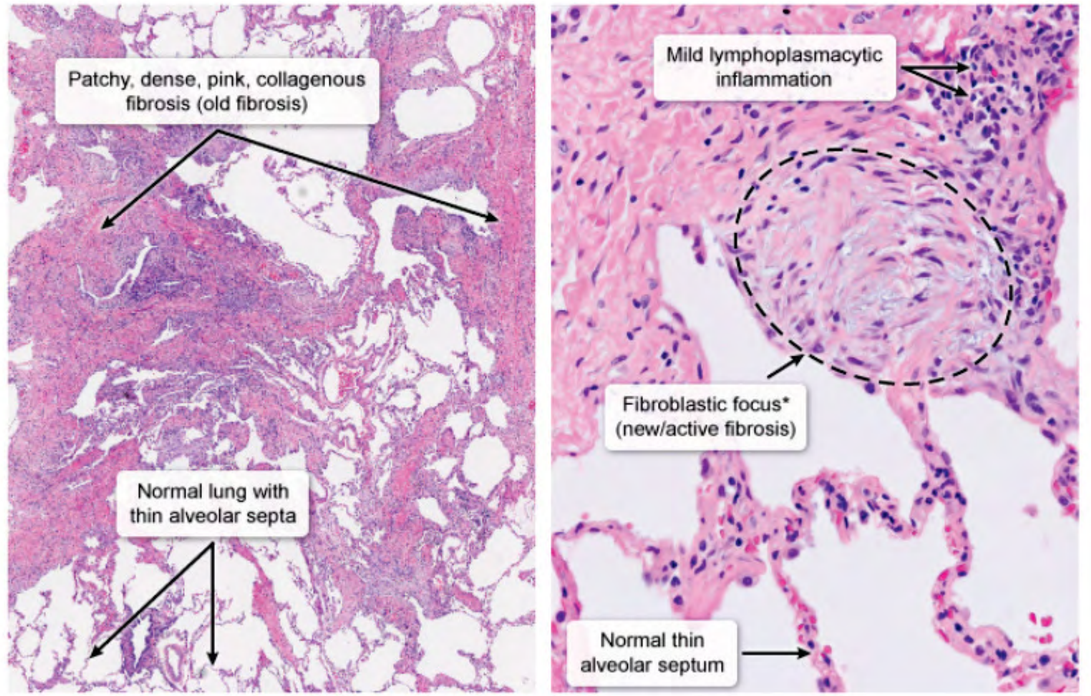

*Proliferation of fibroblasts and myofibroblasts with pale gray stroma.

©UWorld

Zoom In | Zoom Out | Reset | New | Existing | My Notebook

https://t.me/USMLEWorldStep1

Incorrect
Correct answer
E

57%
01 min, 24 secs
2023

Explanation

This patient wi
interstitial lung
fibroblastic pr
pneumocytes a

IPF is a chroni
disordered hea
wound healing
fibroblastic gro
activity, myofib
an antifibrotic a
inhibits PDGF,
progressive fib

(Choice A) Al
panacinar emp
emphysema in

(Choice B) Er
hypertension.
hypertrophy ar

(Choice C) M

Exhibit Display

Lung with honeycomb change

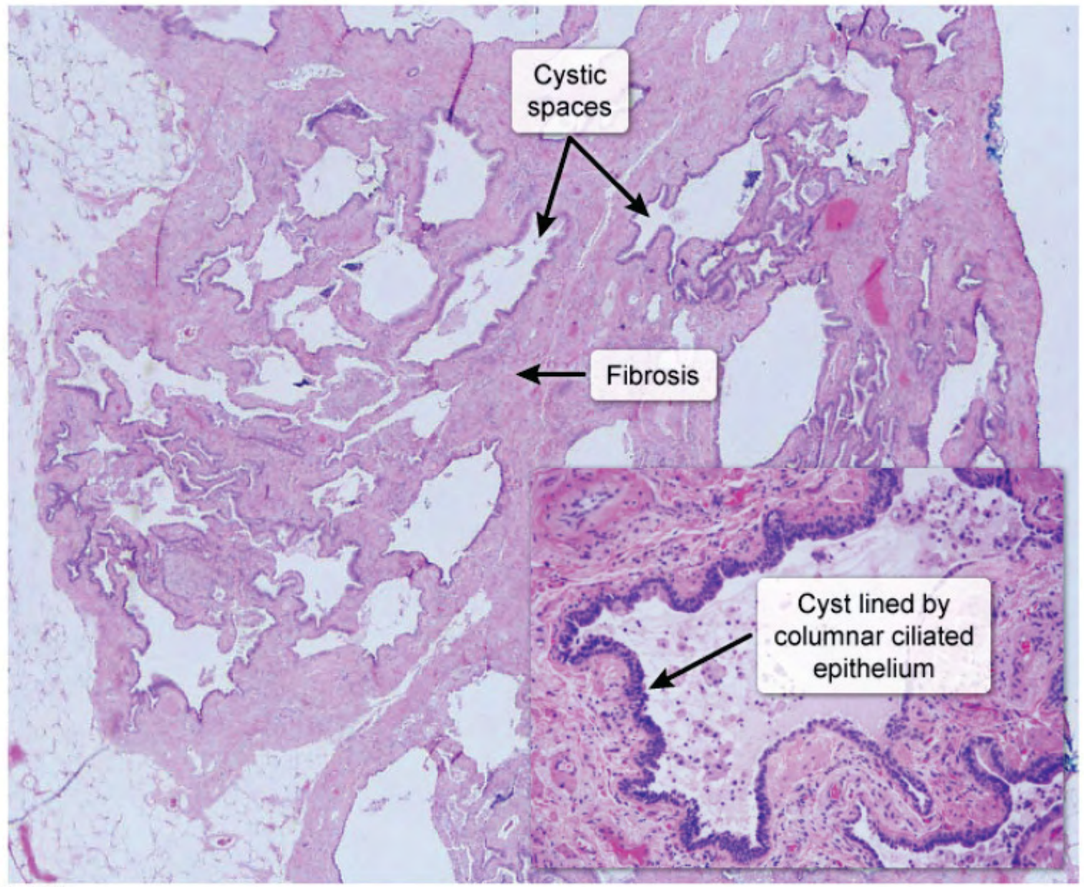

©UWorld

Zoom In | Zoom Out | Reset | New | Existing | My Notebook

https://t.me/USMLEWorldStep1

Incorrect
Correct answer
E

57%
01 min, 24 secs
2023

Explanation

This patient wi
interstitial lung
fibroblastic pr
pneumocytes a

IPF is a chroni
disordered hea
wound healing
fibroblastic gro
activity, myofib
an antifibrotic a
inhibits PDGF,
progressive fib

(Choice A) Al
panacinar emp
emphysema in

(Choice B) Er
hypertension.
hypertrophy ar

(Choice C) M

Exhibit Display

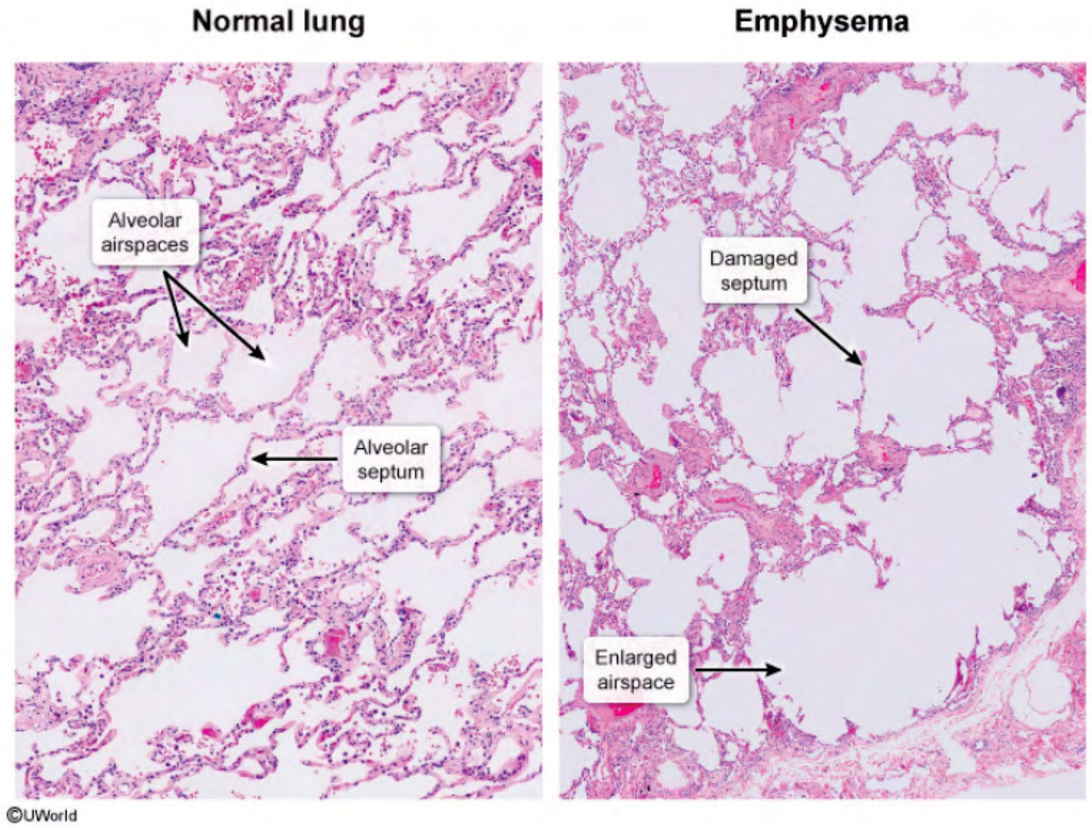

Zoom In
Zoom Out
Reset
New
Existing
My Notebook

https://t.me/USMLEWorldStep1

Incorrect
Correct answer
E

57%
01 min, 24 secs
2023

Exhibit Display

Explanation

This patient wi
interstitial lung
fibroblastic pr
pneumocytes a

IPF is a chroni
disordered hea
wound healing
fibroblastic gro
activity, myofib
an antifibrotic a
inhibits PDGF,
progressive fib

(Choice A) Al
panacinar emp
emphysema in

(Choice B) Er
hypertension.
hypertrophy ar

(Choice C) M

Pulmonary hypertension

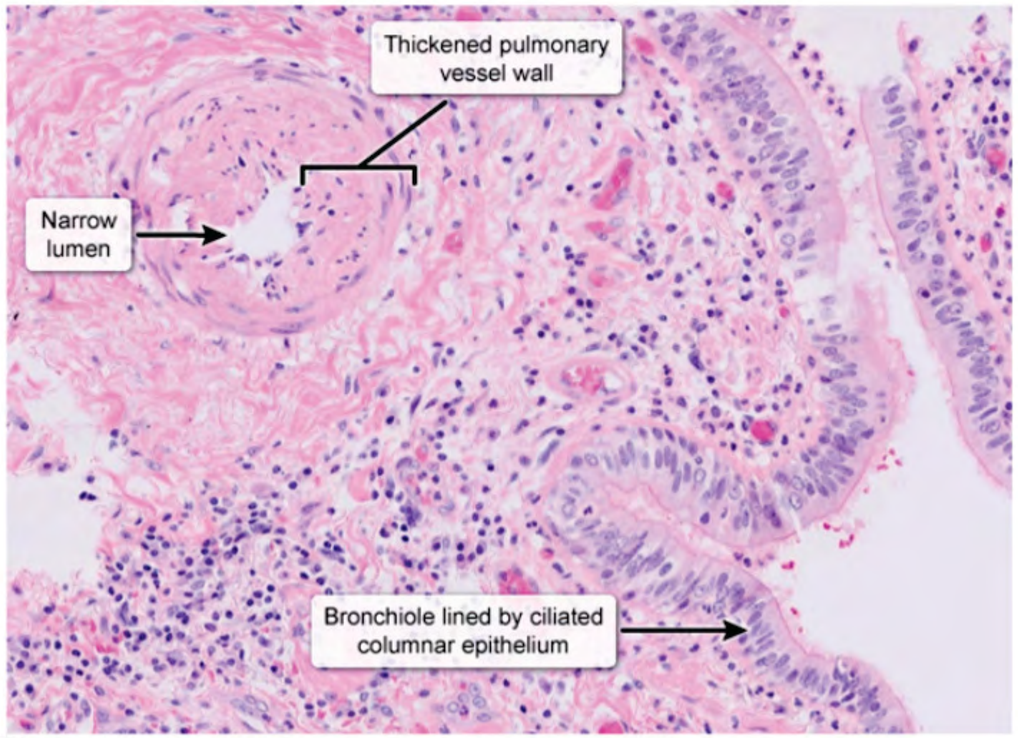

Zoom In | Zoom Out | Reset | New | Existing | My Notebook

https://t.me/USMLEWorldStep1

pneumocytes are highly suggestive of **idiopathic pulmonary fibrosis** (IPF).

IPF
diso
wou
fibro
activ
an a
inhib
prog

(Ch
pana
emp

(Ch
hype
hype

(Ch
proli
cell

(Ch
airw
Hist
exce

Edu

Histologic findings of idiopathic pulmonary fibrosis include patchy dense collagen fibrosis in the interstitium, focal

Exhibit Display

Asthma

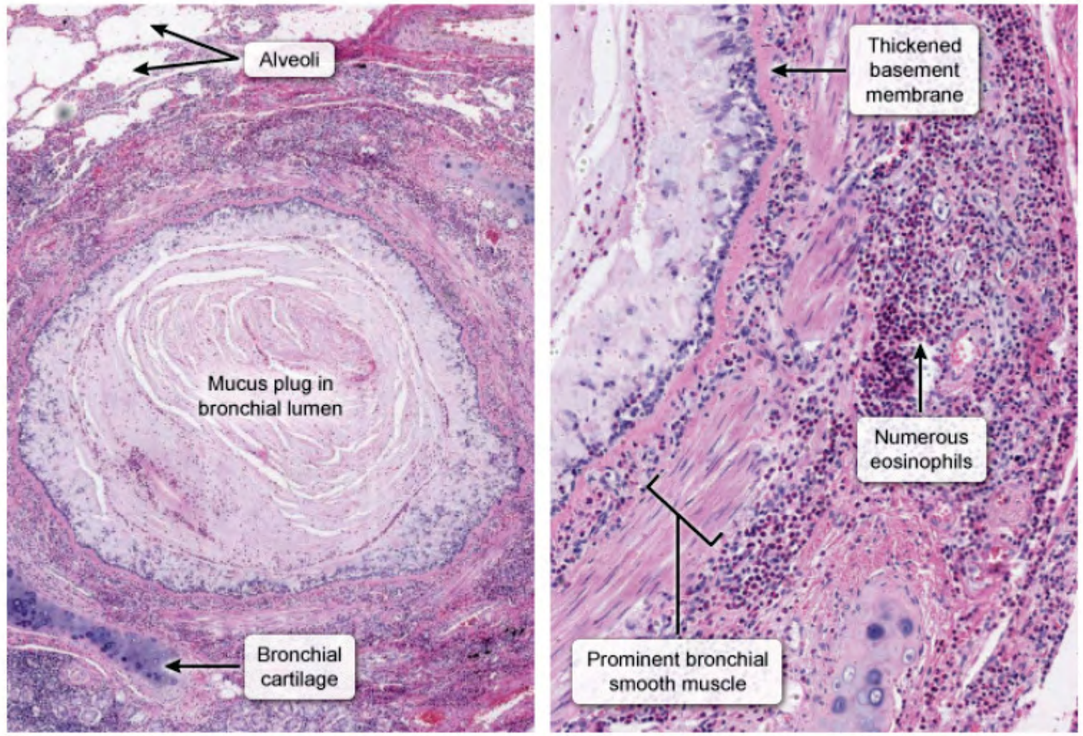

Zoom In | Zoom Out | Reset | New | Existing | My Notebook

https://t.me/USMLEWorldStep1

A 46-year-old man is brought to the emergency department 30 minutes after being found intoxicated in a park. The patient reports a 10-day history of fevers, night sweats, weight loss, and productive cough with foul-smelling sputum. He drinks 1 or 2 pints of vodka daily and has been hospitalized multiple times for intoxication. Temperature is 38.9 C (102 F), blood pressure is 110/65 mm Hg, pulse is 102/min, and respirations are 22/min. Lung auscultation reveals coarse crackles over the right lower lobe. Heart sounds are normal with no murmurs. Laboratory results show an elevated leukocyte count. Chest x-ray reveals a cavitary lesion with an air-fluid level in the superior segment of the right lower lobe of the lung. Which of the following is the most likely cause of this patient's lung findings?

- A. Aspiration of gastric acid
- B. Aspiration of oropharyngeal bacteria
- C. Hematogenous spread from another focus of infection
- D. Primary mycobacterial infection
- E. Simple pulmonary aspergilloma

Submit

https://t.me/USMLEWorldStep1

A 46-year-old man is brought to the emergency department 30 minutes after being found intoxicated in a park. The patient reports a 10-day history of fevers, night sweats, weight loss, and productive cough with foul-smelling sputum. He drinks 1 or 2 pints of vodka daily and has been hospitalized multiple times for intoxication. Temperature is 38.9 C (102 F), blood pressure is 110/65 mm Hg, pulse is 102/min, and respirations are 22/min. Lung auscultation reveals coarse crackles over the right lower lobe. Heart sounds are normal with no murmurs. Laboratory results show an elevated leukocyte count. Chest x-ray reveals a cavitary lesion with an air-fluid level in the superior segment of the right lower lobe of the lung. Which of the following is the most likely cause of this patient's lung findings?

- A. Aspiration of gastric acid (12%)
- ✓ B. Aspiration of oropharyngeal bacteria (70%)
- C. Hematogenous spread from another focus of infection (2%)
- D. Primary mycobacterial infection (10%)
- E. Simple pulmonary aspergilloma (5%)

Correct

70% Answered correctly

04 secs Time Spent

2023 Version

Explanation

Aspiration syndromes		
	Pneumonia	Pneumonitis

https://t.me/USMLEWorldStep1

Aspiration syndromes		
	Pneumonia	**Pneumonitis**
Pathophysiology	• Lung parenchyma **infection** • Aspiration of upper airway or stomach **microbes** (anaerobes)	• Lung parenchyma **inflammation** • Aspiration of **gastric acid** with direct tissue injury
Clinical features	• Present **days** after aspiration event • **Fever**, cough, ↑ sputum • CXR infiltrate in dependent lung segment (classically **RLL**) • Can progress to **abscess**	• Present **hours** after aspiration event • Range from no symptoms to nonproductive cough, ↓ O_2, respiratory distress • CXR infiltrates (one or both lower lobes) resolve without antibiotics
Management	• **Antibiotics:** clindamycin or beta-lactam & beta-lactamase inhibitor	• Supportive (no antibiotics)

https://t.me/USMLEWorldStep1

	Pneumonia	Pneumonitis
Pathophysiology	• Lung parenchyma **infection** • Aspiration of upper airway or stomach **microbes** (anaerobes)	• Lung parenchyma **inflammation** • Aspiration of **gastric acid** with direct tissue injury
Clinical features	• Present **days** after aspiration event • **Fever**, cough, ↑ sputum • CXR infiltrate in dependent lung segment (classically **RLL**) • Can progress to **abscess**	• Present **hours** after aspiration event • Range from no symptoms to nonproductive cough, ↓ O_2, respiratory distress • CXR infiltrates (one or both lower lobes) resolve without antibiotics
Management	• **Antibiotics:** clindamycin or beta-lactam & beta-lactamase inhibitor	• Supportive (no antibiotics)

CXR = chest x-ray; **RLL** = right lower lobe.

This patient has a cavitary lesion with an air-fluid level on chest x-ray, raising strong suspicion for **lung abscess**.

https://t.me/USMLEWorldStep1

This patient has a cavitary lesion with an air-fluid level on chest x-ray, raising strong suspicion for **lung abscess**. Most cases of lung abscess present with several weeks of fever, malaise, weight loss, and leukocytosis. Cough with copious production of greenish, **foul-smelling** sputum is also common.

Lung abscess usually forms due to the **aspiration of oropharyngeal bacteria**. Risk is greatest in patients with ≥1 of the following:

- **Periods of altered consciousness** (eg, alcohol use disorder, seizures, dementia)
- **Impaired swallowing** (eg, nasogastric tube, dysphagia)
- Periodontal disease, particularly gingivitis

Most lung abscesses are polymicrobial and feature a mixture of oral **anaerobic** (eg, *Fusobacterium*, *Peptostreptococcus*, *Bacteroides*) and aerobic bacteria. Infections are most common in dependent areas of the **right lung** because the right bronchus is straighter than the left bronchus; aspiration that occurs in the upright position usually leads to an abscess in the basal segment of the right lower lobe, whereas aspiration that occurs while supine often causes abscess in the posterior segment of the right upper lobe or the superior segment of the right lower lobe.

(Choice A) Aspiration of gastric acid causes chemical pneumonitis (acidic damage to alveoli), which typically results in severe dyspnea, hypoxia, and diffuse pulmonary infiltrates within hours of an aspiration event. It does not usually present with weeks of productive cough or a cavitary lesion.

(Choice C) Right-sided infective endocarditis may result in the development of multiple lung abscesses due to septic emboli. It is most often seen in intravenous drug use. This patient with alcohol use disorder has a single lung abscess in a dependent portion of the right lung, which is most likely due to aspirated oropharyngeal bacteria.

(Choice D) Cavitary tuberculosis (TB) is usually due to reactivated (not primary) mycobacterial infection. In addition, TB cavities do not typically have air-fluid levels and are most common in the upper portions of the lung.

(Choice E) An aspergilloma (fungal ball) usually colonizes an already existing lung cavity, typically in the presence

https://t.me/USMLEWorldStep1

- Periodontal disease, particularly gingivitis

Most lung abscesses are polymicrobial and feature a mixture of oral **anaerobic** (eg, *Fusobacterium*, *Peptostreptococcus*, *Bacteroides*) and aerobic bacteria. Infections are most common in dependent areas of the **right lung** because the right bronchus is straighter than the left bronchus; aspiration that occurs in the upright position usually leads to an abscess in the basal segment of the right lower lobe, whereas aspiration that occurs while supine often causes abscess in the posterior segment of the right upper lobe or the superior segment of the right lower lobe.

(Choice A) Aspiration of gastric acid causes chemical pneumonitis (acidic damage to alveoli), which typically results in severe dyspnea, hypoxia, and diffuse pulmonary infiltrates within hours of an aspiration event. It does not usually present with weeks of productive cough or a cavitary lesion.

(Choice C) Right-sided infective endocarditis may result in the development of multiple lung abscesses due to septic emboli. It is most often seen in intravenous drug use. This patient with alcohol use disorder has a single lung abscess in a dependent portion of the right lung, which is most likely due to aspirated oropharyngeal bacteria.

(Choice D) Cavitary tuberculosis (TB) is usually due to reactivated (not primary) mycobacterial infection. In addition, TB cavities do not typically have air-fluid levels and are most common in the upper portions of the lung.

(Choice E) An aspergilloma (fungal ball) usually colonizes an already existing lung cavity, typically in the presence of TB, lung cancer, or chronic obstructive pulmonary disease. Aspergillomas generally occur in the upper lobes. Unlike chronic aspergillosis, simple aspergillomas are not associated with systemic symptoms (eg, fever, hemoptysis).

Educational objective:
Lung abscess usually occurs in individuals with episodes of impaired consciousness (eg, alcohol/substance use disorder, dementia) or decreased ability to swallow (eg, esophageal strictures). They are generally caused by aspiration of anaerobic and aerobic bacteria from the oral cavity into the lower respiratory tract.

https://t.me/USMLEWorldStep1

A 55-year-old man comes to the office due to malaise and cough over the past 2 months. He describes yellow sputum production with occasional streaks of blood. The patient smokes a pack of cigarettes daily and has a history of alcohol use disorder with prior episodes of binge drinking. Temperature is 37.1 C (98.8 F). Examination shows poor dentition with dental caries, gingivitis, and enlarged submandibular lymph nodes. Coarse rhonchi are heard during auscultation of the right lung. Chest CT scan reveals an extensive right lung consolidative process with air bronchograms. Bronchoscopy is performed, and a lung biopsy specimen shows the findings in the image below.

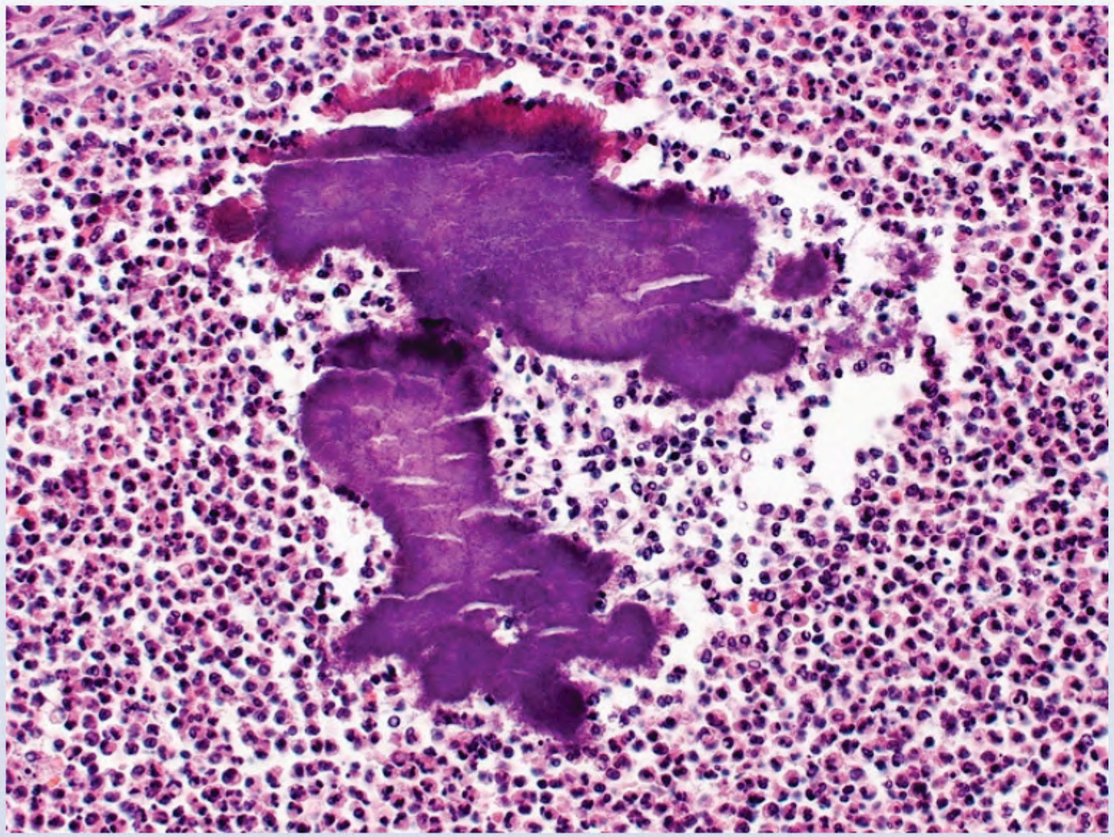

https://t.me/USMLEWorldStep1

A 55 sput histo show hear with belo

Exhibit Display

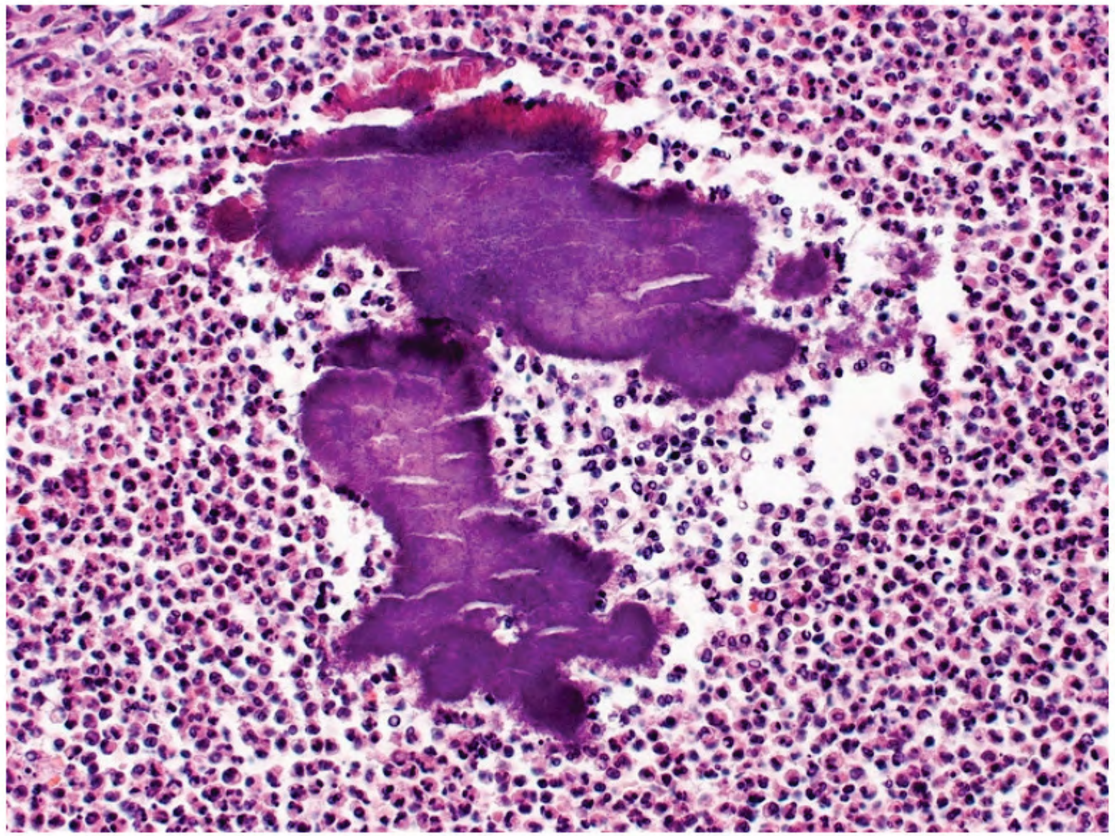

Zoom In Zoom Out Reset New | Existing My Notebook

https://t.me/USMLEWorldStep1

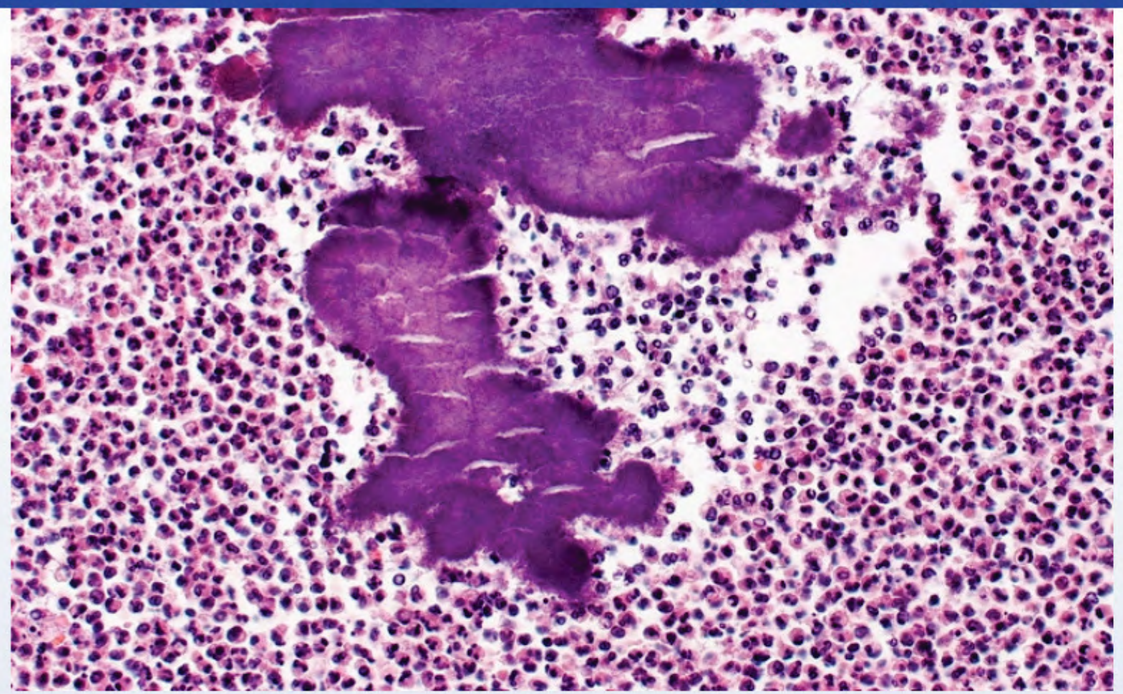

Which of the following is the most likely diagnosis?

- A. Actinomycosis
- B. Adenocarcinoma
- C. Mucormycosis
- D. Sarcoidosis
- E. Tuberculosis

Submit

https://t.me/USMLEWorldStep1

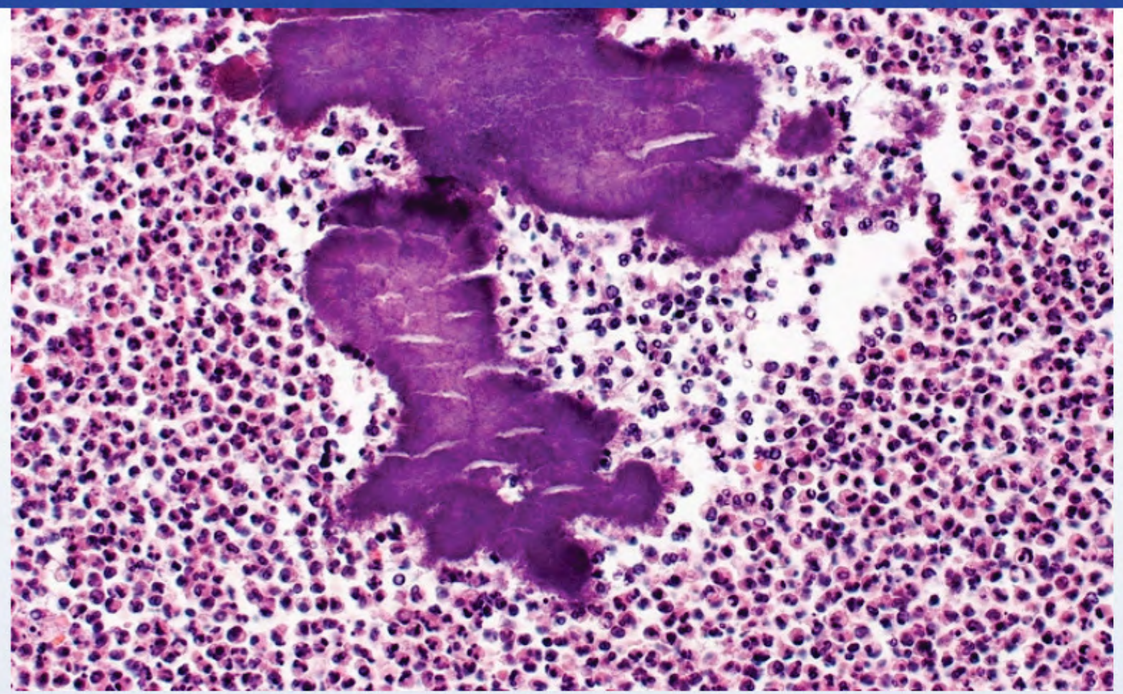

Which of the following is the most likely diagnosis?

- ✓ A. Actinomycosis (61%)
- ✗ B. Adenocarcinoma (12%)
- C. Mucormycosis (7%)
- D. Sarcoidosis (8%)
- E. Tuberculosis (10%)

Incorrect
Correct answer
A

61%
Answered correctly

17 secs
Time Spent

2023
Version

https://t.me/USMLEWorldStep1

E. Tuberculosis (10%)

Exhibit Display

Pulmonary actinomycosis

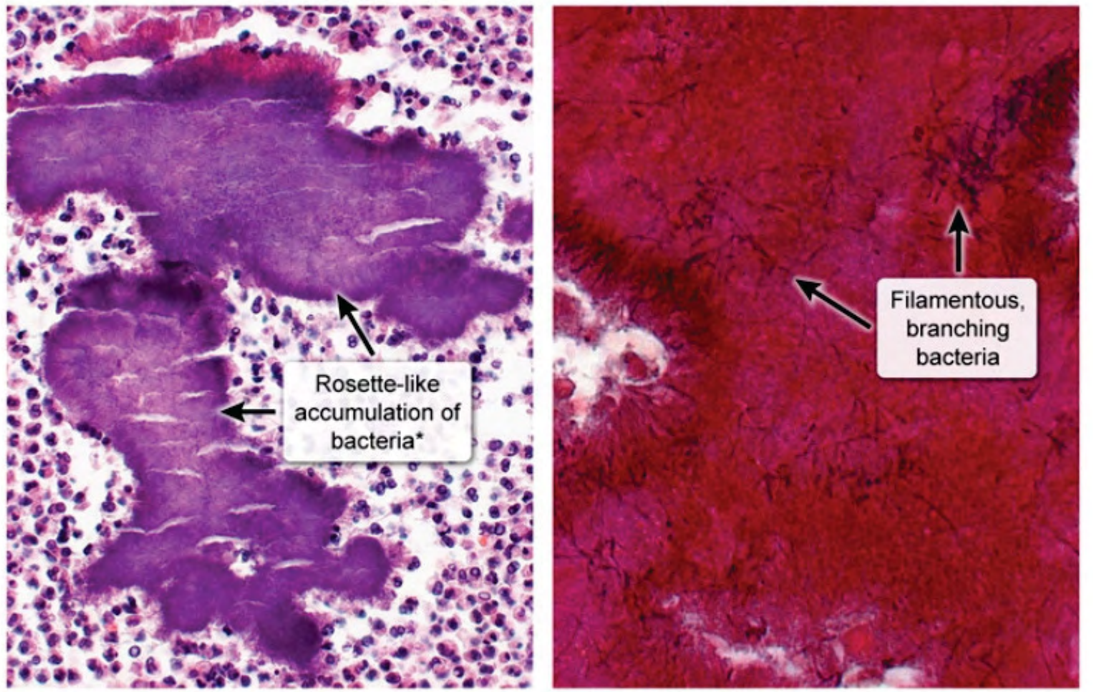

*Sulfur granule

©UWorld

Zoom In | Zoom Out | Reset | New | Existing | My Notebook

*Sulfur granule
©UWorld

https://t.me/USMLEWorldStep1

Actinomycosis is a slowly progressive disease caused by gram-positive anaerobic bacteria. These organisms typically colonize the mouth, colon, and vagina and can be found in dental caries as well as at the margins of gums in patients with poor dentition. *Actinomyces* infection most frequently leads to the formation of cervicofacial abscesses, but systemic infection can develop anywhere in the body when the mucosa is disrupted.

Pulmonary actinomycosis is usually caused by **aspiration**, which often leads to lower lobe consolidation with air bronchograms (air-filled bronchi with surrounding alveolar opacification). Patients with alcohol use disorder are at increased risk. Diagnosis is made by identifying the bacteria with unique filamentous, branching patterns and the characteristic **sulfur granules**, which are formed by calcified mycelial fragments. Sulfur granules grossly appear yellow; however, hematoxylin and eosin staining gives them a basophilic (purple/blue) appearance under light microscopy. **Penicillin G** is the antibiotic treatment of choice.

(Choice B) Lung adenocarcinoma frequently affects nonsmokers and can present with cough, hemoptysis, and pulmonary consolidation with air bronchograms. Histopathologic features typically include cuboidal to low columnar hyperchromatic cells with pleomorphism, prominent nucleoli, and glandular differentiation (eg, gland formation, intracellular mucin).

(Choice C) *Mucor* is a ubiquitous fungus naturally found in soil and decaying material. Mucormycosis results when the fungus is inhaled, causing sinopulmonary and sometimes angioinvasive disease, often in patients with diabetic ketoacidosis. Microscopic examination shows broad, ribbon-like, nonseptate hyphae with right-angle branching.

(Choice D) Sarcoidosis is an autoimmune disorder characterized by noncaseating granulomas on histopathologic examination of affected areas.

(Choice E) Tuberculosis is characterized on histopathology by caseating granulomas, with a necrotic center typically surrounded by multinucleated giant cells.

Educational objective:
Pulmonary actinomycosis develops most commonly following aspiration and can be confused with lung abscess,

https://t.me/USMLEWorldStep1

abscesses, but systemic infection can develop anywhere in the body when the mucosa is disrupted.

Pulmonary actinomycosis is usually caused by **aspiration**, which often leads to lower lobe consolidation with air bronchograms (air-filled bronchi with surrounding alveolar opacification). Patients with alcohol use disorder are at increased risk. Diagnosis is made by identifying the bacteria with unique filamentous, branching patterns and the characteristic **sulfur granules**, which are formed by calcified mycelial fragments. Sulfur granules grossly appear yellow; however, hematoxylin and eosin staining gives them a basophilic (purple/blue) appearance under light microscopy. **Penicillin G** is the antibiotic treatment of choice.

(Choice B) Lung adenocarcinoma frequently affects nonsmokers and can present with cough, hemoptysis, and pulmonary consolidation with air bronchograms. Histopathologic features typically include cuboidal to low columnar hyperchromatic cells with pleomorphism, prominent nucleoli, and glandular differentiation (eg, gland formation, intracellular mucin).

(Choice C) *Mucor* is a ubiquitous fungus naturally found in soil and decaying material. Mucormycosis results when the fungus is inhaled, causing sinopulmonary and sometimes angioinvasive disease, often in patients with diabetic ketoacidosis. Microscopic examination shows broad, ribbon-like, nonseptate hyphae with right-angle branching.

(Choice D) Sarcoidosis is an autoimmune disorder characterized by noncaseating granulomas on histopathologic examination of affected areas.

(Choice E) Tuberculosis is characterized on histopathology by caseating granulomas, with a necrotic center typically surrounded by multinucleated giant cells.

Educational objective:
Pulmonary actinomycosis develops most commonly following aspiration and can be confused with lung abscess, malignancy, or tuberculosis. Microscopic findings include filamentous, branching, gram-positive bacteria and sulfur granules.

References

https://t.me/USMLEWorldStep1

Exhibit Display

Gram stain of *Actinomyces*

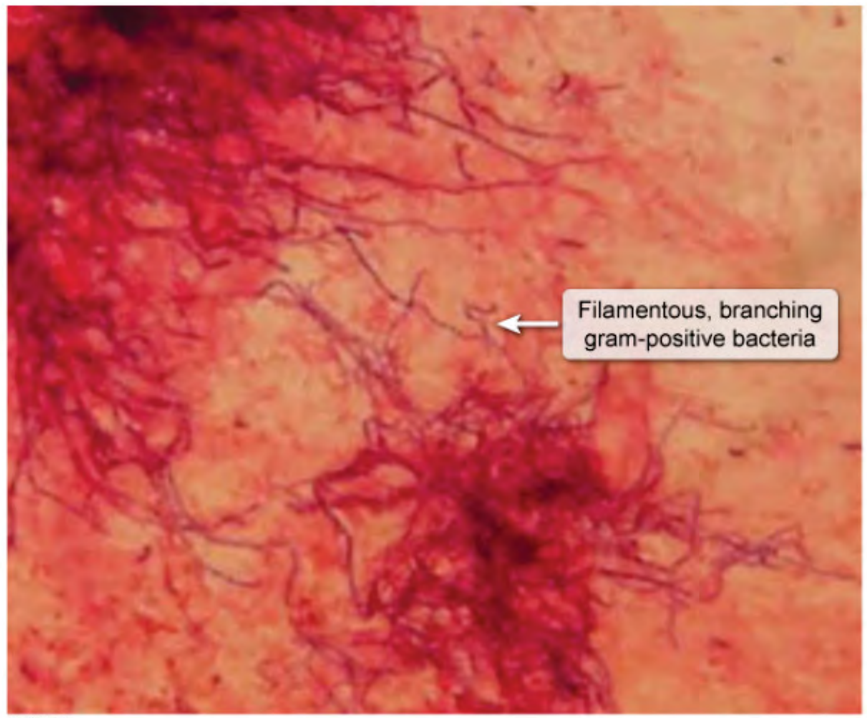

Zoom In | Zoom Out | Reset | New | Existing | My Notebook

Acti
typic
in pa
absc

Pulr
bron
incre
char
yello
micr

(Che
puln
colu
form

(Che
whe
diab
bran

(Che
exar

(Choice E) Tuberculosis is characterized on histopathology by caseating granulomas, with a necrotic center

https://t.me/USMLEWorldStep1

Actinomycosi
typically coloni
in patients with
abscesses, but

Pulmonary ac
bronchograms
increased risk.
characteristic s
yellow; howeve
microscopy. **P**

(Choice B) Lu
pulmonary con
columnar hype
formation, intra

(Choice C) *M*
when the fungu
diabetic ketoac
branching.

(Choice D) Sa
examination of

(Choice E) Tu

Exhibit Display

Lung adenocarcinoma

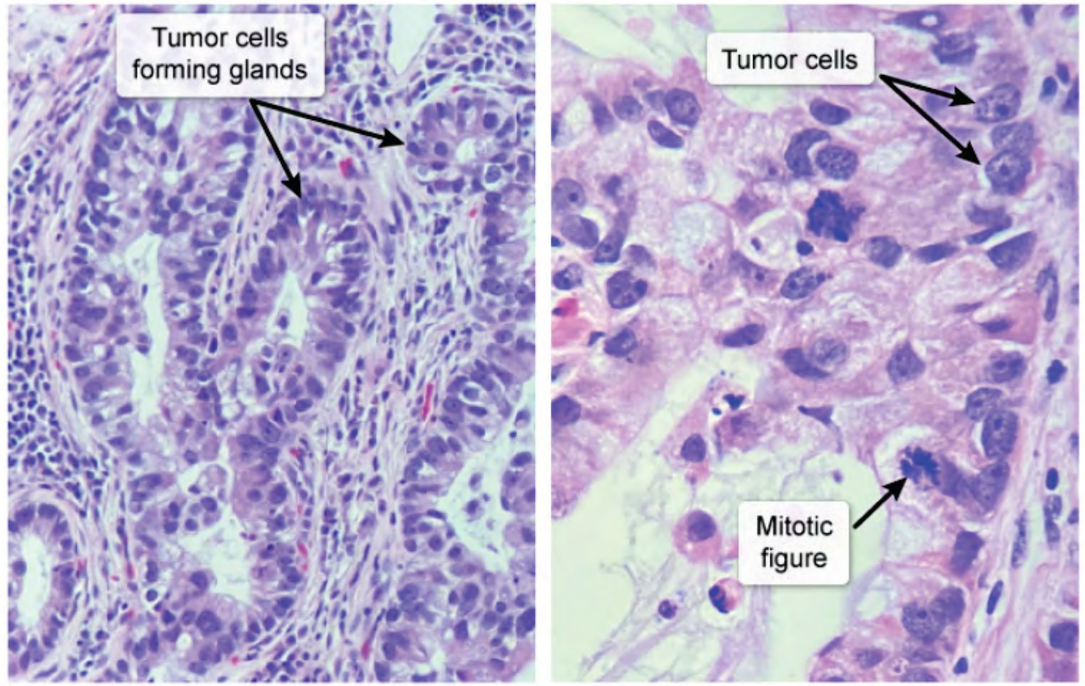

©UWorld

Zoom In | Zoom Out | Reset | New | Existing | My Notebook

https://t.me/USMLEWorldStep1

Exhibit Display

Abdominal mucormycosis

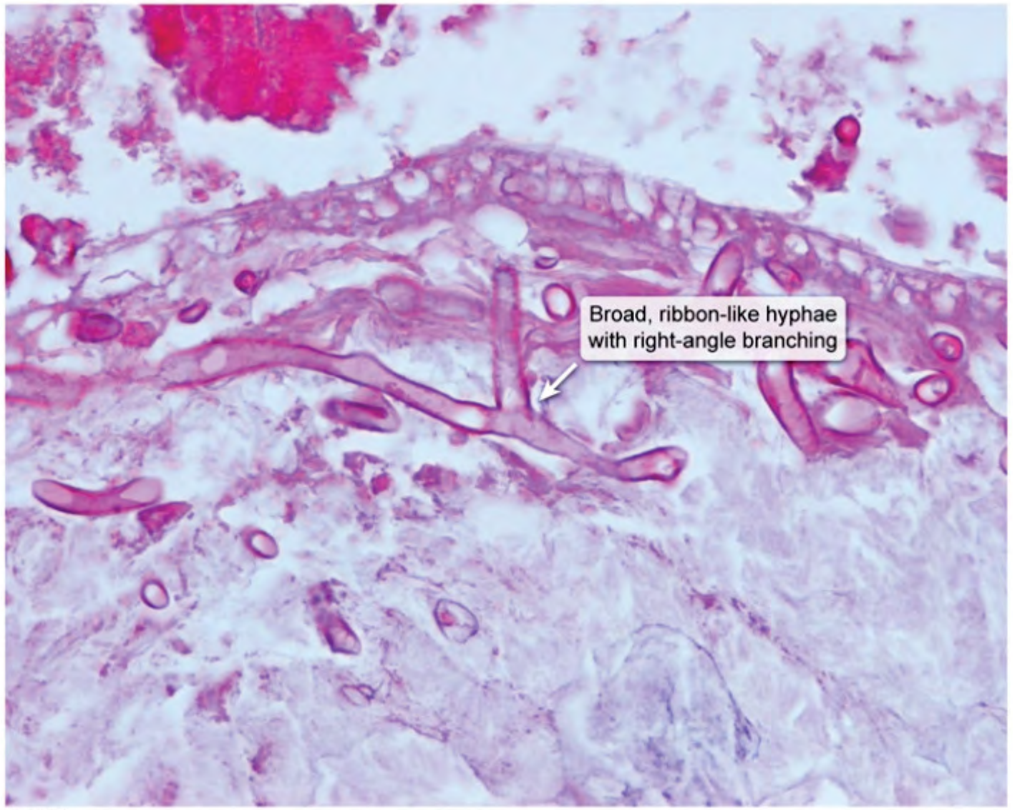

©UWorld

Zoom In | Zoom Out | Reset | New | Existing | My Notebook

Acti
typic
in pa
absc

Pulr
bron
incre
char
yello
micr

(Che
puln
colu
form

(Che
whe
diab
bran

(Che
exar

(Choice E) Tuberculosis is characterized on histopathology by caseating granulomas, with a necrotic center

https://t.me/USMLEWorldStep1

Actinomycosi
typically coloni
in patients with
abscesses, but

Pulmonary ac
bronchograms
increased risk.
characteristic s
yellow; howeve
microscopy. **P**

(Choice B) Lu
pulmonary con
columnar hype
formation, intra

(Choice C) *M*
when the fungu
diabetic ketoac
branching.

(Choice D) Sa
examination of

(Choice E) Tu

Exhibit Display

Sarcoidosis

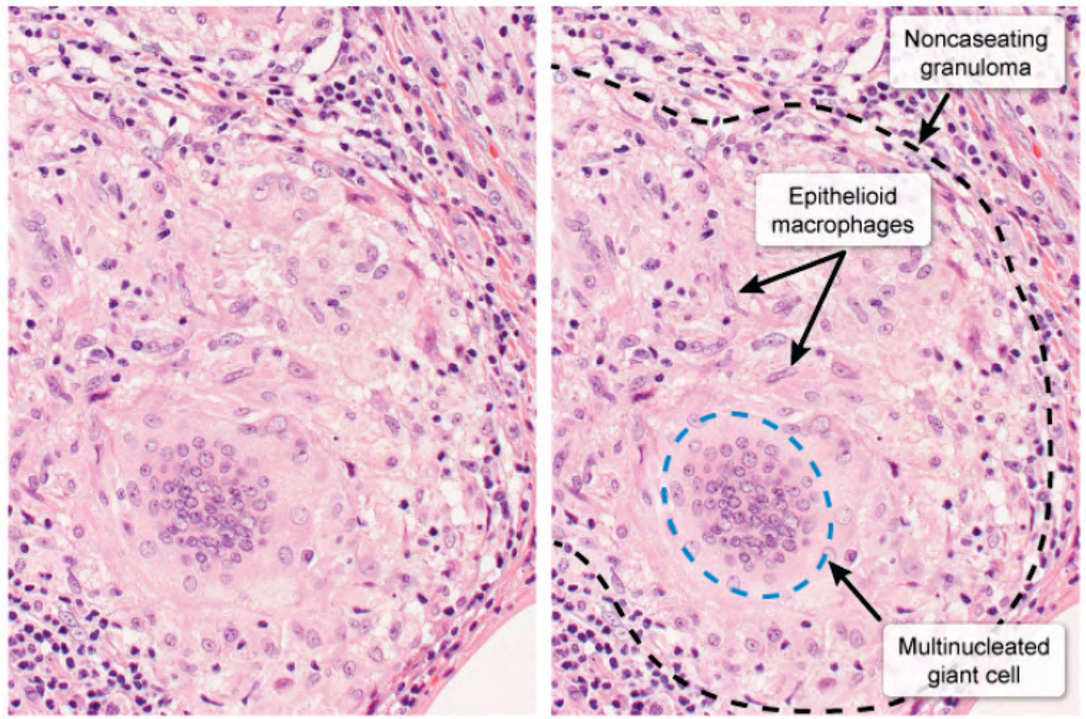

Zoom In | Zoom Out | Reset | New | Existing | My Notebook

https://t.me/USMLEWorldStep1

abscesses, but systemic infection can develop anywhere in the body when the mucosa is disrupted.

Pulm
bron
incre
char
yello
micr

(Che
puln
colu
form

(Che
whe
diab
bran

(Che
exar

(Che
typic

Edu
Puln
mali
gran

References

Exhibit Display

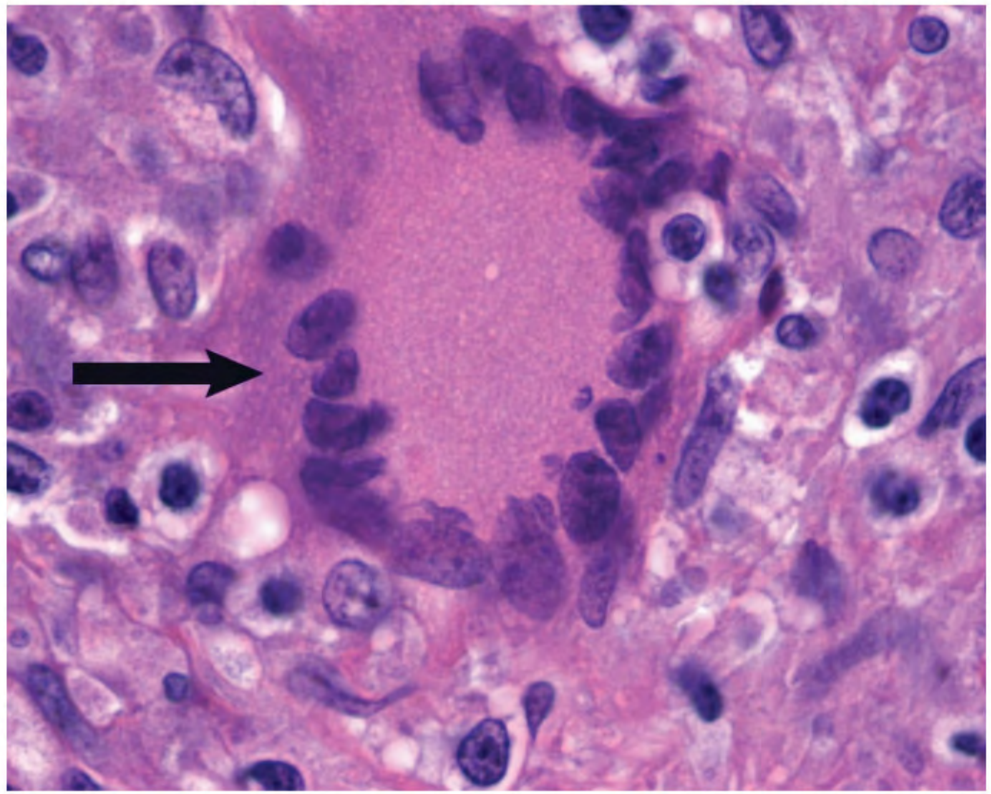

Zoom In | Zoom Out | Reset | New | Existing | My Notebook

https://t.me/USMLEWorldStep1

A 63-year-old man comes to the emergency department due to a 1-week history of progressively worsening shortness of breath and cough. The shortness of breath is exacerbated when the patient lies flat in bed; he has to prop himself up with 3 pillows to sleep well at night. He was treated for a myocardial infarction 2 weeks ago and had 2 stents placed in the left anterior descending artery. The patient's other medical conditions include long-standing hypertension and type 2 diabetes mellitus. Blood pressure is 120/80 mm Hg, pulse is 92/min, and respirations are 22/min. Pulse oximetry is 89% on room air. Physical examination reveals bilateral crackles at the lung bases and an S3. Which of the following is most likely present in this patient?

- A. Decreased alveolar surface tension
- B. Decreased lung compliance
- C. Increased dead space ventilation
- D. Increased functional residual capacity
- E. Left-to-right cardiac shunting

Submit

https://t.me/USMLEWorldStep1

A 63-year-old man comes to the emergency department due to a 1-week history of progressively worsening shortness of breath and cough. The shortness of breath is exacerbated when the patient lies flat in bed; he has to prop himself up with 3 pillows to sleep well at night. He was treated for a myocardial infarction 2 weeks ago and had 2 stents placed in the left anterior descending artery. The patient's other medical conditions include long-standing hypertension and type 2 diabetes mellitus. Blood pressure is 120/80 mm Hg, pulse is 92/min, and respirations are 22/min. Pulse oximetry is 89% on room air. Physical examination reveals bilateral crackles at the lung bases and an S3. Which of the following is most likely present in this patient?

- A. Decreased alveolar surface tension (12%)
- ✓ B. Decreased lung compliance (38%)
- C. Increased dead space ventilation (31%)
- D. Increased functional residual capacity (6%)
- E. Left-to-right cardiac shunting (11%)

Correct | 38% Answered correctly | 04 secs Time Spent | 2023 Version

Explanation

This patient's dyspnea, orthopnea, bibasilar crackles, and S3 suggest **left-sided heart failure** due to recent myocardial infarction (MI). Atherosclerotic plaque rupture in the left anterior descending or left circumflex artery can infarct large areas of the left ventricular myocardium, leading to decreased contractility and reduced cardiac output. This can result in **elevation of end-diastolic pressure** that impairs diastolic return from the pulmonary veins, leading to increased hydrostatic pressure in the pulmonary capillaries with transudation of fluid into the lung

https://t.me/USMLEWorldStep1

Explanation

This patient's dyspnea, orthopnea, bibasilar crackles, and S3 suggest **left-sided heart failure** due to recent myocardial infarction (MI). Atherosclerotic plaque rupture in the left anterior descending or left circumflex artery can infarct large areas of the left ventricular myocardium, leading to decreased contractility and reduced cardiac output. This can result in **elevation of end-diastolic pressure** that impairs diastolic return from the pulmonary veins, leading to increased hydrostatic pressure in the pulmonary capillaries with transudation of fluid into the lung parenchyma **(pulmonary edema)**.

Pulmonary edema in the alveoli impairs ventilation and causes intrapulmonary shunting. In addition, edema in the lung interstitium makes the lungs heavy and stiff, restricting pulmonary expansion during inspiration. This **decreased lung compliance** can mimic that seen with other causes of restrictive lung physiology (eg, interstitial lung disease).

(Choice A) Surfactant decreases the surface tension of the fluid layer that lines alveolar cells, helping prevent alveolar collapse. Pulmonary edema dilutes pulmonary surfactant, increasing both alveolar surface tension and the tendency for alveolar collapse.

(Choice C) Ventilation-perfusion (V/Q) mismatch exists on a spectrum with intrapulmonary shunting (perfusion without ventilation) and dead space ventilation (ventilation without perfusion) on either end. Pulmonary edema causes V/Q mismatch via increased intrapulmonary shunting with a corresponding decrease in dead space ventilation. V/Q mismatch via increased dead space ventilation is seen with pulmonary embolism.

(Choice D) Functional residual capacity is the volume of air in the lungs at the end of normal expiration. It is increased in conditions with increased lung compliance (eg, chronic obstructive pulmonary disease) and decreased in conditions such as pulmonary edema that reduce lung compliance.

(Choice E) Interventricular septal rupture is a mechanical complication of MI that causes left-to-right cardiac

https://t.me/USMLEWorldStep1

output. This can result in **elevation of end-diastolic pressure** that impairs diastolic return from the pulmonary veins, leading to increased hydrostatic pressure in the pulmonary capillaries with transudation of fluid into the lung parenchyma **(pulmonary edema)**.

Pulmonary edema in the alveoli impairs ventilation and causes intrapulmonary shunting. In addition, edema in the lung interstitium makes the lungs heavy and stiff, restricting pulmonary expansion during inspiration. This **decreased lung compliance** can mimic that seen with other causes of restrictive lung physiology (eg, interstitial lung disease).

(Choice A) Surfactant decreases the surface tension of the fluid layer that lines alveolar cells, helping prevent alveolar collapse. Pulmonary edema dilutes pulmonary surfactant, increasing both alveolar surface tension and the tendency for alveolar collapse.

(Choice C) Ventilation-perfusion (V/Q) mismatch exists on a spectrum with intrapulmonary shunting (perfusion without ventilation) and dead space ventilation (ventilation without perfusion) on either end. Pulmonary edema causes V/Q mismatch via increased intrapulmonary shunting with a corresponding decrease in dead space ventilation. V/Q mismatch via increased dead space ventilation is seen with pulmonary embolism.

(Choice D) Functional residual capacity is the volume of air in the lungs at the end of normal expiration. It is increased in conditions with increased lung compliance (eg, chronic obstructive pulmonary disease) and decreased in conditions such as pulmonary edema that reduce lung compliance.

(Choice E) Interventricular septal rupture is a mechanical complication of MI that causes left-to-right cardiac shunting. However, this complication usually occurs within 3-5 days following MI and precipitates a dramatic and acute, rather than gradual, presentation of heart failure.

Educational objective:
Left-sided heart failure is common following myocardial infarction affecting the left ventricle. The resulting accumulation of edema in the pulmonary interstitium makes the lungs heavy and stiff, restricting inspiratory expansion and decreasing lung compliance.

https://t.me/USMLEWorldStep1

A 55-year-old man comes to the emergency department due to sudden-onset dyspnea. Medical history is significant for hypertension, hyperlipidemia, type 2 diabetes mellitus, and chronic kidney disease. The patient takes multiple medications and has no drug allergies. He works for an international bank and returned from a business trip in Australia a day ago. Blood pressure is 110/70 mm Hg and pulse is 110/min. Physical examination shows a moderately overweight man with tachypnea. The lungs are clear on auscultation. ECG shows sinus tachycardia. Ventilation/perfusion scanning is ordered. Which of the following findings would help confirm the suspected diagnosis in this patient?

- A. Absence of ventilation and perfusion abnormalities
- B. An area showing both ventilation and perfusion defects
- C. A perfusion defect without an associated ventilation defect
- D. A ventilation defect without an associated perfusion defect
- E. Several small areas of matched perfusion and ventilation defects

Submit

https://t.me/USMLEWorldStep1

A 55-year-old man comes to the emergency department due to sudden-onset dyspnea. Medical history is significant for hypertension, hyperlipidemia, type 2 diabetes mellitus, and chronic kidney disease. The patient takes multiple medications and has no drug allergies. He works for an international bank and returned from a business trip in Australia a day ago. Blood pressure is 110/70 mm Hg and pulse is 110/min. Physical examination shows a moderately overweight man with tachypnea. The lungs are clear on auscultation. ECG shows sinus tachycardia. Ventilation/perfusion scanning is ordered. Which of the following findings would help confirm the suspected diagnosis in this patient?

- A. Absence of ventilation and perfusion abnormalities (1%)
- ✗ B. An area showing both ventilation and perfusion defects (5%)
- ✓ C. A perfusion defect without an associated ventilation defect (86%)
- D. A ventilation defect without an associated perfusion defect (4%)
- E. Several small areas of matched perfusion and ventilation defects (1%)

Incorrect
Correct answer
C

86%
Answered correctly

04 secs
Time Spent

2023
Version

Explanation

Perfusion defect without ventilation defect

$PO_2 = 150$

https://t.me/USMLEWorldStep1

Explanation

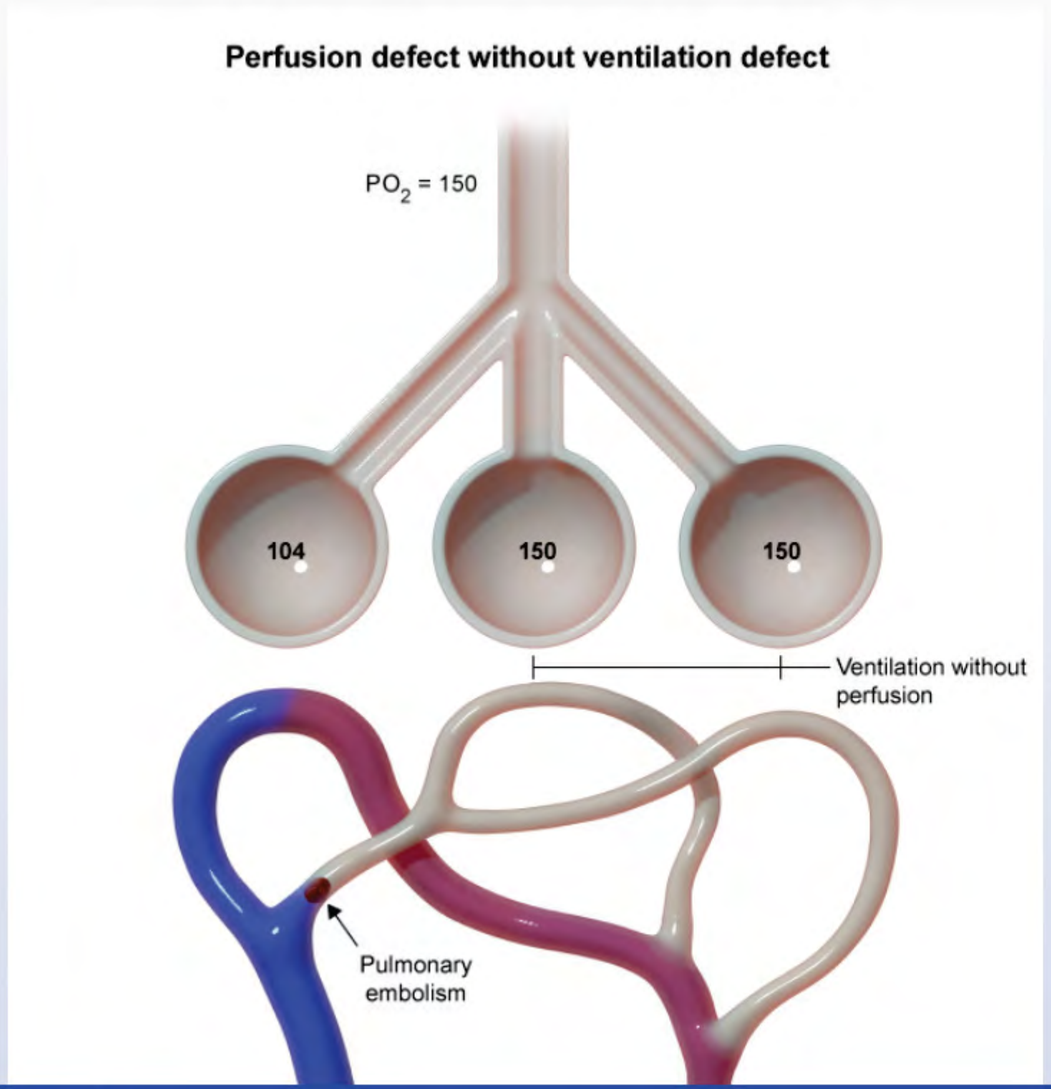

https://t.me/USMLEWorldStep1

Exhibit Display

Perfusion defect without ventilation defect

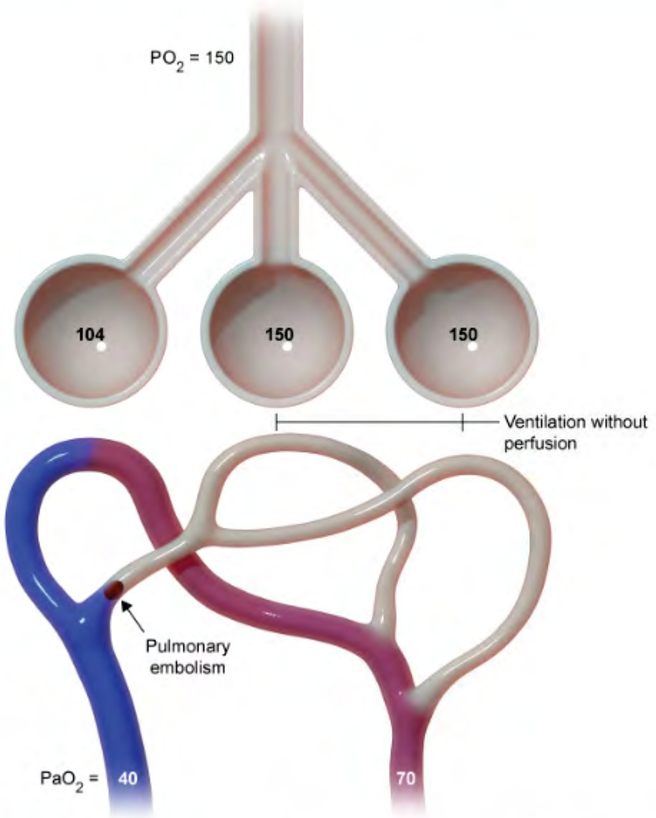

Zoom In | Zoom Out | Reset | New | Existing | My Notebook

https://t.me/USMLEWorldStep1

©UWorld

Pulmonary embolism (PE) should be suspected in this patient with recent extended travel (prolonged immobilization) who now has acute-onset dyspnea and tachypnea, normal lung examination, and sinus tachycardia on ECG. In most patients, **CT angiography**, which requires intravenous contrast administration, is the diagnostic test of choice. However, the contrast used in CT studies should be avoided in patients with chronic kidney disease due to the increased risk of contrast-induced nephropathy; in such patients, a **ventilation/perfusion (V/Q) scan** is the preferred diagnostic study.

A V/Q scan is a nuclear medicine study that uses a radioactive tracer placed in both inhaled gas and the bloodstream to visualize areas of ventilation and perfusion in the lung. In patients with PE, ventilation is preserved but the embolus prevents adequate blood perfusion to the affected areas of the lung. Therefore, the most definitive diagnostic finding for PE on V/Q scan is a large area showing a **perfusion defect without ventilation defect** (mismatched perfusion defect).

(Choice A) The absence of perfusion abnormalities is a useful finding on V/Q scan, as it likely rules out significant PE.

(Choices B and E) Matched ventilation and perfusion defects may result from chronic lung abnormalities (eg, airway inflammation or obstruction, atelectasis) that lead to localized areas of poor ventilation with corresponding hypoxic vasoconstriction, or they may represent a PE that happens to be in an area of poor ventilation. These results are often inconclusive and necessitate additional testing to confirm or rule out PE.

(Choice D) An area of ventilation defect without perfusion defect is suggestive of conditions that lead to acute alveolar filling (eg, pneumonia, pulmonary edema).

Educational objective:
Ventilation/perfusion scanning can be useful for diagnosing pulmonary embolism. A large perfusion defect without ventilation defect is the characteristic positive test result.

https://t.me/USMLEWorldStep1

©UWorld

Exhibit Display

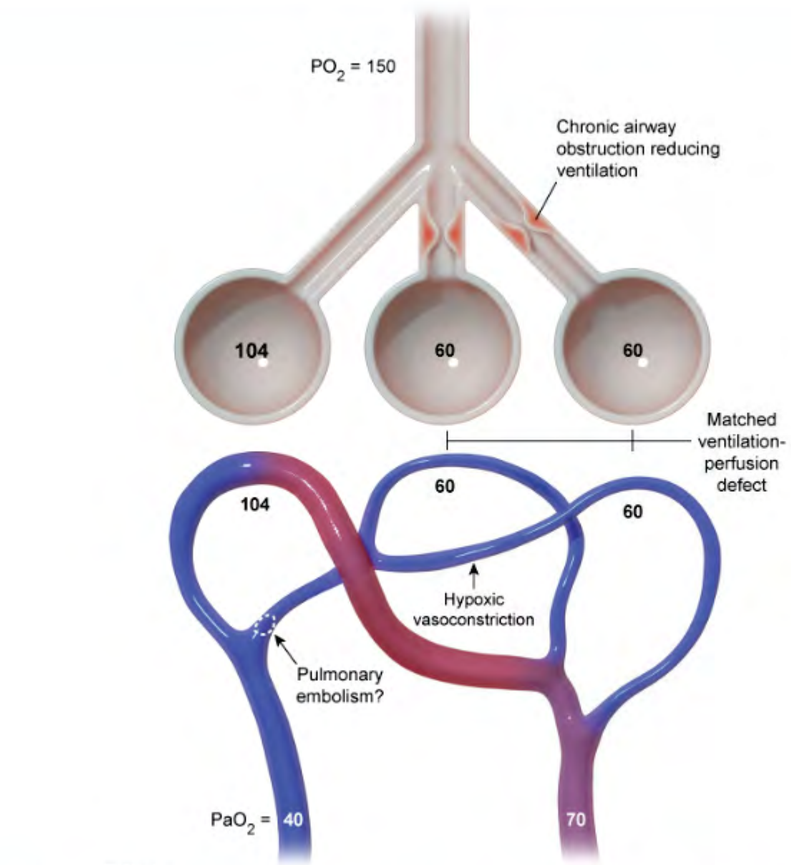

©UWorld

Zoom In | Zoom Out | Reset | New | Existing | My Notebook

Pulr
imm
on E
test
due
the
A V/
bloo
but t
diag
(mis
(Ch
PE.
(Ch
airw
hypo
resu
(Ch
alve
Edu
Vent
ventilation defect is the characteristic positive test result.

https://t.me/USMLEWorldStep1

©UWorld

Exhibit Display

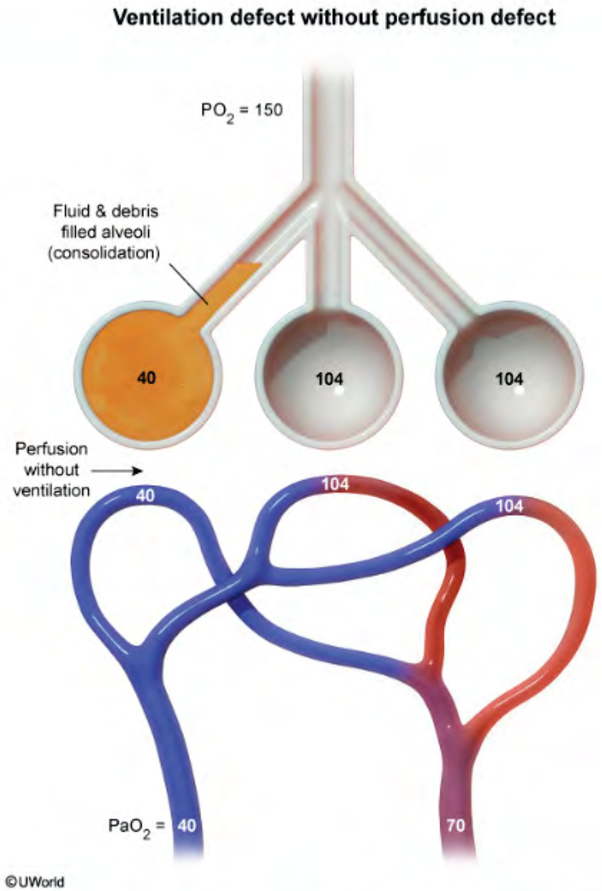

Zoom In | Zoom Out | Reset | New | Existing | My Notebook

Pulr
imm
on E
test
due
the p

A V/
bloo
but t
diag
(mis

(Cho
PE.

(Cho
airw
hypo
resu

(Cho
alve

Edu
Vent
ventilation defect is the characteristic positive test result.

https://t.me/USMLEWorldStep1

A 62-year-old man comes to the office due to shortness of breath. His symptoms have progressed over the last few months and have begun to limit his daily activities. He has no other medical problems and takes no medications. The patient drinks 3 or 4 alcoholic beverages a week and has a 50-pack-year smoking history. Physical examination reveals decreased breath sounds and scattered wheezes bilaterally. Chest x-ray is shown below.

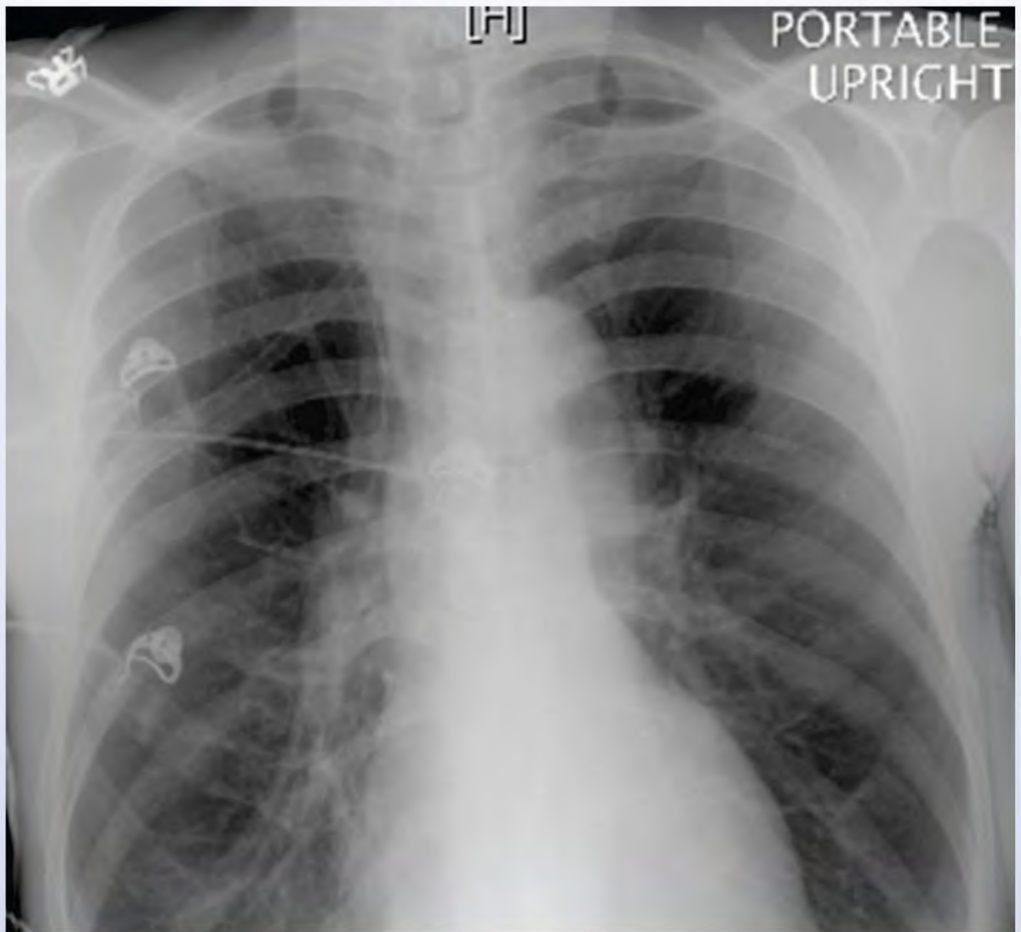

https://t.me/USMLEWorldStep1

A 62
few
med
Phys
belo

Exhibit Display

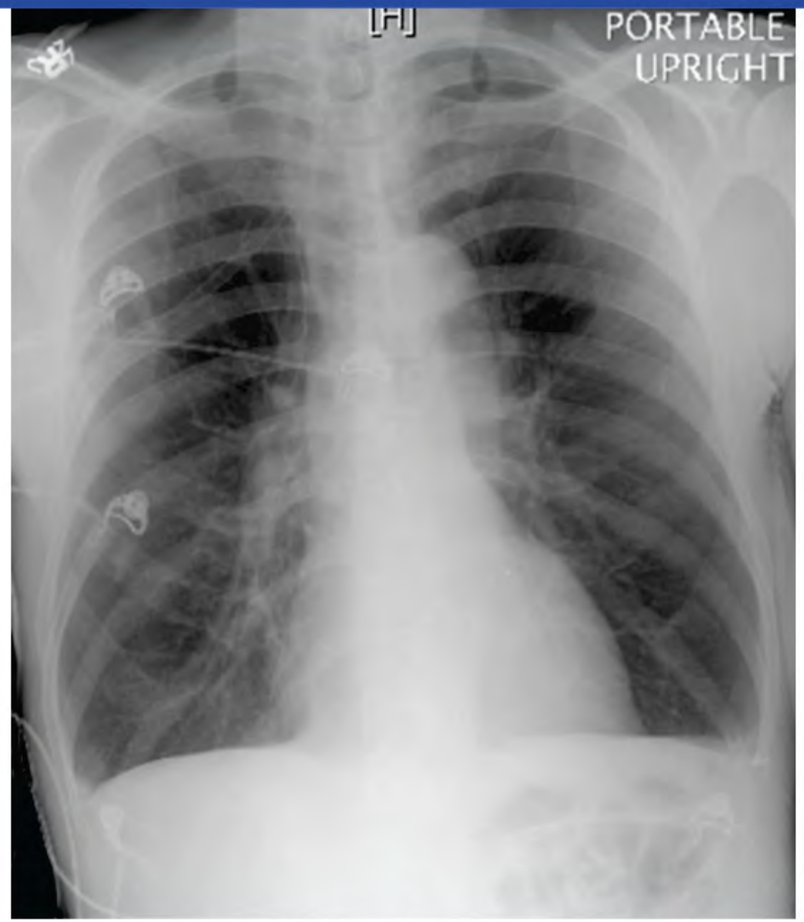

Zoom In | Zoom Out | Reset | New | Existing | My Notebook

https://t.me/USMLEWorldStep1

Which of the following parameters is most likely to be increased in this patient?

- A. Carbon monoxide diffusion capacity
- B. Expiratory flow rates
- C. Forced vital capacity
- D. Functional residual capacity
- E. Lung elastic recoil

Submit

https://t.me/USMLEWorldStep1

Which of the following parameters is most likely to be increased in this patient?

- A. Carbon monoxide diffusion capacity (4%)
- ✕ B. Expiratory flow rates (4%)
- C. Forced vital capacity (5%)
- ✓ D. Functional residual capacity (78%)
- E. Lung elastic recoil (6%)

Incorrect
Correct answer
D

78%
Answered correctly

16 secs
Time Spent

2023
Version

https://t.me/USMLEWorldStep1

Incorrect
Correct answer
D

78%
Answered correctly

16 secs
Time Spent

2023
Version

Exhibit Display

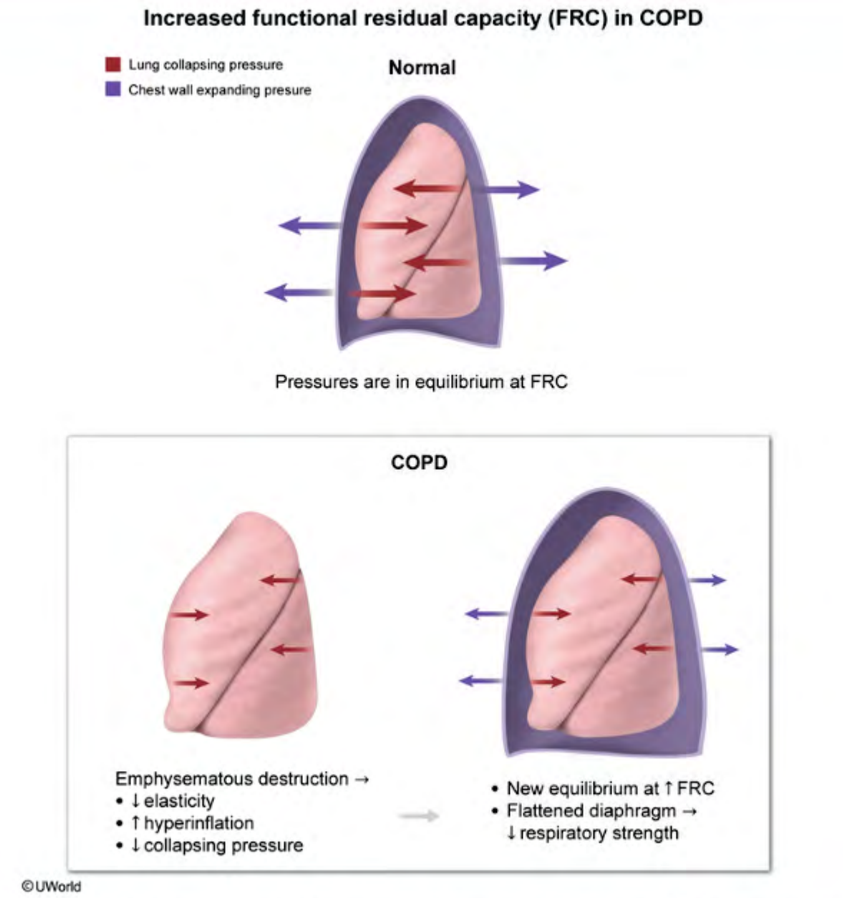

Zoom In
Zoom Out
Reset
New
Existing
My Notebook

https://t.me/USMLEWorldStep1

This patient's chest x-ray reveals **hyperinflated lungs** and a **flattened diaphragm** (compared to normal), consistent with **chronic obstructive pulmonary disease** (COPD). COPD involves components of chronic bronchitis and emphysema, both of which contribute to air-trapping and hyperinflation.

The outward expanding pressure created by the chest wall and the inward collapsing pressure created by the lungs are in equilibrium at the **functional residual capacity** (FRC). In patients with COPD, **decreased elasticity** of the alveoli (from emphysema) results in decreased collapsing pressure created by the lungs to expel air. Bronchial airway thickening and obstruction (from chronic bronchitis) further impairs lung collapse by impeding the expulsion of air. The decrease in collapsing pressure causes the chest wall to **expand outward** until the expanding pressure of the chest is balanced by the collapsing pressure of the lungs. A new pressure equilibrium is reached at a higher lung volume (ie, **higher FRC**) and, as a result, residual volume and total lung capacity are also increased.

(Choice A) The diffusing capacity of the lung for carbon monoxide (DLCO) largely depends on the thickness and total surface area of the alveolar capillary membrane. In emphysema, interalveolar wall destruction decreases the alveolar-capillary surface area, reducing DLCO. Patients with emphysema may have decreased DLCO even when there is little evidence of expiratory airflow obstruction on spirometry.

(Choice B) Expiratory airflow rates are reduced in COPD due to inflammatory and fibrotic narrowing of the bronchi (chronic bronchitis) and decreased alveolar elastic recoil (emphysema).

(Choice C) In COPD, forced vital capacity is usually decreased due to expiratory airflow obstruction limiting the total expiratory volume.

(Choice E) Emphysema causes lung elastic recoil to decrease secondary to destruction of interalveolar walls.

Educational objective:
Chronic obstructive pulmonary disease involves components of chronic bronchitis and emphysema. Bronchial airway obstruction from chronic bronchitis and decreased alveolar elasticity from emphysema result in air-trapping

https://t.me/USMLEWorldStep1

bronchitis and emphysema, both of which contribute to air-trapping and hyperinflation.

The outward expanding pressure created by the chest wall and the inward collapsing pressure created by the lungs are in equilibrium at the **functional residual capacity** (FRC). In patients with COPD, **decreased elasticity** of the alveoli (from emphysema) results in decreased collapsing pressure created by the lungs to expel air. Bronchial airway thickening and obstruction (from chronic bronchitis) further impairs lung collapse by impeding the expulsion of air. The decrease in collapsing pressure causes the chest wall to **expand outward** until the expanding pressure of the chest is balanced by the collapsing pressure of the lungs. A new pressure equilibrium is reached at a higher lung volume (ie, **higher FRC**) and, as a result, residual volume and total lung capacity are also increased.

(Choice A) The diffusing capacity of the lung for carbon monoxide (DLCO) largely depends on the thickness and total surface area of the alveolar capillary membrane. In emphysema, interalveolar wall destruction decreases the alveolar-capillary surface area, reducing DLCO. Patients with emphysema may have decreased DLCO even when there is little evidence of expiratory airflow obstruction on spirometry.

(Choice B) Expiratory airflow rates are reduced in COPD due to inflammatory and fibrotic narrowing of the bronchi (chronic bronchitis) and decreased alveolar elastic recoil (emphysema).

(Choice C) In COPD, forced vital capacity is usually decreased due to expiratory airflow obstruction limiting the total expiratory volume.

(Choice E) Emphysema causes lung elastic recoil to decrease secondary to destruction of interalveolar walls.

Educational objective:
Chronic obstructive pulmonary disease involves components of chronic bronchitis and emphysema. Bronchial airway obstruction from chronic bronchitis and decreased alveolar elasticity from emphysema result in air-trapping and lung hyperinflation. The functional residual capacity is increased, as are residual volume and total lung capacity.

References

https://t.me/USMLEWorldStep1

Exhibit Display

Zoom In | Zoom Out | Reset | New | Existing | My Notebook

This
cons
bron

The
lung
of th
Bron
expu
expa
reac
incre

(Ch
total
alve
ther

(Ch
(chr

(Choice C) In COPD, forced vital capacity is usually decreased due to expiratory airflow obstruction limiting the

https://t.me/USMLEWorldStep1

Exhibit Display

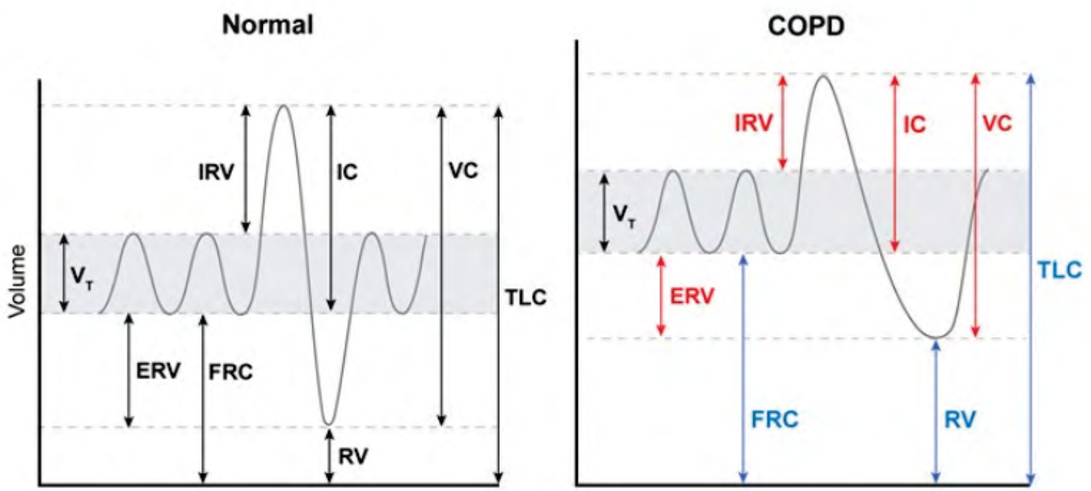

COPD = chronic obstructive pulmonary disease; **ERV** = expiratory reserve volume; **FRC** = functional residual capacity; **IC** = inspiratory capacity; **IRV** = inspiratory reserve volume; **RV** = residual volume; **TLC** = total lung capacity; **VC** = vital capacity; V_T = tidal volume.
©UWorld

Zoom In | Zoom Out | Reset | New | Existing | My Notebook

This patient's c
consistent with
bronchitis and

The outward e
lungs are in eq
of the alveoli (f
Bronchial airwa
expulsion of ai
expanding pres
reached at a hi
increased.

(Choice A) Th
total surface ar
alveolar-capilla
there is little ev

(Choice B) Ex
(chronic bronch

(Choice C) In COPD, forced vital capacity is usually decreased due to expiratory airflow obstruction limiting the

https://t.me/USMLEWorldStep1

A 35-year-old man who received a kidney transplant one year ago comes to the emergency department with pleuritic chest pain and cough. He is found to have a low-grade fever. Chest x-ray reveals an infiltrate in the lower lobe of the right lung. The patient is started on broad-spectrum antibiotics, including vancomycin, ceftriaxone, and azithromycin. Despite these measures, his condition worsens over the next several days. Bronchoscopy with bronchoalveolar lavage is performed. Mucicarmine staining of his bronchoalveolar fluid reveals the following on light microscopy:

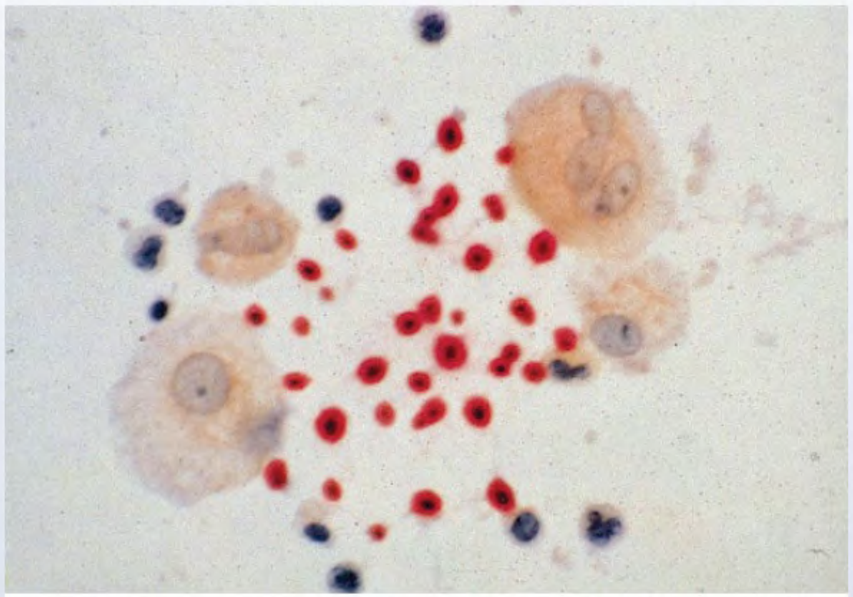

Displayed with permission from Springer Healthcare Ltd. © Copyright 1996, 2004 by Current Medicine

Which of the following is the most likely cause of this patient's condition?

- A. *Aspergillus fumigatus*
- B. *Blastomyces dermatitidis*
- C. *Candida albicans*

https://t.me/USMLEWorldStep1

A 35 [illegible]
pleu
lobe
azith
bron
light

Exhibit Display

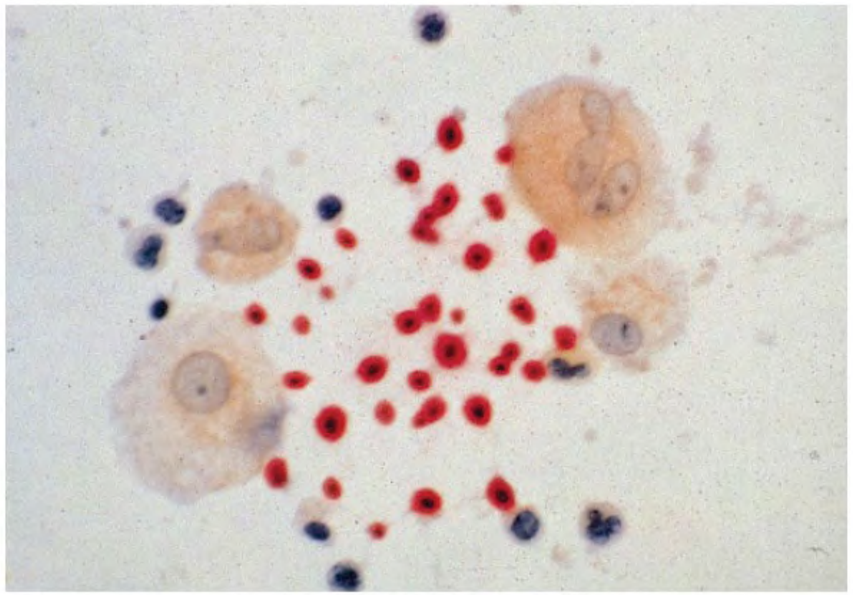

Displayed with permission from Springer Healthcare Ltd. © Copyright 1996, 2004 by Current Medicine

Zoom In | Zoom Out | Reset | New | Existing | My Notebook

Whi

C. *Candida albicans*

https://t.me/USMLEWorldStep1

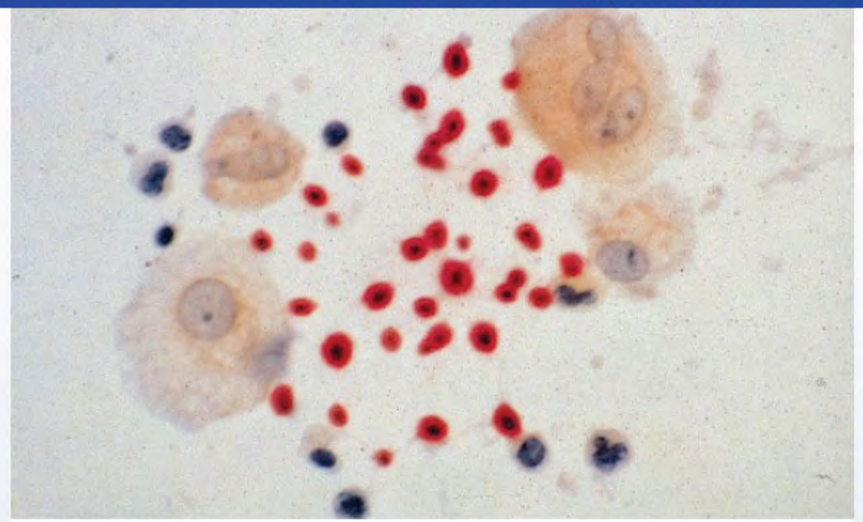

Displayed with permission from Springer Healthcare Ltd. © Copyright 1996, 2004 by Current Medicine

Which of the following is the most likely cause of this patient's condition?

- A. *Aspergillus fumigatus*
- B. *Blastomyces dermatitidis*
- C. *Candida albicans*
- D. *Coccidioides immitis*
- E. *Cryptococcus neoformans*
- F. *Histoplasma capsulatum*
- G. *Rhizopus* species

Submit

https://t.me/USMLEWorldStep1

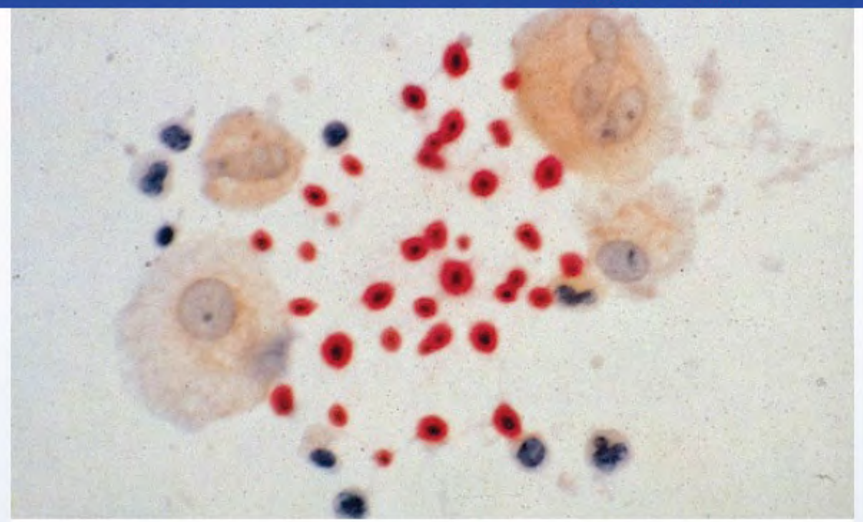

Displayed with permission from Springer Healthcare Ltd. © Copyright 1996, 2004 by Current Medicine

Which of the following is the most likely cause of this patient's condition?

- A. *Aspergillus fumigatus* (4%)
- ✗ B. *Blastomyces dermatitidis* (9%)
- C. *Candida albicans* (0%)
- D. *Coccidioides immitis* (6%)
- ✓ E. *Cryptococcus neoformans* (69%)
- F. *Histoplasma capsulatum* (6%)
- G. *Rhizopus* species (2%)

Incorrect
Correct answer
E

69%
Answered correctly

13 secs
Time Spent

2023
Version

https://t.me/USMLEWorldStep1

Cryptococcus neoformans is a yeast that has an antiphagocytic polysaccharide capsule, a major virulence factor. The polysaccharide **capsule** appears as a clear, unstained zone with India ink and stains **red** with mucicarmine (as seen in this patient). Methenamine silver stain can identify the yeast forms, seen in tissue as round cells with narrow-based buds.

C neoformans usually affects **immunocompromised** patients (eg, kidney transplantation patients on chronic immunosuppression). It is a neurotropic fungus that is transmitted via the respiratory route and most commonly presents with subacute or chronic **meningoencephalitis**. Cryptococcal **lung disease** can occasionally cause pneumonia-like symptoms, including cough with scant sputum production, pleuritic chest pain, dyspnea, and hemoptysis. Chest x-ray findings are nonspecific (eg, infiltrates, nodules). Diagnosis is usually confirmed by identifying *Cryptococcus* in sputum, bronchoalveolar washings, or tissue samples.

(Choice A) *Aspergillus fumigatus* can cause pulmonary disease and invasive aspergillosis, most commonly in immunocompromised patients. However, microscopy typically shows septate hyphae.

(Choice B) *Blastomyces dermatitidis* can cause both lung disease and disseminated mycosis. Its microscopic appearance in tissue is that of a round yeast with **broad-based budding** and a thick, doubly reflective wall.

(Choice C) *Candida albicans* most commonly causes oropharyngeal, mucocutaneous, and esophageal disease. It rarely causes pneumonia. Microscopy typically shows budding yeast with pseudo-hyphae.

(Choice D) *Coccidioides immitis* causes lung disease in immunocompetent individuals and disseminated mycosis in immunocompromised patients. In tissue samples, it appears as large, irregularly sized, thick-walled spherules that contain small, round endospores.

(Choice F) *Histoplasma capsulatum* is a dimorphic fungus that causes tuberculosis-like pulmonary disease. It can also cause disseminated mycosis in immunocompromised patients. It is found intracellularly in tissue (within macrophages), appearing as small, ovoid, and budding yeast cells.

(Choice G) *Rhizopus* species typically causes rhino-orbito-cerebral infection but can cause pulmonary disease,

https://t.me/USMLEWorldStep1

immunosuppression). It is a neurotropic fungus that is transmitted via the respiratory route and most commonly presents with subacute or chronic **meningoencephalitis**. Cryptococcal **lung disease** can occasionally cause pneumonia-like symptoms, including cough with scant sputum production, pleuritic chest pain, dyspnea, and hemoptysis. Chest x-ray findings are nonspecific (eg, infiltrates, nodules). Diagnosis is usually confirmed by identifying *Cryptococcus* in sputum, bronchoalveolar washings, or tissue samples.

(Choice A) *Aspergillus fumigatus* can cause pulmonary disease and invasive aspergillosis, most commonly in immunocompromised patients. However, microscopy typically shows septate hyphae.

(Choice B) *Blastomyces dermatitidis* can cause both lung disease and disseminated mycosis. Its microscopic appearance in tissue is that of a round yeast with **broad-based budding** and a thick, doubly reflective wall.

(Choice C) *Candida albicans* most commonly causes oropharyngeal, mucocutaneous, and esophageal disease. It rarely causes pneumonia. Microscopy typically shows budding yeast with pseudo-hyphae.

(Choice D) *Coccidioides immitis* causes lung disease in immunocompetent individuals and disseminated mycosis in immunocompromised patients. In tissue samples, it appears as large, irregularly sized, thick-walled spherules that contain small, round endospores.

(Choice F) *Histoplasma capsulatum* is a dimorphic fungus that causes tuberculosis-like pulmonary disease. It can also cause disseminated mycosis in immunocompromised patients. It is found intracellularly in tissue (within macrophages), appearing as small, ovoid, and budding yeast cells.

(Choice G) *Rhizopus* species typically causes rhino-orbito-cerebral infection but can cause pulmonary disease, predominantly in immunocompromised patients. Histology typically shows broad hyphae with irregular branching and rare septations.

Educational objective:
Cryptococcus neoformans is the only pathogenic fungus that has a polysaccharide capsule. The capsule appears red on mucicarmine stain and as a clear unstained zone with India ink.

https://t.me/USMLEWorldStep1

Exhibit Display

Cryptococcus

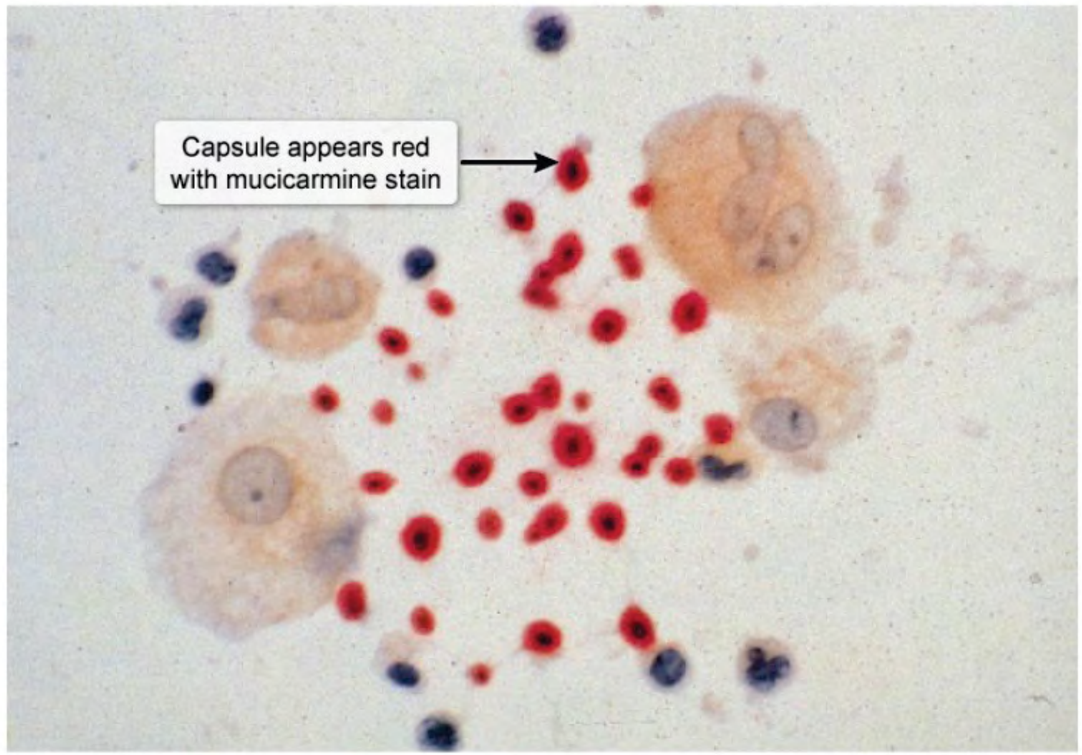

Displayed with permission from Springer Healthcare Ltd. © Copyright 1996, 2004 by Current Medicine

Zoom In | Zoom Out | Reset | New | Existing | My Notebook

(Choice F) *Histoplasma capsulatum* is a dimorphic fungus that causes tuberculosis-like pulmonary disease. It can

https://t.me/USMLEWorldStep1

Exhibit Display

Aspergillus

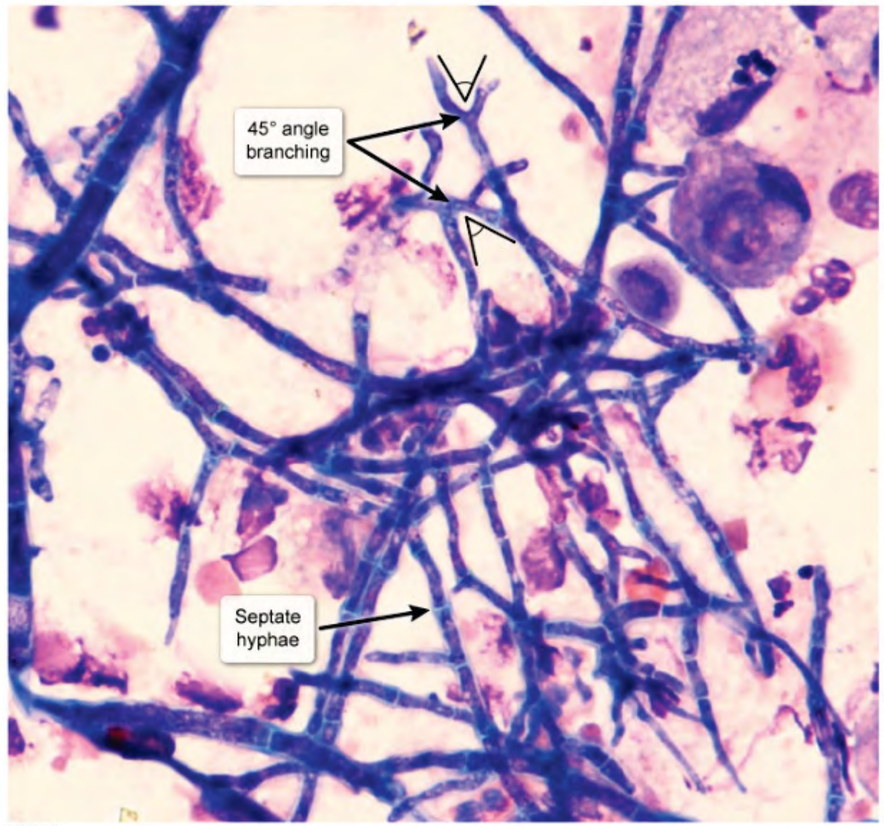

Zoom In | Zoom Out | Reset | New | Existing | My Notebook

(Choice F) *Histoplasma capsulatum* is a dimorphic fungus that causes tuberculosis-like pulmonary disease. It can

https://t.me/USMLEWorldStep1

Explanation

Cryptococcus
factor. The pol
mucicarmine (a
round cells witl

C neoformans
immunosuppre
presents with s
pneumonia-like
hemoptysis. C
identifying *Cryp*

(Choice A) *As*
immunocompr

(Choice B) *Bl*
appearance in

(Choice C) *Ca*
It rarely causes

(Choice D) *Co*
in immunocom
that contain sm

(Choice F) *Hi*

Exhibit Display

Blastomyces dermatitidis

©UWorld

Zoom In | Zoom Out | Reset | New | Existing | My Notebook

https://t.me/USMLEWorldStep1

Explanation

Cryptococcus
factor. The pol
mucicarmine (a
round cells witl

C neoformans
immunosuppre
presents with s
pneumonia-like
hemoptysis. C
identifying *Cryp*

(Choice A) *As*
immunocompr

(Choice B) *Bl*
appearance in

(Choice C) *Ca*
It rarely causes

(Choice D) *Co*
in immunocom
that contain sm

(Choice F) *Hi*

Exhibit Display

Candida albicans

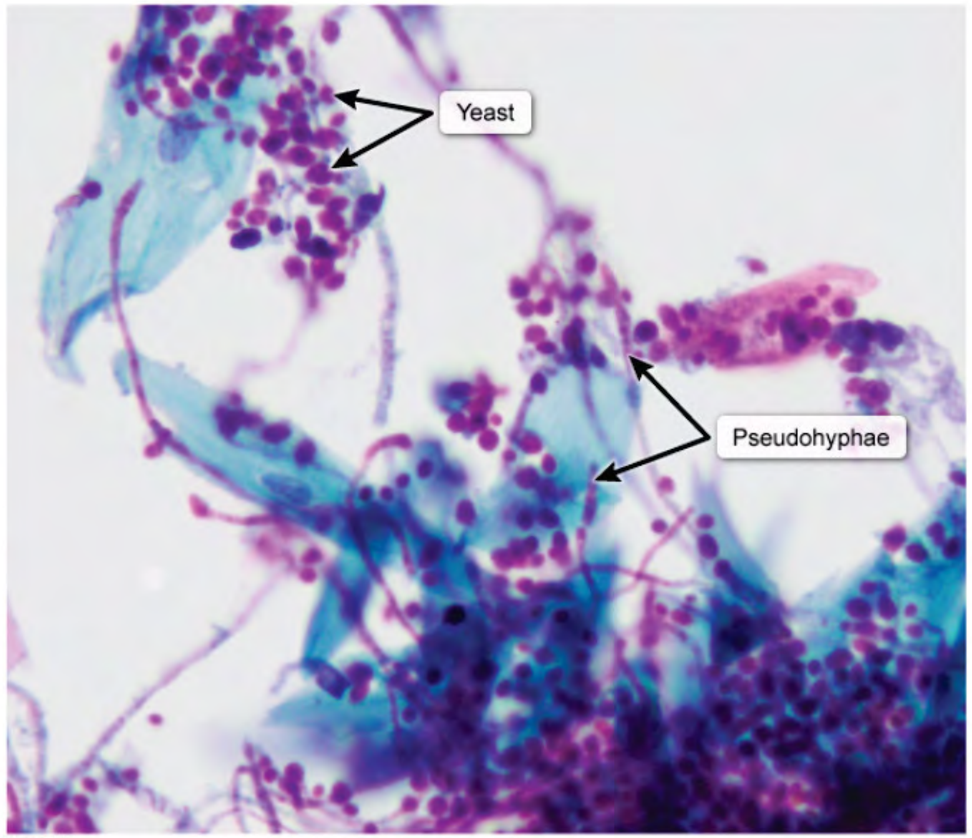

©UWorld

Zoom In | Zoom Out | Reset | New | Existing | My Notebook

https://t.me/USMLEWorldStep1

Cryptococcus neoformans is a yeast that has an antiphagocytic polysaccharide capsule, a major virulence factor. The po
mucicarmine (a
round cells witl

C neoformans
immunosuppre
presents with s
pneumonia-like
hemoptysis. C
identifying *Cryp*

(Choice A) *As*
immunocompr

(Choice B) *Bl*
appearance in

(Choice C) *Ca*
It rarely causes

(Choice D) *Co*
in immunocom
that contain sm

(Choice F) *Hi*
also cause diss
macrophages)

(Choice G) *Rhizopus* species typically causes rhino-orbito-cerebral infection but can cause pulmonary disease;

Exhibit Display

Coccidioidomycosis

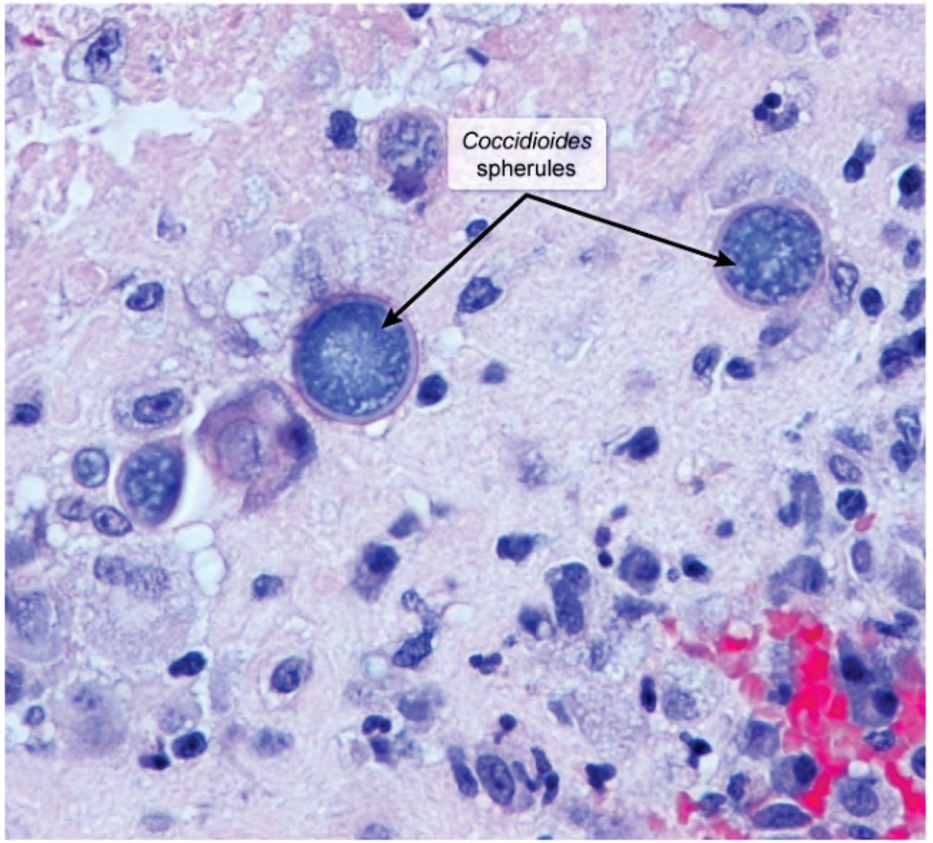

©UWorld

Zoom In | Zoom Out | Reset | New | Existing | My Notebook

https://t.me/USMLEWorldStep1

Cryptococcus neoformans is a yeast that has an antiphagocytic polysaccharide capsule, a major virulence
facto
muc
roun

C ne
imm
pres
pneu
hem
iden

(Cho
imm

(Cho
appe

(Cho
It ra

(Cho
in im
that

(Cho
also
mac

Exhibit Display

Histoplasma

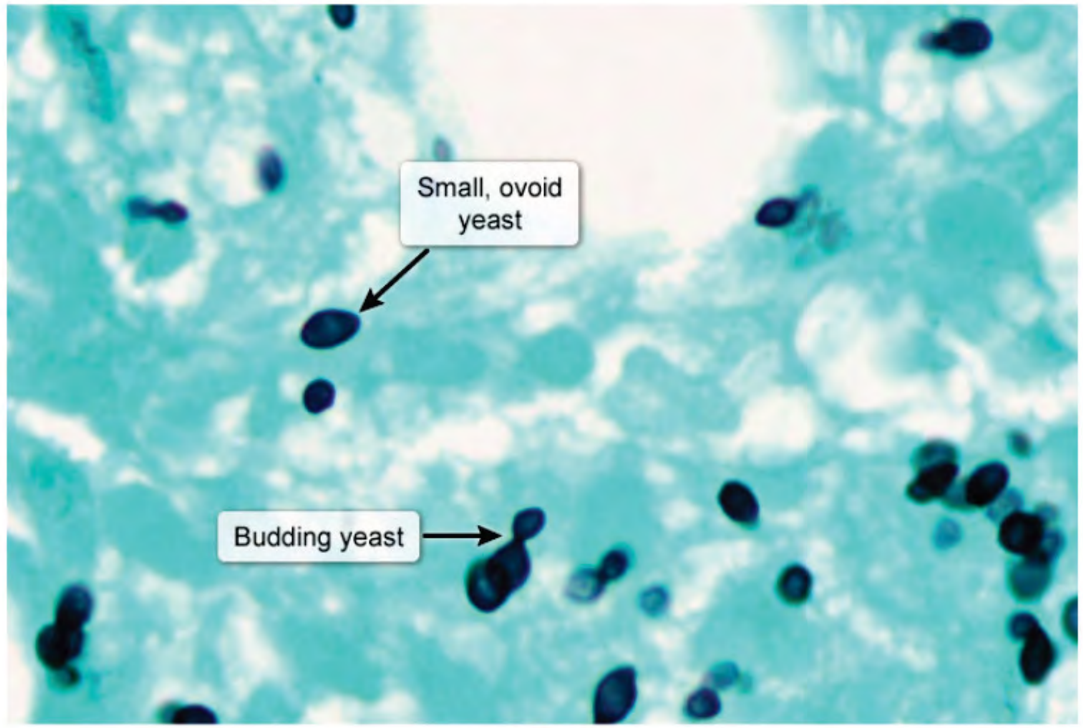

©UWorld

Methenamine silver stain

Zoom In | Zoom Out | Reset | New | Existing | My Notebook

(Choice G) *Rhizopus* species typically causes rhino-orbito-cerebral infection but can cause pulmonary disease,

https://t.me/USMLEWorldStep1

mucicarmine (as seen in this patient). Methenamine silver stain can identify the yeast forms, seen in tissue as round cells with narrow-based buds.

C neoformans immunosuppre presents with s pneumonia-like hemoptysis. C identifying *Cryp*

(Choice A) *As* immunocompr

(Choice B) *Bl* appearance in

(Choice C) *Ca* It rarely causes

(Choice D) *Co* in immunocom that contain sm

(Choice F) *Hi* also cause diss macrophages)

(Choice G) *Ri* predominantly and rare septa

Educational o

Exhibit Display

Invasive fungal sinusitis due to mucormycosis (zygomycosis)

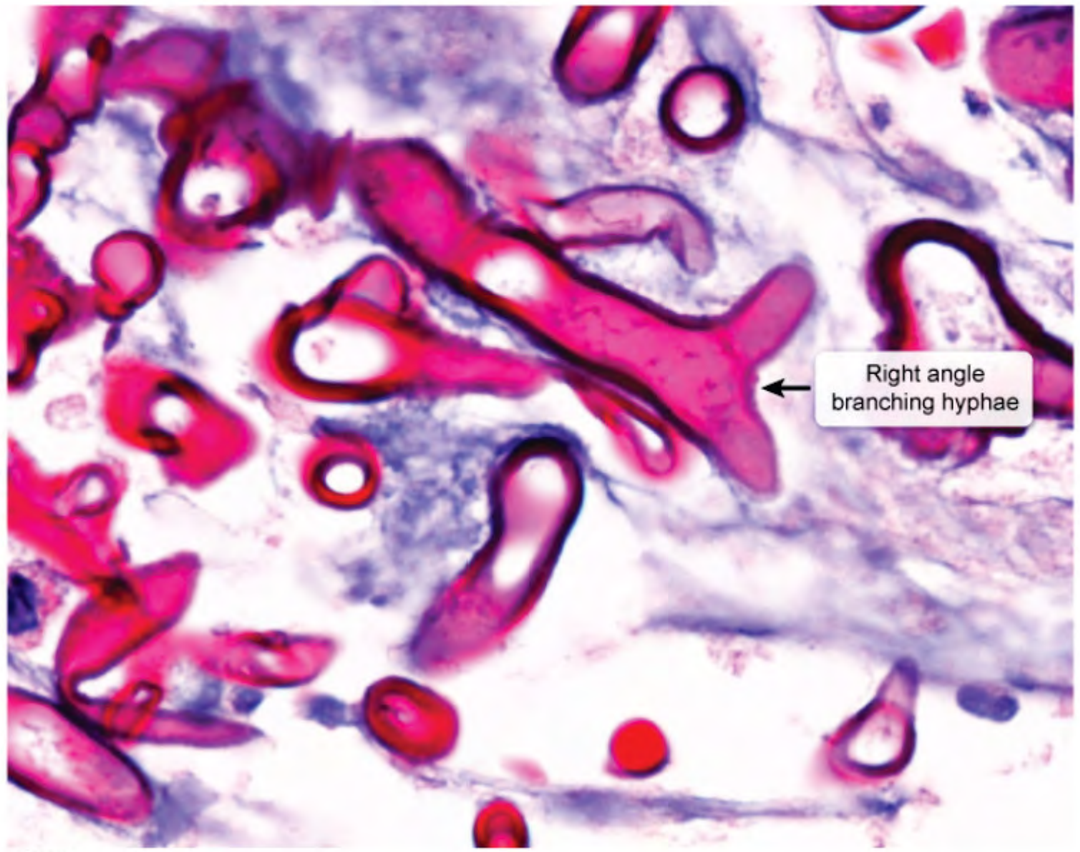

©UWorld

Zoom In | Zoom Out | Reset | New | Existing | My Notebook

https://t.me/USMLEWorldStep1

An 80-year-old man has been participating in a longitudinal study of aging. He has no major medical conditions. Arterial blood gas samples are obtained every decade, on room air at sea level, to monitor long-term changes in pulmonary gas exchange. Compared to 30 years ago, which of the following results is most consistent with normal aging?

	PaO_2	$PaCO_2$	A-a gradient
A.	↑	↓	↑
B.	↑	Unchanged	↓
C.	Unchanged	↑	Unchanged
D.	↓	↓	↑
E.	↓	Unchanged	↑

Submit

https://t.me/USMLEWorldStep1

An 80-year-old man has been participating in a longitudinal study of aging. He has no major medical conditions. Arterial blood gas samples are obtained every decade, on room air at sea level, to monitor long-term changes in pulmonary gas exchange. Compared to 30 years ago, which of the following results is most consistent with normal aging?

	PaO_2	$PaCO_2$	A-a gradient	
A.	↑	↓	↑	(3%)
✗ B.	↑	Unchanged	↓	(1%)
C.	Unchanged	↑	Unchanged	(23%)
D.	↓	↓	↑	(14%)
✓ E.	↓	Unchanged	↑	(56%)

Incorrect
Correct answer
E

56%
Answered correctly

03 secs
Time Spent

2023
Version

Explanation

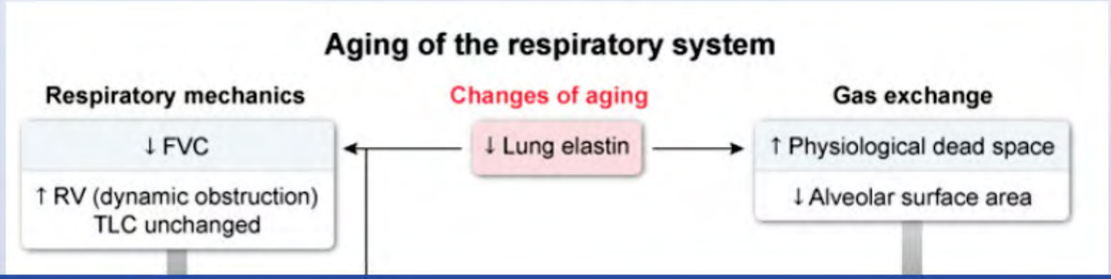

https://t.me/USMLEWorldStep1

C. Unchanged ↑ Unchanged (23%)

D.

E.

Incorrect
Correct answer
E

Explanation

Exhibit Display

Aging of the respiratory system

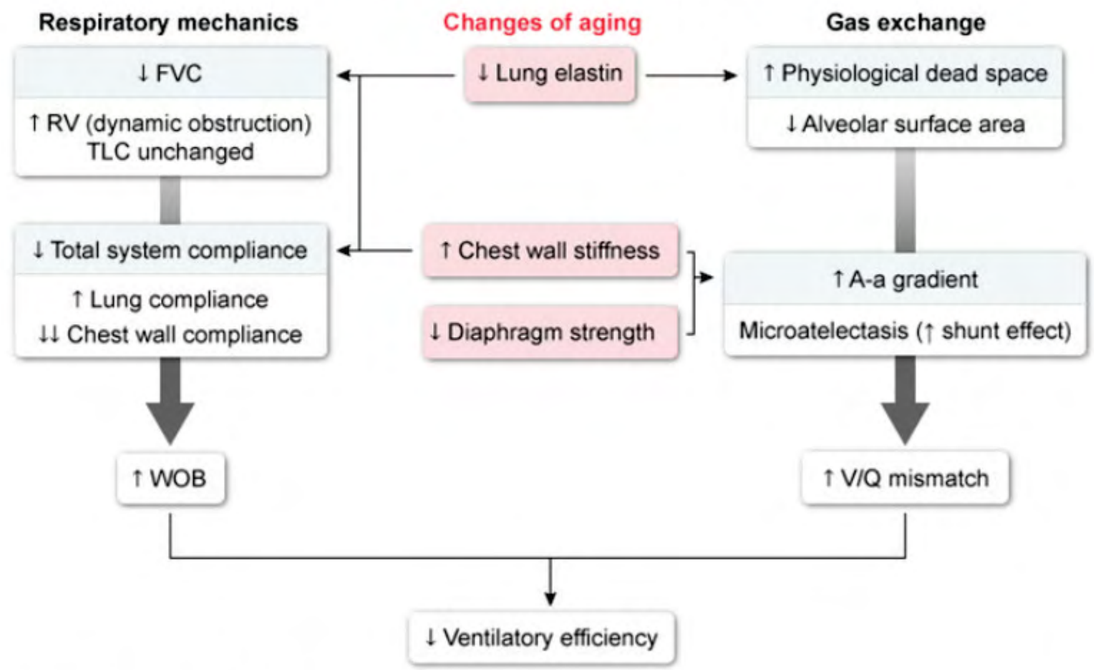

A-a = arterial-alveolar; **FVC** = forced vital capacity; **RV** = residual volume; **TLC** = total lung capacity; **V/Q** = ventilation-perfusion; **WOB** = work of breathing.

©UWorld

Zoom In Zoom Out Reset New | Existing My Notebook

https://t.me/USMLEWorldStep1

TLC = total lung capacity; **V/Q** = ventilation-perfusion; **WOB** = work of breathing.

©UWorld

The human respiratory system undergoes significant changes during **normal aging**. Pulmonary gas exchange becomes subtly impaired due to a sequence of gradual changes:

- Lung elastin degrades over time, leading to **alveolar simplification** (loss of surface area due to airspace enlargement). Loss of elastic fiber support causes dynamic airflow obstruction resembling emphysema, leading to hyperinflation. Therefore, inspired tidal volume has less opportunity to participate in gas exchange. In other words, physiologic dead space is **increased**.

- The muscles of respiration (chiefly the diaphragm) undergo remodeling over time, with atrophy of fast-twitch muscle fibers. This leads to **lower peak force production** for maneuvers such as deep inspiration or coughing. In combination with chest wall stiffening, this allows a small degree of **microatelectasis** to develop at the lung bases. This results in **intrapulmonary shunting** (perfusion of blood through atelectatic [nonventilated] alveoli).

- This combination of increased dead space and increased shunt effect leads to greater **ventilation-perfusion mismatch**. This ultimately causes the alveolar-arterial (A-a) oxygen gradient to progressively widen over decades. When evaluating an **elevated A-a gradient**, patient age must be accounted for to determine whether it is within the expected limits of normal aging (expected A-a gradient = age/3 mm Hg).

- Because of the higher A-a gradient, arterial partial pressure of oxygen (**PaO_2**) **falls** during aging (from 90 to 70 mm Hg by age 80). Since PaO_2 still remains on the plateau portion of the oxyhemoglobin desaturation curve, no change in SaO_2 would be detected by simple pulse oximetry.

In contrast to decreased PaO_2, the partial pressure of carbon dioxide in arterial blood (**$PaCO_2$**) (reflecting total alveolar ventilation) is **not significantly changed**. Although dead space increases and peak diaphragm strength is reduced, these changes are not enough to cause alveolar hypoventilation by themselves; resting hypoventilation (elevated $PaCO_2$) at any age is always pathologic. Instead, elderly persons are less able to compensate for high

https://t.me/USMLEWorldStep1

In other words, physiologic dead space is **increased**.

- The muscles of respiration (chiefly the diaphragm) undergo remodeling over time, with atrophy of fast-twitch muscle fibers. This leads to **lower peak force production** for maneuvers such as deep inspiration or coughing. In combination with chest wall stiffening, this allows a small degree of **microatelectasis** to develop at the lung bases. This results in **intrapulmonary shunting** (perfusion of blood through atelectatic [nonventilated] alveoli).

- This combination of increased dead space and increased shunt effect leads to greater **ventilation-perfusion mismatch**. This ultimately causes the alveolar-arterial (A-a) oxygen gradient to progressively widen over decades. When evaluating an **elevated A-a gradient**, patient age must be accounted for to determine whether it is within the expected limits of normal aging (expected A-a gradient = age/3 mm Hg).

- Because of the higher A-a gradient, arterial partial pressure of oxygen (**PaO_2**) **falls** during aging (from 90 to 70 mm Hg by age 80). Since PaO_2 still remains on the plateau portion of the oxyhemoglobin desaturation curve, no change in SaO_2 would be detected by simple pulse oximetry.

In contrast to decreased PaO_2, the partial pressure of carbon dioxide in arterial blood (**$PaCO_2$**) (reflecting total alveolar ventilation) is **not significantly changed**. Although dead space increases and peak diaphragm strength is reduced, these changes are not enough to cause alveolar hypoventilation by themselves; resting hypoventilation (elevated $PaCO_2$) at any age is always pathologic. Instead, elderly persons are less able to compensate for high minute ventilation loads (eg, sepsis, thyrotoxicosis), making them prone to hypercapnia when acutely ill.

Educational objective:
Normal aging is characterized by a gradual increase in ventilation-perfusion mismatch (due to basilar microatelectasis causing shunt effect) and increased dead space (loss of alveolar surface area). This manifests as a wider alveolar-arterial oxygen gradient (ie, decline in PaO_2) without hypoventilation (normal $PaCO_2$).

https://t.me/USMLEWorldStep1

The human res
becomes subtl

- Lung elas
  enlargeme
  leading to
  In other w
- The musc
  muscle fib
  coughing.
  at the lung
  [nonventil
- This comb
  mismatch
  decades.
  whether it
- Because
  mm Hg by
  no change

In contrast to d

Exhibit Display

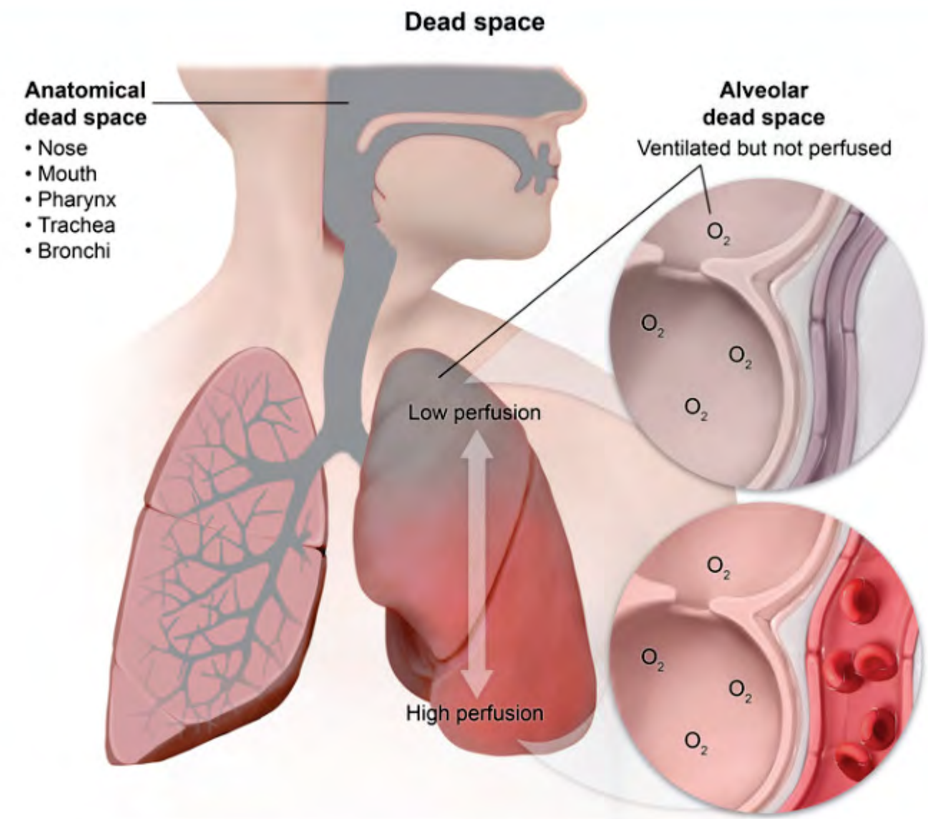

Zoom In Zoom Out Reset New | Existing My Notebook

https://t.me/USMLEWorldStep1

Exhibit Display

The human res
becomes subtl

- Lung elas
  enlargeme
  leading to
  In other w
- The musc
  muscle fib
  coughing.
  at the lung
  [nonventil
- This comb
  mismatch
  decades.
  whether it
- Because
  mm Hg by
  no change

In contrast to c

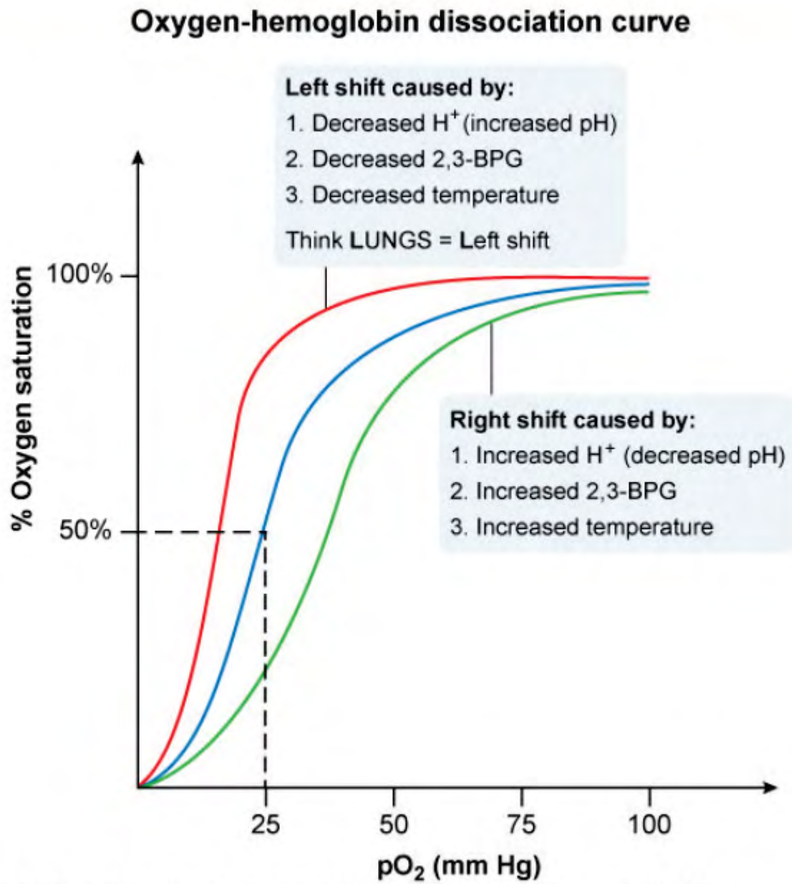

2,3-BPG = 2,3-bisphosphoglycerate; **pO_2** = partial pressure of oxygen in the blood.

©UWorld

Zoom In | Zoom Out | Reset | New | Existing | My Notebook

https://t.me/USMLEWorldStep1

A 65-year-old man comes to the emergency department due to worsening dyspnea. The patient has a history of cigarette smoking and chronic productive cough. He experienced increasing shortness of breath today without fever, chills, or chest pain. Temperature is 36.7 C (98 F), blood pressure is 135/85 mm Hg, pulse is 94/min, and respirations are 24/min. Pulse oximetry shows 86% on room air. He has decreased breath sounds over the right chest. Chest x-ray is shown in the exhibit. Which of the following is the most likely cause of this patient's radiographic findings?

- A. Air leakage and accumulation in the right pleural space
- B. Fibrous replacement of the pulmonary parenchyma
- C. Fluid transudation into the interstitial and alveolar space
- D. Occlusion of the right mainstem bronchus by mucus plug
- E. Thromboembolic occlusion of the right pulmonary artery

Submit

https://t.me/USMLEWorldStep1

A 65 [illegible]
ciga
feve
resp
ches
radi

Exhibit Display

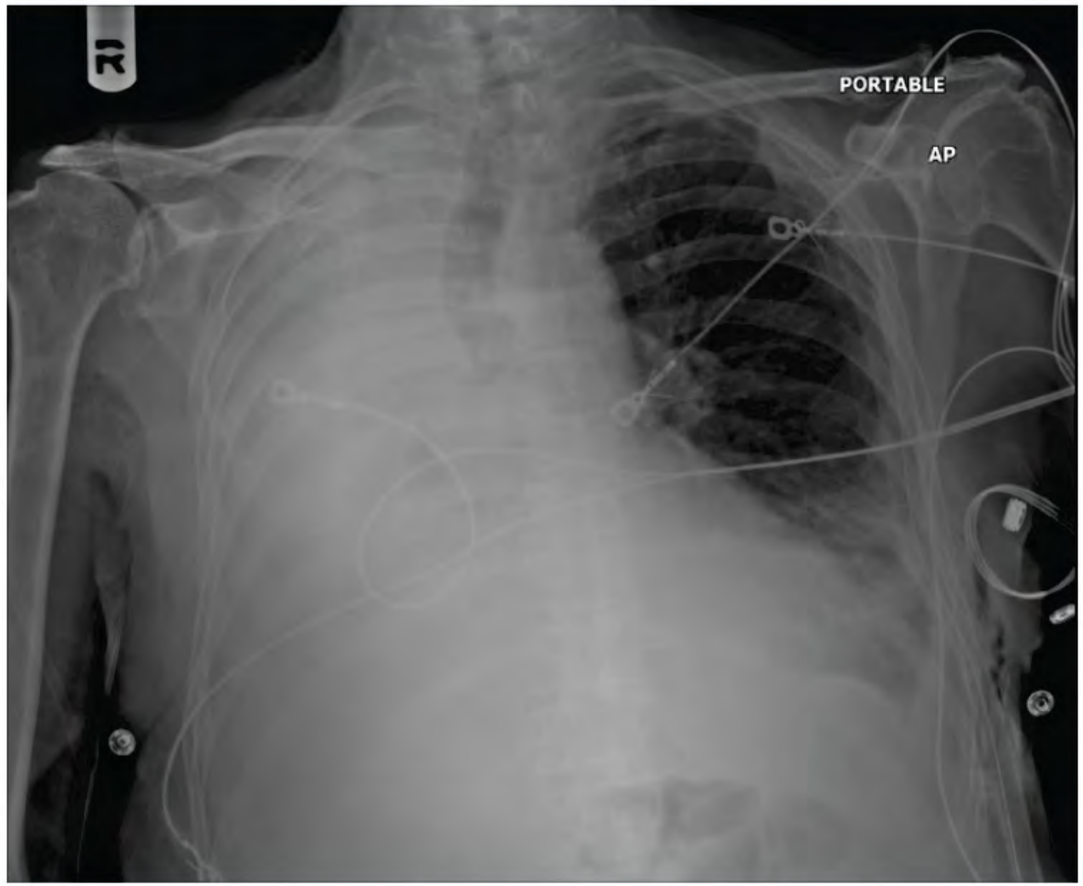

Zoom In | Zoom Out | Reset | New | Existing | My Notebook

https://t.me/USMLEWorldStep1

A 65-year-old man comes to the emergency department due to worsening dyspnea. The patient has a history of cigarette smoking and chronic productive cough. He experienced increasing shortness of breath today without fever, chills, or chest pain. Temperature is 36.7 C (98 F), blood pressure is 135/85 mm Hg, pulse is 94/min, and respirations are 24/min. Pulse oximetry shows 86% on room air. He has decreased breath sounds over the right chest. Chest x-ray is shown in the exhibit. Which of the following is the most likely cause of this patient's radiographic findings?

- A. Air leakage and accumulation in the right pleural space (11%)
- ✗ B. Fibrous replacement of the pulmonary parenchyma (5%)
- C. Fluid transudation into the interstitial and alveolar space (55%)
- ✓ D. Occlusion of the right mainstem bronchus by mucus plug (26%)
- E. Thromboembolic occlusion of the right pulmonary artery (2%)

Incorrect
Correct answer
D

26%
Answered correctly

10 secs
Time Spent

2023
Version

Explanation

Right lung collapse with mediastinal shift

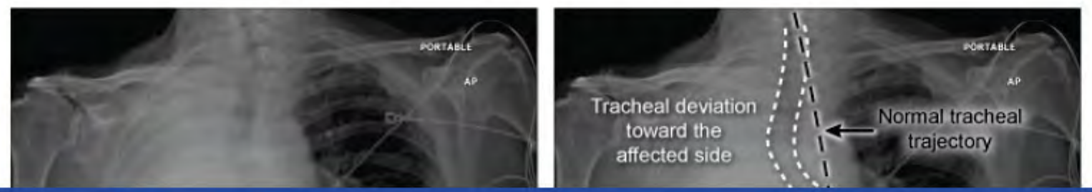

https://t.me/USMLEWorldStep1

Incorrect
Correct answer
D

26%
Answered correctly

10 secs
Time Spent

2023
Version

Exhibit Display

Right lung collapse with mediastinal shift

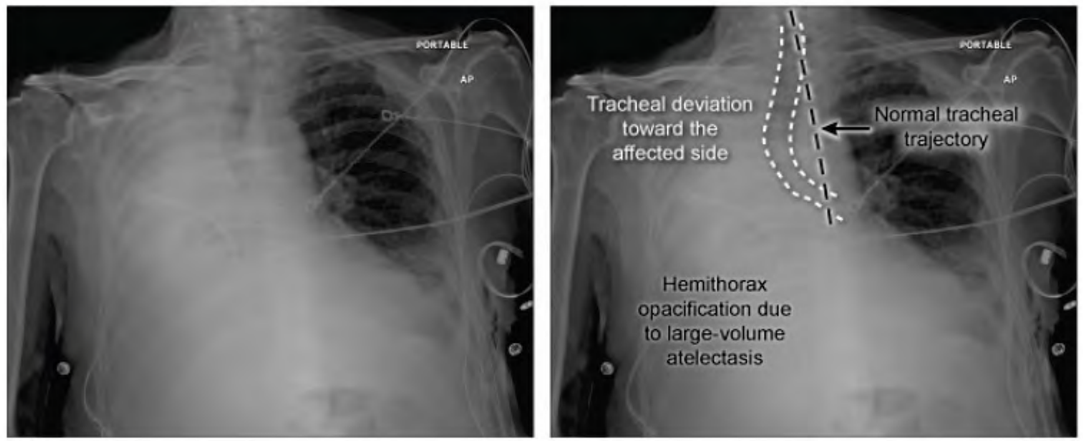

©UWorld

Zoom In | Zoom Out | Reset | New | Existing | My Notebook

This
opac
bron
dise
lung

Dista
ensu

structures (eg, heart, esophagus, great vessels) may also shift in the same direction. The loss of radiolucent air, combined with shifting of organs into the hemithorax, appears as a **completely opacified hemithorax** on chest x

https://t.me/USMLEWorldStep1

©UWorld

This patient's right-sided decreased breath sounds and hemithorax opacification with tracheal deviation toward the opacified side are suggestive of **right lung collapse** (ie, atelectasis) due to obstruction of the **right mainstem bronchus**. This most commonly occurs due to **mucus plugging** in patients with chronic obstructive pulmonary disease or bronchiectasis, or due to **malignant obstruction** by a centrally located lung cancer (eg, squamous cell lung cancer).

Distal to the obstruction, air becomes trapped in the alveoli and gradually gets absorbed into the bloodstream, with ensuing large-volume alveolar collapse and pulling of the **trachea toward the affected side**. Other mediastinal structures (eg, heart, esophagus, great vessels) may also shift in the same direction. The loss of radiolucent air, combined with shifting of organs into the hemithorax, appears as a **completely opacified hemithorax** on chest x-ray.

In contrast, space-occupying pathology such as large pleural effusion or tension pneumothorax (ie, air accumulation in the pleural space) forces tracheal deviation *away* from the affected side **(Choice A)**.

(Choice B) Fibrous replacement of the pulmonary parenchyma occurs in interstitial lung disease. Chest x-ray is expected to show reticular markings in both lungs rather than complete opacification of one side.

(Choice C) Fluid transudation into the alveoli and interstitial spaces occurs with pulmonary edema (eg, heart failure). Chest x-ray typically shows bilateral fluffy-appearing infiltrates, often with an associated bilateral pleural effusion. However, the trachea remains midline.

(Choice E) Thromboembolic occlusion of the right pulmonary artery (ie, acute pulmonary embolism) usually presents with a normal chest x-ray. Characteristic findings such as Westermark sign (area of distal arterial lucency due to the reduced perfusion) or Hampton hump (wedge-shaped opacity adjacent to the pleura) are only occasionally present.

Educational objective:

https://t.me/USMLEWorldStep1

bronchus. This most commonly occurs due to **mucus plugging** in patients with chronic obstructive pulmonary disease or bronchiectasis, or due to **malignant obstruction** by a centrally located lung cancer (eg, squamous cell lung cancer).

Distal to the obstruction, air becomes trapped in the alveoli and gradually gets absorbed into the bloodstream, with ensuing large-volume alveolar collapse and pulling of the **trachea toward the affected side**. Other mediastinal structures (eg, heart, esophagus, great vessels) may also shift in the same direction. The loss of radiolucent air, combined with shifting of organs into the hemithorax, appears as a **completely opacified hemithorax** on chest x-ray.

In contrast, space-occupying pathology such as large pleural effusion or tension pneumothorax (ie, air accumulation in the pleural space) forces tracheal deviation *away* from the affected side **(Choice A)**.

(Choice B) Fibrous replacement of the pulmonary parenchyma occurs in interstitial lung disease. Chest x-ray is expected to show reticular markings in both lungs rather than complete opacification of one side.

(Choice C) Fluid transudation into the alveoli and interstitial spaces occurs with pulmonary edema (eg, heart failure). Chest x-ray typically shows bilateral fluffy-appearing infiltrates, often with an associated bilateral pleural effusion. However, the trachea remains midline.

(Choice E) Thromboembolic occlusion of the right pulmonary artery (ie, acute pulmonary embolism) usually presents with a normal chest x-ray. Characteristic findings such as Westermark sign (area of distal arterial lucency due to the reduced perfusion) or Hampton hump (wedge-shaped opacity adjacent to the pleura) are only occasionally present.

Educational objective:
An obstructive lesion in a mainstem bronchus can prevent ventilation of an entire lung, leading to large-volume atelectasis and complete lung collapse. Characteristic findings on chest x-ray include unilateral opacification and deviation of the mediastinum toward the opacified lung.

https://t.me/USMLEWorldStep1

bronchus. This most commonly occurs due to **mucus plugging** in patients with chronic obstructive pulmonary dise
lung

Dist
ensu
struc
com
ray.

In c
accu

(Ch
expe

(Ch
failu
effus

(Ch
pres
due
occa

Edu
An c
atele
deviation of the mediastinum toward the opacified lung.

Exhibit Display

Large right pleural effusion with mediastinal shift

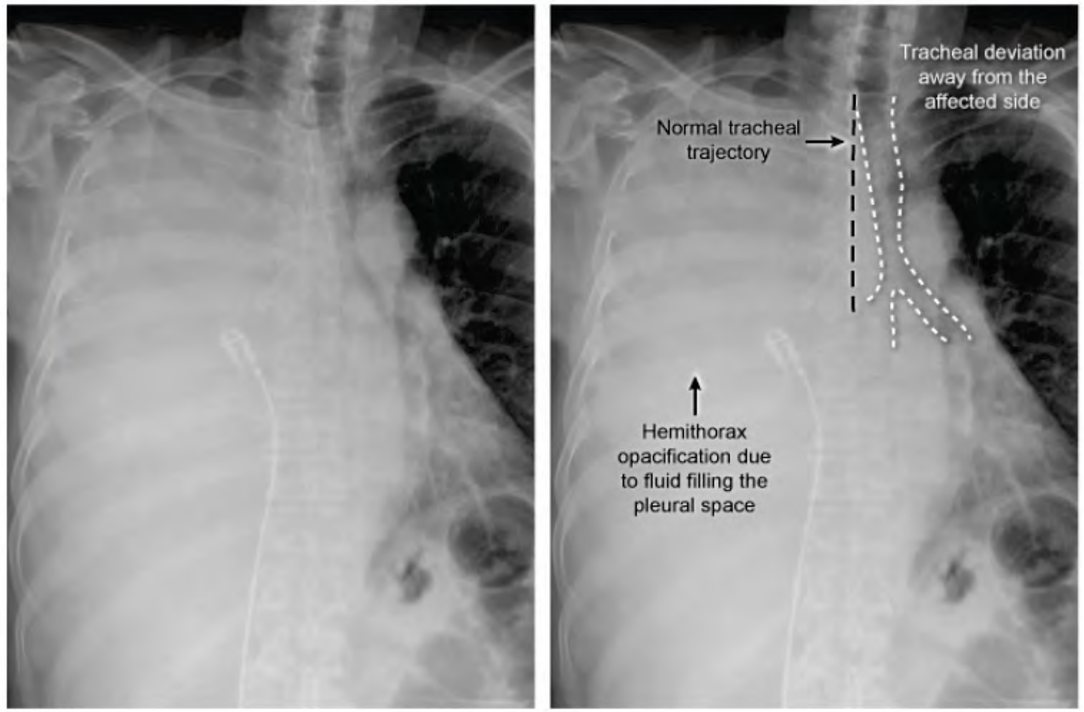

©UWorld

Zoom In | Zoom Out | Reset | New | Existing | My Notebook

https://t.me/USMLEWorldStep1

bronchus. This most commonly occurs due to **mucus plugging** in patients with chronic obstructive pulmonary dise
lung

Dist
ensu
struc
com
ray.

In c
accu

(Ch
expe

(Ch
failu
effus

(Ch
pres
due
occa

Edu
An c
atele
deviation of the mediastinum toward the opacified lung.

Exhibit Display

Left tension pneumothorax with mediastinal shift

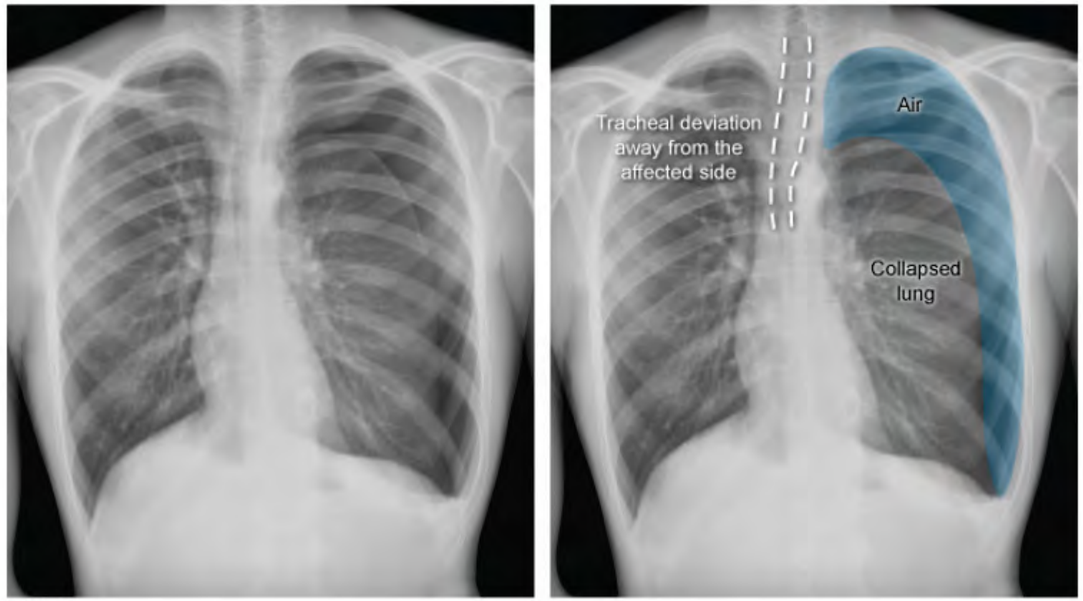

©UWorld

Zoom In | Zoom Out | Reset | New | Existing | My Notebook

https://t.me/USMLEWorldStep1

bronchus. This most commonly occurs due to **mucus plugging** in patients with chronic obstructive pulmonary

dise

lung

Dist

ensu

struc

com

ray.

In c

accu

(Ch

expe

(Ch

failu

effus

(Ch

pres

due

occa

Edu

An c

atele

deviation of the mediastinum toward the opacified lung.

Exhibit Display

Interstitial lung disease

Diffuse reticular (net-like) infiltrates

©UWorld

Zoom In | Zoom Out | Reset | New | Existing | My Notebook

https://t.me/USMLEWorldStep1

bronchus. This most commonly occurs due to **mucus plugging** in patients with chronic obstructive pulmonary disease or bro
lung cancer).

Distal to the ob
ensuing large-
structures (eg,
combined with
ray.

In contrast, spa
accumulation i

(Choice B) Fi
expected to sh

(Choice C) Fl
failure). Chest
effusion. Howe

(Choice E) Th
presents with a
due to the redu
occasionally pr

Educational o
An obstructive
atelectasis and
deviation of the

Exhibit Display

Bilateral pulmonary edema

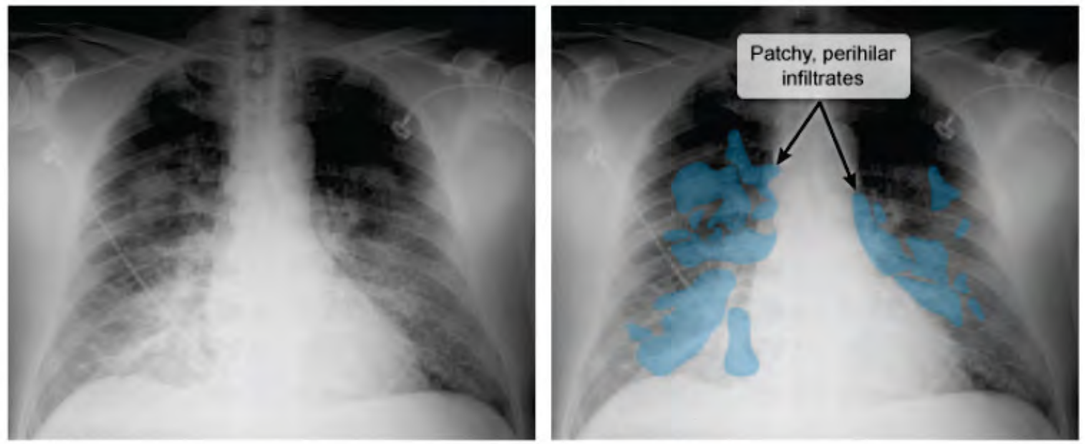

©UWorld

Zoom In | Zoom Out | Reset | New | Existing | My Notebook

https://t.me/USMLEWorldStep1

Physiologists are studying the mechanisms of pleural fluid formation and absorption in the normal state. They obtain healthy experimental animals whose pleuropulmonary anatomy and physiology closely resembles that of humans. Intravenous radioisotope tracers are injected into these animals and are monitored closely to track fluid movement into and out of the pleural space. Which of the following pathways of pleural fluid turnover is most likely to be observed?

	Fluid entry		Fluid exit
○ A.	Bronchial microvessels	→	Pulmonary capillaries
○ B.	Bronchial microvessels	→	Pulmonary parenchymal lymphatics
○ C.	Intercostal microvessels	→	Parietal pleural lymphatics
○ D.	Intercostal microvessels	→	Pulmonary capillaries

Submit

https://t.me/USMLEWorldStep1

Physiologists are studying the mechanisms of pleural fluid formation and absorption in the normal state. They obtain healthy experimental animals whose pleuropulmonary anatomy and physiology closely resembles that of humans. Intravenous radioisotope tracers are injected into these animals and are monitored closely to track fluid movement into and out of the pleural space. Which of the following pathways of pleural fluid turnover is most likely to be observed?

	Fluid entry		Fluid exit	
✗ ◉	A. Bronchial microvessels	→	Pulmonary capillaries	(14%)
○	B. Bronchial microvessels	→	Pulmonary parenchymal lymphatics	(33%)
✓ ○	C. Intercostal microvessels	→	Parietal pleural lymphatics	(47%)
○	D. Intercostal microvessels	→	Pulmonary capillaries	(4%)

Incorrect
Correct answer
C

47%
Answered correctly

04 secs
Time Spent

2023
Version

Explanation

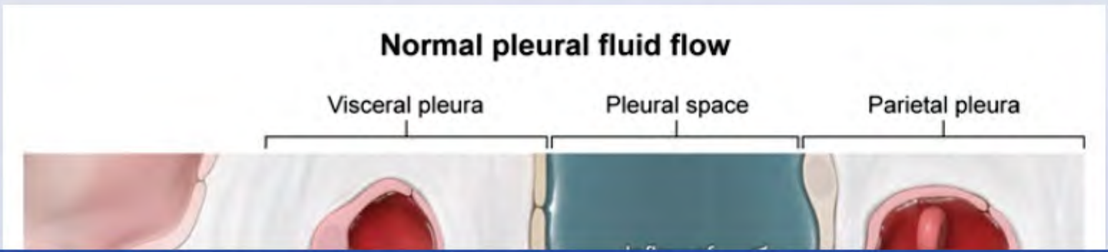

https://t.me/USMLEWorldStep1

Explanation

Exhibit Display

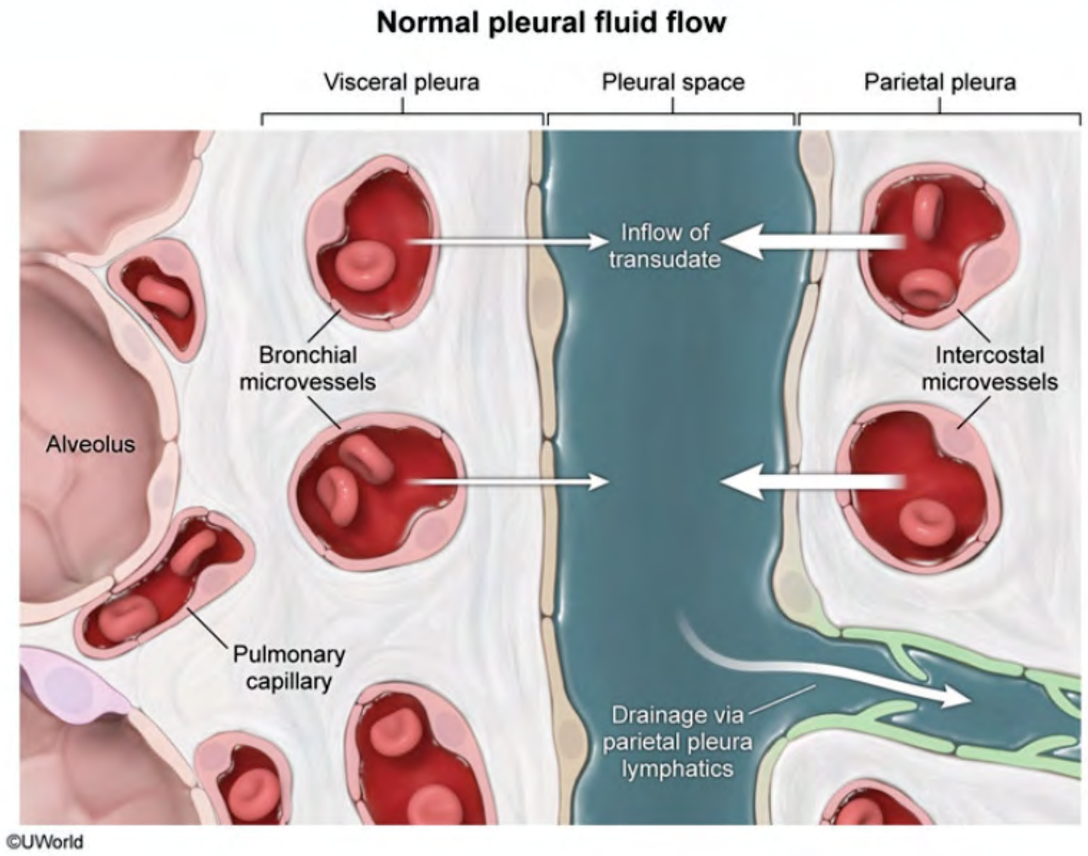

Zoom In | Zoom Out | Reset | New | Existing | My Notebook

Hum
inflo
pleu
fluid filtered from the **intercostal microvessels** in the **parietal pleura** and a lesser amount from the bronchial microvessels in the visceral pleura

https://t.me/USMLEWorldStep1



©UWorld

Humans normally have approximately 5-10 mL of **pleural fluid** in the intrapleural space of each hemithorax, with inflow and outflow of fluid taking place at equal rates to maintain homeostasis. Pleural fluid is believed to **enter** the pleural space via filtration from **systemic circulation** in both the parietal and visceral pleura, with the majority of fluid filtered from the **intercostal microvessels** in the **parietal pleura** and a lesser amount from the bronchial microvessels in the visceral pleura.

Most pleural fluid likely **exits** the pleural space via holes in the parietal pleura known as lymphatic stoma that drain into the **parietal pleural lymphatics**.

Pleural effusion results from an increase in the rate of pleural fluid inflow (eg, increased fluid filtration as occurs with decompensated heart failure, hypoalbuminemia, or an inflammatory increase in pleural vascular permeability) or a decrease in the rate of pleural fluid outflow (eg, malignant obstruction of the parietal pleura lymphatic stoma).

(Choices A, B, and D) Neither the pulmonary capillaries nor the pulmonary parenchymal lymphatics significantly contribute to the uptake of pleural fluid from the pleural space in the normal or pathologic state. Fluid from the pulmonary (alveolar) capillaries (ie, the pulmonary circulation) does not significantly contribute to inflow of pleural fluid into the pleural space in the normal state; however, it can become a primary source of fluid inflow in pathologic states (eg, increased pulmonary capillary hydrostatic pressure with decompensated heart failure).

Educational objective:
Pleural fluid normally enters the pleural space via filtration from the systemic circulation, primarily from the intercostal microvessels of the parietal pleura, and exits the pleural space via stomata in the parietal pleura that drain into the parietal pleura lymphatics.

References

- Pleural mechanics and fluid exchange.

https://t.me/USMLEWorldStep1

parietal pleura
lymphatics

Exhibit Display

Humans norma
inflow and outf
pleural space v
fluid filtered fro
microvessels ir

Most pleural flu
into the **parieta**

Pleural effusio
with decompen
or a decrease i

(Choices A, B
contribute to th
pulmonary (alv
fluid into the pl
states (eg, incr

Educational o
Pleural fluid nc
intercostal mic
drain into the p

References

- Pleural mec

Causes of pleural effusion

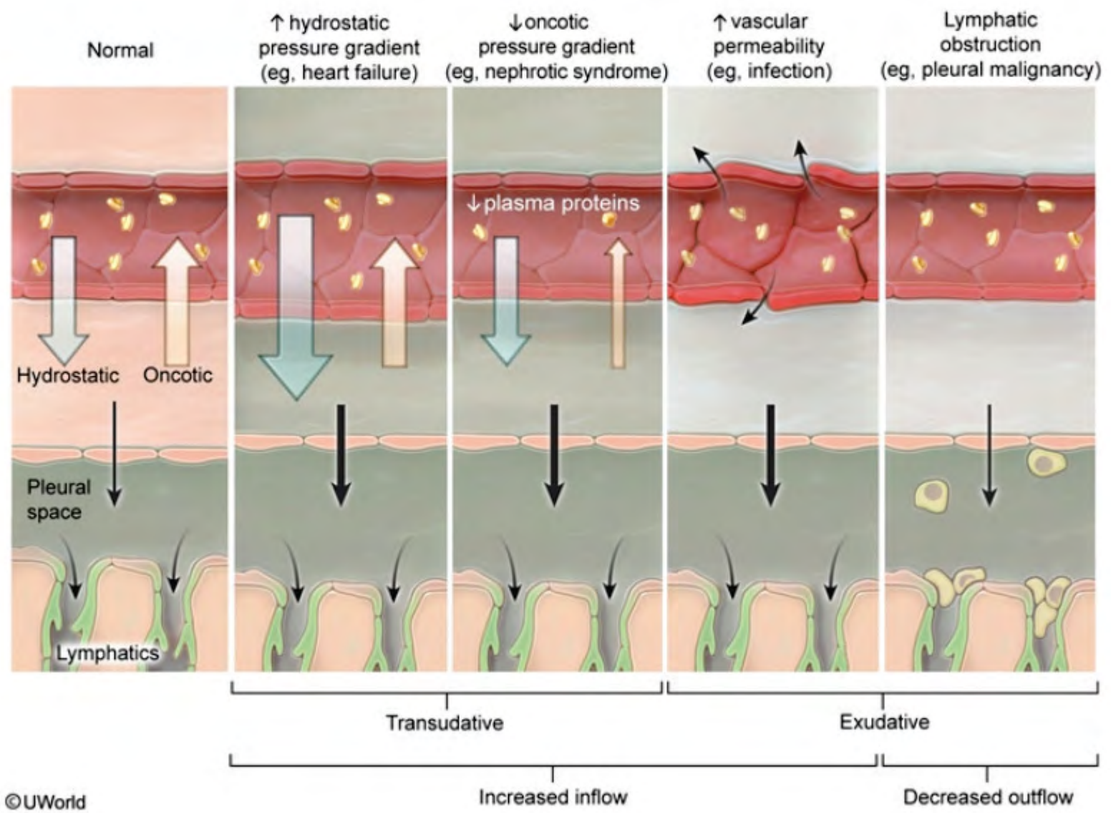

Zoom In | Zoom Out | Reset | New | Existing | My Notebook

https://t.me/USMLEWorldStep1

A 56-year-old man comes to the clinic due to recent-onset headache and dyspnea. The patient also says he has had a puffy face for 2 weeks along with a persistent dry cough. He does not have any neck or shoulder pain. He has no other medical problems. Physical examination shows symmetrical facial swelling and conjunctival edema. The pupils are equal, round, and reactive to light. Dilated veins are noted over his neck and upper trunk. Heart and lung sounds are normal. Peripheral strength and sensation are intact. Which of the following is the most likely cause of this patient's symptoms?

- A. Airway obstruction
- B. Autoimmune disease
- C. Excessive hormone secretion
- D. Mediastinal mass
- E. Pericardial effusion
- F. Pleural effusion
- G. Superior sulcus tumor

Submit

https://t.me/USMLEWorldStep1

A 56-year-old man comes to the clinic due to recent-onset headache and dyspnea. The patient also says he has had a puffy face for 2 weeks along with a persistent dry cough. He does not have any neck or shoulder pain. He has no other medical problems. Physical examination shows symmetrical facial swelling and conjunctival edema. The pupils are equal, round, and reactive to light. Dilated veins are noted over his neck and upper trunk. Heart and lung sounds are normal. Peripheral strength and sensation are intact. Which of the following is the most likely cause of this patient's symptoms?

- A. Airway obstruction (2%)
- ✗ B. Autoimmune disease (6%)
- C. Excessive hormone secretion (10%)
- ✓ D. Mediastinal mass (40%)
- E. Pericardial effusion (3%)
- F. Pleural effusion (2%)
- G. Superior sulcus tumor (34%)

Incorrect
Correct answer
D

40%
Answered correctly

04 secs
Time Spent

2023
Version

Explanation

Superior vena cava syndrome

https://t.me/USMLEWorldStep1

B. Autoimmune disease (6%)

Exhibit Display

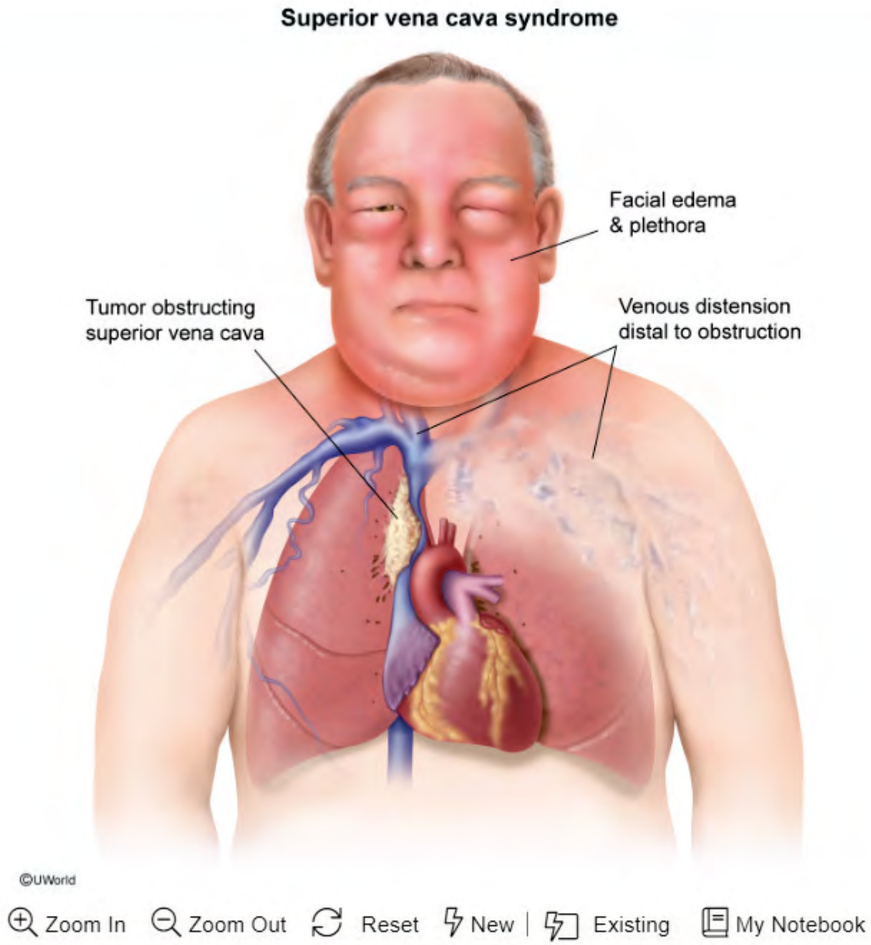

Zoom In | Zoom Out | Reset | New | Existing | My Notebook

https://t.me/USMLEWorldStep1

This patient's symptoms are consistent with **superior vena cava (SVC) syndrome**, a condition that develops when SVC **obstruction** impairs venous return from the head, neck, upper trunk, and upper extremities.

The SVC is formed by the union of the right and left brachiocephalic veins behind the right first costal cartilage and descends inferiorly for 6-8 cm before draining directly into the right atrium. During its course, the SVC is surrounded by multiple mediastinal structures (eg, trachea, right bronchus, aorta, right pulmonary artery) and is close to the perihilar and paratracheal lymph nodes.

Due to its thin walls, the SVC can be easily **compressed by mediastinal masses** (most commonly **malignancy**) that either extend into the mediastinum from the central lung (eg, small cell lung cancer) or nearby lymph nodes (eg, non-Hodgkin lymphoma). Patients with SVC syndrome often experience the following symptoms due to increased venous pressure in the upper body:

- Face and neck swelling and conjunctival edema
- Distended veins due to increased collateral venous drainage
- Headache, dizziness, and/or confusion due to cerebral edema and elevated intracranial pressure
- Cough and/or dyspnea due to laryngeal edema and/or direct compression of adjacent structures (eg, trachea) by the mediastinal mass

(Choices A and B) Airway obstruction and autoimmune disease can cause dyspnea, but facial swelling and dilated collateral veins would not be expected.

(Choice C) Inappropriate secretion of ACTH can occur in small cell lung cancers and cause Cushing syndrome (eg, swollen or moon face due to fatty tissue deposition). However, Cushing syndrome is not associated with conjunctival edema or distended neck veins.

(Choice E) Pericardial effusions can cause dyspnea and distended neck veins; however, facial swelling and headaches would not be expected. In addition, distant heart sounds or pulsus paradoxus (decrease in systolic

https://t.me/USMLEWorldStep1

- Distended veins due to increased collateral venous drainage
- Headache, dizziness, and/or confusion due to cerebral edema and elevated intracranial pressure
- Cough and/or dyspnea due to laryngeal edema and/or direct compression of adjacent structures (eg, trachea) by the mediastinal mass

(Choices A and B) Airway obstruction and autoimmune disease can cause dyspnea, but facial swelling and dilated collateral veins would not be expected.

(Choice C) Inappropriate secretion of ACTH can occur in small cell lung cancers and cause Cushing syndrome (eg, swollen or moon face due to fatty tissue deposition). However, Cushing syndrome is not associated with conjunctival edema or distended neck veins.

(Choice E) Pericardial effusions can cause dyspnea and distended neck veins; however, facial swelling and headaches would not be expected. In addition, distant heart sounds or pulsus paradoxus (decrease in systolic blood pressure >10 mm Hg during inspiration) is often present.

(Choice F) Patients with pleural effusions often have dyspnea but do not typically have facial swelling or dilated veins. In addition, decreased breath sounds and dullness to percussion are often present.

(Choice G) Superior pulmonary sulcus tumors (Pancoast tumors) arise at the lung apex and are a relatively uncommon cause of SVC syndrome due to their more peripheral location within the lung. Most patients initially present with shoulder pain and other neurologic findings (eg, Horner syndrome, hand weakness) due to tumor invasion through the chest wall and involvement of adjacent structures (eg, brachial plexus).

Educational objective:
Extrinsic compression of the superior vena cava by a mediastinal mass (eg, malignancy) can cause superior vena cava syndrome, with impaired venous return from the upper body. Signs and symptoms include facial swelling, distended collateral veins, headache, and dyspnea.

https://t.me/USMLEWorldStep1

Exhibit Display

Superior vena cava syndrome

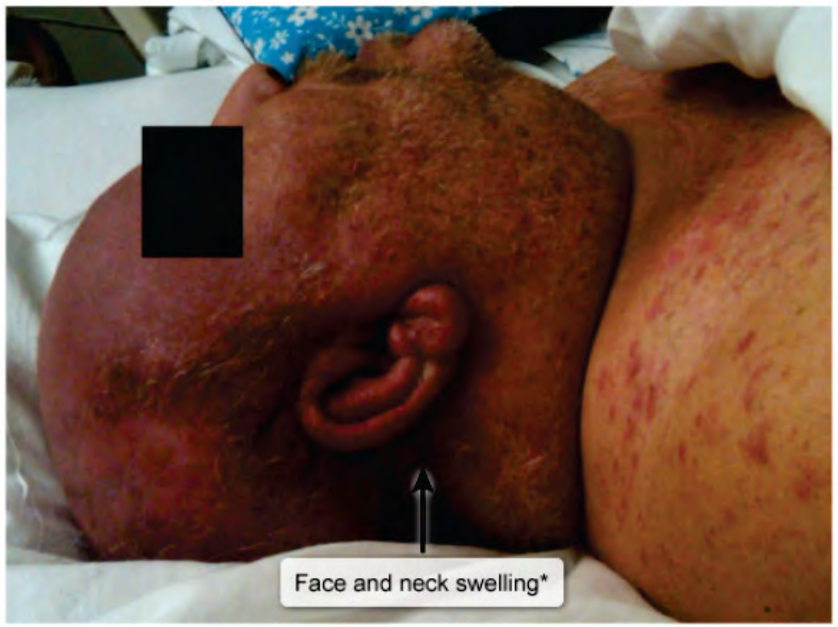

*Increased venous pressure due to impaired venous return.

©UWorld

Zoom In | Zoom Out | Reset | New | Existing | My Notebook

This
whe

The
desc
surr
clos

Due
that
(eg,
incr

-
-
-
-

(Ch
dilat

(Ch
(eg, swollen or moon face due to fatty tissue deposition). However, Cushing syndrome is not associated with conjunctival edema or distended neck veins.

https://t.me/USMLEWorldStep1

Exhibit Display

Superior vena cava syndrome

*Due to increased collateral venous drainage ©UWorld

Zoom In | Zoom Out | Reset | New | Existing | My Notebook

This
whe

The
desc
surr
clos

Due
that
(eg,
incr

-
-
-
-

(Ch
dilat

(Ch
(eg, swollen or moon face due to fatty tissue deposition). However, Cushing syndrome is not associated with conjunctival edema or distended neck veins.

https://t.me/USMLEWorldStep1

- Distended veins due to increased collateral venous drainage
-
-

(Ch
dilat

(Ch
(eg,
conj

(Ch
hea
bloo

(Ch
vein

(Ch
unc
pres
inva

Edu
Extr
cava
distended collateral veins, headache, and dyspnea.

Exhibit Display

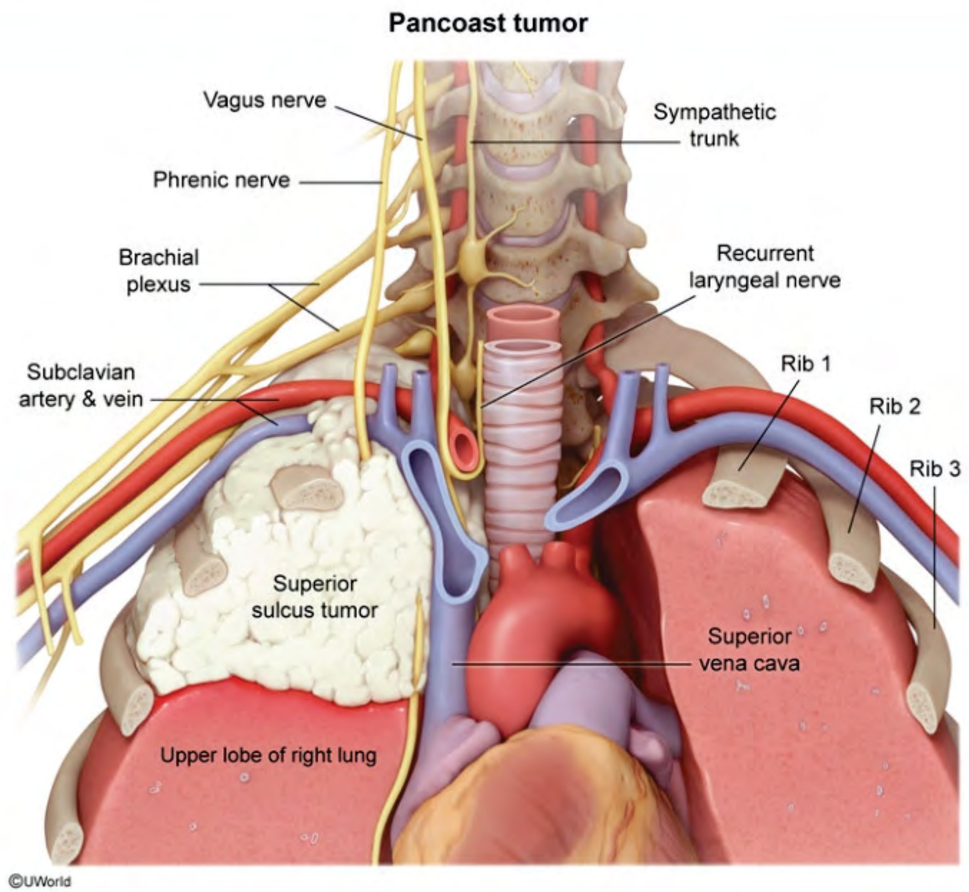

Zoom In | Zoom Out | Reset | New | Existing | My Notebook

https://t.me/USMLEWorldStep1

A 53-year-old man is being evaluated for dyspnea. The graph on the right shows how the patient's work of breathing varies with respiratory rate, whereas the graph on left represents the work of breathing versus respiratory rate in a normal individual. The minute ventilation is constant and equal in both graphs.

Which of the following is the most likely diagnosis in this patient?

- A. Alpha-1 antitrypsin deficiency
- B. Anxiety disorder
- C. Asthma
- D. Goiter
- E. Pulmonary fibrosis

Submit

https://t.me/USMLEWorldStep1

A 53 [illegible]
brea
rate

Exhibit Display

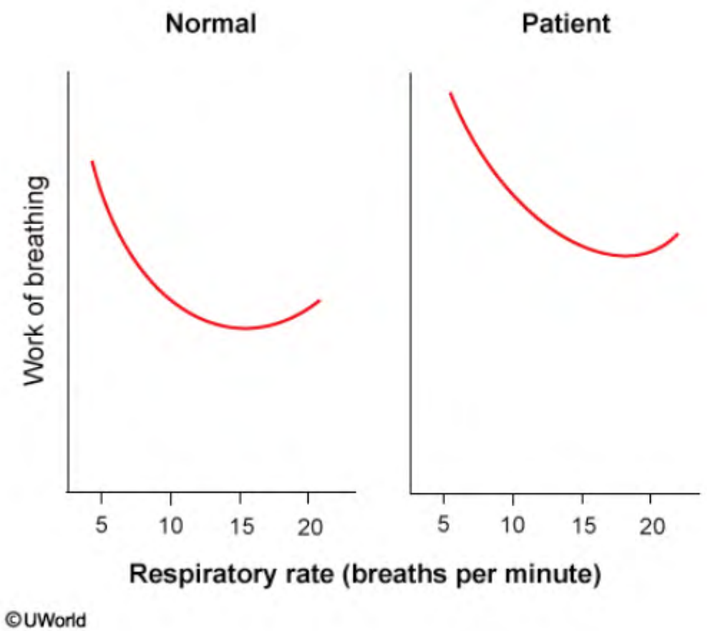

Zoom In | Zoom Out | Reset | New | Existing | My Notebook

Whi

E. Pulmonary fibrosis

https://t.me/USMLEWorldStep1

rate in a normal individual. The minute ventilation is constant and equal in both graphs.

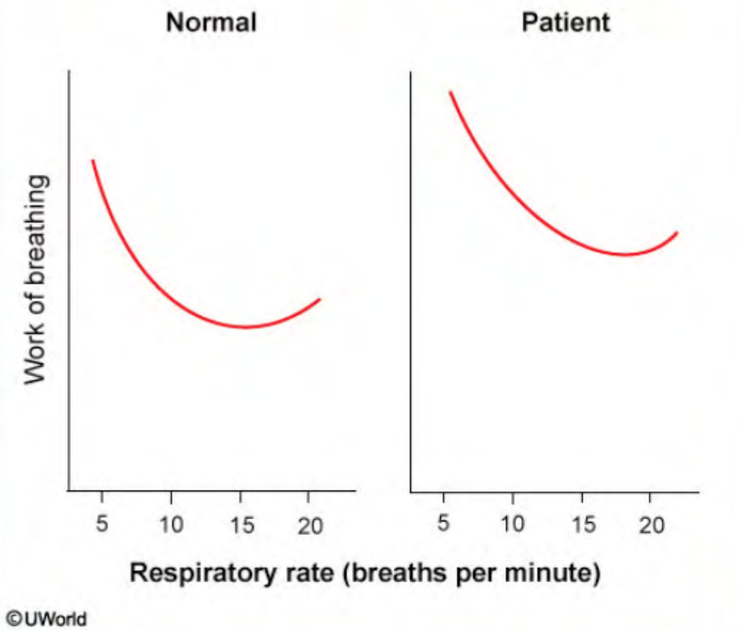

Which of the following is the most likely diagnosis in this patient?

- A. Alpha-1 antitrypsin deficiency
- B. Anxiety disorder
- C. Asthma
- D. Goiter
- E. Pulmonary fibrosis

Submit

https://t.me/USMLEWorldStep1

rate in a normal individual. The minute ventilation is constant and equal in both graphs.

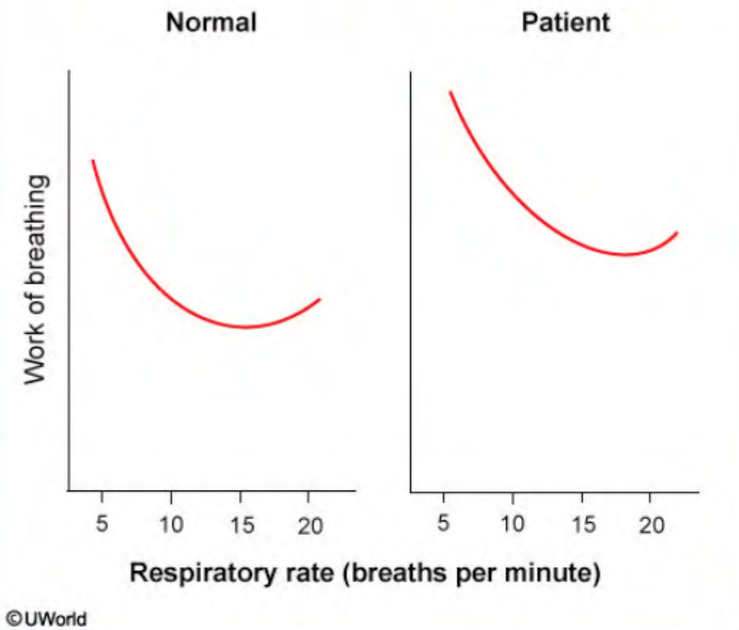

Which of the following is the most likely diagnosis in this patient?

- A. Alpha-1 antitrypsin deficiency (17%)
- ✕ B. Anxiety disorder (3%)
- C. Asthma (11%)
- D. Goiter (1%)
- ✓ E. Pulmonary fibrosis (65%)

Incorrect
Correct answer
E

65%
Answered correctly

11 secs
Time Spent

2023
Version

https://t.me/USMLEWorldStep1

B. Anxiety disorder (3%)

Exhibit Display

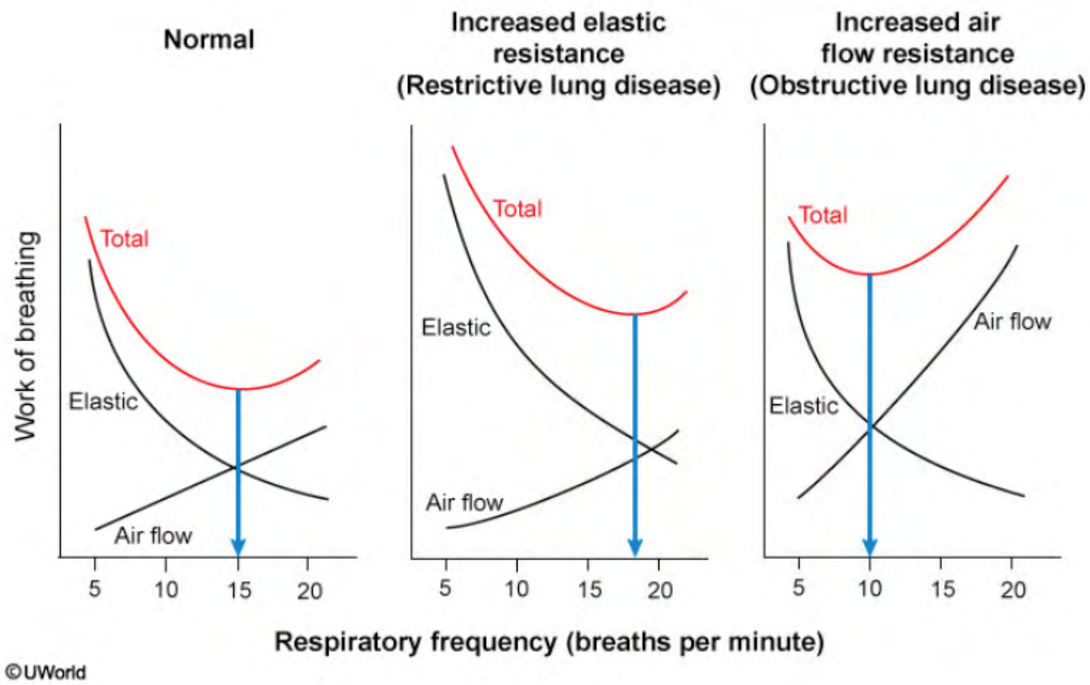

Zoom In | Zoom Out | Reset | New | Existing | My Notebook

Respiratory frequency (breaths per minute)

©UWorld

https://t.me/USMLEWorldStep1

©UWorld

Work of breathing (WOB) is the energy expended during respiration, and comprises the work required to overcome both elastic and airflow resistance:

- **Elastic resistance** is the opposition to lung expansion caused by the intrinsic elastic properties of the lungs and chest wall; it is increased at higher tidal volumes (elastic recoil increases at high lung volumes). **Restrictive lung diseases** (eg, pulmonary fibrosis, severe obesity) are characterized by higher than normal elastic resistance. Interstitial fibrosis increases lung stiffness whereas severe obesity increases chest wall stiffness.
- **Airflow resistance** is the opposition to airflow created by limited airway diameter and turbulent airflow; it is increased at higher respiratory rates (due to faster airflow with increased turbulence) and at low lung volumes (due to reduced airway diameter). **Obstructive lung diseases** (eg, asthma, chronic obstructive pulmonary disease) increase airflow resistance due to bronchoconstriction and/or airway collapse.

To reduce the WOB, the tidal volume and respiratory rate are optimized by the respiratory control centers. In patients with **restrictive lung disease**, the WOB is minimized when the tidal volume is low. Therefore, to compensate for low lung volumes, **rapid**, **shallow breathing** is favored (as in this patient). In contrast, in patients who have obstructive lung disease, the WOB is minimized with lower respiratory rates and higher tidal volumes (ie, relatively slow, deep breathing) **(Choice C)**.

(Choice A) Alpha-1 antitrypsin deficiency causes panacinar emphysema, a type of chronic obstructive pulmonary disease. This causes increased airflow resistance, and slow, deep breaths will be favored to minimize the WOB.

(Choice B) Anxiety disorders (eg, panic attacks) are occasionally associated with rapid, shallow breathing; however, the lungs function normally and, therefore, the WOB versus the respiratory rate curve is normal. Because the breathing rate is higher than the normal optimal rate, the work done against airflow resistance (and total work) is increased.

(Choice D) A fixed upper airway obstruction (eg, caused by a large goiter) leads to increased air flow resistance

https://t.me/USMLEWorldStep1

stiffness.

- **Airflow resistance** is the opposition to airflow created by limited airway diameter and turbulent airflow; it is increased at higher respiratory rates (due to faster airflow with increased turbulence) and at low lung volumes (due to reduced airway diameter). **Obstructive lung diseases** (eg, asthma, chronic obstructive pulmonary disease) increase airflow resistance due to bronchoconstriction and/or airway collapse.

To reduce the WOB, the tidal volume and respiratory rate are optimized by the respiratory control centers. In patients with **restrictive lung disease**, the WOB is minimized when the tidal volume is low. Therefore, to compensate for low lung volumes, **rapid**, **shallow breathing** is favored (as in this patient). In contrast, in patients who have obstructive lung disease, the WOB is minimized with lower respiratory rates and higher tidal volumes (ie, relatively slow, deep breathing) **(Choice C)**.

(Choice A) Alpha-1 antitrypsin deficiency causes panacinar emphysema, a type of chronic obstructive pulmonary disease. This causes increased airflow resistance, and slow, deep breaths will be favored to minimize the WOB.

(Choice B) Anxiety disorders (eg, panic attacks) are occasionally associated with rapid, shallow breathing; however, the lungs function normally and, therefore, the WOB versus the respiratory rate curve is normal. Because the breathing rate is higher than the normal optimal rate, the work done against airflow resistance (and total work) is increased.

(Choice D) A fixed upper airway obstruction (eg, caused by a large goiter) leads to increased air flow resistance and favors slow, deep breaths to minimize the WOB.

Educational objective:
The work of breathing is minimized in patients with increased elastic resistance (eg, pulmonary fibrosis) when their respiratory rate is high and tidal volume is low (fast, shallow breaths). In contrast, patients with diseases that increase airflow resistance (eg, asthma, chronic obstructive pulmonary disease) breathe at a lower respiratory rate and higher tidal volume (slow, deep breaths) to minimize the work of breathing.

https://t.me/USMLEWorldStep1

A 53-year-old man comes to the office due to an 8-month history of progressive shortness of breath that peaks during strenuous activity. Several of his coworkers have experienced similar symptoms. His medical history includes hypertension and type 2 diabetes mellitus. Pulmonary examination reveals diffuse fine crackles. Chest x-ray reveals nodular densities in both lungs that are most prominent in the apical regions. Calcification of the hilar lymph nodes is also seen. Bronchoscopy with transbronchial biopsy of a calcified node is performed, and polarized microscopy shows birefringent particles surrounded by dense collagen fibers. This patient most likely has a history of exposure to which of the following substances?

- A. Asbestos
- B. Beryllium
- C. Coal dust
- D. Organic dust
- E. Silica

Submit

https://t.me/USMLEWorldStep1

A 53-year-old man comes to the office due to an 8-month history of progressive shortness of breath that peaks during strenuous activity. Several of his coworkers have experienced similar symptoms. His medical history includes hypertension and type 2 diabetes mellitus. Pulmonary examination reveals diffuse fine crackles. Chest x-ray reveals nodular densities in both lungs that are most prominent in the apical regions. Calcification of the hilar lymph nodes is also seen. Bronchoscopy with transbronchial biopsy of a calcified node is performed, and polarized microscopy shows birefringent particles surrounded by dense collagen fibers. This patient most likely has a history of exposure to which of the following substances?

- A. Asbestos (14%)
- ✗ B. Beryllium (11%)
- C. Coal dust (4%)
- D. Organic dust (0%)
- ✓ E. Silica (68%)

Incorrect
Correct answer
E

68%
Answered correctly

03 secs
Time Spent

2023
Version

Explanation

This middle-aged patient with dyspnea on exertion, nodular densities on x-ray, calcified hilar lymph nodes, and birefringent particles on biopsy has silicosis. **Silicosis** is a form of pneumoconiosis (ie, a type of interstitial lung disease caused by inhalation of mineral dust). Inhaled crystalline silica, typically due to **industrial exposure** (eg, mining, sand blasting), is toxic to alveolar macrophages and promotes the formation of intrapulmonary free radicals, leading to progressive lung injury and interstitial collagen deposition. Histologically, silicosis is

https://t.me/USMLEWorldStep1

Explanation

This middle-aged patient with dyspnea on exertion, nodular densities on x-ray, calcified hilar lymph nodes, and birefringent particles on biopsy has silicosis. **Silicosis** is a form of pneumoconiosis (ie, a type of interstitial lung disease caused by inhalation of mineral dust). Inhaled crystalline silica, typically due to **industrial exposure** (eg, mining, sand blasting), is toxic to alveolar macrophages and promotes the formation of intrapulmonary free radicals, leading to progressive lung injury and interstitial collagen deposition. Histologically, silicosis is characterized by **birefringent silicate particles** within dense, **whorled collagenous nodules** surrounded by dust-laden macrophages.

Silicosis is often initially asymptomatic but can present with dyspnea on exertion and productive cough, typically 10-20 years after initial exposure. Radiography varies based on disease progression; simple silicosis typically demonstrates numerous small, **rounded nodules** predominant in the **upper lobes** that may rarely coalesce to form mass-like upper lobe fibrosis (progressive massive fibrosis). Calcification of the rim of hilar nodes (**eggshell calcification**) may also be seen.

(Choice A) Asbestosis can present with dyspnea on exertion, but chest x-ray is more likely to reveal an interstitial pattern of involvement most prominent in the lower zones. Pleural plaques may also be noted. Histology shows ferruginous bodies featuring fusiform rods with a translucent asbestos center and a golden-brown iron coating.

(Choice B) Berylliosis may present with dyspnea and ill-defined nodular or irregular opacities on chest x-ray. Histology reveals noncaseating epithelioid granulomas without obvious associated particles.

(Choice C) Coal worker's pneumoconiosis can present with exertional dyspnea and nodular interstitial opacities on chest x-ray. Histology of nodal and perilymphatic lung tissue shows accumulations of black, carbon-laden macrophages (coal macules).

(Choice D) Inhalation of organic dusts can cause hypersensitivity pneumonitis. Patients have exertional dyspnea

https://t.me/USMLEWorldStep1

radicals, leading to progressive lung injury and interstitial collagen deposition. Histologically, silicosis is characterized by **birefringent silicate particles** within dense, **whorled collagenous nodules** surrounded by dust-laden macrophages.

Silicosis is often initially asymptomatic but can present with dyspnea on exertion and productive cough, typically 10-20 years after initial exposure. Radiography varies based on disease progression; simple silicosis typically demonstrates numerous small, **rounded nodules** predominant in the **upper lobes** that may rarely coalesce to form mass-like upper lobe fibrosis (progressive massive fibrosis). Calcification of the rim of hilar nodes (**eggshell calcification**) may also be seen.

(Choice A) Asbestosis can present with dyspnea on exertion, but chest x-ray is more likely to reveal an interstitial pattern of involvement most prominent in the lower zones. Pleural plaques may also be noted. Histology shows ferruginous bodies featuring fusiform rods with a translucent asbestos center and a golden-brown iron coating.

(Choice B) Berylliosis may present with dyspnea and ill-defined nodular or irregular opacities on chest x-ray. Histology reveals noncaseating epithelioid granulomas without obvious associated particles.

(Choice C) Coal worker's pneumoconiosis can present with exertional dyspnea and nodular interstitial opacities on chest x-ray. Histology of nodal and perilymphatic lung tissue shows accumulations of black, carbon-laden macrophages (coal macules).

(Choice D) Inhalation of organic dusts can cause hypersensitivity pneumonitis. Patients have exertional dyspnea and diffuse interstitial infiltrates on chest x-ray. Histology of nodal tissue may reveal noncaseating granulomas.

Educational objective:
Silicosis is characterized by dyspnea and productive cough occurring years after inhalational exposure to crystalline silica. Histologically, it is characterized by birefringent silicate particles within dense, whorled collagenous nodules surrounded by dust-laden macrophages. Radiography typically demonstrates numerous small, rounded nodules predominant in the upper lobes; calcification of the rim of hilar nodes (eggshell calcification) may also be seen.

https://t.me/USMLEWorldStep1

birefringent particles on biopsy has silicosis. **Silicosis** is a form of pneumoconiosis (ie, a type of interstitial lung

Exhibit Display

Silicosis (chronic)

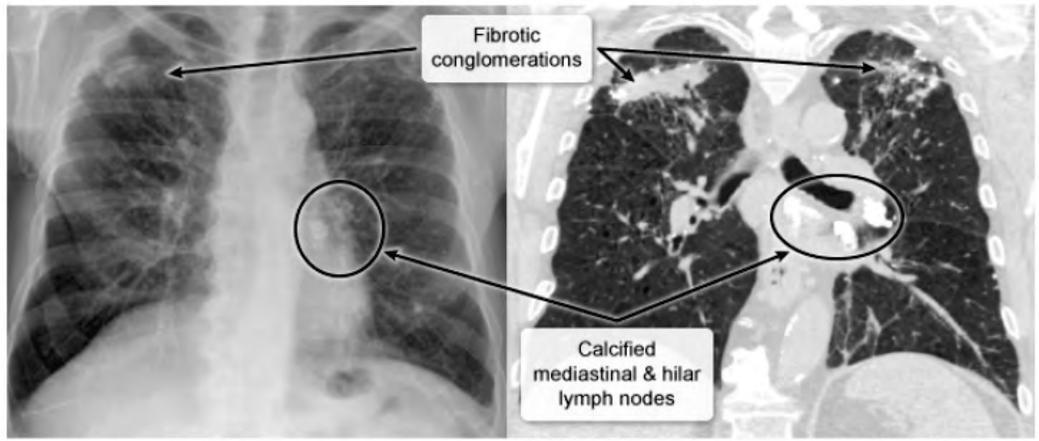

Confluent upper lobe fibrotic conglomerations & calcified lymph nodes in a patient with progressive massive fibrosis due to occupational silica exposure.

©UWorld

Zoom In | Zoom Out | Reset | New | Existing | My Notebook

crystalline silica. Histologically, it is characterized by birefringent silicate particles within dense, whorled

https://t.me/USMLEWorldStep1

birefringent particles on biopsy has silicosis. **Silicosis** is a form of pneumoconiosis (ie, a type of interstitial lung disease caused by inhalation of mineral dust). Inhaled crystalline silica, typically due to **industrial exposure** (eg, mining, sand b
radicals, leadin
characterized b
laden macroph

Silicosis is ofte
10-20 years af
demonstrates r
form mass-like
calcification)

(Choice A) As
pattern of invol
ferruginous bo

(Choice B) Be
Histology revea

(Choice C) Co
on chest x-ray.
macrophages (

(Choice D) In
and diffuse inte

Educational o
Silicosis is cha
crystalline silic

Exhibit Display

Asbestosis

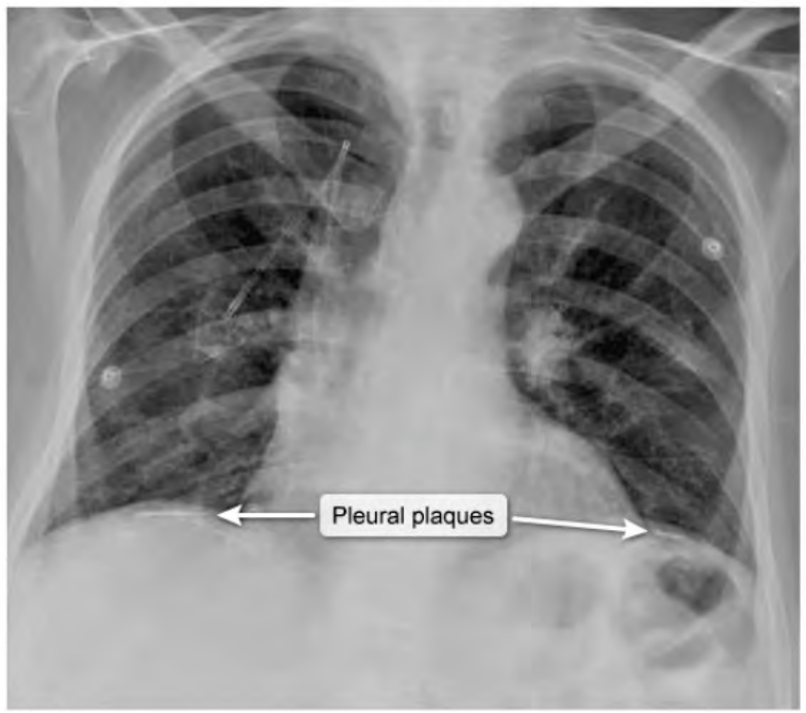

©UWorld

Zoom In | Zoom Out | Reset | New | Existing | My Notebook

https://t.me/USMLEWorldStep1

birefringent particles on biopsy has silicosis. **Silicosis** is a form of pneumoconiosis (ie, a type of interstitial lung

Exhibit Display

Berylliosis

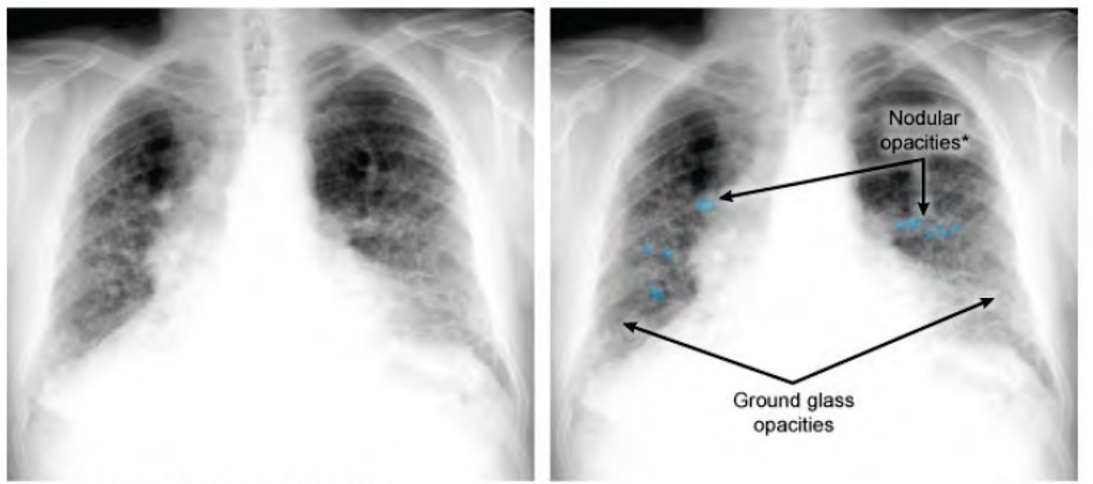

*Typically arise from noncaseating granulomas.

©UWorld

Zoom In | Zoom Out | Reset | New | Existing | My Notebook

crystalline silica. Histologically, it is characterized by birefringent silicate particles within dense, whorled

https://t.me/USMLEWorldStep1

birefringent particles on biopsy has silicosis. **Silicosis** is a form of pneumoconiosis (ie, a type of interstitial lung

Exhibit Display

Chronic hypersensitivity pneumonitis

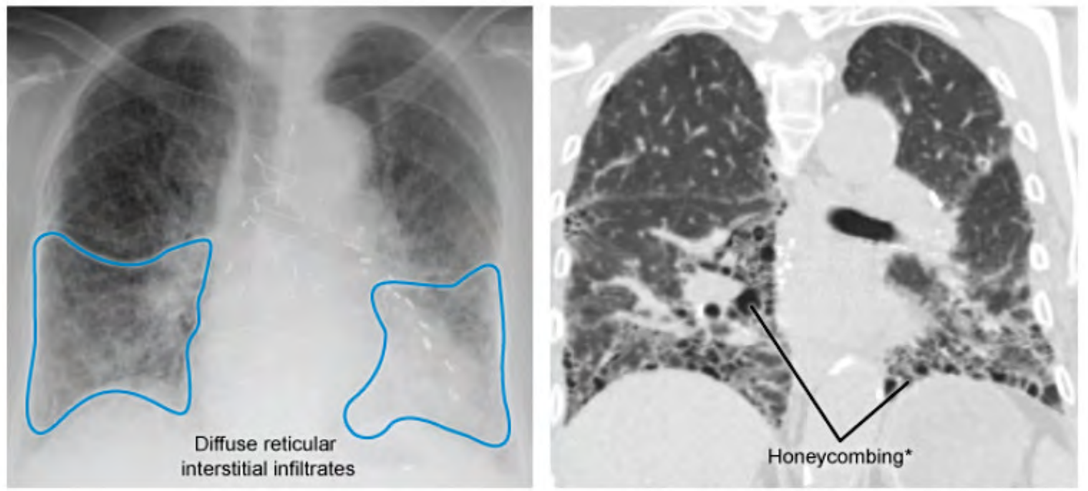

Chest x-ray

CT scan (coronal view)

*Fibrosis resulting from chronic bronchial and peribronchial inflammation.

©UWorld

Zoom In | Zoom Out | Reset | New | Existing | My Notebook

crystalline silica. Histologically, it is characterized by birefringent silicate particles within dense, whorled

https://t.me/USMLEWorldStep1

An autopsy is performed on a patient who died of respiratory failure, and a sample of the patient's lung tissue is obtained. Analysis of several large, cuboidal alveolar cells under electron microscopy reveals decreased numbers of granules containing parallel stacks of membrane lamellae. Which of the following pathological processes is most likely associated with this patient's findings?

- A. Alveolar wall destruction by protease
- B. Bronchial smooth muscle hyperresponsiveness
- C. Excessive airway mucus production
- D. Increased alveolar tendency to collapse
- E. Pulmonary arterial occlusion by thromboembolism

Submit

https://t.me/USMLEWorldStep1

An autopsy is performed on a patient who died of respiratory failure, and a sample of the patient's lung tissue is obtained. Analysis of several large, cuboidal alveolar cells under electron microscopy reveals decreased numbers of granules containing parallel stacks of membrane lamellae. Which of the following pathological processes is most likely associated with this patient's findings?

- A. Alveolar wall destruction by protease (29%)
- ✗ B. Bronchial smooth muscle hyperresponsiveness (6%)
- C. Excessive airway mucus production (10%)
- ✓ D. Increased alveolar tendency to collapse (51%)
- E. Pulmonary arterial occlusion by thromboembolism (3%)

Incorrect
Correct answer
D

51%
Answered correctly

03 secs
Time Spent

2023
Version

Explanation

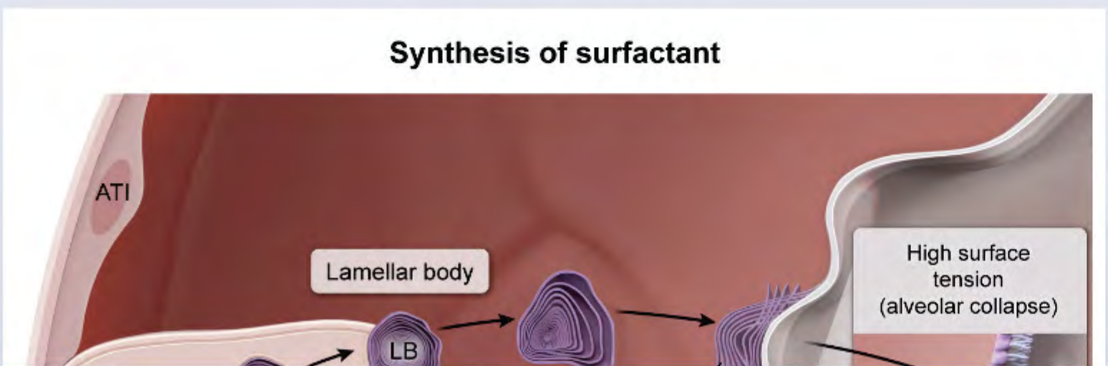

https://t.me/USMLEWorldStep1

Exhibit Display

Synthesis of surfactant

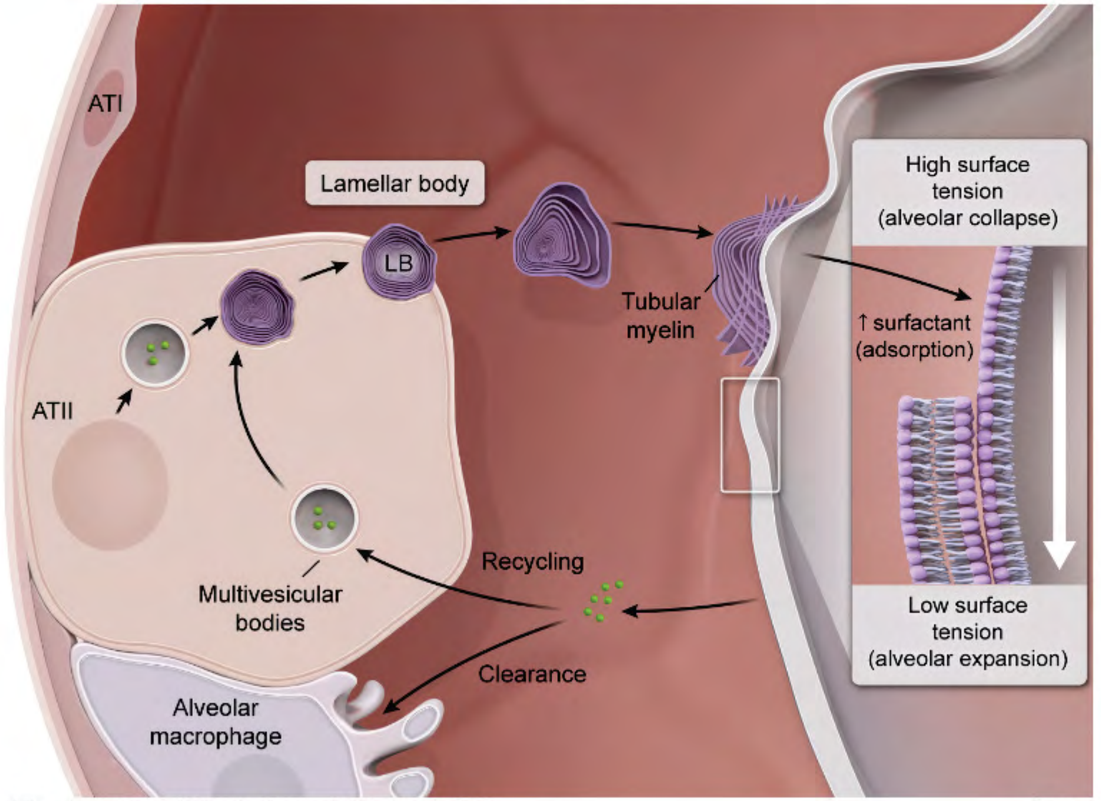

ATI = alveolar type I; **ATII** = alveolar type II; **LB** = lamellar body.

©UWorld

Zoom In | Zoom Out | Reset | New | Existing | My Notebook

This
cond

Normally, type II pneumocytes use lamellar bodies to **store surfactant**, a substance composed of proteins and

https://t.me/USMLEWorldStep1

ATI = alveolar type I; **ATII** = alveolar type II; **LB** = lamellar body. ©UWorld

This patient with respiratory failure was found to have decreased **lamellar bodies**, which are organelles with concentric sheets of lipid membrane, within type II pneumocytes (cuboidal alveolar cells).

Normally, type II pneumocytes use lamellar bodies to **store surfactant**, a substance composed of proteins and phospholipids that **decreases alveolar surface tension** and facilitates lung expansion during respiration. This lipoprotein complex is released from the lamellar bodies by exocytosis into the alveolar spaces, where the lamellar contents unravel into a structured array called tubular myelin. This lattice network adsorbs to the air-liquid interface of the alveoli and spreads along the alveolar lining, forming a surfactant film. As the film degrades, surfactant is recycled back into type II pneumocytes by endocytosis for reprocessing.

Surfactant and the number of lamellar bodies in the fetus rise during the late second and the third trimesters. Therefore, a **low lamellar body count** reflects surfactant deficiency and **lung immaturity**, which typically occurs in premature infants with **neonatal respiratory distress syndrome**. In this condition, alveolar surface tension increases and **alveoli collapse**. Diffuse atelectasis can lead to respiratory failure within minutes to hours after birth and, in severe cases, death.

(Choice A) Emphysema is caused by alveolar wall destruction due to excessive activity of intra-alveolar proteases released by neutrophils and alveolar macrophages. Decreased lamellar bodies within type II pneumocytes would not be seen.

(Choice B) Asthma is characterized by bronchial smooth muscle hyperresponsiveness, and histology typically shows inflammatory cell (eg, eosinophil) infiltration and bronchial smooth muscle hypertrophy. A deficiency of lamellar bodies and surfactant does not cause bronchoconstriction.

(Choice C) Chronic bronchitis manifests as excessive mucus production in the airways and increased inflammatory cells in the submucosa; lamellar body counts would not be affected.

(Choice E) A pulmonary embolism appears on histology as organized layers of red cells, platelets, and fibrin within pulmonary arterial vasculature that is surrounded by ischemic lung changes. Decreased lamellar bodies

https://t.me/USMLEWorldStep1

lipoprotein complex is released from the lamellar bodies by exocytosis into the alveolar spaces, where the lamellar contents unravel into a structured array called tubular myelin. This lattice network adsorbs to the air-liquid interface of the alveoli and spreads along the alveolar lining, forming a surfactant film. As the film degrades, surfactant is recycled back into type II pneumocytes by endocytosis for reprocessing.

Surfactant and the number of lamellar bodies in the fetus rise during the late second and the third trimesters. Therefore, a **low lamellar body count** reflects surfactant deficiency and **lung immaturity**, which typically occurs in premature infants with **neonatal respiratory distress syndrome**. In this condition, alveolar surface tension increases and **alveoli collapse**. Diffuse atelectasis can lead to respiratory failure within minutes to hours after birth and, in severe cases, death.

(Choice A) Emphysema is caused by alveolar wall destruction due to excessive activity of intra-alveolar proteases released by neutrophils and alveolar macrophages. Decreased lamellar bodies within type II pneumocytes would not be seen.

(Choice B) Asthma is characterized by bronchial smooth muscle hyperresponsiveness, and histology typically shows inflammatory cell (eg, eosinophil) infiltration and bronchial smooth muscle hypertrophy. A deficiency of lamellar bodies and surfactant does not cause bronchoconstriction.

(Choice C) Chronic bronchitis manifests as excessive mucus production in the airways and increased inflammatory cells in the submucosa; lamellar body counts would not be affected.

(Choice E) A pulmonary embolism appears on histology as organized layers of red cells, platelets, and fibrin within pulmonary arterial vasculature that is surrounded by ischemic lung changes. Decreased lamellar bodies within type 2 pneumocytes would not be seen.

Educational objective:
Lamellar bodies of type II pneumocytes store and release surfactant, which decreases alveolar surface tension and facilitates lung expansion. A low lamellar body count reflects surfactant deficiency and lung immaturity, as in neonatal respiratory distress syndrome, which results in alveolar collapse and diffuse atelectasis.

https://t.me/USMLEWorldStep1

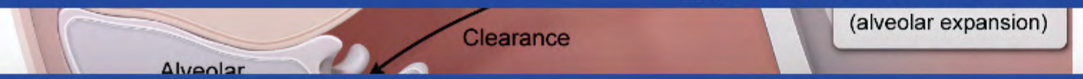

Exhibit Display

Alveoli

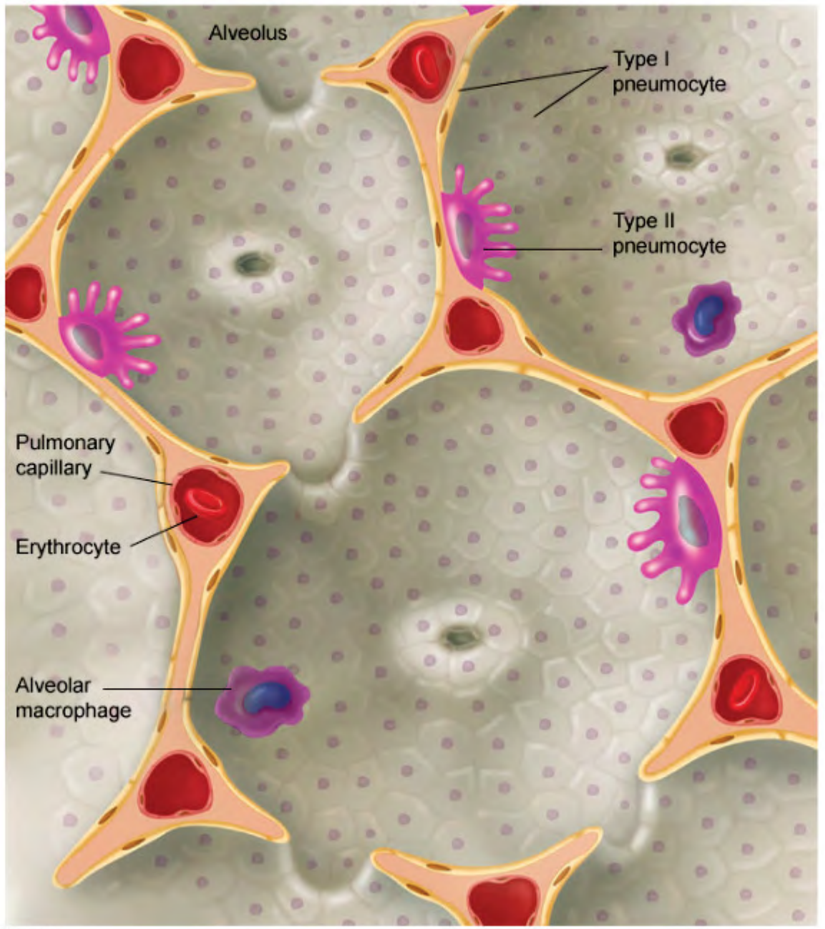

Zoom In | Zoom Out | Reset | New | Existing | My Notebook

This patient wi
concentric she

Normally, type
phospholipids
lipoprotein com
contents unrav
of the alveoli a
recycled back

Surfactant and
Therefore, a **lo**
in premature ir
increases and
birth and, in se

(Choice A) Er
released by ne
not be seen.

(Choice B) As
shows inflamm
lamellar bodies

(Choice C) Ch

https://t.me/USMLEWorldStep1

A 66-year-old woman is evaluated in the clinic for worsening shortness of breath over the last year. She has no previous medical problems and is a lifelong nonsmoker. Blood pressure is 126/78 mm Hg, pulse is 82/min, and respirations are 18/min. BMI is 23 kg/m^2. Physical examination shows a normal oropharynx, flat neck veins, and a midline trachea. Diaphragmatic excursion is decreased bilaterally. Lung auscultation reveals bilateral fine inspiratory crackles. Arterial blood gas analysis is performed while the patient is at rest and after a vigorous walk for several minutes. Arterial partial pressure of oxygen is normal at rest but falls significantly with exercise. Which of the following exercise-related changes is most likely contributing to the latter observation in this patient?

- A. Improved ventilation-perfusion mismatch
- B. Increased alveolar ventilation
- C. Increased pulmonary blood flow
- D. Increased pulmonary capillary recruitment

Submit

https://t.me/USMLEWorldStep1

A 66-year-old woman is evaluated in the clinic for worsening shortness of breath over the last year. She has no previous medical problems and is a lifelong nonsmoker. Blood pressure is 126/78 mm Hg, pulse is 82/min, and respirations are 18/min. BMI is 23 kg/m^2. Physical examination shows a normal oropharynx, flat neck veins, and a midline trachea. Diaphragmatic excursion is decreased bilaterally. Lung auscultation reveals bilateral fine inspiratory crackles. Arterial blood gas analysis is performed while the patient is at rest and after a vigorous walk for several minutes. Arterial partial pressure of oxygen is normal at rest but falls significantly with exercise. Which of the following exercise-related changes is most likely contributing to the latter observation in this patient?

- A. Improved ventilation-perfusion mismatch (16%)
- ✗ B. Increased alveolar ventilation (14%)
- ✓ C. Increased pulmonary blood flow (48%)
- D. Increased pulmonary capillary recruitment (20%)

Incorrect
Correct answer
C

48%
Answered correctly

03 secs
Time Spent

2023
Version

Explanation

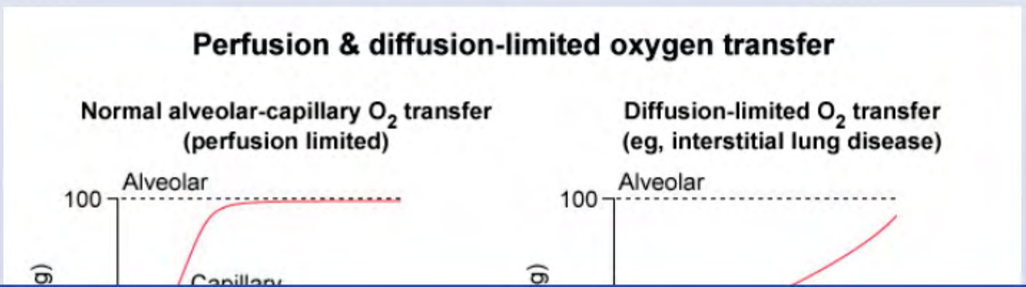

https://t.me/USMLEWorldStep1

Normal alveolar-capillary O_2 transfer Diffusion-limited O_2 transfer

Exhibit Display

Perfusion & diffusion-limited oxygen transfer

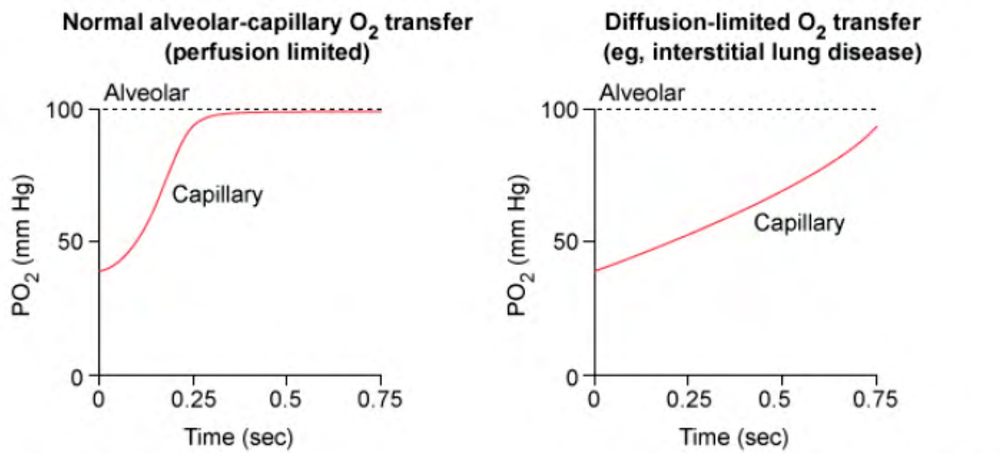

PO_2 = partial pressure of oxygen.

©UWorld

Zoom In Zoom Out Reset New | Existing My Notebook

Oxy
perf
oxyg
with
(ie,

Diff
men
are
bloo
incr
oxyg
exer

(Choices A, B, and D) In healthy individuals, exercise results in increased minute ventilation (ie, product of increased respiratory rate × larger tidal volumes). At the same time, recruitment of apical pulmonary capillaries

https://t.me/USMLEWorldStep1

PO_2 = partial pressure of oxygen.

©UWorld

Oxygen transfer across the alveolar membrane depends on the (1) gas diffusion rate and (2) capillary blood perfusion rate. In healthy lungs, diffusion of oxygen occurs very rapidly: red blood cells become fully saturated with oxygen at only one-third of the total alveolar capillary length. For this reason, oxygen saturation does not fall even with large increases in cardiac output during exercise. In other words, normal oxygen transfer is **perfusion limited** (ie, diffusion is so fast that oxygen transfer depends on the perfusion rate [cardiac output] only).

Diffusion limitation is a mechanism of hypoxia that occurs in diseases that disrupt the alveolar-capillary membrane (eg, emphysema, pulmonary fibrosis). This patient's progressive dyspnea and fine inspiratory crackles are consistent with **interstitial lung disease**. Fibrotic thickening of the interstitial space (between the air and blood) increases the distance that oxygen must cross, limiting the degree of oxygen diffusion. During exercise, the **increase in pulmonary blood flow** accelerates transit through the pulmonary capillaries, reducing the time for oxygen extraction. In patients with diffusion limitation, the increased blood flow during exercise can result in **exertional hypoxemia**, even if oxygenation is normal at rest.

(Choices A, B, and D) In healthy individuals, exercise results in increased minute ventilation (ie, product of increased respiratory rate × larger tidal volumes). At the same time, recruitment of apical pulmonary capillaries (increased perfusion) promotes continued ventilation/perfusion (V/Q) matching as ventilation increases. This remarkably stable V/Q matching during exercise enhances oxygen exchange, preventing hypoxemia.

Educational objective:
Diffusion of oxygen across the alveolar-capillary membrane is normally very rapid. Decreased diffusion rate (eg, interstitial lung disease) can lead to diffusion-limited oxygen transfer, especially when the perfusion rate increases (eg, exertion).

References

- Physiology, pulmonary, ventilation and perfusion.

https://t.me/USMLEWorldStep1

Time (sec) Time (sec)

Exhibit Display

Oxy
perf
oxyg
with
(ie,

Diff
men
are
bloo
incr
oxyg
exe

(Ch
incre
(incr
rema

Edu
Diffu
inter
(eg,

Refe

- Physiology, pulmonary, ventilation and perfusion.

Perfusion & diffusion-limited oxygen transfer

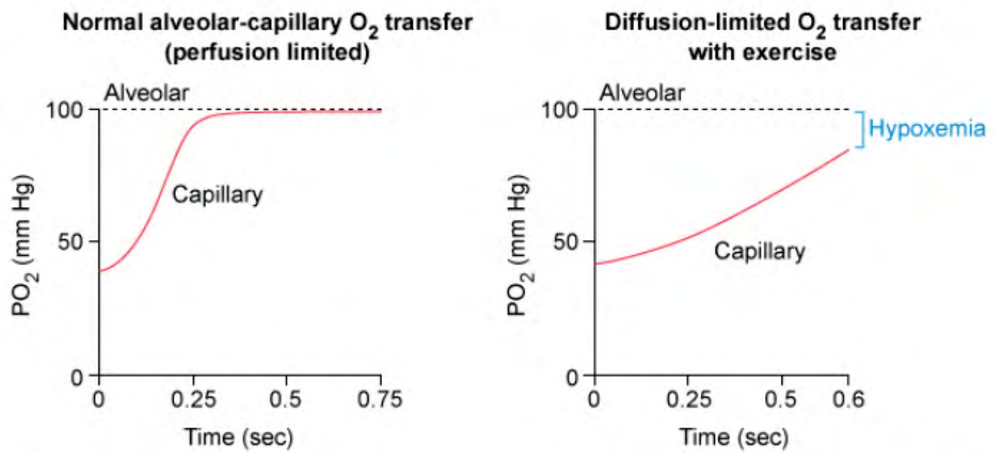

PO_2 = partial pressure of oxygen.

©UWorld

Zoom In Zoom Out Reset New | Existing My Notebook

https://t.me/USMLEWorldStep1

A 48-year-old man is evaluated for shortness of breath and dry cough for 1 week. The patient has never had similar symptoms in the past and takes no medications. He has a 5-pack-year smoking history and does not use alcohol or illicit drugs. The patient is a pig farmer in Ohio and has not traveled recently. Temperature is 37.8 C (100 F), blood pressure is 128/85 mm Hg, pulse is 95/min, and respirations are 16/min. Lung auscultation reveals scattered wheezing and crackles. Peripheral blood smear is shown below.

The nucleated cells seen on this patient's peripheral smear most likely perform which of the following functions?

- A. Bacterial opsonization
- B. Destruction of helminths
- C. Inhibition of fungal growth
- D. Killing of virus-infected cells
- E. Stimulation of fibroblasts

Submit

https://t.me/USMLEWorldStep1

A 48 [illegible]
simi
alco
(100
scat

Exhibit Display

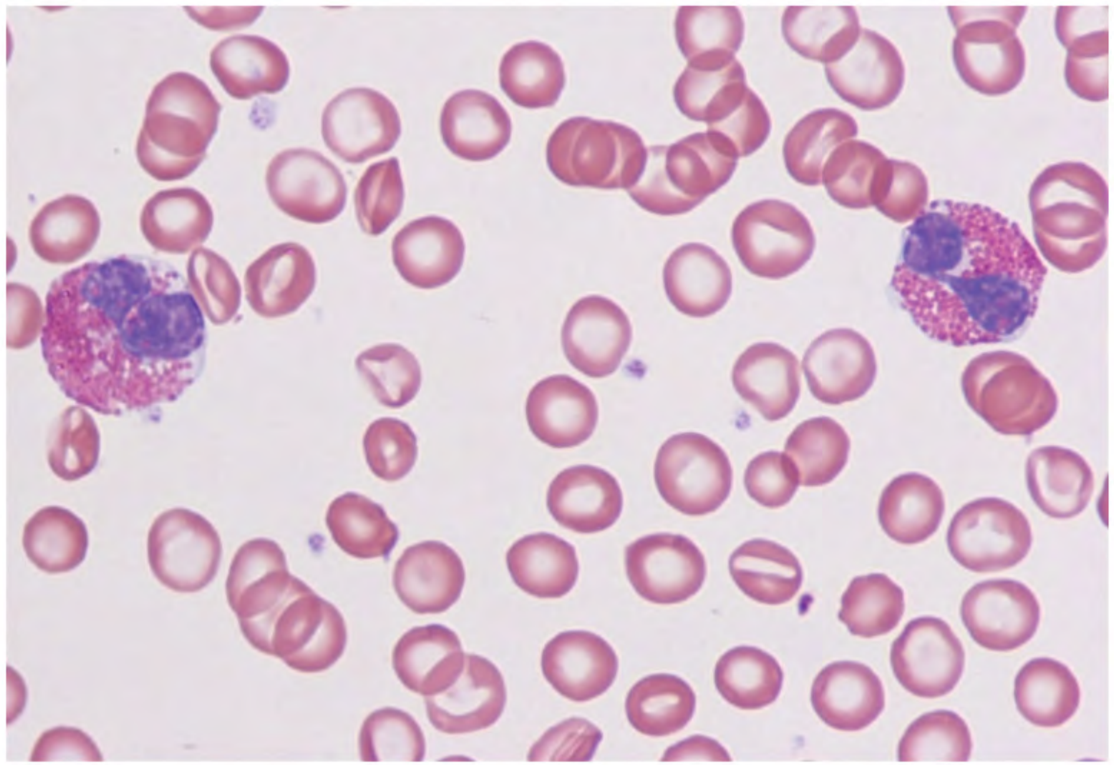

Zoom In | Zoom Out | Reset | New | Existing | My Notebook

The

A. Bacterial opsonization

https://t.me/USMLEWorldStep1

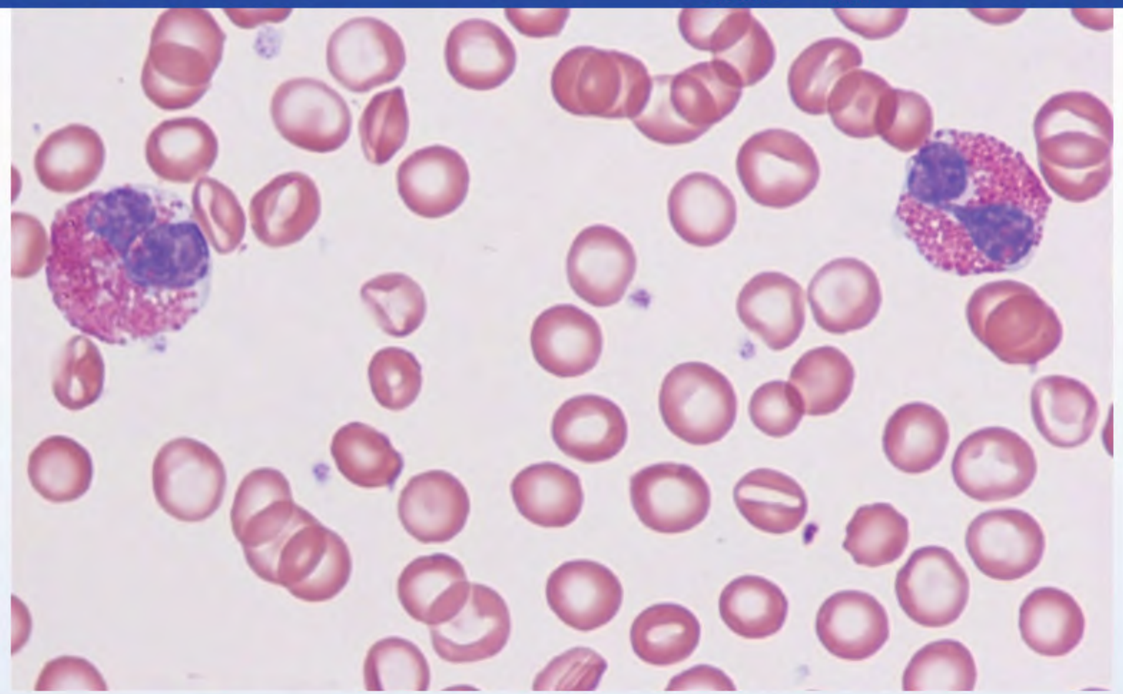

The nucleated cells seen on this patient's peripheral smear most likely perform which of the following functions?

- A. Bacterial opsonization
- B. Destruction of helminths
- C. Inhibition of fungal growth
- D. Killing of virus-infected cells
- E. Stimulation of fibroblasts

Submit

https://t.me/USMLEWorldStep1

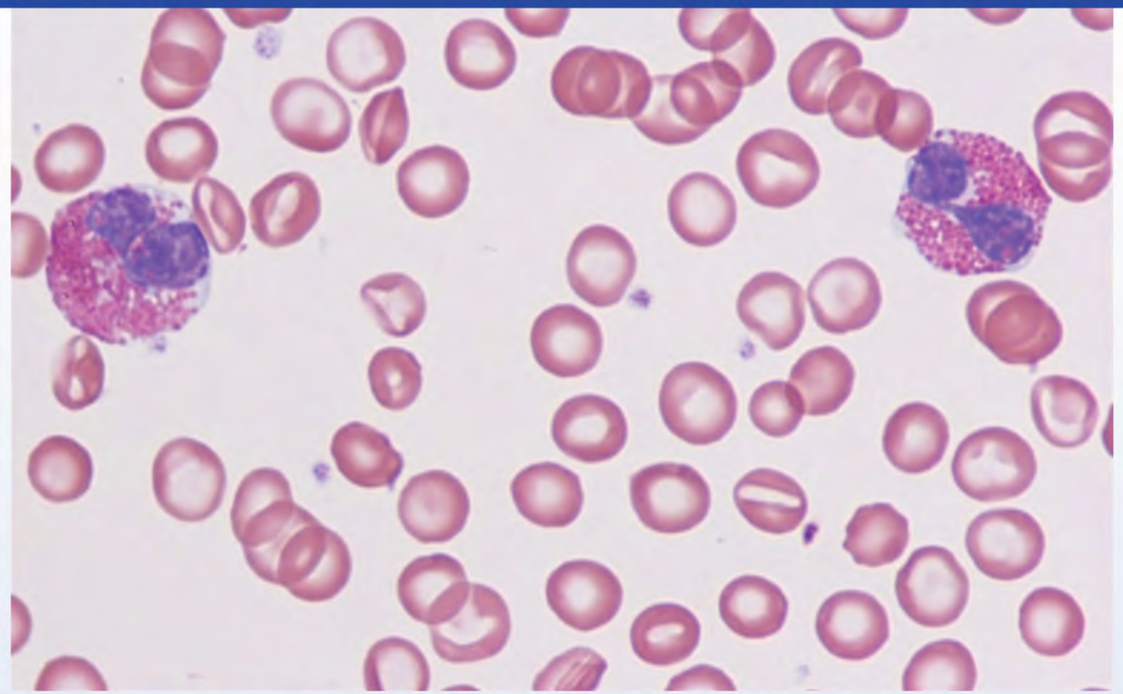

The nucleated cells seen on this patient's peripheral smear most likely perform which of the following functions?

- A. Bacterial opsonization (10%)
- ✓ B. Destruction of helminths (72%)
- C. Inhibition of fungal growth (10%)
- D. Killing of virus-infected cells (3%)
- E. Stimulation of fibroblasts (3%)

Correct

72% Answered correctly

12 secs Time Spent

2023 Version

https://t.me/USMLEWorldStep1

Explanation

This patient's presentation is concerning for **Loeffler syndrome**, a transient eosinophilic pneumonitis (eg, dry cough, dyspnea, wheezing) caused by migration of parasitic roundworm larva (eg, *Ascaris suum* from pigs) through the lungs. His peripheral smear shows numerous erythrocytes and a few scattered platelets accompanied by 2 larger cells with **bilobed nuclei** and **eosinophilic granules**; the 2 larger cells are **eosinophils**.

Eosinophils play a prominent role in allergic disease (eg, asthma, drug reactions) and in defense against parasitic infection. **Major basic protein** is the predominant substance contained within eosinophilic granules, and it acts as a potent toxin against **helminths** (parasitic worms). Release of major basic protein by eosinophils causes damage to epithelial and endothelial cells and is a major mechanism of chronic lung damage in certain pulmonary conditions (eg, **asthma**, *Ascaris* infection).

(Choice A) Plasma cells produce antibodies that opsonize bacteria to facilitate phagocytosis.

(Choice C) Pattern recognition receptors (eg, dectin-1) on phagocytic cells allow for detection and destruction of fungi by the innate immune system.

(Choice D) Virus-infected cells typically lack MHC class I proteins on their surface; these cells are identified and killed by natural killer cells.

(Choice E) Macrophages secrete transforming growth factor-beta (TGF-β), which stimulates fibroblasts to release collagen and form scar tissue.

Educational objective:
Eosinophils have bilobed nuclei and numerous eosinophilic granules in the cytoplasm and are important in allergic disease and defense against parasitic infection. The eosinophilic granules predominantly contain major basic protein, which acts as a potent antihelminthic toxin. Major basic protein also damages epithelial and endothelial cells and is a major cause of chronic lung damage in asthma.

https://t.me/USMLEWorldStep1

Explanation

This
coug
throu
by 2

Eosi
infec
a po
to ep
conc

(Che

(Che
fung

(Che
kille

(Che
colla

Edu
Eosi
dise
prot
cells

Exhibit Display

Eosinophils

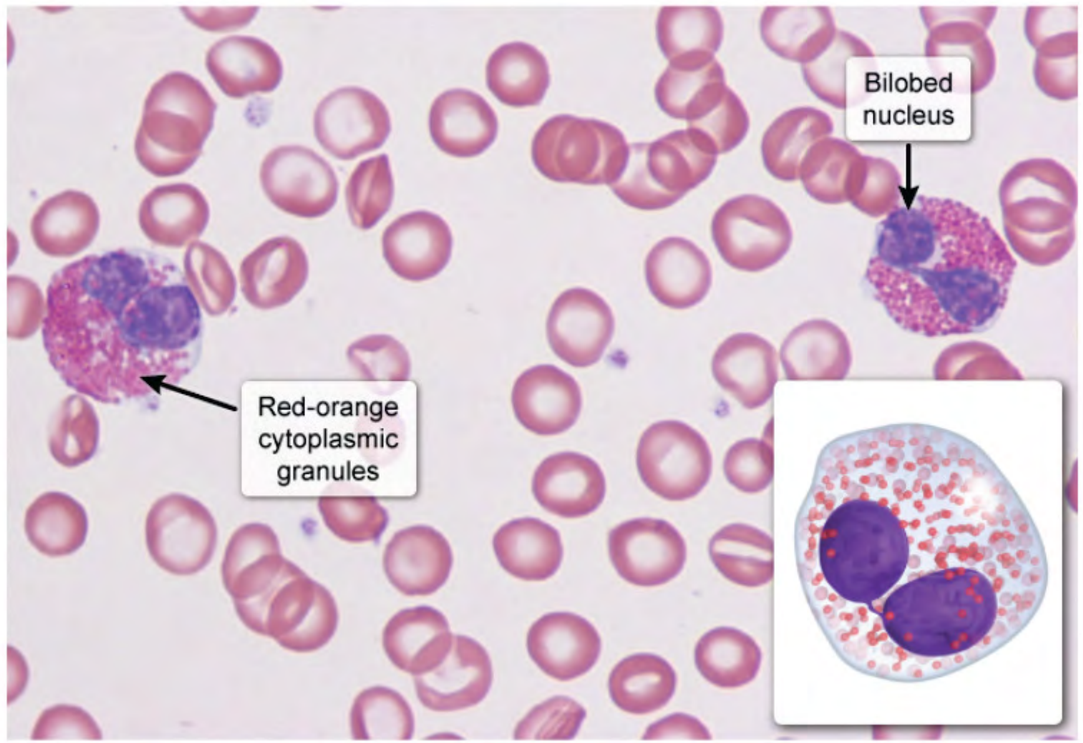

©UWorld

Zoom In | Zoom Out | Reset | New | Existing | My Notebook

https://t.me/USMLEWorldStep1

A 34-year-old man is evaluated due to dyspnea. The patient undergoes complete pulmonary function testing as well as lung volume measurements. His pulmonary volume curve (blue line) is compared with a normal individual's curve (black line) in the illustration below:

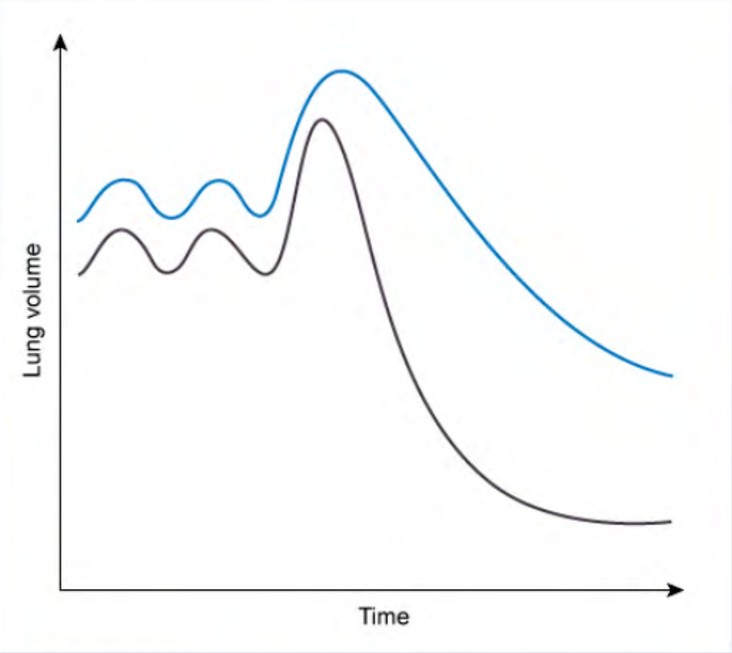

Which of the following measures is increased in this patient?

- A. Expiratory reserve volume
- B. Forced expiratory volume in 1 second
- C. Forced expiratory volume in 1 second/forced vital capacity ratio
- D. Forced vital capacity
- E. Residual volume/total lung capacity ratio

https://t.me/USMLEWorldStep1

A 34 [illegible]
well
curv

Exhibit Display

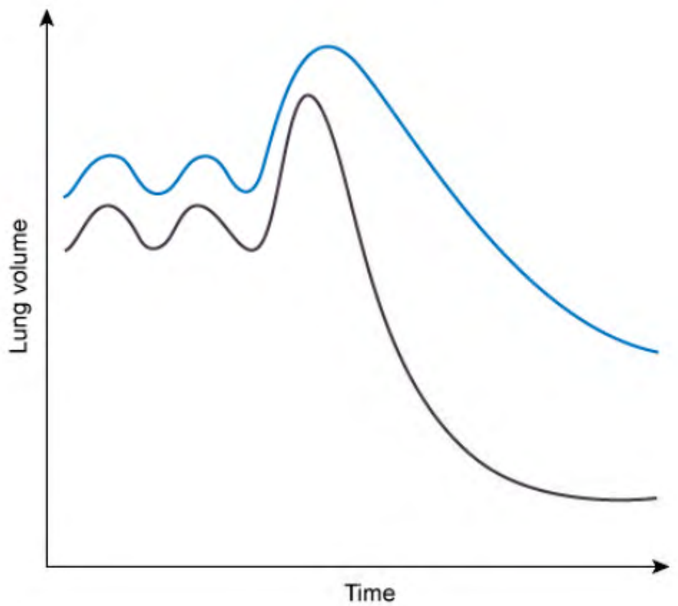

Zoom In Zoom Out Reset New | Existing My Notebook

Whi

[illegible]

E. Residual volume/total lung capacity ratio

https://t.me/USMLEWorldStep1

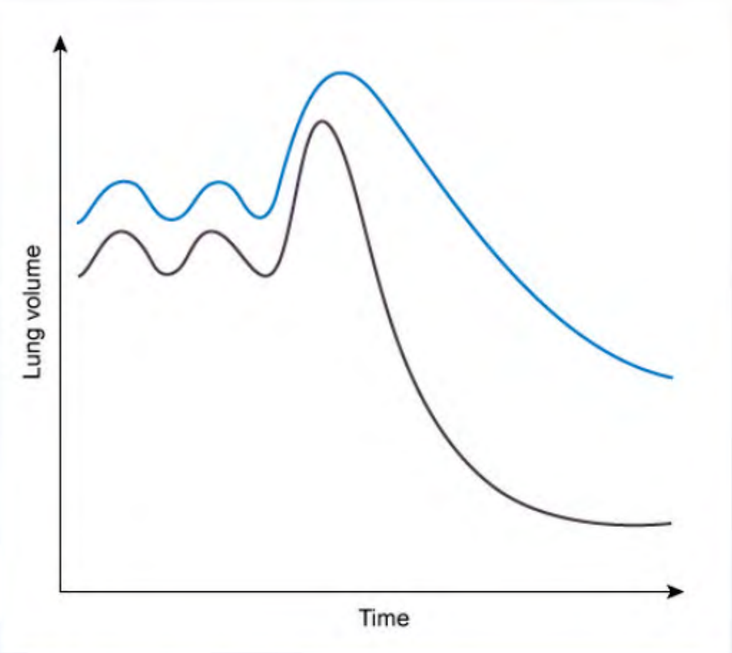

Which of the following measures is increased in this patient?

- A. Expiratory reserve volume
- B. Forced expiratory volume in 1 second
- C. Forced expiratory volume in 1 second/forced vital capacity ratio
- D. Forced vital capacity
- E. Residual volume/total lung capacity ratio

Submit

https://t.me/USMLEWorldStep1

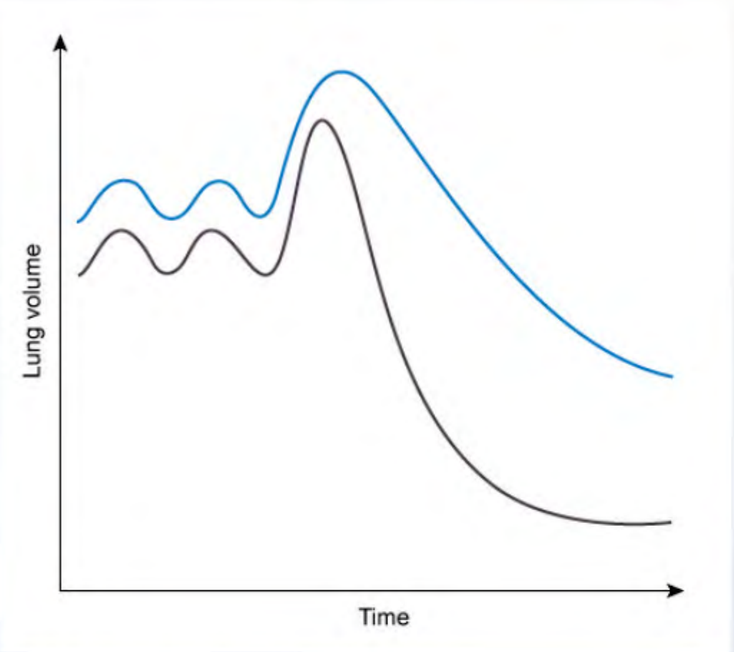

Which of the following measures is increased in this patient?

- A. Expiratory reserve volume (22%)
- ✕ B. Forced expiratory volume in 1 second (3%)
- C. Forced expiratory volume in 1 second/forced vital capacity ratio (9%)
- D. Forced vital capacity (7%)
- ✓ E. Residual volume/total lung capacity ratio (56%)

Incorrect
Correct answer
E

56%
Answered correctly

13 secs
Time Spent

2023
Version

https://t.me/USMLEWorldStep1

B. Forced expiratory volume in 1 second (3%)

Exhibit Display

Normal & COPD respiration curves

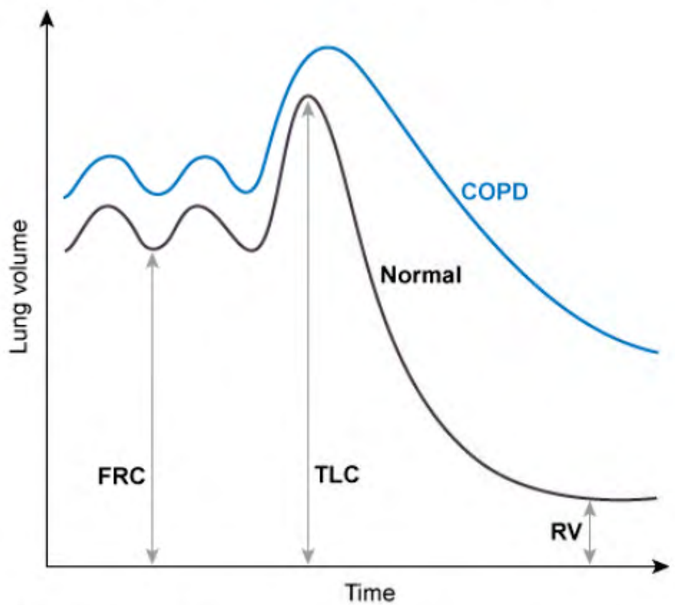

COPD = chronic obstructive pulmonary disease; **FRC** = functional residual capacity; **RV** = residual volume; **TLC** = total lung capacity.

©UWorld

Zoom In | Zoom Out | Reset | New | Existing | My Notebook

Time

https://t.me/USMLEWorldStep1

B. Forced expiratory volume in 1 second (3%)

Exhibit Display

Normal & COPD respiration curves

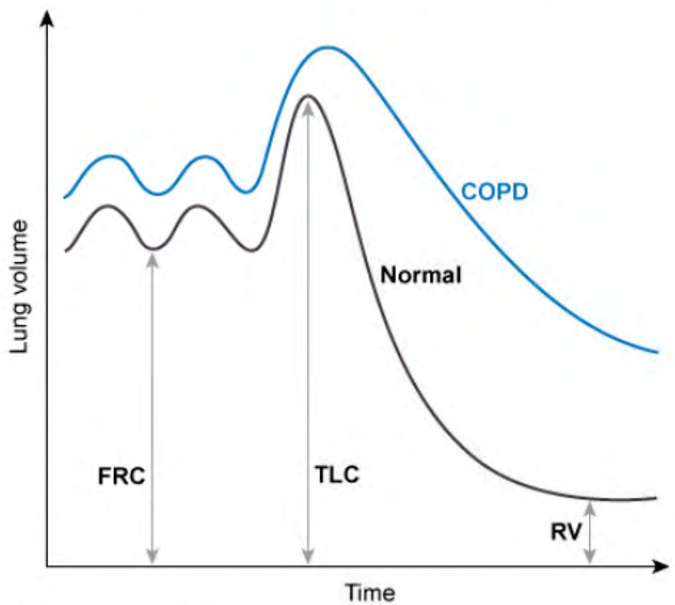

COPD = chronic obstructive pulmonary disease; **FRC** = functional residual capacity; **RV** = residual volume; **TLC** = total lung capacity.

©UWorld

Zoom In | Zoom Out | Reset | New | Existing | My Notebook

Time

https://t.me/USMLEWorldStep1

©UWorld

The graph compares the **respiration curve** for a normal, healthy individual (black line) and this patient (blue line), who most likely has chronic obstructive pulmonary disease (**COPD**); the tracings show resting breaths along with a maximal air intake and expulsion effort. In a resting breath, a single tidal volume (TV) is exchanged. With maximal inhalation, the curve includes both the TV and the inspiratory reserve volume (IRV), which together equal the inspiratory capacity. With maximal exhalation, the curve reflects the expulsion of the IRV and the TV, as well as the amount of additional air that can be expired, which is the expiratory reserve volume (ERV). The air remaining in the lungs following full exhalation is the residual volume (RV).

In patients with COPD, the **RV is substantially increased** due to air trapping (eg, small airway collapse, mucous plugs) within floppy/inflamed airways. The total lung capacity (**TLC**) can also increase over time due to emphysematous destruction of the lung parenchyma (with resulting expansion of alveolar airspaces), but this occurs primarily in advanced disease and to a **lesser extent** than the increase in RV (resulting in an **increased RV/TLC ratio**). Increased airflow resistance and decreased pulmonary elastic recoil further contribute to hyperinflation of the lungs, causing COPD patients to breathe at higher baseline lung volumes (**higher FRC**).

(Choice A) ERV is decreased in obstructive lung disease, as less air can be forcefully exhaled due to airway obstruction and collapse.

(Choices B, C, and D) Both forced vital capacity (FVC) and forced expiratory volume in 1 second (FEV1) are decreased in obstructive lung disease due to airway obstruction. Because FEV1 is decreased more than FVC, the FEV1/FVC ratio is also decreased (<0.7 in COPD).

Educational objective:
Chronic obstructive pulmonary disease causes air trapping and hyperinflation; consequently, these patients breathe at higher baseline lung volumes (higher functional residual capacity). The absolute volume of air in the lungs that is not respired (residual volume) increases substantially, as does the fraction of air in the lungs that is not involved in respiration (residual volume/total lung capacity ratio).

https://t.me/USMLEWorldStep1

©UWorld

The graph compares the **respiration curve** for a normal, healthy individual (black line) and this patient (blue line)

who most likely

maximal air int

inhalation, the

inspiratory cap

amount of addi

the lungs follov

In patients with

plugs) within fl

emphysematou

occurs primaril

RV/TLC ratio),

hyperinflation c

(Choice A) EF

obstruction and

(Choices B, C

decreased in c

FEV1/FVC rati

Educational o

Chronic obstru

breathe at high

lungs that is nc

involved in res

Exhibit Display

Lung volumes & capacities

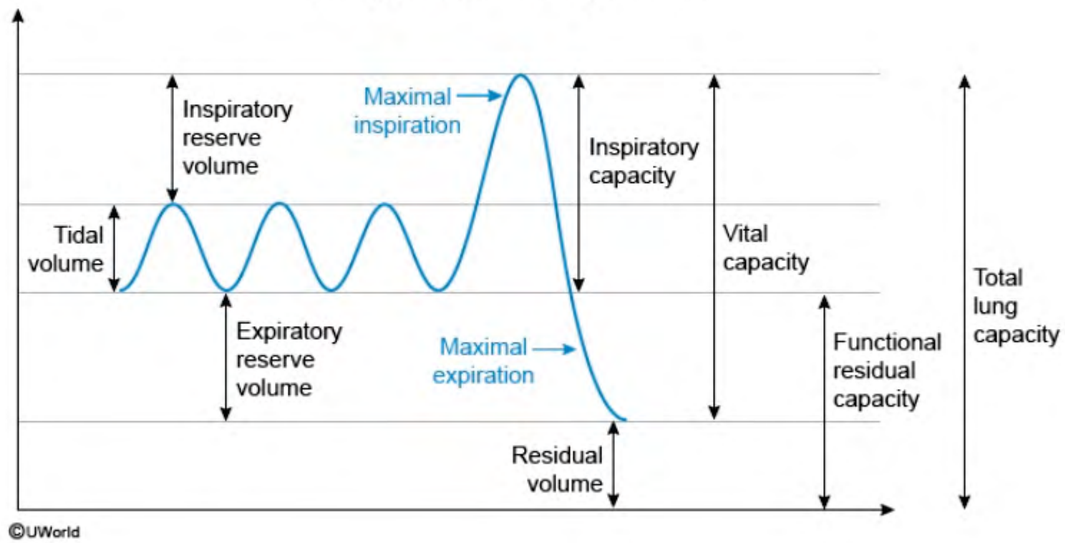

©UWorld

Zoom In | Zoom Out | Reset | New | Existing | My Notebook

https://t.me/USMLEWorldStep1

©UWorld

The graph com... **respiration curve** for a normal, healthy individual (black line) and this patient (blue line)
who most likely...
maximal air int...
inhalation, the ...
inspiratory cap...
amount of addi...
the lungs follov...

In patients with ...
plugs) within flo...
emphysematou...
occurs primaril...
RV/TLC ratio)...
hyperinflation ...

(Choice A) EF...
obstruction and...

(Choices B, C...
decreased in o...
FEV1/FVC rati...

Educational o...
Chronic obstru...
breathe at high...
lungs that is no...
involved in resp...

Exhibit Display

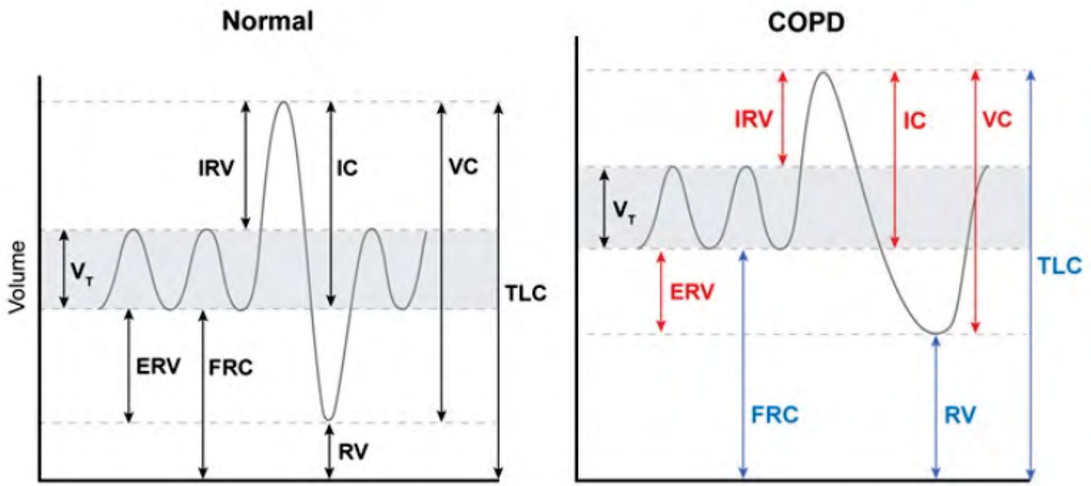

COPD = chronic obstructive pulmonary disease; **ERV** = expiratory reserve volume; **FRC** = functional residual capacity; **IC** = inspiratory capacity; **IRV** = inspiratory reserve volume; **RV** = residual volume; **TLC** = total lung capacity; **VC** = vital capacity; V_T = tidal volume.

©UWorld

Zoom In | Zoom Out | Reset | New | Existing | My Notebook

https://t.me/USMLEWorldStep1

A 26-year-old woman is evaluated for joint pain affecting the elbows, knees, and ankles for the past month. She has also experienced a dry cough and mild shortness of breath over the last 6 months. She is sexually active and takes oral contraceptives. Temperature is 37.2 C (99 F), blood pressure is 120/70 mm Hg, pulse is 84/min, and respirations are 16/min. On physical examination, the lungs are clear to auscultation. There is mild swelling and tenderness of the elbows, knees, and ankles. The lower extremities are tender to palpation and have scattered erythematous nodules. Chest x-ray reveals lung nodules and hilar fullness. Transbronchial biopsy shows large epithelioid cells, occasional giant cells, and no areas of necrosis. Which of the following pharmacotherapies is most appropriate for the initial treatment of this patient?

- A. Ceftriaxone
- B. Doxycycline
- C. Etanercept
- D. Penicillin
- E. Prednisone

Submit

https://t.me/USMLEWorldStep1

A 26-year-old woman is evaluated for joint pain affecting the elbows, knees, and ankles for the past month. She has also experienced a dry cough and mild shortness of breath over the last 6 months. She is sexually active and takes oral contraceptives. Temperature is 37.2 C (99 F), blood pressure is 120/70 mm Hg, pulse is 84/min, and respirations are 16/min. On physical examination, the lungs are clear to auscultation. There is mild swelling and tenderness of the elbows, knees, and ankles. The lower extremities are tender to palpation and have scattered erythematous nodules. Chest x-ray reveals lung nodules and hilar fullness. Transbronchial biopsy shows large epithelioid cells, occasional giant cells, and no areas of necrosis. Which of the following pharmacotherapies is most appropriate for the initial treatment of this patient?

- A. Ceftriaxone (7%)
- ✗ B. Doxycycline (5%)
- C. Etanercept (7%)
- D. Penicillin (2%)
- ✓ E. Prednisone (76%)

Incorrect
Correct answer
E

76%
Answered correctly

05 secs
Time Spent

2023
Version

Explanation

Common features of sarcoidosis	
Epidemiology	• Young adults • African Americans

https://t.me/USMLEWorldStep1

Common features of sarcoidosis	
Epidemiology	• Young adults • African Americans

Clinical	• Constitutional symptoms
	• Cough, dyspnea & chest pain
	• Extrapulmonary findings
	  ◦ Skin lesions
	  ◦ Anterior/posterior uveitis
	  ◦ Löfgren syndrome
	• Parotid gland swelling

Imaging	• Bilateral hilar adenopathy • Pulmonary reticular infiltrates
Laboratory	• Hypercalcemia/hypercalciuria • Elevated serum ACE level
Pathology	• Biopsy showing noncaseating granulomas that stain negative for fungi & acid-fast bacilli

This young patient has arthralgias, dyspnea, cough, and erythema nodosum (tender, subcutaneous, lower extremity nodules). This, in conjunction with lung nodules and hilar fullness on x-ray, is highly suggestive of **sarcoidosis**, an inflammatory disease characterized by granuloma formation in multiple tissues. Diagnosis is confirmed by biopsy showing noncaseating granulomas composed of **epithelioid cells** (activated macrophages) and **giant multinucleated cells** without central necrosis. Typical manifestations include hilar adenopathy, **pulmonary infiltrates** (eg, nodules, interstitial lung disease), skin (eg, erythema nodosum) and ocular (eg, anterior

https://t.me/USMLEWorldStep1

This young patient has arthralgias, dyspnea, cough, and erythema nodosum (tender, subcutaneous, lower extremity nodules). This, in conjunction with lung nodules and hilar fullness on x-ray, is highly suggestive of **sarcoidosis**, an inflammatory disease characterized by granuloma formation in multiple tissues. Diagnosis is confirmed by biopsy showing noncaseating granulomas composed of **epithelioid cells** (activated macrophages) and **giant multinucleated cells** without central necrosis. Typical manifestations include hilar adenopathy, **pulmonary infiltrates** (eg, nodules, interstitial lung disease), skin (eg, erythema nodosum) and ocular (eg, anterior uveitis) involvement, polyarthritis, and constitutional symptoms (eg, fatigue, weight loss).

Many patients with sarcoidosis do not require treatment; however, those with significant symptoms (eg, dyspnea, chest pain) or progressive pulmonary disease (ie, worsening opacities/fibrosis or pulmonary function tests) should be treated. Oral **glucocorticoids** (eg, prednisone) are the initial treatment of choice.

(Choice A) Ceftriaxone is appropriate treatment for disseminated gonococcal infection, which causes arthralgias and tenosynovitis. However, patients typically have a pustular, painless dermatitis; lung involvement would be unexpected.

(Choice B) Doxycycline is used to treat Lyme disease, which presents with an expansive erythematous rash with central clearing (erythema migrans), fatigue, and arthralgias; pulmonary involvement is unexpected. Histology demonstrates an inflammatory infiltrate with spirochetes.

(Choice C) Etanercept is a tumor necrosis factor-alpha inhibitor that is used in rheumatoid arthritis, a condition that can cause arthralgias, skin nodules (rheumatoid nodules), and interstitial lung disease; however, it typically involves the metacarpophalangeal and proximal interphalangeal joints. Pathology shows a periarticular inflammatory infiltrate with joint destruction; noncaseating granulomas would not be seen.

(Choice D) Penicillin is used to treat syphilis, but the rash associated with this disease is typically maculopapular and involves the palms and soles. Histopathology may demonstrate lymphoplasmacytic inflammation and granulomas, and *Treponema pallidum* is visible on darkfield microscopy.

https://t.me/USMLEWorldStep1

and **giant multinucleated cells** without central necrosis. Typical manifestations include hilar adenopathy, **pulmonary infiltrates** (eg, nodules, interstitial lung disease), skin (eg, erythema nodosum) and ocular (eg, anterior uveitis) involvement, polyarthritis, and constitutional symptoms (eg, fatigue, weight loss).

Many patients with sarcoidosis do not require treatment; however, those with significant symptoms (eg, dyspnea, chest pain) or progressive pulmonary disease (ie, worsening opacities/fibrosis or pulmonary function tests) should be treated. Oral **glucocorticoids** (eg, prednisone) are the initial treatment of choice.

(Choice A) Ceftriaxone is appropriate treatment for disseminated gonococcal infection, which causes arthralgias and tenosynovitis. However, patients typically have a pustular, painless dermatitis; lung involvement would be unexpected.

(Choice B) Doxycycline is used to treat Lyme disease, which presents with an expansive erythematous rash with central clearing (erythema migrans), fatigue, and arthralgias; pulmonary involvement is unexpected. Histology demonstrates an inflammatory infiltrate with spirochetes.

(Choice C) Etanercept is a tumor necrosis factor-alpha inhibitor that is used in rheumatoid arthritis, a condition that can cause arthralgias, skin nodules (rheumatoid nodules), and interstitial lung disease; however, it typically involves the metacarpophalangeal and proximal interphalangeal joints. Pathology shows a periarticular inflammatory infiltrate with joint destruction; noncaseating granulomas would not be seen.

(Choice D) Penicillin is used to treat syphilis, but the rash associated with this disease is typically maculopapular and involves the palms and soles. Histopathology may demonstrate lymphoplasmacytic inflammation and granulomas, and *Treponema pallidum* is visible on darkfield microscopy.

Educational objective:
Sarcoidosis commonly presents with hilar adenopathy, pulmonary infiltrates, and skin findings (eg, erythema nodosum). Biopsy shows noncaseating granulomas composed of epithelioid cells (activated macrophages) and giant multinucleated cells. Oral glucocorticoids are the initial treatment of choice.

https://t.me/USMLEWorldStep1

- Hypercalcemia/hypercalciuria

Exhibit Display

Erythema nodosum

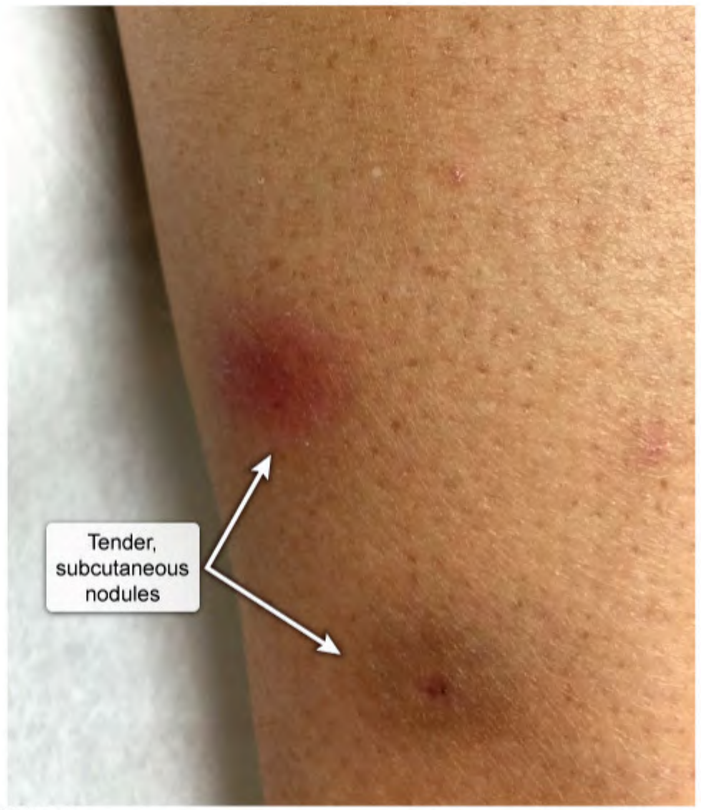

©UWorld

Zoom In | Zoom Out | Reset | New | Existing | My Notebook

This
extre
sarc
conf
and
pulr
uvei

Man
ches
be tr

(Ch
and
unex

(Ch
cent
dem

(Ch
that
involves the metacarpophalangeal and proximal interphalangeal joints. Pathology shows a periarticular

https://t.me/USMLEWorldStep1

- Hypercalcemia/hypercalciuria

Exhibit Display

Sarcoidosis

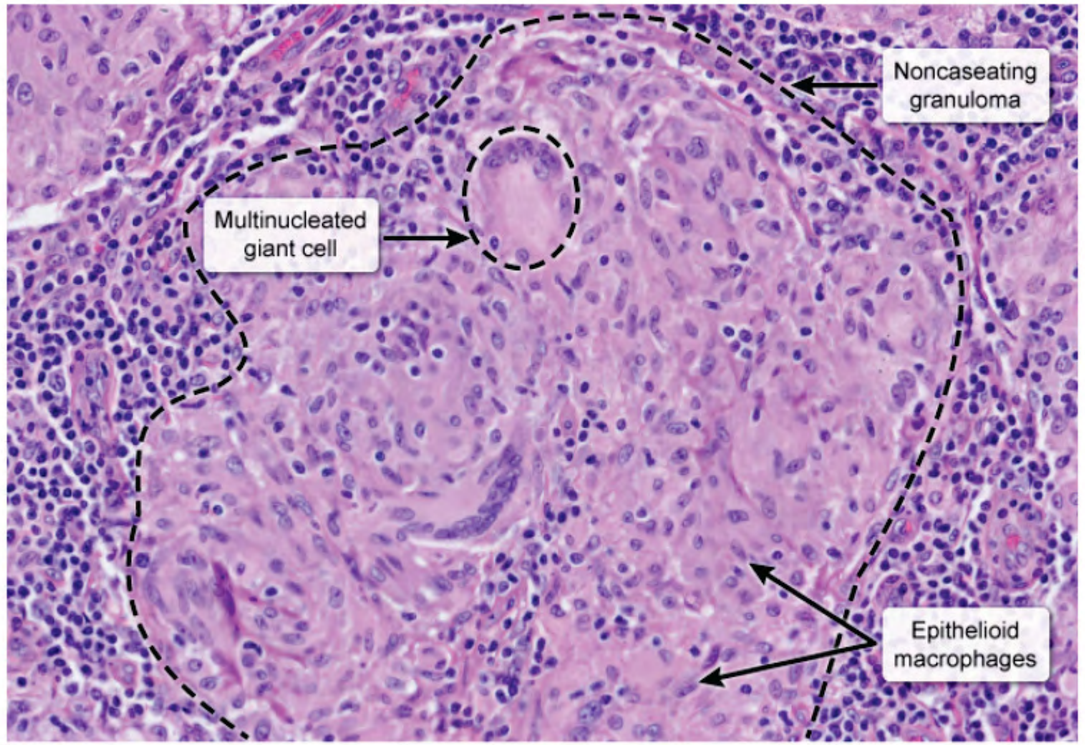

©UWorld

Zoom In | Zoom Out | Reset | New | Existing | My Notebook

This
extr
sarc
conf
and
pulr
uvei

Man
ches
be t

(Ch
and
unex

(Ch
cent
dem

(Ch
that
involves the metacarpophalangeal and proximal interphalangeal joints. Pathology shows a periarticular

https://t.me/USMLEWorldStep1

- Hypercalcemia/hypercalciuria

Exhibit Display

Sarcoidosis

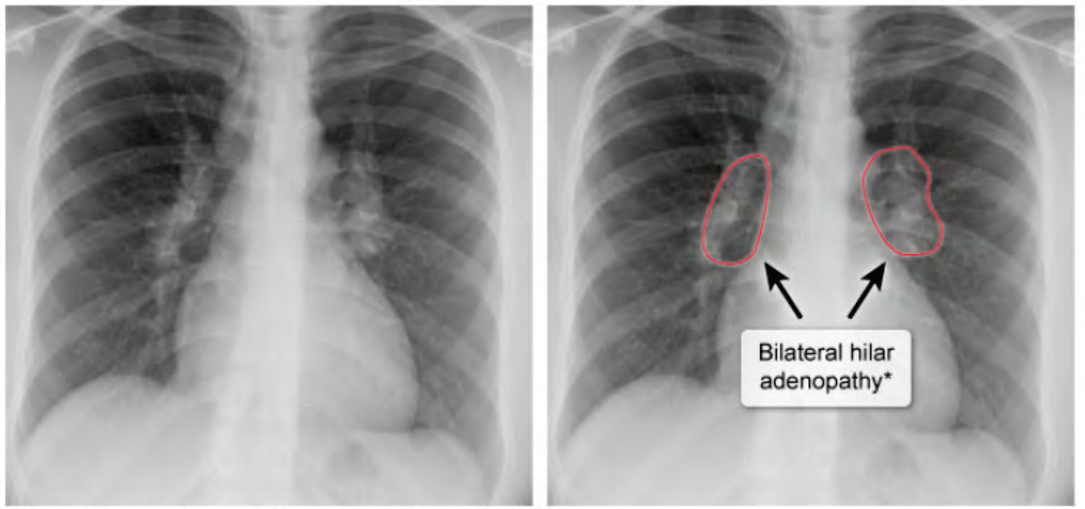

*Noncaseating granuloma and inflammatory cell accumulation

©UWorld

Zoom In | Zoom Out | Reset | New | Existing | My Notebook

This
extre
sarc
conf
and
pulr
uvei

Man
ches
be tr

(Cho
and
unex

(Cho
cent
dem

(Cho
that
involves the metacarpophalangeal and proximal interphalangeal joints. Pathology shows a periarticular

https://t.me/USMLEWorldStep1

A 4-hour-old girl is evaluated in the neonatal intensive care unit. The patient was born at 30 weeks gestation via spontaneous vaginal delivery after 3 hours of labor. Membranes ruptured at the onset of labor and amniotic fluid appeared clear. Immediately after birth, the child was placed on continuous positive airway pressure by nasal prongs due to signs of breathing difficulty. Temperature is 36.7 C (98 F), pulse is 158/min, and respirations are 54/min. Pulse oximetry is 92% on 60% oxygen. Examination shows audible grunting and subcostal chest wall retractions. Cardiac examination shows no murmurs. A chest x-ray is obtained:

https://t.me/USMLEWorldStep1

A 4-
spor
appe
pron
54/n
retra

Exhibit Display

Zoom In | Zoom Out | Reset | New | Existing | My Notebook

https://t.me/USMLEWorldStep1

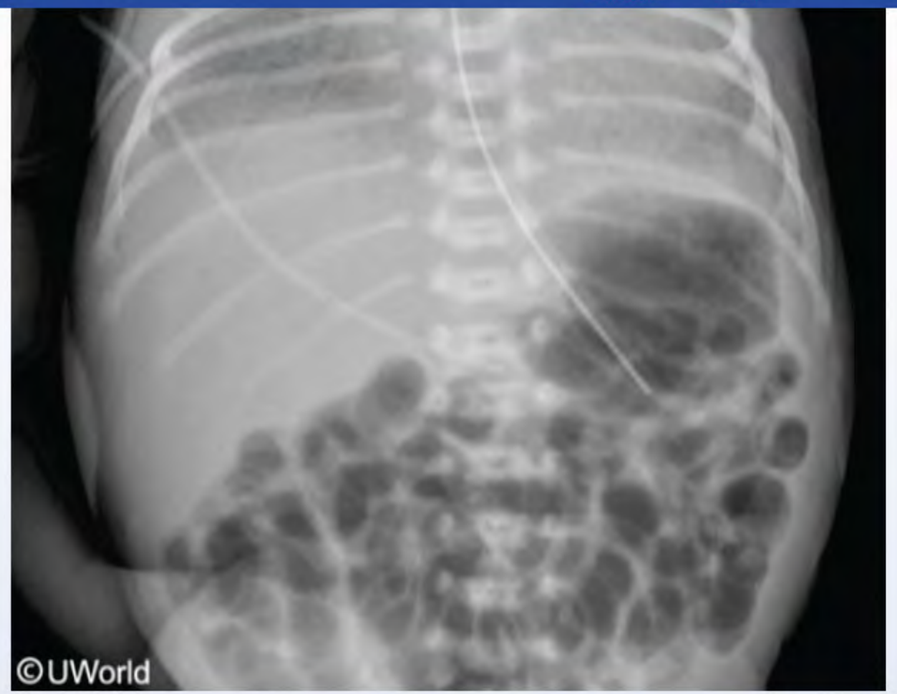

The radiographic findings in this patient most likely represent which of the following?

- A. Air leakage into pleural space
- B. Alveolar and capillary dysplasia
- C. Diffuse atelectasis
- D. Occlusion of the bronchioles
- E. Retained extracellular fluid

Submit

https://t.me/USMLEWorldStep1

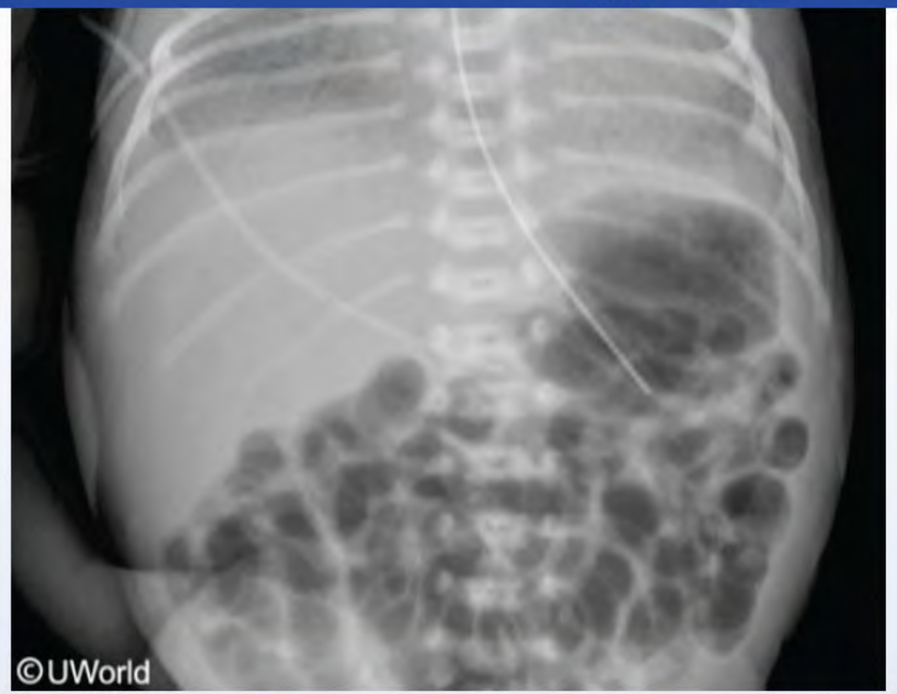

The radiographic findings in this patient most likely represent which of the following?

- A. Air leakage into pleural space (12%)
- B. Alveolar and capillary dysplasia (15%)
- ✓ C. Diffuse atelectasis (56%)
- D. Occlusion of the bronchioles (4%)
- E. Retained extracellular fluid (10%)

Correct

56% Answered correctly

35 secs Time Spent

2023 Version

https://t.me/USMLEWorldStep1

Explanation

Exhibit Display

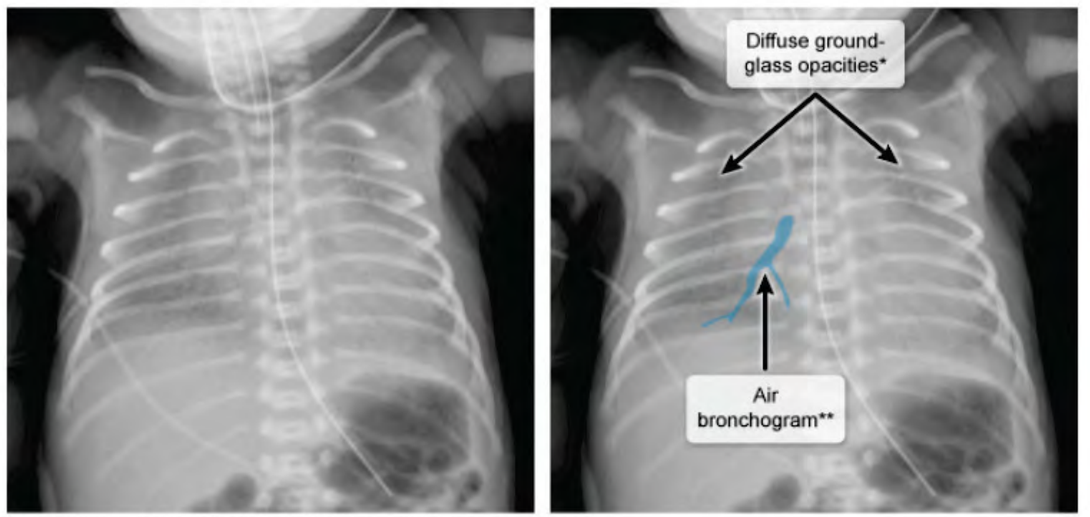

Zoom In | Zoom Out | Reset | New | Existing | My Notebook

This
bron
RDS
surf
the
ches
then

Man
reduce surface tension). During the first week of life, type 2 pneumocytes begin to release endogenous surfactant, and respiratory distress typically begins to improve.

https://t.me/USMLEWorldStep1

This preterm infant with increased work of breathing and hypoxia has diffuse ground-glass opacities and air bronchograms on imaging. These findings are consistent with **neonatal respiratory distress syndrome** (RDS). RDS is caused by immaturity of type 2 pneumocytes, which normally produce alveolar surfactant. **Lack of surfactant** causes decreased compliance and increased surface tension of alveoli, leading to alveolar collapse at the end of expiration. This **diffuse atelectasis** results in the characteristic reticular or **ground-glass opacities** on chest x-ray. Unlike alveoli, larger airways **remain patent** and filled with air due to their cartilaginous walls, making them visible **(air bronchograms)** against the reticular background.

Management of RDS is respiratory support (to maintain alveolar pressure and prevent collapse) and surfactant (to reduce surface tension). During the first week of life, type 2 pneumocytes begin to release endogenous surfactant, and respiratory distress typically begins to improve.

(Choice A) Pneumothorax is characterized by air leakage into the pleural space with subsequent respiratory distress. However, x-ray would show a visceral pleural line with absent distal lung markings.

(Choice B) Bronchopulmonary dysplasia (BPD), which causes tachypnea, retractions, and hypoxia, is classically caused by prolonged (>1 month) mechanical ventilation, leading to lung injury and diffuse fibrosis. Another form of BPD is caused by an arrest of pulmonary development, leading to a decreased number and function of alveoli and pulmonary capillaries. Although this infant is at risk for developing both forms of BPD due to prematurity, this condition is diagnosed at age >1 month, not immediately after birth.

(Choice D) Occlusion of the bronchioles by meconium causes meconium aspiration syndrome. In contrast to this patient, affected infants have patchy bilateral infiltrates and lung hyperexpansion due to air trapping. In addition, this patient's amniotic fluid is clear, making this diagnosis unlikely.

(Choice E) Retained extracellular fluid is seen in transient tachypnea of the newborn. X-ray findings include streaky interstitial fluid collections and fluid in the minor fissures, neither of which are seen in this patient.

Educational objective:

https://t.me/USMLEWorldStep1

RDS is caused by immaturity of type 2 pneumocytes, which normally produce alveolar surfactant. **Lack of surfactant** causes decreased compliance and increased surface tension of alveoli, leading to alveolar collapse at the end of expiration. This **diffuse atelectasis** results in the characteristic reticular or **ground-glass opacities** on chest x-ray. Unlike alveoli, larger airways **remain patent** and filled with air due to their cartilaginous walls, making them visible **(air bronchograms)** against the reticular background.

Management of RDS is respiratory support (to maintain alveolar pressure and prevent collapse) and surfactant (to reduce surface tension). During the first week of life, type 2 pneumocytes begin to release endogenous surfactant, and respiratory distress typically begins to improve.

(Choice A) Pneumothorax is characterized by air leakage into the pleural space with subsequent respiratory distress. However, x-ray would show a visceral pleural line with absent distal lung markings.

(Choice B) Bronchopulmonary dysplasia (BPD), which causes tachypnea, retractions, and hypoxia, is classically caused by prolonged (>1 month) mechanical ventilation, leading to lung injury and diffuse fibrosis. Another form of BPD is caused by an arrest of pulmonary development, leading to a decreased number and function of alveoli and pulmonary capillaries. Although this infant is at risk for developing both forms of BPD due to prematurity, this condition is diagnosed at age >1 month, not immediately after birth.

(Choice D) Occlusion of the bronchioles by meconium causes meconium aspiration syndrome. In contrast to this patient, affected infants have patchy bilateral infiltrates and lung hyperexpansion due to air trapping. In addition, this patient's amniotic fluid is clear, making this diagnosis unlikely.

(Choice E) Retained extracellular fluid is seen in transient tachypnea of the newborn. X-ray findings include streaky interstitial fluid collections and fluid in the minor fissures, neither of which are seen in this patient.

Educational objective:
Neonatal respiratory distress syndrome is characterized by inadequate surfactant production, resulting in increased alveolar surface tension and decreased alveolar compliance. Diffuse alveolar collapse (atelectasis) is seen on chest x-ray as ground-glass opacities with air bronchograms.

https://t.me/USMLEWorldStep1

This preterm ir
bronchograms
RDS is caused
surfactant cau
the end of expi
chest x-ray. U
them visible **(a**

Management c
reduce surface
and respiratory

(Choice A) Pr
distress. Howe

(Choice B) Br
caused by prol
BPD is caused
pulmonary cap
condition is dia

(Choice D) O

Exhibit Display

Alveoli

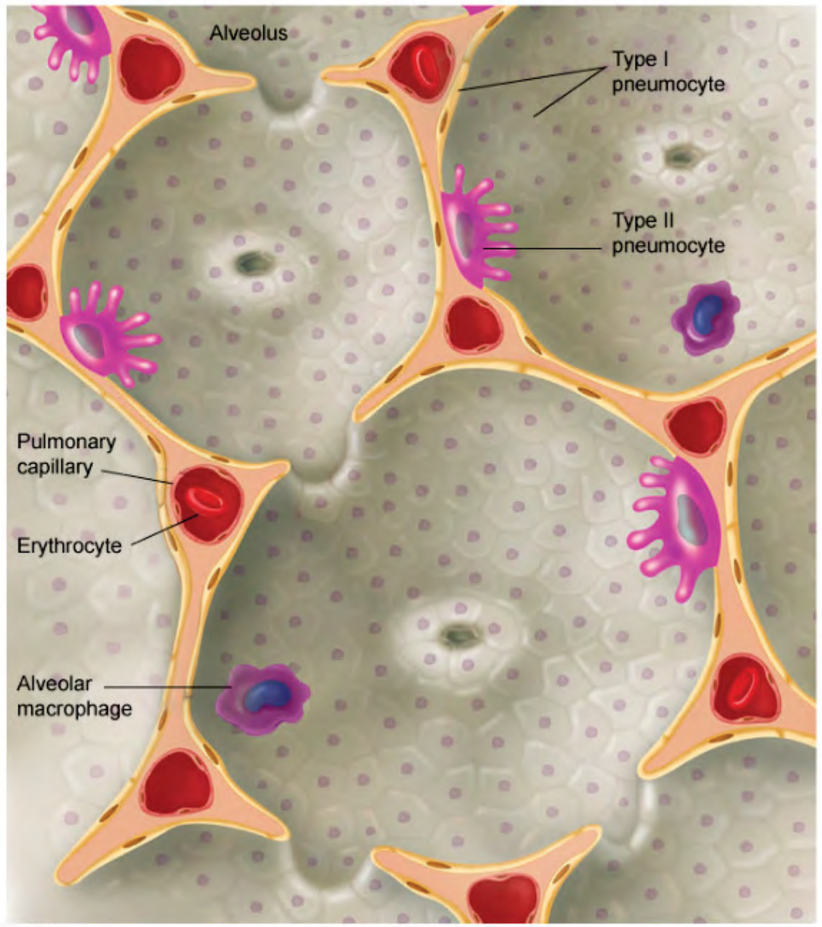

Zoom In | Zoom Out | Reset | New | Existing | My Notebook

https://t.me/USMLEWorldStep1

Exhibit Display

This preterm ir
bronchograms
RDS is caused
surfactant cau
the end of expi
chest x-ray. U
them visible **(a**

Management c
reduce surface
and respiratory

(Choice A) Pr
distress. Howe

(Choice B) Br
caused by prol
BPD is caused
pulmonary cap
condition is dia

(Choice D) O

Pneumothorax

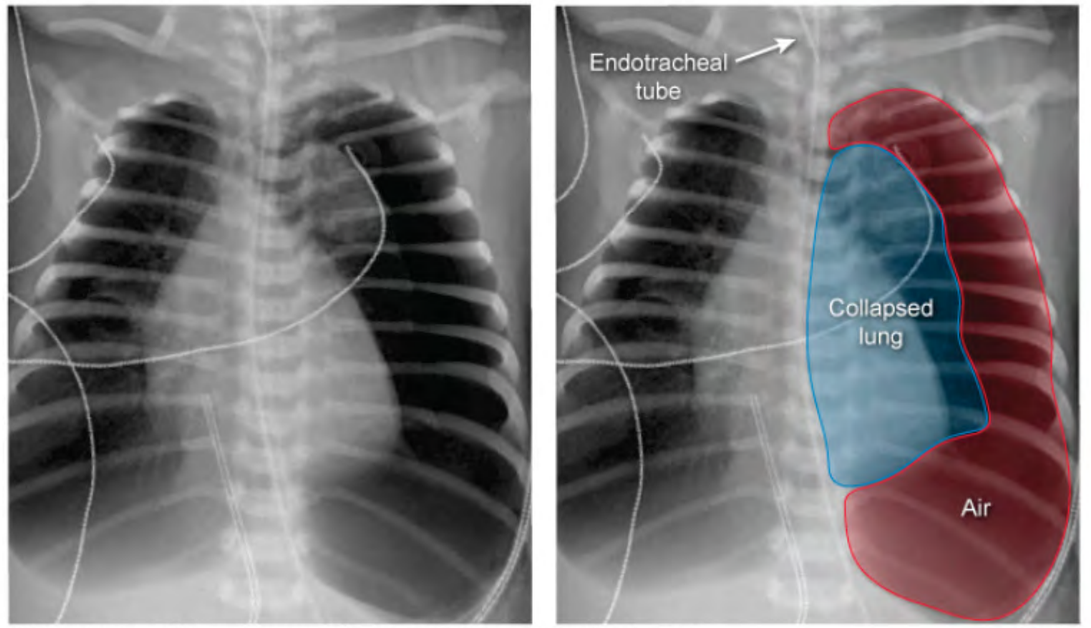

*Iatrogenic pneumothorax in a neonate due to mechanical ventilation (barotrauma)

©UWorld

Zoom In | Zoom Out | Reset | New | Existing | My Notebook

https://t.me/USMLEWorldStep1

RDS is caused by immaturity of type 2 pneumocytes, which normally produce alveolar surfactant. **Lack of surfactant** causes decreased compliance and increased surface tension of alveoli, leading to alveolar collapse at the e
ches
then

Man
redu
and

(Ch
distr

(Ch
caus
BPD
puln
conc

(Ch
patie
this

(Ch
strea

Edu
Neo
alve
chest x-ray as ground-glass opacities with air bronchograms.

Exhibit Display

Transient tachypnea of the newborn

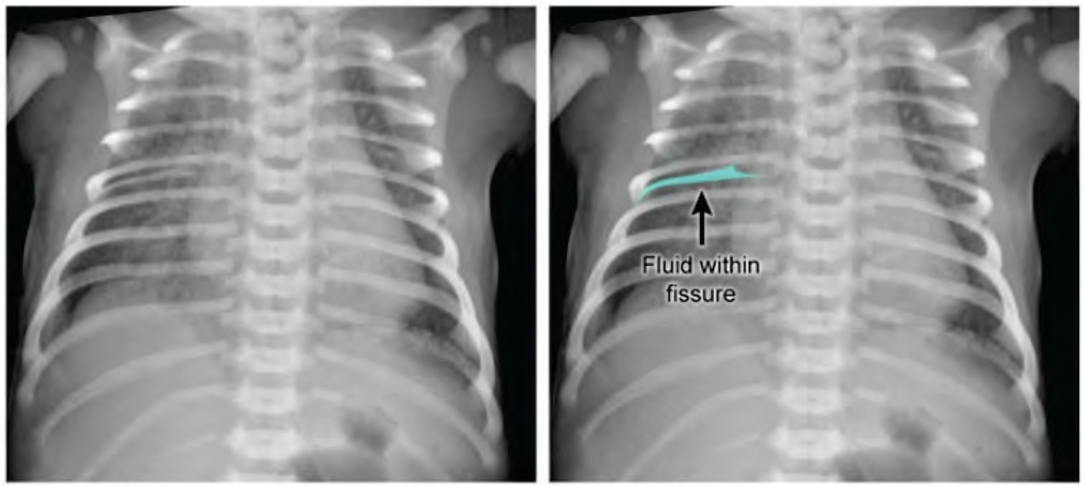

©UWorld

Zoom In | Zoom Out | Reset | New | Existing | My Notebook

https://t.me/USMLEWorldStep1

A research study is conducted to evaluate the effects of various serum proteins in healthy and diseased states. Healthy volunteers and patients with various medical conditions are recruited. In an experiment, purified elastin is exposed to stimulated neutrophils, which results in the degradation of the elastin molecules into smaller peptides. This process can be inhibited by adding serum from healthy volunteers but not from a specific patient population. Which of the following is the strongest recommendation for patients in this specific population?

- A. Avoidance of competitive sports participation
- B. Avoidance of immunosuppressive agents
- C. Avoidance of second-hand smoke
- D. Periodic aortic diameter monitoring
- E. Regular bone density measurement
- F. Regular ophthalmologic examinations

Submit

https://t.me/USMLEWorldStep1

A research study is conducted to evaluate the effects of various serum proteins in healthy and diseased states. Healthy volunteers and patients with various medical conditions are recruited. In an experiment, purified elastin is exposed to stimulated neutrophils, which results in the degradation of the elastin molecules into smaller peptides. This process can be inhibited by adding serum from healthy volunteers but not from a specific patient population. Which of the following is the strongest recommendation for patients in this specific population?

- A. Avoidance of competitive sports participation (4%)
- ✗ B. Avoidance of immunosuppressive agents (6%)
- ✓ C. Avoidance of second-hand smoke (72%)
- D. Periodic aortic diameter monitoring (13%)
- E. Regular bone density measurement (1%)
- F. Regular ophthalmologic examinations (2%)

Incorrect
Correct answer
C

72%
Answered correctly

04 secs
Time Spent

2023
Version

Explanation

Neutrophil elastase is released by both neutrophils and macrophages and is the primary protease responsible for extracellular elastin degradation. The major **serum inhibitor** of elastase is **alpha-1 antitrypsin** (AAT).

In this study, the patients whose serum is unable to inhibit elastin degradation likely have **AAT deficiency**, a condition characterized by early-onset panacinar emphysema due to the unopposed action of neutrophil elastase on alveolar walls.

https://t.me/USMLEWorldStep1

Explanation

Neutrophil elastase is released by both neutrophils and macrophages and is the primary protease responsible for extracellular elastin degradation. The major **serum inhibitor** of elastase is **alpha-1 antitrypsin** (AAT).

In this study, the patients whose serum is unable to inhibit elastin degradation likely have **AAT deficiency**, a condition characterized by early-onset panacinar emphysema due to the unopposed action of neutrophil elastase on alveolar walls.

Tobacco exposure dramatically **accelerates** the development of **emphysema** in patients with AAT deficiency by inducing inflammation (increasing neutrophil and macrophage activation) and permanently oxidizing and inactivating AAT. Therefore, patients with AAT deficiency should be counseled to avoid smoking and exposure to second-hand smoke.

(Choice A) Patients with hypertrophic cardiomyopathy are at risk for sudden cardiac arrest with exertion and are typically counseled to avoid participation in most competitive sports.

(Choice B) Patients with chronic granulomatous disease (impaired phagocytic intracellular killing due to defective NADPH oxidase) should avoid certain immunosuppressive agents (eg, TNF-alpha blockers) due to risk of overwhelming infection.

(Choice D) Periodic aortic diameter monitoring is indicated in patients with Marfan syndrome (impaired fibrillin synthesis), who are at risk for both aortic dissection and chronic aortic regurgitation due to aortic root dilation.

(Choice E) Patients with osteogenesis imperfecta (decreased production of type 1 collagen) are at high risk of developing osteoporosis and should undergo regular bone density monitoring.

(Choice F) Patients with Ehlers-Danlos syndrome (impaired collagen synthesis) are at risk for scleral fragility, ocular globe rupture, and retinal detachment and should undergo routine ophthalmologic exams.

Educational objective:

https://t.me/USMLEWorldStep1

In this study, the patients whose serum is unable to inhibit elastin degradation likely have **AAT deficiency**, a condition characterized by early-onset panacinar emphysema due to the unopposed action of neutrophil elastase on alveolar walls.

Tobacco exposure dramatically **accelerates** the development of **emphysema** in patients with AAT deficiency by inducing inflammation (increasing neutrophil and macrophage activation) and permanently oxidizing and inactivating AAT. Therefore, patients with AAT deficiency should be counseled to avoid smoking and exposure to second-hand smoke.

(Choice A) Patients with hypertrophic cardiomyopathy are at risk for sudden cardiac arrest with exertion and are typically counseled to avoid participation in most competitive sports.

(Choice B) Patients with chronic granulomatous disease (impaired phagocytic intracellular killing due to defective NADPH oxidase) should avoid certain immunosuppressive agents (eg, TNF-alpha blockers) due to risk of overwhelming infection.

(Choice D) Periodic aortic diameter monitoring is indicated in patients with Marfan syndrome (impaired fibrillin synthesis), who are at risk for both aortic dissection and chronic aortic regurgitation due to aortic root dilation.

(Choice E) Patients with osteogenesis imperfecta (decreased production of type 1 collagen) are at high risk of developing osteoporosis and should undergo regular bone density monitoring.

(Choice F) Patients with Ehlers-Danlos syndrome (impaired collagen synthesis) are at risk for scleral fragility, ocular globe rupture, and retinal detachment and should undergo routine ophthalmologic exams.

Educational objective:
The major serum inhibitor of extracellular elastase is alpha-1 antitrypsin (AAT); patients with AAT deficiency typically develop early-onset panacinar emphysema due to unchecked elastase activity. Exposure to tobacco smoke dramatically accelerates the development of emphysema in patients with AAT deficiency and should be avoided.

https://t.me/USMLEWorldStep1

Explanation

Neutrophil ela
extracellular el

In this study, th
condition chara
on alveolar wa

Tobacco expo
inducing inflam
inactivating AA
second-hand s

(Choice A) Pa
typically couns

(Choice B) Pa
NADPH oxidas
overwhelming

(Choice D) Pe
synthesis), wh

(Choice E) Pa
developing ost

(Choice F) Pa
ocular globe rupture, and retinal detachment and should undergo routine ophthalmologic exams.

Exhibit Display

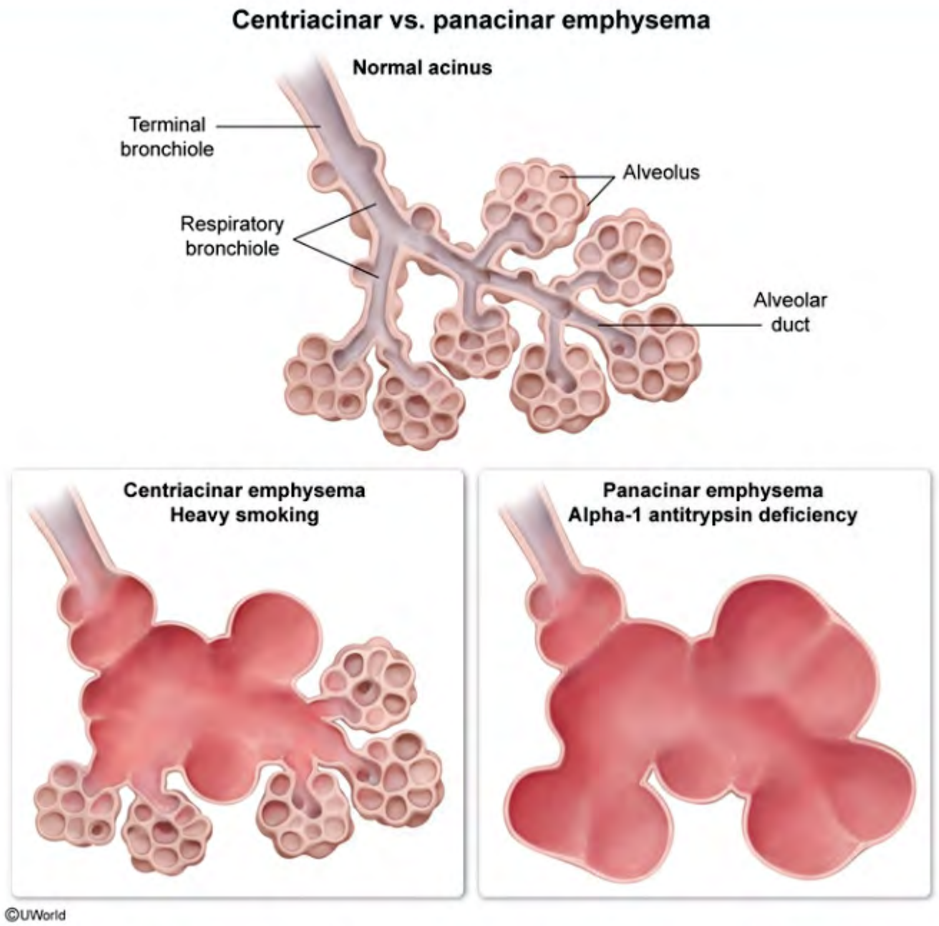

Zoom In | Zoom Out | Reset | New | Existing | My Notebook

https://t.me/USMLEWorldStep1

Neutrophil elastase is released by both neutrophils and macrophages and is the primary protease responsible for extra

In th
conc
on a

Toba
indu
inac
secc

(Che
typic

(Che
NAD
over

(Che
synt

(Che
deve

(Che
ocul

Edu
The major serum inhibitor of extracellular elastase is alpha-1 antitrypsin (AAT); patients with AAT deficiency typically develop early-onset panacinar emphysema due to unchecked elastase activity. Exposure to tobacco

Exhibit Display

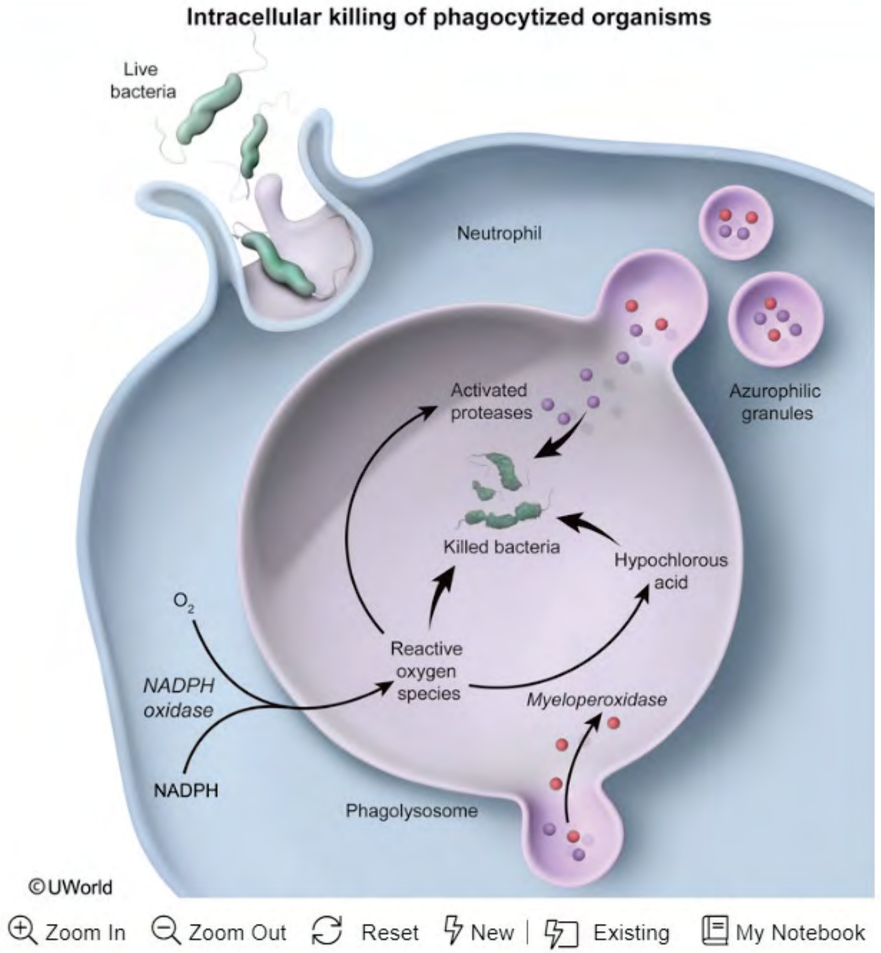

Zoom In | Zoom Out | Reset | New | Existing | My Notebook

https://t.me/USMLEWorldStep1

A 62-year-old woman is brought to the emergency department due to progressive weakness and dyspnea. The patient is visiting her niece, who says the patient forgot to bring her regular medications and has not been taking them for the past week. The patient began feeling weak and fatigued 3 days ago and has had shortness of breath since yesterday. Temperature is 37 C (98.6 F), blood pressure is 122/88 mm Hg, pulse is 90/min, and respirations are 24/min and shallow. On physical examination, the patient appears dyspneic with drooping at the eyelids and corners of the mouth. Her speech has a nasal quality. Arterial blood gas obtained on room air shows pH 7.32; $PaCO_2$ is 52 mm Hg, PaO_2 is 72 mm Hg, and HCO_3 is 26 mEq/L. Bedside spirometry demonstrates decreased forced vital capacity. A pathologic process involving which of the following structures is the most likely cause of this patient's shortness of breath?

- A. Brain stem respiratory center
- B. Muscles of respiration
- C. Pulmonary arteries
- D. Terminal airways and alveoli
- E. Upper larger airways

Submit

https://t.me/USMLEWorldStep1

A 62-year-old woman is brought to the emergency department due to progressive weakness and dyspnea. The patient is visiting her niece, who says the patient forgot to bring her regular medications and has not been taking them for the past week. The patient began feeling weak and fatigued 3 days ago and has had shortness of breath since yesterday. Temperature is 37 C (98.6 F), blood pressure is 122/88 mm Hg, pulse is 90/min, and respirations are 24/min and shallow. On physical examination, the patient appears dyspneic with drooping at the eyelids and corners of the mouth. Her speech has a nasal quality. Arterial blood gas obtained on room air shows pH 7.32; $PaCO_2$ is 52 mm Hg, PaO_2 is 72 mm Hg, and HCO_3 is 26 mEq/L. Bedside spirometry demonstrates decreased forced vital capacity. A pathologic process involving which of the following structures is the most likely cause of this patient's shortness of breath?

- A. Brain stem respiratory center (15%)
- ✓ B. Muscles of respiration (58%)
- C. Pulmonary arteries (2%)
- D. Terminal airways and alveoli (16%)
- E. Upper larger airways (7%)

Correct

58% Answered correctly

05 secs Time Spent

2023 Version

Explanation

https://t.me/USMLEWorldStep1

B. Muscles of respiration (58%)

Exhibit Display

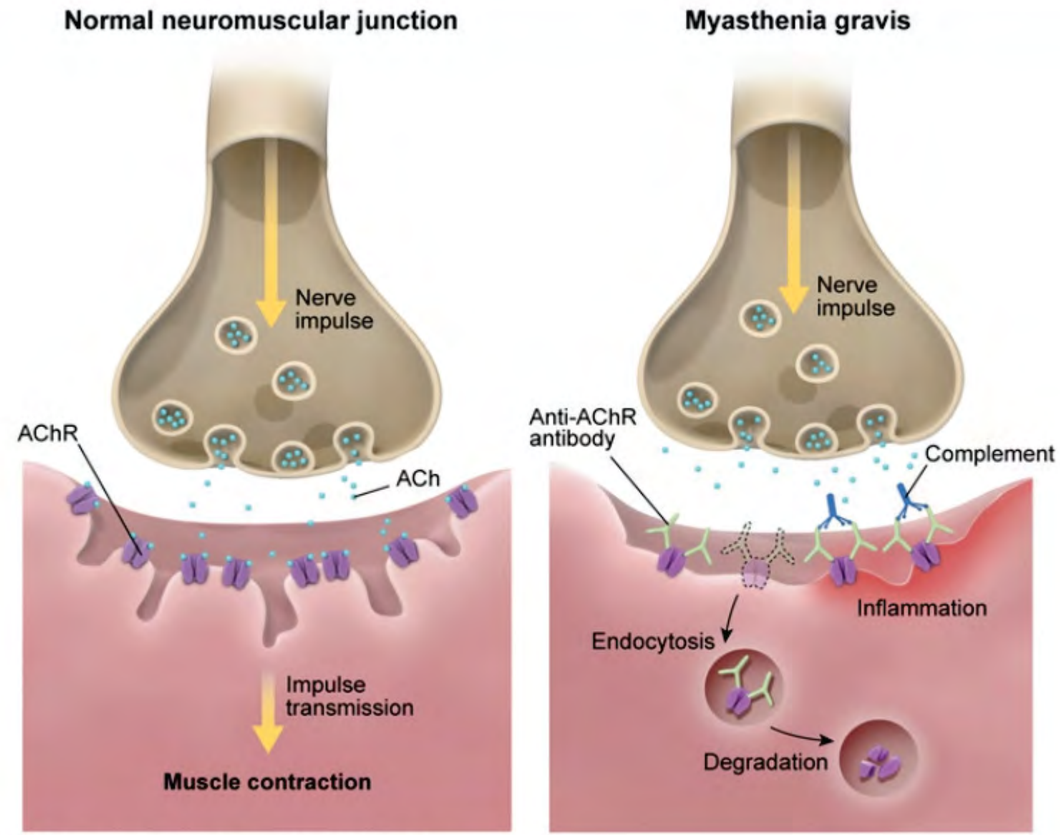

ACh = acetylcholine; **AChR** = acetylcholine receptor.

©UWorld

Zoom In | Zoom Out | Reset | New | Existing | My Notebook

https://t.me/USMLEWorldStep1

©UWorld

This patient has hypercapnic and hypoxic respiratory failure (low pH, high CO_2, low O_2) indicating **global hypoventilation**. In association with the ptosis, bulbar weakness, and low forced vital capacity, this presentation suggests **myasthenic crisis** (severe weakness and respiratory depression due to an exacerbation of myasthenia gravis [MG]).

MG is characterized by **autoantibodies against nicotinic acetylcholine receptors** on the postsynaptic membrane of the neuromuscular junction, resulting in receptor degradation. This reduces the sensitivity of the postsynaptic membrane to acetylcholine stimulation, leading to reduced muscular response despite normal acetylcholine release. Muscle **weakness worsens with repetition** as acetylcholine stores within the presynaptic nerve terminal become progressively depleted.

Patients with MG typically have extraocular (eg, ptosis, diplopia), bulbar (eg, dysphonia, difficulty chewing), and facial (eg, myasthenic snarl) weakness. In addition, neck and proximal muscle weakness may occur, and in severe cases the **respiratory muscles** may be affected, leading to **respiratory failure** (as in this patient). Acetylcholinesterase inhibitors (eg, pyridostigmine, neostigmine) are used for symptomatic treatment, and withdrawal can trigger a myasthenic crisis.

(Choice A) Impairment of the respiratory control centers in the brain stem causes hypoventilation during sleep (Ondine curse); however, voluntary breathing is unaffected.

(Choice C) Pulmonary embolism can result in dyspnea and gas exchange abnormalities (eg, hypoxia). However, significant muscular weakness (eg, ptosis, nasal speech, decreased vital capacity) would be unexpected.

(Choices D and E) Patients with diseases involving the terminal airways and alveoli (eg, pulmonary fibrosis, emphysema) and large airways (eg, asthma, chronic bronchitis) can present with respiratory failure subsequent to muscle fatigue. However, these diseases are not associated with non-respiratory muscle weakness (eg, dysphonia, bulbar weakness).

Educational objective:

https://t.me/USMLEWorldStep1

gravis [MG]).

MG is characterized by **autoantibodies against nicotinic acetylcholine receptors** on the postsynaptic membrane of the neuromuscular junction, resulting in receptor degradation. This reduces the sensitivity of the postsynaptic membrane to acetylcholine stimulation, leading to reduced muscular response despite normal acetylcholine release. Muscle **weakness worsens with repetition** as acetylcholine stores within the presynaptic nerve terminal become progressively depleted.

Patients with MG typically have extraocular (eg, ptosis, diplopia), bulbar (eg, dysphonia, difficulty chewing), and facial (eg, myasthenic snarl) weakness. In addition, neck and proximal muscle weakness may occur, and in severe cases the **respiratory muscles** may be affected, leading to **respiratory failure** (as in this patient). Acetylcholinesterase inhibitors (eg, pyridostigmine, neostigmine) are used for symptomatic treatment, and withdrawal can trigger a myasthenic crisis.

(Choice A) Impairment of the respiratory control centers in the brain stem causes hypoventilation during sleep (Ondine curse); however, voluntary breathing is unaffected.

(Choice C) Pulmonary embolism can result in dyspnea and gas exchange abnormalities (eg, hypoxia). However, significant muscular weakness (eg, ptosis, nasal speech, decreased vital capacity) would be unexpected.

(Choices D and E) Patients with diseases involving the terminal airways and alveoli (eg, pulmonary fibrosis, emphysema) and large airways (eg, asthma, chronic bronchitis) can present with respiratory failure subsequent to muscle fatigue. However, these diseases are not associated with non-respiratory muscle weakness (eg, dysphonia, bulbar weakness).

Educational objective:
Myasthenia gravis is characterized by autoantibodies against postsynaptic nicotinic acetylcholine receptors at the neuromuscular junction, which result in receptor degradation. Patients typically have extraocular, bulbar, and facial weakness that worsens with activity. In severe cases, the respiratory muscles may be affected, leading to hypoventilation and respiratory failure.

https://t.me/USMLEWorldStep1

A 48-year-old woman comes to the office for follow-up of long-standing emphysema. She has a history of alpha-1 antitrypsin deficiency treated with inhaled bronchodilators and glucocorticoids. Over the past several months, the patient has been feeling progressively more short of breath, even with minimal exertion. She reports no change in her sputum, cough, or wheezing. She has no other medical conditions. Temperature is 37.1 C (98.8 F), blood pressure is 130/80 mm Hg, pulse is 82/min, and respirations are 18/min. Physical examination is significant for increased anteroposterior chest diameter, prolonged expiratory phase, and decreased breath sounds bilaterally. Heart sounds are distant. Chest x-ray reveals hyperinflated lungs with no consolidation, pleural effusion, or pneumothorax. Room air arterial blood gas analysis is performed. Which of the following sets of results is most likely to be seen in this patient?

	pH	$PaCO_2$(mm Hg)	Plasma HCO_3^- (mEq/L)	PaO_2 (mm Hg)
○ A.	7.19	65	24	50
○ B.	7.34	60	31	50
○ C.	7.40	40	24	90
○ D.	7.47	50	35	90
○ E.	7.56	28	24	50

Submit

https://t.me/USMLEWorldStep1

A 48-year-old woman comes to the office for follow-up of long-standing emphysema. She has a history of alpha-1 antitrypsin deficiency treated with inhaled bronchodilators and glucocorticoids. Over the past several months, the patient has been feeling progressively more short of breath, even with minimal exertion. She reports no change in her sputum, cough, or wheezing. She has no other medical conditions. Temperature is 37.1 C (98.8 F), blood pressure is 130/80 mm Hg, pulse is 82/min, and respirations are 18/min. Physical examination is significant for increased anteroposterior chest diameter, prolonged expiratory phase, and decreased breath sounds bilaterally. Heart sounds are distant. Chest x-ray reveals hyperinflated lungs with no consolidation, pleural effusion, or pneumothorax. Room air arterial blood gas analysis is performed. Which of the following sets of results is most likely to be seen in this patient?

	pH	$PaCO_2$(mm Hg)	Plasma HCO_3^- (mEq/L)	PaO_2 (mm Hg)	
✗ A.	7.19	65	24	50	(12%)
✓ B.	7.34	60	31	50	(64%)
C.	7.40	40	24	90	(6%)
D.	7.47	50	35	90	(10%)
E.	7.56	28	24	50	(6%)

Incorrect
Correct answer
B

64%
Answered correctly

04 secs
Time Spent

2023
Version

Explanation

https://t.me/USMLEWorldStep1

D. 7.47 50 35 90 (10%)

Exhibit Display

Arterial blood gas interpretation of acid-base disorders

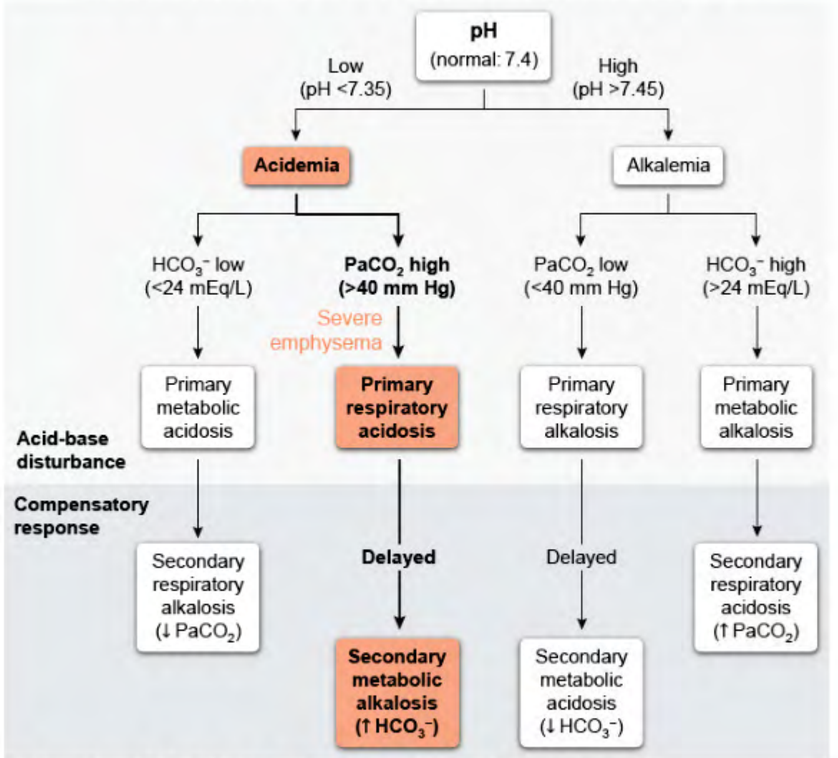

* The normal ranges for $PaCO_2$ and HCO_3^- vary slightly around 40 mm Hg and 24 mEq/L.
For simplicity, these numbers should be used as a normal baseline for acid-base calculations.

HCO_3^- = bicarbonate; $PaCO_2$ = partial pressure of carbon dioxide in arterial blood.

©UWorld

Zoom In | Zoom Out | Reset | New | Existing | My Notebook

Secondary respiratory | Delayed | Delayed | Secondary respiratory

https://t.me/USMLEWorldStep1

This patient's increased anteroposterior chest diameter (barrel chest), prolonged expiratory phase, distant heart sounds, and hyperinflation of the lungs on chest x-ray are signs consistent with **severe emphysema**.

Alveolar membrane destruction leads to increased dead space (wasted ventilation due to loss of capillaries). The overall decrease in alveolar ventilation results in chronic retention of CO_2 (primary respiratory acidosis). The kidneys compensate by increasing **reabsorption of bicarbonate** (secondary metabolic alkalosis) to help normalize the pH. Therefore, the arterial blood gases (ABGs) reflect **compensated respiratory acidosis** (↑ $PaCO_2$ and ↑ HCO_3^- with low-normal pH).

In addition to the acid-base disturbance, the ABGs also reveal **hypoxemia** (ie, PaO_2 <60 mm Hg) with an elevated alveolar-arterial (A-a) gradient, which is mainly caused by ventilation/perfusion mismatch due to emphysematous damage to the alveoli and airways. Patients with chronic hypoxemia, as in this case, may derive a survival benefit from initiation of home oxygen therapy.

(Choice A) These values (↓ pH, ↑ $PaCO_2$, and normal HCO_3^-) demonstrate an uncompensated acute respiratory acidosis. This scenario would be consistent with acute hypoventilation (eg, opioid overdose), in which there is insufficient time for compensatory metabolic alkalosis (ie, renal bicarbonate absorption).

(Choice C) These values are within their normal ranges (no acid-base disturbance or hypoxemia).

(Choice D) These values (high-normal pH, ↑ $PaCO_2$, and ↑ HCO_3^-) demonstrate a compensated primary metabolic alkalosis (eg, profuse vomiting). Excess bicarbonate is compensated for by a secondary respiratory acidosis (alveolar hypoventilation resulting in CO_2 accumulation). The pH corrects close to normal but remains slightly alkaline.

(Choice E) These values (↑ pH, ↓ $PaCO_2$, and normal HCO_3^-) demonstrate an uncompensated acute respiratory alkalosis with hypoxemia. This scenario could be consistent with acute pulmonary embolism. The sudden hyperventilation (due to pain, anxiety, hypoxemia) leaves insufficient time for compensatory metabolic acidosis (ie, renal bicarbonate excretion).

https://t.me/USMLEWorldStep1

kidneys compensate by increasing **reabsorption of bicarbonate** (secondary metabolic alkalosis) to help normalize the pH. Therefore, the arterial blood gases (ABGs) reflect **compensated respiratory acidosis** (↑ $PaCO_2$ and ↑ HCO_3^- with low-normal pH).

In addition to the acid-base disturbance, the ABGs also reveal **hypoxemia** (ie, PaO_2 <60 mm Hg) with an elevated alveolar-arterial (A-a) gradient, which is mainly caused by ventilation/perfusion mismatch due to emphysematous damage to the alveoli and airways. Patients with chronic hypoxemia, as in this case, may derive a survival benefit from initiation of home oxygen therapy.

(Choice A) These values (↓ pH, ↑ $PaCO_2$, and normal HCO_3^-) demonstrate an uncompensated acute respiratory acidosis. This scenario would be consistent with acute hypoventilation (eg, opioid overdose), in which there is insufficient time for compensatory metabolic alkalosis (ie, renal bicarbonate absorption).

(Choice C) These values are within their normal ranges (no acid-base disturbance or hypoxemia).

(Choice D) These values (high-normal pH, ↑ $PaCO_2$, and ↑ HCO_3^-) demonstrate a compensated primary metabolic alkalosis (eg, profuse vomiting). Excess bicarbonate is compensated for by a secondary respiratory acidosis (alveolar hypoventilation resulting in CO_2 accumulation). The pH corrects close to normal but remains slightly alkaline.

(Choice E) These values (↑ pH, ↓ $PaCO_2$, and normal HCO_3^-) demonstrate an uncompensated acute respiratory alkalosis with hypoxemia. This scenario could be consistent with acute pulmonary embolism. The sudden hyperventilation (due to pain, anxiety, hypoxemia) leaves insufficient time for compensatory metabolic acidosis (ie, renal bicarbonate excretion).

Educational objective:
Patients with severe emphysema typically have chronic CO_2 retention leading to compensated respiratory acidosis (↑ $PaCO_2$ with ↑ HCO_3^-) producing a low-normal pH, often accompanied by hypoxemia.

https://t.me/USMLEWorldStep1

sounds, and hyperinflation of the lungs on chest x-ray are signs consistent with **severe emphysema**.

Alveolar memb
overall decreas
kidneys compe
normalize the p
$PaCO_2$ and ↑ H

In addition to th
alveolar-arteria
damage to the
from initiation o

(Choice A) Th
acidosis. This
insufficient time

(Choice C) Th

(Choice D) Th
alkalosis (eg, p
(alveolar hypov
alkaline.

(Choice E) Th
alkalosis with h
hyperventilatio
renal bicarbona

Educational o

Exhibit Display

Arterial blood gas interpretation of acid-base disorders

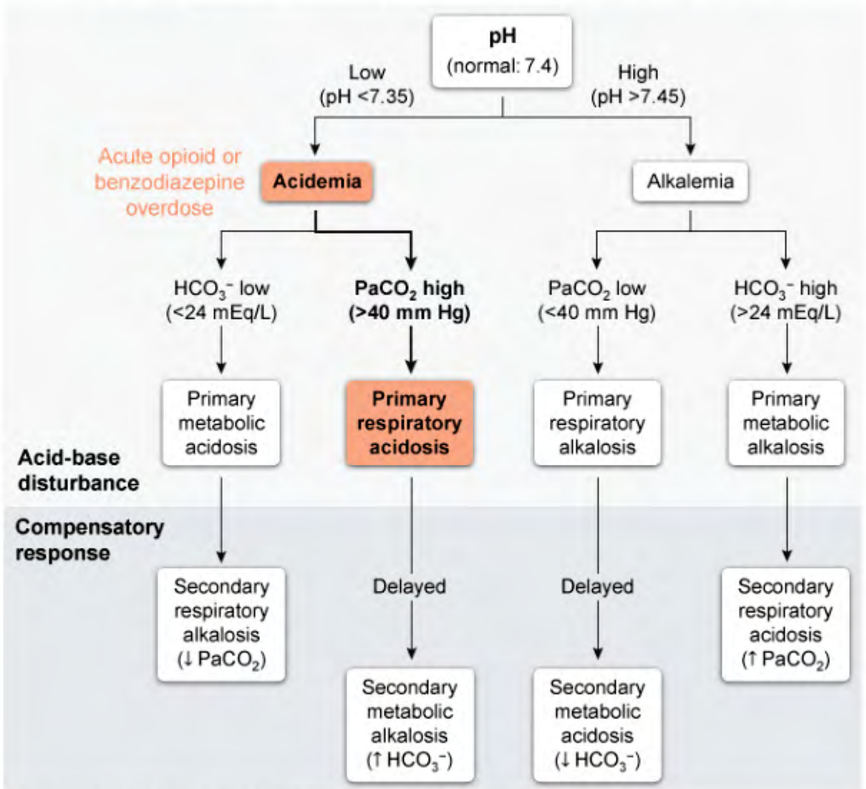

* The normal ranges for $PaCO_2$ and HCO_3^- vary slightly around 40 mm Hg and 24 mEq/L.
For simplicity, these numbers should be used as a normal baseline for acid-base calculations.

HCO_3^- = bicarbonate; **$PaCO_2$** = partial pressure of carbon dioxide in arterial blood.

©UWorld

Zoom In | Zoom Out | Reset | New | Existing | My Notebook

https://t.me/USMLEWorldStep1

sounds, and hyperinflation of the lungs on chest x-ray are signs consistent with **severe emphysema**.

Alve
over
kidn
norr
PaC

In ac
alve
dam
from

(Ch
acid
insu

(Ch

(Ch
alka
(alve
alka

(Ch
alka
hype
rena

Educational objective:

Exhibit Display

Arterial blood gas interpretation of acid-base disorders

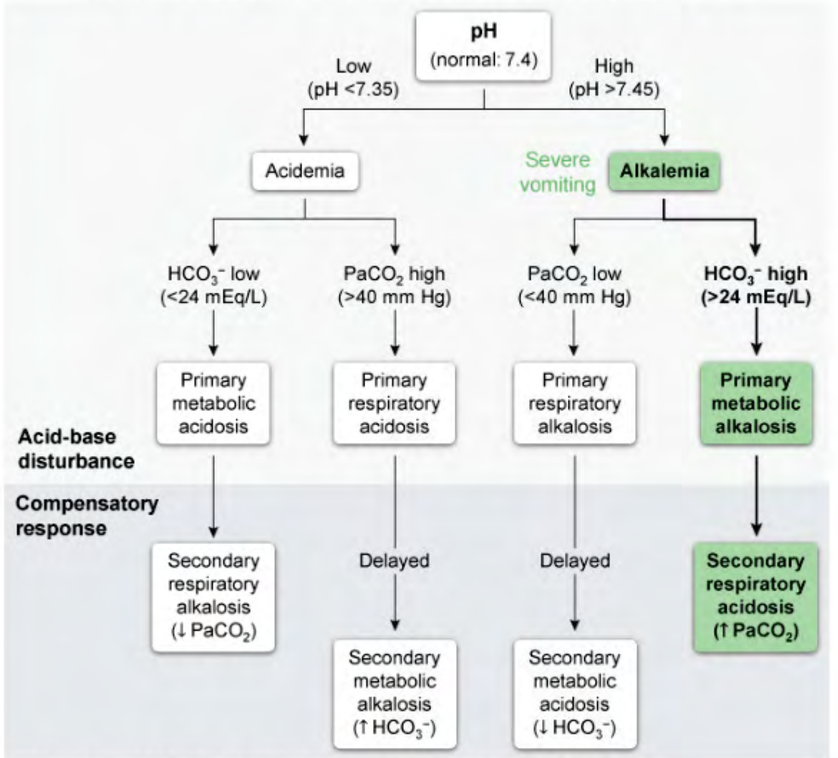

* The normal ranges for $PaCO_2$ and HCO_3^- vary slightly around 40 mm Hg and 24 mEq/L.
For simplicity, these numbers should be used as a normal baseline for acid-base calculations.

HCO_3^- = bicarbonate; **$PaCO_2$** = partial pressure of carbon dioxide in arterial blood.

©UWorld

Zoom In | Zoom Out | Reset | New | Existing | My Notebook

https://t.me/USMLEWorldStep1

sounds, and hyperinflation of the lungs on chest x-ray are signs consistent with **severe emphysema**.

Alve
over
kidn
norr
PaC

In ac
alve
dam
from

(Ch
acid
insu

(Ch

(Ch
alka
(alve
alka

(Ch
alka
hype
rena

Educational objective:

Exhibit Display

Arterial blood gas interpretation of acid-base disorders

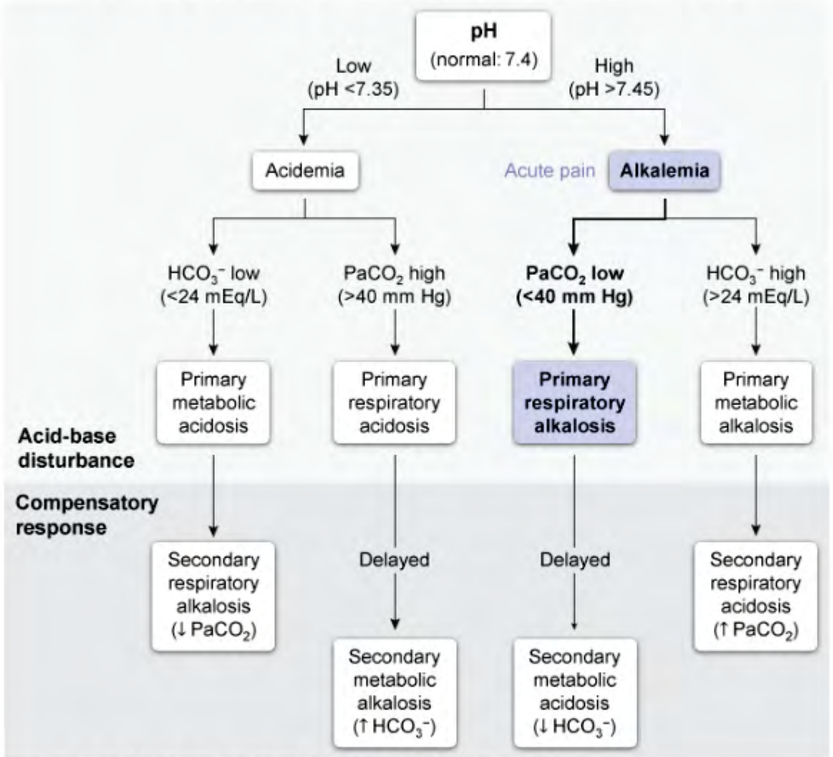

*The normal ranges for $PaCO_2$ and HCO_3^- vary slightly around 40 mm Hg and 24 mEq/L.
For simplicity, these numbers should be used as a normal baseline for acid-base calculations.

HCO_3^- = bicarbonate; **$PaCO_2$** = partial pressure of carbon dioxide in arterial blood.

©UWorld

Zoom In | Zoom Out | Reset | New | Existing | My Notebook

https://t.me/USMLEWorldStep1

A 46-year-old, previously healthy man develops sudden-onset, sharp, left-sided flank pain radiating to the groin. CT scan of the abdomen reveals a left ureteral calculus, which he passes spontaneously in the urine. Other, incidental findings include a left lower lobe lung nodule and foci of calcifications in the spleen. Chest imaging shows several small calcified nodules in both lungs and a calcified mediastinal lymph node. The patient has had no pulmonary symptoms and is a lifelong nonsmoker. He is a farmer who lives in Ohio and has not traveled recently. Physical examination reveals no abnormalities. Tuberculosis skin test shows a <5 mm induration at 48 hours. Repeat chest imaging 3 months later reveals no changes. Which of the following is the most likely cause of the observed findings in this patient?

- A. Fungal infection
- B. Metastatic cancer
- C. Miliary tuberculosis
- D. Parathyroid adenoma
- E. Silica exposure

Submit

https://t.me/USMLEWorldStep1

A 46-year-old, previously healthy man develops sudden-onset, sharp, left-sided flank pain radiating to the groin. CT scan of the abdomen reveals a left ureteral calculus, which he passes spontaneously in the urine. Other, incidental findings include a left lower lobe lung nodule and foci of calcifications in the spleen. Chest imaging shows several small calcified nodules in both lungs and a calcified mediastinal lymph node. The patient has had no pulmonary symptoms and is a lifelong nonsmoker. He is a farmer who lives in Ohio and has not traveled recently. Physical examination reveals no abnormalities. Tuberculosis skin test shows a <5 mm induration at 48 hours. Repeat chest imaging 3 months later reveals no changes. Which of the following is the most likely cause of the observed findings in this patient?

- ✓ A. Fungal infection (43%)
- ✗ B. Metastatic cancer (10%)
- C. Miliary tuberculosis (10%)
- D. Parathyroid adenoma (19%)
- E. Silica exposure (16%)

Incorrect
Correct answer
A

43%
Answered correctly

04 secs
Time Spent

2023
Version

Explanation

This patient has calcified lung, mediastinal, and splenic lesions that are stable over time and asymptomatic, raising suspicion for a contained **granulomatous infection**. The most likely cause is the dimorphic fungus ***Histoplasma capsulatum***, which exists as a mold in the soil of the **Ohio** and Mississippi River Valleys (midwestern/central United States)

https://t.me/USMLEWorldStep1

This patient has calcified lung, mediastinal, and splenic lesions that are stable over time and asymptomatic, raising suspicion for a contained **granulomatous infection**. The most likely cause is the dimorphic fungus ***Histoplasma capsulatum***, which exists as a mold in the soil of the **Ohio** and Mississippi River Valleys (midwestern/central United States).

The pathogen is inhaled into the lungs, where it converts to yeast form and is phagocytosed by alveolar macrophages. Macrophages cannot initially eliminate the organism due to microbial virulence factors that prevent phagolysosome formation and acidification. Therefore, *H capsulatum* is able to replicate within the macrophage and spread through the draining **lymphatic system** and (often) into the reticuloendothelial system (eg, **spleen**, liver).

After about 2 weeks, patients with intact immunity develop a cell-mediated immune response that contains the infection within granulomas. Over time, the granulomas fibrose and **calcify** and can be visualized on radiographic imaging at the initial sites of infection (eg, lungs, hilar and mediastinal lymph nodes, spleen). In healthy patients, most infections with *H capsulatum* are asymptomatic and are therefore often discovered incidentally during evaluation for an unrelated condition (eg, nephrolithiasis).

(Choice B) Metastatic cancer often causes multiple lung lesions. However, these lesions generally enlarge in size over time and calcification is rare.

(Choice C) Miliary tuberculosis is marked by multiple pulmonary lesions and clinical illness (eg, fever, night sweats); calcified lesions would be atypical. Although primary tuberculosis is often associated with a calcified lung and an ipsilateral hilar lymph node lesion (Ranke complex), tuberculosis is unlikely in this case given the patient's negative tuberculin skin test.

(Choice D) Parathyroid adenoma is a benign tumor that does not spread to the lungs; it is often associated with hypercalcemia due to increased secretion of parathyroid hormone. Although metastatic calcification can be a rare manifestion of hyperparathyroidism (it is more common with end-stage renal disease), such patients would almost

https://t.me/USMLEWorldStep1

liver).

After about 2 weeks, patients with intact immunity develop a cell-mediated immune response that contains the infection within granulomas. Over time, the granulomas fibrose and **calcify** and can be visualized on radiographic imaging at the initial sites of infection (eg, lungs, hilar and mediastinal lymph nodes, spleen). In healthy patients, most infections with *H capsulatum* are asymptomatic and are therefore often discovered incidentally during evaluation for an unrelated condition (eg, nephrolithiasis).

(Choice B) Metastatic cancer often causes multiple lung lesions. However, these lesions generally enlarge in size over time and calcification is rare.

(Choice C) Miliary tuberculosis is marked by multiple pulmonary lesions and clinical illness (eg, fever, night sweats); calcified lesions would be atypical. Although primary tuberculosis is often associated with a calcified lung and an ipsilateral hilar lymph node lesion (Ranke complex), tuberculosis is unlikely in this case given the patient's negative tuberculin skin test.

(Choice D) Parathyroid adenoma is a benign tumor that does not spread to the lungs; it is often associated with hypercalcemia due to increased secretion of parathyroid hormone. Although metastatic calcification can be a rare manifestion of hyperparathyroidism (it is more common with end-stage renal disease), such patients would almost certainly have systemic signs of hypercalcemia (eg, weakness, fatigue, depressed mood).

(Choice E) Silica inhalation can cause innumerable, small, rounded opacities in the upper lobes of the lungs that may fibrose over time, resulting in pulmonary disease. Silica exposure is primarily occupational (eg, miners, sandblasters).

Educational objective:
Histoplasma capsulatum replicates within macrophages and often spreads from the lungs through the pulmonary lymphatics to the reticuloendothelial system (eg, spleen, liver). Most healthy individuals quickly contain the infection within granulomas and do not become ill; a minority develop self-limited pneumonia. Over time, the granulomas at the initial sites of infection calcify and may be seen incidentally on radiographic imaging.

https://t.me/USMLEWorldStep1

macrophages. Macrophages cannot initially eliminate the organism due to microbial virulence factors that prevent phagolysosome formation and acidification. Therefore, *H capsulatum* is able to replicate within the macrophage and

liver

Afte
infec
imag
mos
eval

(Ch
over

(Ch
swe
and
nega

(Ch
hype
man
certa

(Ch
may
sand

Edu

Histoplasma capsulatum replicates within macrophages and often spreads from the lungs through the pulmonary

Exhibit Display

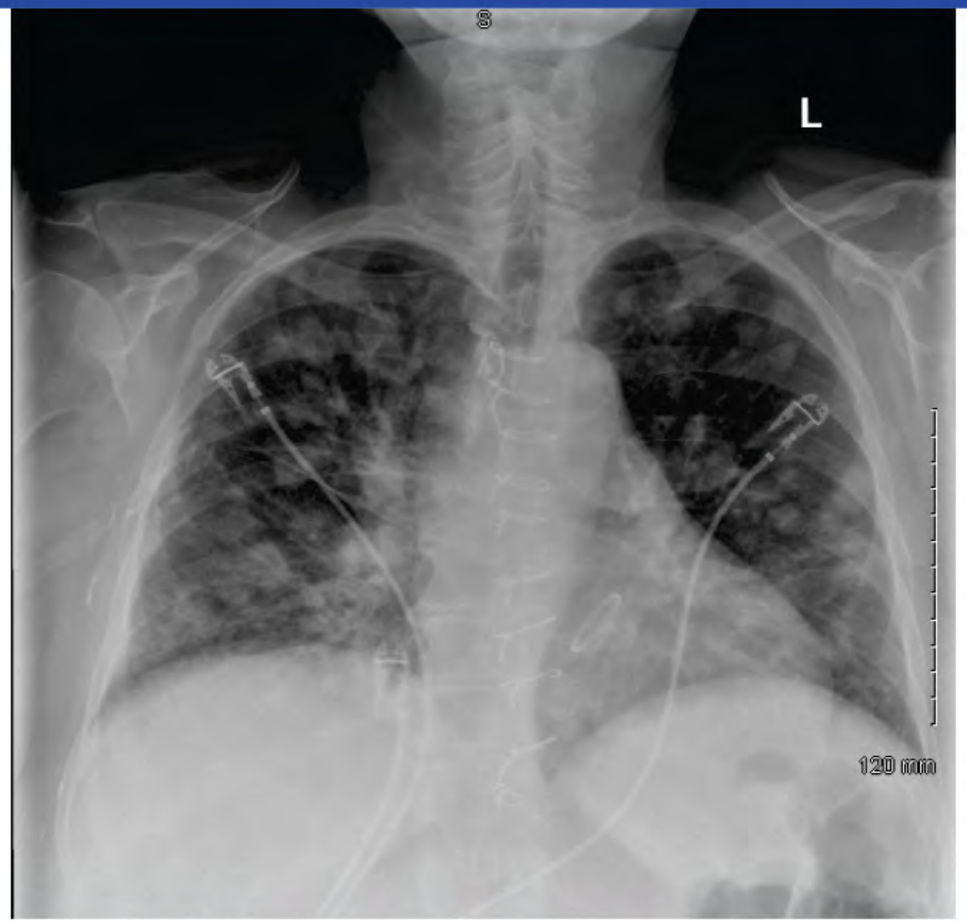

Zoom In | Zoom Out | Reset | New | Existing | My Notebook

https://t.me/USMLEWorldStep1

macrophages. Macrophages cannot initially eliminate the organism due to microbial virulence factors that prevent phagolysosome formation and acidification. Therefore, *H capsulatum* is able to replicate within the macrophage and liver

Afte
infec
imag
mos
eval

(Ch
over

(Ch
swe
and
nega

(Ch
hype
man
certa

(Ch
may
sand

Edu

Histoplasma capsulatum replicates within macrophages and often spreads from the lungs through the pulmonary

Exhibit Display

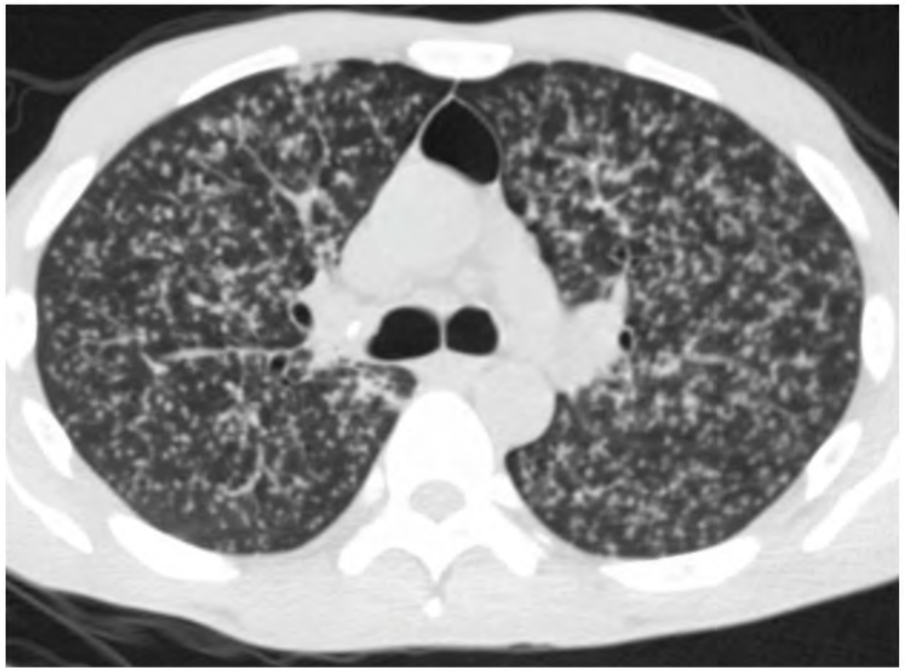

Zoom In | Zoom Out | Reset | New | Existing | My Notebook

https://t.me/USMLEWorldStep1

A 57-year-old man is being evaluated for progressive shortness of breath. His respiratory flow-volume curve is shown in red below.

Which of the following pathologic findings is most likely to be present in this patient?

- A. Alveolar hyaline membranes
- B. Compression atelectasis
- C. Interalveolar wall destruction
- D. Intraalveolar hemorrhage
- E. Pulmonary fibrosis
- F. Thromboembolic disease

Submit

https://t.me/USMLEWorldStep1

A 57 [illegible]
shov

Exhibit Display

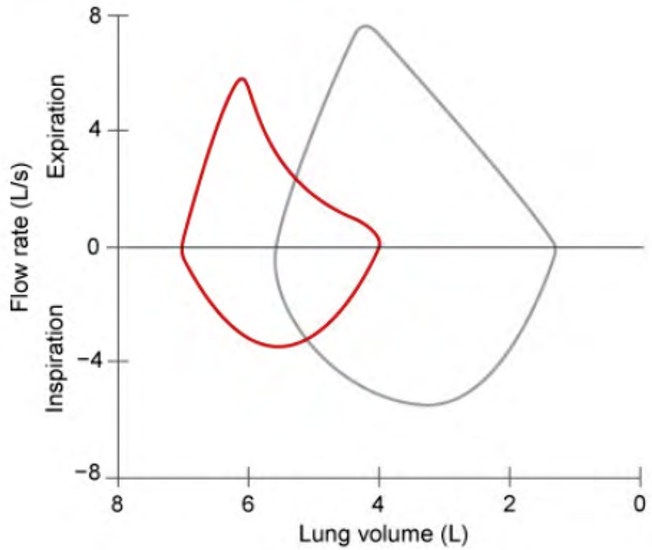

Zoom In Zoom Out Reset New | Existing My Notebook

Whi

https://t.me/USMLEWorldStep1

shown in red below.

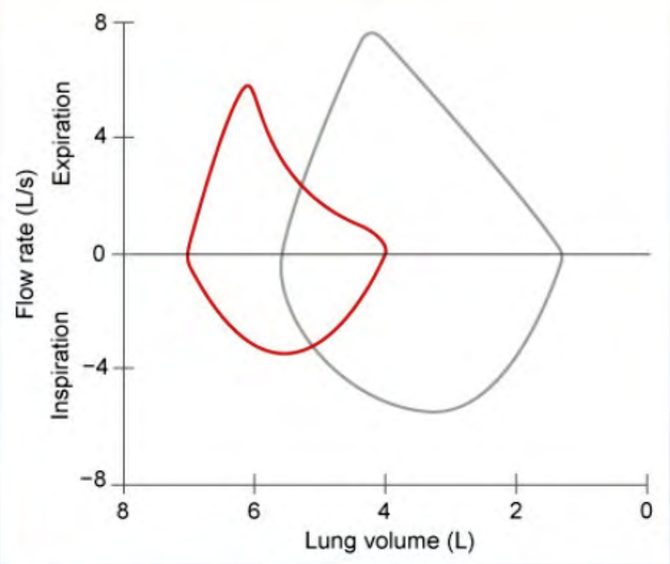

Which of the following pathologic findings is most likely to be present in this patient?

- A. Alveolar hyaline membranes
- B. Compression atelectasis
- C. Interalveolar wall destruction
- D. Intraalveolar hemorrhage
- E. Pulmonary fibrosis
- F. Thromboembolic disease

Submit

https://t.me/USMLEWorldStep1

shown in red below.

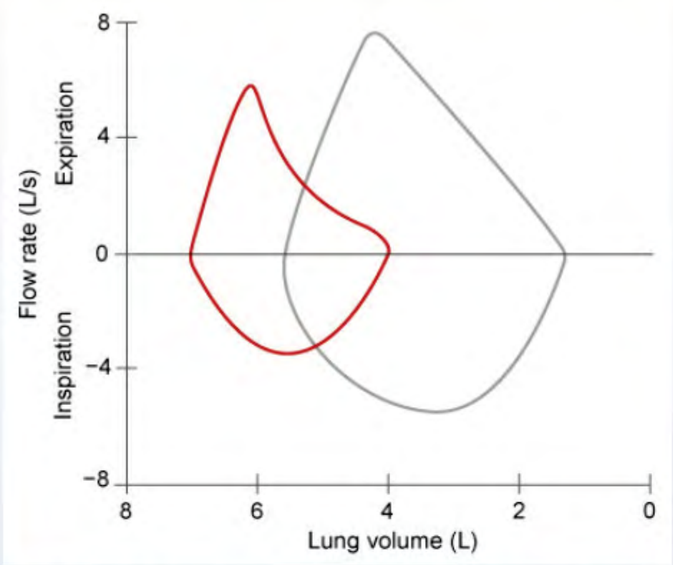

Which of the following pathologic findings is most likely to be present in this patient?

- A. Alveolar hyaline membranes (3%)
- ✗ B. Compression atelectasis (4%)
- ✓ C. Interalveolar wall destruction (63%)
- D. Intraalveolar hemorrhage (0%)
- E. Pulmonary fibrosis (26%)
- F. Thromboembolic disease (1%)

Incorrect
Correct answer
C

63%
Answered correctly

11 secs
Time Spent

2023
Version

https://t.me/USMLEWorldStep1

Exhibit Display

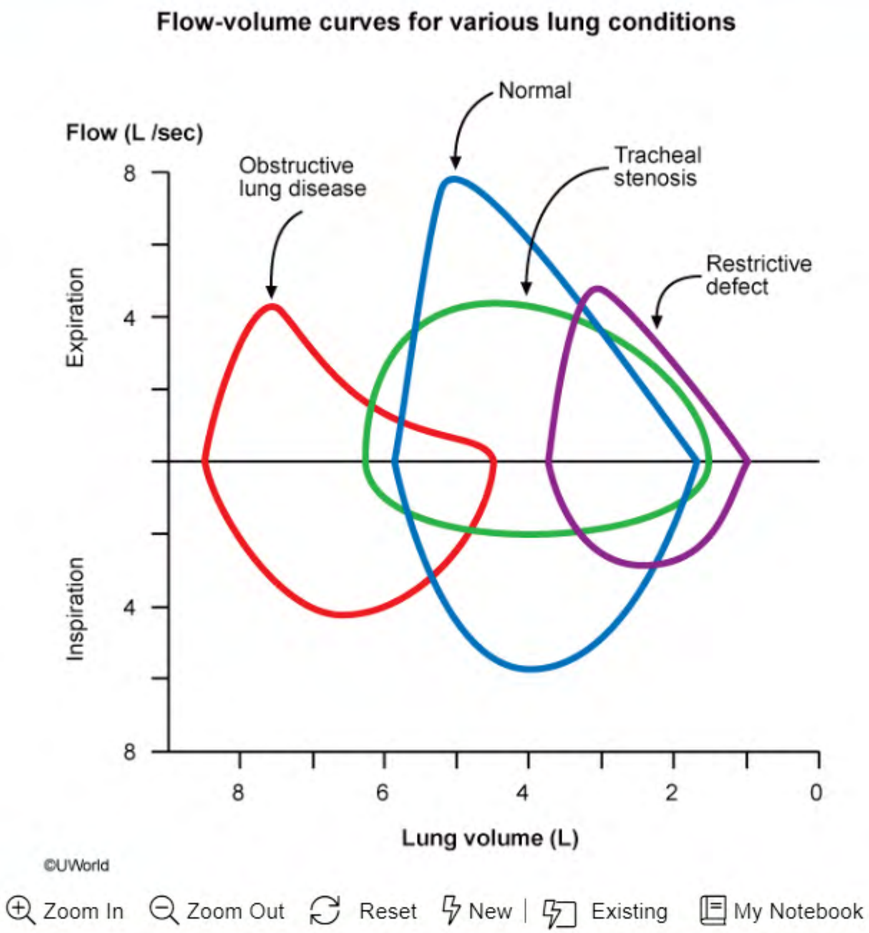

Zoom In | Zoom Out | Reset | New | Existing | My Notebook

Flov
This
volu
expi
in **ch**
narr
interalveolar walls (emphysema) promotes dynamic compression of the airways during expiration (intrapleural

https://t.me/USMLEWorldStep1

Flow-volume loops plot air velocity in relation to lung volume during a cycle of maximal inspiration and expiration. This patient's flow-volume loop exhibits a leftward shift indicating **increased total lung capacity** and **residual volume**. In addition, there is a characteristic **"scooped-out" expiratory pattern** consistent with the reduced expiratory flow rates seen in obstructive lung disease. This hyperinflation and expiratory airflow obstruction occur in **chronic obstructive pulmonary disease** (COPD). Airflow obstruction in COPD is partially due to anatomic narrowing of the bronchi (chronic bronchitis). In addition, decreased lung elasticity resulting from **destruction of interalveolar walls** (emphysema) promotes dynamic compression of the airways during expiration (intrapleural pressure becomes greater than airway pressure), further contributing to expiratory airflow obstruction.

Hyperinflation in COPD also reduces the inspiratory reserve volume, limiting the maximal tidal volume. This is especially true during exercise, when expiration time is limited. Because patients with COPD require extra time for exhalation, increasing amounts of air can become trapped in the lungs during rapid breathing, leading to further reduction in tidal volume. This is known as **dynamic hyperinflation** and is believed to be a major cause of dyspnea and exercise limitation in COPD.

(Choice A) Alveolar hyaline membranes are seen in acute respiratory distress syndrome. The pulmonary edema tends to reduce lung compliance, causing a restrictive flow-volume pattern (purple curve).

(Choice B) Atelectasis due to extrinsic pulmonary compression may occur when the pleural cavity fills with air (ie, pneumothorax) or fluid (eg, exudate, blood). Lung volumes and total lung compliance are likely reduced under such conditions, producing a restrictive flow-volume pattern.

(Choice D) Diffuse intraalveolar hemorrhage tends to dilute alveolar surfactant, increasing alveolar surface tension and promoting alveolar atelectasis. These changes would reduce lung volumes and lung compliance, resulting in a restrictive flow-volume pattern.

(Choice E) Pulmonary fibrosis tends to decrease lung volume and compliance, producing a restrictive pattern. In restrictive diseases, total lung capacity and residual volume are reduced. The expiratory flow rate is increased relative to the low lung volumes but is reduced compared to normal peak expiratory flow rates.

https://t.me/USMLEWorldStep1

Hyperinflation in COPD also reduces the inspiratory reserve volume, limiting the maximal tidal volume. This is especially true during exercise, when expiration time is limited. Because patients with COPD require extra time for exhalation, increasing amounts of air can become trapped in the lungs during rapid breathing, leading to further reduction in tidal volume. This is known as **dynamic hyperinflation** and is believed to be a major cause of dyspnea and exercise limitation in COPD.

(Choice A) Alveolar hyaline membranes are seen in acute respiratory distress syndrome. The pulmonary edema tends to reduce lung compliance, causing a restrictive flow-volume pattern (purple curve).

(Choice B) Atelectasis due to extrinsic pulmonary compression may occur when the pleural cavity fills with air (ie, pneumothorax) or fluid (eg, exudate, blood). Lung volumes and total lung compliance are likely reduced under such conditions, producing a restrictive flow-volume pattern.

(Choice D) Diffuse intraalveolar hemorrhage tends to dilute alveolar surfactant, increasing alveolar surface tension and promoting alveolar atelectasis. These changes would reduce lung volumes and lung compliance, resulting in a restrictive flow-volume pattern.

(Choice E) Pulmonary fibrosis tends to decrease lung volume and compliance, producing a restrictive pattern. In restrictive diseases, total lung capacity and residual volume are reduced. The expiratory flow rate is increased relative to the low lung volumes but is reduced compared to normal peak expiratory flow rates.

(Choice F) In pulmonary thromboembolism there is decreased perfusion but minimal effect on ventilation. Therefore, the flow-volume curve will remain mostly normal.

Educational objective:
The flow-volume loop for chronic obstructive pulmonary disease is characterized by increased residual volume and total lung capacity, as well as a "scooped-out" expiratory pattern due to reduced expiratory flow rates. Both airway narrowing due to chronic bronchitis and decreased elasticity due to emphysematous destruction of interalveolar walls are responsible for the hyperinflation and airflow limitation.

https://t.me/USMLEWorldStep1

8 6 4 2 0

Exhibit Display

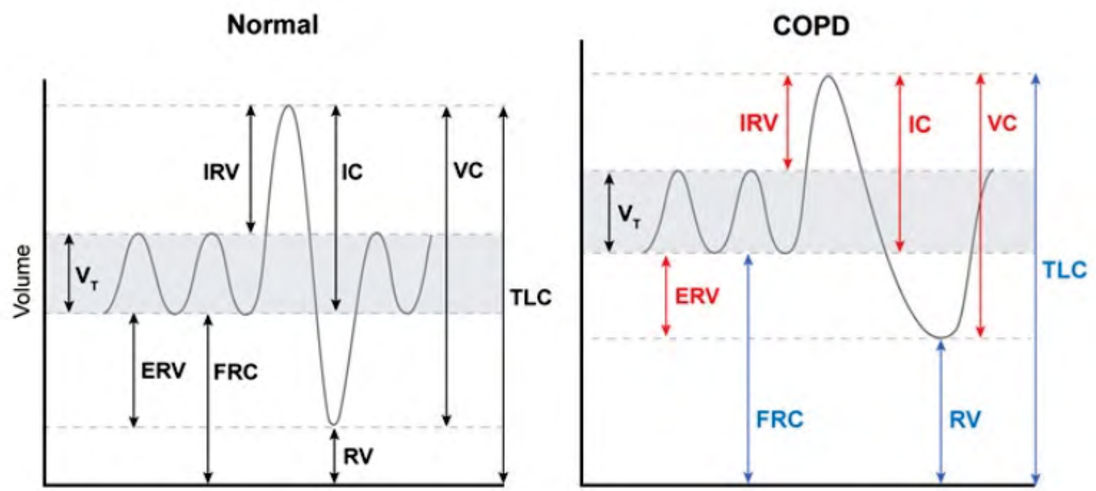

COPD = chronic obstructive pulmonary disease; **ERV** = expiratory reserve volume; **FRC** = functional residual capacity; **IC** = inspiratory capacity; **IRV** = inspiratory reserve volume; **RV** = residual volume; **TLC** = total lung capacity; **VC** = vital capacity; V_T = tidal volume.
©UWorld

Zoom In Zoom Out Reset New | Existing My Notebook

Flow-volume
This patient's f
volume. In ad
expiratory flow
in **chronic obs**
narrowing of th
interalveolar v
pressure becor

Hyperinflation i
especially true
exhalation, incr
reduction in tid
dyspnea and e

(Choice A) Alv
tends to reduce

(Choice B) At
pneumothorax
such condition

(Choice D) Di
tension and pr
resulting in a restrictive flow-volume pattern.

https://t.me/USMLEWorldStep1

A 46-year-old hospitalized man experiences worsening dyspnea and hypoxemia. The patient was admitted 2 days ago due to alcohol-induced acute pancreatitis. He has no history of cardiopulmonary disorders. Chest x-ray reveals new bilateral infiltrates. His respiratory condition progressively deteriorates and endotracheal intubation is performed. Mechanical ventilation with a lung-protective strategy is begun and a positive end-expiratory pressure of 10 cm H_2O is applied. Which of the following is the most likely effect of this latter intervention?

- A. Decreased alveolar pressure
- B. Decreased intrapleural pressure
- C. Increased functional residual capacity
- D. Increased intrapulmonary shunting
- E. Increased minute ventilation

Submit

https://t.me/USMLEWorldStep1

A 46-year-old hospitalized man experiences worsening dyspnea and hypoxemia. The patient was admitted 2 days ago due to alcohol-induced acute pancreatitis. He has no history of cardiopulmonary disorders. Chest x-ray reveals new bilateral infiltrates. His respiratory condition progressively deteriorates and endotracheal intubation is performed. Mechanical ventilation with a lung-protective strategy is begun and a positive end-expiratory pressure of 10 cm H_2O is applied. Which of the following is the most likely effect of this latter intervention?

- A. Decreased alveolar pressure (14%)
- ✗ B. Decreased intrapleural pressure (18%)
- ✓ C. Increased functional residual capacity (42%)
- D. Increased intrapulmonary shunting (5%)
- E. Increased minute ventilation (19%)

Incorrect
Correct answer
C

42%
Answered correctly

08 secs
Time Spent

2023
Version

Explanation

Acute respiratory distress syndrome	
Risk factors	• Sepsis, pneumonia • Trauma • Pancreatitis
	• Cytokine release, endothelial activation

https://t.me/USMLEWorldStep1

Acute respiratory distress syndrome	
Risk factors	• Sepsis, pneumonia • Trauma • Pancreatitis
Pathophysiology	• Cytokine release, endothelial activation • Neutrophil recruitment & degranulation in lung • ↑ Capillary permeability, alveolar fluid accumulation • Formation of hyaline membrane
Clinical features	• Hypoxia • Bilateral pulmonary infiltrates • Normal pulmonary capillary wedge pressure (6-12 mm Hg)

This hospitalized patient with worsening hypoxemia and bilateral lung infiltrates mostly likely has **acute respiratory distress syndrome** (ARDS), a potential complication of acute pancreatitis. ARDS involves an inflammatory response in the lungs that leads to alveolar capillary leakage and diffuse pulmonary edema; the edema prevents ventilation of affected alveoli and facilitates alveolar collapse, leading to increased intrapulmonary shunting (perfusion without ventilation). In addition, functional residual capacity (FRC) (ie, the volume of air in the lungs at end-tidal expiration) is reduced.

Mechanical ventilation is typically needed for the management of ARDS because it allows for the application of **positive end-expiratory pressure** (PEEP). PEEP helps treat ARDS by **opening collapsed alveoli** to reduce intrapulmonary shunting **(Choice D)** and **increase FRC** back to near-normal levels. The increase in FRC has the following beneficial effects:

- There is a critical lung capacity (ie, closing capacity) at which some of the lung's small airways collapse during

https://t.me/USMLEWorldStep1

Clinical features	• Bilateral pulmonary infiltrates • Normal pulmonary capillary wedge pressure (6-12 mm Hg)

This hospitalized patient with worsening hypoxemia and bilateral lung infiltrates mostly likely has **acute respiratory distress syndrome** (ARDS), a potential complication of acute pancreatitis. ARDS involves an inflammatory response in the lungs that leads to alveolar capillary leakage and diffuse pulmonary edema; the edema prevents ventilation of affected alveoli and facilitates alveolar collapse, leading to increased intrapulmonary shunting (perfusion without ventilation). In addition, functional residual capacity (FRC) (ie, the volume of air in the lungs at end-tidal expiration) is reduced.

Mechanical ventilation is typically needed for the management of ARDS because it allows for the application of **positive end-expiratory pressure** (PEEP). PEEP helps treat ARDS by **opening collapsed alveoli** to reduce intrapulmonary shunting **(Choice D)** and **increase FRC** back to near-normal levels. The increase in FRC has the following beneficial effects:

- There is a critical lung capacity (ie, closing capacity) at which some of the lung's small airways collapse during expiration (due to decreased radial traction at lower lung volumes). When FRC drops below this critical capacity, alveoli supplied by the collapsed airways are without ventilation for part of the respiratory cycle, which contributes to intrapulmonary shunting and increases ventilation-perfusion mismatching. Increasing FRC minimizes the time spent below closing capacity and in doing so **decreases ventilation-perfusion mismatching**.
- Because the FRC air volume remains in the lungs throughout the respiratory cycle, it acts as a store of oxygen that the body can pull from during brief periods of increased need. Therefore, increasing FRC **increases the oxygen reserves** in the lungs.

(Choice A) PEEP increases, rather than decreases, alveolar pressure, which has the negative effect of increasing the risk of pulmonary barotrauma.

(Choice B) Intrapleural pressure is normally negative throughout the respiratory cycle due to the opposing

https://t.me/USMLEWorldStep1

- There is a critical lung capacity (ie, closing capacity) at which some of the lung's small airways collapse during expiration (due to decreased radial traction at lower lung volumes). When FRC drops below this critical capacity, alveoli supplied by the collapsed airways are without ventilation for part of the respiratory cycle, which contributes to intrapulmonary shunting and increases ventilation-perfusion mismatching. Increasing FRC minimizes the time spent below closing capacity and in doing so **decreases ventilation-perfusion mismatching**.
- Because the FRC air volume remains in the lungs throughout the respiratory cycle, it acts as a store of oxygen that the body can pull from during brief periods of increased need. Therefore, increasing FRC **increases the oxygen reserves** in the lungs.

(Choice A) PEEP increases, rather than decreases, alveolar pressure, which has the negative effect of increasing the risk of pulmonary barotrauma.

(Choice B) Intrapleural pressure is normally negative throughout the respiratory cycle due to the opposing elasticity of the lungs (tend to collapse) and chest wall (tends to expand). Increased end-expiratory airway pressure during PEEP reduces the collapsing force of the lungs, causing the intrapleural pressure to increase.

(Choice E) Minute ventilation is determined by the product of tidal volume and respiratory rate. PEEP causes breathing to occur at a higher baseline lung volume (ie, higher FRC), but tidal volume and respiratory rate are not directly affected, and minute ventilation is unchanged.

Educational objective:
Positive end-expiratory pressure helps treat acute respiratory distress syndrome by opening collapsed alveoli to reduce intrapulmonary shunting and increase functional residual capacity (FRC). The increased FRC decreases ventilation-perfusion mismatching and increases the oxygen reserves in the lungs.

References

- Physiology, functional residual capacity.

https://t.me/USMLEWorldStep1

	• Formation of hyaline membrane

This hospitaliz
distress synd
response in the
ventilation of a
(perfusion with
end-tidal expira

Mechanical ve
positive end-e
intrapulmonary
following benef

- There is a
expiration
capacity, a
which con
FRC minir
mismatch
- Because t
that the bo
oxygen re

Exhibit Display

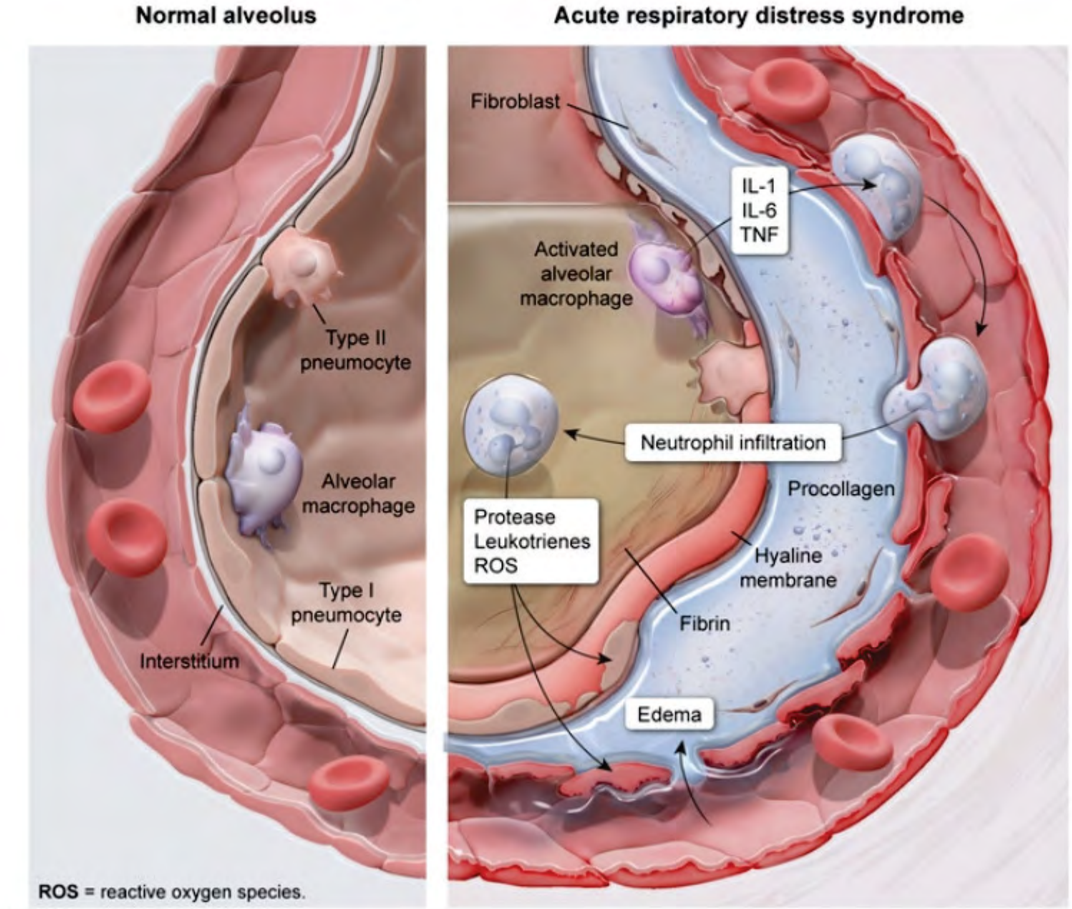

Zoom In | Zoom Out | Reset | New | Existing | My Notebook

https://t.me/USMLEWorldStep1

- Formation of hyaline membrane

Exhibit Display

This hospitalize
distress syndr
response in the
ventilation of a
(perfusion with
end-tidal expira

Mechanical ve
positive end-e
intrapulmonary
following benef

- There is a
expiration
capacity, a
which con
FRC minir
mismatch
- Because t
that the bo
oxygen re

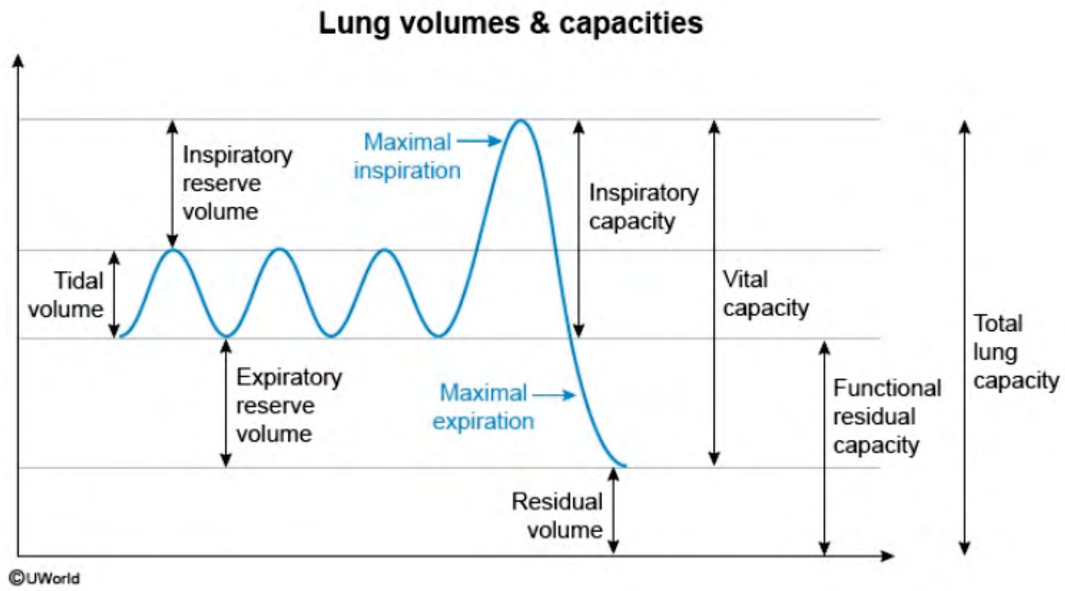

Zoom In | Zoom Out | Reset | New | Existing | My Notebook

https://t.me/USMLEWorldStep1

distress syndrome (ARDS), a potential complication of acute pancreatitis. ARDS involves an inflammatory

resp

vent

(per

end-

Mec

pos

intra

follo

-

-

(Ch

the

(Ch

elas

pres

(Choice E) Minute ventilation is determined by the product of tidal volume and respiratory rate. PEEP causes

Exhibit Display

Functional residual capacity and closing capacity in ARDS

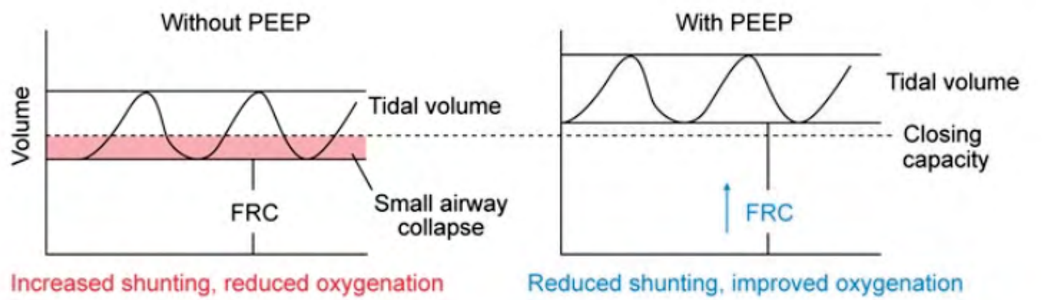

ARDS = acute respiratory distress syndrome; **FRC** = functional residual capacity; **PEEP** = positive end-expiratory pressure. ©UWorld

Zoom In | Zoom Out | Reset | New | Existing | My Notebook

https://t.me/USMLEWorldStep1

A 62-year-old man comes to the physician because of recent weight loss, cough, and occasional hemoptysis. His past medical history is significant for poorly controlled diabetes mellitus and chronic obstructive pulmonary disease treated with bronchodilators and oral corticosteroids. Chest x-ray shows pulmonary infiltrates and an area of cavitation in the right upper lobe. Sputum microscopy shows acid-fast bacilli. Which of the following is the most accurate statement concerning this patient's pulmonary infection?

- A. First exposure to the bacilli occurred recently
- B. Healing of the lung lesion would result in Ghon complex formation
- C. It originated from reactivation of an old infection
- D. It was facilitated by low levels of protective antibodies
- E. Negative tuberculin skin test would signify strong cell-mediated immunity

Submit

https://t.me/USMLEWorldStep1

A 62-year-old man comes to the physician because of recent weight loss, cough, and occasional hemoptysis. His past medical history is significant for poorly controlled diabetes mellitus and chronic obstructive pulmonary disease treated with bronchodilators and oral corticosteroids. Chest x-ray shows pulmonary infiltrates and an area of cavitation in the right upper lobe. Sputum microscopy shows acid-fast bacilli. Which of the following is the most accurate statement concerning this patient's pulmonary infection?

- A. First exposure to the bacilli occurred recently (3%)
- ✗ B. Healing of the lung lesion would result in Ghon complex formation (8%)
- ✓ C. It originated from reactivation of an old infection (84%)
- D. It was facilitated by low levels of protective antibodies (2%)
- E. Negative tuberculin skin test would signify strong cell-mediated immunity (0%)

Incorrect
Correct answer
C

84%
Answered correctly

04 secs
Time Spent

2023
Version

Explanation

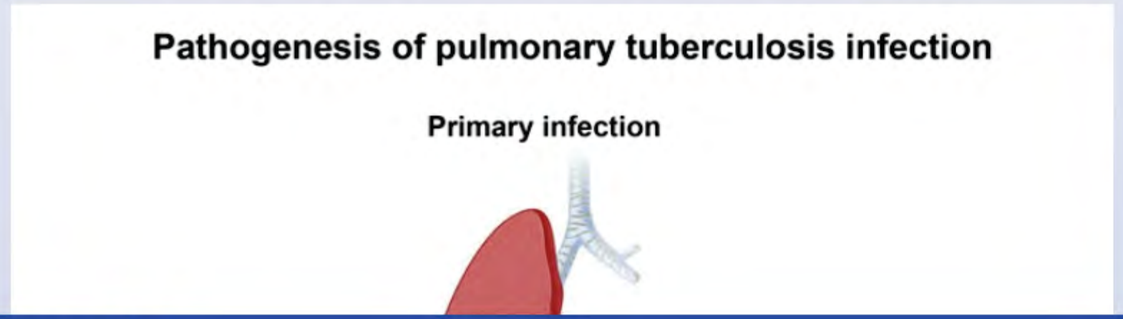

https://t.me/USMLEWorldStep1

A 62-year-old man comes to the physician because of recent weight loss, cough, and occasional hemoptysis. His past medical h
treated with br
cavitation in th
accurate stater

- A. Firs
- ✕ B. Hea
- ✓ C. It o
- D. It w
- E. Neg

Incorrect
Correct answer
C

Explanation

Exhibit Display

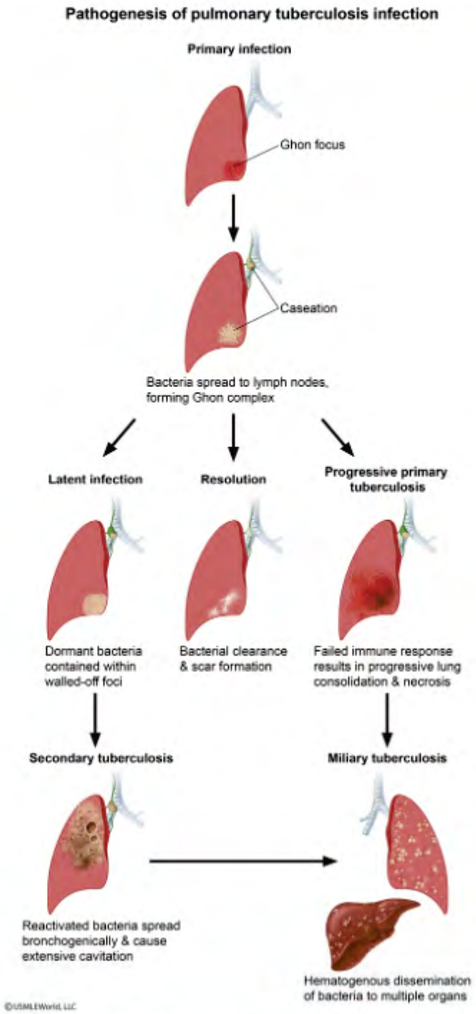

Zoom In | Zoom Out | Reset | New | Existing | My Notebook

https://t.me/USMLEWorldStep1

of bacteria to multiple organs

©USMLEWorld, LLC

This patient's symptoms (cough, hemoptysis, weight loss), acid-fast bacilli on sputum culture, and upper lobe cavitary lesion are suggestive of **secondary (reactivation) tuberculosis**. His advanced age, multiple comorbidities, and partial immune suppression secondary to chronic oral corticosteroid use also place him at risk for reactivation disease.

Primary tuberculosis infection occurs following inhalation of aerosolized *Mycobacterium tuberculosis*. The organisms are deposited in the lower lungs and phagocytosed by alveolar macrophages, where they proliferate until the macrophages are activated by T_H1 lymphocytes. The infection can be subsequently eliminated if the area of involvement is small enough. However, larger regions of caseating necrosis become walled off, allowing *M tuberculosis* to survive in a dormant state without causing disease or symptoms. Later in life (usually following immunosuppression by drugs or HIV) the bacteria can **reactivate** and establish infection in the **upper lungs** (particularly the apex). The predilection for upper lung regions may be related to decreased lymphatic flow or increased oxygen tension. The organisms multiply in the apices, causing caseous and liquefactive necrosis and extensive **cavitary disease**. Erosion into the pulmonary vessels can result in severe hemoptysis. Hematogenous dissemination may also occur, causing miliary or extrapulmonary (eg, Potts disease, tuberculous meningitis) tuberculosis.

(Choice A) Primary tuberculosis infection often begins as a focal lesion in the mid-to-lower lungs (Ghon focus). *M tuberculosis* then spreads lymphatically to the hilar lymph nodes, forming a Ghon complex. The organisms can remain dormant in a walled-off Ghon complex for many years before reactivating. Alternatively, the lesion may heal, forming a benign, calcified Ranke complex that is not associated with reactivation tuberculosis.

(Choice B) A Ghon complex forms during primary tuberculosis infection and consists of a Ghon focus and hilar lymphadenopathy. This patient's upper lung involvement and cavitary lesion are more characteristic of secondary (reactivation) tuberculosis. Healing of this lesion would result in a persistent cavity that may become secondarily infected with *Aspergillus flavus* and form fungus balls.

https://t.me/USMLEWorldStep1

immunosuppression by drugs or HIV) the bacteria can **reactivate** and establish infection in the **upper lungs** (particularly the apex). The predilection for upper lung regions may be related to decreased lymphatic flow or increased oxygen tension. The organisms multiply in the apices, causing caseous and liquefactive necrosis and extensive **cavitary disease**. Erosion into the pulmonary vessels can result in severe hemoptysis. Hematogenous dissemination may also occur, causing miliary or extrapulmonary (eg, Potts disease, tuberculous meningitis) tuberculosis.

(Choice A) Primary tuberculosis infection often begins as a focal lesion in the mid-to-lower lungs (Ghon focus). *M tuberculosis* then spreads lymphatically to the hilar lymph nodes, forming a Ghon complex. The organisms can remain dormant in a walled-off Ghon complex for many years before reactivating. Alternatively, the lesion may heal, forming a benign, calcified Ranke complex that is not associated with reactivation tuberculosis.

(Choice B) A Ghon complex forms during primary tuberculosis infection and consists of a Ghon focus and hilar lymphadenopathy. This patient's upper lung involvement and cavitary lesion are more characteristic of secondary (reactivation) tuberculosis. Healing of this lesion would result in a persistent cavity that may become secondarily infected with *Aspergillus flavus* and form fungus balls.

(Choice D) *M tuberculosis* is a facultative intracellular bacterium that can survive and multiply within macrophages; as a result, circulating antibodies cannot bind it to promote phagocytosis or complement-mediated killing. Therefore, humoral immunity plays no role in the control of *M tuberculosis*.

(Choice E) A negative skin tuberculin test after *M tuberculosis* exposure suggests anergy against tuberculosis antigens and a weak cell-mediated immune response. This can occur in the setting of HIV, sarcoidosis, and other illnesses.

Educational objective:
Primary tuberculosis causes the formation of Ghon foci in the lower lungs. Secondary (reactivation) tuberculosis occurs in patients with prior tuberculosis infection that never cleared completely. Reactivation tuberculosis occurs most often in immunosuppressed patients and is characterized by apical cavitary lesions and hemoptysis.

https://t.me/USMLEWorldStep1